

Basement

8-11-50

Digitized by the Internet Archive
in 2007 with funding from
Microsoft Corporation

OPERATIVE SURGERY

BY

JOSEPH D. BRYANT, M. D.

Professor of the Principles and Practice of Surgery, Operative and Clinical Surgery, University and Bellevue Hospital Medical College; Visiting Surgeon to Bellevue and St. Vincent's Hospitals; Consulting Surgeon to the Hospital for Ruptured and Crippled, Woman's Hospital, and Manhattan State Hospital for the Insane; former Surgeon-General of N. G. N. Y.; Fellow of the American Surgical Association; Member of the International Society of Surgeons, and of the American Medical Association; former President of the New York State Academy of Medicine, and of the New York State Medical Association; President of the New York State Medical Society, etc.

VOLUME I

GENERAL PRINCIPLES, ANÆSTHETICS, ANTISEPTICS, CONTROL OF HÆMORRHAGE AND SHOCK. TREATMENT OF OPERATION-WOUNDS, LIGATURE OF ARTERIES. OPERATIONS ON VEINS, CAPILLARIES, NERVOUS SYSTEM, TENDONS, LIGAMENTS, FASCIÆ, MUSCLES, BURSÆ, AND BONES. AMPUTATIONS, DEFORMITIES. PLASTIC SURGERY. OPERATIONS ON MOUTH, PHARYNX, NOSE, CÆSOPHAGUS, AND NECK

FOURTH EDITION, PRINTED FROM NEW PLATES
ENTIRELY REVISED AND LARGELY REWRITTEN

*THIS VOLUME CONTAINS
EIGHT HUNDRED AND NINETY-EIGHT ILLUSTRATIONS
SIXTY-ONE OF WHICH ARE COLORED*

NEW YORK AND LONDON
D. APPLETON AND COMPANY

1906

PHYSICS
COLLEGE

W0500
B915,0
1905
v. 1

COPYRIGHT, 1886, 1899, 1905,
By D. APPLETON AND COMPANY

All rights reserved

PRINTED AT THE APPLETON PRESS
NEW YORK, U. S. A.

TO

THE GRADUATES IN MEDICINE

WHOM IT HAS BEEN MY PLEASURE TO INSTRUCT IN ANATOMY AND
SURGERY DURING THE LAST TWENTY-FIVE YEARS,
AND IN RECOGNITION OF
THE UNIFORM COURTESY SHOWN BY THEM TO THE AUTHOR,
THIS WORK IS RESPECTFULLY INSCRIBED



PREFACE TO FOURTH EDITION.

THE rapid absorption of the repeated issues of the third edition, the warmth of the commendations bestowed upon it, the accelerated pace of surgery in various respects and the repeated requests of many whose support and friendship the author holds in high esteem, have hastened the preparation of the fourth edition. This edition contains about two hundred and fifty pages and two hundred and thirty illustrations more than the preceding one. It has been entirely revised, much of it rewritten, and new matter introduced. Some things more or less obsolete are retained in this edition, mainly for sentimental reasons. As in the preceding editions, earnest efforts are made to give due credit to those whose labors have added interest and usefulness to its pages, and any failure to do so is the result of inadvertence, not of intent. The author begs to express his great indebtedness to Prof. William C. Lusk, M. D., for the revision and advancement of the chapter on the rectum; to Prof. Hermann A. Haubold, M. D., for his painstaking search for items adding renewed usefulness to "The Results"; to Dr. William M. Ford for the thorough index so patiently prepared; and also to Dr. Thomas L. Bennett, an anæsthetist of broad experience, to whom we are largely indebted for the practical considerations given to anæsthesia. The artists, the artisans, and the publishers have vied with each other in enhancing the value of the products of the author's labors. With profound thanks to the members of the profession for the evidences of appreciation so freely bestowed on the past editions, the author humbly submits the present one for such consideration as it may justly merit.

JOSEPH D. BRYANT, M. D.

32 WEST FORTY-EIGHTH STREET, NEW YORK.

m u 7

PREFACE TO THIRD EDITION.

THE flattering reception of the second edition, and the requests of many interested friends that a third be written, prompted me about four years ago to begin the task. But the frequent and somewhat extended interruptions begotten of the demands of life's activities, together with the determination to extend the scope and size of the work, have unexpectedly delayed its publication. Besides, the rapid advance in the last few years of surgical endeavor has greatly increased the amount and complicated the character of the labor required for the purpose. The general policy of arrangement of the work is maintained, and, as in the past, frequent references are made to the labors and sayings of others, to all of which credit is given in the text or in the index. Special effort is made to eliminate from the faces of the illustrations all evidences suggestive of commercial thrift. Much is gained in this respect by the introduction of half-tone groups of instruments and by the gracious co-operation of Mr. Ford. An index of illustrations, in which due credit is given to all, is introduced. The operations peculiar to the female sex, and of the eye and ear, are omitted in this, as in the preceding editions, and for similar reasons. The valuable services of Professors George D. Stewart and William C. Lusk, in connection with proof reading and indexing, are especially painstaking, and are gratefully acknowledged. The artists, Messrs. Mason (photographer to Bellevue Hospital) and Senior, vied with each other in their efforts to produce proper illustrative effects. In conclusion, it is hoped and believed that the reader will find in the following pages sufficient of interest and importance to justify the use of the time employed by himself and the author in their consideration.

JOSEPH D. BRYANT, M.D.

54 WEST THIRTY-SIXTH STREET, NEW YORK.

PREFACE TO SECOND EDITION.

THE frequent request on the part of those whom it has been my pleasure to instruct in operative surgery during the past few years, to make a book based somewhat on the plan I have employed in teaching this subject, is the principal incentive to my action. The field of operative surgery is too well cultivated already for one to do more in this brief space than aid the student of surgery to acquire established facts. The works of Ashhurst, Agnew, Gross, Erichsen, Holmes, Smith, Esmarch, Packard, Stimson, and many others, together with the current medical literature, have been consulted. The illustrations, which are numerous, have been selected in most instances from standard works, although a considerable number of original and modified illustrations have been introduced. Mr. W. F. Ford, of the reputable firm of Caswell, Hazard & Co., of this city, kindly provided the instrumental cuts, as is to be seen by the Index of Illustrations. The author desires to acknowledge the aid derived from the above-mentioned sources, and trusts the reader will find something to commend in the pages that are to follow. The author regrets that sufficient data are not at hand to permit the "results" to be given in all instances as modified by the antiseptic method of treatment. The operations peculiar to the female sex, and the eye and ear, have not been considered, since they are entitled, in the opinion of the author, to a more extended consideration than the intentional scope of this work will admit. The author desires to acknowledge the valuable services of Drs. Glover, C. Arnold, and Hermann M. Biggs, in connection with the proof reading, and of Dr. Arnold also for the complete indices of the book. The assistance of Dr. A. H. Doty in preparing many of the original illustrations is likewise gratefully acknowledged.

JOSEPH D. BRYANT, M. D.



CONTENTS OF VOLUME I.

CHAPTER I.

THE GENERAL CONSIDERATIONS.

	PAGE
Definition of operative surgery—Facts to be ascertained before operating—Time for operation—Place for operation—Sick-room—Nursing—Diet—Requirements relating to operations—How to prepare patient for anæsthesia—How to prepare administrator of anæsthetic—Treatment of anæsthetic poison—Dangers of use of anæsthetic—Inhalers—Chloroform—A. C. E. mixture—Nitrous oxide—Gas and oxygen—Morphine with anæsthetics—Moderate inebriation—Oxygen anæsthesia—Rapid respiration—Local anæsthesia—Infiltration anæsthesia—Spinal anæsthesia—Cocain—Eucain—Instruments necessary for operations—Methods of holding scalpel—Blunt dissection—Incisions—Antiseptic and aseptic methods—Operating tables—Aseptic and antiseptic solutions—Sponges—Wipers, etc.	1

CHAPTER II.

AGENTS FOR THE CONTROL OF HEMORRHAGE.

Artificial hæmostatics—Styptics—Position—Bandages—Compresses—Digital pressure—Tourniquets—Davy's lever—Trendelenburg's rod—Wyeth's method—Torsion—Forceps—Forepressure—Cautery—Ligatures—How made—How tied—Assistants—Preparation of patient—Preparation of field of operation	65
--	----

CHAPTER III.

THE TREATMENT OF OPERATION-WOUNDS.

Sutures—Needles—Needle-holders—Various forms of sutures—Drainage tubes—Catgut drainage—Canalization—Protective dressings—Antiseptic douche—Antiseptic dressings—Objections to use of iodoform—Objections to bichloride gauze—Common preparations for a modern operation—Diagram of arrangements—Open dressing—Precautionary requirements of operations—Special emergencies of operations	96
--	----

CHAPTER IV.

THE LIGATURE OF ARTERIES.—GENERAL CONSIDERATIONS.

Guides to ligaturing—Making primary incision—Opening sheath of a vessel—Passing ligature—Instruments required for ligaturing—Ligature of abdominal aorta—Of common iliac artery—Of internal iliac artery—Of gluteal artery—Of pudic artery—Of dorsalis penis artery—Of external iliac artery—Of deep epigastric artery—Of deep circumflex iliac artery—Of superficial femoral artery—Of deep femoral artery—Of external circumflex artery—Of popliteal	
--	--

artery—Of anterior tibial artery—Of dorsalis pedis artery—Of posterior tibial artery—Of peroneal artery—Of innominate artery—Of subclavian arteries—Of internal mammary artery—Of inferior thyroid artery—Of axillary artery—Of brachial artery—Of radial and ulnar arteries—Of palmar arteries—Of common carotid artery—Of both common carotid arteries—Of the common carotid artery—Temporary ligature of common carotid—Ligature of the internal carotid—Of the superior thyroid artery—Of the lingual artery—Of the facial artery—Of the temporal artery—Of the occipital artery—Extirpation of aneurism—Radical cause of aneurism—Arteriorrhaphy—Phleborrhaphy.	125
--	-----

CHAPTER V.

OPERATIONS ON VEINS, CAPILLARIES, ETC.

Ligature of veins—Operations for varicose veins—Injection—Acupressure—Subcutaneous ligaturing—Excision—Venesection—Transfusion—With saline solution—Mother's mark, treatment of—Nævi, treatment of—Cirroid growths, treatment of	215
--	-----

CHAPTER VI.

OPERATIONS ON THE NERVOUS SYSTEM.

Operations for chronic hydrocephalus—For acute hydrocephalus—For meningocele—For encephalocele—Craniotomy, instruments employed in—Important considerations in—Craniotomy in meningeal hemorrhage—For microcephalus—For cerebral tumor, instruments employed in—Craniotomy for epilepsy—For evacuation of pus—For cerebellar tumor—For thrombosis of lateral sinus and jugular vein—For general paralysis of the insane—Opening the mastoid antrum, instruments employed in—Trepining the frontal sinus—Gunshot wounds of the cranium—Location of the missile—The precautions—The results.
Special operations on nerves—Nerve section or neurotomy—Nerve resection or neurectomy—Nerve stretching or neurectomy—Suture or neuroorrhaphy—Nerve grafting or neuroplasty—The methods of practice—The results.
Operations on special nerves—Operations on supra-orbital nerve—On supra-trochlear nerve—On infra-orbital nerve—On superior maxillary nerve—On Meckel's ganglion—On inferior dental nerve—On lingual nerve—On gustatory nerve—On auriculo-temporal nerve—On buccal nerve—On trunk at the foramen ovale.
Intracranial neurectomy, instruments employed in—Rose method—Hartley-Krause method—Stages of—Precautions—Complications—Results and sequels—Doyen's method—Cushing's method—Abbe's method—Spiller and Frazer method—Horsley's intradural method—Operations on the facial nerve—Cushing's for paralysis.
Operations on the spinal cord and spinal nerves—Laminectomy, instruments employed in—Examination of the contents of the canal—Opening of the dura—Results—Operation of spinal meningeal drainage—Parkin's operation—Spina bifida, operations for—Injection—Excision—Meningocele, operations for—Meningo-myelocoele, operations for—Tumors of the spinal cord—The operation for—The results—Spinal accessory nerve, operations on—Branches of the cervical nerves, operations on—Roots of the spinal nerves—Intraspinal, division of—Branches of the brachial plexus, operations on—On musculo-

cutaneous nerve—On musculo-spiral nerve—On circumflex nerve—On median nerve—On ulnar nerve—Branches of the sacral plexus, operations on—On great sciatic nerve—On internal popliteal nerve—On external popliteal nerve—On plantar nerves—On brachial nerves—On tibial nerve, etc.—Branches of the lumbar plexus, operations on—On anterior crural nerve—On obturator nerve—On long saphenous nerve—On short saphenous nerve 227

CHAPTER VII.

OPERATIONS ON TENDONS, LIGAMENTS, FASCIAS, MUSCLES, AND BURSAE.

Tenotomy, instruments employed in—Rules for—Tenotomy of tendons of flexor sublinis and flexor profundus digitorum muscles—Of extensor communis digitorum muscle—Of extensor brevis longus and ossis metacarpi pollicis muscles—Of flexor carpi radialis muscle—Of flexor carpi ulnaris muscle—Of the biceps muscle of the forearm, etc.—Of the tibialis posticus muscle—Of the flexor longus digitorum muscle—Of flexor longus pollicis muscle—Of tendo Achillis—Of peroneus longus and brevis muscles—Of tibialis anticus muscle—Of extensor proprius pollicis muscle—Of extensor longus digitorum muscle—Of peroneus tertius muscle—Of hamstring tendons—Of gracilis and sartorius muscles—Of quadriceps extensor—Of adductor longus muscle.

Myotomy—Of pectineus muscle—Of tensor vaginae femoris muscle—Of multifidus spinæ muscle—Of latissimus dorsi muscle—Of erector spinæ muscle—Of trapezius muscle—Of sterno-mastoid muscle, etc.

Tenorrhaphy, special considerations in—Tendon lengthening—Tendon shortening—Tendon transplantation—The results.

Myotomy, oblique division in—V-shaped division in—Syndesmotomy—Fasciotomy—Dupuytren's contraction, treatment of—Bursæ, treatment of—Thecitis, treatment of 329

CHAPTER VIII.

OPERATIONS ON BONES.

Gouging, instruments employed in—Schede's method of healing—Sequestrotomy, instruments employed in—Excisions of extremities, instruments employed in—Treatment of excision wounds—Excision of upper jaw, instruments employed in—Partial and complete excision—The lines of incision—Removal below the floor of the orbit—Various methods of practice—After-treatment—Results—Excision of lower jaw—Anatomical considerations—Remarks—Excision of central portion—Of a lateral portion—Of lateral half—Of alveolar process—Immobility of inferior maxilla, operations for—Excision of sternum—Excision of clavicle—Excision of entire scapula—Excision of body of the scapula—Excision of glenoid angle of scapula—Subperiosteal excision of scapula—Remarks—After-treatment—Results—Excision of humerus—Excision of upper end—Subperiosteal excision of head—Senn's method—Kocher's method—Arthrotoomy for irreducible dislocations—Operation for habitual dislocation—Excision of shaft—Excision of lower extremity—After-treatment—Results—Excision of elbow joint—Anatomical points—Hüter's method—Langenbeck's method—Lister's method—Ollier's method—After-treatment—Results—Excision of ulna—Excision of radius—Excision of lower extremities of bones of forearm—Excision of wrist joint—Langenbeck's method—Ollier's method—Lister's method, etc.—Precautions—After-treatment—Results—Excision of metacarpo-phalangeal joints—Excision of phalan-

geal joints—Excision of phalangeal joints of tarsus—Of metacarpo-phalangeal joints—Of tarso-metatarsal joints—Of dorsal joints—Of calcaneum—Of astragalus—Excisions of ankle joint—Langenbeck's method—Bush's method, etc.—Comments—After-treatment—Results—Wladimirow-Mikulicz operation—Excision of bones of leg—Excision of knee joint—Anatomical points—Mackenzie's method—Bird's method—Langenbeck's method—Ollier's method—Remarks—After-treatment—Results.	
Arthrectomy—Of knee—Of ankle—Results—Excision of patella—Excision of great trochanter—Excisions of hip joint—Anatomical points—Langenbeck's method—Barker's method—Sayre's method—General remarks—After-treatment—Results—Arthrotomy for old unreduced and irreducible dislocations of hip—Excision of coccyx.	
Osteotomy, instruments employed in—Comments—Subcutaneous division of the neck of femur—With saw—With chisel—Volkmann's method—Sayre's method—Congenital displacements of hip—Hoffa's operation—Lorenz's modification of—Remarks—Results—Bony ankylosis of knee joint—Linear osteotomy in—Cuneiform osteotomy in—General remarks.	
Genu valgum—Anatomical points—Macewen's method of treatment—Results—Ogston's method—Reeves's method—Chiene's method.	
Genu varum—Linear osteotomy in—Cuneiform osteotomy in—Hallux valgus—Methods of treatment of—Osteotomy for talipes—Davies-Colley method—Bradford's method—Phelps's open-incision method—Enucleation of astragalus, etc.	
Osteoplasty—Preparation of bone—Preparation of cavity—Filling of cavity and treatment of wound	356

CHAPTER IX.

AMPUTATIONS.—GENERAL CONSIDERATIONS.

General considerations—Serviceable stump—Proper lengths of flaps—Division of tissues—Classification of flaps—Instruments employed in amputation—Comparative merits of different flaps—Periosteal flap—Manner of grasping amputating knife—Of carrying it around limb—Sawing the bone—Use of retractors—Metal retractor—Catching and tying bleeding points.	
Amputations of upper extremities—General remarks—Amputation at phalangeal articulations—Conservatism illustrated—At metacarpo-phalangeal articulations—Amputation of thumb—Of little and index fingers—Amputation through metacarpal bone—Amputation of last four metacarpal bones—Amputation of inner three metacarpal bones—Amputation of four metacarpal bones with fingers—Amputations at wrist joint—Circular-flap method—Single palmar-flap method—Double-flap method—Radial-flap method—Remarks—Results—Amputations at forearm—Circular skin-flap method—Equilateral skin-flap method—Musculo-cutaneous-flap method—Comments—Results—Amputation at the elbow joint—Anatomical points—Elliptical-flap method—Circular method—Anterior single-flap method—Comments—Results—Amputations of arm—Circular-flap method—Irregular double-flap method—Antero-posterior-flap method—Long anterior- and small posterior-flap method—Teal's method—Amputations at surgical neck of humerus—Anatomical points—Oval method—Single external-flap method—Remarks—Results—Amputations at shoulder joint—External- and internal-flap method—Circular method—Racquet methods of Larrey and Spence—Wyeth's method of prevention of hæmorrhage in—Remarks—Results—Amputation above shoulder joint—Results	451

CHAPTER X.

AMPUTATION AT THE LOWER EXTREMITY.

	PAGE
Amputation of phalanges of toes—Amputation of first phalanx of great toe—Of last phalanx of great toe—Amputation of single toes—Of great and little toes—By single-flap method—By oval-flap method—By internal plantar-flap method—Amputation of two adjoining toes—Of all toes at metatarso-phalangeal joints—Amputations of metatarsal bones—Amputation through all these bones—Of great toe and metatarsal bone—Of little toe and metatarsal bone—Of whole or part of metatarsal bone—Lisfranc's amputation—Remarks—Modifications of—Chopart's amputation—Remarks—Results—Forbes's modification of—Irregular tarsal amputation—De Lignerolles's amputation—Verneuil's amputation—Hancock's operation—Tripier's operation—Amputations at ankle joint—Syme's method—Modifications of—Fallacies in—Results—Roux's method—Pirogoff's operation—Remarks—Results—Fergusson's modification of—Le Fort's modification of—Brüms's modification of—Esmarch's modification of Le Fort—Amputations at leg—Amputation of leg at lower third—Guyon's method—Duval's method—Author's method—Teale's method—Large posterior-flap method—Bilateral-flap method—Hood-flap method—Amputation of leg at middle third—By large posterior-flap method—By long external-flap method—Amputation of leg at upper third—By long external-flap method—By circular-flap method—By bilateral-flap method—Amputations at knee joint—Anatomical points—Amputation by bilateral-flap method—By elliptical-flap method—By circular-flap method—By long anterior-flap method—S. Smith's amputation at knee joint for gangrene of toes and foot—Amputation of thigh through condyles by Carden's method—By Gritti's method—Bier and Eiselsberg's method—Bier's method—By Sabanwjeff's method—Amputations of thigh—Special considerations—Amputation by equilateral-flap method—By bilateral-flap method—By antero-posterior musculo-integumentary-flap method—By circular integumentary-flap method—By high circular-incision method—By long anterior-flap method—By long antero-posterior-flap methods—General remarks—After-treatment—Results—Amputations at hip—Methods of control of hæmorrhage in—Pancoast's, Esmarch's, and Lister's tourniquets—Trendelenburg's rod—Davy's lever—Brandis's method—Wyeth's method—McBurney's method—Senn's method—Amputation at hip by external-racquet method—By anterior-racquet method—By long anterior- and short posterior-flap methods—By circular-flap method—By Furneaux Jordan method—By antero-posterior-flap method—By single-flap method—After-treatment—Results.	496

CHAPTER XI.

DEFORMITIES.

Congenital or acquired— <i>Brisement forcé</i> in ankylosis—Barton's operation in ankylosis—Curvature of the spine—Sayre's apparatus for—Deformities dependent upon perverse muscular action—Torticollis, treatment of—Hammer-toe, treatment of—Snap finger, treatment of—Deformities due to fusion—Polydactylism—Syndactylism—The various methods of treatment—Diday's method—Agnew's method—Zeller's method—Fowler's method, etc.—Ingrown toe nail—The operation for—Anger's method—Cotting's method—Dowd's experience—Bunion, complications and treatment of	558
---	-----

CHAPTER XII.

PLASTIC SURGERY.

PAGE

Definition of—The preparation of patient—Size of flap—Instruments employed in—Methods of practice in—Sliding in direct line—Four varieties of—Sliding in curved line—Dieffenbach's methods—Burow's methods—Jaesche-Dieffenbach's method—Litteneur's method—Brüns's method—Weber's method—Jumping—Pedicle not twisted—Pedicle much twisted—Inversion—Eversion—Tagliacotian operation—Grafting—With heteroplastic substances—Skin grafting—Reverdin's method—Thiersch's method—Krause's method—Lusk's method—Croft's operation for cicatricial contraction—Flaps with single and double pedicles—Rhinoplasty—the French method—Syme's operation—Ellis's method—Langenbeck's method—Denonvillier's method—Buck's method—Repair of columna—Dieffenbach's method of restoration of nose—Verneuil's method—Indian method—Thiersch's method—Langenbeck's and Ollier's method—Triangular flap in—Dieffenbach's flap in—Langenbeck's flap in—Keegan's method—Italian method—Osteoplasty—Rhinoplasty—Ollier's method—König's method—Israel's modification of—Sabine's method—Pancoast's subcutaneous method—Saddle-back and angular deformities of the nose—Paraffin treatment—König's method—Martin's method—The use of gold, silver, rubber, etc., in—Comments—Disfigurements of nose—Morbid growths—Author's case—Harelip—Age of operation—Control of patient—Instruments employed in—Steps of—Single harelip—Mirault's method—Malgaigne's method—Hagedorn's method—Simon's method—Dieffenbach's method—König's method—Giraldès's method—Double harelip—Complicated harelip—Management of projecting intermaxillary bones—Blandin's operation—Rose's operation—operation for double harelip—Hagedorn's method—Owen's method—Cheiloplasty—Grant's method—Blasius's method—Celsus's method—Estlander's method—Langenbeck's method—Brüns's method—Syme-Buchanan method—Syme's method—Buck's method—Malgaigne's method—Sédillot's method—Dowd's method—Deformities of the upper lip—Buck's method—Brüns's method—Sédillot's method—Dieffenbach's method—Szymanowski's method—Ledran-Mackenzie method—Vanzette's method—Stomatoplasty—Buck's method—Serre's method—Melo-plasty—Grussenbauer's method—Trendelenburg's method—Israel's method—Kraske's method—Lallemand's method, etc.—Operations upon palate—Instruments employed in—Staphylorrhaphy—Comments—Rose's position in—Steps of operation of staphylorrhaphy—Results—Uranoplasty—Langenbeck's method—Steps in—Dieffenbach-Fergusson method—Lannelongue's method—Davies-Colley method—Ferguson's method—General comments—After-treatment—Results—Mechanical means employed in—Staphyloplasty—Schönborn's operation—Lane's method—Elongated uvula	569
--	-----

CHAPTER XIII.

OPERATIONS ON MOUTH, PHARYNX, NOSE, OESOPHAGUS, AND NECK.

Salivary fistula—Agnew's method of cure—Dessault's method—Van Buren's method—Richelot's method—Dequise's method—Excision of tonsil—Removal with knife or scissors—Abscess of tonsil—Operations on tongue—Langenbeck's method—Preliminary laryngotomy—Excision of tongue—V-shaped incision—Hypertrophy of tongue—Removal of entire tongue—Removal of half of tongue—Operation through mouth—Whitehead's method—
--

Kocher's method—Removal of tongue with division of jaw—Jaeger's method—Baker's method—Rignoli's method—Billroth's method—Choice of method—The results—Tongue-tie—Ranula—Removal of tumor of tonsil and pillar of fauces—Pharyngotomy—Cheever's method—Czerny's method—Mikulicz's method—General remarks—The results—Operations on nose—Plugging of posterior nares—Removal of nasal polypi—Removal of some nasal and nasopharyngeal polypi—Nasal route—Chassaignac's method—Ollier's method—Lawrence's method—Rouge's method—Langenbeck's method—Palatine route—Nélaton's method—Chalot's method—Annandale's method—Maxillary route—Boeckel's method—Guérin's method—Kocher's method—Cheever's method—General comments—Choice of operation—The results—Deviation of septum nasi—Operations for—Operations on œsophagus—The anatomical points—Foreign bodies in œsophagus—The remarks—Introduction into œsophagus of instruments—A method of introduction of stomach tube—Other methods of introduction—The precautions—The remarks—Ingenious plans of action for removal of special obstructions—Esophagotomy—Cervical esophagotomy—The fallacies—The remarks—The after-treatment—The results—Foreign bodies in thoracic œsophagus—Operations on œsophagus—Gastrotomy—The operation—The precautions—The comments—Stricture of œsophagus—Treatment of—By dilatation—By retrograde dilatation—By divulsion—By direct and retrograde divulsion—Internal œsophagotomy—Division by string friction—The comments—Tubage—The results—Esophagotomy—The results—Esophagotomy—Operations on neck—Bronchotomy—Anatomical points—The after-treatment—Laryngotomy—Operation of—Tracheotomy—Anatomical points—Operation below isthmus—Operation above isthmus—Operation through isthmus—Laryngo-tracheotomy—Rapid laryngo-tracheotomy—Operation of—Thyrotomy—Operation of—The precautions—General comments—After-treatment—The results of tracheotomy—Subhyoid pharyngotomy—Operation of—Intubation of larynx—Introduction of tube—After-treatment—The results—Foreign bodies in air passages—Methods of treatment—The results—Laryngectomy—Complete laryngectomy—Kocher's method—The results—Treves's method—Partial laryngectomy—Total laryngectomy—Keen's plan of operation—Tamponing the trachea—Trendelenburg's tampon—Hahn-Michael's tampon—Gerster's tampon—Artificial larynx—The results—Operations on thyroid body—Anatomical points—Preparation of patient—Partial excision—Kocher's method—Angular incision—Transverse incision—Kocher's methods—The removal of intra-thoracic goitre—Enucleation resection—Kocher's method—Enucleation—Socin's method—Resection of goitre—Kocher's method—Recurrent goitre—Treatment of ligature of thyroid arteries—By exothyropexy—By excision of sympathetic—By injection—Dangers of operations—To recurrent laryngeal—From cellulitis—From cachexia—The results—Wounds of neck—Treatment of—Abscess and phlegmon of neck—Retropharyngeal abscess—Anatomical points—Chiene's method of treatment—Buckhardt's method—Removal of diseased cervical lymphatic glands—Anatomical points—Treves's operation—The precautions—The remarks—Hartley's method—Mitchell's method—The results—Branchial cysts—Extirpation of parotid gland—Anatomical points—Contra-indications of—The results	632
---	-----



ILLUSTRATIONS.

	PAGE
Abdominal vessels, linear guides to. Figs. 180, 181.	<i>Original.</i> 181
Abscess, retropharyngeal, opening of. Fig. 893.	<i>Esmarch.</i> 726
Acupressure. Figs. 93, 94, 95.	<i>Thomas Bryant.</i> 75
Adams's clamp. Fig. 844.	<i>W. F. Ford & Co.</i> 661
Adams's saw. Fig. 452.	<i>W. F. Ford & Co.</i> 433
Amputating knives. Fig. 487.	<i>W. F. Ford & Co.</i> 461
Amputating knife, how held. Fig. 488.	<i>Original.</i> 462
Amputating knife, how carried around limb. Fig. 489.	<i>Original.</i> 462
Amputating knife, another method, carrying around limb. Fig. 490.	<i>S. Smith.</i> 463
Amputating knife, common method, carrying around limb. Fig. 491.	<i>Esmarch.</i> 463
Amputation, circular method. Fig. 473.	<i>Esmarch.</i> 453
Amputation, dissection of flap. Fig. 474.	<i>Esmarch.</i> 454
Amputation, how to dissect flap. Fig. 475.	<i>Esmarch.</i> 454
Amputation, circular division of muscles. Fig. 476.	<i>Esmarch.</i> 455
Amputation, circular, stump of. Fig. 477.	<i>Esmarch.</i> 455
Amputation, modified periosteal flap. Fig. 478.	<i>Gross.</i> 456
Amputation, flaps by transfixion. Fig. 480.	<i>Gross.</i> 457
Amputation, part removed by transfixion. Fig. 481.	<i>Gross.</i> 457
Amputation, skin flaps, equilateral. Fig. 484.	<i>Esmarch.</i> 458
Amputation, improper periosteal flap. Fig. 485.	<i>New.</i> 459
Amputation, instruments employed in. Fig. 486 (half tone).	<i>Original.</i> 460
Amputation, sawing bone. Fig. 495.	<i>Esmarch.</i> 465
Amputation, catching and tying bleeding points. Fig. 502.	<i>MacCormac.</i> 468
Amputation at wrist, Dubrueil's method. Figs. 532, 533.	<i>Esmarch.</i> 479
Amputation, arm, Langenbeck's method. Fig. 540.	<i>Esmarch.</i> 484
Amputation of arm, flaps. Figs. 541, 542.	<i>Esmarch.</i> 485
Anæsthesia, infiltration. Figs. 25, 26.	<i>W. F. Ford & Co.</i> 39
Anæsthesia, infiltration, Matas. Figs. 27, 28.	<i>Matas.</i> 40
Anæsthesia, spinal. Figs. 29, 30, 31, 32.	<i>Tuffier.</i> 41, 42
Anderson-Makin's lines. Fig. 287.	<i>Mills.</i> 249
Aneurism, extirpation of. Figs. 232, 234.	<i>Moynahan.</i> 203, 205
Aneurism, radical cure. Figs. 235, 247.	<i>Matas.</i> 207, 213
Aneurismal needle, student's. Fig. 177.	<i>W. F. Ford & Co.</i> 129
Aneurismal needle, Mott's. Fig. 178.	<i>W. F. Ford & Co.</i> 129
Ankle joint, excision of. Fig. 425.	<i>Treves, modified.</i> 410
Ankle joint, anatomy of. Fig. 426.	<i>Esmarch.</i> 411
Ankle joint, excision of. Fig. 428.	<i>Treves, modified.</i> 412
Ankle joint, anatomy of. Fig. 429.	<i>Esmarch.</i> 413
Ankle joint, splint for excision. Fig. 430.	<i>Esmarch.</i> 414
Antiseptic dressings in position. Fig. 159.	<i>Watson.</i> 109
Approach to vessels. Fig. 170.	<i>Original.</i> 126
Arteries of neck, linear guides to. Fig. 205.	<i>New.</i> 159
Arteriorrhaphy. Figs. 248, 249.	<i>Murphy.</i> 213, 214
Artery, torsion of. Fig. 97.	<i>Esmarch.</i> 76
Astragalus, excision of. Fig. 425.	<i>Treves, modified.</i> 410
Atomizer, Richardson's. Fig. 21.	<i>W. F. Ford & Co.</i> 36

	PAGE
Axillary artery, ligature of, first portion. Fig. 218.	<i>Mott, modified.</i> 179
Axillary, brachial arteries, ligature of. Fig. 219.	<i>Kocher.</i> 181
Barton's operation. Fig. 673.	<i>Gross.</i> 559
Baudens's amputation. Fig. 569.	<i>Modification.</i> 502
Bobbins for ligatures. Fig. 122.	<i>W. F. Ford & Co.</i> 86
Bone repair. Figs. 371, 372, 373.	<i>Gerster.</i> 358, 359
Boston surgical cushion. Fig. 60.	<i>W. F. Ford & Co.</i> 54
Bottles for ligatures. Figs. 124, 126.	<i>W. F. Ford & Co.</i> 86
Brachial artery, pressure digital. Fig. 86.	<i>MacCormac.</i> 72
Brachial artery, tourniquet applied to. Fig. 89.	<i>Esmarch.</i> 73
Brain, puncturing of ventricles. Fig. 264.	<i>Keen.</i> 228
Brain, topography of. Figs. 289, 290a.	<i>Dalton, modified.</i> 252
Brain tumor, instruments in operations on. Fig. 290 (half tone).	<i>Original.</i> 252
Brandis's method of compression. Fig. 651.	<i>Esmarch.</i> 542
Broad-bladed saw. Fig. 492.	<i>W. F. Ford & Co.</i> 464
Buck's needle conductor. Fig. 96.	<i>W. F. Ford & Co.</i> 76
Buck's method. Figs. 726, 727.	<i>Buck.</i> 583
Buck's incision. Fig. 776.	<i>Buck.</i> 610
Bullet forceps. Fig. 299.	<i>W. F. Ford & Co.</i> 268
Bunion and hallux valgus. Fig. 691.	<i>Gross.</i> 568
Butcher's bone saw. Fig. 494.	<i>W. F. Ford & Co.</i> 464
Carden's amputation. Fig. 626.	<i>Stimson.</i> 528
Carotid, vertebral and facial arteries. Fig. 217.	<i>Kocher.</i> 175
Carotid, common, ligature of. Fig. 228.	<i>Sedillot, modified.</i> 192
Carpus, synovial membranes of. Fig. 413.	<i>Gray.</i> 401
Carpus, ligaments of dorsal surface. Fig. 414.	<i>Esmarch.</i> 401
Carpus, ligaments of palmar surface. Fig. 415.	<i>Esmarch.</i> 401
Carpus, transverse section of. Fig. 416.	<i>Treves.</i> 402
Catgut in glass tubes. Fig. 125.	<i>W. F. Ford & Co.</i> 87
Cautery, actual, blowpipe and irons. Fig. 107.	<i>W. F. Ford & Co.</i> 79
Cautery, galvanic, electrodes. Fig. 109.	<i>W. F. Ford & Co.</i> 80
Celsus's, amputation of thigh. Figs. 673, 639.	<i>Esmarch.</i> 536
Celsus's method. Figs. 768, 769.	<i>New.</i> 607
Chain saw. Fig. 376.	<i>W. F. Ford & Co.</i> 364
Chain saw carrier. Fig. 377.	<i>W. F. Ford & Co.</i> 364
Cheeks drawn aside by elastic traction. Fig. 799.	<i>Dennis.</i> 622
Cheiloplasty, Estlander method. Fig. 770.	<i>Tillmanns.</i> 607
Cheiloplasty, Langenbeck and Brüns. Figs. 771, 772.	<i>Tillmanns.</i> 608
Cheiloplasty, Langenbeck, Syme-Buchanan. Figs. 773, 774.	<i>Tillmanns.</i> 608
Chin, cheek, and lip, repair of, Vanzette's method. Fig. 786.	<i>Terrier.</i> 615
Chopart's amputation. Figs. 575-579.	<i>Esmarch.</i> 504, 506
Closure of vessel <i>en masse</i> . Fig. 128.	<i>Esmarch.</i> 96
Clot dural, exposure. Figs. 278, 279.	<i>Lejars.</i> 240
Columna, repair of. Fig. 728.	<i>Treves.</i> 583
Common iliac, ligaturing of. Fig. 182.	<i>Modified from Otis.</i> 133
Compress, pyramidal. Fig. 82.	<i>Esmarch.</i> 71
Compress, oblong. Fig. 83.	<i>Esmarch.</i> 71
Compress, conical. Fig. 84.	<i>Esmarch.</i> 71
Counter-opening, locating of, author's method. Fig. 300.	<i>Original.</i> 268
Counter-opening, located, author's method. Fig. 301.	<i>Original.</i> 269
Cranial bones, section of. Fig. 280.	<i>Chipault.</i> 243
Cranial fissures and sutures, relation of in adult. Fig. 282.	<i>Morris.</i> 282
Cranial fissures and sutures, relation of in child. Fig. 283.	<i>Morris.</i> 283
Craniotomy, for fracture of the skull, instruments used in. Fig. 295 (half tone).	<i>Original.</i> 232
Craniotomy, circular. Fig. 266.	<i>Esmarch, modified.</i> 233
Craniotomy (trephining). Figs. 267, 268, 269, 270, 271, 272.	<i>Jacobson and Scudder, modified.</i> 232, 236

	PAGE
Craniotomy, sites for. Fig. 292.	<i>Treves.</i> 259
Crile's suit for shock. Fig. 167.	<i>Crile.</i> 121
Croft's operation. Fig. 714.	<i>Treves.</i> 578
Crural nerve, anterior. Fig. 338.	<i>Agnew.</i> 338
Cutting skin grafts. Fig. 712.	<i>Dennis.</i> 576
Cutting skin grafts. Fig. 713.	<i>Esmarch.</i> 577
Davy's lever applied. Fig. 91.	<i>Davy.</i> 74
De Lignerolle's amputation. Figs. 581, 586.	<i>Esmarch.</i> 506, 508
Denonvillier's method. Fig. 725.	<i>Tillmanns.</i> 582
Diagram of arrangements. Fig. 164.	<i>Treves.</i> 116
Dieffenbach's method. Fig. 729.	<i>Stimson, modified.</i> 584
Dieffenbach's flap. Fig. 735.	<i>Treves.</i> 588
Dieffenbach's method. Fig. 752.	<i>Treves.</i> 601
Digits, tendinous sheaths of. Fig. 369.	<i>Gerster.</i> 354
Dorsalis pedis, ligature of. Fig. 202.	<i>Kocher.</i> 155
Douching bottle. Fig. 157.	<i>W. F. Ford & Co.</i> 109
Douching bottle, extemporized. Fig. 158.	<i>W. F. Ford & Co.</i> 109
Doyan's method. Figs. 321, 322.	<i>Doyan.</i> 303, 304
Drainage tube, rubber, thread fastening. Fig. 153.	<i>Original.</i> 105
Drainage tube, rubber, pin fastening. Fig. 154.	<i>Original.</i> 106
Drainage strips, iodoform gauze. Fig. 155.	<i>W. F. Ford & Co.</i> 106
Drainage, catgut. Fig. 156.	<i>Wyeth.</i> 106
Drainage, base of skull. Fig. 332.	<i>Parkin.</i> 317
Dupuytren's contraction. Figs. 366, 367.	<i>Abbe.</i> 351
Elbow joint, excision, Hüter's incision. Fig. 406.	<i>Esmarch.</i> 396
Elbow joint, ligaments of. Fig. 407.	<i>Gray.</i> 396
Elbow joint, excision, Langenbeck's incision. Fig. 408.	<i>MacCormac, modified.</i> 397
Elbow joint, excision, Ollier's incision. Fig. 408.	<i>MacCormac, modified.</i> 397
Elbow joint, excision, Liston's incision. Fig. 409.	<i>Esmarch.</i> 397
Elbow joint, excision, exposing internal condyle. Fig. 410.	<i>Esmarch.</i> 398
Elbow joint, excision, splint applied. Fig. 411.	<i>Esmarch.</i> 399
Elbow joint, amputation at, elliptical flap. Fig. 535.	<i>Treves.</i> 481
Elbow joint, amputation at, circular method. Figs. 536, 537.	<i>Esmarch.</i> 482
Elbow joint, amputation at, by transfixion. Figs. 538, 539.	<i>S. Smith.</i> 483
Ellis's method. Fig. 723.	<i>Roberts.</i> 582
Epigastric artery, ligature of. Fig. 189.	<i>Kocher.</i> 141
Esmarch's tourniquet. Fig. 647.	<i>Esmarch.</i> 540
Esmarch's tourniquet applied. Fig. 649.	<i>Esmarch.</i> 541
Esmarch's elastic bandage. Fig. 75.	<i>Esmarch.</i> 69
Esmarch's elastic bandage applied. Fig. 76.	<i>Esmarch.</i> 69
Ethyl chloride, spray. Fig. 22.	<i>W. F. Ford & Co.</i> 37
Excision of bones of the face, instruments employed in. Fig. 378 (half tone).	<i>Original.</i> 366
Excisions of extremities, instruments employed in. Fig. 375 (half tone).	<i>Original.</i> 363
Extemporized retractors. Fig. 176.	<i>Modified from Esmarch.</i> 129
Fascia, deep cervical. Fig. 892.	<i>Gray.</i> 725
Fascia palmar. Fig. 365.	<i>Morris.</i> 350
Fasciatome. Fig. 364.	<i>W. F. Ford & Co.</i> 349
Fasciatome, short. Fig. 368.	<i>W. F. Ford & Co.</i> 351
Femoral artery, digital pressure on. Fig. 85.	<i>MacCormac.</i> 71
Femoral artery, tourniquet applied to. Fig. 88.	<i>Esmarch.</i> 73
Femoral artery, superficial, ligature of. Fig. 190.	<i>Kocher.</i> 144
Femoral artery, deep, ligature of. Fig. 194.	<i>Kocher, modified.</i> 148
Femur, lower end of, transverse section. Fig. 461.	<i>Treves, modified.</i> 443
Fibula, removing end of. Fig. 427.	<i>S. Smith.</i> 412
Finger stalls, rubber. Fig. 163 (half tone).	<i>Original.</i> 115
Fingers, amputation of, appearance of flaps. Figs. 513, 514.	<i>Esmarch and Jacobson</i> 473

	PAGE
Fissure of Rolando, locating, Chiene's method. Fig. 285	<i>Keen.</i> 247
Flap, single pedicle. Figs. 715, 717.	<i>Wyeth.</i> 579
Flap, single pedicle, author's case. Fig. 718.	<i>Original.</i> 579
Flaps, double pedicle. Fig. 716.	<i>Tillmanns.</i> 579
Fluhrer's probe. Fig. 297.	<i>W. F. Ford & Co.</i> 267
Forceps, serre-fine. Fig. 102.	<i>W. F. Ford & Co.</i> 78
Forceps, tongue-holding, Mathieu's. Fig. 2.	<i>W. F. Ford & Co.</i> 13
Forceps, isolation, anæsthesia. Fig. 24.	<i>W. F. Ford & Co.</i> 37
Forceps, thumb. Fig. 40.	<i>W. F. Ford & Co.</i> 47
Forceps, claw-bite. Fig. 42.	<i>W. F. Ford & Co.</i> 47
Forceps, cutting between. Fig. 41.	<i>Löbker.</i> 47
Forcipressure, patterns of. Fig. 106.	<i>W. F. Ford & Co.</i> 79
Forearm, stump after circular amputation of. Fig. 534.	<i>Esmarch.</i> 480
Foullis's fastening. Figs. 78, 79.	<i>Esmarch.</i> 70
Framework of nose, formation of. Fig. 733.	<i>Tillmanns.</i> 587
Genu valgum. Fig. 460.	<i>Poore.</i> 442
Genu varum. Fig. 469.	<i>Poore.</i> 445
Giraldès's method. Fig. 754.	<i>Tillmanns.</i> 602
Girdner's electric probe. Fig. 298.	<i>W. F. Ford & Co.</i> 267
Gland, borated, anatomy of. Fig. 897.	<i>Testut.</i> 734
Gland, borated, surgical anatomy of. Fig. 898.	<i>Esmarch, modified.</i> 736
Glands, cervical lymphatic, instruments for removal (half tone). Fig. 894.	<i>Original.</i> 728
Glands, cervical lymphatic, Hartley's method. Fig. 845.	<i>Stimson.</i> 731
Glands, cervical lymphatic, Mitchell's method. Fig. 896.	<i>Johns Hopkins Hospital Rpt.</i> 732
Gloves, canton flannel. Fig. 162 (half tone).	<i>Original.</i> 115
Gluteal and sciatic arteries, guides to. Fig. 184.	<i>MacCormac.</i> 136
Gluteal artery, ligature of. Fig. 185.	<i>Kocher.</i> 137
Gouging, instruments employed in. Fig. 370 (half tone).	<i>Original.</i> 357
Grad, method of ligature removal. Fig. 121.	<i>Grad.</i> 85
Granny knot. Fig. 115.	<i>Heath.</i> 82
Gritti's amputation. Fig. 568.	<i>Stimson.</i> 530
Grooved director. Fig. 46.	<i>W. F. Ford & Co.</i> 48
Gross's needle forceps. Fig. 800.	<i>Gross.</i> 623
Gross's artery compressor. Fig. 104.	<i>W. F. Ford & Co.</i> 78
Hagedorn's method. Fig. 750.	<i>Tillmanns.</i> 601
Halux valgus. Fig. 471.	<i>Tubby.</i> 446
Hamilton's artery forceps. Fig. 100.	<i>W. F. Ford & Co.</i> 77
Hammer-toe. Fig. 678.	<i>Tubby.</i> 562
Hancock's amputation, bones sawed through. Fig. 585.	<i>Esmarch.</i> 508
Hand, appearance of. Fig. 522.	<i>Watson.</i> 475
Hand and forearm protection. Fig. 165 (half tone).	<i>Original.</i> 116
Hand conservatism illustrated. Fig. 503.	<i>Jacobson.</i> 469
Hand, palm of, surface markings. Fig. 504.	<i>Treves.</i> 469
Hand-lamp for illumination. Fig. 110.	<i>W. F. Ford & Co.</i> 81
Harelip, double. Fig. 755.	<i>S. Smith.</i> 603
Harelip, complicated. Fig. 756.	<i>Gross.</i> 603
Harelip, double, operation for. Fig. 758.	<i>Tillmanns.</i> 604
Harelip, double, Hagedorn's operation. Fig. 759.	<i>Tillmanns.</i> 605
Harelip, pins inserted. Fig. 762.	<i>Gross.</i> 606
Harelip, instruments employed in. Fig. 747 (half tone).	<i>Original.</i> 598
Hartley-Krause method, lines of incision. Fig. 318.	<i>Chalot.</i> 298
Hartley-Krause method, making bone flap. Fig. 319.	<i>Chalot.</i> 298
Hartley-Krause method, branches fifth nerve. Fig. 320.	<i>Chalot.</i> 299
Head, antero-posterior section of. Fig. 263.	<i>Keen.</i> 227
Hip joint, amputation of, Wyeth's method. Figs. 650, 652.	<i>Wyeth.</i> 543
Hip joint, amputation of, Menee's method. Figs. 660, 663.	<i>Esmarch.</i> 550

	PAGE
Hip joint, amputation of, Dieffenbach's method. Figs. 665, 667.	<i>Esmarch.</i> 553
Hip joint, amputation of, Furneaux Jordon method. Fig. 668.	<i>Treves.</i> 555
Hip joint, amputation of, Guthrie's method. Fig. 669.	<i>Treves.</i> 555
Hip joint, amputation of, Malgaigne. Figs. 670, 672.	<i>S. Smith.</i> 555
Hip joint, Senn's method. Figs. 656, 659.	<i>Senn.</i> 546
Hip joint, White's incision in excision of. Fig. 446.	<i>Esmarch.</i> 426
Hip joint, nerve and rotary muscles of. Fig. 447.	<i>Esmarch.</i> 426
Hip joint, sawing off head in excision of. Fig. 448.	<i>Esmarch.</i> 422
Hip joint, Langenbeck's incision in excision of. Fig. 449.	<i>Esmarch.</i> 428
Hip joint, Sayre's incision in excision of. Fig. 449.	<i>Esmarch.</i> 428
Holding knife, first position. Figs. 34, 35.	<i>Bernard & Huette.</i> 46
Holding knife, second position. Figs. 36, 37.	<i>Bernard & Huette.</i> 46
Holding knife, third position. Figs. 38, 39.	<i>Bernard & Huette.</i> 46
Horsley's fissure meter. Fig. 285.	<i>Mills.</i> 247
Hughson's torsion forceps. Fig. 98.	<i>W. F. Ford & Co.</i> 77
Humerus, excision of head of. Fig. 336.	<i>Esmarch, modified.</i> 384
Humerus, epiphysis of. Fig. 391.	<i>Treves.</i> 385
Humerus, excision of head, incision for. Fig. 392.	<i>Esmarch, modified.</i> 385
Humerus, excision of head of, raising tendon. Fig. 393.	<i>Esmarch.</i> 386
Humerus attachments, tuberosities of. Fig. 394.	<i>Esmarch.</i> 386
Humerus, excision of head of. Fig. 395.	<i>Esmarch.</i> 387
Iliac artery, external, ligature of. Fig. 188.	<i>Mott.</i> 139
Iliac artery, common, ligature of. Fig. 183.	<i>Kocher.</i> 134
Incisions in maxillæ. Fig. 385.	<i>Treves.</i> 376
Indian method. Fig. 731.	<i>Treves.</i> 586
Inferior maxilla, Keen's method. Fig. 314.	<i>Kccn.</i> 290
Inferior maxilla, Kühn's method. Fig. 314.	<i>Kocher, modified.</i> 290
Inferior maxilla, Lücke's method. Fig. 314.	<i>Kocher, modified.</i> 290
Inferior maxilla, Horsley's method. Fig. 314.	<i>Kocher, modified.</i> 290
Inferior maxilla, Linhart's method. Fig. 314.	<i>Kocher, modified.</i> 290
Inferior maxilla, Pancoast's method. Fig. 314.	<i>Kocher, modified.</i> 290
Inferior maxilla, removal of lines of incision. Fig. 384.	<i>Kocher, modified.</i> 375
Inferior maxilla, severing connections of. Fig. 386.	<i>Agnew.</i> 377
Inferior dental nerve, resection of. Fig. 313.	<i>Kocher, modified.</i> 286
Infusion, apparatus for. Figs. 253, 254 (half tone).	<i>Original.</i> 219, 220
Ingrown toe nail, operations for. Fig. 688.	<i>Dowd, modified.</i> 567
Ingrown toe nail, transverse section showing. Fig. 689.	<i>Stimson.</i> 567
Ingrown toe nail, Anger's operation. Fig. 690.	<i>Dowd.</i> 568
Inhaler, cloth and paper. Fig. 9.	<i>Original.</i> 25
Inhaler, Allis's. Figs. 10, 11.	<i>W. F. Ford & Co.</i> 26
Inhaler, Fowler's modification of Allis's collapsable. Fig. 12.	<i>W. F. Ford & Co.</i> 26
Inhaler, Bennett's, ether. Fig. 15.	<i>W. F. Ford & Co.</i> 28
Inhaler, Bennett's, nitrous oxide. Fig. 19.	<i>W. F. Ford & Co.</i> 33
Inhaler, Bennett's, "gas and ether." Fig. 20.	<i>W. F. Ford & Co.</i> 34
Inhaler, Clover's. Fig. 13.	<i>W. F. Ford & Co.</i> 27
Inhaler, Ormsby's. Fig. 14.	<i>W. F. Ford & Co.</i> 27
Inhaler, Esmarch's chloroform. Fig. 16.	<i>Esmarch.</i> 30
Inhaler, Junker. Fig. 17.	<i>W. F. Ford & Co.</i> 31
Inhaler, Junker's nasal and pharyngeal tubes. Fig. 18.	<i>W. F. Ford & Co.</i> 31
Innominata, ligature of. Figs. 207, 208, 209, 210.	<i>Ncw.</i> 162
Innominata, ligature of, Curtis. Figs. 211, 212.	<i>Curtis.</i> 165
Intermaxillary bone, Blandin's operation. Fig. 757.	<i>Dennis.</i> 604
Interrupted suture. Fig. 139.	<i>S. Smith.</i> 101
Intracranial neurectomy, instruments employed in. Fig. 317 (half tone).	<i>Original.</i> 297
Intracranial neurectomy, Cushing method. Figs. 323, 324.	<i>Cushing.</i> 305, 306
Intracranial neurectomy, Spiller-Frazier method. Fig. 325.	<i>Spiller and Frazier.</i> 308
Iodoform sprinkler. Fig. 160.	<i>W. F. Ford & Co.</i> 110
Italian method. Fig. 711.	<i>Aucient.</i> 575

	PAGE
Janeway's sphygmomanometer. Fig. 168 (half tone).	<i>Janeway.</i> 123
Jaw pry, wooden. Fig. 6.	<i>Original.</i> 14
Jaw, pushing forward. Fig. 8.	<i>Esmarch.</i> 13
Joint, metatarso-phalangeal, excision of. Fig. 428.	<i>Treves, modified.</i> 412
Jumping, pedicle not twisted. Fig. 709.	<i>Löbker.</i> 574
Jumping, pedicle much twisted. Fig. 710.	<i>Prince.</i> 574
Jumping, repair by. Figs. 722, 724.	<i>Gross.</i> 582
Kangaroo tendon in glass tube. Fig. 129.	<i>W. F. Ford & Co.</i> 97
Keegan's operation. Fig. 737.	<i>Treves.</i> 589
Keen's electrode. Fig. 291.	<i>W. F. Ford & Co.</i> 253
Kelly's surgical cushion, large. Fig. 58.	<i>W. F. Ford & Co.</i> 54
Kelly's surgical cushion, small. Fig. 59.	<i>W. F. Ford & Co.</i> 54
Keyes's needle, varicocele treatment of. Fig. 251.	<i>W. F. Ford & Co.</i> 217
Kingsley's interdigital splint. Fig. 826.	<i>Kingsley.</i> 643
Knee joint, anatomy of. Fig. 433.	<i>Morris.</i> 416
Knee joint, excision of, Mackenzie. Fig. 434.	<i>Esmarch.</i> 417
Knee joint, excision of, sawing femur. Fig. 435.	<i>Treves.</i> 418
Knee joint, excision of, sawing tibia. Fig. 436.	<i>Treves.</i> 418
Knee joint, Bird's incision in excision of. Fig. 437.	<i>Esmarch.</i> 419
Knee joint, Langenbeck's incision in excision of. Fig. 439.	<i>Esmarch.</i> 420
Knee joint, anatomy of. Fig. 440.	<i>Esmarch.</i> 420
Knee joint, saw lines in excision of. Fig. 442.	<i>S. Smith.</i> 421
Knee joint, Ollier's incision in excision of. Fig. 441.	<i>Esmarch.</i> 421
Knee joint, epiphyseal cartilages of. Fig. 443.	<i>Stimson.</i> 422
Knee joint, splint for excision of. Fig. 445.	<i>Esmarch.</i> 423
Knee joint, cuneiform excision of. Fig. 459.	<i>Treves, modified.</i> 442
Knee joint, amputation at. Figs. 618-620.	<i>S. Smith.</i> 524
Knee joint, amputation at, circular method. Figs. 621-623.	<i>Esmarch.</i> 526
Knee joint, amputation at, in anterior third, posterior flap. Figs. 624, 625.	<i>Esmarch.</i> 527
Knee flexion, force of. Fig. 74.	<i>Tillmanns.</i> 68
König's method, nose. Fig. 740.	<i>Tillmanns.</i> 591
König's method, lip. Fig. 753.	<i>Tillmanns.</i> 602
Krug's inclined plane, portable. Fig. 71.	<i>W. F. Ford & Co.</i> 59
Laminectomy, instruments employed in. Fig. 326 (half tone).	<i>Original.</i> 309
Laminectomy, exposure of posterior structures. Fig. 327.	<i>Chipault.</i> 313
Laminectomy, spinal cord exposed. Fig. 327.	<i>Chipault.</i> 313
Laminectomy, removal of bone pressure. Fig. 329.	<i>Chipault.</i> 314
Laminectomy, osteoplastic flap. Fig. 330.	<i>Chipault.</i> 315
Langenbeck's method. Fig. 724.	<i>Löbker.</i> 582
Langenbeck's serre-fine. Fig. 103.	<i>W. F. Ford & Co.</i> 78
Langenbeck's saw. Fig. 451.	<i>W. F. Ford & Co.</i> 433
Langenbeck's flap. Fig. 736.	<i>Treves.</i> 588
Larynx, instruments for intubation. Fig. 871 (half tone).	<i>Original.</i> 694
Larynx, intubation of, introducing tube. Figs. 872, 896.	<i>Lojars.</i> 695
Larynx, Gussenbauer's artificial. Fig. 881.	<i>Tillmanns.</i> 708
Laving basin. Fig. 72.	<i>W. F. Ford & Co.</i> 60
Leg, amputation of, lower third, Guyon and Duval's methods. Fig. 608.	<i>Treves.</i> 516
Leg, amputation of, lower third, author's method. Figs. 609, 611.	<i>Original.</i> 517
Leg, amputation of, lower third. Figs. 612, 613.	<i>Treves.</i> 519
Leg, amputation of, Bier and Eiselberg. Figs. 628, 629.	<i>Zuckeremdl.</i> 531
Leg, amputation of, Bier method. Fig. 631.	<i>Bier.</i> 531
Leg, amputation of, middle third, long external flap. Fig. 614.	<i>Esmarch.</i> 521
Leg, amputation of, upper third. Figs. 615, 616.	<i>Treves.</i> 522
Leg, amputation of, middle third, bilateral flap. Fig. 617.	<i>S. Smith.</i> 523
Levis's blunt dissector. Fig. 48.	<i>W. F. Ford & Co.</i> 49
Ligature of arteries, instruments for. Fig. 175 (half tone).	<i>Original.</i> 128

	PAGE
Ligature, tying of. Figs. 112, 118.	<i>Hcath.</i> 82
Ligatures, receptacle for, in office, etc. Fig. 127.	<i>W. F. Ford & Co.</i> 91
Ligaturing, subcutaneous. Figs. 257, 259.	<i>S. Smith.</i> 225
Ligaturing, subcutaneous. Figs. 260, 263.	<i>S. Smith.</i> 225
Lingual artery, ligature of. Fig. 229.	<i>Kocher, modified.</i> 199
Lingual artery, ligature of, third situation. Fig. 230.	<i>Hcath, modified.</i> 199
Lip, epithelioma of. Fig. 763.	<i>Tillmanns.</i> 607
Lip, lower, Grant's operation. Fig. 763.	<i>Grant.</i> 606
Lip, lower, Owen's operation. Fig. 764.	<i>Owen.</i> 606
Lip, lower, Blasius's method. Figs. 765, 766.	<i>Blasius.</i> 606
Lip, lower, Dowd's method. Fig. 779.	<i>Dowd.</i> 611
Lip, lower, Brüns's method. Figs. 780a, 780b.	<i>Brüns.</i> 612
Lisfranc's amputation. Figs. 570, 574.	<i>Esmarch.</i> 503
Lister's tourniquet. Fig. 648.	<i>Esmarch.</i> 541
Liston's spring-catch forceps. Fig. 99.	<i>W. F. Ford & Co.</i> 77
Liston's mouse-tooth forceps. Fig. 101.	<i>W. F. Ford & Co.</i> 77
Looped suture. Fig. 801.	<i>Gross.</i> 623
Lower lip, Buck's method. Fig. 775.	<i>Buck.</i> 609
Lower lip, Sédillot's method. Fig. 778.	<i>Tillmanns.</i> 611
Lucas-Championnière's lines. Fig. 288.	<i>Roberts.</i> 250
Making incision. Fig. 169.	<i>Bernard & Huette.</i> 126
Malgaigne's method. Fig. 749.	<i>Tillmanns.</i> 600
Malgaigne's method, lower lip. Fig. 777.	<i>Tillmanns.</i> 611
Malleoli, oblique, division of. Fig. 593.	<i>Original.</i> 511
Mallet finger. Fig. 679.	<i>Morris.</i> 563
Martin's bandage, elastic. Fig. 81.	<i>W. F. Ford & Co.</i> 70
Martin's nasal support. Fig. 741.	<i>Terrier.</i> 593
Mastoid antrum, instruments in opening of. Fig. 293 (half tone).	<i>Original.</i> 262
Mastoid antrum exposed. Figs. 294, 295, 296.	<i>New.</i> 263, 264
Meloplasty. Fig. 789.	<i>Tillmanns.</i> 616
Meloplasty, Gussenbauer's method. Fig. 790.	<i>Tillmanns.</i> 617
Meloplasty, Israel's method. Fig. 791.	<i>Tillmanns.</i> 617
Meloplasty, Kraske's method. Fig. 792.	<i>Tillmanns.</i> 618
Meloplasty, Lallemand's method. Fig. 793.	<i>Terrier.</i> 618
Meningeal artery, middle. Fig. 273.	<i>Kronlein.</i> 237
Meningeal artery, middle, anterior branch. Fig. 274.	<i>Gray, modified.</i> 237
Meningeal artery, middle, anterior branch, in groove. Fig. 275.	<i>Gray, modified.</i> 238
Metacarpal bones, fourth and fifth, amputation through. Fig. 520.	<i>Watson.</i> 474
Metacarpal bones, amputation through. Fig. 521.	<i>Esmarch.</i> 474
Metacarpal bones, last four, amputation of. Figs. 523, 526.	<i>Esmarch.</i> 476
Metatarsal bones, amputation through. Figs. 566, 568.	<i>Esmarch, Treves.</i> 501
Mikulicz's amputation. Fig. 569.	<i>Original.</i> 502
Milne's serre-fine. Fig. 103.	<i>W. F. Ford & Co.</i> 78
Mirault's method. Fig. 748.	<i>Tillmanns.</i> 600
Mouth gag, Denhard's. Fig. 4.	<i>W. F. Ford & Co.</i> 13
Myotome. Fig. 363.	<i>W. F. Ford & Co.</i> 347
Nasal disfigurement, operations on. Figs. 745, 746 (half tone).	<i>Original.</i> 597
Nasal septum, deviating instruments for. Fig. 845 (half tone).	<i>Original.</i> 662
Needle-holder, Hartley-Markoe. Fig. 133.	<i>W. F. Ford & Co.</i> 100
Needle-holder, Sand's. Fig. 134.	<i>W. F. Ford & Co.</i> 100
Needle-holder, Luer's. Fig. 135.	<i>W. F. Ford & Co.</i> 100
Needle-holder, Halsted-Leur. Fig. 136.	<i>W. F. Ford & Co.</i> 100
Needle wounds. Fig. 132.	<i>Tieman.</i> 99
Needles, assorted sizes and curves. Fig. 131.	<i>W. F. Ford & Co.</i> 99
Nerve grafting, Chalot. Fig. 306.	<i>Tillmanns.</i> 275
Nerve, repair, by catgut. Fig. 305.	<i>Esmarch.</i> 275
Nerve, ulnar, at elbow. Fig. 405.	<i>Esmarch.</i> 395
Nerves, circumflex and musculo-spiral. Fig. 404.	<i>Gray.</i> 394

	PAGE
Nerves, musculo-spiral, musculo-cutaneous, circumflex. Fig. 334.	<i>Kocher, modified.</i> 322
Nerves, median and interosseous. Fig. 335.	<i>Kocher, modified.</i> 323
Nerves, great sciatic, small sciatic, external popliteal. Fig. 336.	<i>Kocher, modified.</i> 325
Nerves, great sciatic, external popliteal, short saphenous, incisions for exposure of.	
	Fig. 337. <i>Kocher.</i> 326
Nerves, primary suture of. Fig. 302.	<i>Esmarch.</i> 273
Nerves, Gleiss's method, secondary suture. Fig. 303.	<i>Sajous.</i> 274
Nerves, secondary, suturing of. Fig. 304.	<i>Sajous.</i> 275
Neuroplasty, Duncan's method. Fig. 305.	<i>Sajous.</i> 275
Neuroplasty. Fig. 304.	<i>Esmarch.</i> 275
Nicaise's compression band. Fig. 77.	<i>Esmarch.</i> 69
Nose, inferior view of. Fig. 738.	<i>Tillmanns.</i> 590
Obturator artery, ligature of. Fig. 189.	<i>Kocher.</i> 141
Occipital artery, ligature of. Fig. 231	<i>Kocher, modified.</i> 201
Oesophagotomy, instruments in. Fig. 848 (half tone).	<i>Original.</i> 667
Oesophagotomy, primary incision. Fig. 849.	<i>Esmarch.</i> 668
Oesophagotomy, final incision. Fig. 850.	<i>Esmarch.</i> 669
Oesophagotomy, string friction, Obbe. Fig. 853.	<i>Obbe.</i> 675
Oesophagotomy, string friction, Obbe. Fig. 854.	<i>Obbe.</i> 675
Oesophagotomy, string friction, author's. Fig. 855.	<i>Original.</i> 676
Oesophagotomy, string friction, author's. Fig. 856.	<i>Original.</i> 676
Oesophagus, instruments, removal foreign bodies. Fig. 486 (half tone).	<i>Original.</i> 664
Oesophagus, introducing tube into. Fig. 847.	<i>Esmarch.</i> 665
Oesophagus, tubage of. Fig. 857.	<i>Denris.</i> 678
Oesophagus, stricture of, instruments. Fig. 852 (half tone).	<i>Original.</i> 673
Oesophagus, diverticulum, operation on. Figs. 858, 859, 860.	<i>Richardson.</i> 679
Ollier's method. Fig. 739.	<i>Stimson.</i> 591
Opening sheath. Fig. 171.	<i>Esmarch.</i> 126
Opening vein. Fig. 252.	<i>Esmarch.</i> 218
Operating table, extemporized. Fig. 57 (half tone).	<i>Dowd.</i> 53
Operating table, Cleveland's. Fig. 61.	<i>W. F. Ford & Co.</i> 55
Operating table, Cleveland's, Trendelenburg position. Fig. 62.	<i>W. F. Ford & Co.</i> 55
Operating table, Fowler's, first position. Fig. 63.	<i>W. F. Ford & Co.</i> 56
Operating table, Fowler's, second position. Fig. 64.	<i>W. F. Ford & Co.</i> 56
Operating table, Fowler's, third position. Fig. 65.	<i>W. F. Ford & Co.</i> 57
Operating table, Markoe's. Fig. 66.	<i>W. F. Ford & Co.</i> 57
Operating table, Prior's portable. Fig. 67.	<i>W. F. Ford & Co.</i> 58
Operating table, folded. Fig. 68.	<i>W. F. Ford & Co.</i> 58
Operating table, Edeboh's portable. Fig. 69.	<i>W. F. Ford & Co.</i> 59
Operating table, folded. Fig. 69.	<i>W. F. Ford & Co.</i> 59
Oral screw, hard rubber. Fig. 5.	<i>W. F. Ford & Co.</i> 14
Oral pry, wooden. Fig. 6	<i>Original.</i> 14
Os calcis, excision of. Figs. 424, 425.	<i>S. Smith.</i> 409
Os calcis, lines of section through. Fig. 596.	<i>S. Smith.</i> 512
Osteotomy, instruments employed in. Fig. 450 (half tone).	<i>Original.</i> 432
Osteotomy, holding osteotome. Fig. 455.	<i>Tubby.</i> 436
Osteotomy, sawing neck of femur. Fig. 456.	<i>Gross.</i> 437
Osteotomy, Volkman's section. Fig. 458.	<i>Gross.</i> 438
Osteotomy, Sayre's section. Fig. 457	<i>Sayre.</i> 438
Osteotomy, supracondyloid. Fig. 463.	<i>Maccwen.</i> 444
Osteotomy, supracondyloid. Fig. 466.	<i>Macewen.</i> 444
Osteotomy, supracondyloid, Ogsten's method. Fig. 467	<i>Macewen.</i> 444
Osteotomy, supracondyloid, Chain's method. Fig. 468.	<i>Treves.</i> 444
Osteotomy, linear. Fig. 470.	<i>Treves.</i> 445
Osteotomy, cuneiform. Fig. 470.	<i>Treves.</i> 445
Pad, antiseptic gauze. Fig. 73 (half tone).	<i>Original.</i> 63
Pad and elastic-band compression. Fig. 585.	<i>Esmarch.</i> 482

	PAGE
Palate, instruments employed in operations on. Fig. 794 (half tone).	<i>Original.</i> 619
Palate, deformities of. Fig. 795.	<i>S. Smith.</i> 620
Palate, muscles of. Fig. 797.	<i>Esmarch.</i> 621
Palmar arteries. Fig. 227.	<i>Gray, modified.</i> 190
Pancoast's tourniquet. Fig. 646.	<i>Esmarch.</i> 540
Paper, protective. Fig. 692.	<i>Prince.</i> 570
Paquelin's thermo-cautery. Fig. 108.	<i>W. F. Ford & Co.</i> 80
Passing needle. Fig. 172.	127
Passing a probe. Fig. 173.	<i>Esmarch.</i> 127
Passing curved needle. Fig. 174.	<i>Esmarch.</i> 127
Peroneal artery, ligature of. Fig. 204.	<i>Kocher.</i> 157
Petit's tourniquet. Fig. 87.	<i>W. F. Ford & Co.</i> 72
Phalanges, attachments of, tendons of. Fig. 505.	<i>Original.</i> 470
Phalanx, flexed. Fig. 506.	<i>Esmarch.</i> 470
Phalanx, amputation of. Figs. 507, 508.	<i>Esmarch.</i> 470
Phalanx, amputation of, transfexion. Figs. 509, 510.	<i>Esmarch.</i> 471
Pharyngotomy, Cheever's, Mikulicz's, and author's incisions. Fig. 828.	<i>New.</i> 645
Pharyngotomy, low, tumors from, author's case. Fig. 829.	<i>Original.</i> 649
Pharyngotomy, subhyoid, anatomy of. Fig. 870.	<i>Esmarch.</i> 693
Phillip's head lamp for illumination. Fig. 111.	<i>W. F. Ford & Co.</i> 81
Phleborrhaphy. Fig. 250.	<i>New.</i> 214
Pirogoff's amputation. Figs. 596, 600.	<i>Esmarch.</i> 512
Pirogoff's amputation, Le Fort's modification. Figs. 601, 602.	<i>Esmarch.</i> 514
Pirogoff's amputation, Brüns's modification. Fig. 603.	<i>Esmarch.</i> 514
Pirogoff's amputation, Esmarch's modification. Figs. 604, 607.	<i>Esmarch.</i> 514
Plaster-of-Paris jacket, applied. Figs. 674, 677.	<i>Sayre.</i> 560
Plastic surgery, instruments employed in. Fig. 693 (half tone).	<i>Original.</i> 570
Plastic surgery, Dieffenbach's method. Figs. 698, 699.	<i>Dennis.</i> 572
Plastic surgery, Burow's method. Figs. 701, 702.	<i>Löbker.</i> 572
Plastic surgery, Jaesche-Dieffenbach's method. Fig. 703.	<i>Tillmanns.</i> 573
Plastic surgery, Littenneur's method. Fig. 704.	<i>Dennis.</i> 573
Plastic surgery, Brüns's method. Figs. 705, 706.	<i>Dennis.</i> 573
Plastic surgery, Weber's method. Fig. 708.	<i>Treves.</i> 574
Plugging posterior nares. Fig. 830.	<i>Esmarch, modified.</i> 651
Polypus, nasal, looping of. Fig. 832.	<i>Esmarch.</i> 653
Polypus, cannula in place. Fig. 833.	<i>Packard.</i> 653
Polypus, loop applied. Fig. 834.	<i>Esmarch.</i> 653
Polypus, nasal, Chossaignac's method. Figs. 835, 836.	<i>Esmarch.</i> 654
Polypus, nasal, Ollier and Lawrence's method. Fig. 837.	<i>Esmarch.</i> 654
Polypus, nasal, Rouge's method. Fig. 838.	<i>Esmarch.</i> 655
Polypus, nasal, Langenbeck and Boeckel's method. Fig. 839.	<i>Esmarch, modified.</i> 655
Polypus, nasal, Langenbeck's method continued. Fig. 840.	<i>Esmarch.</i> 655
Polypus, nasal, Nalaton's and Chalot's methods. Fig. 841.	<i>Treves.</i> 656
Polypus, nasal, Allier's, Guérin, Langenbeck, incisions. Fig. 842.	<i>New.</i> 658
Polypus, naso-pharyngeal, Kocher's method. Fig. 843.	<i>Tillmanns.</i> 659
Popliteal artery, ligature of. Fig. 195.	<i>Kocher, modified.</i> 148
Popliteal artery, ligature of lower third. Fig. 197.	<i>Kocher.</i> 150
Powell's electric saw. Fig. 281.	<i>W. F. Ford & Co.</i> 243
Prepared for operation. Fig. 166 (half tone).	<i>Original.</i> 117
Pudic artery, ligaturing of. Fig. 186.	<i>S. Smith.</i> 138
Pudic artery, relations of. Fig. 187.	<i>Morris.</i> 138
Radial and ulnar arteries, ligature of. Fig. 222.	<i>Kocher.</i> 184
Radial artery, ligature of. Fig. 226.	<i>Kocher, modified.</i> 188
Ranula. Fig. 827.	<i>S. Smith.</i> 644
Receptacle, kidney shape. Fig. 52.	<i>W. F. Ford & Co.</i> 51
Receptacle, glass. Fig. 54.	<i>W. F. Ford & Co.</i> 51
Receptacle, gutta-pereha. Fig. 53.	<i>W. F. Ford & Co.</i> 51
Receptacle, author's rubber. Fig. 55.	<i>W. F. Ford & Co.</i> 51

	PAGE
Receptacle, author's rotary. Fig. 56.	<i>W. F. Ford & Co.</i> 52
Reef knot. Fig. 114.	<i>Heath.</i> 82
Reid's lines. Fig. 26S.	<i>Starr.</i> 248
Relations of abdominal vessels. Fig. 179.	<i>Morris.</i> 130
Restraint, method of. Fig. 1 (half tone).	<i>Original.</i> 12
Retractor for two bones. Fig. 496.	<i>Esmarch.</i> 465
Retractor, three-tailed applied. Fig. 497.	<i>Esmarch.</i> 466
Retractor, for one bone. Fig. 498.	<i>Esmarch.</i> 466
Retractor, two-tailed applied. Fig. 499.	<i>Esmarch.</i> 466
Retractor, metal. Figs. 500, 501.	<i>Griswold.</i> 467
Retractors, hooked. Fig. 50.	<i>W. F. Ford & Co.</i> 50
Ring, isolation anæsthesia. Fig. 23.	<i>W. F. Ford & Co.</i> 37
Rose method, trephining base of skull. Fig. 316.	<i>Chalot.</i> 255
Rose's position. Fig. 796.	<i>Rose.</i> 296
Roux's method. Figs. 594, 595.	<i>Esmarch.</i> 512
Rubber tube control. Fig. 80.	<i>Original.</i> 70
Sabenejeff's amputation. Fig. 632.	<i>Tillmanns.</i> 532
Salivary fistula, Desault's method. Fig. 814.	<i>Richelet's method.</i> Fig. 815. <i>Ferrer.</i> 632
Salivary fistula, Dequise's method. Fig. 816.	<i>Ferrer.</i> 633
Saw, common bone. Fig. 493.	<i>W. F. Ford & Co.</i> 464
Sayre's jury-mast. Figs. 674, 675.	<i>Sayre.</i> 560
Scalpels and bistouries. Fig. 33.	<i>W. F. Ford & Co.</i> 45
Scapula, entire excision of. Fig. 387.	<i>Modified.</i> 381
Scapula, body, excision of. Fig. 388.	<i>Chalot.</i> 382
Scapula, excision of, subperiosteal. Fig. 389.	<i>Modified.</i> 383
Scapula, excision of angle. Fig. 389.	<i>Esmarch, modified.</i> 383
Sciatic artery, ligature of. Fig. 185.	<i>Kocher.</i> 137
Scissors, varieties of. Figs. 44, 47.	<i>W. F. Ford & Co.</i> 48
Scissors, manner of holding. Fig. 48.	<i>Löbker.</i> 49
Second finger, amputating, oval flap. Figs. 511, 512.	<i>Esmarch.</i> 472
Sequestrotomy, instruments employed in. Fig. 374 (half tone).	<i>Original.</i> 360
Shoulder, amputation of, racquet flap. Fig. 478.	<i>Esmarch.</i> 456
Shoulder joint, amputation of. Wyeth's method. Figs. 543, 544.	<i>Wyeth.</i> 487
Shoulder joint, amputation at, flap method. Fig. 545.	<i>Esmarch.</i> 489
Shoulder joint, amputation at, circular method. Fig. 548.	<i>Esmarch.</i> 490
Shoulder joint, oval-flap method. Figs. 550, 551.	<i>S. Smith.</i> 492
Shoulder joint, racquet-flap method. Fig. 552.	<i>Treves.</i> 492
Shoulder joint, amputation at. Figs. 553, 554.	<i>Treves.</i> 493
Shoulder joint, resection of, Senn's method. Figs. 396, 399.	<i>Senn.</i> 388
Shoulder joint, resection of, Kocher method. Figs. 400, 402.	<i>Kocher.</i> 389
Shoulder, dislocation, McBurney's book. Fig. 403.	<i>W. F. Ford & Co.</i> 392
Shrady's saw. Figs. 453, 455.	<i>W. F. Ford & Co.</i> 433
Silver wire in special tube. Fig. 130.	<i>W. F. Ford & Co.</i> 98
Simon's method. Fig. 751.	<i>Dennis.</i> 601
Skey's amputation. Fig. 569.	<i>New.</i> 502
Sliding in a direct line. Figs. 694, 697.	<i>Löbker and Prince.</i> 571
Spinal drainage. Fig. 331.	<i>Chipault.</i> 316
Spinal nerves, roots of. Fig. 333.	<i>New.</i> 321
Spinal accessory nerve, the linear guides. Fig. 214.	<i>Kocher, modified.</i> 171
Sponge-holder. Fig. 7.	<i>Wyeth.</i> 14
Spools for silk. Fig. 123.	<i>W. F. Ford & Co.</i> 86
Staffordshire knot. Fig. 119.	<i>Foster's Dictionary.</i> 84
Stay-knot, floss-silk. Fig. 120.	<i>New.</i> 84
Sterilizer, portable. Fig. 161.	<i>W. F. Ford & Co.</i> 113
Stokes's amputation. Fig. 627.	<i>Stimson.</i> 530
Stomatoplasty, Buck's method. Fig. 787.	<i>Buck.</i> 615
Stomatoplasty, Serre's method. Fig. 788.	<i>Treves.</i> 616
Subclavian right and innominate arteries. Fig. 206.	<i>MacCormac, modified.</i> 159

	PAGE
Subclavian artery, left. Fig. 213.	<i>MacCormac, modified.</i> 169
Subclavian artery, right, anatomy of. Fig. 206.	<i>Heath.</i> 159
Subclavian and carotid arteries. Fig. 216	<i>Kocher.</i> 173
Superior maxilla, divisions of. Fig. 379.	<i>Tillmanns.</i> 367
Superior maxilla, incisions in removal of. Fig. 380.	<i>Modified.</i> 368
Superior maxilla, division of. Fig. 381.	<i>Agnew.</i> 369
Superior maxilla, lines of incision in removal of. Fig. 382.	<i>Modified.</i> 370
Superior maxilla, lines of incision in removal of. Fig. 383.	<i>Modified.</i> 372
Superior and inferior maxilla, lines of incision in removal of. Fig. 384.	<i>Modified.</i> 375
Supernumerary digits. Fig. 680.	<i>Tubby.</i> 563
Supraorbital and infraorbital nerves, divisions of. Fig. 308.	<i>Kocher, modified.</i> 276
Surgeon's knot. Fig. 113.	<i>Heath.</i> 82
Suture, interrupted, removal of. Fig. 141.	<i>Esmarch.</i> 102
Suture, continuous. Fig. 142.	<i>Esmarch.</i> 102
Suture, continuous, tying of. Fig. 143.	<i>Original.</i> 102
Suture, quill. Fig. 144.	<i>Thomas Bryant.</i> 102
Suture, hare lip. Fig. 145.	<i>Esmarch.</i> 102
Suture, twisted. Fig. 146.	<i>Esmarch.</i> 103
Suture, button. Fig. 148.	<i>S. Smith.</i> 104
Suture, relaxation and coaptation. Figs. 149, 150.	<i>S. Smith.</i> 104
Sutures, three-cornered wounds. Figs. 151, 152.	<i>Wyeth.</i> 105
Sutures, deep and superficial, alternating. Fig. 140.	<i>Löbker.</i> 102
Syme's amputation. Figs. 587, 592.	<i>Esmarch.</i> 509
Syme's operation on nose. Figs. 720, 721.	<i>Syme.</i> 581
Szymanowski's saw. Fig. 437.	<i>W. F. Ford & Co.</i> 419
	<i>Modified.</i> 502
Tarsus, bones of. Fig. 569.	<i>Gray.</i> 409
Tarsus, bone and membranes of. Fig. 423.	<i>Gross.</i> 458
Teale's method, amputation. Figs. 482, 483.	<i>W. F. Ford & Co.</i> 78
Tenaculum. Fig. 105.	<i>Sayre.</i> 334
Tendo Achillis, division of. Fig. 34.	<i>Sayre.</i> 334
Tendo Achillis, rectification after division of. Fig. 342.	<i>Chalot.</i> 341
Tendo Achillis, lengthening of, Poncet's method. Fig. 353.	<i>Chalot.</i> 342
Tendo Achillis, lengthening of. Fig. 356.	<i>Chalot.</i> 343
Tendo Achillis, shortening of, Z method. Fig. 359.	<i>Chalot.</i> 341
Tendon lengthening, single-flap method. Fig. 350.	<i>Chalot.</i> 341
Tendon lengthening, double-flap method. Fig. 351.	<i>Chalot.</i> 341
Tendon lengthening, Anderson's double-flap method. Fig. 352.	<i>Anderson.</i> 341
Tendon lengthening, incision method. Figs. 354, 355.	<i>Chalot.</i> 341
Tendon transplantation, first series. Fig. 360.	<i>Vulpinus.</i> 344
Tendon transplantation, second series. Fig. 361.	<i>Vulpinus.</i> 344
Tendon anastomosis. Fig. 362.	<i>Chalot.</i> 345
Tenorrhaphy. Fig. 343.	<i>Sajous.</i> 339
Tenorrhaphy, Witzel's method. Fig. 345.	<i>Sajous.</i> 339
Tenorrhaphy, quilt suture. Fig. 344.	<i>Sajous.</i> 339
Tenorrhaphy, Wölfler's quilt suture. Fig. 346.	<i>Esmarch.</i> 339
Tenorrhaphy, Hüter's peritendinous suture. Fig. 346.	<i>Esmarch.</i> 339
Tenorrhaphy, Billroth's bundle suture. Fig. 347.	<i>New.</i> 340
Tenorrhaphy, oblique coaptation of ends. Fig. 348.	<i>Sajous.</i> 340
Tenorrhaphy, Hüter's method. Fig. 349.	<i>Esmarch.</i> 340
Tenorrhaphy, Glück's method, catgut repair. Fig. 349.	<i>Esmarch.</i> 340
Tenotome, pocket case. Fig. 340.	<i>W. F. Ford & Co.</i> 330
Tenotomes. Fig. 339.	<i>W. F. Ford & Co.</i> 329
Tension while sewing. Fig. 137.	<i>Treves.</i> 100
Tension of sutures. Fig. 138.	<i>S. Smith.</i> 100
Thiersch's rhinoplasty. Fig. 732.	<i>Tillmanns.</i> 587
Thigh, amputation of lower third. Fig. 633.	<i>Treves, modified.</i> 533
Thigh, amputation of, circular division, conical-shaped cavity. Fig. 634.	<i>Gross.</i> 534
Thigh, amputated. Fig. 635.	<i>Gross.</i> 534

	PAGE
Thigh, amputations of. Fig. 636.	<i>Treves.</i> 535
Thigh, amputation of, periosteal flap. Fig. 638.	<i>S. Smith.</i> 536
Thigh, amputation of, Farabeuf's method. Fig. 640.	<i>Treves.</i> 537
Thigh, amputation of, periosteum over bone. Figs. 641, 643.	<i>Esmarch.</i> 538
Thigh, amputation of, approximation soft parts. Figs. 642, 644.	<i>Esmarch.</i> 539
Thigh, amputation of, dressed. Fig. 645.	<i>Esmarch.</i> 539
Thumb, amputation of, oval method. Figs. 515, 517.	<i>Esmarch.</i> 473
Thumb, amputation of, lateral-flap method. Figs. 518, 519.	<i>Esmarch.</i> 474
Thyroid, excision of, Kocher's method. Fig. 882.	<i>Kocher.</i> 711
Thyroid, excision of, stages of operation. Figs. 883, 886.	<i>Kocher.</i> 712, 713
Thyroid, excision of, angular incision. Fig. 887.	<i>Kocher.</i> 714
Thyroid, excision of, dislocation of tumor. Fig. 888.	<i>Kocher.</i> 715
Thyroid, excision of, left-sided tumor. Fig. 889.	<i>Kocher.</i> 716
Thyroid, excision of, Kocher's grooved director. Fig. 890.	<i>Kocher.</i> 717
Thyroid, excision of, enucleation-resection. Fig. 891.	<i>Kocher.</i> 719
Tibial artery, anterior, ligature of. Fig. 198.	<i>Kocher.</i> 151
Tibial artery, posterior ligature of. Fig. 203.	<i>Kocher.</i> 156
Toe, great, single-flap method. Fig. 559.	<i>Esmarch.</i> 498
Toe, great, oval-flap method. Fig. 560.	<i>Esmarch.</i> 499
Toe, great, amputation of. Figs. 561, 562.	<i>Treves.</i> 499
Toe, great, amputation through. Fig. 555.	<i>Treves.</i> 497
Toes, amputation of. Fig. 556.	<i>S. Smith.</i> 497
Toes, amputation of all. Figs. 563, 564.	<i>Esmarch.</i> 499
Toes, great and little, lateral-flap method. Figs. 557, 558.	<i>Esmarch.</i> 498
Tongue, drawing forward of. Fig. 3.	<i>Wyeth.</i> 13
Tongue, operations on, instruments (half tone). Fig. 817.	<i>Original.</i> 636
Tongue, V-shaped incision. Fig. 813.	<i>S. Smith.</i> 637
Tongue, flaps united. Fig. 819.	<i>S. Smith.</i> 637
Tongue, hypertrophy of. Fig. 820.	<i>S. Smith.</i> 637
Tongue, Jaeger's and Roher's incisions. Fig. 821.	<i>Kocher.</i> 639
Tongue, Sédillot's incision. Fig. 822.	<i>Sédillot.</i> 640
Tongue, Roux, Syme, Rignoli, and Billroth's incisions. Fig. 822.	<i>New.</i> 640
Tourniquet, improvised. Fig. 90.	<i>MacCormac.</i> 73
Trachea, diameters of tubes. Fig. 861.	<i>Treves.</i> 681
Trachea, topography of. Fig. 862.	<i>Esmarch.</i> 682
Trachea, anatomy, trachea and larynx. Fig. 863.	<i>Heath, modified.</i> 683
Trachea, operations on, instruments for. Fig. 864 (half tone).	<i>Original.</i> 684
Trachea, Langenbeck's hook. Fig. 865.	<i>Esmarch.</i> 685
Trachea, laryngotomy and tracheotomy incisions. Fig. 866.	<i>Heath, modified.</i> 686
Trachea, laryngeal, tracheal incisions, deep. Fig. 867.	<i>Tillmanns.</i> 687
Trachea, opening of. Fig. 868.	<i>Esmarch.</i> 688
Trachea, tube in position. Fig. 869.	<i>Esmarch.</i> 688
Trachea, tamponing, Trendelenburg. Figs. 877, 878.	<i>Tillmanns.</i> 706
Trachea, tamponing, Hahn and Michael. Fig. 879.	<i>Tillmanns.</i> 707
Trachea, tamponing, Gerster's tampon. Fig. 880.	<i>Gerster.</i> 707
Traction loops. Fig. 51.	<i>Original.</i> 51
Transfusion, introduction of tube. Fig. 255.	<i>Esmarch.</i> 221
Transfusion apparatus, Collins's. Fig. 256.	<i>Esmarch.</i> 222
Transverse incision, closure by. Figs. 695, 696.	<i>Prince.</i> 571
Transverse section, right knee. Fig. 196.	<i>Esmarch.</i> 149
Transverse section, right leg, upper third. Fig. 199.	<i>Esmarch.</i> 152
Transverse section, right thigh, upper third. Fig. 191.	<i>Esmarch, modified.</i> 145
Transverse section, right thigh, middle third. Fig. 192.	<i>Esmarch, modified.</i> 146
Transverse section, right thigh, lower third. Fig. 193.	<i>Esmarch, modified.</i> 147
Transverse section, right leg, middle third. Fig. 200.	<i>Esmarch.</i> 153
Transverse section, right leg, lower third. Fig. 201.	<i>Esmarch.</i> 154
Transverse section, right arm, at axilla. Fig. 220.	<i>Esmarch.</i> 182
Transverse section, right arm, middle third. Fig. 221.	<i>Esmarch.</i> 183
Transverse section, at right elbow. Fig. 223.	<i>Esmarch.</i> 185

	PAGE
Transverse section, right forearm, upper third. Fig. 224.	<i>Esmarch, modified.</i> 186
Transverse section, right forearm, middle third. Fig. 225.	<i>Esmarch, modified.</i> 187
Trendelenburg's position. Fig. 62.	<i>W. F. Ford & Co.</i> 55
Trendelenburg's rod. Fig. 92.	<i>W. F. Ford & Co.</i> 75
Triangular flap. Fig. 734.	<i>Treves.</i> 588
Trifacial nerve, divisions of. Fig. 309.	<i>Gray, modified.</i> 278
Trifacial nerve, second division, resection. Fig. 311.	<i>Koehler, modified.</i> 281
Trifacial nerve, second division, exposure at foramen ovale. Fig. 312.	<i>Koehler, modified.</i> 282
Trifacial nerve, third division. Fig. 313.	<i>Koehler.</i> 286
Trifacial nerve, third division, foramen ovale. Fig. 314.	<i>Koehler, modified.</i> 291
Trifacial nerve, Pancoast's operation. Fig. 315.	<i>Koehler, modified.</i> 292
Tubercle of os calcis, transplantation of. Figs. 357, 358.	<i>Chalot.</i> 342
Tupfer, antiseptic. Fig. 73.	<i>Original.</i> 63
Tying reef knot, first step. Fig. 116.	<i>Heath.</i> 83
Tying reef knot, second step. Fig. 117.	<i>Heath.</i> 83
Tying reef knot, third step. Fig. 118.	<i>Heath.</i> 83
Upper lip, Buck's method. Figs. 780, 781.	<i>Buck.</i> 613
Upper lip, Sédillot's method. Fig. 872.	<i>Tillmanns.</i> 619
Upper lip, Dieffenbach's method. Fig. 783.	<i>New.</i> 614
Upper lip, Szymanowski's method. Fig. 784.	<i>Treves.</i> 614
Upper and lower lips, Ledran-Mackenzie method. Fig. 785.	<i>Terrier.</i> 615
Uranoplasty, Langenbeck's method. Figs. 802, 804.	<i>Esmarch.</i> 624
Uranoplasty, Dieffenbach-Fergusson method. Fig. 805.	<i>Treves.</i> 625
Uranoplasty, Davies-Colley. Figs. 806, 807.	<i>Treves.</i> 626
Uranoplasty, Fergusson's method. Figs. 808, 811.	<i>Fergusson.</i> 627
Verneuil's method. Fig. 730.	<i>New.</i> 585
Vessel approach. Fig. 170.	<i>Original.</i> 126
Webbed fingers. Fig. 681.	<i>Gross.</i> 564
Webbed fingers, Norton's operation. Fig. 681.	<i>Dennis.</i> 564
Webbed fingers, Diday's operation. Fig. 683.	<i>Dennis.</i> 565
Webbed fingers, Agnew's operation. Fig. 684.	<i>Dennis.</i> 565
Webbed fingers, Zeller's operation. Fig. 685.	<i>Dennis.</i> 565
Webbed fingers, Fowler's operation. Figs. 686, 687.	<i>Dennis.</i> 566
Whitehead's mouth gag applied. Fig. 798.	<i>Tieman.</i> 622
Wiper, antiseptic gauze. Fig. 73.	<i>Original.</i> 63
Wire serre-fine. Fig. 103.	<i>W. F. Ford & Co.</i> 78
Wladimirow-Mikulicz's operation. Figs. 431, 432.	<i>Tillmanns.</i> 415
Wrist, amputation of, circular method. Figs. 527, 528.	<i>Esmarch.</i> 477
Wrist, amputation at, single palmar flap. Fig. 529.	<i>Treves, modified.</i> 478
Wrist, amputation at, double-flap method. Figs. 530, 531.	<i>Esmarch.</i> 478
Wrist joint, excision of, Bourgery's method. Fig. 412.	<i>Esmarch.</i> 400
Wrist joint, excision of, Langenbeck's incision. Fig. 417.	<i>Treves, modified.</i> 403
Wrist joint, excision of, Ollier's incision. Fig. 417.	<i>Treves, modified.</i> 403
Wrist joint, excision of, Boeckel's incision. Fig. 417.	<i>Treves, modified.</i> 403
Wrist joint, excision of, subperiosteal, Lister. Fig. 418.	<i>Treves, modified.</i> 404
Wrist joint, incision, interrupted splint form, excision of. Fig. 419.	<i>Esmarch.</i> 405
Wrist joint, Esmarch's splint applied. Fig. 420.	<i>Esmarch.</i> 406
Wrist joint, plaster-of-Paris splint. Fig. 421.	<i>Esmarch.</i> 406

OPERATIVE SURGERY.

CHAPTER I.

THE GENERAL CONSIDERATIONS.

Operative Surgery treats principally of the manual procedures that are necessary for the accomplishment of the surgical object in view. An operation in surgery can be aptly compared to the execution of a verdict in law; therefore, as in legal measures, the reasons for the accomplishment should be based on a proper appreciation of the principles relating to the procedure. The surgeon, in most instances, bears a threefold relationship to the patient—viz., that of juror, judge, and executor. As juror, he inquires into and determines the facts concerning the surgical problem submitted to his judgment, and renders the verdict according to the established truths of the case. As judge, he estimates the importance of the facts and the value of the conclusions that can be drawn from them, as based on the results of his own and recorded experience, before he pronounces the decision, for which he alone, as executor, is compelled to bear the immediate responsibility.

It is therefore very essential to the welfare of the patient and to the dignity of the profession that the surgeon carefully ascertain and properly estimate the value of the facts relating to a case in order that the verdict be a just one, and that its execution does not needlessly inflict the patient nor cast opprobrium on himself or the profession. The being competent to operate skillfully is not sufficient for the purposes of surgery; for it is of great importance that the surgeon be qualified to so fit the patient and prepare himself that no unanticipated complication can happen during or at any time properly associated with an operation. No operation, however trivial, is entirely devoid of danger. It follows, then, that the surgeon who treats the natural apprehensions of patients and their friends with indifference or derision, will suffer some day from great humiliation, and perhaps loss of professional reputation, because of an unfortunate result, the possibility of which had been anticipated only by the friends or the patient. While the surgeon should take no mercenary advantage of opportunities born of the unnecessary though natural fear of patients and friends regarding an operation, still wise forethought on his part should not permit him to belittle or conceal the actual dangers of an operation when good judgment suggests that they be stated.

The risks of operations relate chiefly to the life of the patient, and to the usefulness and cosmetic aspects of the part subjected to the procedure. Urgent conditions demand prompt action; therefore, in such as these, less heed can be given to the established detail belonging to deliberate practice. In acute laryngeal stenosis, the prompt admission of air to the lungs is the great desideratum, and all other measures of treatment must be subservient to this end if death is to be averted. The needs of both slight and grave operations should receive deliberate thought, even when the state of the patient is not suggestive of immediate danger. The subsequent usefulness of a part, and the cosmetic effects of an operation, ought to be carefully weighed, and those concerned candidly informed of any unfavorable results in these respects that may follow a surgical effort. If this course be not observed, the manifestations of grievous disappointment on the part of the patient and friends may be the only acknowledgment willingly bestowed on the surgeon.

Regarding the general principles of surgery, the reader is referred to the many useful works on that subject, since it is not the intention of the author to intrude in this department except so far as to form a proper estimate of the risks arising from operations and the best means of meeting and of avoiding them.

Prior to an operation, especially if it be one of any magnitude, it is essential that the importance of the following facts relating to the patient be considered :

1. The age, sex, general physical condition, and occupation of the patient.
2. If the patient be suffering from shock.
3. The condition of the heart, lungs, kidneys, brain, and large vessels.
4. If there be any acute surgical or other complication of an important part of the body. A coexisting fracture, dislocation, severe contusion, or the involvement of an essential viscus, or of a serous or bony cavity, often adds great gravity to what might otherwise be a simple procedure.
5. If the patient be anæmic, scorbutic, rheumatic, hysterical, insane, etc. If he have syphilis, tuberculosis, epilepsy, glycosuria, hæmophilia, malaria, erysipelas, or be liable to an attack of delirium tremens.
6. If he be willing and prepared for the operation.

The Age.—As between youth and old age, operations are better borne by the former class. The most favorable period is between five and fifteen years, the next between fifteen and thirty years; after the latter period the risk to life is nearly twice as great as during it. The influences of the responsibilities, acts, and duties incident to advancing age increase the vulnerability of the vital forces in a marked degree. The subtle effects of physical and mental strain, of deteriorating practices, and the natural changes incident to increasing years, lessen the resisting power of the human organism in almost a direct proportion to their degree and extent. While youth is markedly sensitive to shock and pain, still the absence of responsibility and the presence of healthy organs enable this class to withstand physical injury better than the aged. The effect of pain, shock, loss of blood, restlessness, excitability, and the disarrangement and soiling of dressings, are the chief

elements of danger in the surgery of children; and the younger the children the more potent are the effects of these agencies. Aged patients differ in their degree of endurance from each other more than do the young. An aged patient who has good muscular and mental vigor, and is well nourished, not given to adiposity, has good digestion, sound organs, and pliable vessels, is the best of this class. But an aged patient who is fat, flabby, wheezy, and unused to exercise, with hardened arteries, bad digestion, and perhaps addicted to the constant use of alcoholics, is a poor subject indeed for any operation. His wounds should not be deep; his blood should be spared; his body kept warm; his food of moderate amount and easily assimilated; complications should be watched for, and the confinement in bed be made as brief as possible.

The Sex.—Women withstand operations and surgical injuries rather better than men. This difference is largely due to the fact that women are endowed with a greater degree of patience and fortitude, while under physical infliction, than men. Confinement to the house and in bed is better borne by them, and, too, they are more temperate and discreet in the customs and habits that are recognized as being inimical to human endurance. Unless it be urgently demanded, it is unwise to operate on the female during pregnancy, lactation, or menstruation. However, the gravest of operations have been performed under these circumstances without the appearance of an unfavorable manifestation depending on them.

The Physical Condition.—As a general proposition, those of good physical vigor bear operations better than those in a feeble state; but one is not to understand that such is always the case. The athlete who prides himself on his strength of frame and fleetness of limb, and whose entire system is fitted only for active effort, is ill prepared for the confinement of the sick-room. The semi-invalid and the one to whom confinement brings no special regret are, other things being equal, better fitted for the ordeals of operation than a veritable Hercules. It follows, therefore, that those of the former class should, if expedient, spend a few days on probation in the prospective sick-room, thus familiarizing themselves with its surroundings, while at the same time their emunctories eliminate the then useless residue of an active life. The obese patient is ill fitted for an operation, especially if the obesity has been the result of indolence, luxury, or intemperance. Hereditary obesity is of less moment than the acquired variety, especially when personal discipline has been directed unsuccessfully to the reduction of the latter. Physiological plethora, fortified by physical and functional vigor, offers no obstacle to surgery, but the acquired plethora of the tippler and the gourmand serves as a beacon, warning the surgeon against all operative procedures unsupported by the logic of expediency and unprotected by the strictest technique.

The Occupation.—The occupations that expose one to the depressing influences incident to mental worry, bad ventilation, and the inhalation of irritating, offensive, and poisonous gases and dust; those also that expose to the direct absorption of deleterious metallic and other agents, and that subject one to great extremes of temperature, are not infrequently of vital im-

portance in estimating the prognosis of operative procedures. The almost indelible imprint of the influence of occupation on the physical condition of patients makes it unnecessary to do more than to refer to the preceding special illustrations of the fact.

The Shock.—If the surgical condition demanding operation be a recent one, and the patient be suffering from shock, operation should be deferred until reaction is established, if wise. If the degree of shock be disproportionate to the extent of the recognized injury, a further examination of the patient should be made to determine the cause. If a complication be discovered which of itself imperils life or increases the gravity of the situation, then the question of operation is doubly perplexing, and the proper solution of the case requires the sagacity due to experience or the judicious forethought that prompts a consultation. A thoughtful scrutiny of those who are injured or diseased, supplemented by proper advisement, will lessen the pungency of the satirical expression, "The operation was successful, but the patient succumbed"! Shock may supervene during an operation, either as the result of the formidable character of the procedure or of the loss of blood. The previous condition of the patient, the degree and extent of the injury, and the time consumed in the operation are potent factors bearing on the occurrence and the degree of shock. Shock may be followed by syncope, syncope by collapse, collapse by death. In view of the importance of shock and its intimate relationship with surgical procedures, a surgeon ought not to attempt an operation unless he be informed as to the symptoms and the sequels of shock, their prevention and their prompt and effective treatment. (See page 121.)

The Condition of the Heart, Lungs, Liver, Kidneys, Brain, and Large Vessels.—Upon the sound condition of the viscera depend not only the advisability of an operation, but also of the choice and use of anæsthetics. If the kidneys be diseased, all operations, especially those on the genito-urinary tract, are invested with special danger. In the latter the simplest procedures are followed not infrequently by fatal suppression of urine; therefore a microscopical and analytical examination of the urine should always be made in advance of an operation when conditions will permit. A practical examination of the urine can be readily made, even under perplexing circumstances, by the use of heat or nitric acid. The symptoms of such affections as chronic bronchitis, emphysema, phthisis, are often aggravated by the administration of anæsthetics, especially ether; and the resulting dyspnoea and cough, loss of sleep and strength, are potent influences against recovery.

It is well to remember, however, that the mental emotion and physical suffering often associated with an operation without the use of anæsthesia may be more objectionable than the evil influence of the drug itself.

The presence of chronic dyspepsia with vomiting; organic disease of the liver with icteric manifestations; structural heart disease with respiratory interference; cerebral disease—acute or chronic—attended with cephalalgia or mental or motor disturbances; disease of the arterial system, suggestive of aneurism or the difficult control of hæmorrhage due to structural changes of

the coats; are among the prominent complicating factors of a case, and are deserving of respectful thought before the final decision is rendered.

The Complications.—The presence of complications of whatever nature should be studiously sought for and their importance estimated before operation. It is unfortunate, indeed, that a patient should die as the result of a complication, and especially if the complication has not been suspected before the operation. It happens often that patients die from known complications that are stimulated to vigorous action by the influences belonging to surgical procedures, and it is truly sad when such a result follows a surgical effort that was prompted more by sentiment than by necessity.

Tuberculosis, Syphilis, and Glycosuria.—The influence of these diseases on the prognosis of operations is modified by the acuteness and extent of the diseased processes, the ability to effect their complete removal, and the post-operative environments of the patient. The removal of a long-continued and exhausting site of serofulous or tuberculous disease—one that has caused persistent suffering and confinement within doors—is often followed by the promptest beneficial results, especially if no visceral complications have ensued and the patient can be placed under favorable sanitary surroundings. Notably this is true in children when complete removal of the products of diseased action has been accomplished. Incomplete removal of tuberculous products is always productive of questionable results; in fact, little is gained of local worth in these cases, except that dependent on improved drainage. The free opening of large tuberculous abscesses exposes the patient to the danger of exhaustion from suppuration, and to that of a general tuberculosis caused by the rapid production and spread of tuberculous infection through the body. Those suffering from acute or progressive tuberculosis of the lungs are unfavorable subjects for any operation that excites apprehension or requires the use of anaesthetics. Operations on such subjects as these are rarely permissible, except to lessen the burden already imposed by disease, and thereby to husband the strength of the patient, that he may better resist the continued infliction. Though the wounds of chronic tuberculous patients often heal quickly and well, still they may refuse to unite, or, after unsound union, reopen and become the source of great exhaustion. The wounds of syphilitic patients commonly heal well. Although the reverse of this result is rare, yet one is not justified in attempting local surgical measures in these cases without the previous employment of constitutional specific medication, if circumstances will permit.

In glycosuria, wounds heal badly and sometimes not at all, and the occurrence of cellulitis and gangrene are often provoked by operative measures. The results of preparatory treatment are fickle, as a rapid increase in sugar without apparent cause while under seemingly curative treatment frequently happens. Operations with this complication, if it be pronounced, should be those of last resort, and every chance of infection eliminated in all cases.

Patients afflicted with *rheumatism* or *gout* are good subjects for operation, provided heart and kidney complications are not present, or, if so, not well established. However, it should not be forgotten that the inaction of

the patient and of his secretions resulting from the confinement incident to an operation may soon provoke an attack of either of these diseases.

Hæmophilia, Scurvy, and Leucocythæmia.—In any one of these conditions no operation should be performed except from absolute necessity, as they each expose the patient to death from uncontrollable hæmorrhage, the first being especially fatal in this respect. It is important to know, however, that in hæmophilia one may not meet with fatal hæmorrhage, even after severe operations. Leucocythæmia, scurvy, and icterus not only predispose to severe and perhaps fatal hæmorrhage, but in addition to this wounds of those afflicted with the first two diseases suppurate profusely, heal badly, and often remain unclosed.

The statements of patients that they are “bleeders” should not be accepted as final in instances of emergency without confirmatory evidence. Not long ago the author had a patient with a pelvic abscess due to appendicitis, and who opposed operation because he had been assured by a physician a short time before that he was a “bleeder.” The statement was proved untrue for the time by making a short incision in the integument at the seat of the proposed operation, which incision healed quickly without an untoward symptom. Promptly thereafter the operation was done and the patient recovered in a most uneventful manner. (See page 67.)

Malaria.—Malarial poisoning often hinders healing, and predisposes to suppuration, inflammation, and neuralgia. An operation sometimes arouses latent malaria attended with febrile manifestations peculiar to itself, and if its nature be not recognized will cause the surgeon great apprehension lest they be the result of septic influences.

Erysipelas.—No avoidable operation should be performed in the presence of erysipelatous influences. If the surgeon be driven to this extremity, the most rigid antiseptic measures should be enforced. Patients with strangulated hernia, retention of urine, a crushed limb, and the like, require relief, and the surgeon must act promptly to save life, irrespective of conflicting demands.

Insane, hysterical, and epileptic persons are not good surgical subjects, as they are ill fitted to submit to the control essential to prompt and proper healing; moreover, their physical status is deteriorated and quite unresponsive to local and general medication, in many instances.

Alcoholism.—A person who is addicted to the continuous use of intoxicating beverages is a bad surgical patient, and, worse still, if he receives an injury during a prolonged debauch, as then he suffers not only from the effects of the previous excesses, but incurs a greater danger of delirium tremens.

Willing and Prepared.—It is not necessary to the successful issue of an operation that the patient be willing and prepared for it; yet, if such be the case, much will be added to the ultimate success of the measure. If he be irresponsible by reason of childhood or incompetent mental state, others who are accountable for or interested in him should be consulted. The approval by himself or those concerned should be accepted only after a clear statement on the part of the surgeon of the nature of the injury or disease, the necessity

for and the gravity of the operation, together with the probable result of the procedure. If the operation be a momentous one, the advisability of the adjustment of business and spiritual affairs should be suggested to the patient himself or to the friends. The satisfactory arrangement of such matters will reconcile the patient to his trials, and be a cause of satisfaction to the friends in any event. The *preparatory treatment* should be directed to improving the general condition of the patient, either by proper diet or by medication intended to antagonize the diseases and conditions that may prejudice the final result. The patient must be thoroughly examined in every material respect before an operation is undertaken in order to determine his actual physical status. It is unwise, if unnecessary, to operate precipitately; rather allow the patient to familiarize himself with the surroundings by remaining in the room for a time, and in bed even, if it adds to his comfort. After careful physical examination the patient should be bathed, and warmly clad, the bowels should be moved, the face shaven, the hair combed and neatly arranged, and the temperature, pulse, and respiration taken well in advance of the time of operation; also carefully examine the blood.

The Time for Operation.—The proper time for operation refers to the season of the year, the day and the time of day best suited for the purpose. It is fortunate, indeed, for all concerned when circumstances will permit the selection of the time that will contribute the greatest advantages to every interest connected with the case. Often, however, the urgency of the occasion commands prompter action, affording only sufficient time to make the immediate preparations referable to the patient and his surroundings and to the surgeon himself. At all events, the exact time should be settled and the engagement promptly kept. *A surgeon should not ever be lacking in punctuality on these occasions.* Many patients regard operative procedures on themselves with a degree of dread akin to that felt by a culprit whose time for punishment is fast approaching; and, too, they fix the time when the operation will be completed and themselves safely started on the road to recovery. Therefore, a needless delay disturbs their calculations, often arouses their superstition, defers and lessens their hopes, and perhaps destroys their courage, an element of great importance to successful issues.

The months of October, January, and April are regarded as the most favorable for operation; December, May, and November as the most unfavorable. In general terms, spring and autumn are the most favorable seasons. A cool, pleasant day with rising barometer and minimum humidity is best suited for the purpose. The hour of early morning is best, as then the light is ample, the time of worry limited, and the need for food avoided. However, there is no reason to believe that the advantages of selected months exercise as great influence on operative results as do other well-heeded opportunities and requirements, having but little bearing on the time or humidity of the day.

The Place for Operation.—The office of the surgeon is not the proper place to perform operations of any magnitude nor those requiring the use of an anæsthetic, because the rest and quiet that should follow can not be had if the patient be removed; and, moreover, anæsthesia is often succeeded by

persistent nausea and vomiting, and not infrequently by prolonged noisy delirium. In a private residence *the room for operation* should adjoin the sick-room, and, if possible, be convenient to the water supply. The room should be thoroughly cleansed by scrubbing the floor and walls, and wiping the ceiling and above the doors and windows with a dampened cloth. Fumigation with sulphur will not be amiss, unless it be employed to the exclusion of the preceding measures. Needless articles should be removed and others made aseptic, or be covered with aseptic sheets. Clean linen and blankets should be at hand. A good light should be secured and unwelcome observation from without excluded. The preparation of the room should be completed in time to permit the settling of dust before operation. If the room can be disconnected from the living rooms of the dwelling, the occupants will be spared the distress and annoyance arising from the noises and odors incident to the operation.

The Sick-room.—The sick-room should be commodious, sunny, and aseptic, and, when possible, on the second floor, with a southern exposure, and with the doors and windows so arranged that it can be easily ventilated without causing objectionable air currents. All sewer-connected wash basins or other receptacles of waste should be excluded from the room. The plainer the walls and ceilings the better, for, if the patient becomes delirious, the outlines and figures of decorations may invite and become the basis of exciting hallucinations. It is better at all times—for hygienic reasons—that the room be as plain as possible, and that all unnecessary articles, as carpets, etc., be removed therefrom. The bed should be single, with freshly-aired linen, and have a rubber cloth beneath the sheet if needed. During convalescence, and after all dangers from septic influences are passed, objects of interest may be placed upon the mantels and walls, which can be varied from time to time to please the fancies of the patient. The room should be made as cheerful as possible, consequently all annoyances should be removed whenever the faucies of the patient indicate their presence. The presence in the sick-room of flowers and other odoriferous agents are not to be encouraged, although they may exert a good moral influence in that they remind the patient of the existence of sympathizing friends without.

The temperature of the room should be maintained at about 70° F. *Pure air* is quite as essential to a rapid recovery as good food. The room should be thoroughly ventilated at least once each day. Ventilation can be readily secured by opening the windows and doors, thereby creating a through-and-through current, at the same time using caution that the patient be protected from direct draughts, and be well covered till the temperature shall have resumed a suitable standard.

The subsequent care of the room calls for scrupulous cleanliness, the prevention of offensive odors, and the prompt elimination of foul and disagreeable matters. Dusting should not be done without dampening the surfaces with an antiseptic fluid when practicable; and sufficient time should elapse after the dusting to permit the subsidence of the disturbed particles before the wound is exposed. All unnecessary articles causing or collecting dust should be kept away from the room until the wound is closed.

The Nursing.—The services of trained nurses are the most reliable, for not only are they familiar with the common details of the sick-room, but they are educated also to meet emergencies of unusual character, as secondary hæmorrhage, etc. The well-intended attentions and efforts of solicitous friends are often misleading to the surgeon as well as burdensome to the patient. Friends, too, are quite as apt to be controlled in their actions by the desires of the patient as by the expressed directions of the medical attendant. It is well to remember, however, that a discreet friend is a far better attendant than a garrulous, self-sufficient nurse. The attendant who proffers his views and airs his experience in the sick-chamber, hoping thereby to emphasize his attainments, is as detrimental to the moral atmosphere of the room as are closed windows and doors to the physical.

The Diet.—Precisely the variety and amount of food to be given are matters which must be determined by the requirements of the individual cases. Milk, eggs, milk punch, kumyss, and stimulants, are stereotyped articles, the usefulness of which is well established. The traditional beef tea and the elaborate chemical extracts with which the market is cloyed should not be substituted for them without special reasons.

The Requirements relating to Operations.—*The requirements* necessary to the attainment of commendable results may be divided into the essential and precautionary.

The essential requirements comprise the implements, agents, and information necessary to the proper performance of an operation, and a due consideration as to the probable result.

The precautionary requirements are those which are needful in the various emergencies that may complicate an operation; and if they become of practical utility, it is necessary that the emergencies be anticipated, and that the means to meet them be at hand and prepared for immediate use.

THE ESSENTIAL REQUIREMENTS.

1. A knowledge of the results of the operation to be performed, as modified by the patient's condition and the emergencies liable to occur.
2. A knowledge of the anatomy of the parts involved in the operation.
3. The anæsthetics; a proper knowledge of their administration and the combating of their dangers. (See page 16.)
4. The necessary instruments, and a knowledge of their use.
5. The suitable receptacles to contain instruments.
6. The operating table, sponges, "wipers," "tupfers," antiseptic pads, antiseptic solutions, rubber cloths, towels, sheets, empty vessels, etc.
7. The agents for controlling hæmorrhage.
8. The assistants, of suitable number and proficiency.
9. The proper preparation of the patient and surgeon, table, assistants, nurses, etc., for the operation.
10. The proper materials for the treatment of operation wounds, and a knowledge of their use.

A knowledge of the results of the operation to be performed as modified by the patient's condition and the emergencies liable to occur, is one of the

chief factors to be regarded in the determination of operative propriety, and is therefore entitled to primary consideration. This knowledge is gained from but three sources: *First*, from the personal experience of the operator; *second*, from the judgment of others present; *third*, from the recorded experience of the profession. The utilization of the second source implies the calling of a consultation, which should be done whenever a doubt exists in the mind of the surgeon regarding the nature or the result of an operation. This course not only offers to the patient every available chance for life and usefulness, but, in unfortunate results, it frequently soothes the feelings of disappointment experienced by all concerned. In every instance the surgeon should heed the teachings of the recorded experience of the profession, which record, being modified from year to year by practice and improved methods, to be of commendable utility should be recent.

An understanding of the anatomy of the part involved in an operation is always essential to the comfort of the operator, and frequently to the safety of the patient. This knowledge is somewhat difficult to acquire, and is always of uncertain tenure. In the instance of the general practitioner it consists largely of that which can be gained from text-books and anatomical plates, added to the anatomical knowledge retained since graduation. Those who reside near to and in large cities should avail themselves of the ample opportunities offered there to rehearse on the cadaver important operations.

The Anæsthetics.—The anæsthetics in established use are ether, chloroform, A. C. E. mixture, and nitrous oxide or laughing gas. The practical use of anæsthesia comprehends the selection of the anæsthetic, the preparations for anæsthesia, the methods of administration, and the treatment of the complications incident to their employment. Ordinarily the condition of the patient and the character and length of the operation will determine the selection of the anæsthetic. It not infrequently happens, however, that the surgeon is obliged to act in such matters irrespective of established rules, and even in opposition to his own judgment, owing to inadequate supply or adverse environment. The circumstances regulating the general employment of individual anæsthetics, together with the complications peculiar to their use, will be indicated in connection with the consideration of the individual drugs. The physical condition of the patient should be carefully scrutinized in all respects, to ascertain if he be subject to any special danger from anæsthesia or from the use of an especial anæsthetic. Much has been said already under the physical condition of the heart, lungs, etc., bearing on this question, and on account of the importance more will be added in connection with the detailed consideration of special anæsthetics.

The Preparations for Anæsthesia.—The preparations relate to those directed to the patient and to the administrator of the anæsthetic.

HOW TO PREPARE A PATIENT FOR ANÆSTHESIA.

1. Determine as to the healthful condition of the brain, heart, lungs, kidneys, and vessels, and, if disease be found, inform the patient or friends

of any additional danger incurred from the use of the anæsthetic. Administer to the patient at once the necessary remedies to forestall or mitigate the danger—as digitalis, strychnin, etc., in the instance of heart disease.

2. Make a record of the pulse and respiration; note the character of each, making due allowance for any excitement caused by surrounding circumstances; also the temperature—the rectal and vaginal are the most reliable. These observations will be much more trustworthy if they be made some time prior to the operation. A note of arterial pressure is often important.

3. Ascertain if solid food has been taken for six to eight hours before the operation; if so, either defer the operation or evacuate the stomach before giving the anæsthetic. The practical manner of meeting this indication is to omit the meal immediately preceding the operation. If the time be then too long, a glass or two of milk, or other suitable liquid food, five or six hours before will suffice. It is wise to remember that the apprehension of the patient may so hinder digestion as to give rise to objectionable emesis even with these precautions.

4. If false teeth be in place, remove them, also anything that might become dislodged and obstruct the larynx or œsophagus.

5. Loosen all constricting bands that surround the abdomen, chest, or throat.

6. Cause the evacuation of the bladder and rectum; this precaution will often prevent the patient soiling the clothes during anæsthesia.

7. Place the patient on the back with the head and shoulders raised slightly, neck not bent. If the patient's co-operation be needed to place the body properly for operation, then it may be advisable to administer the anæsthetic from the outset with the patient in the required position.

8. If the patient have a beard, it should be thoroughly wet, to prevent the escape of ether through it from beneath the cone.

9. So adjust the doors and windows as to admit fresh air without exposing the patient to draughts.

10. Endeavor to relieve the patient of any fear of danger attending the use of the anæsthetic. Patients who are disturbed by grave apprehensions or inconsistent fancies regarding the outcome of anæsthesia do not usually yield readily and satisfactorily to its influence.

Struggling patients should not be forcibly restrained, unless their efforts interfere with the administration of the anæsthetic, or there be danger that they will injure themselves. The means of restraint employed for such patients is manual, and may require not less than four assistants for proper execution (Fig. 1). The hands nearest to the head of the patient, of the assistants, should be placed respectively on the shoulders and pelvis of the patient, and the disengaged hands should grasp correspondingly the upper and lower extremities of the respective sides of the body. When thus arranged the control of a resisting patient with a minimum outlay of strength is readily attained. A rational control, instead of an absolute confinement of the patient's efforts by any physical means, is the wiser and safer plan. At all events, the operating surgeon should not tax his muscular strength and nerve command in the efforts to restrain a rebellious patient, for obvious reasons.

Coughing and swallowing in the early stages of anæsthesia indicate that the vapor is too strong, therefore it should be temporarily modified in intensity by the admission of air. If coughing, swallowing, or vomiting hap-

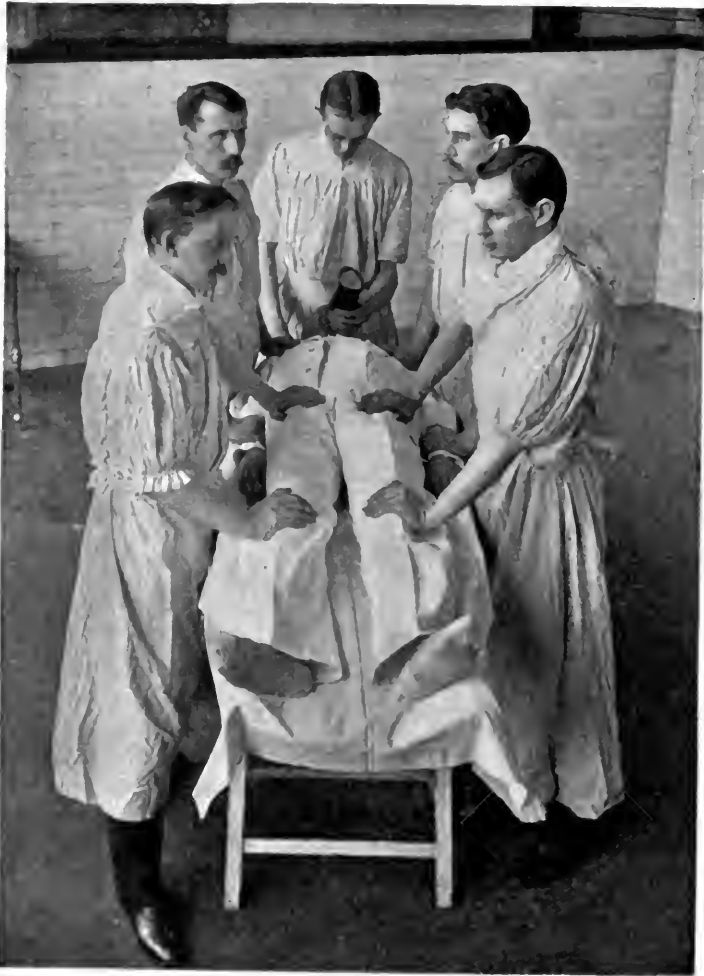

FIG. 1.—A method of restraint.

pen during the later stages of anæsthesia, it indicates returning consciousness, due to the employment of an inadequate amount of the anæsthetic, and a prompt increase is demanded in order to avoid the annoyance and delay incident to vomiting. Repeated acts of swallowing during the later stages of anæsthesia are often followed promptly by vomiting, hence the anæsthetic should be "pushed" at once to avoid this unpleasant result.

How to prepare the Administrator of an Anæsthetic.—Often, indeed, too little importance is attached to the giving of an anæsthetic. This post of responsibility is slighted when it is permitted to be occupied by one not

thoroughly competent to judge promptly and accurately of the effects of anæsthetics, and qualified to apply at once the necessary means to neutralize any unfavorable influences caused by them. The common custom of most hospitals in this country assigns the giving of the anæsthetic to the junior member of the staff. I am convinced that this practice is open to serious objection, as it happens not




FIG. 2.—Mathieu's tongue-holding forceps.

infrequently that the proper giving of the anæsthetic is a matter of greater moment than the performance of the operation demanding its use. At all events, I feel justified in saying that a perfunctory selection of one to give an anæsthetic is always an injudicious act, even though the protecting influ-

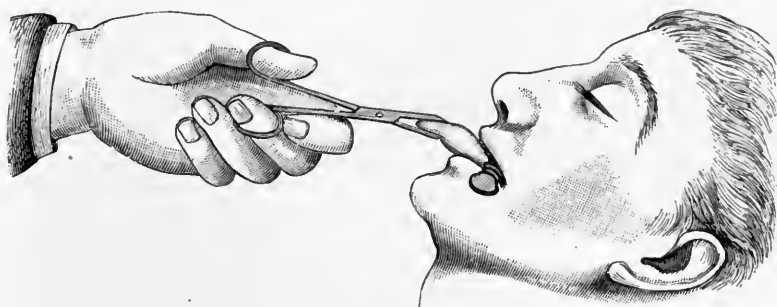


FIG. 3.—Drawing tongue forward.

ence of Nature's limitless resources interposes often in these cases, and converts that which might be an unfortunate disaster into a surprisingly good result. The administrator of an anæsthetic should have at his quick command *a tongue forceps, mouth gag, basin and towel, sponges and sponge holders.* The tongue forceps used for grasping and drawing the tongue forward (Fig. 3) should be so constructed as to cause the least possible injury to the organ (Fig. 2). The seizing of the tongue with ordinary forceps, or forci-pressure, as one not infrequently observes, inflicts a needless amount of injury, and subjects the patient to unnecessary suffering. The mouth gag (Fig. 4) should be of such a pattern as will admit of easy introduction between the closed teeth, as it frequently happens that the patient will vomit with clenched jaws, and therefore will

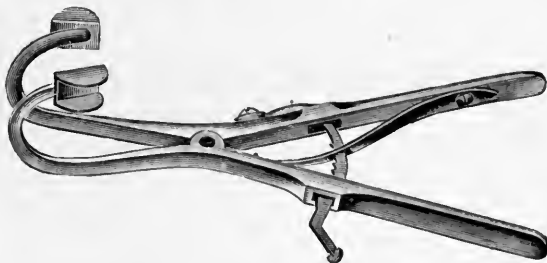


FIG. 4.—Denhard's mouth gag.

be in greater peril than otherwise from the inhalation of vomited matter; a hard-rubber oral screw can be used for this purpose (Fig. 5). A round pine stick of suitable size and strength, and properly pointed, can be inserted between the teeth more easily than any other agent, and without breaking the teeth or lacerating the gums, as occasionally occurs when forcible or hasty efforts are made to separate the jaws with a metallic implement. Fig. 6 illustrates the



FIG. 5.—Hard-rubber oral screw.

one used for many years by the author. *The basin* is for the reception of vomited matter, and *the towel* to wipe away the saliva and vomit from the mouth. If saliva collects in the pharynx of sufficient amount to

impede respiration, it should be wiped out with sponges held by a sponge holder or forceps (Fig. 7). It is very important that the sponge be securely held during the wiping, since not infrequently it has been torn loose while in the pharynx, quickly drawn into the larynx, and caused the death of



FIG. 6.—Wooden jaw pry.

the patient in spite of every effort at removal.

In addition to the preceding agents, there should be near at hand and prepared for instant use a hypodermic syringe, nitrite of amyl capsules, brandy, ammonia;

also suitable preparations of camphor, caffeine, musk, strychnin, digitalis, etc., for hypodermic use. The practice of injecting ether can not be commended in ether anaesthesia, not only on account of the local irritation and pain which it produces, but because it logically contributes to the depression already present. The employment of alcoholic

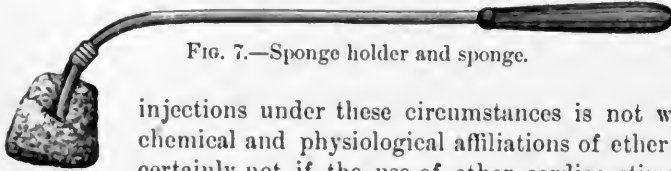


FIG. 7.—Sponge holder and sponge.

injections under these circumstances is not wise, owing to the chemical and physiological affiliations of ether and alcohol, and certainly not if the use of other cardiac stimulants be practicable. The employment of stimulating hypodermic injections in connection with anaesthesia is much more common than formerly, and the necessity for it is not clearly apparent; therefore there is good reason to regard the increasing tendency with disfavor. Adrenalin for injection should be at hand.

During the administration of the anaesthetic the giver should watch carefully the respiration, pulse, and facies of the patient. The character of the respiration can be estimated by the respiratory sounds and the abdominal and chest movements; the pulse, by the carotid and temporal pulsations; the facies, by the color, as whether pallid, florid, livid, etc., remembering that with each anaesthetic it should be possible to cause unconsciousness without cyanosis, and that any practical method characterized by its occur-

rence is open to serious objection. The relations of the patient and the administrator of the anæsthetic are such that he can easily estimate both the carotid and temporal pulsations without special effort, and also can push the jaw forward (Fig. 8) readily while holding the inhaler in a proper position. It is quite a common practice now to push the jaw forward continuously during the entire administration of the anæsthetic. This is unnecessary, as the pressure may serve no special purpose, except during profound anæsthesia; and a too persistent and vigorous use of force not only fatigues the anæsthetist, but also lames the patient's jaw.

Complete quietude on the part of all present should be maintained, since conversation often stimulates the patient's inebriated fancies, causing them to form the basis of disorderly actions. The handling of the part to be operated on prior to complete insensibility is a fertile source of disturbance, and is often suggestive to the patient of a premature beginning of the operation. The preparation of the site of operation early in the administration

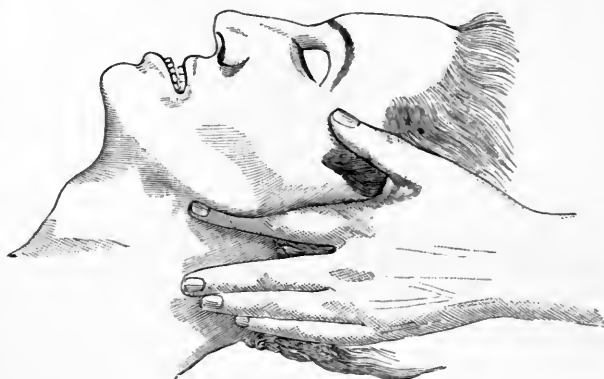


FIG. 8.—Pushing jaw forward.

of the anæsthetic not only delays the effect of the drug by disturbing the patient and exciting his fears, but it also increases the amount necessary for proper anæsthesia.

The Dangers from the Use of Anæsthetics.—The dangers attending the use of an anæsthetic may be reduced to a minimum, provided proper attention be given to the physical conditions recognized as contra-indicating it or requiring in all respects caution in the administration. The controlling influences in the selection of the anæsthetic will appear under the consideration of the uses of the individual agents.

In complete anæsthesia the pupils are variable, pulse is full, soft, regular, and perhaps accelerated; the respiratory acts are quickened, the inspirations deepened, and stertor is usually present; the muscles are relaxed, and reflex action is quite abolished. *The reflexes that are heeded as guides* in anæsthesia are four in number—viz., the movements of the limbs incited by irritation, as when caused by pinching or pricking the skin, and also relaxation, as demonstrated by flexion and extension without muscular opposition; spasm of the orbicularis muscle of the eye when the conjunctiva is touched; the reflexes of cough and deglutition stimulated by the presence of mucus and of the vapor in the throat, larynx, etc. The conjunctival reflex test is the one commonly applied to determine advancing or receding consciousness. It is especially useful for this purpose, since it is the last of the re-

flexes to disappear and the first to reappear during anæsthesia. Dilated and fixed pupils indicate excessive anæsthesia. The anæsthesia for the uninterrupted performance of operations on the mouth, rectum, and genito-urinary organs should be of a greater degree at the outset than for operations on other portions of the body, owing to the interference with continuous administration in the first instance, and to the greater sensibility of the parts in the latter instances. Since it appears that death happens with comparative frequency in trivial operations, with incomplete anæsthesia, the full effects of the drug should be secured before an operation is commenced.

It is difficult sometimes to secure complete anæsthesia—a fact that causes much annoyance and not a little trepidation on the part of the surgeon. This incident is commonly dependent on timid or inexperienced administration, or the use, perhaps, of an inadequate amount of the anæsthetic. The known likelihood of this difficulty in a patient requires a careful use of the drug, and a ready and thorough knowledge of the dangers and the methods of meeting and averting them. Patients who are feeble, aged, anæmic, suffering from shock and the benumbing influences of narcotics, yield quickly to anæsthetics, and for this reason corresponding care should be exercised. The ear of the administrator should attend keenly to the respiratory sounds, noting carefully all variations in their intensity and rhythm. A complete reliance, however, on the respiratory movements of the chest and abdomen as properly indicating the patient's condition in anæsthesia is unwise and misleading, for these movements may be present after complete exclusion of air from obstruction has taken place, which may be caused at any period of anæsthesia by foreign bodies in the larynx and trachea, such as false teeth and vomited matter. In complications of this character the obstructing agent must be removed immediately or death will ensue, unless tracheotomy be performed. During vomiting the head should be so lowered and turned to one side, as to carry the vomited matters away from the larynx; and the throat and mouth should be promptly relieved of vomit by sponges. The rima glottidis may be obstructed by the falling backward of the tongue, which happens only during the stage of complete anæsthesia, and can be readily remedied by pressing the jaw forward (Fig. 8), or by seizing the tongue with the forceps or a dry cloth and pulling it forward (Fig. 3). A tenaculum may be used, or the finger may be hooked over the base of the organ and the tongue pulled forward by this means.

Failure of respiration not dependent on obstructions of the air-passages may arise from senile changes of the respiratory muscles and framework of the thorax, chronic intrathoracic disease, shock, and loss of blood.

The Dangers of Anæsthesia and their Treatment.—The successful treatment for the relief of poisoning due to an overdose of an anæsthetic will depend not only upon the presence of mind of the surgeon, but upon the precautionary preparations which have been made for such a contingency, as well as the promptness and judgment with which the remedies are applied.

The dangers which result from the administration of anæsthetics are connected with either the circulation or the respiration. The dangers from

chloroform are chiefly in connection with the circulation, and are manifested by various degrees of circulatory depression. The dangers from ether and nitrous oxide are chiefly in connection with the respiration, and are manifested by various degrees of asphyxia.

The various degrees of asphyxia attending the administration of anæsthetics are due, for the most part, to the following causes: *Direct obstruction to respiration*, as caused by a valve-like action of the air passages and orifices above the larynx, and by foreign bodies; *spasm of the respiratory muscles and paralysis of the respiratory center* from an overdose.

The various degrees of circulatory depression during anæsthesia, which are attributable, directly or indirectly, to the anæsthetic, are due to giving too little or too much of the agent. The giving too little of the anæsthetic, causing incomplete anæsthesia, may result in depression of the circulation from nausea and reflex effects from operative procedures. This is rare under ether, but not uncommon under chloroform. Circulatory depression from an overdose of the anæsthetic occurs in two ways: If the overdose is administered gradually, the dangerous effects upon the circulation are usually secondary and consecutive to dangerous paralysis of respiration. If the overdose is administered rapidly, the circulatory depression is usually primary, especially in the case of chloroform. Unduly prolonged narcosis often causes gradual circulatory depression. The immediate dangers, therefore, in the administration of anæsthetics are manifested by either asphyxia or syncope.

One of the greatest sources of respiratory obstruction during anæsthesia is that associated with *stertor*, which may be of nasal, buccal, palatine, pharyngeal, or laryngeal origin. *Stertor* may be inspiratory or expiratory, and may occur during light or deep anæsthesia. During light anæsthesia it is frequently reflex from operative procedures, while during deep narcosis it is usually paralytic. The direct cause of *stertor* is the interference of the tissues and organs situated in the air-way above the trachea with the currents of air during inspiration and expiration. The situation of the tongue, its weight, and its relations with the epiglottis and larynx, render it perhaps the greatest source of obstruction to respiration during anæsthesia.

In the treatment of these conditions prophylaxis is of the greatest value, for a majority of the difficulties and dangers of anæsthesia are due to faulty administration.

Reflex stertor, if troublesome and distinctly connected with the operative manipulations, should be met by a deeper narcosis. *Stertor* not resulting from too light narcosis may be relieved by the following measures: extension of the head by raising the chin from the sternum; pushing the lower jaw forward by pressing behind its angles; pulling the tongue forward by the tip or hooking it forward from its base. One or more of these measures will relieve all ordinary obstructions to respiration during anæsthesia; but should they fail and the asphyxia be alarming, tracheotomy should be promptly performed. Obstruction to respiration due to valve-like action of the nares, cheeks, lips, and pharynx, should be prevented or relieved by the use of a nasal speculum or by holding the mouth open with

a small prop. Obstruction to respiration from foreign substances, as blood, mucus, stomach contents, or other material, should be met by their prompt removal.

An exceedingly rare form of obstruction to respiration during anaesthesia is due to spasm of the muscles of respiration with complete cessation of all respiratory movement. This form of obstruction usually occurs in the early stages of narcosis during the period of general muscular rigidity. All that can be done in such cases is, to see that the air-way is free and then perform vigorous artificial respiration. All forms of obstructed breathing resulting in asphyxia, with cessation or practical cessation of respiration, should, after determining the unobstructed condition of the air-way, be treated by artificial respiration. During this time the administration of oxygen to hasten the relief from asphyxia is indicated. Asphyxia from paralysis of respiration from an overdose of an anaesthetic is treated by stopping the administration, and, if necessary, promoting elimination of the anaesthetic by artificial respiration. In all cases of asphyxia the heart should be sustained by the administration of stimulants.

The best methods of performing artificial respiration for the purpose under consideration are: simple compressions of the chest, Silvester's method, and forced respiration. Forceful compression of the chest and its prompt expansion not only causes a considerable movement of air into the lungs, but is a powerful excitant of respiratory effort, when the patient's condition renders possible such response. Air forced from the lungs in this way also serves to remove obstructions, such as undue apposition of the epiglottis to the laryngeal opening, foreign bodies, etc.

Silvester's method of artificial respiration is readily carried out and more effective than other similar methods. Faradism of the phrenic nerves is a decided aid to artificial respiration. Forced respiration by means of the Fell-O'Dwyer or similar apparatus would probably be of great value in extreme cases of asphyxia of this nature if the apparatus were at hand and ready for use. (See Tumors of Ribs, Vol. II.)

The *syncope* which occasionally occurs from nausea and from operative procedures under light narcosis by chloroform should be avoided by avoiding the conditions which permit it to occur.

The minor degrees of circulatory depression, occurring under chloroform, may be relieved by lessening the administration, if the narcosis is of moderate or deep degree, or by changing to ether or A. C. E. and by the administration of restorative measures.

Alarming degrees of syncope call for prompt and energetic treatment. The administration should be stopped, and nothing allowed to interfere or delay the application of restorative measures. The condition of the circulation and respiration should be carefully noted. The anaesthetic contained in the air of the patient's lungs should be removed by rapid and effective artificial respiration, and throughout the treatment of the case the air-way should be maintained unobstructed. In the treatment of the graver forms of *syncope* the following are the chief measures of value:

The Posture.—More or less inversion of the patient is almost invariably practised under these circumstances, and there can be no doubt that many

lives have been saved by this means. The improvement in the pulse and respiration following inversion in *approaching* collapse from chloroform is proof of its value under these circumstances. Inversion is supposed to act by determining a flow of blood to the medulla and to the heart, thus stimulating respiration and circulation. Inversion has been employed, however, in nearly all of the fatal chloroform accidents. Thus it is evident that it is not invariably effective; indeed, it is probable that it is often positively harmful. In sudden complete syncope the heart is paralyzed and distended with blood, as are the great vessels of the chest and abdomen. Hill has pointed out that to invert a patient under these circumstances is "worse than useless," as "the paralytic dilatation of the heart is thereby increased." Hill recommends the following measures, which he has found to relieve nearly every case of this kind in animals. "Artificial respiration is at once applied, the thorax is rhythmically squeezed over the region of the heart, while the animal is placed in the horizontal position. If the pulse does not speedily return, the animal is dropped into the vertical, feet-down posture. By this simple means the heart, owing to the influence of gravity, is emptied into the splanchnic area, and thus the dilatation of the organ is relieved. Artificial respiration is maintained throughout this manœuvre. After a few seconds the animal is returned to the horizontal posture, and the heart is thus filled with a fresh supply of blood. If the pulse does not return, the movement is once more repeated. When the pulse has returned and the heart beat has become efficient, the artificial respiration can be discontinued, and after a short space of time the natural breathing will usually return, owing to the excitation of asphyxia. During this period the pulse must be carefully watched, and artificial respiration renewed if there be any signs of failure. The second type of collapse (slow and gradual overdose) is relieved by the vertical head-down position. It is equally relieved by the horizontal position and artificial respiration. As the anæsthetist can never be sure which type of collapse he has to deal with, it seems to me that the head-down method should never be employed. If we have to deal with the first type of collapse (sudden overdose), the latter method is a fatal mistake; if the second type of collapse confronts us, recovery can be brought about by performing artificial respiration and placing the patient in the horizontal position."

Artificial respiration carried out by rhythmic compressions of the thorax, by Silvester's method, by methods of forced respiration, and by faradism of the phrenic nerves, probably affords the most effective means of treating syncope from anæsthetics.

The method by *heart compression* has proved to be of great value in many cases of chloroform syncope. "The operator stands on the left side of the patient with face toward the head of the patient; the cardiac region is pressed upon with rapid and strong pressure by the ball of the right thumb laid upon the chest between the place of apex beat and the left border of the sternum; one hundred and twenty shocks or compressions are to be made per minute. Care must be taken to exert enough force. Fix the patient's body by the left hand on the right side of the thorax. Success is denoted by artificially produced carotid pulse and contraction of pupils,

which should control the force and rapidity of impulses. An assistant should watch the pupil and carotid pulse. As long as the condition of the patient does not improve, the pauses in treatment should be as far between and as short as possible. When the pupil contracts you may wait till it begins to dilate, or as long as spontaneous respiratory movements continue." (Maas.)

The Drugs.—Experiments have demonstrated the great value of strychnin and digitalis in the treatment of syncope from chloroform, and the inefficiency of alcohol, atropin, ammonia, amyl nitrite, and caffen. Strychnin must be used in large doses under these circumstances. The author (Dr. Bennett) has given three-twentieths of a grain in divided doses with advantage upon several occasions, and others have given still more.

Also experiments prove that suprarenal extract acts as a powerful vasomotor stimulant, and is highly recommended as an antidote to the depressant effect of chloroform.

The striking effects of the rectal, the subcutaneous, and the intravenous injection of saline solutions in conditions of shock and of collapse is proof of their value in syncope from anæsthetics. Laborde's method (page 22) of "tongue traction" has been resorted to in many cases of apparent death from anæsthetics with excellent results.

Brisk rubbing of the lips often excites increased respiratory efforts, and in the light breathing which occurs early in an overdose this excitant may be used to advantage. Faradism of the heart and its puncture with a needle have been recommended in chloroform syncope, but are impracticable and of doubtful value.

The After-Effects.—Nausea and vomiting constitute the most conspicuous and distressing though not the most dangerous consequences of anæsthesia. Nitrous oxide causes the least after-disturbance of this kind. Ether causes nausea and vomiting more frequently than chloroform, but more cases of protracted and dangerous vomiting are met with after chloroform than after ether.

Patients differ greatly in this respect. A patient may vomit excessively on one occasion, and little or none on another, under apparently like conditions. Patients properly prepared for anæsthesia have less sickness than those unprepared, although in many instances cases with full stomachs and no preparation are not nauseated from anæsthesia. Washing out the stomach at the close of the administration will lessen and perhaps prevent nausea and vomiting in a large percentage of cases, and is an excellent routine practise which should be carefully done.

At later periods this is one of the best means of treatment. After consciousness has been restored it may be practised at proper intervals by causing the patient to drink a glass of warm water and expel it by vomiting. A large dose of the bromide of sodium or potassium by rectum will often act beneficially. The administration of opium is occasionally the only means that will control this infliction.

Headache following anæsthetics, commonly noted after prolonged administration of nitrous oxide, is best relieved by cold applications to the head, by bromide, or opiates.

Bronchitis, broncho-pneumonia, and typical lobar pneumonia have occurred with noticeable frequency soon after anaesthesia. These diseases occur after all anaesthetics, but more commonly after ether than chloroform. They are not due to the direct effect of the anaesthetics on the pulmonary tissues, but are caused, for the most part, by infection of the lungs arising from aspirated infected material released from the throat during the narcosis. *Add to this the chilling influences attending the anaesthesia and the operation, the repression of coughing after certain operations, and the exposure incident to change from the operating room, change of clothing, etc., and it is not surprising that these pulmonary after-effects occasionally develop.*

Prophylaxis consists chiefly in the use of clean inhalers, cleansing the mouth, nose, and throat before administration, avoiding aspiration of foreign material into the air passages, and keeping the patient free from exposure and depression.

Renal congestion, nephritis, and urinary suppression are not infrequently observed after the administration of an anaesthetic. The effects of the deprivation of fluids before and after operation, the exposure attending it, and sepsis must not be overlooked in this connection. Saline infusion by way of the rectum, cellular tissue, or veins has proved of great benefit in promoting kidney action under these conditions.

Jaundice, glycosuria, insanity, and other abnormal states have been noted after anaesthesia. Their exact relations to the narcosis are not fully understood.

The After-Care.—During the recovery of patients from the effects of anaesthetics they should have certain special care. They should receive assistance during the vomiting, and, owing to the suddenness of its occurrence, the patient should not be alone until capable of taking care of himself. Vomiting is easily and safely accomplished if the patient is lying on the side. If the dorsal position is necessary, the head should be turned well to one side during vomiting. The elevation of the corresponding shoulder will aid the act. Vomited matters should be removed from the mouth as quickly as possible. The common custom of pushing the jaw forward during vomiting is unnecessary and dangerous. The act draws the tongue forward, exposing the glottis, thus defeating the natural means of protecting the air passage.

The patient should be guarded from exposure during recovery. The chilling influences of the anaesthetic and the operation render the patient unusually sensitive, and more than usual covering should be provided. *Artificial heat*, when necessary, should be provided, but the application should be cautiously made, as the patient, being more or less anaesthetic, may not appreciate that he is being burned. The patient should not be exposed to draughts, and undue sweating should be remedied.

The question of food and drink is important. The custom of withholding everything for many hours is unnecessary. The patient's desire for food and drink is often a reliable guide for the giving in small amount. Weak patients should not be kept as long as the strong without nourishment. As a rule, it is best to begin with small quantities

of warm fluids, continuing according to the conditions that present. Thirst may be relieved by giving large amounts of fluid by the rectum and small amounts by the mouth.

The Laborde Method of Artificial Respiration.—Laborde, who claims that traction made on the tongue excites directly the contractile respiratory function of the diaphragm, recommends the following method of artificial respiration: Place the patient on the back with the head low, clothing loosened, and jaws held apart. Free the throat from mucus; seize the tongue far back between the thumb and index finger, already covered with a dry cloth to prevent slipping; pull the entire tongue sharply forward, once in four seconds—fifteen times per minute—allowing prompt relaxation. These movements should be kept up for half an hour or more, as may seem necessary. The Laborde method can be supplemented by concentric thoracic and upward abdominal pressure applied in a rhythmic manner by two assistants at the time of relaxation of the tongue. While it is difficult now to estimate the relative worth of this method, there seems good reason to regard it with favor, especially when practiced in connection, as already indicated, with other manipulations.

The Results:

Statistics collected by Julliard:	ADMINISTRATIONS.	DEATHS.	RATE.	
Chloroform	524,507	161	1 in	3,258
Ether	314,738	21	1 in	14,987
Statistics collected by Ormsby:				
Chloroform	152,260	53	1 in	2,873
Ether	92,815	4	1 in	23,204
Statistics collected by Gurlt in Germany from 1891 to 1897:				
Chloroform	1 in	2,039
Ether	1 in	5,000
Statistics from St. Bartholomew's Hospital from 1875 to 1890:				
Chloroform	19,526	13	1 in	1,502
Ether	8,491	3	1 in	2,830
"Gas and ether"	12,941	1	1 in	12,941

There are only very few deaths reported from nitrous oxide, considering the millions of administrations that have taken place; the *rate* of mortality is probably one in several hundred thousand.

It is our opinion that the statistics of anæsthesia are particularly unreliable and misleading owing to the unreported fatalities, of which there are probably a far greater number than those reported.

Another source of error is the fact that the fatalities reported are, for the most part, due to the *immediate* effect of the anæsthetic, while those dying subsequently from conditions which may be attributed partly or wholly to the anæsthetic are more apt to go unrecorded. Ether probably furnishes a greater number of these latter cases than chloroform, conse-

quently the statistics of chloroform are probably more favorable than are generally believed. Nitrous oxide is the safest general anæsthetic, if its use is restricted to comparatively brief administrations. However, the prolonged administration of this anæsthetic is quite a different matter. At the present time there are not sufficient data relating to this plan of use to warrant reliable conclusions as to its safety. The writer has administered gas with air or with oxygen for operations lasting a few minutes and two hours or more in several hundred cases, without fatal outcome, although alarming symptoms have several times occurred with such rapidity and with so little warning that it seems probable that the general adoption of this variety of anæsthesia would lead to a mortality quite approximating, if not exceeding, that of chloroform and ether.

Ether is undoubtedly second in safety, whether used alone or following nitrous oxide.

Chloroform is the least safe of the agents under consideration.

In mixtures such as A. C. E. the most active ingredient is chloroform, the effect of which is modified by dilution and by the action of the other elements of the mixture. In point of safety these mixtures should probably be placed between those of ether and chloroform; the greater the proportion of chloroform the more dangerous is the mixture.

From the standpoint of statistics, the choice of an anæsthetic should be as follows:

First, nitrous oxide for such operations as necessitate *no more* than one complete administration of the gas.

Second, ether, whether given alone or preceded by nitrous oxide.

Third, a mixture such as A. C. E.

Fourth, chloroform.

There are, however, other factors than statistics to be considered before a proper choice can be made, and these are found in connection with the *condition of the patient and the nature of the operation.*

Ether.—Ether is employed much more in surgery in this country than all the other anæsthetics combined. The chief objections to its use are its pungency and inflammability, and the causation of nausea, vomiting, and cerebral excitement. The pungency can be lessened, and, in fact, almost entirely obviated, if a good volume of air be caused to mingle with it during the first few moments of administration. One has but to cover one's own face with the well-charged ether cone in common use to appreciate the sense of impending suffocation that is experienced by the patient, whose resistance is often violent, and suggestive of the belief that on his part the struggle is for life. Scenes of this kind ought always to be avoided. The resultant *nausea* and *vomiting* are not of sufficient importance to contra-indicate the use of ether, except in such cases as would be unfavorably affected by these manifestations. Vomiting is more dangerous when solid food has been recently taken, as then it may enter the larynx and trachea and cause suffocation. In not all instances does vomiting occur even when the stomach is more or less replete with food. This fact, however, should not prompt the giving with thoughtless haste.

The Inflammability.—This characteristic is to be regarded only while operating in the presence of artificial light and with the use of actual cauter. The employment of actual cauter in or near the mouth of a patient while under the influence of ether is to be avoided, for obvious reasons; in cases like this ether should not be employed, except with extraordinary care, and then only when absolutely necessary. The liability of ignition in the presence of artificial light is lessened by the fact that the weight of the vapor creates a downward current, thereby tending to remove it from contact with an igniting agent placed at the usual distance above the patient. It is wiser, however, for all concerned to treat ether on such occasions as if it were waiting only for the slightest opportunity to assert its explosive power.

The cerebral excitement which often precedes complete anæsthesia may depend entirely on the drug or be provoked by surrounding circumstances. The patient should be assured that no harm will attend the administration, and it should be given in a gentle manner—slowly at the beginning—in order that the bronchial mucous membrane may not suffer too great irritation.

Ether is employed more often, perhaps, than is wise if the various conditions of those to whom it is administered were analyzed and the resulting conclusions were met by the adoption of the anæsthetic best calculated to meet the exact requirements of a case. The quite pronounced general aversion to the use of chloroform, the inability to command nitrous oxide, and the inexperience with A. C. E. mixture, all hinder a proper discrimination in the general employment of ether. When practicable to avoid it, ether should not be administered to the aged, especially if marked atheromatous changes are noticeable. Acute or chronic kidney and pulmonary disease, or any intrathoracic affection attended with dyspnœa or cyanosis, contra-indicates the use at all ages. In laryngeal stenosis from any cause the spasm of the respiratory forces excited by the use of ether often produces alarming symptoms, and even death, dependent on suffocation. Ether is not as well borne by the obese and plethoric as by the stout and relaxed, provided the latter be not full-blooded. There is reason to believe that ether is not well borne by those who have been long addicted to the excessive use of alcoholics, irrespective of the influence on the patient of the visceral lesions that so often take place as the result of their use.

Ether Inhalers.—The variety of inhalers for the administration of ether is so great that it is no part of my intention to discuss their comparative worth, but, instead, to speak only of those in common use, and at the same time to offer to one who is removed from the basis of surgical supplies a knowledge that will enable him to construct the kind of cone that is largely employed. The simplest method of administering ether is by moistening a napkin or towel with the fluid and holding it to the nose and mouth. This plan is not satisfactory, inasmuch as it involves an unwise expenditure of time, a great waste of ether, and produces less satisfactory anæsthesia than any other method. In fact, this plan is employed so rarely as not to be esteemed of any special significance.

The simplest form of inhaler is known as the “cloth and paper cone” (Fig. 9).

The construction of this inhaler is simple, and the materials employed are always accessible. A sheet of paper of strong texture, or three or four layers of an ordinary newspaper two feet in length and eighteen or twenty inches in width, together with a strong piece of cloth the dimensions of which exceed those of the paper by two or three inches, and a dozen ordinary pins, are all that is required. Place the cloth—a towel is usually employed—and the paper on a table, with the paper uppermost; fold them in

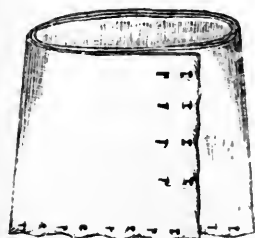



FIG. 9.—Cloth and paper cone.

the middle of their long diameter so as to bring the cloth on the outer surface and the paper within. Then fold them in the short diameter, the length of the fold corresponding to the distance from the symphysis mentis to the root of the nose of the patient; when thus folded, wrap around the fold the remainder of the material, and pin the outer and inner extremities firmly through the whole texture of the sides, using care that the pins be so placed as not to stick the patient's face or the hands of the administrator. Several pins are passed

through all the textures in various situations to hold them firmly together. One end can be closed, which is easily and quickly accomplished by turning inward the borders and securely pinning them to each other. It is better to close the end formed by the free borders of the material, reserving the other as a firmer basis to the cone. Into the top of the cone is crowded a good-sized sponge or a piece of coarse-textured cloth, always observing that it is well above the face of the patient. Numerous layers of muslin may be interposed between the borders of the upper end, instead of closing it by turning and pinning as just described. If this material be confined in position by means of pins, and the end covered with a layer of thin gauze, the ether can then be poured upon it and thus be administered without removing the cone from the face. The advantages which this simple inhaler possesses over the permanent and more expensive ones are quite numerous. It can not be damaged by the patient, nor will the face be bruised by its borders during his struggles; it is a temporary affair, and therefore need never be used a second time—a fact which is obviously of considerable importance in a fastidious and hygienic sense. It does not, however, admit of the easy regulation of the amount of ether to be given, nor the amount of air to be admitted; it is also liable, unless care be used in replenishing it with ether, to permit the anæsthetic to flow into the eyes and upon the face of the patient; in addition, the air space is almost invariably contracted during the struggles of the patient; yet these are objections which can be easily surmounted by a requisite degree of caution. The amount of ether required with this apparatus is less than if a napkin be used alone, but it exceeds that employed in the more perfect inhalers.

Allis' Inhaler.—Allis' inhaler is made of a fenestrated metallic framework for the support of cloth partitions (Fig. 10), surrounded by an adjustable leather or rubber covering (Fig. 11). It is simple, efficient, portable, and can be quite easily cleansed. Briefly stated, its advantages are the following: It

allows a free admission of air from above, which becomes saturated with ether; the evaporating surface is great, causing thereby a rapid vaporization, which hastens anæsthesia and saves ether; the ether can be replenished through the top, which obviates the necessity of removing the inhaler and interrupting the administration. The cloth partitions can be readily changed



FIGS. 10, 11.—Allis' inhaler.

whenever propriety and cleanliness demand. Fowler has modified this inhaler by making it collapsible, thereby economizing space in a surgical outfit (Fig. 12).

The inhalers of Clover, Squibb, Ormsby, and others are all serviceable, and whoever possesses either of them can, so far as the apparatus is concerned, administer ether with safety. It is not necessary to the security of the patient that any special one be employed. It is, however, necessary, no



FIG. 12.—Fowler's modification of Allis' inhaler (collapsible).

matter which one be used, that the administrator of the anæsthetic shall rely on the knowledge of the principles governing the administration rather than on the apparatus used.

Clover's Inhaler (Fig. 13).—Clover's inhaler consists of a receptacle holding two ounces of ether, a mouthpiece cushioned with inflated rubber fitting closely over the patient's nose and mouth, and connected with the ether receptacle in such a manner that the amount of ether inhaled may be increased or diminished at will. The rubber bag which receives the expired air is charged with ether vapor at the same time.

The advantages claimed for this inhaler are: The patient can be anæsthetized in a very short time; the depression of the system is not so great; the patient recovers consciousness more quickly, and does not feel the effects of ether as long as with the use of simpler forms of ether inhalers. The

amount of ether inhaled is regulated by adjustment of the apparatus; when turned at 0, no ether is inhaled; when at 1, one quarter is ether vapor; at 2, one half; at 3, three quarters; and at F the entire amount inhaled is ether vapor. Thus the quantity of ether administered can be increased or diminished during the operation. The small amount of ether consumed renders this inhaler very economical for hospital and field service.




FIG. 13.—Clover's inhaler.

Ormsby's inhaler is the simplest device for giving ether by the close method. It is not a regulating inhaler, such as Clover's, and is, therefore, inferior to the latter for the induction of narcosis, but is considered preferable for continuing the administration, being smaller, and having an air tap for regulating the air supply.

The amount of ether required to produce insensibility depends upon several conditions, the most important of which are the suscep-

tibility of the patient, the manner of administering, and the purity of the anæsthetic. Some persons can be completely anæsthetized by an ounce, and even less; on the other hand, one occasionally meets with those who "take ether badly," and can not be rendered quiet unless an unusual amount be given; rarely, indeed, a case is encountered which apparently will not yield to its influence, and the surgeon is forced to desist in the interest of the patient's safety. It is not prudent to predicate in advance the definite amount of ether that will be required, except possibly in some peculiar cases. Anæsthesia is never to be attempted unless the surgeon is certain he has a sufficient quantity of the anæsthetic to complete the operation, for nothing can be more humiliating than to be obliged to discontinue an operation for the purpose of procuring an additional amount. It is not wise to begin an operation that requires much time and care unless at least one pound of ether be at hand.

The Manner of administering Ether.—The manner of administering ether will depend somewhat upon the kind of inhaler that is used; if it be of

Ormsby's Inhaler (Fig. 14). — Ormsby's inhaler is the simplest device for giving ether by the close method. It is not a regulating inhaler, such as Clover's, and is, therefore, inferior to the latter for the induction of narcosis, but is considered preferable for continuing the administration, being smaller, and having an air tap for regulating the air supply.

Ormsby's Inhaler (Fig. 14). — Ormsby's inhaler is the simplest device for giving ether by the close method. It is not a regulating inhaler, such as Clover's, and is, therefore, inferior to the latter for the induction of narcosis, but is considered preferable for continuing the administration, being smaller, and having an air tap for regulating the air supply.

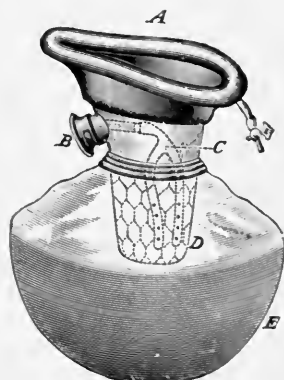

FIG. 14.—The Ormsby ether inhaler. A, face-piece with inflatable rubber edge (detachable). B, tap for admission of air and addition of ether, which passes to the cage D through the tube C. E, the rubber bag which permits re-breathing.

simple construction (Fig. 9), one should begin by pouring a small amount (an ounce or so) into or upon the inhaler (Figs. 10 and 11), and adjusting the apparatus so that a good volume of air will mingle with the ether for the first few moments of the administration. After the sense of pungency has somewhat subsided, the patient should be told to "cough," "breathe deeply," at the same time the fresh air is quite rapidly excluded from the lower end of the cone. The patient soon becomes oblivious, and may be fully anaesthetized without further delay. Often, however, the patient will be seen to pass through three distinct stages of anaesthesia, which will vary in their length and manifestations according to individual circumstances. In ether, as a rule, the pupils are dilated and in direct proportion to the depth of the anaesthesia.

Bennett's Ether Inhaler (Fig. 15).—Bennett's inhaler combines the advantages of Clover's and Ormsby's inhalers in that the strength of the ether vapor and the supply of air are under perfect control.

Chloroform.—Chloroform is a colorless liquid, having an agreeable odor and a sweet taste; is of high specific gravity, and non-inflammable. Were it not for the inherent dangers attending the administration it would without doubt be the most satisfactory anaesthetic in use. Ordinarily the patient passes under its influence without the exhibitions of turbulence and bronchial irritation that distinguish ether.

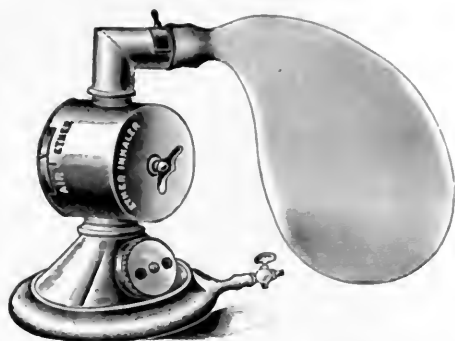


FIG. 15.—Bennett's ether inhaler.

There are not many practical differences between the manifestations of normal chloroform anaesthesia and those of ether. In ether anaesthesia, stertorous breathing and the abolition of the reflexes do not contra-indicate a continuous administration of the drug. In chloroform anaesthesia, however, the presence of those expressions are suggestive of the necessity for additional caution in the administration, since alarming symptoms may rapidly supervene at this time if fresh air be excluded or the amount administered be increased.

The fatalities from the use of chloroform are largely dependent on the inadequate dilution of the vapor with fresh air during the time of administration. If this fact be kept clearly in view under all circumstances, and the indications be observed, the danger from chloroform is not of sufficient moment to forbid its use when other anaesthetics are especially objectionable. The stage of excitement and the period immediately following it are the times of greatest danger; as, during the former period, the deep inspirations of the patient, supplemented by a close or thoughtless application of the inhaler, cause too great a volume of improperly aerated chloroform vapor to be inhaled. "With ether it is possible, almost with impunity, to pass be-

yond the realm of reflex action, and to keep up an unnecessarily deep narcosis; but with chloroform this is not the case, an overdose being likely, with but little warning, to set up the most alarming symptoms" (Hewitt).

It is now quite generally believed that chloroform destroys by paralyzing the respiratory centers (Hyderabad Commission). Wood and others, however, dissent from this view, and Wood presents a record of 384 deaths during chloroform anæsthesia, in which the pulse failed entirely before respiration in 227 cases, the respiration and pulse simultaneously in 77, and the respiration first in 80 cases. The anæsthetist should watch closely for any unusual respiratory and cardiac manifestations during the time of chloroform anæsthesia, and if any such occur, the administration should be suspended and prompt measures of relief be taken.

The fact that respiratory paralysis is said to distinguish chloroform poisoning ought not to foster inattention to cardiac action as indicated by radial pulsation. On the contrary, the anæsthetist should realize that feeble, hesitating, and irregular cardiac action without, or perhaps with but trifling respiratory failure during chloroform narcosis, is often a matter of grave significance. Usually the pupils are moderately contracted in chloroform anæsthesia.

Other things being equal, the cases best suited for chloroform narcosis are:

1. Those requiring operations on the throat and mouth, especially if actual cautery is to be employed. It is not an infrequent practice in these cases to give ether to a complete anæsthesia, and then continue with chloroform. In fact, ether must not be employed continuously here if actual cautery is contemplated, as unfortunate accidents have arisen from the unavoidable combustion of ether vapor. However, it should be recalled that the decomposition of chloroform vapor into phosgene gas by aid of gaslight often causes bronchial irritation and coughing of the attendants, and it is reported to have caused death of the patient from pneumonia in one instance.

2. Operations on the neck complicated with present or prospective venous engorgement, as in tracheotomy for the relief of laryngeal stenosis, etc.

3. In abdominal section, to avoid, if possible, the unpleasant results following the coughing, vomiting, and struggling of the patient, which are common with the use of ether.

4. In operations directed to the anus, perinæum, and genital organs, the potent analgesic effects of chloroform are often serviceable, especially if there be objection to the profound anæsthesia of ether, which is often necessary to overcome the acute sensibility of these parts of the body. For the same reason chloroform offers special advantages in oral and ocular surgery, and in labor. However, the greater the dose of chloroform the greater is the danger.

5. Chloroform can be employed wisely in childhood, and in the atheromatous changes of old age. However children are not specially immune to danger from this drug.

The Administration.—Before the administration of chloroform is begun, the nose and adjacent portions of the face should be smeared lightly with

vaseline or a similar substance, to obviate the danger of the vesication that frequently arises from the incautious contact of the drug with the naked skin. Chloroform may be administered by the aid of a plain smooth napkin held near to the nose and mouth of the patient. Not infrequently the napkin is rumbled into a conelike form and used in that shape. In either instance the chloroform should be dropped on the cloth rather than poured on, as then a suitable amount can be easily estimated. Four or five drops used at the outset is quickly followed by a similar or even larger quantity. This amount repeated from time to time, supplemented by a liberal supply of fresh air, soon causes complete and safe anæsthesia.

The Chloroform Inhalers.—The simplest and best inhalers are Esmarch's, Skinner's, and Junker's devices.

Esmarch's Inhaler consists of a properly shaped wire framework covered with flannel and so arranged that it may be fastened to the head (Fig. 16). A few drops of the anæsthetic are discharged from a graduated bottle

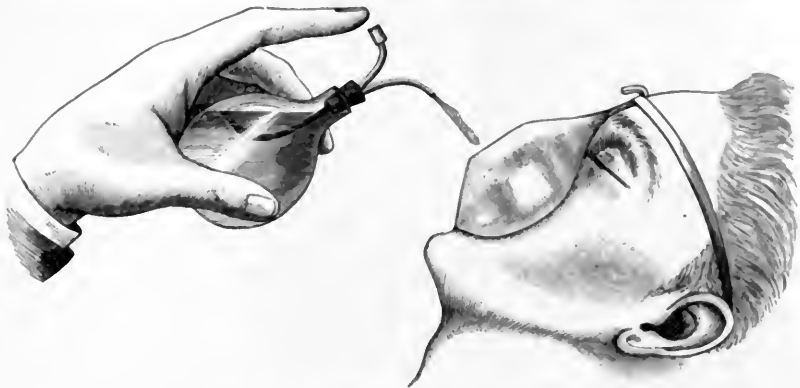

FIG. 16.—Esmarch's chloroform inhaler.

on the cloth from time to time until the desired effect is attained. The flannel covering should be kept dry at the sides, that fresh air may be freely admitted there during the administration. The head attachment of Esmarch's inhaler permits the anæsthetist to maintain a constant scrutiny of the pulse with the disengaged hand.

Skinner's Inhaler and bottle differ in no essential respects from those of Esmarch, and are employed in a similar manner.

Junker's apparatus is formed of a hand bellows and face-piece connected with a graduated bottle for the anæsthetic (Fig. 17). About an ounce of chloroform is put in the bottle, and the bottle is attached by the hook to a garment of the anæsthetist. Then, after placing the face-piece in proper position, aerated chloroform vapor is administered by gentle pressure of the hand bellows. It is estimated that a single compression of the bellows vaporizes about one and one fifth minim of chloroform, provided that the fluid be at a temperature of 55° F. If a flexible metallic tube or tubes with fixed curves for use in the nose and throat (Fig. 18) be substituted for the face-piece, the vapor can be discharged deeply into the mouth

or throat without hindrance to the operator, in cases requiring surgical interference with the throat or palate. The availability of the apparatus to meet this requirement appears to me to be the chief advantage that it offers over the other inhalers. If care be not taken in this method of use, liquid chloroform will be discharged from the apparatus instead of the vapor.

Occasionally ether and chloroform are employed interchangeably in the same case, chloroform being



FIG. 17.—Junker's apparatus.



FIG. 18.—Nasal and pharyngeal tubes (Junker's apparatus).

given at the outset with the view of avoiding the irritating effects of the ether. Again ether is given later on to avoid or overcome the depressing influence of chloroform. However, great pains should be taken on such occasions to consult the safety rather than the comfort of the patient.

A. C. E. Mixture.—This fluid is composed of one part of pure ethylic alcohol, two parts of pure chloroform, and three parts of pure ethylic ether. The mixture has an agreeable odor, and should be regarded as diluted chloroform and be administered accordingly. Esmarch's or Skinner's apparatus (including the droppers) should be employed for use in children and feeble adult patients. Allis' inhaler can be utilized in the administration to the vigorous, but in all cases a liberal supply of air should be secured. In the latter class half a drachm at a time may be discharged into the cone; in the former the fluid is sprinkled on the inhaler by means of the drop bottle. A uniform evaporation of the ingredients is necessary for the best results, and therefore small amounts should be employed frequently, rather than large ones occasionally.

A. C. E. mixture is not used in this country to any considerable extent.

The sensitive respiratory membranes of the young, and the diseased ones of the old, are irritated but little by it. Persons above sixty, those who are obese, those with cardiac or pulmonary disease attended with dyspnoea or cyanosis, respond satisfactorily to a judicious employment of this mixture.

The dangers and the discomforts attending the administration of ether and chloroform have called for the outlay of much time and effort directed to their abolition. However, the recent ingenious devices for administration, and the different combinations of gases and vapors with decided practical advancement, is a source of much congratulation. *Schleich*, of Berlin, brought forward still another method, the claimed safety and comfort in the use of which are based on the relation of the boiling point of the anæsthetic to the rapidity of the evaporation; the more rapid the evaporation, the greater the comfort and the less the danger of the use, and *vice versa*.

The following three mixtures are those recommended by *Schleich*:

Mixture 1.—(Boiling point, 100·2° F.) Chloroform, 45 parts; petroleum ether, 15 parts; sulph. ether, 180 parts.

Mixture 2.—(Boiling point, 104° F.) Chloroform, 45 parts; petroleum ether, 15 parts; sulph. ether, 150 parts.

Mixture 3.—(Boiling point, 107·5° F.) Chloroform, 30 parts; petroleum ether, 15 parts; sulph. ether, 80 parts.

The boiling point of the petroleum ether should be between 140° and 149° F. An ounce of the No. 1 mixture is sufficient for an operation lasting twenty minutes or so. The longer the operation is to be, the higher should be the boiling point of the anæsthetic, as such anæsthetics evaporate less rapidly, and therefore exercise a more profound and lasting effect on the patient. The manner of giving differs in no essential regard from that of the careful administration of other anæsthetics by means of a dropper, and the same precautions are likewise enjoined. Extended experience in their use does not warrant belief that these mixtures have special advantages.

Nitrous Oxide.—Nitrous oxide is the most agreeable and safest anæsthetic in use, and the death rate is infinitesimal. If the patient have heart disease, kidney disease, or phthisis, nitrous oxide is a suitable anæsthetic; but if much degeneration of the vessels or aneurism be present it is objectionable on account of the high blood pressure it causes. The administration is now principally in the hands of specialists. It is often given by those skilled in its employment for the purposes of major operations when other anæsthetics are contra-indicated, and preliminary to the use of ether to obviate the primary discomfort and perhaps alleviate the sequels of the latter. In the former class of cases the anæsthetic state is often prolonged for an hour or more with safety to the patient. However, the short period of anæsthesia, unfamiliarity with the use, and the completest outfit required for administration hinder the general adoption of this meritorious agent. In some hospitals it is highly regarded for the demands of simple operations and the making of diagnoses under painful circumstances. But inasmuch as the use of this anæsthetic is not yet practicable in a general surgical sense, any desiring further information should seek it of those who are skilled by experience, and from the special literature addressed to the subject. There are

several different plans of administering this agent—viz.: pure, mixed with air, or mixed with oxygen. Administered in a pure state, the resulting anæsthesia is *complicated* by asphyxia depending upon deprivation of oxygen. Given in combination with small percentages of air, complete anæsthesia may be induced with marked lessening or absence of asphyxia. In combination with oxygen, complete anæsthesia results without asphyxia.

Dr. Bennett's gas inhaler (Fig. 19) consists of three parts—the face-piece, the valve chamber, and the gas bag. The face-piece is identical with that of the ether inhaler. A complete description of Dr. Bennett's inhalers and the method of their operation is provided with each apparatus.

Nitrous Oxide with Oxygen is unquestionably the best and safest form of nitrous-oxide anæsthesia. It possesses all of the favorable characteristics of the latter, and is to a great extent free from the worst of its unfavorable features, i. e., the asphyxial element, to which may be attributed practically all that is dangerous and unpleasant in ordinary nitrous-oxide anæsthesia. The unfavorable characteristics of gas and oxygen are as follows:

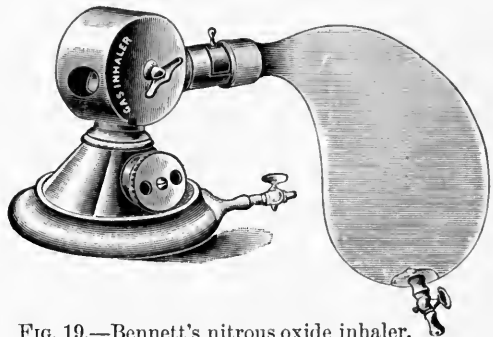


FIG. 19.—Bennett's nitrous oxide inhaler.

1. Difficulties, inconvenience, and expense of the administration.

2. Light form of narcosis.

3. Failure to procure satisfactory anæsthesia, in a small percentage of cases.

1. *Gas and oxygen* is vastly more difficult to administer satisfactorily than chloroform or ether, requiring considerable experience and the closest attention. It is practically impossible to move the patient after this anæsthetic has been started without disturbing the narcosis. It is, therefore, necessary to have the patient upon the operating-table before beginning anæsthesia. Any other position than the supine renders the administration too difficult to be practicable. The apparatus is large, and is apt to be in the way in operations about the head or neck. It is necessary to protect the tubes through which the gases flow from pressure. If stepped upon they will burst, as the author has several times experienced. The cost of a long administration of gas and oxygen is considerably more than ether or chloroform.

2. While narcosis may be carried to a deeper degree with gas and oxygen than with gas alone, it occasionally is not deep enough, which is especially true in rectal and abdominal operations. The abdomen is peculiarly apt to remain rigid, even though the narcosis is deep and free from signs of asphyxia. Gas and oxygen anæsthesia is not recommended in intra-abdominal operations, except in cases in which the advantages more than offset this particular objection.

3. Failure to produce satisfactory anaesthesia is exceedingly rare, and is apt to be the result of faulty administration. However, the author is convinced that there are patients who, with fairly skillful treatment, will not pass into that quiet deep narcosis so desirable. These patients probably belong to the class that take anaesthetics badly, requiring large amounts, and exhibiting marked resistance to the action of the agent.

The Choice of Gas with Air or with Oxygen as the Anaesthetic.—The limitations already noted regarding the scope of nitrous oxide for surgical operations indicate its field of usefulness. In the writer's judgment, the chief indications for employment of this form of anaesthesia are found: 1. In patients who are more than usually endangered by ether or chloroform, because of their general physical state or on account of the presence of some special pathological condition. Examples of this class are: the very weak patients, the very aged, those presenting active lesions of the lungs, the kidneys, or the heart. 2. In operations that are short or trivial so as to render the effects of ether or chloroform out of proportion to the requirements of the case. 3. In patients who previously have suffered unusually from the effects of ether or chloroform, and who have great dread of these drugs. The administration of two or more anaesthetics in succession forms a distinct method of practice, and is attended with numerous advantages.

Gas before ether, consisting in the administration of nitrous oxide before ether, is perhaps the best example, and its advantages are: the induction of unconsciousness is almost ideal, being accomplished in from ten to twenty seconds, with practically no discomfort. Complete ether narcosis may be obtained in from two to four minutes from the beginning of the gas, with entire absence of a stage of excitement.

Chloroform before ether is frequently resorted to in order that the patient may have the comfort of the more agreeable and less pungent odor of the former and to avoid the mental effect often produced upon the patient by the more formidable apparatus used in the administration of the latter. In this plan it should not be forgotten that a large percentage of the deaths from chloroform have occurred during the early part of its administration.

Chloroform mixtures before ether are less dangerous and nearly as pleasant. Ethyl bromide and ethyl chloride before ether produce unconsciousness nearly as quickly as gas, but




FIG. 20.—Bennett's "gas and ether" inhaler.

are less pleasant to inhale. The succession of gas, ether, and chloroform is suitable for those cases in which the latter agent is indicated, and in which it is desirable to avoid the conditions noted during the stage of excitement.

The condition of the respiration and circulation under nitrous oxide renders the succession of gas and chloroform a dangerous procedure, and it should not be undertaken.

A change from one anæsthetic to another is often advantageous during an administration. Thus the sedative and depressing effects of chloroform are counteracted by those of the previous or subsequent administration of ether. The irritation or excessive stimulation of ether is overcome by changing to chloroform.

The administration of oxygen during anæsthesia has received much attention, especially in conjunction with nitrous oxide, which when given in a pure state is complicated by asphyxia resulting from deprivation of oxygen. Oxygen has been recommended in conjunction with ether and chloroform by numerous observers, and while it is probable that oxygen is not an antidote to these agents, and will not prevent their fatal effects when administered in an overdose, there is no doubt that its use will lessen or obviate the asphyxia which frequently complicates their administration, thereby removing an unpleasant and occasionally dangerous element of the narcosis.

Experience has demonstrated that chloroform and ether may be administered in such a manner that the patient does not suffer from lack of oxygen, and it is therefore evident that the routine use of this agent during anæsthesia is uncalled for. A possible danger in its use is the following: "The supply of oxygen keeps the patient of a cherry-red color, and chloroform is pumped on until the respirations stop through poisoning of the medulla. No peripheral dusiness or gradual failure of respiration appears, as the tissues remain red until circulation and respiration cease." (Buxton.)

Morphin with Anæsthetics.—It is recommended, and with much force, to administer, hypodermically or otherwise, a small dose of morphin an hour or so before anæsthesia is commenced. If chloroform is to be employed, the dose of morphin should be much smaller than if ether is used, and, too, the administration of the former should then be conducted with the greatest care, as chloroform acts more rapidly and profoundly when morphin has been given. Morphin ought not to be administered while the patient is under complete anæsthesia, since the combined effects of the drugs may cause unpleasant results that perplex and alarm the surgeon. It is advised by some to delay giving the morphin until signs of returning consciousness are well established, as then the cause of any unexpected manifestations can be the better interpreted. The morphin quiets the nervous excitement of the patient, reduces the amount of the anæsthetic otherwise necessary, and prolongs its effects, lessens the tendency to nausea and vomiting, and diminishes shock. This plan is not one of routine practice; it is used with great discretion.

Moderate Inebriation.—Moderate inebriation with brandy or whisky can be induced in advance of an operation for injury already attended with dangerous shock; and, too, this plan can be utilized in those cases that are greatly weakened by chronic disease. If a severe operation be necessary

under the above circumstances, the patient can be brought to a state of semi-intoxication in four or five hours by the administration of an ounce or two of brandy or whisky every hour in hot milk or hot beef tea. A small dose of morphin may be given shortly before the operation. Now, if ether be administered in the usual manner, the amount required will be small, and the analgesic stage will be sufficiently prolonged to permit the performance of the final minor details of the operation, without the further use of ether or the causing of pain and annoyance to the patient.

Rapid Respiration.—Rapid respiration will cause sufficient analgesia to permit of slight operations, as the passage of a probe or sound, the manipulations of inflamed or injured parts, without pain. The effect is produced by causing the patient to breathe rapidly for two or three minutes, or until there is a tingling of the extremities and surface, attended with a sense of fullness of the head, dizziness, and confusion. Those who suffer from organic disease of the heart, lungs, or brain should not attempt this measure.

Local Anæsthesia.—Numerous agents are known that will cause local anæsthesia. The majority of them, however, are noted more as ingenious exhibits of chemistry than of practical anæsthesia. The ones commonly employed are ice, ether, chloride of ethyl, cocain, and eucain.

Ice.—Ice, when cracked finely and combined with an equal amount of salt, restrained by a rubber or gauze inclosure, and applied directly to the part long enough to cause the surface to become pale, bloodless, and numb before the incision is made, is serviceable, and requires no further mention here.

Sterilized fluids, such as distilled waters, or the physiological saline solution, may be injected into the skin in small amounts by a hypodermic syringe, causing wheals and inducing sufficient anæsthesia to make painless minor operations of the surface. It is not impossible that much of the virtue of dilute medicated fluids is the result of a mechanism not unlike that of simpler fluids.

Ether.—Ether is easily obtained, and can be readily applied by means of an atomizer (Fig. 21).



FIG. 21.—Richardson's atomizer.

The pain following the return of sensibility is often more severe than is the immediate suffering from the operation without its use. The tissues ought not to be frozen, but benumbed, since to freeze them adds to the pain and retards repair.

Chloride of Ethyl.—Chloride of ethyl acts in a similar though more painful manner than ether, and can be easily and neatly employed by compressing the valve controlling the nozzle of the tube in which it is offered for sale (Fig. 22). This anæsthetic can not be readily procured in most localities, and is therefore of lesser utility than ether. It must be carefully kept in a cool place. Its effect is produced in about thirty seconds.

Cocain.—Hydrochlorate of cocain is an excellent local anæsthetic. It is applied in solution to all mucous and cutaneous surfaces, and also is injected into the tissues beneath these surfaces with very satisfactory results. It is applied to mucous surfaces in solutions of various strengths, usually




FIG. 22.—Chloride of ethyl.

from five to twenty per cent, either directly by means of a swab or through the agency of a spray. It may be applied to the cutaneous surface in similar ways, but its action here is

comparatively feeble and delayed; therefore, small injections into the skin are preferred to relieve the pain of trivial incisions. Solutions of divers strengths are used in the deeper tissues, the strength employed depending on the amount to be injected and the character of the contemplated operation. Ten to thirty minims of a four-per-cent solution, or an equivalent of a two-per-cent, can be employed subcutaneously with satisfaction in minor operations. Even much weaker solutions are not infrequently used.

Briefly, the technique of injection is as follows: After thorough aseptic preparation throughout, insert obliquely the tip of a hypodermic needle at the point commanding the field of operation, unless hypersensitive, into, but not entirely through, the skin. Inject half a drop or so of the fluid and withdraw the needle; make an incision through the skin for half an inch, and longer if pain be not caused; repeat the injection into the skin at either angle of the wound and extend the incision the desired length; apply traction to the benumbed borders only and draw them apart; continue the dissection, repeating the injections as needed, until the operation is completed. The amount of the drug employed, and the rapidity of its introduction, are matters that must be regulated largely by the judgment of the surgeon. It is better to introduce the needle at a distance from a hypersensitive point rather than into it, unless the sensation has been deadened already by cold.

Remarks.—When thus employed, the danger of use increases correspondingly with the amount injected. Care should be taken to avoid its introduction into vessels and nerves, also that the patient maintain a reclining posture until the effects shall have subsided; especially if the amount injected be

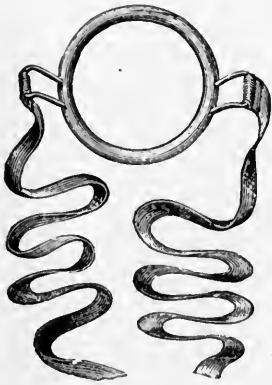

FIG. 23.—Isolation ring.

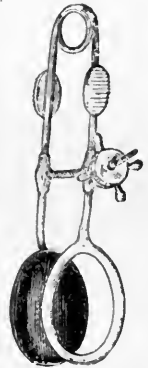


FIG. 24.—Isolation forceps.

comparatively large or the patient be, for any reason, unusually susceptible to its influence. Unfavorable outcomes of various degrees seem more often

to happen in cases when the stronger solutions have been applied to mucous membranes. For this reason a combination of ethyl chloride and a medium strength solution of cocain may be employed to cause surface anæsthesia. The expedients devised for limiting the action of this drug are ingenious and effective. Elastic bandages of proper width, elastic rings of suitable size to constrict an extremity, metallic rubber-covered rings (Fig. 23), and isolation forceps (Fig. 24) to constrict limited areas, are employed. Figs. 25 and 26 illustrate the preceding method.

Regional Paraneural Infiltration Anæsthesia.—In this procedure the constricting agent is placed about the digit or other portion of an extremity and the needle is introduced at a short distance below the constricted point and the tissues about the nerves are infiltrated with the fluid by means of superficial or deep injections, according to the depth of the nerves from the surface of the part thus treated. A suitable degree of anæsthesia is secured in about ten minutes for operative purposes. The amount and strength of the solution injected should regulate the length of time the constriction is maintained. If weak the pressure may be removed at once. *Kohlhardt* determined that in animals a toxic dose caused a fatal effect when liberated within fifteen minutes; but if restrained from thirty to sixty minutes, the toxic symptoms diminished correspondingly, all subjects recovering, and, when the constriction was maintained for an hour or more, no toxic effects followed the removal of the constricting agent.

Intraneural Infiltration Anæsthesia.—After suitable tissue infiltration the nerve is exposed and injected with a one-per-cent solution, which is soon followed by anæsthesia of the areas supplied by the nerve thus treated. This method of anæsthesia not only prevents the pain incident to operations, but also lessens operation shock by blocking the afferent and efferent impulses of the nerve in question (*Crile*). One-half-of-one-per-cent solutions are employed, and even half of these strengths may be effective if combined with a like amount of a physiological saline solution. The effect occurs in about five minutes, and lasts three or four times as long.

Infiltration Anæsthesia (Schleich).—Infiltration anæsthesia consists in the hypodermic introduction into the tissue of weak solutions of different combinations of cocain, morphin and common salt.

No. 1 Solution, Strong.

Cocain muriate	gr. iij
Morphin muriate	gr. $\frac{3}{4}$
Soda chloride	gr. iij
Distilled sterilized water.....	$\bar{\text{v}}\text{ij}\frac{3}{4}$

No. 2 Solution, Normal.

Cocain muriate	gr. jss.
Morphin muriate	gr. $\frac{3}{4}$
Soda chloride	gr. iij
Distilled sterilized water.....	$\bar{\text{v}}\text{ij}\frac{3}{4}$

No. 3 Solution, Weak.

Cocain muriate	gr. $\frac{1}{2}$
Morphin muriate	gr. $\frac{3}{4}$
Soda chloride	gr. iij
Distilled sterilized water.	\mathfrak{z} ij $\frac{1}{2}$

Solution No. 1 is employed in the most painful operations, and as many as six and a half drachms can be used during the procedure.

Solution No. 2 is employed in the less painful ones, and three ounces and a half can be used of this.

Solution No. 3 is injected into the deeper and less sensitive tissues, and employed in extended operations. Of this a pint can be used at a sitting.

To each of these solutions may be added, for obvious reasons, two drops of carbolic acid. In incisions limited to the skin sterile saline solution answers the purpose quite well. In instances of limited infiltration a hypodermic syringe can be used (Fig. 29). In more extended uses of the fluid larger syringes of similar construction or those especially designed for the purpose may be utilized. Of the special kind, the one devised by Matas

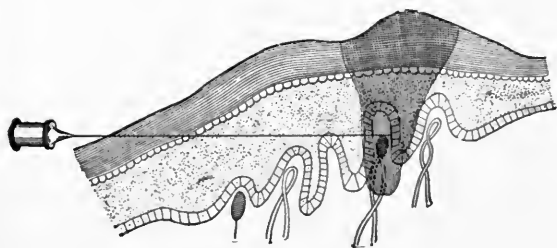


FIG. 25.—Infiltration of deep layer of skin.

(Fig. 27) is of great practical utility. The receptacle is filled through the bottom, a glass gauge at the side indicates the amount of fluid introduced. Air is injected into the receptacle passing *en route* through a small cylinder filled with absorbent cotton (Fig. 28). This and similar infiltration devices enable the operator to promptly and continuously introduce the fluid with a limited number of punctures of the tissue for the purpose.

The Method of Introduction.—After thorough asepsis introduce the needle obliquely into the deep layer of the skin (Fig. 27); inject sufficient fluid to cause a large wheal; repeat the injection as often as needed, introducing the needle at the advancing border of each preceding wheal, so as to avoid the sticking pain of the initial puncture: incise the integument along the line of the infiltrated area, infiltrating the deeper tissues in turn before division; infiltrate independently large nerves in the line of the incision before their division; the small ones are commonly made insensitive by the tissue infiltration; infiltrate the walls



FIG. 26.
Infiltration
anæsthesia.

of arteries and veins before ligature to lessen pain of tying; avoid tearing and stretching of tissues during dissection, carefully cutting them instead; avoid undue infiltration, as it blurs and obscures the field of endeavor; obviate the danger of necrosis of tissues, of infection, and suppuration by careful dissection and the use of sterile agents; re-infiltrate the point of needle puncture when pain attends closure of the wound by sewing.

The General Remarks.—The performance of major operations by this method can be advised only when the greater security of the patient demands it, usually in instances of great exhaustion. The preliminary injection of a small dose of mor-

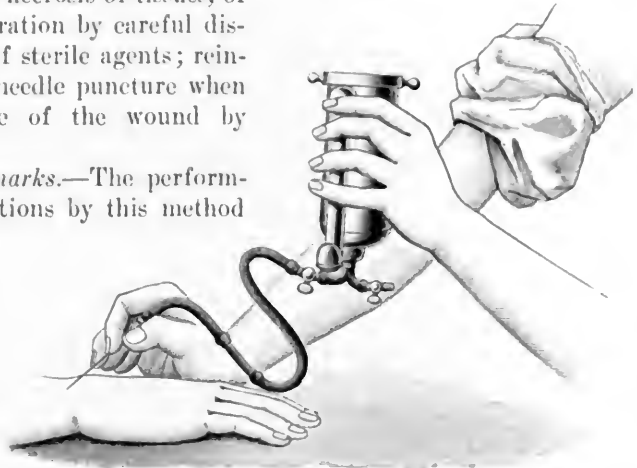


FIG. 27.—Matas infiltration anaesthesia apparatus.

phin at proposed seat of infiltration often adds to the success of the method. Dilute solutions of cocain should always be employed in prolonged operations. Familiarity with the symptoms of cocain poisoning and the means of relief ought to be fully understood and at hand. During the operation an assistant should watch the pulse and respiration of the patient, direct the mind from the operative sensations, and otherwise sustain the courage throughout. It is better to depend entirely on a weak solution of cocain than to lessen the effects of the stronger by combining them with other

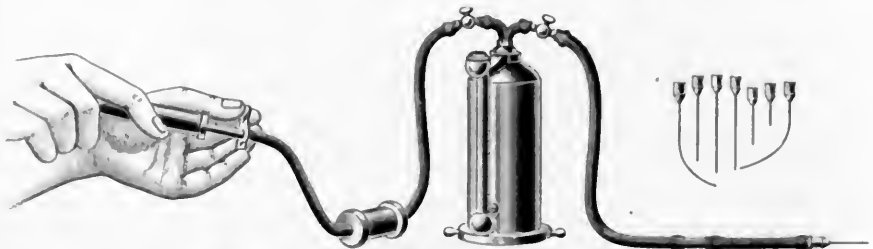

FIG. 28.—Matas apparatus, introducing the air.

drugs of less potent nature. Local anaesthesia is often supplemented at intervals with general chloroform narcosis, i. e., "morphin-cocain-chloroform anaesthesia" of Schleich and Cushing. *Gonka* combines the electric current with a four-per-cent solution of cocain, applied by means of gauze to the skin, thus obtaining an anaesthesia of five minutes' duration, sufficient to permit removal of large skin grafts. *Tropococain* is milder than cocain, less frequently followed by ill effects, and especially commended by Schwartz

for spinal anaesthesia. *Schleich's* solution No. 2 is most commonly employed for infiltration purposes. In instances of extended use of large amounts of the fluid the morphin may be inserted at first, or later in the course of the dissection to avoid any unpleasant effects that may come from




FIG. 29.—Pravaz syringe for spinal anaesthesia.

it. This fluid may be supplemented in the deeper tissues with advantage by the use of the sterile salt solution. A drop of carbolic acid applied at the seat of puncture renders penetration painless. A solution of cocain raised quite to the boiling point two or three times does not materially affect its anaesthetic properties.

Spinal Anaesthesia.—To Corning belongs the credit of first using the spinal injection of cocain to cause anaesthesia. Spinal anaesthesia may be employed when local anaesthesia is impracticable and general anaesthesia is contra-indicated in operations of magnitude. A Pravaz syringe with long needles of reliable strength or apparatus especially devised for the purpose may be employed (Figs. 29, 30). The cocain solution should certainly be sterile.* Sterilization may be attained by means of the ordinary steam sterilizer (fractional method), or after the manner of Matas, who dissolves in a hundred minims of hot sterilized water five tablets, each containing one-fifth of a grain of cocain hydrochlorat, one-fortieth of a grain of morphin hydrochlorat, and one-fifth of a grain of sodium chlorid. Twenty minims of this solution equals the strength of a single tablet. After reesterilization by the fractional method twenty-two minims are injected, thus allowing two minims for waste and twenty




FIG. 30.—Tuffier's spinal syringe for spinal anaesthesia.

* W. C. Reilly, N. Y. Med. Record, vol. lx, 1901, page 213.

minims for medication. The fluid should be at about the temperature of 100° F. when introduced.

The Operation of Injection (Tuffier).—Seat the patient on a table with the back toward the operator, the hands resting on the thighs to support the trunk; prepare the lumbar region with antiseptic care, make the spine as straight as possible by holding the trunk nearly upright; identify the highest point of the iliac crests posteriorly, and connect them with a horizontal line (Figs. 31, 32); identify the tip of the fourth lumbar spine at the point it is crossed by this line; introduce the needle at point just below the outer side of the place of contact of the line with the spine, passing it in a slightly upward direction; arrest the progress of the needle at the first appearance of cerebro-spinal fluid, allowing as little as possible to escape; exclude air from the syringe, connect it with the needle, and *slowly* introduce

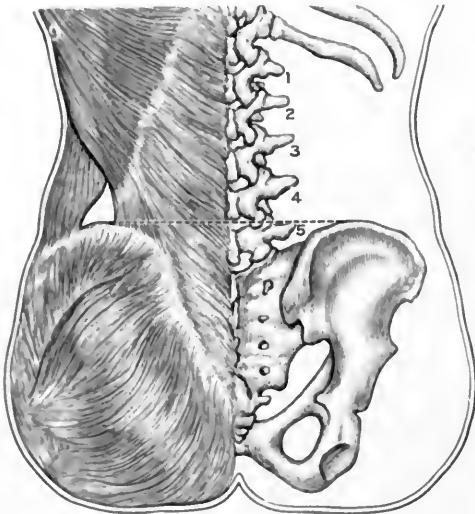


FIG. 31.—The anatomy relating to the introduction of the needle.

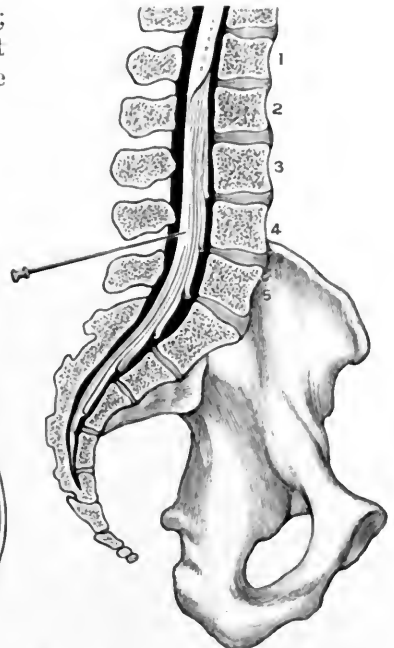


FIG. 32.—The needle introduced.

the solution. Within three minutes, or sooner, analgesia begins, usually at the feet, and extends upward to the costal arch, affecting the abdominal viscera, sometimes going higher, even to the scalp. The effect lasts from twelve minutes to three hours and longer, the average being from half an hour to an hour and a half.

The Precautions.—Spinal anaesthesia should not be employed except for the best of reasons, as it can not safely be regarded at the present time, as a substitute for the older methods of practice. Thorough asepsis of all agents concerned in the act should be assured. The usual dose is fifteen minims of a two-per-cent solution. Not more than one third of a grain of cocain should be administered at one time. Familiarity with the symp-

toms of poisoning, and the knowledge and availability of the use of the remedial agents are matters of great importance. Introduce the needle cautiously to avoid the bony structure, the breaking or impairing of it, and of injury to the intraspinal nerves. Inject the fluid slowly, using quite a minute for the purpose. Inject the solution only after escape through the needle of cerebro-spinal fluid, as this alone assures that its extremity is suitably advanced. Plugging of the needle by fat during its introduction is liable to happen, causing uncertainty and confusion in the practice. For this reason an estimate of the requisite distance of introduction of the needle should be made before trial, so that plugging can be quickly detected, and the needle partly or completely withdrawn, and the obstacle dislodged by a fine wire. Carefully note that no bony deformity be present at the established seat of puncture that can interfere with the act. Needles especially devised to prevent plugging are commended.

The Comments.—Dr. A. W. Morton, whose large experience in spinal anæsthesia commands attention, places sterile tubes containing crystals of cocain hydrochlorat for fifteen minutes in a dry atmosphere at a temperature of 300° F. The dose employed varies from 0.3 to 0.5 grain. The requisite sized dose is placed into a sterile syringe with a glass barrel and the piston introduced. The patient lying on the side, with the back curved, the needle is entered between the spinous processes of the third and fourth lumbar vertebræ, passed upward and forward until cerebro-spinal fluid escapes from it. The barrel of the syringe is then connected with the needle, the piston withdrawn until the glass chamber is half filled with cerebro-spinal fluid. As soon as the cocain is dissolved the fluid is slowly injected, the needle withdrawn, and the puncture sealed with collodion. By this method Morton has practiced spinal anæsthesia 673 times without a failure; * 60 of which were produced by puncture above the diaphragm. *Morton* advises that the concave part of the extremity of the needle be dull, to avoid the cutting that often plugs the lumen with tissue. *Patterson* estimates the death rate from spinal cocainization at about 3 in 1,000.

Eucaïn Hydrochlorat.—Although this drug does not equal cocain in anæsthetic effect, it no doubt is the most potent substitute. Eucaïn is less toxic than cocain, and by many is regarded as superior and safer, especially when employed in the urethra, bladder, and upper air passages, and, too, in connection with mucous membranes generally. Solutions of one to four-per-cent may be employed independently or to supplement cocain when the latter acts unfavorably in the course of an operation. Eucaïn sometimes causes sloughing, especially of cutaneous and fatty tissues. Eucaïn is not impaired by boiling, hence can be thoroughly sterilized. Our experience with eucaïn has been so infrequent as not to afford opportunity to practically judge of the comparative merits of the drugs.

Beta Eucaïn.—Beta eucaïn is thought by some to be superior to eucaïn because, while possessing all of the virtues of the latter, it is less often followed by pain and smarting on the subsidence of anæsthesia. It is

* Journal of the American Medical Association, Nov. 8, 1902.

administered by direct injection and by the infiltration plan. In the former five to seven minims of a two-per-cent solution are employed, in the latter five or six ounces of a solution of 1 to 1,000 of the physiological saline solution can be used during an operation.* The solution should be warm when introduced into the tissues. In about five minutes the local effect will be ample for the purpose intended, and after twenty minutes a second medication will probably be needed if further operative action be required. As with cocain so with this drug, major abdominal and elsewhere operations have been performed with satisfactory outcome both in ordinary and on necessitous occasions. We are disposed to think that it is better that the surgeon should aim to consult the comfort of the patient when practicable, rather than to test unusual means of accomplishing great results in an astonishing manner.

THE INSTRUMENTS NECESSARY FOR THE PERFORMANCE OF OPERATIONS.

The instruments necessary for the performance of an operation must be regulated by the magnitude and nature of the procedure. They can, however, for the sake of brevity, be divided into those in general use and those for special purposes.

The Selection of Instruments.—The selection of proper instruments for surgical procedures requires especially the consideration of their utility, construction, and quality. The pattern of the instrument should conform to the accepted standard of requirement. Although good surgery can be done with clumsy and old-fashioned instruments, yet the more delicately and simply formed the instruments are the more satisfactory will be the labor and the better the technique of the procedure. A multiplicity of instruments devised for similar purposes, or to meet fancied or shadowy indications, or to exploit the name of the inventor, is to be regretted.

The construction and finish of instruments should be carefully noted, and, when practicable, they should be made in a plain and substantial manner. The handles and shanks should be smooth and closely adjusted, or the entire instrument made of metal and highly polished. Inequalities, and mechanisms that can lodge impurities, should not be needlessly tolerated. All lines of embellishment and the stamp of the manufacturer should be eliminated.

The standard of quality of cutting instruments can be estimated by the following means:

1. By drawing the cutting edge slowly across the border of the nail, to detect the presence of nicks.
2. By drawing the edge in the same manner, with the blade tilted, across the flat of the nail, to determine the presence of a soft or wiry edge.
3. By passing the point of the instrument through tightly stretched kid

* Arthur E. Barker, M. D., *Lancet*, January 20, 1900.

or gold beaters' skin; a crackling sound will be caused if the point be rough; otherwise, it will pass noiselessly through these structures.

4. By testing the edge on a hair held between the thumb and finger, as is practiced to estimate the cutting edge of a razor. The acuteness can be determined by shaving a few hairs from the back of the clinched hand of the operator or an assistant.

The variety and extent of the armamentarium of a surgeon should depend on the present and prospective demands for his services. Those who can avail themselves of easy access to the business places of instrument makers and dealers in surgical supplies are seldom at a loss to secure the necessary instrument at once; but those who are distant from the base of supplies must necessarily possess the instruments which their professional environment suggests, many of which may rarely, if ever, be called into use.

The ingenious and comprehensive outfits now offered for sale in the form of pocket cases and special and general operating cases and bags, and emergency outfits, enable one to provide reasonably for all probable requirements. The exercise of good judgment and reasonable forethought on the part of surgeons will cause them to utilize many instruments for divers purposes, and thus lessen the expense and also limit the production of instruments to within the bounds of reason and expediency.

The instruments in general use include scalpels and bistouries of various forms (Fig. 33), thumb forceps, grooved directors, and scissors. Those for special purposes are employed in the performance of operations which in most instances caused their creation; they will be considered in connection with the operations to which they are particularly adapted.

The Methods of Holding the Scalpel. — Three positions are commonly recommended, each of which is subdivided into two. The positions resemble the manner of holding respectively, the ordinary table knife, the pen, and the violin bow.




FIG. 33.—Scalpels and bistouries.

Figs. 34 and 35 represent the subdivisions of the first position; they indicate that force and firmness are required. Figs. 36 and 37 represent the subdivisions of the second position; these are taken when quick, delicate,

and precise movements are made. Figs. 38 and 39 are the subdivisions of the third position, and are employed when caution is used in conjunction with delicacy in cutting.

The preceding positions are more essential to graceful than to successful operative methods.

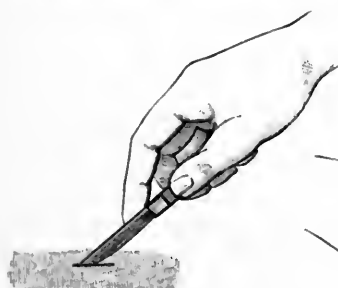

FIG. 34.

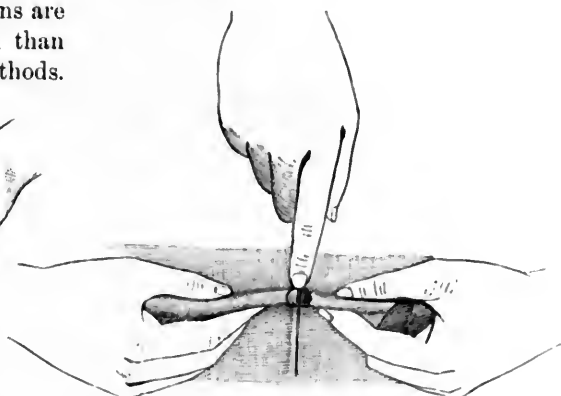


FIG. 35.

Holding knife, first position.

The Thumb Forceps (Fig. 40).—The thumb forceps is used in connection with the scalpel or scissors. It is employed to pick up portions of tissues, such as the fascia, which are to be removed or incised near to the point grasped, for




FIG. 36.

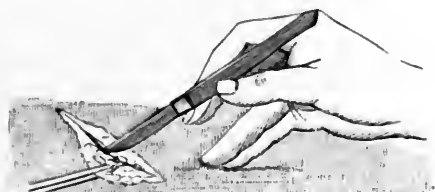


FIG. 37.

Holding knife, second position.

various reasons. The scalpel, or bistoury, should be held at nearly a right angle to the forceps when the incision is made, especially when important structures lie immediately beneath the line of incision. The tissue may be

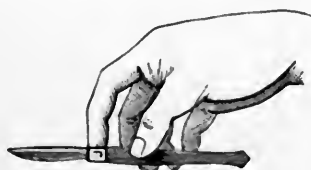


FIG. 38.



FIG. 39.

Holding knife, third position.

grasped at each side of the median line of the wound with forceps, and the division be made directly downward upon a vessel or other important struc-

ture (Fig. 41). This plan, when supplemented with gentle separation of the tissues with retractors, is technically superior in all respects to the one in which a grooved director is employed. The spring of the forceps should be quick and not too strong, and the bite wide, to secure ease and certainty of execution and limit the bruising of the tissues grasped to a minimum. Unnecessary pinching of tissues by forceps must be avoided, as repair of the wound is thereby hindered, and non-union may result. The injury of the tissues from forc-



FIG. 40.—Thumb forceps.

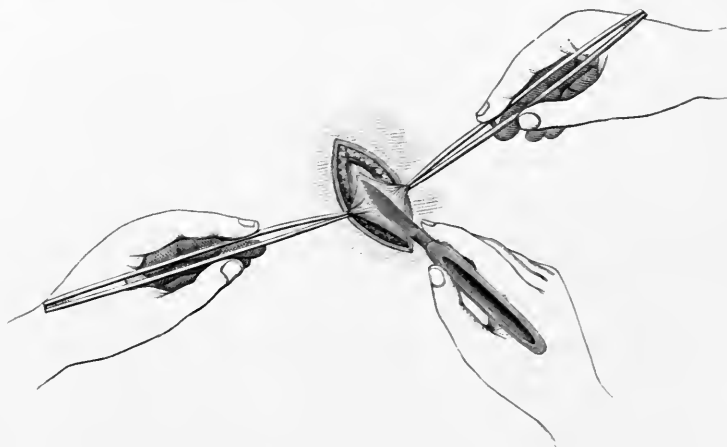


FIG. 41.—Cutting between forceps.

pressure can be lessened, and in fact almost obviated, by the use of forceps with the claw-shaped bite (Fig. 42). However, the narrow bite of this implement exposes the tissues to greater danger of laceration, unless the degree of force exercised be proportionately regulated.




FIG. 42.—Claw-bite forceps.

The Grooved Director (Fig. 43).—The grooved director is employed to separate and raise those tissues which are to be divided with caution. The director should be five or six inches in length, depending upon the extent of the incision and the depth of the wound into which it is to be inserted; it should be flexible, with a broad extremity for grasping, and a pocket at the end of the groove to arrest the point of the knife or scissors. The end of the instrument should not be pushed beyond the extremities of the external

incision, because of the danger of making pockets there in the soft parts, which will provoke inflammation and impede drainage. The tissues raised upon the director should be divided within these extremities. Care should



FIG. 43.—Grooved director.

be taken when the director is passed between a serous membrane and its superimposed fascia that the membrane does not fold over the advancing extremity, thereby causing it to be prematurely punctured or divided by the knife or scissors. Many operators employ the director but rarely. On the contrary, not a few use it as a blunt dissector, to tear asunder tissues during operative procedures. While it is no doubt true that this instrument is employed unwisely on frequent occasions, still the comfort and security that its proper use affords to inexperienced, timid, or even discreet operators justifies its retention in a surgical outfit.

The Scissors.—The scissors is sometimes used as a substitute for the scalpel for deep and cautious cutting in a limited space. Less oozing of blood follows its use than that of the scalpel, on account of the crushing



FIG. 44.
Straight scissors.




FIG. 45.
Curved on the side.

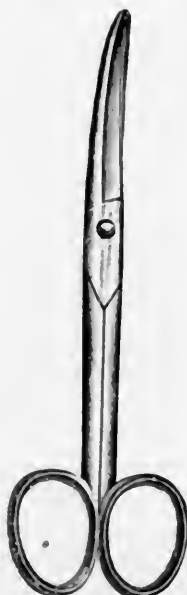


FIG. 46.
On the flat.




FIG. 47.
On the flat.

nature of its cutting force. Curved on the flat blunt-pointed scissors (Fig. 46) can be handily utilized as dry dissectors, to separate and push aside tissues that impede the progress of an operation or lie in contact with morbid

growths. Scissors should be so constructed as to readily meet the purposes of their use; they may be straight (Fig. 44), curved on the side (Fig. 45) or on the flat (Fig. 46), with long or short handles, long or short blades, sharp (Fig. 47) or dull points, etc. Sharp-pointed scissors can be used to make the channels in tissues in which drainage tubes are placed. If the sharp points of the scissors, while closed, be carried through the tissues guided by the fingers within the wound, to the external surface, and their withdrawal, while opened, be followed closely by suitable forceps or forcipressure, the drainage tube can be caught and pulled into position with a maximum accuracy of adjustment and a minimum degree of danger to the intervening structures. A graceful and delicate method of holding the scissors (Fig. 48), adds quite as much to the style of the operator as do similar methods of holding the scalpel.

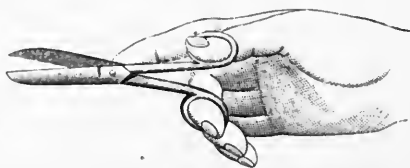


FIG. 48.—A manner of holding scissors.

Blunt Dissection.—Blunt or dry dissection is practiced by a blunt implement (see scissors) devised for the purpose, and employed to supplement the use of cutting instruments in the approach and removal of morbid growths

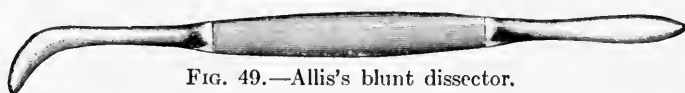

FIG. 49.—Allis's blunt dissector.

associated with important structures (Fig. 49). These agents separate instead of dividing the tissues, thereby permitting cautious advance without wounding the important vessels and nerves. Their use is especially indicated in the removal of tumors from the deep structures of the neck.

Incisions.—The varieties of incisions are numerous, and are classed according to the direction in which they are made—as the straight, curved, cross-shaped, etc. The choice of incision is determined largely by the underlying anatomy, the contour of the growth to be removed, the establishment of good drainage, the avoidance of disfigurement of the patient, and the cleavage of the skin. Incisions made in the lines of cleavage of the skin gape but little, unite promptly, and with a minimum degree of scarring. Incisions for drainage purposes should be made at right angles with the lines of cleavage, if the retractive tendency of the skin alone is relied upon to maintain the patency of the opening. If drainage agents are employed, the direction of the incision is less important.

The length of an incision is controlled by the special requirements of an operation. It should be long enough to permit a good view of the parts involved, and an expeditious and proper treatment of the abnormal and the healthy tissues. An incision can be lengthened from time to time as the necessities require. There is greater danger of making an incision too short than too long, and of the two the former is the greater evil, since a long, clean-cut incision will drain better and heal quicker than a short deep one bounded by tissues that have been bruised and torn by the efforts directed to

the accomplishment of a definite purpose within a too limited space. The fear of disfigurement from an incision ought not to invite disaster by an unwise limitation of its extent.

Before the incision is formed, the integument to be divided should be made tense at either side by opposing forces gently and equably employed (Fig. 169). If this precaution be not observed, the relaxation of the released tissues after division will cause the incision to fall outside of the proper line of action in the deeper structures, and impaired view, unwise manipulation of the tissues, bad drainage, and unnecessary scarring will follow, unless another and a suitable division be made. This error often happens when an assistant incautiously endeavors to aid the operator in the movement.

Primary incisions should be clean-cut from end to end, and the tissues beneath should be as cleanly cut or carefully separated as circumstances will permit. The tearing apart of tissues with the finger, handle of the scalpel, or other device, must be carefully avoided, as unwise and unguarded methods of this kind foster delay in repair, imperfect drainage, and therefore unsatisfactory results.

Deep dissections should be made in a more careful manner than the superficial, and as near to the immediate environment of the abnormal condition as good judgment indicates. Both superficial and deep incisions and separations of tissues should be made as nearly as possible in the line of the course of the vessels, nerves, and the muscular fibers that fall in their way. The uppermost dissections should be made first, so that the bleeding caused by them will not obscure the subsequent steps of the operation.

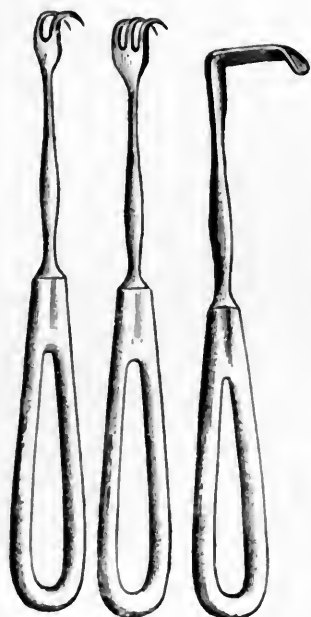


FIG. 50.—Retractors.

During the course of an operation carried on through an incision of the soft parts the borders of the wound should be held asunder so as to permit of a good view and proper manipulation of the deeper structures. For this purpose variously formed retractors have been devised (Fig. 50)—those with sharp hooks, blunt hooks, etc. (Fig. 175). Operations of a complicated or special nature require special retractors, and these will be illustrated in their proper places. If the retractors be cumbersome and in the way, long, strong silk traction loops can be passed deeply through the center of each side of the wound, tied or not, caught with forceps, and drawn apart by the assistant or by a suitable weight attached to the ends (Fig. 51). This idea is especially serviceable in limited spaces, as in perineal, axillary, and tracheal incisions.

Antiseptic and Aseptic Methods.—In the brief study of the remaining essential requirements the expressions antiseptic and aseptic frequently ap-

pear; but since each signifies a like outcome, their dissimilarity will not be stated until later on (page 94).

The Receptacles for Instruments.—The receptacles for instruments vary in shape (Fig. 52), size, and in material, according to the fancy of the de-

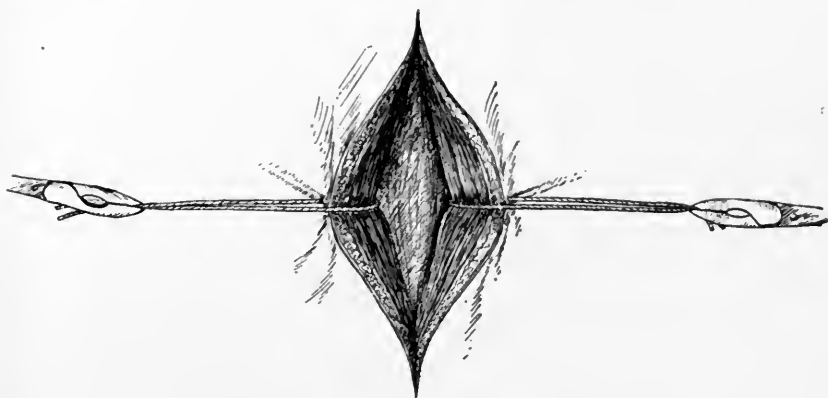

FIG. 51.—Traction loops.

signer, the size of the instruments, and the nature of the antiseptic fluids employed. The number, too, should conform to the convenience of the operator and the demands of the occasion. Under all circumstances the receptacles should be thoroughly cleansed by scrubbing and boiling before the antiseptic fluids are put into them.

They should be tight, and of sufficient depth to permit of complete immersion of the instruments in the purifying fluid. Wooden receptacles are

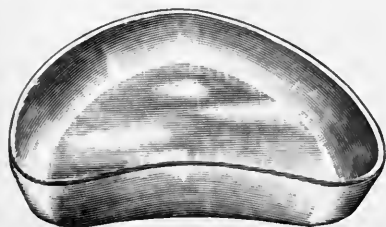

FIG. 52.—Kidney-shaped receptacle.



FIG. 53.—Gutta-percha receptacle.




FIG. 54.—Glass receptacle.



FIG. 55.—Author's rubber receptacle, with metal frame.

not suitable for the purpose, as one can not be certain that they are in a cleanly condition. Rubber, gutta-percha (Fig. 53), *papier-maché*, porcelain, earthen-, glass- (Fig. 54), and agate-ware receptacles are cheap, common,

and serviceable. Tin receptacles, while always available, are unsuited for the use of mercurial solutions. Rubber receptacles that may be folded so as to occupy but limited space are cheap, portable, durable, and convenient. The one designed by the author (Fig. 55) can be employed with or without the metal framework belonging to it, depending on whether or not it is to be moved while in use. If the support of the framework be omitted, the receptacle can not be moved, except with great care, without the danger of slopping over. The rubber receptacle with a hollow elevated border admitting of inflation is also convenient and portable, but is liable to collect objectionable matter in the retiring angles of the sides, which may escape observation and become the source of infection.

As every instrument employed in an operation should be thoroughly sterilized before it is handled or brought in contact with the field of procedure, it is necessary to exercise great care to secure this desideratum. For this purpose the instruments should be carefully wrapped in a clean towel, and, while thus surrounded, placed in a suitable receptacle containing pure water or the soda solution (page 62) and boiled for not less than half an hour; then, while yet surrounded by the towel, they are promptly immersed in the antiseptic fluid, unwrapped, and placed in suitable and separate receptacles already supplied with antiseptic fluid, in which they remain until required for use. Before boiling, the blades should be unlocked to insure asepsis, and the cutting edges wrapped in cotton to prevent dulling. Solutions of carbolic acid, of beta-naphthol, or of Thiersch's fluid are suitable for immersion purposes, as they cause no deleterious effects on the cutting edge. While different sterilizers are designated in which to boil instruments, it is often more a matter of convenience than necessity in private practice that one is employed, since in any household a suitable utensil can be quite easily procured and cleansed for this purpose.

The different kinds of *portable* (page 113) and of *fixed sterilizers* for office and hospital work, with a detailed statement of their management, can be purchased at the depots for surgical supplies. A tinsmith can make a serviceable one by fitting within a copper receptacle of suitable size and with a movable top, a perforated tin tray upon which the instruments are placed and immersed within the fluid in the copper vessel and boiled.

If the number of assistants be limited, or if they be inexperienced or careless in shifting the instruments to and from the fluid during the operation, the receptacles can be so placed as to allow the operator to take charge of this duty himself. In order that this demand can be properly and promptly met, the author has devised a rotary framework on which are firmly placed several receptacles for instruments (Fig. 56), which are brought into use by turning the platform on which the receptacles are placed, as occasion requires. The fluids in these



FIG. 56.—Author's rotary receptacle.

that this demand can be properly and promptly met, the author has devised a rotary framework on which are firmly placed several receptacles for instruments (Fig. 56), which are brought into use by turning the platform on which the receptacles are placed, as occasion requires. The fluids in these

receptacles can be readily discharged when necessary through a rubber tube adjusted to a spigot in the corner of each. This apparatus is too cumbersome for use in other than office or hospital work.

The Operating Table.—The securing of light, freedom of action, and cleanliness in operations require that the patient be placed on some form of operating table during these procedures. If the operation be trivial, it is better not to excite the apprehensions of the patient and friends by unnecessary preparations, but, instead, to utilize for the purpose the ordinary couch or lounge that is at hand in most instances. However, the operations that require the free use of anæsthesia and fluids, careful observa-



FIG. 57.—Extemporized operating table.

tion, and are attended with much expenditure of time and method, require that special provisions be made for the purpose of properly supporting the patient.

Operating tables may be of established form, or contrived at the time of the demand by the utilization of the ordinary tables and stands that are a part of the belongings of every household (Fig. 57). These articles, when placed in proper position and covered with old blankets and water-tight aseptic rubber sheets, answer well the purposes, unless the patient be violent; then the struggles will frequently disarrange the outfit. Each detail of the preparation of an operating table should be adjusted carefully, in order to obviate the unnecessary soiling or disfigurement of the furnishings of the premises. The caretakers of household matters have a keen appreciation of any efforts that may be directed to the prevention of needless soiling or disfigurement of household articles on these occasions, not so much on account of their intrinsic worth as the unpleasantness of the recollections suggested later by their presence.

The width of the table should permit the operator and the assistants to stand close to the patient, and it should be so tilted or constructed as to cause all fluids connected with the operation to be promptly discharged into suitable receptacles placed at the side or foot of the table. The rubber sheeting placed beneath the patient can be folded and raised at the sides by thin pieces of wood or sand bags so as to limit the spread of fluids to the part of the patient immediately beneath the field of operation. Pieces of rubber tubing can be placed transversely immediately under the



FIG. 58.—Kelly's large surgical cushion.



FIG. 59.—Kelly's small surgical cushion.



FIG. 60.—The Boston surgical cushion.

patient above and below the seat of operation for the same purpose. This aim should be earnestly sought, as unnecessary wetting deepens shock, exposes the patient to taking cold, and also increases the task of properly cleansing and wiping the surfaces after the operation. The rubber surgical cushions now in common use are both convenient and serviceable in this regard (Figs. 58, 59, 60).

The operating table of comprehensive pattern ought to possess the following characteristics:

1. It should permit the elevating and lowering of the head of the patient, so as to secure for the operator and the patient every advantage arising from the influences of the force of gravity. The surgeon is aided in many operations on the abdominal contents, and the patient is sometimes benefited by this maneuver. But the good points of this device are often overdone, since they may be unwisely employed or unnecessarily prolonged to the disadvantage of the patient and the discredit of the method. The operating table devised by Cleveland is made entirely of wrought iron, and is so constructed as to permit the placing of the patient in almost any re-

quired positions (Figs. 61, 62). Fowler's operating table can be promptly adjusted to meet surgical need, and is provided also with a platform of

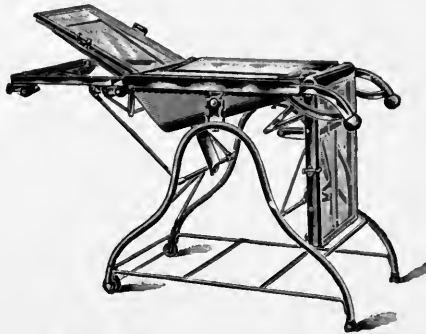

FIG. 61.—Cleveland's operating table.

tubes containing water of proper temperature through which the patient is supplied with warmth (Figs. 63, 64, 65). *Crile's* hot-water mattress may be used on any table with satisfaction.

2. It should cause the prompt discharge of all fluids away from the patient. Inasmuch as all surgical paraphernalia are being constantly modi-

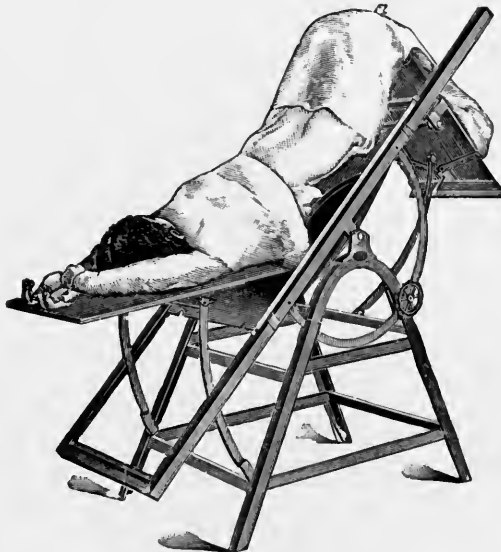

FIG. 62.—Cleveland's table, Trendelenburg position.

fied to conform to the special and newly born demands of surgical advance, one contemplating the purchase of a special article of this kind should confer with those in active touch with improved technique, rather than rely entirely on the belated representations of surgical tomes. No surgeon should so exaggerate the demands of an occasion as to require the procurement of a

special operating table, when the exercise of reasonable forethought and ingenuity on his part will enable him to meet the necessary requirements by the utilization of the resources near at hand.




FIG. 63.—Fowler's operating table. First position.

Portable Operating Tables.—The table of Pryor (Figs. 67, 68), and that of Edebohls (Figs. 69, 70), are notable examples of numerous patterns of this kind of support.

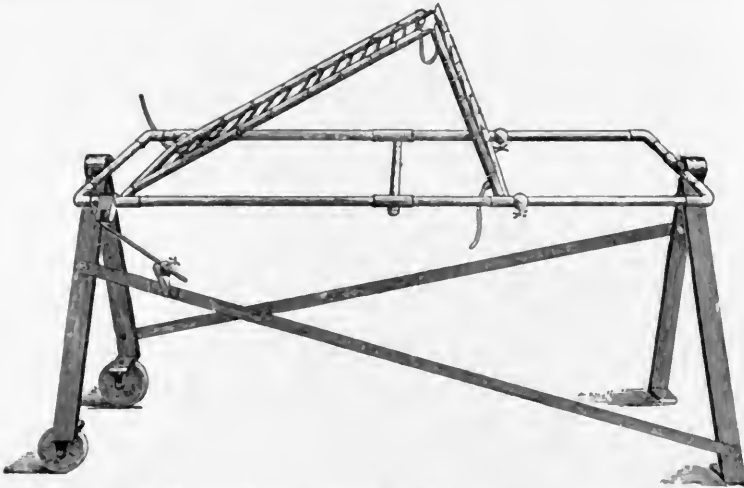


FIG. 64.—Fowler's operating table. Second position.

A portable inclined plane for pelvic elevation is very serviceable, and can be adjusted by fixing-clamps to any table (Fig. 71).

An improvised inclined plane for pelvic elevation can be made with an ordinary chair. The top of the back and the front of the seat of the chair should rest on the table, with the legs in the air. The patient's extremities are bound to the front rungs and his back laid upon the back of the chair. The chair may be fastened to the table on which it rests.

The Empty Vessels.—An ample supply of aseptic empty vessels, consisting of pails, basins, pitchers, etc., should always be provided, whether the operation be performed in a hospital or elsewhere. The careful and

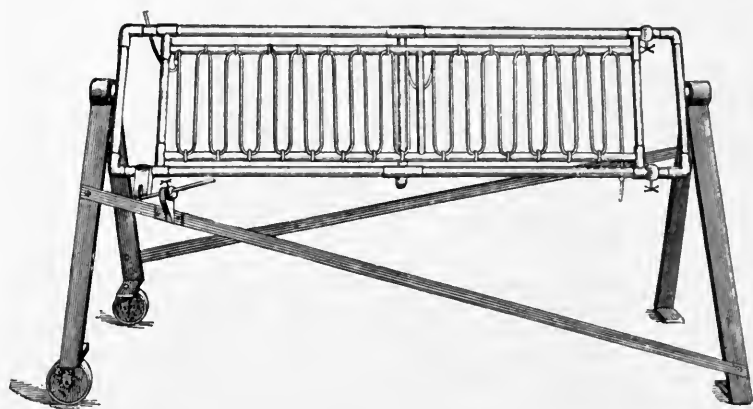


FIG. 65.—Fowler's operating table. Third position.

orderly disposal of soiled articles and waste of all kinds is an earnest of thorough work in other respects. Soiled textile fabrics and sponges should be put at once where they can not become the sources of present or prospective infection. Pails for cold water; pitchers for cold and hot water, and antiseptic solutions; basins for clean and soiled sponges and wipers, and to contain antiseptic fluids for every established purpose in an operation, should be freely provided. The receptacles for antiseptic fluids should be legibly tagged, stating the nature and strength of their contents, to avoid confusion and mistakes.

A deep, oblong basin (Fig. 72) containing an antiseptic or aseptic solution, in which the surgeon can lave the forearms and hands for a while (after scrubbing and rinsing them) before commencing the operation, and into which he can frequently plunge them during the course of the performance, should be provided and placed within a convenient distance.

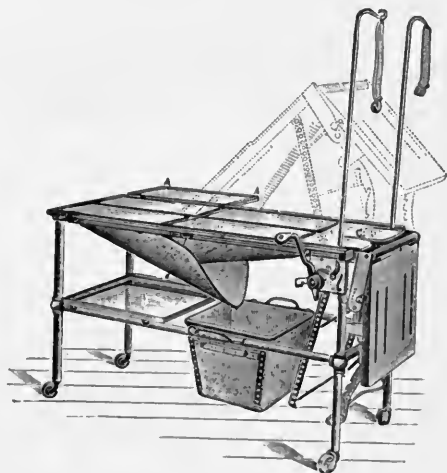


FIG. 66.—Markoe's operating table.

The Clean Aseptic Towels and Sheets.—An abundance of clean aseptic towels and sheets is required not only for the purpose of securing general cleanliness of the patient's immediate surroundings, but also for properly protecting and isolating the

field of operation. When used for the latter purpose they should be made aseptic by sterilization with moist heat, or antiseptic by long saturation with effective fluids of this nature.

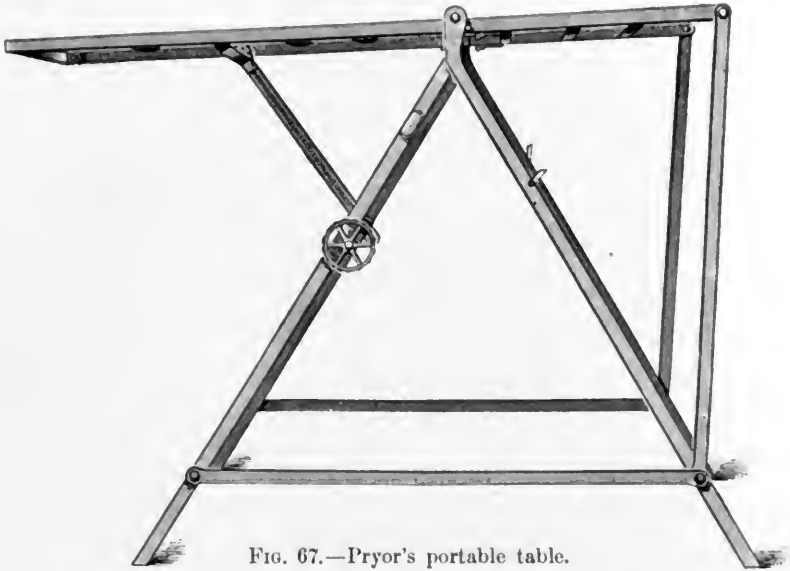


FIG. 67.—Pryor's portable table.

During an operation the surgeon frequently needs to wipe his hands or the immediate surrounding surface of the seat of the procedure; for this purpose wet antiseptic towels are the better, as dry ones do not so readily clean the surface, and they are applied with less ease and are more liable to convey infection. A dozen each of dry steam sterilized, and a similar




FIG. 68.—Pryor's portable table, folded.

number of wet antiseptic ones, should be provided in advance of the operation and kept in separate bundles, carefully wrapped in wet antiseptic towels or antiseptic gauze arranged for the purpose, or inclosed in sterilized receptacles and withdrawn as needed. The textile fabrics used in contact with the field of operation or with the instruments and the hands of the operator must be carefully prepared and handled, and frequently changed, otherwise they may become potent agents of wound infection.

The Aseptic and Antiseptic Solutions.—Much has been said and written regarding these agents. To the watery solutions of carbolic acid and cor-




FIG. 69.—Edebohl's portable table.



FIG. 70.
Edebohl's table, folded.

rosive sublimate have been given the greatest attention and use. The ease of their procurement and the general belief in their greater comparative

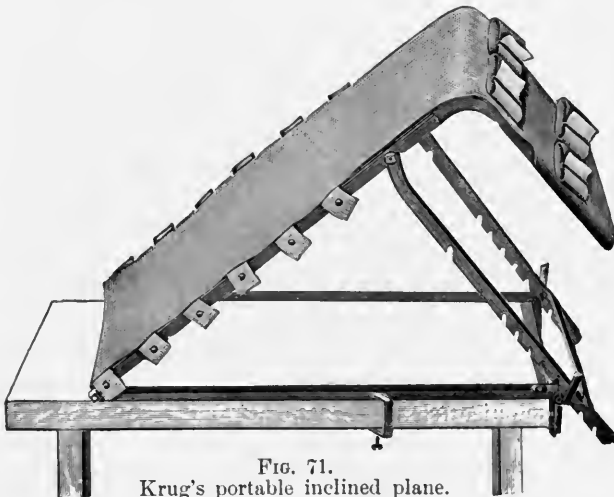


FIG. 71.
Krug's portable inclined plane.

efficiency account reasonably for the merited discrimination. Antiseptic solutions are employed by some with a degree of superficial dispatch indica-

tive of unwise confidence in their efficiency, and by others with an assiduity and faith comparable to the zeal of a fanatic.

Antiseptic fluids were once used in everything that had to do with the wound, and also to the fresh surfaces of the wound itself, at intervals, or continuously during an operation, by means of the spray, douche, and sponging. However, it soon appeared that the free use of these fluids not only hindered repair, but also was a source of discomfort to the patient and the cause of annoyance and delay to the surgeon. A little later the discovery of the facts that pus-producing germs could withstand for an hour or so without destruction the direct action of stronger solutions of corrosive sublimate than can be wisely




FIG. 72.—Laving basin.

employed in surgery, and that these germs can be wiped from the surface of wounds after thorough douching with these fluids, led to the belief that their use in this manner can be wisely omitted from the technique of fresh wound treatment.

Antiseptic solutions should be used in lieu of the aseptic by all who are obliged to handle the instruments, the undressed wound or anything coming in contact with it.

Carbolic acid is frequently employed; it is cheap, easily obtained, and in a strong solution is very efficient. Two solutions are commonly used, a weak and a strong solution. The latter is made as follows:

Carbolic-acid crystals.....	1 part.
Alcohol.....	1 “
Water.....	20 parts.

This solution may be employed for washing the surfaces before operation, for immersion of the instruments, and for the spray when desired. The cleansing of the hands with this solution should be avoided, as it constricts the integument, benumbs the sensibility, and is often followed by exfoliation of the cuticle.

The weaker solution is employed for the general purposes of cleanliness, and can be freely used in securing this end, but is altogether too weak to meet the special requirements of antiseptis. The following is the composition:

Carbolic-acid crystals.....	1 part.
Alcohol.....	1 “
Water.....	40 parts.

Carbolic acid is often combined with oleaginous substances in the proportion of one of the acid to five or ten of the substance, and although the antiseptic power of the acid is lessened, it is not entirely overcome, by such combinations. The objections to carbolic acid are its offensive odor and the liability to produce poisoning. The former objection can be tolerated, while the latter can be prevented in nearly all instances by not permitting the strong solution to become confined within the tissues.

Solutions of the chloride of zinc (1 to 15), iodine (1 to 500), sulphocarbonate of zinc (1 to 80), bichloride of mercury (1 to 2,000 to 1 to 10,000), binio-

dide of mercury (1 to 2,000), a saturated solution of boric acid, sulphurous acid, pure or diluted (1 to 2), or a saturated solution of iodoform and ether, etc., are variously employed as washes or applications to wounded surfaces.

The solutions of the bichloride of mercury (1 to 2,000 to 1 to 10,000) are deserving of especial consideration, inasmuch as they rival the carbolic-acid solutions as antiseptic agents. Like the former, they are cheap, accessible, efficient, and of little danger; unlike them, they are inoffensive, more active, less penetrating, but do not benumb the sensations of the operator. They should be freshly prepared before using, and their tendency to chemical transformation into the chloride by exposure counteracted by the addition of a small amount of common salt. The liability of mercurial poisoning from a proper use during an operation is of little practical importance. It is not advisable, however, to employ these solutions for the purpose of the daily cleansing of wounds of larger size, since thus the constitutional effects may be produced. For the purpose of cleansing large cavities they should not be used oftener than twice a week, and should be carefully drained from the wound cavity, and the patient be rigidly scrutinized to detect the first manifestation of the constitutional effects of mercury.

Beta-naphthol is used for the same purpose as the bichloride of mercury in a solution of 1 to 2,500 or 3,000, but is less active. Later, *kreolin* (in a five-per-cent emulsion) is safely used to irrigate large cavities, as it has no toxic effect.

Thiersch's Fluid.—Thiersch's fluid, composed of one grain of salicylic acid and six grains of boric acid to an ounce of water, is frequently employed for antiseptic purposes. This solution is bland, and does not produce the cathartic influence upon the tissues that is so characteristic of the strong carbolic and bichloride-of-mercury solutions. Thiersch's fluid may be used in operations on serous surfaces, and on the mucous membrane of the eye, throat, and urethra. It can be employed with safety at all times, and the use is especially indicated when idiosyncrasy or extreme youth of the patients contra-indicate the employment of the standard solutions of carbolic acid and mercury. Convenience of use is facilitated by increasing the comparative amount of the substances to conform to a pint of water. The powders thus compounded and securely inclosed can be kept constantly at hand and ready for immediate use.

Peroxide of Hydrogen.—Peroxide of hydrogen has long been recognized as a strong deoxidizing agent. It can be used for antiseptic purposes in the original strength, or diluted with water to various strengths, depending on the indications for employment. It is used at full strength in the treatment of old sinuses and abscess cavities; in solutions of twenty-five per cent it is poured or injected into open cavities, whether recent or long-established, for cleansing purposes. It is sometimes employed in abdominal surgery, especially if septic influences be present, and often in the surgery of mucous surfaces. The prompt and decided effervescence of solutions of this fluid is regarded as advantageous in dislodging and bringing to the surface the septic and diseased products that lie loosely and often unsuspectedly in

the depths of operation wounds, well-opened peritoneal interstices, and old sinuses. If free escape be not afforded forced dissemination of infecting agents may occur. Ordinary solutions are not germicidal.

This fluid is not advised in delicate operations, as the effervescent character obscures the field, and may otherwise annoy the operator.

Heat is the most valuable and available antiseptic, moist heat is more efficient than dry. Pressure increases the potency of the latter. All pathogenic bacteria are destroyed at 140° F. for ten minutes, except tubercle bacillus and anthrax spores, requiring 212° F., moist, for four minutes.

Solution of Carbonate of Soda.—The carbonate-of-soda solution is especially adapted to the purification of surgical instruments. When boiled for fifteen or twenty minutes in a ten-per-cent aqueous solution of ordinary washing soda, they are properly purified for surgical purposes. This act exercises a minimum degree of impairment of the cutting edge and lessens rusting. However, the organic parts of instruments are more or less impaired by its influence.

Boiled Water.—Boiled water is an excellent aseptic fluid, and can be employed in connection with surfaces and substances that are properly purified already. If one could be assured of immunity from infecting agents, this fluid would be an ideal one for local use, as it is bland and unirritating, and can be readily and bounteously provided wherever required. It is an excellent and almost universal menstruum for antiseptic solutions.

Saline Solution.—The saline solution is made by dissolving in a quart of filtered water sterilized at 240° F. a drachm and a half of table salt. On account of its unirritating nature, it is used chiefly at a temperature of 100° to 110° F. for the cleansing of serous surfaces. At the present time it is commonly employed in the treatment of shock, especially when due to loss of blood (page 220 *et seq.*).

Alcohol, thymol, eucalyptol, and the *essential oils*, especially of mustard, are recommended for use not infrequently on account of their antiseptic virtues.

The Sponges.—Sponges act more promptly than any other agent that can be employed for the purpose of wiping and absorbing from the surface of a wound the blood and other fluids that attend an operation. And this is especially true if the hæmorrhage be profuse, or rapid absorption of the blood and fluids be required. They are, however, often the cause of infection of a wound owing to careless handling, imperfect preparation, and subsequent care, and for these reasons their use is discarded by many.

The surgeon should guard against the former means of infection by restricting the handling of sponges to as few assistants as possible, and permitting those only to touch them who are well informed and appreciative of the importance of the trust reposed in them. The rinsing and handling of sponges by careless, uninformed, and indifferent attendants is a common source of danger that can not be overestimated. The variety known as "surgeons' sponges" are the most expensive in use. The less costly larger sponges of a proper texture can be cut into portions of suitable size, and

when thoroughly cleansed and disinfected can be employed with satisfactory results. No sponge of whatever quality should be used until it has been freed of all foreign matters and properly disinfected. It should be the practice to select and cleanse a number of sponges and keep them in a closed jar containing a strong solution of carbolic acid or other suitable disinfectant until needed. The broad, thin sponges for abdominal work should be at hand and prepared for instant use. *Aseptic gauze pads* of generous size and with tape attachments are now much more often employed in abdominal surgery than the broad sponge.

Sponges ought not to be used repeatedly. It is better evidence of careful surgery to provide fresh ones in each case than to use them a second time, even under seemingly favorable circumstances.

The Preparation of Sponges.—Various methods are advised for this purpose, the following (Schimmelbusch) is both simple and effective. The sponges are beaten, washed, and kneaded repeatedly in cold and warm water, until the dirt, shells, and other foreign matter are entirely removed; they are then pressed together, surrounded by gauze, and put into a one-per-cent aqueous solution of soda, just removed while boiling from the fire, in which they remain half an hour. Sponges should not be boiled as boiling hardens them. The soda is now washed away with boiled water, after which they are stored in a tight jar filled with a solution (1 to 2,000) of corrosive sublimate.

The "Wipers," "Tupfers," and "Pads."—Wipers (Fig. 73) are made of sterilized gauze folded upon itself in such a manner as to form squares of various sizes and thickness, dependent on the requirements of a special case. The cut edges of the gauze are turned in and stitched in place, so that loose threads will not become detached and remain in the wound. Ordinarily wipers are made two and a half to three inches square, and comprise four or five thicknesses of the gauze.

Before using, they are thoroughly sterilized by exposure to steam for half an hour at least while wrapped loosely in a towel or inclosed in steril-

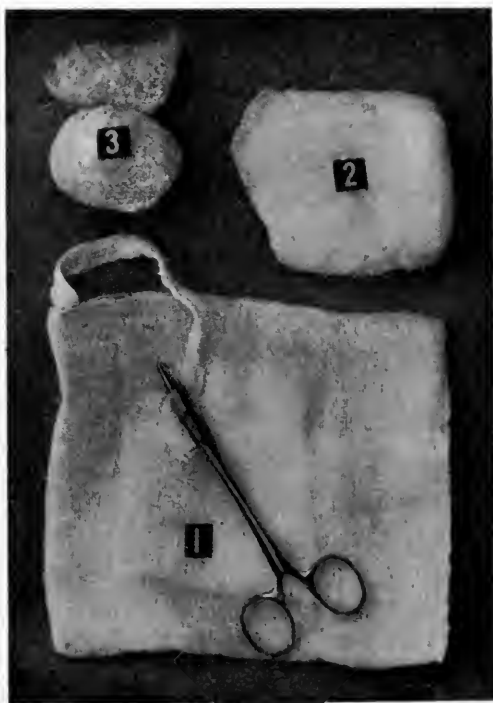

FIG. 73.—1, Aseptic gauze pad. 2, Aseptic wiper. 3, Aseptic tupfer.

izing cases. When in use they should be placed close to the surgeon or his first assistant, who should pick them up, use them, and throw them aside at once; thus the danger from miscellaneous handling and repeated use are certainly avoided. Wipers and pads can not be so well employed in deep or serous cavities as in other situations, since they can not be so effectually applied, and they may be overlooked and left behind, unless a piece of tape of suitable length be connected with each and left in view anchored, if need be, by a forcipressure (Fig. 73). Scrupulous care should be taken to remove loosened threads from these agents, else they may be left behind in the wound and hinder healing by their presence, especially if they become finally infected.

Not a less number than twenty or thirty wipers should be provided for an operation of ordinary magnitude. The prompt removal of blood from a wound is better attained by sponges than by wipers or tuffers. The latter absorb less readily, and are less well adapted for the use of holders.

Tuffers are small balls of sterilized cotton surrounded by absorbent gauze (Fig. 73). Like the wipers, they are made of various sizes and for special purposes; they are prepared for use in the same way, employed for the same purpose, and are then thrown away.

CHAPTER II.

AGENTS FOR THE CONTROL OF HÆMORRHAGE.

THE agents that are employed to arrest hæmorrhage are multifarious and suited to all of its phases. They may be divided into the *natural* and *artificial* hæmostatics, and the former may be subdivided into the *temporary* and *permanent* varieties.

A natural hæmostatic is one interposed by Nature—one which arises as a natural consequence from stimulation of the peculiar inherent tendencies of the blood and the vessels by traumatic influence. The principal temporary natural agents or hæmostatics are the contraction and retraction of the inner coats of a divided or tightly ligatured vessel, followed by the formation of a blood clot within the vessel and between it and the contiguous tissues. Proper contraction and retraction of the coats of a vessel require that these coats be not diseased, and that they be completely severed by the ligature or other constricting force. However, the internal clot is formed with a practical certainty whether these coats be closely constricted or completely divided by the ligature. This fact is of great importance in connection with vessels so extensively diseased that the severance of the inner coats by the ligature may lay the foundation for secondary hæmorrhage.

The formation of a proper internal clot requires that a suitable distance be present between the ligature and the collateral branches; also that the blood and the coats of the vessel be in a healthy state. The recognition of the foregoing facts is of great importance in determining the site and the feasibility of an operation.

The permanent natural agent in the arrest of hæmorrhage is the contraction, permanent organization of the blood clots, and union with the wall of the vessel, causing thereby a complete occlusion of its lumen. This result will depend largely upon the healthy condition of the coats of the vessel and of the blood, and it has a very important bearing on the possibility of the occurrence of that much-dreaded sequel of an operation—secondary hæmorrhage.

The Artificial Hæmostatics.—The artificial hæmostatics are temporary in character, and should be supplemented by the natural to effect a permanent closure of the vessel. The following are the latest, and also the ones long in constant use: Gelatin, animal extracts, etc., styptics, posture of injured part, bandages of various kinds, digital, instrumental, and elastic pressure, pressure by a simple or graduated compress, acupuncture,

torsion, forceps, serre-fines, cautery, etc.; finally, and the most practical, the ligature.

Recently a number of remedies exercising influence in arresting hæmorrhage by modifying the normal constituents of the blood have been brought to the notice of the profession. Gelatin, supra-renal extract, adrenalin, and calcium chlorid are prominent examples.

Gelatin.—The injection of a normal salt solution of gelatin into the subcutaneous tissue increases the coagulability of the blood. When taken by the mouth the coagulating property is much diminished, but not entirely destroyed. It appears to exercise a controlling influence when applied to a bleeding surface. The use by rectum is commended by some, but can not be regarded equal to injection into the tissue. It seems best employed in connection with the normal saline solution forming Carnot's solution. This solution, when prepared after Sailer's method,* offers an approved plan of administration. Take of pure common salt 75 grains (15 gms.), of distilled water 1 quart (1 liter), of gelatin 3 ounces (100 gms.). Heat the water to 212° F. (100° C.), and slowly stir in the gelatin to form a solution. Cool the solution to 104° F. (40° C.), add the white of an egg, stir for several minutes, then boil the mixture. Filter the product through gauze and then through paper. Pour the fluid into test-tubes, each containing 2½ drams (10 cc.), plugging the open ends with cotton. Sterilize the tubes in a steam sterilizer for fifteen minutes for each of three consecutive days. Before using liquefy the gelatin by placing the tube in a cup of hot water; pour the fluid into a sterile glass, from which it is drawn into a sterile syringe.

The Precautions.—Avoid injecting the solution into a blood-vessel. *Be sure that it is sterile, because of the liability of tetanus* from its use. Irrespective of the menace of tetanus the use is not without danger, as deaths from other causes have occurred. It should not be employed in cases with renal disease, as it irritates the kidneys. From 2½ to 5 drams of a ten-per-cent solution may be injected at a time. It may be introduced into the subcutaneous tissue either at the outer side of the thigh, between the shoulders, or beneath the breast in the female. It should be given at the temperature of the body, and as frequently as the character of the case demands.

Supra-Renal Extract.—This substance is a valuable agent for the control of capillary oozing, and is especially applicable to operations on the larynx, pharynx, nose, etc.; also for checking hæmorrhage from hollow viscera. It is not impaired by boiling, and is preserved by the addition of carbolic acid. It acts promptly (twenty seconds) and decidedly (five minutes), its effects last from one and a half to twenty-four hours (Somers). *Coleman* commends the giving of 5 grains of adrenal substance every hour in the intestinal hæmorrhage of typhoid fever. It may be given in 10-grain doses by the bowel when use by the mouth causes nausea.

Adrenalin Chlorid is derived from the gland and its extracts, being 625

* *Therapeutic Gazette*, August, 1901.

to 1,000 times stronger than the former, and easily sterilized by heat. It is employed locally and administered internally. *Internally*, i. e., intravenously, intraperitoneally, subcutaneously, and by the mouth. *Locally* in normal saline solution 1 to 1,000 to 10,000. Applied directly or sprayed on the surface of mucous membranes it acts admirably, controlling capillary bleeding during and after operation.

Intravenously.—Langworth commends this method of employment in cases of sudden heart failure in from $\frac{1}{100}$ to $\frac{1}{1000}$ of a grain, conjoined with a copious saline solution. *Crile** declares that adrenalin acts upon the heart and blood-vessels," and demonstrates its great use in profound shock, employed in the proportion of 1 to 50,000 to 100,000 of the saline solution.

Intraperitoneally it is used for the same purpose and in the same manner as when employed upon mucous surfaces.

Subcutaneously.—Adrenalin chlorid may be administered subcutaneously in the proportion of $\frac{1}{100}$ of a grain to a pint of saline solution. By the mouth in doses of $\frac{1}{100}$ to $\frac{1}{8}$ gr. in solution or in tablet three times daily. Comparatively little practical utility attends administration by mouth or rectum. Since adrenalin seems to impair the germicidal power of the blood, it should be given with great caution in cases of infection. The introduction of the drug should be slowly made, occupying half an hour or so. The treatment repeated with increasing doses until response is seen or failure is apparent.

"The toxic dose for men is not known, but it is probably several hundred times greater than that in which the drug is ordinarily given." †

Calcium Chlorid.—In hæmophilia the use of this drug in 10-grain doses three times a day, for a week or so, as a preparatory measure of operation appears to be of considerable importance in controlling the loss of blood that so often characterizes even trivial operations in these cases. In a similar manner it may be given before and after operations associated with cholæmia, but it does not appear to exercise a sufficient influence on the profounder cases to justify the placing of a special reliance upon its virtues in these instances. In the lighter forms it may be of some special value. It should be recalled that in the giving of this drug for a long time, or in doses of unusual size, instances of thrombosis, without other apparent causes, have happened, giving rise to the notion that in some cases at least a dangerous degree of coagulability may be caused which of itself alone might outrank in significance the reasons for moderation. *Wright*, who first suggested its use, pointed out the fact that if given too freely or for longer periods than three or four days diminished coagulability might follow. Evidently further light is needed in this regard. The comparative coagulation time of the blood, taken before and after its employment, is a guide by which the efficiency of the drug may be estimated.

* The Boston Medical and Surgical Journal, March 5th, 1903.

† American Med., page 813, November, 1903 (Martin and Pennington).

The Styptics.—Cold and hot water are employed to check oozing of blood, even if the bleeding be of an active type. Formerly the cold was used exclusively, and the suggestion of the use of hot water for this purpose, except in greatly depressed subjects, caused ominous frowns to gather on the brows of experienced practitioners. Once, within the easy recollection of the writer, a celebrated obstetrician vetoed the graduation of a student who ventured to express the then somewhat premature opinion that intra-uterine injections of hot water were a suitable treatment for post-partum hæmorrhage. Latterly, however, the use of hot water for the arrest of hæmorrhages has almost entirely superseded the cold. If water as hot as the hand can well bear (118° F.) be freely applied to a cut surface, it not only acts as a hæmostatic but also exercises an aseptic effect on the tissues. If a large sponge saturated with hot water be pressed against an oozing surface, the styptic effect is usually prompt and salutary.

Solutions of subsulphate of iron, alum, tannin, and resin, etc., were much more frequently applied to bleeding surfaces formerly than at present. The inorganic styptics can be applied directly or in aqueous solutions of various strengths; the organic ones are usually liquefied in ether, alcohol, or chloroform and then applied. The employment of these agents for the arrest of hæmorrhage from a wound is not to be countenanced until all other means have proved futile. Their inconsiderate introduction into a wound disguises the presence of foreign bodies, renders cleansing imperfect, and destroys the possibility of prompt union.

Collodion, when dissolved in ether and applied to the already united lips of a wound by means of a camel's-hair pencil, not only controls oozing but aids primary union by causing closer coaptation of the wound borders and the exclusion of infecting agents. Styptic collodion with or without a small amount of iodoform in the solution is better, possibly, than the plain collodion for the purpose.

The Position.—The elevation or flexion of a limb (Fig. 74) impedes its circulation, especially that of the more distant portions of the body, and therefore correspondingly lessens the degree of hæmorrhage of these parts. The reverse of this principle counsels the lowering of the head if the patient be prostrated from the loss of blood.

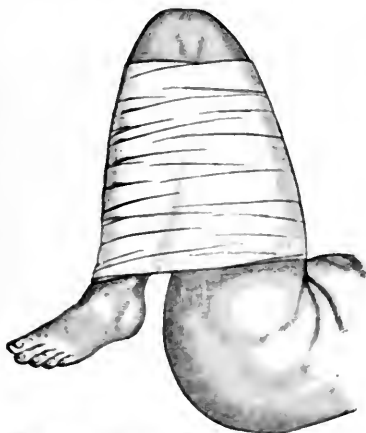


FIG. 74.—Forced flexion of the knee for temporary arrest of hæmorrhage in the popliteal space.

The Bandages.—The bandages can be divided into two distinct classes, the inelastic and elastic. *The inelastic variety*, the ordinary roller bandage, is well adapted for the arrest of capillary and venous oozing when applied firmly to the bleeding part. Under these circumstances the interposition of an abundant amount of gauze or absorbent cotton equalizes the pressure of the bandage and adds correspondingly to the comfort of the patient.

The elastic bandage, of which Esmarch is the inventor, is composed of elastic webbing of the width of an ordinary roller, and of sufficient

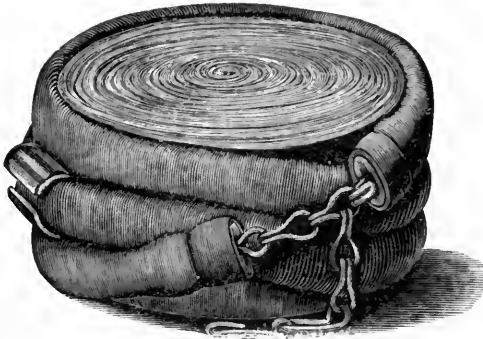


FIG. 75.—Elastic bandage.

length to meet the requirements (Fig. 75). It is applied firmly to the limb in a spiral manner from the distal extremity (Fig. 76) to a good distance above the point of operation, and then it is supplemented by a rubber cord or strap passed firmly around the limb at this point held by forceps, a clasp, or hook adapted to that special purpose (Figs. 77, 78, and 79). The bandage is then removed by unwinding it from above downward.

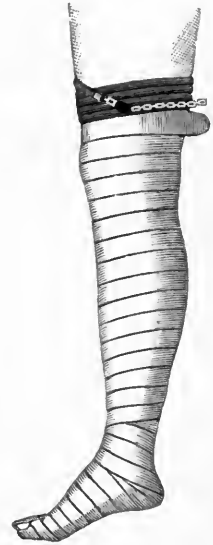


FIG. 76.
Elastic bandage applied.

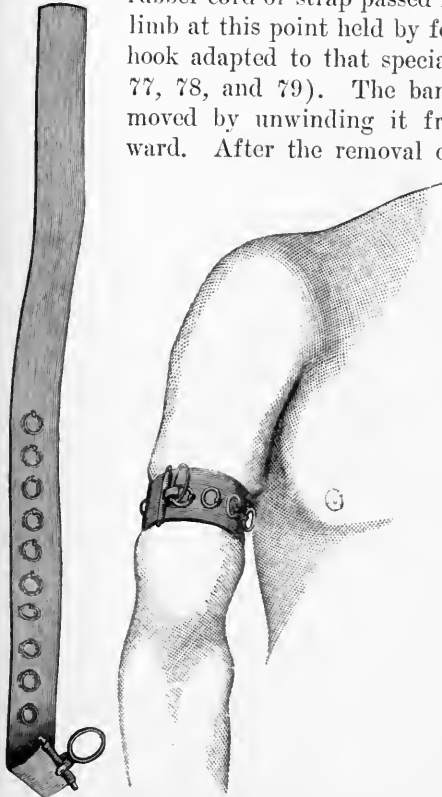


FIG. 77.—Nicaise's compression band.

After the removal of the bandage the limb will have a cadaverous aspect, being entirely devoid of blood, and the necessary operation can be performed and the wound dressed without the least hæmorrhage. However, this, like many other useful ones, has objectionable features. The removal of the bandage and the cord is often followed by a vigorous and persistent oozing; its application may force into the circulation deleterious agents which form the basis of septic or other disease. Its use may temporarily paralyze the part to which it was applied, and cause transient disturbances of the general circulation. These latter are not, however, sufficiently important to contra-indicate its employment. In amputation of an extremity for gangrene due to diseased vessels, the elastic bandage should not be

applied, since the pressure will crush the stiffened capillaries and otherwise impair the nutrition of the limb. Digital pressure of the vessel only should be employed in these cases. The tendency to severe oozing is an

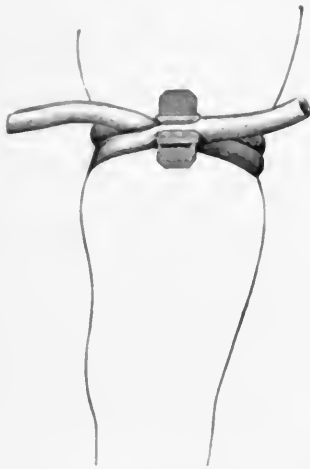


FIG. 78.—Foulis's fastening in position.

objection which must stand against the use of this agent; but its power to force improper products from diseased or injured parts into the general circulation can be obviated by omitting the application to those parts—that is, by raising the limb and holding it till well depleted by the force of gravity, then applying the bandage to the sound parts, below the seat of injury or disease, and passing very lightly over or omitting altogether these parts on the way up to the seat of operation, and then using the rubber band as before. It is adapted to the accomplishment of another very important purpose—that of forcing the blood of the extremities into the circulation of the trunk in cases of extreme prostration from hemorrhage. The control of bleeding in operations on the scalp can readily be secured by a rubber tube and forcipressure, as indicated in Fig. 80. On




FIG. 80.—Rubber tube control.



FIG. 81.—Martin's bandage.



FIG. 79.
Foulis's fastening with rubber cord.

page 226, under cirroid growth, control was had by the writer years ago by a rubber band. *Martin's bandage* (Fig. 81) is simply a rubber roller, and is used to meet the same indications as the former. It can be, however, more readily cleansed than the webbed one, and in this particular is preferable to it. *Solid rubber rings* of a suitable size to pass firmly over an extremity have been used as a substitute for the rubber roller. In connection with the digits, and even the foot, hand, and wrist, they act quite well, but have not as yet entered into common use.

The Compresses.—Two kinds of compresses are in common use: the simple

and graduated. *The simple compress* consists of several thicknesses of cloth, or other suitable material, folded in small dimensions; it is then




FIG. 82.—Pyramidal compress.

placed over the vessel, or upon the part where pressure is desired, and held in position by a tightly drawn bandage or a broad strip of adhesive plaster. *The graduated compress*




FIG. 83.—Oblong compress.

may be formed like an inverted pyramid or cone, or may be oblong (Figs. 82, 83, 84). Its apex should be firm and unyielding, to give an equal and constant pressure.

This compress can be made of superimposed layers of cloth on anti-septic gauze, or other suitable material, and of a size and shape to

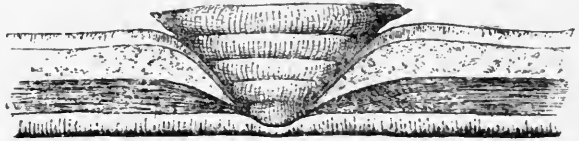


FIG. 84.—Conical compress.

form a symmetrical structure. It is employed to make pressure upon the deep-seated vessels of soft parts, and to arrest hæmorrhage within a deep wound or cavity. Care must be taken to properly adjust it, else it may impede venous return, or cause pain from pressure upon large nervous trunks.

The Digital Pressure.

—Digital pressure is the most available of all the compressing hæmostatics. It is constantly at hand, and often intuitively seeks to arrest the flow of blood. It is only necessary to add the influence of a sensitive finger and a sensible brain to a knowledge of where and how to apply the force, to render this form of pressure of inestimable value. The vessel should be pressed against some firmly resisting part lying near it, as against a bone. If the bone be deeply seated, the vessel must be pressed toward it (Fig. 85), unless the limb can



FIG. 85.—Digital pressure on femoral.

be grasped so as to bring the ends of the fingers against the vessel. If blood flow from an open wound, direct pressure should be made upon the bleeding point with one hand, while the other hastens to compress the main artery above the point of hæmorrhage. It is not necessary to use great force to interrupt the blood current; moreover, to do so tires the arm and hand, and causes the patient much pain; use just force enough to interrupt all

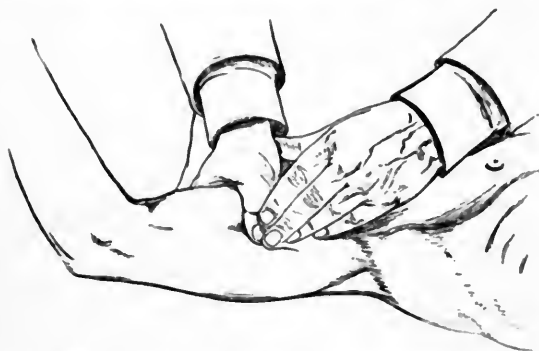

FIG. 86.—Digital compression of the brachial against the bone.

blood flow. The thumb of the right hand is the best digit to apply at first; afterward it may be relieved in various ways by the alternate aid of the remaining fingers (Fig. 86) and thumb of the surgeon or those of others who are present. If secondary hemorrhage be anticipated, or have occurred, the proper point for compressing the vessel involved must be indicated

by some indelible substance, so that in case of a sudden bleeding an attendant can apply promptly the necessary pressure. With this object in view, the attendants must be instructed in the details of making the pressure, and be thoroughly acquainted with the necessity of constant vigilance and of instant and effective action.

The circulation of a vessel that is inaccessible to proper digital compression, as the subclavian, can be controlled often by the handle of a key, or by a short crutch, and the applied extremity of either should be covered with some soft material, to prevent injury to the vessel and the superimposed soft parts.

The Instrumental Pressure.— Under this heading are included the various forms of tourniquets and such other devices as are not directly connected with the adjustment of ligatures to bleeding vessels. The tourniquet commonly used was devised by Petit, and it is no doubt familiar to all (Fig. 87). It should be cautiously applied, with the pressure so directed as to crowd the vessel against the bone when possible (Figs. 88 and 89). A simple and effective tourniquet can be extemporized by placing a roller

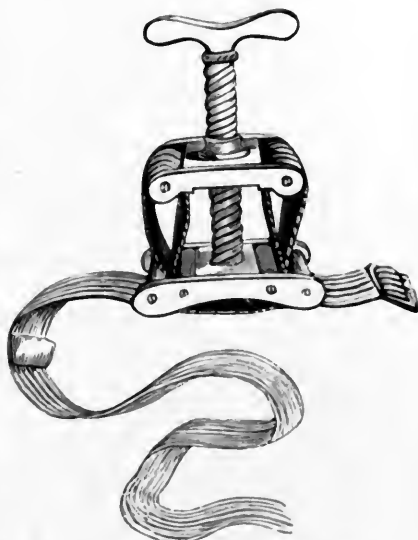


FIG. 87.—Petit's tourniquet.

bandage over the site of the vessel and confining it in position by a handkerchief passed around the limb. If the handkerchief be then tied and twisted by a stick, the circulation will be controlled (Fig. 90).

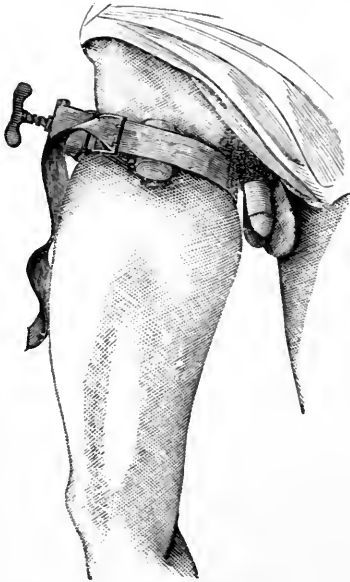

FIG. 88.—Tourniquet applied to femoral.

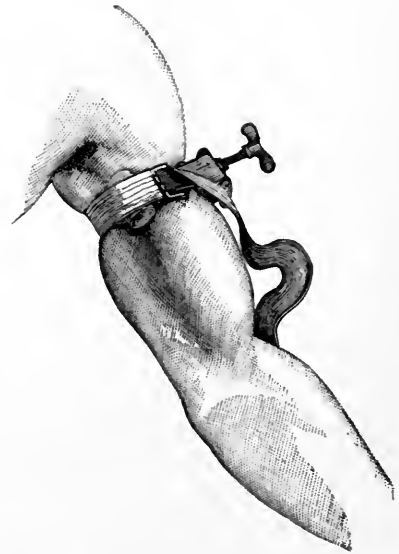

FIG. 89.—Tourniquet applied to brachial

Davy's Lever, an implement devised by the surgeon whose name it bears, was formerly often employed for the especial purpose of controlling hæmorrhage in amputations at the hip joint. The instrument is turned from ebony, and is from eighteen to twenty inches in length. The surface is smooth, and its extremities rounded; its largest diameter is about five eighths of an inch. It can be graduated so that the surgeon will be able to estimate the exact extent of the entrance into the bowel. Its shape has been variously modified to meet the requirements suggested by its more

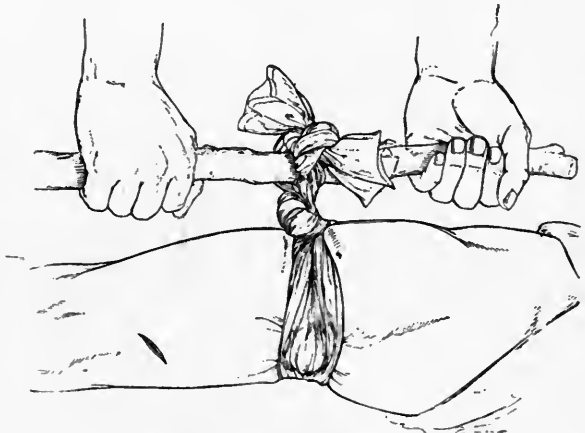


FIG. 90.—Improved tourniquet.

extended use. It is passed up the rectum in the direction of that canal a sufficient distance to make pressure on the common iliac artery at the side from which the limb is to be removed. The upper extremity of the lever is

then carried to the right or left, as the case may be, sufficiently to lie between the bodies of the lumbar vertebræ and the *psaos magnus* muscle. The lower extremity of the lever is then raised so as to bring the requisite pressure to bear upon the vessel (Fig. 91).

This implement has been employed with signal success. It can be more safely applied at the left than at the right side of the body, because the left

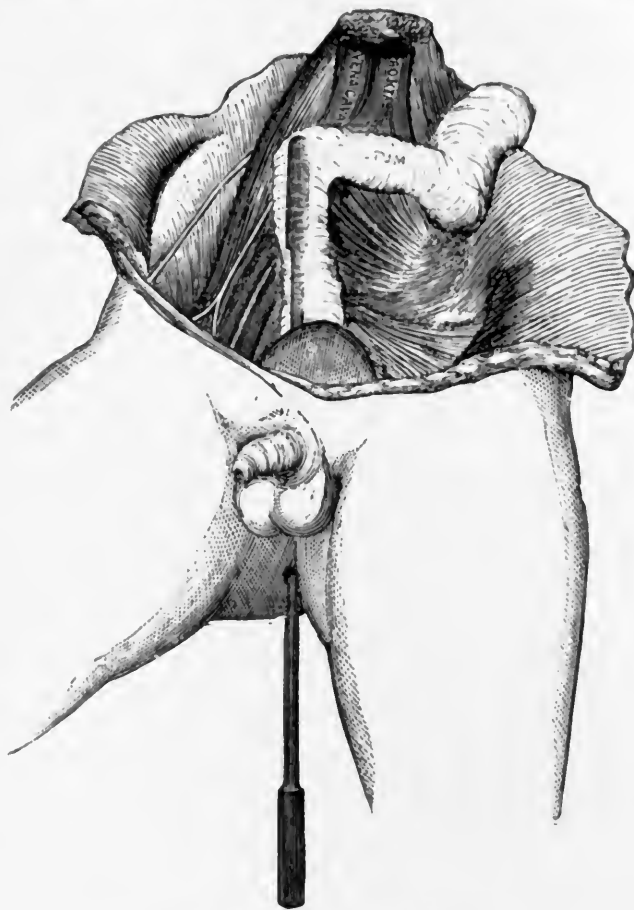


FIG. 91.—Davy's lever applied.

iliac artery is nearer to the rectum than is the right. The introduction should be preceded by an injection of sweet oil into the rectum, after which the lever is cautiously introduced and held in position by a gentle, though firm, upward elevation of the free end, thereby causing the perineal tissues to act as a fulcrum. The free extremity is then pressed against the opposite thigh, and carefully held in position during the operation. If unnecessary force be used, the gut may be torn or perforated.

Trendelenburg's Rod.—Trendelenburg's rod is used for the same purpose as Davy's lever, but in an entirely different manner (Fig. 92). The soft

parts are transfixed by this rod at such a depth as to include the whole thickness of the proposed flap. A strong rubber cord is then passed over the extremities of the rod with sufficient force to compress the vessels in the tissues above it. The flap can then be made and the vessels ligatured without loss of blood, after which the rod is withdrawn and the remaining flap made in a similar manner.

The preceding method illustrates the use of transverse elastic pressure as associated with the transfixion of a limited amount of the soft tissues by a sharp rod, for the purpose of securing bloodless operations.

Somewhat recently Dr. Wyeth has brought forward a wise modification of this means, which consists of circular elastic compression of the entire limb associated with pin or skewer transfixion of the soft parts, for the same purpose. This method is superior in all respects to the last two preceding ones, and which it has superseded. Since the details of the plan are directed to amputation at the hip, their description will appear under that title (page 543 *et seq.*).

The Acupressure.—Acupressure for the control of hæmorrhage was devised by Sir James Y. Simpson, and is used much less than formerly. It is applied in many ways; the methods of the application may, however, be reduced practically to two in number: *one*, where the pin is carried through the soft parts *under*

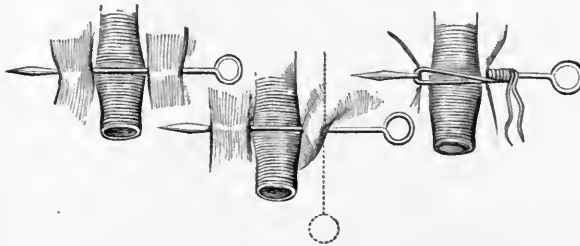


FIG. 93.
Pin above
vessel.

FIG. 94.
Oblique inser-
tion of pin.

FIG. 95.
Pin beneath
vessel.



FIG. 92,
Trendelenburg's rod.

the vessel, and the point elevated and pushed through at an angle sufficient to cause it to tightly close the lumen of the artery by pressing the vessel against the overlying tissues (Fig. 95).

If this means be not effective, additional pressure can be made by passing beneath each extremity and obliquely above the pin several turns of cotton yarn or of the ordinary silk ligature. *The other method* is the reverse of the first, the pin resting upon and pressing the vessel downward upon the deep-seated tissue, instead of upward against the superficial (Figs. 93 and 94). Acupressure is often employed to arrest hæmorrhage from small branches of

the palm of the hand and in other similarly constituted structures. The distance from the open end of the vessel to the point at which the pressure is applied depends on the size of the vessel—if large, within one half inch; if smaller, the distance is lessened proportionately to the size.

The introduction of the pin can be facilitated by the aid of Buck's pin conductor (Fig. 96), which when passed beneath the vessel and out through

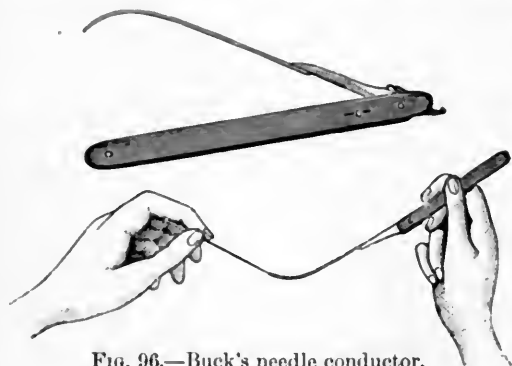


FIG. 96.—Buck's needle conductor.

the integument at the opposite side will, on withdrawal, properly place the pin, provided the point of the latter be well inserted into the open end of the instrument. A surgical needle, curved or straight, according to situation, can be passed beneath a vessel and caused to effect the closure in a similar manner as with the pin.

Circumclusion, torsion, and retroclusion are

variations in the method of pin pressure arising either from twisting or compressing the caliber of the vessel. These methods seem to possess but one distinct, practical advantage over occlusion by catgut ligature—viz., they can be more safely practiced on vessels with brittle coats due to atheromatous and other changes. The minute description of the various modifications of acupressure can be found in the text-books and medical dictionaries of the day. The pins are made of gold, silver, steel, and iron, are of various lengths, have metal or glass heads and differently shaped points. A further description or an illustration of them is not necessary, since they can be readily and satisfactorily ordered from the venders of surgical supplies. Shawl pins, ordinary pins, and needles can be safely substituted if required by the exigencies of the case.

The Torsion.—Torsion consists in thoroughly isolating and drawing down the end of the vessel, seizing it firmly with a forceps about half an inch above its extremity, and twisting the end several times with another forceps till the resistance of the vessel is overcome (Fig. 97), care being taken not to twist it off. The blood is then allowed to impinge upon the twisted portion before the vessel is released, to



FIG. 97.—Torsion of an artery.

test the completeness of the occlusion. The twisting produces a mutilation and breaking up of the coats of the vessel, which closes its caliber and causes a rapid formation of the internal clot. It is evident, if the coats be diseased and brittle, that much caution is necessary in twisting them, otherwise a good basis for the occurrence of secondary hæmorrhage will be established. Torsion forceps, which combine in one instrument the holding and twisting forces, have been recommended, although not commonly employed (Fig. 98). Torsion as a substitute for ligaturing is not considered with much favor in this country except in individual instances. It is commonly employed, however, to close the small bleeding points seen on the surface of freshly cut wounds, and when thus employed rarely more than a single forceps is used for the purpose. Only the end of the vessel should be seized, to avoid the unnecessary twisting and devitalization of the contiguous tissues.




FIG. 98.—Hewson's torsion forceps.

The Forceps, Serre-fines, and Tenacula.—Since these instruments are closely associated in common usefulness, they can be spoken of in connection with each other. The spring-catch fenestrated forceps, now rarely used, is the best. There are two patterns of these — Liston's (Fig. 99), and those devised by Hamilton (Fig. 100).




FIG. 99.—Liston's spring-catch fenestrated artery forceps.

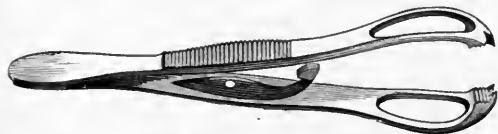


FIG. 100.—Hamilton's (F. H.) artery forceps.

Liston's mouse-tooth forceps (Fig. 101), while it is not suitable for the common purpose of catching bleeding vessels, is nevertheless of great service in securing bleeding points on flat surfaces, especially when surrounded by dense tissues.

The serre-fine forceps is of great utility in the control of bleeding points during an operation. It can be easily and quickly adjusted, and by its continued pressure on the coats of the small vessels the necessity of subsequent ligaturing may be obviated. It is used to catch and control bleed-



FIG. 101.—Liston's mouse-tooth forceps.

ing points to which the application of a ligature is impracticable, and is often allowed to remain on the vessels till all danger of bleeding has subsided. There are several varieties of these instruments—

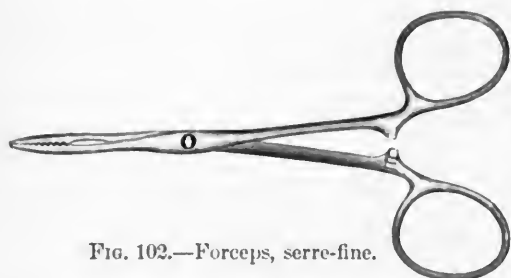


FIG. 102.—Forceps, serre-fine.

the forceps *serre-fine*, which is the largest (Fig. 102), is admirably adapted to controlling large vessels, and on account of its seizing and retaining power can be utilized in grasping and holding tissues for other purposes. The

smaller *serre-fines* (Fig. 103) are used to catch and hold small bleeding points during operation.

Milne's *serre-fine* forceps (*a*) is closely allied in principle to the Langenbeck (*b*) and wire (*c*) *serre-fines*, and like them it is useful for compressing the divided ends of smaller arteries and the trunks in their course through the soft tissues, as the coronary arteries in the operation for harelip. The compressor devised by Gross (Fig. 104) can be attached to the bleeding point, the handle unscrewed, and the blades permitted to remain until all danger of bleeding has ceased.



FIG. 103.

- a.* Milne's *serre-fine*.
- b.* Langenbeck's *serre-fine*.
- c.* Wire *serre-fine*.

The Tenaculum (Fig. 105).—The tenaculum is used to pick up and draw outward from the soft parts the open mouths of vessels. If the extremity of a small vessel be too short to be ligatured by the aid of forceps, it can be transfixed along with a small portion of the




FIG. 104.—Gross's artery compressor.

contiguous soft parts by the tenaculum, and a ligature thrown around the combined tissues. If a nick be made on either side of the tissues raised by the tenaculum, the ligature can be more securely applied and the vessel more firmly grasped.




FIG. 105.—Tenaculum.

The Forcepressure.—The implements bearing this name are quite numerous and withal exceedingly efficient. While there are many deviations in pattern of a minor degree, and for which distinct advantages are claimed,

still these variations are often too fanciful to be dignified by special mention. The straight and the curved (Fig. 106) are the patterns now in constant use, the curved perhaps being the more favored of the two, because it has the smaller bite, and obstructs less the field and view of the operator. These instruments are strong, convenient, serviceable, and cleanly, and therefore have superseded almost entirely the use of the older forceps. Those with blunt points are better aids in the proper placing of a ligature than are those with slender points, for obvious reasons. The T-shaped one is sometimes employed to check oozing of extended surfaces.

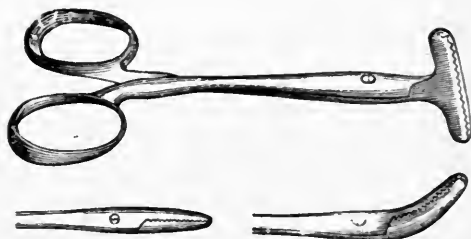


FIG. 106.—Forecpressure.

The Cautery.—Cautery, which was once a common means of controlling hæmorrhage, has now but a limited application for this purpose. There are three varieties in common use—the *actual*, the *thermo*-, and *electro-cauteries*. The actual cautery requires the employment of cautery irons (Fig. 107), which should be accompanied by the blowpipe and lamp, although they can be heated by ordinary measures. The blowpipe is by far the best means, since during the summer months, or in unfavorable situations,

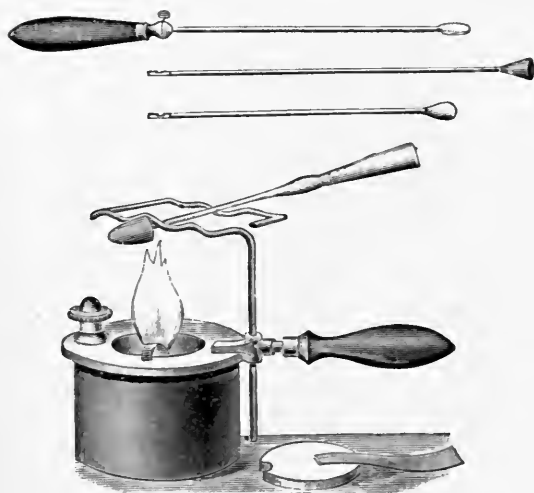


FIG. 107.—Actual cautery, blowpipe, and irons.

or when great haste is necessary, the domestic means of heating them will be inadequate.

Thermic Angiotripsy.—Downes combines heat and the angiotribe, thus controlling hæmorrhage in major operations in a satisfactory way.*

Thermo-Cautery.—The Paquelin cautery consists of an isolated hollow handle adapted to three movable platinum points, into either of which a continuous stream of benzine vapor is introduced by a bulb connected by a tube

with the bottle containing the fluid (Fig. 108), after the cautery is heated in the flame of a spirit lamp. The use of this mechanism brings the platinum point quickly to the required temperature, which is maintained by squeezing the rubber bulb. *If the benzine vapor be introduced into the platinum point*

before the metal is properly heated the instrument is made temporarily unserviceable—a fact which often leads to much vexation and pernicious delay.



FIG. 108.—Paquelin's thermo-cautery.

The range of usefulness of this instrument is more extended than that of the former means of cautery. It is used not only for the same purposes, but can be employed as a cutting implement for the removal of morbid growths, etc., when union by first intention becomes a lesser consideration than the annoy-



FIG. 109.—Galvano-cautery battery, with knife electrodes.

ance from primary hæmorrhage.

The Galvano Cautery. — Electricity is employed for the purposes of cautery much more frequently than heretofore; and this is especially true in connection with the destruction of vascular growths and the removal of small malignant neoplasms.

The ingenious command that is had of this subtle

agent enables the surgeon to perform many trivial operations with but little pain to the patient and inconvenience to himself (Fig. 109). Storage batteries (Fig. 110) and their adaptability for special illuminating purposes in deep wounds, and also the opportunity to use the various associated devices of the batteries for operative purposes, are of great importance (Fig. 111). O. Fig. 999, Vol. II.

The Ligature.—The ligature is by far the best agent for the control of hæmorrhage that the surgeon possesses. It is easily portable, can be readily applied, and is always obtainable in some form. Ligatures are classified, according to their nature, into the *organic* and *inorganic*. The organic

comprise the hemp, silk, and catgut varieties, and for convenience should not be less than twelve to sixteen inches in length, and longer, even, should circumstances require. A ligature should be of sufficient strength to withstand the traction necessary to meet the demand

for its use. Its size should depend somewhat upon the force to be employed in the tying and the area of the seat of constriction. The requisite force to properly occlude a vessel can not be practically estimated by ounces, but is largely a matter of observation. The traction should be made steadily over the ends of the forefingers or thumbs, and without disturbing the relation of the vessel to its surrounding parts (Fig. 112). The giving away of the inner coat of a vessel indicates that the ligature

is drawn sufficiently tight, but this sensation is not noticeable except in connection with the larger vessels. The firm apposition of the surfaces of the inner coat without division is adequate for the purpose, but in usual

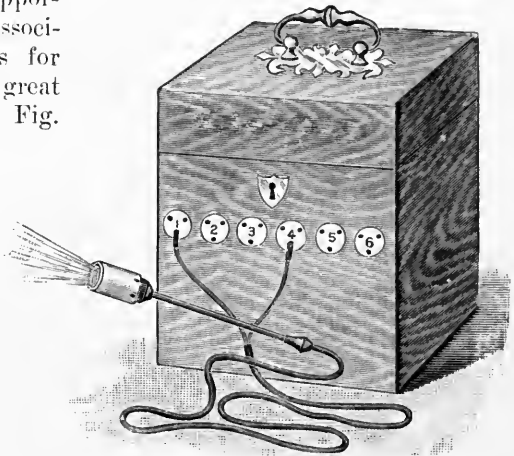


FIG. 110.—Hand-lamp for illumination.

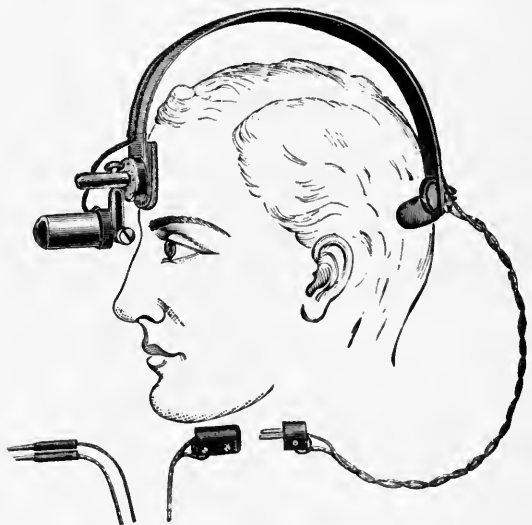


FIG. 111.—Head-lamp for illumination.

practice the complete division of this coat is made, unless the vessel be large or much diseased, when the former practice is regarded the safer, as it is followed less frequently by secondary hæmorrhage. Great caution is to be exercised to prevent other tissues than the walls of the vessel from being included in the grasp of the ligature, but when the vessel is diseased, not

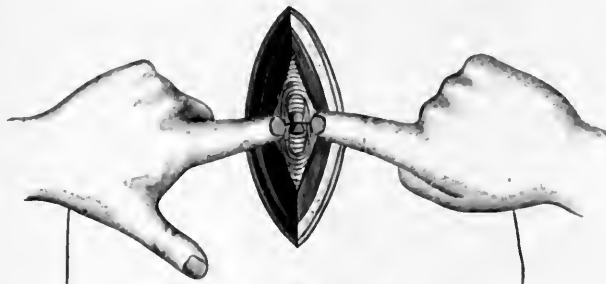


FIG. 112.—Tying a ligature.

infrequently small portions of contiguous soft tissues are taken in to prevent undue severance of the arterial walls. In such instances two ligatures can be applied a short distance apart. The first one is applied near the end of the vessel and firm enough to close the lumen entirely. The second above, tight enough to nearly arrest the flow of blood. The second one protects the first from undue impulse, and between the two a clot is quickly formed. The writer has practiced this plan in several instances in greatly diseased arteries, with prompt and permanent closure on each occasion. If a nerve be tied in, the patient may be tormented by pain, which may not cease even with the disappearance of the constricting agent.

Knots.—The security of the ligature depends very much on the kind of knot employed in the tying. All knots are insecure unless carefully tied.

The surgeon's or the friction knot is formed by making two turns of the ligature at the first loop instead of one (Fig. 113). It will not slip if it has been drawn tightly; it is wisely employed in tying a vessel beyond the sight



FIG. 113.—Surgeon's knot.



FIG. 114.—Reef knot.




FIG. 115.—Granny knot.

of the surgeon, because then the first half of a reef knot may slip without his knowledge, thereby resulting in an imperfect closure of the vessel. It is proper to say, however, that when this knot is supplemented by turns, two should be employed, as a single turn tends to cause relaxation of the first two and thus lessens its security.

It sometimes happens, when a silk ligature is saturated with blood or other fluid, that the first half of the knot can not be drawn as tightly as it

should, owing to the binding of the thread; thus an insecure fastening is made, even when it is fortified by overlying turns.

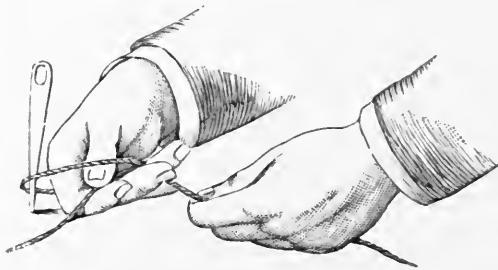


FIG. 116.—First step in tying reef knot.

by any other: "The ligature is held in the palm of the right hand, between the thumb and finger; the end is then thrown around the forceps closely and caught with the left hand, and carried across the right thumb and inserted between the third and fourth fingers of the right hand (Fig. 116). The left at the same moment seizes the other end, and the ends of the threads are drawn out, as is demonstrated in Fig. 117. There will now be no difficulty in drawing the knot thus formed tight with the forefingers (Fig. 118), or, if preferred, with the thumbs. To complete the knot



FIG. 117.—Second step.

by making another tie, the same maneuver is to be effected, taking care always to begin with the opposite hand to that which began before. It is quite immaterial which hand begins the first part of the knot, so long as the opposite one always begins the second part; in this way, with a little practice, the reef knot may be unerringly tied with the greatest rapidity." When the knot is completed it will be seen that the ends of the ligatures lie parallel with and in contact with the portion of the ligature which surrounds the vessel.

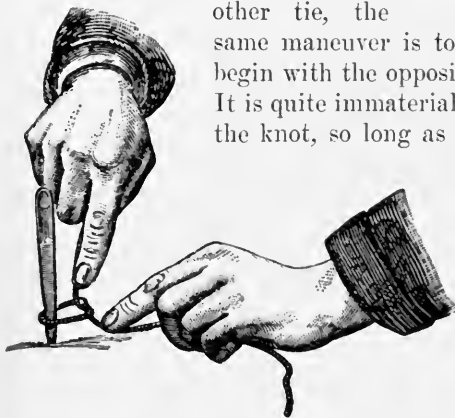


FIG. 118.—Third step.

Great care should be exercised after the proper tightening of the first fold of the knot not to disturb it by making the ends tense during the tying of the second part, for if the first part be then loosened

and the loosening pass unnoticed, the placing of the second part will make the completed knot very insecure. Catgut can be tied with the surgeon's or the reef knot, but it is less secure than silk. Therefore, when catgut is applied to a large vessel an additional tie should be given, irrespective of the kind of knot.



FIG. 119.—Staffordshire knot.

The Staffordshire Knot (Fig. 119).—The Staffordshire knot is used in tying pedicles. It is formed by carrying the ligature through the pedicle and returning the needle so as to leave a loop at the distal side. The loop is then slipped over the pedicle and the free ends are carried one above it, the other below, where they are tied together with a reef knot. This knot may slip.

The elaborate studies of Ballance and Edmunds of the question of knots and their tying, especially of the larger vessels, emphasize in no uncertain manner the importance of the use of their "stay knot."

The Floss-Silk Stay-Knot.—This variety of knot is made as follows: Carry around the vessel two ligatures of soft floss silk, lying side by side and parallel with each other (Fig. 120); tie each independently with equal force, half of a square knot, using sufficient traction to firmly coapt the inner walls of the vessel without causing rupture, but arresting entirely the flow of blood, grasp conjointly the ends of the ligatures at either side of the vessel and gently tighten the half knots if practicable. Complete the tying by uniting the two ends at each side, and using them as one in finishing the knot. The innominate can be wisely ligatured by this method of tying (Figs. 207, 208). Catgut and other agents for ligaturing are employed in a similar way, using two or more strands for the purpose, according to the size of the vessel, the degree of force of the circulation, and the structural integrity of the coats. However, the floss-silk knot is softer than that formed by the preceding firmer agents, and therefore less liable to cause unequal pressure of the constricted vessel and the greater danger of hæmorrhage that attends their use.

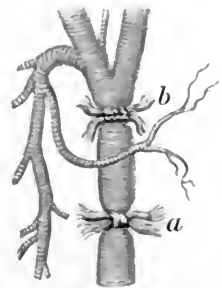


FIG. 120.—The floss-silk stay-knot. *a*. The combined fold, completed knot. *b*. The independent single folds.

The atrophy of the inner coats of vessels caused by the compression of the ligatures, when not attended with division of these structures, is variable, being modified in its extent by the degree and the area of the compressing force, also by the actual state of the circulation in the tissues themselves.

It will be noted (page 162 *et seq.*) that in ligature of the innominate this variety of knot is especially indicated, and, moreover, it is not at all uncertain that in the successful outcomes of ligatures of this important vessel the stay-knot of Ballance and Edmunds has contributed no unim-

portant factor to the manner of the application, also no insignificant amount of the favorable features of spinal cases can be justly attributed.

The difficulty of the removal of deep-seated ligatures, especially when connected with pedicles, is not a new or trifling matter. Dr. Grad has devised the following ingenious and excellent plan for the loosening and removal of this class of ligatures (Fig. 121). As will be noted in the illustration, an independent traction loop is included beneath each fold of the

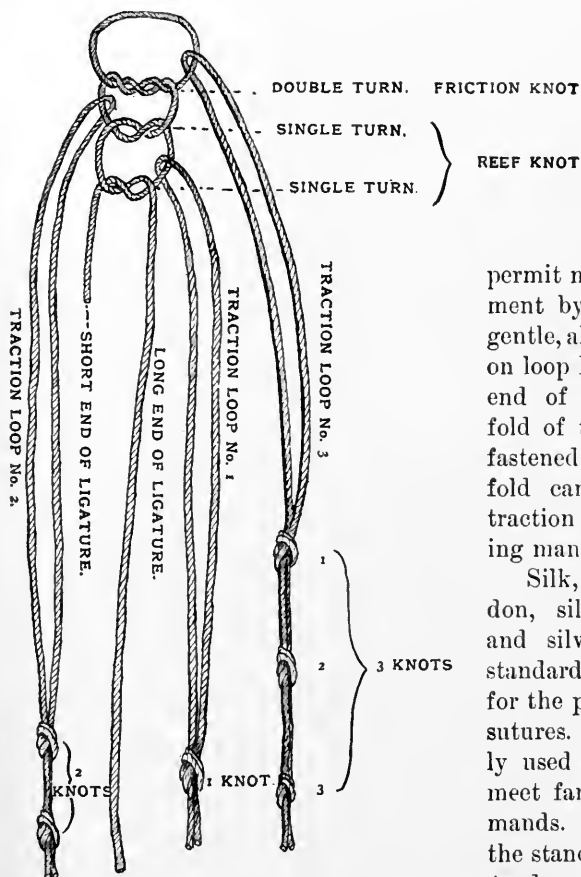


FIG. 121.—The Grad method of ligature removal.

ligature in the tying of the knot, and the order of the relation to the surface of the respective loops is indicated numerically by knots tied in them. One end of the ligature is cut short to

permit more readily the displacement by the traction loops. If gentle, alternate traction be made on loop No. 1 and on the longer end of the ligature, the third fold of the knot is quickly unfastened; and each preceding fold can be untied by similar traction directed in a corresponding manner.

Silk, catgut, kangaroo tendon, silkworm-gut, horsehair, and silver wire constitute the standard materials now employed for the purposes of ligatures and sutures. The last three are rarely used as ligatures, except to meet fancied or emergency demands. Silk and catgut are the standard ligatures, kangaroo tendon being rarely employed for the purpose.

Silk.—Silk is employed constantly in various forms and sizes for ligaturing and suturing. It is fitted especially for integumentary and intestinal sewing, and the ligature of pedicles and other large masses of tissue. When employed for intestinal suturing the black silk is advisable, as it can be easily seen and accurately placed. Silk as a ligature has the following advantages: It is cheap, easily obtained and sterilized, readily applied, and remains firmly fixed if properly tied. However, it is comparatively readily infected both within and without the wound, and the use is frequently attended with suppuration of the stitch-hole variety. *Silk is sterilized by boiling in a one-*

per-cent aqueous solution of washing soda for ten minutes, or by steaming in a sterilizer for fifteen minutes. It can be thus treated in skeins or while wound loosely on glass spools or bobbins (Figs. 122, 123). After washing out the soda by a few moments' immersion in pure boiling water the ligatures can then be properly preserved in sterilized glass tubes plugged with cotton, or in wide-mouthed bottles (Fig. 124) containing alcohol or other proper antiseptic fluid. Strong solutions of carbolic acid are objectionable for



FIG. 122.—Bobbins for ligatures.



FIG. 123.—Silk on spools.




FIG. 124.—Wide-mouthed bottle for ligatures.

this purpose, since they impair the integrity of the fiber. A strict surgical technique enjoins the use of freshly prepared silk on each occasion.

Catgut.—Catgut is used extensively as ligatures and sutures. The best catgut is that which comes from Germany in the form of violin, guitar, or banjo strings. Only the very best should be used. In general it will be found that only five sizes are required. Manufacturers are in the habit of designating the size of catgut by numbers, and those of different makers frequently stand for different thicknesses of gut—a fact which should be borne in mind when prepared catgut is ordered from a dealer. Catgut is the rival of silk in surgical technique, and the question which is the better is not yet finally settled, except in individual minds and for special purposes. Catgut is of uncertain strength, and therefore not at all times reliable for the ligature of pedicles and larger portions of tissue. It slips more readily than silk, hence greater caution is needed in tying; it is sterilized with great difficulty and labor, and for these reasons may invite carelessness and infection; it is sometimes not easily obtainable, and therefore ought not to be relied on too exclusively. Catgut is less reliable for integumentary sewing than silk, as it causes more irritation and is less durable; but for the ligature of vessels and the obliteration of dead spaces, properly pre-

pared and carefully applied, catgut is the most useful of all agents. *Fowler*, of Brooklyn, prepared catgut by boiling in alcohol one hour. When sealed in small glass tubes (Fig. 125) and thus treated, and the tubes broken at the time of use of the ligatures, the strictest asepsis is secured.

Preparation of Catgut at Bellevue Hospital, New York, and its Dependencies.—The late Dr. Charles Rice, the eminent chemist, and the pharmacist of Bellevue and the Allied Hospitals, for years prepared excellent catgut as follows:

“Two kinds of catgut are generally used, the smooth and the rough.

“1. *The Smooth Catgut.*—This is the best quality of imported smooth banjo and violin strings, put up in boxes containing thirty strings each, and of the following sizes:

DESIGNATION.	Average length of each string.	Average breaking strain of each string (raw).
Banjo 1 (thinnest).....	67½ inches.	5 pounds.
Banjo 2.....	67½ “	8 “
Violin E.....	67½ “	18 “
Violin A.....	44½ “	24 “
Violin D (heaviest).....	44½ “	32 “

“The first three sizes are those mostly in use. Each string or coil is tied in two places with silk, which should be white, not colored, because, if colored, the tint will be more or less transferred to the catgut when boiled with ether or alcohol.

“2. *The Rough Catgut.*—This is the kind for clockmakers’ and jewelers’ use. It is usually in strings of five metres in length, of various thicknesses, and tied with itself. The smaller sizes, Nos. 00, 0, 1, 2, and 3, are those most generally in use.

“If smooth catgut is to be boiled in ether or strong alcohol, the string of silk with which it is tied need not be removed, for neither of these liquids will alter the regular circular form of the coils or cause them to twist. But if this catgut is to be heated to a temperature over about 200° F. in oil of turpentine, vaseline, paraffin oil, albolene, or other similar liquids, the ties must be removed, as they do not expand equally with the gut, and are apt to strangle it or almost cut it in two. Each coil must be opened and securely wound on some kind of reel or bobbin, so as not to twist or snarl. In the absence of any specially prepared reels the coils may be wound on the outside of a test tube, several strings being tied together if necessary, the two free ends being secured with wire. The test tube, properly weighted with shot or otherwise, is then immersed in the hot liquid for the prescribed time. Upon removal the coils will retain their spiral shape.



FIG. 125.—Catgut in glass tubes.

“In any case, when catgut is to be heated to a temperature over about 200°

F. in any of the above-mentioned or similar liquids, it must first be perfectly dried, otherwise the heat of the liquid will cause the moisture in the gut to be expelled in fine bubbles, and this will make it brittle and rotten.

“In preparing catgut for surgical use the principal object to be kept in view is to render and keep it absolutely sterile. This is accomplished either by macerating and preserving the gut in some efficient bactericidal and antiseptic liquid, or by subjecting it, while immersed in a suitable liquid, to a sufficiently high temperature, or by both methods combined.

“*The Removal of Fat.*—All catgut contains a certain amount of fat. Although fat may be rendered sterile while in the gut, it is nevertheless preferable to remove it as far as possible, since it is practically a foreign body, and may retain germs which the antiseptic is unable to reach.

“The fat may for the most part be removed by macerating the gut for a number of days in ether (‘stronger ether’) or chloroform. If proper facilities are at hand, however, this may be accomplished within an hour by boiling the gut with enough ether to cover it completely. This is best done in a wide-mouthed Erlenmeyer flask, to which is fitted a well-cooled upright condenser, which causes the ascending vapor of the ether to be condensed and to flow back into the flask, thus preventing loss of ether. The heating should be done by steam, in a place remote from lights or fire. After an hour’s boiling the ether is allowed to cool a little, and is then poured off. It should not be used again without being redistilled.

“Since the gut, even though boiled in ether, still retains at least as much fat as the amount of ether in the interior of the gut can hold in solution, it is best to boil it again in absolute alcohol (completely covered thereby) for one hour. It is preferable always to use absolute alcohol, though the ordinary official alcohol (ninety-four per cent by volume) may be used if the other is not at hand. Should the percentage strength of the official alcohol fall materially below ninety-four, there is danger of causing the gut to soften, gelatinize, snarl, and become rotten.

“*Sterilization and Preservation of Catgut by a Solution of Biniodide of Mercury in Chloroform.*—After the catgut has been deprived of fat in the manner stated it is at once transferred to ‘chloroform with biniodide’ (a saturated solution of the latter in the former, of the strength of about 1 to 1,000) which completely penetrates it and renders it sterile. It is kept in this liquid in vessels provided with well-fitting glass stoppers until required for use.

“*Sterilization of Catgut by heating it with Alcohol, preferably under Pressure.*—Some surgeons prefer catgut that has been sterilized by alcohol and heat alone. Since alcohol, at the ordinary pressure of the atmosphere, boils at about 176° F., this temperature is not always sufficiently high to destroy the vitality of certain germs. Hence it is preferable to apply the heat in such a manner that the vapor of the alcohol will be under pressure. For most purposes the pressure will be high enough if the vessel is surrounded with steam or boiling water. If possible, however, a temperature of 120° C. (248° F.) should be aimed at, and this may easily be reached by exposing the vessel to moist steam under pressure in a suitable apparatus.

“When such an apparatus is not available, the following method will suffice in most cases: Roll each string of catgut into a coil of such a diameter that a number of them will readily go into a so-called one-ounce glycerin jelly jar. If the gut is stiff, it is best to tie each coil in two places with fine aluminum wire. Fill as many jars as may be convenient, and, having inserted an extra well-fitting rubber washer into each lid, and having poured into each jar enough absolute alcohol to fill it completely, screw on the lids as tightly as possible, and place the jars inside of a museum jar (Whitall, Tatum & Co.'s) which had previously been tested and found to stand the intended pressure. Pour into the museum jar enough alcohol to cause the jelly jars to stand in about two inches of liquid, and then screw on the lid of the museum jar, having first interposed a rather thick soft-rubber washer. Tie a stout cloth around the jar, so that if it should burst through excessive pressure the fragments may do as little damage as possible. Now expose the jar in a suitable chamber or apparatus—first, to a very gentle current of steam, to heat it gradually, and afterward to a stronger current, so as to have it constantly surrounded by steam, and keep it thus for about five hours. If steam is not available for this purpose, the jar may be immersed (weighted down, if necessary) in water in a capacious vessel, the water gradually brought to a boil, and maintained thus during the required time. When the jar is removed from the steam or boiling water it should be allowed to cool *gradually* and *spontaneously*.

“If upon removal of the museum jar it is seen that there remains at least a part of the alcohol surrounding the jelly jars, and if each of the latter still contains the whole or at least part of the absolute alcohol which had been poured in, this is adequate proof that the tension of the vapor inside of the apparatus during the whole time has been sufficiently high. If, however, the whole of the alcohol in the bottom of the museum jar, and, in addition, the larger portion or all of the absolute alcohol in the jelly jars should have disappeared, this indicates that there was a leak, and that, consequently, the pressure was not high enough. The operation must then be repeated under stricter precautions.

“Upon removal of the jelly jars from the outer jar they should be completely filled with hot absolute alcohol, securely closed again, and kept immersed in alcohol in a tightly closed jar or other vessel until required for use. Only so many coils should be removed from a jar at a time as may be deemed necessary for an operation. If any be left over, they should not be put back into the jar, but put on one side and re-sterilized with the next batch.

“*Sterilization of Catgut by being Heated in some Fatty Liquid at a Temperature of about 135° C. (275° F.).*—In order to insure still more perfectly the sterilization of catgut, the following method, based upon suggestions made by Dr. William E. Studdiford, has gradually been elaborated at Bellevue Hospital:

“Catgut of the various sizes, having first been boiled in ether and absolute alcohol, and having then been kept immersed for some time in ‘chloroform with biniodide,’ is wound on wooden bobbins. Each bobbin

contains from three to five strings, according to the thickness of the gut, and the ends are securely fastened at each end of the bobbin. The bobbins (which must previously have undergone the following treatment by themselves alone) are then put into vessels containing albolene, and heat is applied to these vessels by means of a bath of petrolatum. The temperature of the latter is run up until that of the albolene reaches 275° F., where it is maintained by properly regulating the heat during at least fifteen minutes. The temperature is then allowed slowly to fall until the bobbins can be transferred again to 'chloroform with biniodide.'

"*Chromicized Catgut*.—The method used for preparing this kind of catgut is, in all its essential features, that recommended by Dr. George M. Edebohls. It is as follows:

"Rough catgut (see above), of the proper size, chiefly Nos. 0 and 00, is first deprived of fat by being boiled with ether. It is then wound upon bobbins of wood, as many strings being tied together as each bobbin will hold, the ends being secured in notches made in the bobbins. The latter are then weighted down by sinkers and completely immersed into a sufficient quantity of a solution prepared after the following formula:

Potassium bichromate.....	22½ grains.
Water.....	15 ounces.

Dissolve, and then add

Glycerin.....	2½ drachms.
Carbolic acid.....	2½ "

"In this solution the bobbins are allowed to remain during thirty hours. They are then removed and the catgut at once wound upon frames of wood three feet long, with notches a quarter of an inch apart at each end, in such a way that the gut is stretched, rather tight, up and down one face of the board in parallel rows. It is now allowed to become completely dry at a temperature not exceeding 45° C. (113° F.), which will require a few days.

"When it is completely dry the gut is removed in pieces of the length of the board (three feet), and the pieces are rolled into coils small enough to go into one-ounce glycerin jelly jars, each coil being secured, if necessary, by two pieces of fine aluminum wire. It is finally sterilized by means of alcohol under pressure, as described above.

"If it be found, for any purpose, too permanent, the time of maceration in the bichromate solution may be shortened in proportion.

"This chromicized catgut is now also sterilized by the albolene method mentioned in the preceding paragraph."

The following simple plan of sterilization is quoted: "Put into a jar a pint of absolute alcohol and the catgut; cover the jar tightly with a lid, on which may be placed an ice bag to hasten condensation of the vapor coming from the boiling alcohol. If the alcohol evaporate and leave the gut exposed, or the temperature long exceed 200° F., the catgut is rendered useless by the fallacies of the method itself."

Ligatures when prepared are put up in small wide-mouthed glass receptacles (Fig. 126), and can be utilized as desired. Larger receptacles for hospital and office use are convenient and efficient (Fig. 127). *Halsted* practices

the following simple and efficient method of sterilizing and preserving ligatures and sutures: The material is wound on small glass reels, and these are put into a screw-topped small glass jar containing alcohol. The cover of the small glass jar is loosely screwed down upon its rubber washer, and then this jar is put into a still larger one, three quarters filled with alcohol, attached to the condenser, and after an hour's boiling the small jar is removed, the cover tightly screwed down, and the ligatures and sutures not disturbed until needed for use. Then the bobbins can be removed one at a time as needed, and the material unwound by grasping the bobbin between the thumb and finger so as not to touch the gut.

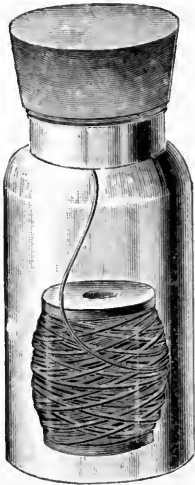

FIG. 126.—Wide-mouthed bottle for catgut.

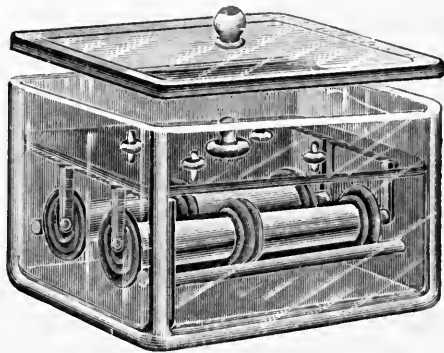


FIG. 127.—Ligature receptacle for office and hospital use.

Von Bergmann's Method of preparing Catgut is the following: Sterilize the glass disk in which the catgut is to be placed, by steam, for three quarters of an hour; wind the gut on the glass bobbins; cover with ether for twenty-four hours; pour off ether, and substitute the following solution:

Bichloride of mercury	10 parts.
Absolute alcohol.....	800 “
Distilled water.....	200 “

Change the last solution daily for two days and then substitute for it ordinary alcohol. If glycerin (20 per cent) be added, the gut is hardened.

König's Method.—Place the catgut in the form of rings in the dry hot air of an oven or sand bath at a temperature of 158° F. for two hours; then heat in cumol to a temperature of 329° F. for an hour, and finally transfer to and preserve in petroleum benzine. Clark and Miller have modified König's method as follows: “1. The catgut, twelve strands, is rolled in a figure-of-eight form, so that it can be slipped into a large test tube. 2. Bring the catgut up to a temperature of 176° F., and hold it at this point for one hour. 3. Place in cumol, which must not be above 212° F., raise it to 329° F., and hold it at this point for one hour. 4. Pour off the cumol, and either allow the heat of the sand bath to dry the catgut, or transfer it to a hot-air oven, at a temperature of 212° F., for two hours. 5. Transfer the

rings with sterile forceps to the test tubes previously sterilized, as in a laboratory. In drying or boiling, the catgut should not come in contact with the bottom or sides of the vessel, but should be suspended on slender wire supports or placed upon cotton loosely packed in the bottom of the beaker glass. Cumol, which is of a clear limpid or slightly yellowish appearance when procured from the chemist, is changed to a brownish color by boiling. The catgut is allowed to remain in the sand bath until the excess of cumol is driven off and it appears entirely free from any oily matter. A period of one to two hours is usually sufficient to dry it thoroughly. From the sand bath or hot-air oven it is transferred with sterile forceps to sterile test tubes, such as are used for culture media, in which it is preserved from contamination until ready for use. Small quantities should be placed in each tube, to obviate the necessity of opening them too frequently. In conclusion, it is well to bear in mind that while cumol is not explosive it is very inflammable, and great care should be observed in lifting the wire screen from the beaker glass to prevent drops of the cumol from falling in the flame or on the heated piece of metal on which the sand bath rests, as it will take fire, flare up, and ignite the fluid in the beaker glass. Such an accident has occurred three times in our experience."

Catgut thus prepared is used in St. Luke's Hospital of New York and in Johns Hopkins of Baltimore with complete satisfaction.

Preparation of Catgut at the New York Hospital.—"The raw gut is put in benzine for twenty-four hours to remove fat; it is then wiped dry, wound on glass spools, and boiled in sterile alcohol for an hour to an hour and a half, the time varying according to the size of the gut. After twenty-four hours the gut (still remaining in the alcohol) is boiled for half an hour to kill any spores which may remain, and is then ready for use. It is kept in sterile alcohol until used."

Dr. F. W. Murray, of the hospital, to whom the writer is indebted for the statement of the above method, adds: "This gut has been satisfactory. Frequent cultures show that it is sterile, but it breaks easier than the cumol preparation does."

The "Jefferson Method."—The method of preparation of catgut in the Jefferson Hospital is one of long trial, extended use, and is highly commended by Keen.

"First steep the gut, as received from the manufacturer, in the best ether; allow light gut to remain in it for not less than twenty-four hours; heavy gut for forty-eight hours. When it has been steeped a sufficient length of time in the ether transfer it directly into a mercuric-chloride mixture, consisting (proportionally) of forty grains of mercuric chloride and two hundred grains of tartaric acid in twelve ounces of ninety-five-per-cent alcohol. Very fine gut should not remain in the mercuric mixture longer than from five to seven minutes, the next size ten to fifteen minutes, and the third and fourth sizes from twenty to twenty-five minutes respectively. Before transferring the gut from the ether into the mercuric-chloride mixture, jars for keeping it ready for use should be at hand, thoroughly scalded, and then bathed in an aqueous solution of mercuric chloride (1 to 1,000).

When the jars are ready they should be nearly filled with alcohol (ninety-five per cent strength), containing palladium bichloride in the proportion of one sixteenth of a grain (two drops of a solution which contains fifteen grains of the salt to the ounce) to the pint of alcohol (more of the true bichloride of palladium will not stay in solution in alcohol, and when a precipitate occurs through excess of the palladium the whole goes to the bottom and is not soluble in alcohol). As the gut is lifted from the bichloride mixture it should be dropped into the prepared alcohol, and is then ready for use, and will keep, as far as is yet known, for any length of time."

At the present time the preparation of catgut and other surgical supplies of aseptic and antiseptic character are provided by manufacturers who devote skill and energy to the perfection of this class of products. Catgut, especially the chromicized, is prepared to endure a longer or shorter period of time—five, ten, and twenty days—as circumstances seem to require. However, many surgeons do now and will continue to place greater confidence in products of their own making than in those which are the outcome of enterprise and thrift.

Ligatures composed of *aortic* tissue, whalebone tissue, etc., have been mentioned for use in special purposes, but their fancied virtues have properly given to them only an ephemeral existence.

The Assistants.—The number of efficient assistants and the relation of things necessary to conduct an operation with ease is modified by its character.

To *one* must be intrusted the administration of the anæsthetic, watching the pulse, respiration, and circulation of the patient. By combining these duties the anæsthetist becomes the immediate observer of the effects of the drug, and he must be prepared to carry into execution the various expedients that are recommended for the ordinary complications attending anæsthesia. If the temporal and radial pulsations be compared before the administration, the assistant will be able to judge thereafter of the latter from the character of the former. This assistant not only gives the anæsthetic, but, when necessary, pushes forward the lower jaw to prevent swallowing the tongue (Fig. 8), and, with the finger on the temporal artery and eye on the respiratory movement, he judges of the necessities of the case without any interruption. His undivided attention is demanded for this duty.

To a *second* should be assigned the care of the instruments; he hands them to the surgeon when asked for, and returns them to a place of aseptic safety after being used.

To a *third* may be intrusted the care of the sponges and wipers; he must see to it that a suitable number of each is prepared and placed at the convenience of the operator.

To a *fourth* the care of the ligatures may be given, together with the sponging or wiping of the wound, ligaturing vessels, and otherwise assisting, as best suits the circumstances of the case or the desire of the operator.

In operations of invasion of deep cavities, more especially the abdominal, an exact and verified count of the agents—gauze-pads, sponges, forc-

pressure, etc., etc.—to be employed in the operation should be made and recorded. To a responsible party, not otherwise engrossed, should be given in charge the accounting for the agents thus employed, avoiding thereby the retention within the cavity of a missing agent. The operator should not assume this task, for in the multiplicity of detail and complications that are so often present in these cases he is unfitted for the responsibility.

The security of the bleeding points and the necessary sponging are often done by the operating surgeon; however, these are matters which will become self-regulating as the operation progresses. While a greater number than four assistants can be easily utilized in many operations, still it is wise to recognize the fact that any unnecessary display or expenditure on these occasions should be sedulously avoided. If the surgeon is not able to avail himself of a suitable number of assistants, he must then draw upon his own resources. This is accomplished by placing the sponges, wipers, and instruments where they can be conveniently reached; then the surgeon can sponge, secure, and tie the vessels. If the circumstances demand it, he can at the same time regulate the administration of the anæsthetic, by observation of the proper reflexes and sounds of the patient, the color of the blood, respiratory movements, etc. The utilization of the services of an educated nurse will relieve the stress in such instances.

The Patient should be prepared for the operation. The physical, legal, and spiritual aspects of preparation have been heretofore considered under various headings, consequently little remains to be said other than to properly cleanse the part to be operated upon.

The Antiseptic Method.—In the antiseptic method everything employed in connection with the preparation for operation, the operative procedure, and the dressing of the wound is sterilized by germicidal substances (page 60 *et seq.*).

The Aseptic Method.—In the aseptic method no antiseptic substances are employed during the operation or the dressing of the wound, except to such factors of the procedure as can not be properly sterilized by heat.

Therefore the field of operation, the hands of the operator and of the assistants, and the catgut, and perhaps the drainage agent, are antiseptically prepared in both methods. In the aseptic method, sterilized water, sterilized saline solutions, sterilized wipers and dressings, prepared by dry or moist heat, are exclusively used.

The advantages of the aseptic method are substantial: It is applicable to all parts of the body; the wounds heal quicker; the skin is not irritated, and toxic dangers are absent. Inasmuch as aseptic and antiseptic technique have each a common object in view—the establishment of an aseptic wound—and since both include a series of means of attainment of this object which will be applied practically as fitted to the operative measures that follow, no extended individual consideration will be given to either under its proper name.

The method of preparation of the field of operation depends entirely on its location and condition. If the field have an epidermal area, it should be thoroughly soaped and moderately scrubbed with a stiff aseptic brush and

shaved closely the day before the operation. A thin layer of green soap may then be applied over the area and confined in place until morning. After the removal of the soap the part is rubbed with a cloth or scrubbed again with a soft brush, all loosened cuticle removed, and the area rinsed with boiled water and covered with aseptic cloths saturated with a five-per cent solution of carbolic acid, which are allowed to remain until the patient is on the operating table and well under the influence of the anæsthetic. The cloths are then removed, and the surface is again rubbed with the cleansed hand or glove with suitable soap, rinsed with hot boiled water, followed with a free flushing of the surface with alcohol, ether, or an ethereal solution of iodoform.

If the cuticle of the patient be sensitive, castile, and even milder soap than this, can be applied.

Mucous surfaces can not be treated thus, for obvious reasons. However, they can be scrubbed with a soft aseptic brush and soap, rinsed with antiseptic solutions, wiped dry, and covered with dry antiseptic gauze some time before an operative procedure, and finally cleansed again at the time of operation. These directions apply, of course, to the easily accessible mucous-lined cavities, like the mouth, rectum, and vagina. The deep, narrow ones, as the urethra and those of the nose, can be thoroughly flushed with antiseptic fluids, which is all that can be practically done. The use of bichloride solutions should be avoided in those situations.

If the part to be operated upon be already septic, then, indeed, great care and patience will be essential to prepare it so as to avoid further infection, and for the procurement of prompt non-suppurative repair. Only patient and untiring scrutiny will enable the surgeon to remove all foreign matter, septic agents, and devitalized tissue from the wound, and to cleanse it so thoroughly thereafter as to eliminate the possibility of a remaining infection.

The peroxide of hydrogen is especially indicated for use in septic cases. As every recess of the wound must be cleansed, this fluid plays an important and interesting part by reason of the effervescent properties which dislodge and bring to the surface objectionable matters.

After thorough efforts at cleansing, this class of wounds should be well drained when of sufficient depth to require it, and it may be necessary to pack them lightly with iodoform gauze. The latter agent not only aseptizes the wound still further, but also absorbs the incidental fluids as well.

The preparations for operation relating to the patient, operating table, surgeon, etc., etc., are stated briefly on page 113.

General Remarks.—A thorough warm bath of the entire body of the patient should precede an operation when practicable. The rapid growth of hair in many instances and situations requires that the surface be shaven just before rather than the day preceding operation, in order to secure the greatest degree of cleanliness. Too harsh scrubbing of the skin serves rather to dislodge and free the germs of that tissue than to eliminate them from the field of infectivity. The first scrubbing should be from three to five minutes' duration, the second and third somewhat less.

CHAPTER III.

THE TREATMENT OF OPERATION-WOUNDS.

It is necessary to have the materials and agents for the proper treatment of operation-wounds, together with a knowledge of their use.

As soon as the operation is completed the wound should be wiped dry with a soft aseptic sponge or wiper, care being taken to remove all tissue shreds and blood clots. If oozing of blood be present, brief firm pressure with a dry wiper may check the flow; if not thus arrested, the wound can then be douched with hot sterilized water, and pressure again applied. Application to the surface of the strong solution of carbolic acid (page 48) may suffice for the purpose. If, despite these measures, oozing continues, a sponge or wiper saturated with hot water should be pushed firmly into the wound and allowed to remain while the integumentary sutures are being laid. However, before tightening the sutures the agent should be carefully removed and further bleeding watched for. If the flow do not yield to these simple measures, and time be an important element in the case, then a fine catgut

ligature should be passed through the tissue around the bleeding area, the same as for closure of a vessel *en masse* (Fig. 128), and tightened sufficiently to arrest the flow; or dry gauze may be introduced in narrow strips and permitted to hang from the lower end of the cut until the superimposed sutures are tied, when the gauze is carefully withdrawn, and the deep wound surfaces pressed firmly together by proper bandaging, or by deep sutures carried so as to control the bleeding surface. The ability to properly arrest the loss of blood by simple measures is largely a matter of experience, and under

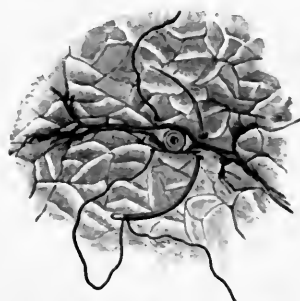


FIG. 128.—Closure *en masse*.

no circumstances should a wound be finally closed until hæmorrhage is arrested. Instead of closing the wound, it should be packed with gauze, and the sutures placed; the wound is finally closed after arrest of hæmorrhage and removal of the gauze.

The proper securing of the divided tissues and the dressing of the wound contemplate three important considerations: 1, A retentive coaptation of the surfaces of the wound; 2, Perfect drainage, or the absence of its necessity; 3, The application of a suitable protective dressing.

The retentive coaptation of the surfaces of a wound is necessary for prompt healing, and both the superficial and deep structures are of impor-

tance in this respect. Of the two, it is more important for the safety and prompt recovery of the patient that the deep tissues be properly apposed, since if this be not done a cavity remains in which blood or pus may collect. It happens not infrequently that the superficial tissues unite promptly and well, while the deep ones fail, and from lack of coaptation of the surfaces form "dead spaces," which often imperil and even destroy the prospects of prompt recovery by harboring unwelcome products which cause abscess or sinus formations, and thus lead to a tedious and protracted recovery. If union by first intention be a desideratum, the wound surfaces must be kept in perfect coaptation. For this purpose numerous means are employed, such as sutures, bandages, compresses, adhesive strips, etc., supplemented by the salutary influences of rest and the proper placing of the wounded part.

The Sutures are classified with reference to their nature, situation, and form.

Sutures are of organic and inorganic nature. The organic are most often employed. Catgut, silk (page 71 *et seq.* and Intestine, Vol. II), kangaroo tendon, silkworm-gut, and horse-hair belong to this class, and when rendered aseptic they are in common use in connection with various surgical procedures.

The catgut suture is readily absorbable, and often this peculiarly unsuits it for use in cases where delay in this respect is requisite. However, the greater durability of chromicized gut will meet unusual requirements by exercising a restraining influence for ten or more days, according to the method of preparation, while scarcely more than five to ten days can be expected of the simpler varieties of gut. Practically speaking, silk and silkworm-gut are non-absorbable, since the former disappears long after the term of usefulness has expired, and the period of durability of the latter is as yet undetermined.

Kangaroo Tendon.—Kangaroo tendon is a more recent product than catgut, and is not much employed except in those cases in which great durability is required, as the union of bone in fracture of the patella, Bassini's method for radical cure of hernia, etc. It and silkworm-gut can be sterilized in a manner similar to that of catgut. They are offered for sale in long glass tubes hermetically sealed (Fig. 129). There is much that is comparatively worthless in the market.

Silkworm-gut.—Silkworm-gut is rapidly superseding silk for the sewing of cutaneous wounds. The small size, smooth surface, impervious structure, durability, firm grip, ease of sterilization, and the comparatively little danger of infection, render this material an admirable agent in connection with superficial wound treatment. When employed in any situation, the extremities should be cut off as short as is consistent with the safety of the knot, else they will scratch the contiguous tissues and surfaces, and cling firmly to the apposed



FIG. 129.
Kangaroo
tendon in
glass tube.

dressings. The cutting tendency of this material forbids that traction be exercised to any degree in closing wounds, as it quickly cuts through the soft parts when thus employed. It should not be used subcutaneously. It can be sterilized by boiling and then kept in glass tubes (Fig. 129) in alcohol, and is made sufficiently aseptic if immersed with the instruments employed in an operation.

Horsehair.—Horsehair is an old and reliable agent for the closure of superficial integumentary wounds of a simple nature. It should be selected with care from the back and upper part of the tail, to avoid the contamination from discharges, carefully washed with soap and water, boiled for an hour in strong alcohol, and then it is ready for use. It can be stored in glass bottles filled with pure alcohol. Mayo favors this agent.

*Celluloid Thread** is strong, flexible, ties with a firm knot, and can be sterilized without impairment. Its unyielding hardness in the tissues is an objectionable feature.

The Inorganic or Metallic Sutures.—The metallic sutures in common use are of silver and iron wire.

Silver Wire.—Silver wire is the better. It varies in size and strength, and can therefore be employed under divers circumstances. It is unirritating and strong, and consequently is used to unite large and gaping wounds in which much traction is required; suturing of the patella, and in all operations in which approximation by means of deep through-and-through suturing is required. Silver wire can be easily sterilized with the instruments by boiling in the soda solution, and kept for use in a special tube (Fig. 130).

Sutures may be classed into the deep and superficial varieties.

Deep sutures are those that are carried deeply through the tissues from the external surface of the part, for the purpose of closing the dead spaces within, or to properly support and retain in position flaps of large size and those that exercise undue traction.


The Uniting of Divided Tissues.—The accomplishment of the union of tissues requires that sutures be properly placed. *Needles* of various shapes, sizes, and penetrating powers are employed for this purpose. Some needles are straight, others are curved (Fig. 131); some have round-pointed extremities, like the housewife's needle; others have cutting edges at the extremity; others again are formed for special purposes and the sewing of special tissues. Needles with sharp points and round extremities separate the tissues as they pass, make a small opening, and thus provide a firm bed for the ligature and cause a minimum degree of hæmorrhage. These needles are used with comparative difficulty.

Needles with cutting extremities parallel with the wound sever the tissues and form large gaping punctures (Fig. 132, *c, d*) which are less secure and



FIG. 130.
Special tube
for assorted
sizes of
silver wire.

more liable to bleed than those made by needles with round points and then passed at right angles with the sides (Fig. 132, *a, b*). Those with sharp points and round extremities are adapted to the sewing of serous surfaces,



the others to integumentary. Curved needles are used in cavities and depressed tissues; straight, on plain surfaces.

Needle Forceps or Holders.—While in many instances a needle can be readily introduced without the aid of a holder, still the accuracy and steadiness of the passage, and preservation of the integrity of the fingers of the surgeon, demand the use of the holder on most occasions. Various useful needle-holders are now in the market, among which Figs. 133 and 134 are employed for light sewing. For heavy work, Figs. 135 and 136 illustrate the forceps, both of which are convenient and durable.

The closure of a wound relates to its deep and superficial parts. If the deep portion be not closed first, the fact that such closure can be readily done by pressure or other suitable means should be demonstrated before the superficial parts are united. Whenever the outlines of the superficial wound will permit, they should be made tense before sewing, by traction made in the long axis by means of the fingers of an assistant, or hooks selected for the purpose (Fig. 137). This maneuver contributes much to the rapidity and symmetry of placing the sutures.

The sutures should be introduced as near the free edge of the wound as is compatible with the security of union. The depth of the passing, the distance between the sutures, and from the edges of the wound, are regulated by the depth, degree of tension of the wound, its location, and the nature of the material employed for suturing. From a quarter of an inch to a line from the border is a fair estimate of the distance at which sutures

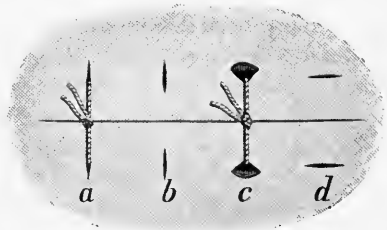


FIG. 132.—Needle wounds.

may be properly introduced in most wounds. If too near, they quickly cut through; if too far away, the borders overlap or turn in, and thus cause imperfect, delayed, and distorted union. Sutures must not be drawn too tight (Fig. 138), for the tissues thus grasped will be strangulated, and the borders of



FIG. 133.—Hartley-Markoe needle-holder.

FIG. 134.—Sand's needle-holder.

FIG. 135.—Luer's needle-holder.

FIG. 136.—Halsted-Leui needle-holder.

the wound will draw apart, causing delayed union and disfigurement. If the integument within the grasp of a suture remain white after the suture is tightened, the suture must be loosened before the final dressing is completed, or otherwise the pallid tissue will slough, and obvious results will follow.

The length of time that sutures should re-

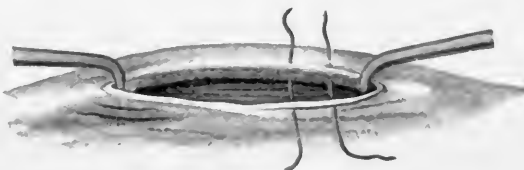


FIG. 137.—Tension while sewing.

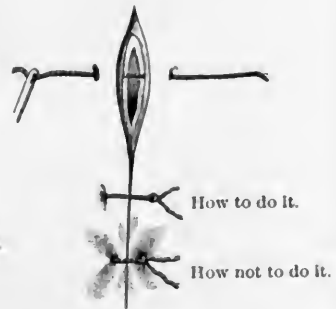


FIG. 138.
Tension of sutures.

main *in situ* is governed by the liability to ulceration and disfigurement that they may cause, the gaping of the wound, and the nature of the suture material. In exposed parts of the body sutures should be removed before

marked irritation is observed, to avoid disfigurement. In such cases additional means of support can be employed, such as adhesive strips, renewed suturing, collodion, etc. The adhesive strips should be made as nearly antiseptic as practicable by immersing them in a hot solution of corrosive sublimate (1 to 500) just before they are applied.

The Management of Dead Spaces.—Dead spaces are vacant cavities existing between wounded tissues, the result of removal of connected portions, or of the separation of these tissues. Dead spaces may be occluded by the approximation of their boundaries through the agency of the buried or the deep through-and-through sutures, firm bandaging, or the organization of the blood clots that may form in them. The objections to the buried (page 104), and the advantages of the through-and-through sutures are quite evident. The repair of these spaces by aid of blood clot can be accomplished only in the presence of complete asepsis. The infection of a clot thus retained in the tissues will be quickly followed by abscess formation, and perhaps by general constitutional infection, to say nothing of the certain defeat of local repair. This plan of action is best adapted to the restoration of gaping wounds of the soft parts, or a loss of substance of the hard. The technique of the method in the latter instance will be considered in connection with operative procedures calling especially for its employment (page 450).

Secondary suturing is directed to the unirritated areas contiguous to a wound, for the purpose of lessening or removing the strain on the primary sutures, and retaining the parts in proper position until final healing takes place, also to the closure of wounds with granulating surfaces. The special cautions regarding suturing, and the proper use of special forms of suture, will be considered later on under the headings requiring their use.

The Different Forms of Sutures.—The interrupted, continuous, quilled, twisted or harelip, button, relaxation and coaptation, and three-cornered wound sutures, are the forms employed for the common purposes of suturing. Buried and subcuticular are modifications of the use of these. Other forms will be described with the operations calling for them.

The interrupted suture has a greater general application than has any other form (Fig. 139). This suture is made by passing a needle armed with proper material through the integument and subcutaneous tissue of the borders of the wound at a distance of a line or more from them, depending on the size and depth of the wound and the retractile force of its tissues. The suture is then tied by a reef knot drawn with only sufficient force to appose the borders of the wound without puckering the skin. The knots can be placed at alternate sides of the wound or at one side only. The former is the better plan, since if the dressings cling to the knotted extremities of the sutures their incautious removal is less liable to disturb the line of union. If tension be present, alternating deeper sutures may be introduced. Superficial sutures to appose the borders can be introduced between deeper ones (Fig. 140). If silkworm-gut be employed, it should be tied, if practicable, only with the friction knot, for



FIG. 139.
Simple interrupted suture.

when thus united the ends of the suture lie close to the surface if cut short. In the removal of interrupted sutures, especially of wire, the suture should be so divided and grasped as to secure unobstructed withdrawal (Fig. 141).




FIG. 140.—Alternating deep and superficial sutures.

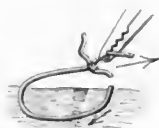

FIG. 141.
Removal of interrupted suture.



FIG. 142.
Continuous suture.

Silver wire is introduced the same as silk or by a needle armed with a loop of silk cord to draw the wire suture into position. The sutures are then twisted into place.

The *continuous suture*, sometimes called the *glover's* (Fig. 142), is employed to unite superficial wounds and such others as require but little force to cause a proper adjustment of the divided surfaces. It is made by repeatedly passing the needle through the tissues without cutting the thread, and, after fitting the sutures to the wound strain, completing the union and confining the end of the thread by means of a final suture formed by uniting the ends caused by division close to



FIG. 143.—Tying continuous suture.

the eye of the needle, with the end of the suture remaining at the opposite side of the wound (Fig. 143). The continuity makes this one less reliable than the interrupted sutures.

The Quilled Suture.—The quilled suture is made by passing several doubled threads through the lips of the wound, half an inch or so apart, and uniting them over quills, wood, etc., as the latter lie parallel with the cut (Fig. 144). This suture is used in vaginal and perineal sewing, and when the closure of deep, gaping wounds is required.




FIG. 144.—Quilled suture.

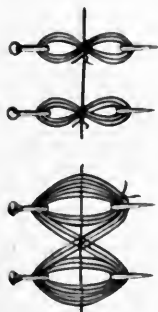


FIG. 145.
Harelip suture.

The Pin, Twisted, or Harelip Suture.—The twisted or harelip suture (Fig. 145) is made by pushing a pin through the

edges of the wound and passing aseptic cotton yarn, narrow strips of anti-septic gauze, or other suitable material, around the pin in a continuous or

interrupted figure-of-eight form, confining it in position, and at the same time opposing the divided surfaces of the wound. The yarn should be changed repeatedly, so as to prevent undue soiling. If the yarn be drawn too tight, rapid ulceration around the pins is liable to occur, and result in pinhole disfigurement unless the traction be promptly released. The twisted suture (Fig. 146) is of great use in closing deep wounds, in which case

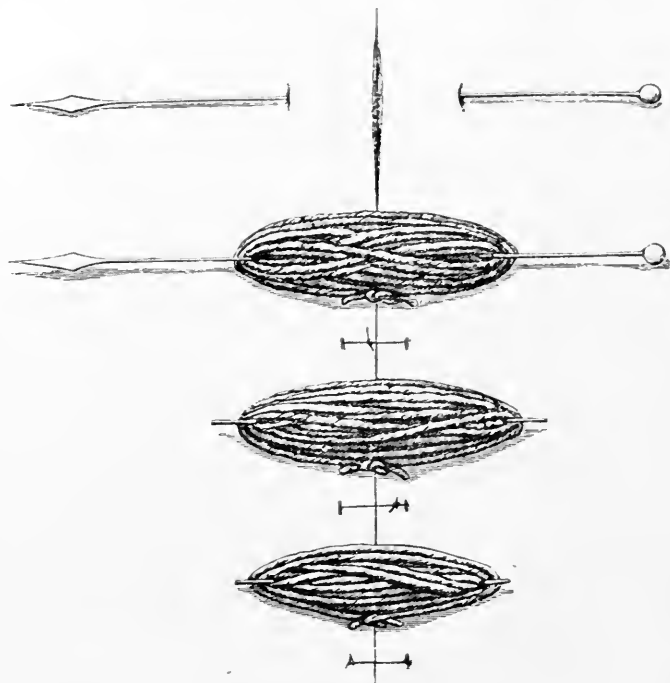


FIG. 146.—Twisted suture.

needles of large size, and even skewers, may be thrust through the tissues. An ordinary pin or needle can be employed, although those that are specially constructed for the purpose are preferable (Fig. 147). If spear-pointed, they may be pushed through the tissues unaided, or Post's or Buck's pin carrier (page 76) can be used as a guide for their introduction. Pins with adjustable sharp points are frequently used. At all events, the points should be removed as near to their exit as is consistent with the security of the suture; the intervening spaces are closed with superficial interrupted sutures when necessary.

The Button Suture (Fig. 148).—The button, like the quilled suture, is employed to approximate the deep portions of a wound, thereby relaxing its borders and thus permitting them to be united with simple sutures which are not exposed to traction.

The Buried Suture.—Buried sutures are introduced into wounds cut short, and closed in by superficial sutures. Catgut, kangaroo tendon, and silk are employed to occlude dead spaces, silkworm-gut and metallic su-

tures being objectionable. *Buried sutures* are employed within the wound to eradicate dead spaces and to suitably bring in contact with each other

the several layers of tissue that compose its walls. The employment of buried sutures introduces into the wound a greater or less amount of constricting foreign material, which may become the source of infection. For this reason the practice of introducing the buried sutures has not as yet taken so strong a hold on the profession as their worth suggests. The element of uncertainty connected with their employment will limit it to expert hands sustained by undoubted resources for some time to come.

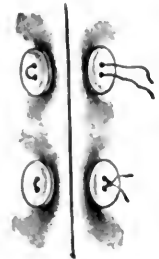



FIG. 148.
Button suture.



Harelip pins.

Post's pin-carrier.

Adjustable pointed pin.

FIG. 147.

The Subcuticular Suture.—Halsted recommends the subcuticular suture to avoid the infecting influence of the skin coccus incident to passing the stitch through the integument. The needle is introduced at the under surface of the skin at one side and passed out just beneath

the cut edge; it is then passed in the reverse direction at the opposite side and tied (Fig. 1331, Vol. II). Fine catgut, silk, or wire are used in this instance.

The Relaxation and Coaptation Suture (Figs. 149, 150).—As the name indicates, this suture is a double one and meets dual indications. It not only approximates the deep tissues in its grasp (mattress stitch, *a*), and relaxes the superficial (relaxation suture), but is employed also to unite the relaxed borders (continuous stitch, *b*) of the wound (coaptation suture).

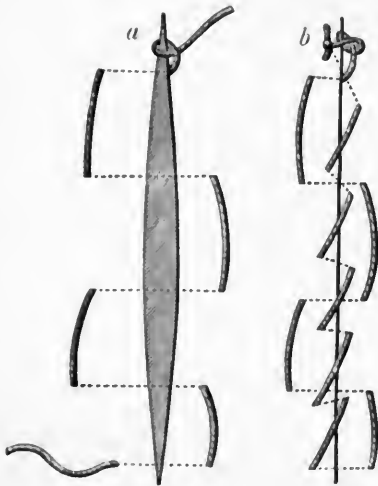


FIG. 149.

FIG. 150.

The relaxation and coaptation suture.

The three-cornered wound sutures and their uses are explained at once by the illustrations of their application (Figs. 151, 152).

Drainage.—Proper drainage is not only of great importance in securing successful union of divided surfaces, but it is also necessary for the safety of the patient. Good drainage is as potent

a factor of cleanliness in a wound as is good drainage of a dwelling to the healthfulness of its occupants. No one local condition peculiar to an operation will interfere so materially with the process of healing, or expose the

patient to greater constitutional danger, than the collection and decomposition in the wound of fluids.

When the surfaces of a wound can be brought together and maintained so as to obliterate permanently the wound cavity and dead spaces, no drainage is needed. But since the means of deep-tissue coaptation are often imperfectly applied and maintained, and dead spaces escape notice, and fluid collections not infrequently occur, it is wise to provide for drainage during the first forty-eight hours succeeding an operative procedure of any magnitude. The possible presence in a wound of bruised, diseased, or infected tissue, of persistent bloody or serous oozing, also demands the establishment of drainage.

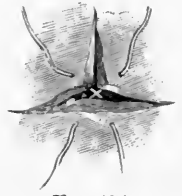

FIG. 151.

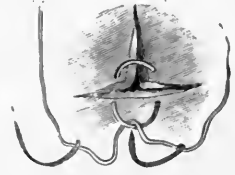


FIG. 152.

Three-cornered wound sutures.

Drainage may be secured through dependent incisions in the flaps, or, better still, by introduction into the wound of an aseptic drainage agent. An ordinary piece of aseptic rubber tubing (Fig. 153) about a fourth of an inch in diameter, with holes through the sides at irregular intervals, may be inserted through the most dependent portion to the bottom of the wound cavity; another can be introduced to the top of the cavity through the upper-



FIG. 153.—Rubber drainage tube, thread fastening.

most angle of the wound. The size of the tube is regulated by the size of the wound and the necessity of providing for free and copious discharge. Tubes too small rather than too large are often employed. It may be better to introduce two short tubes, one above and the other below, than one through-and-through long one, because the use of the latter introduces into the wound a superfluous amount of foreign material which does not meet an indication commensurate with the disturbance caused by its presence. With this plan of drainage the wound can be flushed through one tube, while the other permits a free escape of the fluid. Rubber drainage tubes of assorted sizes are stored in antiseptic fluid contained in long glass receptacles of similar shape but larger than those for kangaroo tendon. When thus cared for they are ready for immediate use.

Drainage tubes should be fastened securely in position, so that they can not slip into the wound. If a tube be missed and can not be found in the dressings, it should be sought for in the wound itself. Tubes are fastened

in position by a thread or catgut passed through the projecting extremities and tied around or fastened to the limb (Fig. 153), or, better yet, by the insertion of a safety-pin at the same situation. The pin should be inserted into the tube in such a manner as to lie smoothly on the surface and not interfere with drainage. To meet these desires, the pin should pierce the side of the tube parallel with the surface of the wound (Fig. 154), rather

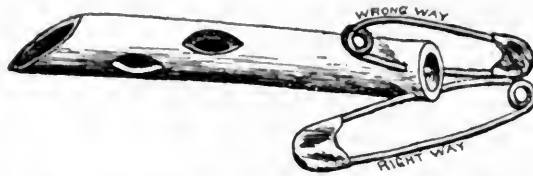


FIG. 154.—Rubber drainage tube, pin fastening.

than any portion of its open extremity. If catgut or aseptic thread be used to hold a tube in position, it should be loosely tied around the limb, to avoid the constriction that may follow

swelling of the soft parts. The open extremities of the tubes should be cut off flush with the soft parts as nearly as possible. Agents of wound drainage should be removed promptly, because if allowed to remain too long they provoke a discharge, and their retention may serve only for the removal of self-infected products.

A drainage tube can be pushed into position directly; it is better if the introduction is aided by means of a director or probe inserted within it, either as a propelling agent or a guide. It may be pushed or drawn into place by the ordinary thumb forceps; the latter agent is the better if the wound be open. Strips of iodoform (Fig. 155) or other gauze can be used for drainage purposes.



FIG. 155.
Iodoform
gauze drain-
age strips.

The *decalcified tubes* of Neuber are not accessible enough to rival the rubber ones; moreover, they not infrequently become absorbed before the wound is sufficiently healed to properly dispense with the use of drainage. *Several strands of antiseptic catgut* (Fig. 156), *horsehair*, or *silkworm-gut*, can be introduced loosely and retained in the wound when limited discharge is anticipated; they drain quite satisfactorily, and the first is readily absorbed or can be easily removed, as desired. Care should be exercised in the introduction into a deep wound of the bent ends of silkworm-gut, as its springy nature will cause it to disappear into the wound cavity, and, too, the withdrawal while sprung apart will destroy the repair along the course of removal. *Chicken bones* decalcified by a weak solution of hydrochloric acid may be utilized, and, while they are suitable for drainage, still they are too hard to be absorbed, and consequently do not add materially to the surgeon's equipment.



FIG. 156.
Catgut
drainage.

Special methods of drainage will be described in connection with the operations to which they are adapted.

Canalization.—Canalization is a term applied by Neuber to a method of establishing drainage without the use of tubes. *Shallow* and *deep canalization* comprise its varieties. *Shallow canalization* is the drainage of a shallow subcutaneous cavity by oval-shaped punctures a fourth of an inch or so in width, made through the integumentary flap at the most dependent portion of the wound. These punctures vary in number and situation to meet the demands of the case, and are formed by a punch constructed not unlike the leather punch; in fact, the latter may be employed as a suitable substitute. *Deep canalization* may be directed to the drainage of deep-wound cavities, which, when united by granulation, produce an objectionable amount of cicatricial tissue. The integument at either border of the wound is loosened outward from its deep connections to an extent sufficient to permit the borders to be easily drawn or slid into apposition with each other and carried to the bottom of the wound cavity, to which they are connected by sutures. The surface then appears concave or troughlike, and is formed by the depressed integument, which should be caused to unite with the walls and floor of the cavity by first intention. Although this method of cure is not in common use, it is nevertheless of much utility in the treatment of bony defects, comprehending assured long delay, and followed by sensitive and objectionable deformities (page 358 *et seq.*).

The Protective Dressing.—Various kinds of protective dressings are employed, usually now of a simpler character than formerly, because the attainment of asepsis can be achieved with less variety of dressing than usually attends the antiseptic method. Simple aseptic gauze and medicated gauze of various kinds form the basis of the protective dressings of the day. Sometimes oiled silk, rubber tissue, rubber dam, etc., are used to supplement textile fabric agents in attaining special ends. However, as impervious agents prevent proper surface evaporation, causing the dressings to become warm and moist, and maceration of the epidermis—conditions that encourage the development of germs rather than inhibit them, as is characteristic of dry dressings—these special agents enter no longer into common use, being employed only for the special purposes befitting their utility.

Oiled Silk is rarely, indeed, placed directly upon the skin when employed for protective purposes. Often rubber tissue cut into suitable strips is utilized in this manner, especially in skin grafting (page 576) and in Schede's method of healing (page 358). However, both of these substances not infrequently cover and are tucked around gauze fabric already applied to a wound for purposes of cleanliness and protection against external influences.

At the present time enterprising chemists are engaged in preparing for the general market all varieties of aseptic and antiseptic dressings, of which the various forms of gauze are the striking illustrations. There seems to be no doubt that reputable producers of these articles provide trustworthy products at a rate much more satisfactory in all respects than can be made by the individual consumer and with a great saving of time and annoyance to the latter. It is not to be forgotten that sophistication of all such products can be readily practised and with evident disastrous

results, and therefore consumers ought to exercise no inconsiderable vigilance in securing efficient articles.

Rubber Dam.—Rubber dam is more substantial than rubber tissue, and, like it, can be sterilized by soaking in a solution of carbolic acid or of bichloride of mercury. It, too, can be used over gauze dressings to keep them moistened when diffusion of the discharges through the dressings is anticipated or is desirable.

The Douching Apparatus (Figs. 157, 158).—The douching apparatus is easily made by siphoning the fluid from an established or improvised receptacle by means of a long, small rubber tube, at the end of which is attached a glass or rubber nozzle of suitable caliber to properly gauge the amount of fluid employed. The flow can be easily regulated by pinching the tube with the thumb and finger, or by a mechanical attachment constructed especially for this purpose. *An ordinary fountain syringe* is a durable, convenient, and satisfactory irrigator for most purposes. The douching of wounds during operation is rarely practiced now, except for the purpose of arresting hemorrhage or for the removal of infecting agents.

The Cotton Batting Dressing.—Sterilized cotton batting was much employed formerly in contact with the gauze dressings. However, it is entirely inadequate as an absorbent of wound discharges. The advent of absorbent, borated, salicylated, and other varieties of medicated cotton, abrogated the use of the former, except for purposes of warmth and comfort.

The Combined Dressing.—This form of dressing is made by placing several layers of borated or other variety of medicated cotton between two layers of antiseptic or aseptic gauze. The combined textures are then sterilized by heat and shaped to suit the circumstances of the case, and placed over the gauze already applied, and are then confined in position with aseptic bandages (Fig. 159).

In many respects the "combined" portion of the dressing of a wound is the most important of the textile fabric contributory to the purpose. The proper thickness, the suitable outline and the appropriate extent of this portion of dressing are matters of significant fact, as bearing on the comfort of the patient, the protection of the wound and the maintenance of accurate coaptation of its component parts. The application of this dressing, and the retention in place by means of bandages or binders or by adhesive strips, are matters of prime consequence in all respects. At the outset the dressing should be accurately and evenly applied and thus held while the retaining agent is similarly adjusted for the purposes of secure retention. A failure in either of these needs is quite certainly followed by physical discomfort and perhaps by surgical disappointment. The width of the retaining agent should be proportionate to the thickness of the dressing and the firmness of the required application. Unduly narrow bandages, etc., etc., are quite likely to become cord-like in action, causing insecurity and discomfort, only the wider ones being in all respects trustworthy. Whenever this dressing and superimposed fabrics become soiled from within, either prompt renewal, superficial antiseptics, with supplemental dressing, should be applied, as the opportunity affords.

Iodoform.—Iodoform alone and variously combined is largely employed in surgery. Iodoform, when dissolved in ether, can be readily poured or sprayed over the surface of the operation field, and the prompt evaporation of the ether will leave the iodoform evenly applied thereon. Only *pure* ether should be used for this purpose. If there is any

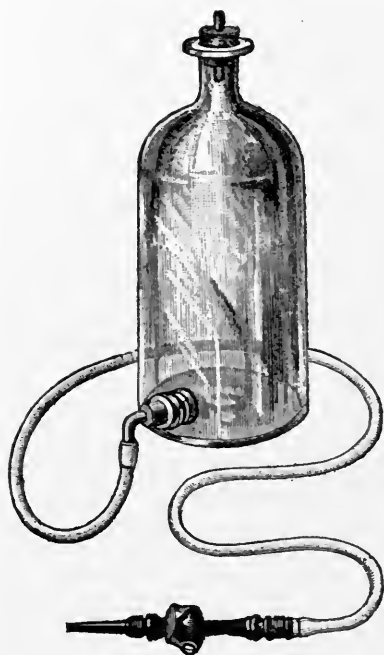


FIG. 157.—Douching bottle.



FIG. 158.—Extemporized douching bottle.

sign of the liberation of iodine by the appearance of an iodine tint, the ether was impure and the solution should not be used. *Pulverized iodo-*

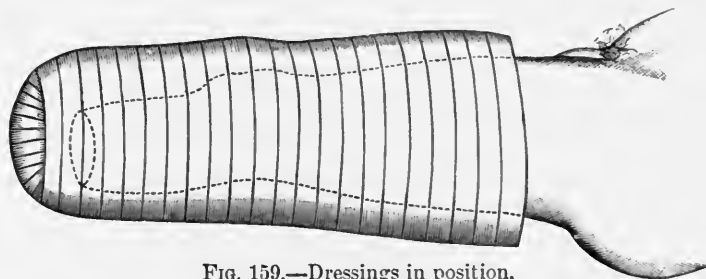


FIG. 159.—Dressings in position.

form can be well applied by the agency of a sprinkler or blower (Fig. 160) especially constructed for the purpose. The latter, however, is too fickle in its action for general use, and can be best employed for the introduction

of iodoform and other powders into deep cavities and sinuses. The amount of iodoform thus employed should be small and be evenly applied. The too common practice of dusting the suture line with iodoform, without special indication, is a needless waste of the drug and an unwise exposure to its poisonous effects.

Aristol, iodol, and naphthalin are sometimes employed as substitutes for iodoform, on account of the objections to the latter. They are not, however, as efficient as iodoform.

The Iodoform Gauze.—Iodoform gauze is now in general and established use. It has thus far withstood the economic assaults of the pharmacists and the ill-judged prejudice of the skeptics, and become a highly valued agent in advanced surgical technique. Iodoform gauze is prepared by two methods—one, the ready method, which consists in rubbing pulverized iodoform into the meshes of moistened sterilized gauze. This method produces the most useful article, because it obviates the decomposing influence of ether on the drug, and impairs less the capillarity of the textile fabric; but for commercial purposes and hospital uses it is prepared differently.

At Bellevue Hospital many kinds of dressings are used, and of various percentage strength. It is therefore impracticable to give all the formulas, but by giving typical ones, chosen from those most in use, the manner of preparation will be made sufficiently clear.

Dr. Charles Rice said: "It is proper to state at the outset that the percentage strength of antiseptic dressings, such as iodoform gauze, bichloride gauze, etc., should refer to the actual percentage by weight of the antiseptic agent contained in the fabric when made as dry as possible. It is not desirable completely to dry a prepared dressing which is to be wetted or dampened before it is used, as the wetting is likely to wash out some of the antiseptic.

"Many nurses and some manufacturers of dressings call a ten-per-cent fabric one that has been dipped in a ten-per-cent solution or mixture and then more or less wrung out. The rule should be to designate a medicated fabric by the percentage of active ingredient it contains when practically dry, and not by the percentage strength of the liquid with which it is impregnated.

"To prepare a ten-per-cent iodoform gauze, take, say, 50 parts by weight of gauze, 40 parts of glycerin, and 10 of iodoform. To properly incorporate the latter, additional liquid is required, say, for instance, 200 parts of alcohol and 100 parts of water. When this gauze is finished and dried the alcohol and water will evaporate, while the glycerin and iodoform will remain, and the amount of the latter will then be ten per cent.

"*The Preparation of Iodoform Gauze of Different Strengths.*—To make iodoform gauze of the following strengths, use:



FIG. 160.
Iodoform
sprinkler.

Sterilized absorbent gauze (dry).... 475 grains;
 Iodoform..... The below-given amount;
 Glycerin 1 fluidounce;
 Alcohol..... 2 fluidounces.

For a 10-per-cent gauze use 116 grains of iodoform.

"	20-	"	"	"	260	"	"
"	25-	"	"	"	350	"	"
"	30-	"	"	"	450	"	"
"	40-	"	"	"	700	"	"
"	50-	"	"	"	1,045	"	"

" Place the required amount of iodoform in a suitable basin and add to it the glycerin and alcohol. Mix the iodoform thoroughly with the liquid, so that a perfectly homogeneous mixture will result; then incorporate the mixture with the proper amount of gauze by repeatedly rubbing it into the texture and wringing out and reabsorbing until the mixture is entirely taken up and uniformly distributed in the gauze. Then spread the gauze on a table covered with an impervious fabric rendered aseptic by wiping with bichloride solution (1 to 1,000); smooth out and then fold it in a suitable manner; wrap it in sterilized paraffin paper, and finally in sterilized oiled muslin, and place it in air-tight jars.

" If the amount of liquid for the higher strengths be found insufficient, a little sterilized water may be added to give the mixture the proper degree of fluidity.

" *The Preparation of Thiersch's Gauze.*—Prepare a 1-in-50 solution of Thiersch's powder (which consists of salicylic acid 1 part, and boric acid 8 parts) in sterilized water. To make 1 quart of this solution, 292 grains of the powder will be required. Saturate the gauze with this solution and retain it therein, completely immersed, for at least twenty-four hours; then wring it out more or less as may be required. It is not intended usually that this gauze shall contain a definite percentage of the antiseptics.

" *The Preparation of Bichloride Gauze.*—To make bichloride gauze of the following strengths, use:

STRENGTH.	1 in 1,000.	1 in 500.	1 in 400.
Absorbent gauze (dry).....	13 avoirdupois ounces (10 yards).	13 avoirdupois ounces (10 yards).	13 avoirdupois ounces (10 yards).
Bichloride solution (1 in 1,000).....	12½ fluidounces.	25 fluidounces.	31 fluidounces.
Sterilized water, enough to make.....	32 fluidounces.	32 fluidounces.	32 fluidounces.

" The solution should be repeatedly pressed out and reabsorbed until the impregnation is uniform and the whole of the mixture is taken up by the gauze. If required, the gauze may be dried, best between sheets of muslin in a place free from dust. But it is preferable to leave it moist, or at least not to dry it completely. It should be neatly folded and wrapped in paraffin paper which has itself been sterilized by the bichloride solution. The packages should be kept in air-tight receptacles. Large museum jars of a wide diameter are very suitable for this purpose.

"The weight of absorbent gauze per yard naturally varies with the thickness and number of the threads per unit of surface. That which has been found to be most suitable for general purposes, and is preferred at Bellevue Hospital, contains 24 threads per inch of width and 28 per inch of length; average weight 475 grains per square yard."

Objections to the Use of Iodoform.—The odor of iodoform is an objection to the use which can not be gainsaid. A too free application of the drug to extended surfaces, especially cranial, has been followed by both local and general deleterious and even fatal effects on the patient.

The addition of tincture of musk, tonka bean, or oil of bergamot will lessen the offensiveness of the odor. Iodoform should be used in small amounts, especially in elderly persons and in those affected with organic heart or kidney disease. The needless or perfunctory use in any form or measure is to be condemned. The employment in connection with firm pressure on the wound and with the use of carbolic acid is not advisable. A small, rapid pulse, attended with sleeplessness, restlessness, mental excitement, etc., call for the prompt removal of iodoform dressing. Fifteen grains has caused transient delirium; a drachm and more has been applied without special significance. The author has not yet observed unfavorable manifestations from the use, except in one instance, and that in the case of the free use to a large cranial surface.

The Peat Dressing.—Into a small carbolized gauze bag light peat or turf is introduced, combined with two and a half per cent of iodoform; over this a large bag filled with carbolized peat is applied, and the whole is bandaged firmly in position. The fine peat serves admirably to make equable pressure and absorb the discharges, and need not be reapplied until it has become soiled. Peat dressing is now rarely used, nor is there reason to regard it with favor, except it be first sterilized by heat.

Coarse and fine jute, wood-wool, wood-pulp, moss, peat, and sawdust, can each be made antiseptic by steeping six or eight hours in a solution of bichloride of mercury (1 to 1,000) with five per cent of glycerin; they are then wrung out, sterilized with heat, after which suitable sized pads or bags are made with some variety of antiseptic gauze.

Improvised Antiseptic and Aseptic Gauze.—Absorbent gauze is made antiseptic by putting it into a solution, bichloride of mercury 10 parts, water 2,240 parts, glycerin 250 parts, and allowing it to stand for ten or twelve hours, then wringing out and sterilizing by heat. If gauze be boiled for a few moments and the water wrung out, it is then sufficiently aseptic for brief use. If it be soaked in a strong antiseptic solution for a short time it becomes antiseptic, and, like the former, can be employed pending the prompt use of the substantial variety. Textile fabrics and instruments can be sterilized—made aseptic—by heat (Fig. 161) in any of the many apparatus devised for the purpose and offered for sale, as before stated (page 52). Those that combine moist heat and pressure influences are the most effective.

If a specially prepared absorbent gauze, from which all oily matters have been extracted, is not available, ordinary bleached or unbleached muslin may be boiled in a solution containing ten per cent of washing soda and two per

cent of caustic soda, after which it is washed with water until it no longer affects red litmus paper.

It should not be forgotten that the bichloride of mercury is a somewhat unstable component, and it therefore becomes necessary to use the freshly prepared combinations. If a small amount of common salt be added to the solution its stability is better maintained.

Objections to Bichloride Gauze.—It is well to remember that bichloride gauze should not be applied directly to the skin, especially that of a child, as it is very liable to cause an erythematous irritation.

The bichloride dressing is recommended as one possessing efficiency and safety. *The soluble compressed tablets*, containing a definite amount of bichloride of mercury, are very convenient for the minor requirements of general practice. They should not, however, become in any way associated with the compressed tablets employed for internal medication, for obvious reasons.

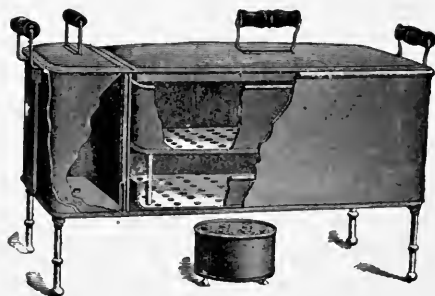


FIG. 161.—A portable sterilizer for dressings and instruments.

Summary of the Common Preparations for a Modern Operation. *The Operating Table.*—The table should be well covered with blankets, and by a rubber cloth so arranged, if need be, that if the table be slightly tilted all the fluids employed will be quickly discharged into a suitable-sized receptacle placed on the floor (page 41 *et seq.*).

The Patient.—The portions of the body not to be operated upon should be carefully excluded from draughts of air, and also from contact with fluids, by isolating them from the immediate field of operation by aseptic, suitably arranged warm rubber cloths, blankets, and flannel garments. Precautions of this kind lessen the degree of shock and the dangers of kidney and pulmonary complications.

The part to be operated upon, together with the contiguous area, must be made entirely aseptic a few hours before operation when practicable by shaving, soaping, and scrubbing with a stiff aseptic brush, after which they should be rinsed in alcohol, or a strong solution of carbolic acid, or chlorine water, and wrapped in towels saturated with a strong antiseptic fluid. A saturated ethereal solution of iodoform may be poured over the immediate site of the operation, and the antiseptic wraps omitted if the operation is to be commenced in a few moments (page 94 *et seq.*).

The surrounding areas, outside the immediate field of the operation, should be isolated from it by towels thoroughly wet with strong antiseptic fluid, and when soiled they should be replaced promptly by clean ones. The fluids thus employed should be warm.

The forearms, hands, and nails of the operator, the assistants, and of others who are brought in contact with the wound or with the instruments, together with the *instruments*, must be made thoroughly aseptic.

The following is an efficient method of securing proper cleanliness of the hands, etc. :

The nails should be cut short, and all foreign matter and dead cuticle should be removed from beneath them and from the ungui-cutaneous creases; the forearms and hands (fingers) should be thoroughly scrubbed for ten or fifteen minutes with soap and a stiff brush; the soap is then carefully washed off with sterilized hot water, and the nail-cleaner employed again as before; a similar scrubbing and washing is repeated, after which the extremities are thoroughly rinsed in pure alcohol and kept immersed in a hot antiseptic fluid or wrapped in antiseptic towels or mittens until the operation is commenced.

The following method of cleansing the hands is employed at the Johns Hopkins Hospital :

1. The nails are kept short and clean.
2. The hands are washed thoroughly for ten minutes with soap and water, the water being as hot as can be comfortably borne, and being frequently changed. A brush sterilized by steam is used, and any excess of soap is washed off with water.
3. The hands are immersed for from one to two minutes in a warm saturated solution of permanganate of potash.
4. They are then placed in a warm saturated solution of oxalic acid, where they remain until complete decolorization of the permanganate occurs.
5. They are next washed off with a sterilized salt solution or water.
6. They are then immersed for ten minutes in sublimate solution (1 to 1,500).

The Nascent Chlorine Method.—This method, introduced by Weir, is practiced as follows: Scrub the hands and forearms thoroughly in hot running water, using green soap, and aiding the cleansing under and about the nails with a pointed wooden brush.

Take about a tablespoonful of bleaching powder (the ordinary commercial chloride of lime) and about a cubic inch of carbonate of soda (common washing soda), to which add enough water to make a thin paste, and rub the whole about like soap. A thick cream is formed which emits free chlorine gas. Its application to the skin surface at first produces a sensation of heat, but a little later one of coolness.

Continue rubbing until the little rough grains of chloride of lime disappear, or until the creamy fluid thickens into a pasty layer, or until the sense of coolness is felt. The procedure occupies from three to five minutes.

Wash the paste off in sterile water.

The odor of chlorine can be removed by neutralization in a (sterile) one-fifth-per-cent solution of aqua ammonia.

Antiseptic Gloves.—If those who have to do with operative procedures, handling the dressings, etc., will, after the thorough cleansing of the hands and arms, wear long canton flannel gloves or mittens (Fig 162) saturated with a bichloride solution, the handling of miscellaneous articles during

preparation of the patient need cause no concern, especially if the hands be rinsed again before coming in direct contact with important things. Thin rubber and cotton gloves are advised for the same purpose, and are worn by many surgeons during operation. The author uses thin rubber finger stalls instead of gloves (Fig. 163). They are cheap, serviceable, cover the digits well, and can be promptly renewed and replaced by others when defective. At all events, no matter which be worn, the hands should be cleansed with



FIG. 162.—Canton flannel gloves.

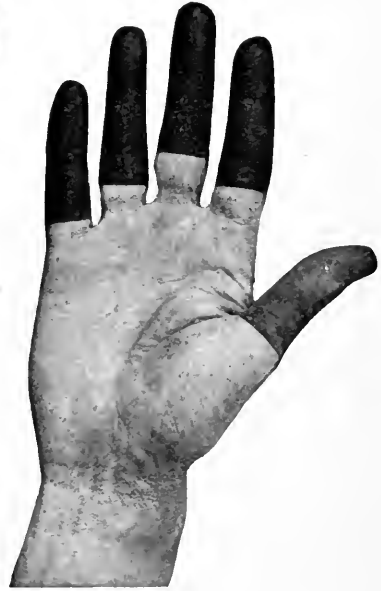

FIG. 163.—Rubber finger stalls.

the same degree of care as without their use, otherwise the wound may be contaminated by the escape from within, through a tear or puncture of the rubber, of infecting matter.

Diagram of Arrangements.—The diagram of arrangement (Treves) for operation illustrates a convenient method of disposal of the different means under favorable circumstances. It is rare indeed that this arrangement is available or perhaps desirable, except in hospital practice (Fig. 164).

The apparel of the surgeon and the assistants should be clean, newly put on, and free from the insidious influences of communicable disease. A long aseptic rubber apron covered with a freshly sterilized, short-sleeved, white linen gown, both reaching to the feet, are suitable for the surgeon, and can be supplemented by pinning in front a sterilized towel moistened with the antiseptic fluid. Each of the assistants should be similarly clothed and cleansed (Fig. 165). The use of freshly laundered white linen overwear is both cleanly and attractive. The change of the underwear is a measure

that is not always practiced, but it adds much, indeed, to the after-comfort of the surgeon, and not a little to his personal safety in the instances of tedious effort in a hot room. Changeable water-tight footwear is advised.

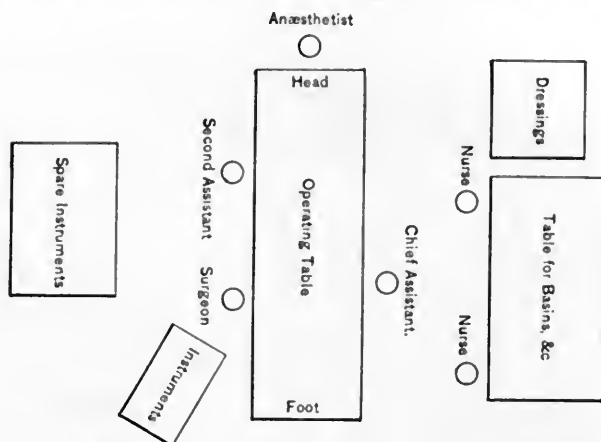


FIG. 164.—Diagram of arrangements. Abdominal operation.

Douching.—When douching is practiced an attentive assistant should have the care of the douching fluid, discharging it as may be required on

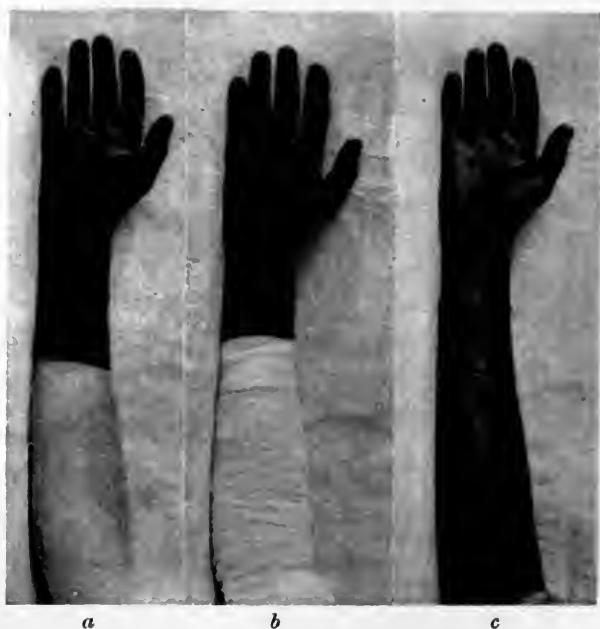

FIG. 165.—*a.* The rubber glove with naked forearm. *b.* The rubber glove, forearm lightly bandaged with aseptic gauze, fastened above to the sleeve of the operating gown. The gauze can be moistened with an antiseptic fluid for purposes of better apposition and cleanliness. *c.* The rubber glove with rubber gauntlet on forearm. This plan is apt to be uncomfortable and cumbersome. The writer practices the second method (*b.*)

the cut surfaces during the entire operation. This fluid may be used either hot (110° F. to 120° F.) or cold, according to the individual cases.

As already noted, the employment of free douching, or even douching




FIG. 166.—Prepared for operation. The Crane operating room, Bellevue Hospital.

at all, is practiced only to a limited extent at the present time, except in the instance of foul and offensive wounds or for the arrest of hæmorrhage.

The Wound.—All bleeding points should be tied with catgut, the wound itself closed with catgut, if practicable, and thoroughly drained when necessary. If desirable, a small amount of iodoform may be dusted on and close the seat of the wound, after which the kind of dressings are applied that have been selected to complete the treatment and are retained in place by antiseptic bandages.

After the Operation.—The patient is wiped dry, closely wrapped, and removed to bed, into which bags or bottles of hot water are introduced when indicated, so surrounded with flannel as to prevent burning the patient. This precaution is of great significance, especially if the patient be oblivious to thermal effects. Accidental burning is often the basis of legal action, becoming a source of great tribulation to all concerned.

The After-treatment.—Absolute quiet of the patient and of the part bearing the wound is not the least of the elements necessary to secure a satisfactory result. A careful record of the pulse, temperature, and respiration should be kept (page 11). If the temperature rises to 102° F., and does not become quite normal in two or three days, the dressing should be removed, the drainage carefully examined, and the part inspected, after which, if no contra-indications exist, it is again dressed as before. Usually the dressings are removed two or three days after the operation, and *at once when the discharges from the wound have soiled their external surface.* Furthermore, care must be taken that the external dressings be kept closely in contact with the patient for a considerable distance from the operation-wound, otherwise unfavorable influences may gain admission to the wound and prompt healing be thus prevented. The same antiseptic precautions should be employed with the redressing of the wound as with the operative procedure itself. Examination of the blood, urine, and lungs should be made from time to time for obvious reasons.

The Open Dressing.—The so-called open method of dressing consists in washing the wound cavity with the strong carbolic-acid solution at the completion of the operation, after which the limb is placed upon a suitable cushion of oakum, and over it is laid a thin piece of gauze, which is kept moistened with a solution of carbolic acid. The wound is washed two or three times daily by gentle irrigation with a carbolic solution, after which balsam of Peru is poured into it. All the dressings are to be kept clean. If an antero-posterior line of coaptation of the flaps is desired, they are drawn together by two or three stitches; otherwise no mechanical agents are applied to the wound. Before the time of the perfection of aseptic methods the open plan of treatment of operation-wounds was frequently practiced; since then it is rarely employed, except in infected and sloughing wounds of considerable magnitude. The late Professor James R. Wood practiced this method with eminent success in Bellevue Hospital before the time of Listerism, as the writer had, during his internship, abundant opportunity to witness.

THE PRECAUTIONARY REQUIREMENTS.

Many of the precautionary requirements and their importance have been indicated already (pages 13 and 14).

The Stimulants, of which brandy, whisky, champagne, ammonia, nitrite of amyl, digitalis, strychnin, etc., are in common use, and one or more should be at hand during an operation, irrespective of its brevity or nature. Caffein citrate hypodermically and infusion of strong coffee by the bowels are very useful agents.

For purposes of administration of these agents, the hypodermic and Davidson's syringe are most convenient. Under no circumstance should fluids be administered by the mouth, if the patient be unconscious, except by the medium of a stomach tube.

The Tongue Forceps and Mouth Gag.—The importance of these implements has been sufficiently emphasized already to render the necessity for their presence evident (page 13).

The Electric Battery.—The battery must be at hand when the nature of the operation or condition of the patient might give rise to the failure of the circulatory or respiratory powers.

The Tracheotomy Tube.—Although the tracheotomy tube is not necessary to the performance of tracheotomy or laryngotomy when indications suddenly arise calling for either, yet it is better to be provided with one. The surgeon must not overlook the fact that the death of a patient due to the absence of a tube, or to the loss of time consumed in seeking for one, is unpardonable.

The Elastic Bandages.—Elastic bandages are not only important in preventing the direct loss of blood, but, as heretofore stated (page 69), very important when applied to the limbs for the purpose of forcing the blood contained in them into the trunk, as in cases of impending death from shock due to the loss of blood. They are, in our opinion, of great practical utility for immediate use in such cases. They will certainly bridge over the interval of time necessary to prepare for transfusion better than any other expedient.

Transfusion.—If the operation be of such a nature that great loss of blood is liable to happen, arrangements should be perfected for the rapid performance of this measure by the utilization of blood or, better still, the saline solution (*Transfusion*, page 220 *et seq.*).

Artificial Respiration.—No one can be safely intrusted to administer an anæsthetic or to attempt any operative procedure who is not familiar with the manipulations necessary for the proper performance of this means of resuscitation (pages 18, 19). It is, in fact, the only one of the requirements which should be continuously employed until the safety of the patient is assured, or until death is an established fact.

Finally, a surgeon should not begin an operation without having carefully rehearsed its various steps in his mind (page 10), together with the possible complications that may arise and the best means of combating them.

Precautions of this kind serve to distinguish the careful and conscien-

tious surgeon, who places a proper value upon human life, and a just professional reputation, from the one who operates only because the opportunity is offered, and considers the details tedious or worthless because he has not had sufficient patience or faith to practice them. Such as he trust to luck, and often attribute the result when the patient succumbs to inscrutable Providence.

THE SPECIAL EMERGENCIES.

While the scope of this work will not admit of an extended consideration of these emergencies, still it is the author's earnest desire to so emphasize their importance, that those desiring additional information will seek it from other and more extended sources. Unexpected emergencies not infrequently occur during the course of an operation, even though they be of a minor character. The anæsthetic given to relieve pain may from unknown reasons prove a treacherous ally, and by an unexpected influence surround the case with greater gravity than that of the condition demanding the operation. This emergency, together with the suffocation that may be caused by the solid contents of an incautiously fed stomach, or one with tardy digestion, finding their way into the air passages, has been quite fully considered in the preceding pages.

Shock.—The symptoms of this important nervous state especially demand a careful study on the part of those who contemplate practicing surgery. Shock may exist before, occur during, or follow an operation, and in either instance may depend on loss of blood, on physical injury, profound emotion, or on all combined. Shock may be slight in degree or be characterized by *syncope*, may be attended or followed by *collapse*. Also depression of the vital forces is caused by profound mental emotion, and in all instances shock is the outcome of exhaustion of or hindrance of the vaso-motor function. In *shock*, the blood accumulates in the veins, especially those of the abdominal system, leaving the arteries and capillaries correspondingly depleted.

Collapse, according to Crile, is a manifestation due to hindrance or inhibition of the vaso-motor center, and *shock* is dependent on exhaustion of this center. However, both may be present at the same time. Obviously, shock varies in intensity and duration, according to the degree of injury, the loss of blood, the sex and personal characteristics of the patient, and the nature and extent of already **existing** disease. Injury of some special organs, as the brain, thoracic and abdominal viscera, and of the testicle, cause profounder shock than attends injuries of a similar degree of other tissues. Direct stimulation of the pneumogastric and reflex stimulation of the nuclei arrests cardiac action, causing death by inhibition.

The prevention of shock relates to a careful study of the patient's complicating conditions, and the employment of measures to obviate these adverse influences. The length of time the patient is exposed to operative measures, to the effects of ether, and of wet and cold, and the amount of hæmorrhage exercise a potent effect, suggesting that the procedure be completed as soon as practicable with a minimum amount of ether, with warm,

dry surface, and prompt arrest of bleeding. For an operator to be obliged to wait for an assistant to thread needles, cut ligatures, and attend to other various details, thus consuming time important for the patient's welfare, is conclusive evidence of a serious lack of foresight, which too often contributes its influence to disastrous results.

Cocaine infiltration of the large nerves of a limb in amputation lessens and even prevents shock (page 35).

Shock due to the loss of blood has characteristics somewhat distinctive from that dependent on mutilation of the soft parts. In the former, the cold, clammy surface, feeble, fluttering pulse, extreme pallor of the mucous surfaces, great restlessness, and sighing respiration are especially prominent.

The Treatment of Shock.—The treatment of shock is modified by the degree and by the cause of the depression. In an ordinary degree of shock, lowering of the head, admission of fresh air, the application to the surface of bottles and bags of hot water, and hot blankets may suffice. Mustard sinapisms to the epigastric, the cardiac, and to the dorsal regions of the hands and feet, collectively or singly, will contribute a restorative effect. High enemata of hot normal saline solution, hot infusion of coffee, and perhaps of whiskey, are advantageous aids. The inhalation of oxygen, the subcutaneous injection, according to circumstances, of fifteen or twenty drops of sterilized oil of camphor (Senn), and bandaging of the extremities, are commended in severe cases; also abdominal massage, artificial respiration and diaphragmatic stimulation (galvanic) can be utilized in similar cases. The injection of the hot saline solution into the cellular tissue of the thigh, breast, and intra-scapular region (*hypodermoclysis*, page 222),

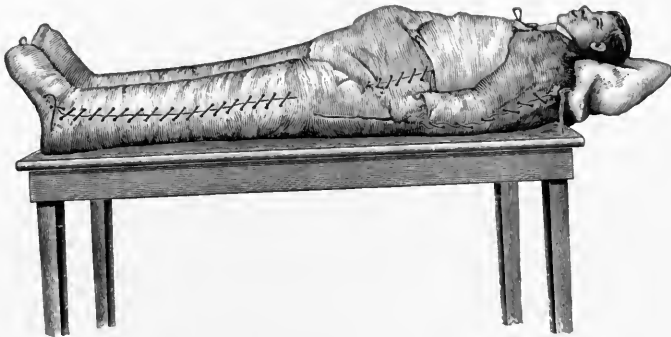


FIG. 167.—Crile's inflated rubber suit for treatment of shock.

into the bowel (*enteroclysis*, page 222), and into the venous system (*intravenous injection*, page 220), are each of signal importance in cases of severe shock, especially when due to loss of blood.

In pure shock (diminution of blood pressure due to exhaustion of vaso-motor center), according to Crile, the peripheral capillary exhaustion due to vaso-motor failure is best met by agents that create peripheral resistance. For that purpose *medicinally* Crile commends the slow intravenous intro-

duction of a fluid composed of a teaspoonful of a solution (1 to 1,000) of adrenalin and a quart of hot normal saline solution. To meet the same indication *mechanically* Crile applies to the surface of the patient's body "a rubber suit made of a double layer of especially constructed rubber, which, when inflated, gives a uniform pressure (Fig. 167) upon the surface, producing an artificial peripheral resistance." The pressure is varied with the demands of the case.

In *collapse* the fall of the blood pressure is sudden, due to profuse hæmorrhage, injuries of the vaso-motor center or to cardiac failure, "representing suspension of function rather than exhaustion of centers" (Crile). For this condition strychnia, ammonia, etc., may be employed combined with artificial respiration, rhythmic pressure upon the præcordial region, lowering and raising the head, followed by the hot saline infusion with or without adrenalin, as the severity of the case demands.

The Comments.—In deepening shock cease operation at once, except dependent on cause demanding continuance to save the life of the patient. When lowering of head causes cyanosis, reverse the movement. The arterial pressure incident to varying arterial tension can be quite well estimated by educated touch, but instruments of precision (Fig. 168) are better for the purpose, and afford the opportunity of establishing a definite record of measurement. Ether should be carefully administered in cases of shock, and not at all hypodermically when its inhalation causes depression, for an obvious reason. The use of strychnia, digitalis, amyl nitrite, hypodermically or otherwise, without well-considered therapeutic differentiation of need should be carefully avoided. The careless and seemingly even guarded use of bags and bottles of hot water are so frequently attended with grievous burns as to require the most careful surveillance in their application.

Air in the Veins.—This accident is associated with operations upon the portions of the body where the venous circulation is markedly influenced by the force of aspiration, as in the regions of the neck, chest, and axillæ. Here, if a vein that is connected with a morbid growth be nicked while on the stretch, or otherwise divided, it may open sufficiently to admit the entrance of air, on account of the tension of its walls and the influence of the respiratory force. The air gains the right side of the heart, causing distention of that cavity with frothy blood, obstructing more or less the pulmonary circulation. If the wound is filled with blood or fluid this accident will not occur, as the fluid will prevent the entrance of air into the vessel.

The Symptoms.—The local symptoms are a bubbling or hissing sound at the seat of the hæmorrhage, sometimes attended with air-bubbles. The patient becomes pallid, with anxious facies, labored breathing, and livid lips, attended with a churning sound on cardiac contraction. Rapid insensibility or convulsions may be the principal features. Sudden death not infrequently occurs.

The Treatment.—The treatment should be quick and decisive. Close the opening at once with the finger or sponge, and make forcible pressure on the thorax with the next expiratory movement, raising the finger from the

vessel to permit the air to escape. Close the vessel again and repeat the thoracic compression, if need be.

Catheterization of the wounded vein and aspiration of the heart by passing the needle through the fourth intercostal space near the left side




FIG. 168.—Janeway's portable sphygmomanometer.

A. Jointed U-tube manometer, which folds into case. B. Compressing armlet (12 cm. inside width). C. Politzer inflator. D. T-tube connecting A, B, and C. For carrying, upper joint of manometer fits in rings to right, scale slides down, cork F closes open end of manometer, rubber joint G is automatically compressed by block in bottom of case, and spring H holds stop-cock E.

of the sternum (see Heart, Vol. II) are permissible in desperate cases, and based upon the idea of withdrawing frothy blood and thus relieving the obstruction. Consequently the effort should cease at once with the escape

of clear blood. However, in this class of cases death usually forestalls the effort of relief.

Kemp recommends artificial respiration and hot saline infusion in these accidents.

The Preventive Treatment.—The preventive treatment consists in the adoption of such measures as shall prevent the entrance of air: 1. Pressure upon the vein by the fingers at its proximal portion during an operation. 2. Avoid making incisions during inspiration, especially in the vicinity of large veins, and when the veins are held open by disease of their coats or of the surrounding tissues. 3. If a vein be cut, compress it at once and then ligature it. 4. Keep the field of operation well covered with fluid, if possible.

If the means here given be carefully employed, the fear of this complication need not oppress the surgeon.

CHAPTER IV.

THE LIGATURE OF ARTERIES.—GENERAL CONSIDERATIONS.

ARTERIES are ligatured in their continuity and at their divided extremities. Under this heading, however, will be considered the ligaturing of arteries in their continuity only. Nearly all arteries to which ligatures are thus applied can, from their association with the soft and hard parts, be said to possess certain guides, which, when carefully adhered to, indicate with precision the normal position of the vessel beneath the surface.

The guides to arteries in the living subject are practically six in number : 1. The linear guide. 2. The muscular guide. 3. The bony guide. 4. The contiguous anatomical guide. 5. The pulsation. 6. The color of the vessels.

The linear guide to an artery is a line drawn upon the external surface so as to correspond with the established course of the vessel beneath. The extremities of the line are usually indicated by the relation which the vessel bears to fixed bony prominences.

The muscular guide is one based upon the relation which the vessel bears to some portion of a well-developed superficial or deep muscle, the outline of which can be quite readily traced if the muscle be placed upon the stretch. If the border of a muscle be given as the guide, it must not be forgotten that, in case the muscle be unusually developed, or have a broader origin or insertion than common, it will overlap the vessel, and thus may lead the surgeon astray. Under these circumstances attention must be directed unerringly to the *contiguous anatomical guides*, which include the relation that a vessel bears to the immediate surrounding parts, and, when taken in connection with the pulsation, lead directly to it. *The contiguous guides* to an artery may be *muscular*, if a muscle be ascertained to bear an established relation to it; or *bony*, when a bony prominence is in close contact with it; or *nervous*, when a certain nerve is known to lie in a definite relation to it; or *vascular*, when vessels of an established arrangement are associated with it; and, finally, the *sheath* of the vessel itself becomes a valuable guide when it is considered in connection with the other guides. Some of the large vessels, of which the common carotid and femoral arteries are the most striking examples, have well-developed sheaths, while the smaller arteries are surrounded by a greater or less amount of areolar tissue only. The larger arteries, as the popliteal, femoral, and subclavian, are each accompanied by a single vein which commonly runs in a definite relation with them. The smaller arteries, especially those of the extremities, are attended by satellite veins, two in number, known as *venæ comites*; however, this

arrangement is not invariable, since three or more of these veins are often seen. The vessels are distinguished from each other by the light or *pinkish color of the arteries* and the dark color of the veins. If three vessels are seen, the middle one is almost certain to be the artery; if more than three

exist, the third vein usually rests upon the artery. If pressure be made upon these vessels, the veins become distended and the artery collapsed on the distal side of pressure. If to these facts be now added *the pulsation of the artery*, its location is assured. However, the operator who relies exclu-

sively upon the arterial impulse as a guide may be led astray by the transmitted pulsations of contiguous vessels, or by the movements of parts near to which the artery is located.

Having settled the details of the operation, the portion of the body in which the vessel is situated is properly prepared and so placed as to afford room and the best possible light for the procedure.

The part of the vessel is then selected for ligation at which the surgeon feels best assured of the absence of branches of sufficient size to interfere with formation of the internal clot. *The primary incision* is made, if possible, so that the center shall correspond to the portion of the vessel to which the ligation is to be applied.

The length of the primary incision will depend upon the depth of the vessel, and should always be of sufficient extent to afford easy access to it. If the thumb and finger be employed to make the integument tense and steady at the time of the incision, great care must be taken that the

tension be equal on the respective sides (Fig. 169), otherwise the incision will fall outside the line of the vessel after the tissues are released, which, if unheeded, will lead the surgeon astray; besides, the consequent irregularity of the wound will interfere with the necessary space and light as well as

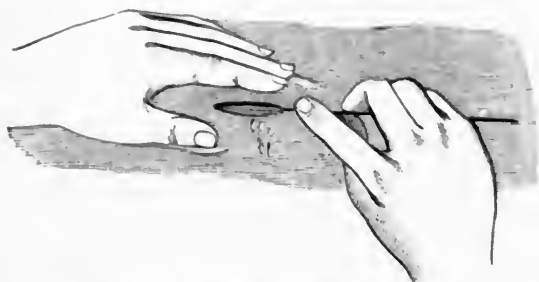

FIG. 169.—Making primary incision.

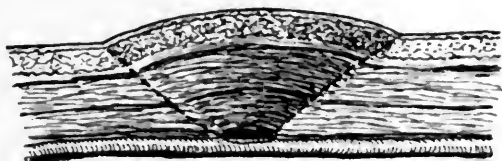


FIG. 170.—Approach to vessel.




FIG. 171.—Opening the sheath.

with the drainage of the part. The external incision should be made with one sweep of the knife rather than by repeated cuts, which tend to chop the tissues, thus lessening the prospect of union by first intention.

The fascia is divided in a similar manner. The tissues beneath the fascia are gently separated by the fingers or handle of the scalpel, using the cutting

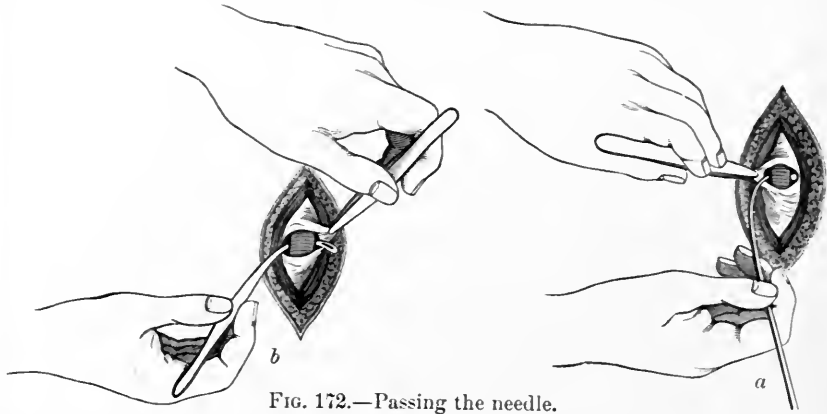


FIG. 172.—Passing the needle.

edge only when necessary, until the sheath of the vessel is reached. The nearer the approach to the vessel the shorter should be the line of the separation of the tissues, so that when the vessel is reached the outline of the wound will resemble somewhat an inverted triangle, with its apex corresponding to the sheath of the artery (Fig. 170). When the sheath is reached a small opening is made into it—about one fourth of an inch being ample—of sufficient size to pass the needle with ease. This opening is made by picking up the sheath or condensed tissue with the thumb forceps, carefully cutting from it a buttonhole-shaped piece of a suitable size (Fig. 171).

The borders of the opening in the sheath are then separately raised, to enable the operator to ascertain if deeper tissues still surround the vessel; if so, they, too, should be incised in a similar manner. When the peculiar pinkish-white appearance of the coats of the artery are seen, the side of the

cut in the sheath nearest to the contiguous vein, or other important structure, should be grasped and raised by the forceps (Fig. 172, *a*), and the aneurism needle, armed with a ligature or not, carefully passed from the point of greatest danger

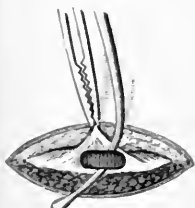


FIG. 173.
Passing the probe.

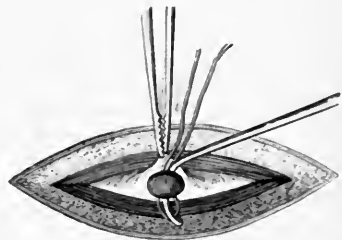


FIG. 174.—Passing curved needle.

around the vessel, while the opposite side of the opening in the sheath is grasped (*b*) to facilitate the exit of the advancing end of the instrument. When the needle is armed, a bent probe can be used to prepare the way (Fig. 173). If the location of the vessel will permit, the needle may be intro-

duced armed (Fig. 174), and when the advancing ligature appears at the opposite side of the vessel it is seized and one end brought through by forceps and the other left in position by withdrawal of the needle. Less disturbance of the soft parts attends the placing of a ligature when the

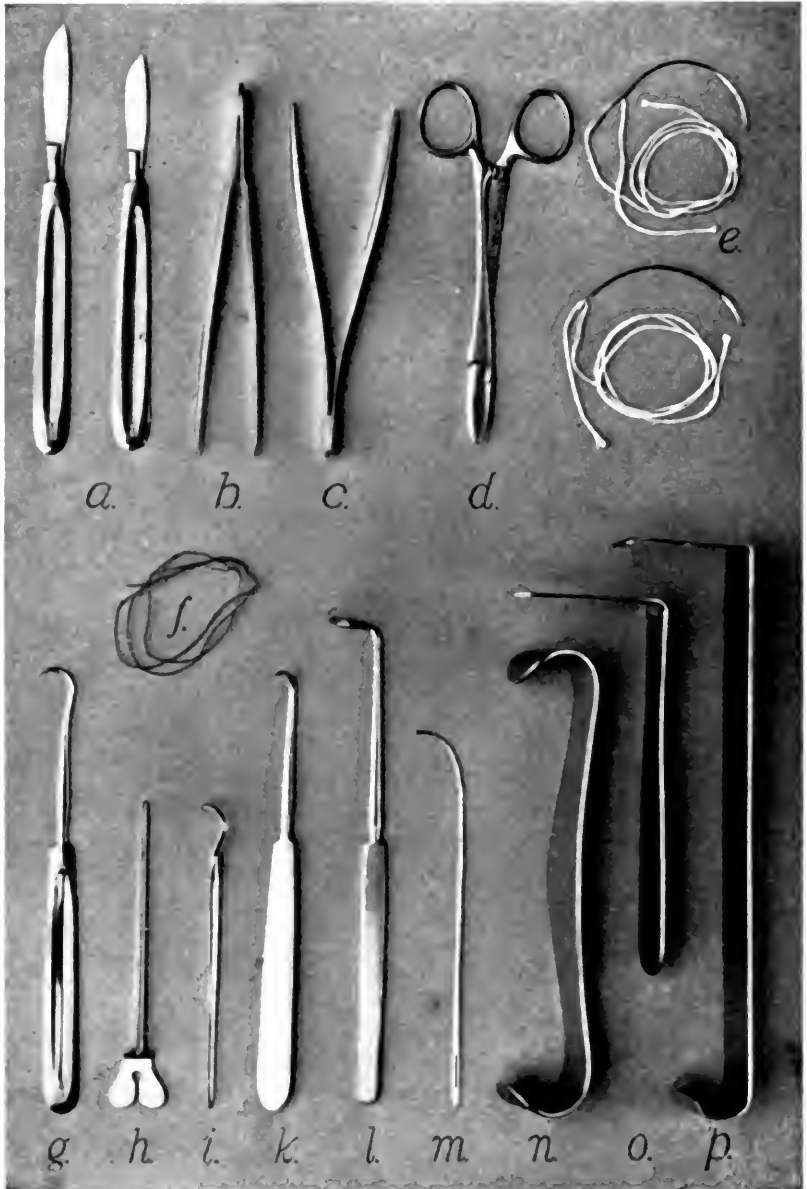


FIG. 175.—Instruments for ligature of arteries.

a. Scalpels. *b, c.* Forceps. *d.* Forceipressure. *e.* Traction loops. *f.* Ligature. *g.* Tenaculum. *h.* Grooved director. *i, k, l.* Aneurism needles. *m.* Bent probe. *n, o, p.* Common retractors.

needle is introduced unarmed and when the way has been prepared already by the probe. If all doubts be settled as to the identity of the vessel, the ligature is tied by either the surgeon's or the reef knot, both ends cut short, and the wound closed and dressed in the usual manner.

The kind of Instruments required to Ligature Arteries in their Continuity (Fig. 175).—Ordinary scalpels (*a*), common thumb and mouse-tooth forceps (*b, c*), forcipressure (*d*), traction loops (*e*), tenaculum (*g*), grooved directors (*h, i*), aneurism needles (*k, l*), probe (*m*), retractors (*n, o, p*), and ligatures (*f*). The number of each of the respective agents is regulated by the demands of individual cases. The need for blunt hooks, artificial light, and specially designed instruments will be self-evident as circumstances arise.

The Retractors vary in size and shape. The ones recommended by Professors Mott (*o, p*, Fig. 175) and Parker (*n*, Fig. 175) are appropriate



FIG. 176.—Extemporized retractors.




FIG. 177.
Student's needle.

for all common purposes. If neither be at hand, others can be extemporized by bending the handle of a common table spoon or the tines of a fork to the necessary angle (Fig. 176).

The Aneurism Needle.—The aneurism needles differ in size, shape, and arrangement. The simplest form is combined with a director. Also one with a lateral curvature may be employed (*i, l*, Fig. 175); another with adjustable points for the purpose of securing deep-seated vessels. These points must be securely screwed in position, else the turning of the instrument, often necessary in passing it, may loosen them, causing the instrument to become a source of annoyance instead of an advantage

FIG. 178.
Mott's aneurism
needle.

(Fig. 178). In Fig. 177 is a representation of the safest needle with movable points now in use. It is known as the "Movable Immovable Aneurism Needle," and also as the "Student's" Needle. It was devised by Dr. S. W. Fletcher, of Pepperell, Mass., while a student; hence the name sometimes given to it.

THE LIGATURE OF SPECIAL ARTERIES.

Ligature of the Abdominal Aorta.—The abdominal aorta can be ligatured at its lower two inches—that is, below the origin of the inferior mesenteric—by either of two or three methods.

The Contiguous Anatomy.—*In front* lie the omentum, intestines, peritonæum, sympathetic nerves, and mesentery; *behind* lie the left lumbar veins, receptaculum chyli, thoracic duct, and vertebral column; *at the right* lie the inferior vena cava, vena azygos, and thoracic duct; *at the left* no important structures are sufficiently near to be injured with the exercise of reasonable caution (Fig. 179).

The linear guide to the vessel is the linea alba. The vessel at this situation has no practical muscular or bony guide.

The Operation. First Method (Cooper).—With the patient on the back and the legs flexed, make a straight incision four or five inches in length to the left of the umbilicus—to

which the center of the incision may correspond (Fig. 180, *a*)—through the various tissues, comprising the abdominal wall at this point, to the peritonæum, dividing each carefully. Check all oozing, and cautiously incise the peritonæum, securing its borders with long traction loops (see Fig. 51) to prevent them from retreating outward behind the abdominal muscles.

Turn the patient toward the right, or tilt the table in that direction, thereby aiding the displacement of the intestines to that side; locate the vessel with the finger and carefully cut through the peritonæum covering the vessel at the left side, pass the needle away from the vena cava and from behind forward, closely hugging the aorta and carefully avoiding the sympathetic nerves and inferior vena cava. This operation should be done with strict antiseptic precautions. If it be possible, the temperature of the operating-room should be 85° F. at least, and the room should have been thoroughly cleansed. If it be necessary to remove any of the intestines from the abdominal cavity, they must be wrapped after removal in aseptic

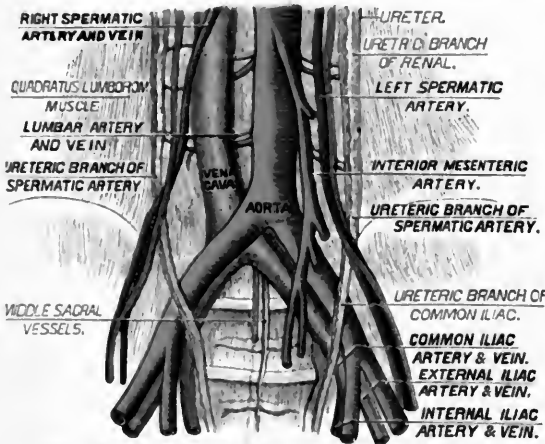


FIG. 179.—Relations of large vessels to each other.

which the center of the incision may correspond (Fig. 180, *a*)—through the various tissues, comprising the abdominal wall at this point, to the peritonæum, dividing each carefully. Check all oozing, and cautiously incise the peritonæum, securing its borders with long traction loops (see Fig. 51) to prevent them from retreating outward behind the abdominal muscles.

Turn the patient toward the right, or tilt the table in that direction, thereby aiding the displacement of the intestines to that side; locate the vessel with the finger and carefully cut through the peritonæum covering the vessel at the left side, pass the needle away from the vena cava and from behind forward, closely hugging the aorta and carefully avoiding the sympathetic nerves and inferior vena cava. This operation should be done with strict antiseptic precautions. If it be possible, the temperature of the operating-room should be 85° F. at least, and the room should have been thoroughly cleansed. If it be necessary to remove any of the intestines from the abdominal cavity, they must be wrapped after removal in aseptic

gauze well wet with the hot saline solution. The Trendelenburg position may be employed with advantage.

Second Method (Murray).—The second method leads to the vessel without opening into the abdominal cavity.

The Linear Guide to the Operation.—A line drawn from the apex of the tenth rib downward and forward to within about one inch of the anterior superior spine of the ilium (Fig. 181, *b*) is a proper linear guide.

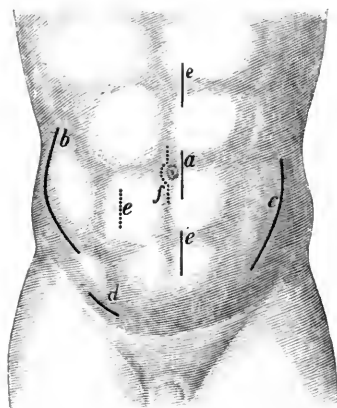


FIG. 180.—Linear guides.

a. For ligature of aorta (Cooper). *b.* For ligature of common iliac (Crampton). *c.* For ligature of common iliac (McKee). *d.* For ligature of deep epigastric and circumflex iliac arteries. *e. e. e.* Incisions in upper, lower, and lateral regions. *f.* Carotid curved incision in median line.

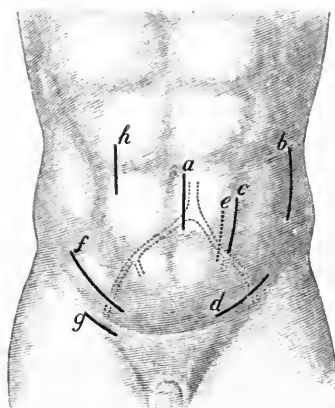


FIG. 181.—Linear guides.

a. For ligature of common iliac (transperitoneal). *b.* For ligature of common iliac (extra peritoneal). *c.* For ligature of common iliac through semilunar line (transperitoneal). *e.* For same through fibers of rectus. *d.* For ligature of external iliac. *f.* For ligature of same. *g.* For ligature of common femoral. *h.* Incision through outer border of rectus for opening abdomen at that situation.

The Contiguous Anatomy.—The ureter lies to the outer side. In other respects the importance of the relations of the vessel is alike in both methods.

The Operation.—Divide the various tissues comprising the abdominal wall on a grooved director down to the peritonæum; turn the body to the opposite side; insert the hand into the wound; separate the peritonæum and raise it along with the intestines and ureter carefully upward and inward, thus readily exposing the aorta to view. The aorta is then raised with the finger or a blunt instrument and the ligature passed as before. The aorta can be reached through an incision extending from the end of the last rib to the anterior superior spinous process of the ilium.

The Results.—The aorta has been ligatnred fourteen times, and in every instance death occurred within from three hours to forty-eight days after the operation. Ten were ligatured before the aseptic period.

Ligature of the Common Iliac Arteries.—The common iliac arteries are ligatured with greater confidence since the advent of aseptic procedure.

The Anatomical Points.—The common iliac arteries average about two inches in length, and should be ligatured as near the middle as possible. They commonly begin at the left of the middle of the body of the fourth

lumbar vertebra, and diverging pass downward and outward to the sacro-iliac synchondroses.

The Contiguous Anatomy.

THE RELATIONS OF THE COMMON ILIAC ARTERIES. (GRAY.)

In front.

Peritonæum.
Small intestines.
Sympathetic nerves.
Ureter.

In front.

Small intestines.
Peritonæum.
Sympathetic nerves.
Rectum.
Superior hæmorrhoidal artery.
Ureter.

Outer side.

Right common iliac artery. Vena cava.
Right common iliac vein
Psoas muscle.

Inner side.

Left common iliac vein.

Outer side.

Psoas muscle.

Left common iliac artery.

Behind.

Right and left common iliac veins.
Last two lumbar vertebræ.

Behind.

Left common iliac vein.
Last two lumbar vertebræ.

The Linear Guide to the Vessels.—An imaginary line crossing the abdomen, between the highest portions of the iliac crests, corresponds very nearly indeed to the level of origin of the iliac arteries. The vessels run divergently from a point in this line a little to the left of the center of the abdomen downward and outward on either side to a little within a mid-point between the pubes and the anterior superior spinous process.

There are two general methods of access to the common iliac artery: one, by entering the abdominal cavity from in front (transperitoneal), the other by raising the peritonæum through an incision made down to it at the side of the abdomen (extraperitoneal). Trendelenburg pose best in both methods.

The First Method (Transperitoneal).—At present this method is generally accepted as a substitute for the latter one, especially in those cases in which the latter is of doubtful expediency. The outer border of the rectus abdominis muscle, or more properly the linea semilunaris, is the best *superficial guide* to the vessel in this method. The lineæ semilunares extend downward on either side of the abdomen from the cartilage of the ninth rib to the spine of the pubes, arching slightly outward. In the abdomen of a normal adult these lines are about three inches transversely from the umbilicus. The relations of the common iliac arteries and veins are intricate, and are dissimilar on the respective sides (Fig. 179), and therefore they should be thoroughly understood before beginning the operation.

The Operation.—An incision five inches in length, and three inches to the left of the median line (Fig. 181. c), is made carefully into the abdominal cavity; the omentum is raised upward, the intestines are pushed aside, the vessel is located with the fingers, and a small opening is made through the peritonæum covering the vessel, and the vessel ligatured by passing the needle around it from without inward on the right and from within outward on

the left side. That is to say, the needle is passed *from* the vein nearest the vessel in each instance (Fig. 183). The external wound is then closed.

An incision through the rectus corresponding to the iliac artery to be tied should be employed in lieu of the former incision, and the vessel exposed in the same careful manner (Fig. 181, *a*).

The Results.—Of 19 cases, 14 died and 5 recovered. Five were tied for hæmorrhage, 4 died and 1 recovered. Thirteen for cure of aneurism, 9 died and 4 recovered. One for malignant disease, result fatal. Ten were done before 1883, all died. Since 1883 these vessels have been ligatured aseptically nine times, 4 died and 5 recovered.

The Second Method (Extraperitoneal).—In this method the abdominal cavity is unopened.

There are Two Linear Guides to this Method.—In one (Crampton) is a line drawn from the apex of the cartilage of the last rib downward and a little forward nearly to the crest of the ilium, then carried forward parallel with it to a little below the anterior superior spine (Fig. 180, *b*, and Fig. 182).

In the other (McKee) a line drawn downward from the tip of the cartilage of the eleventh rib to a point an inch and a half within the anterior superior spine, then curved downward, forward, and inward, and terminating abruptly above the internal abdominal ring (Fig. 180, *c*).

The Muscular Guide.—There is no *superficial* muscular guide to the common iliac artery except the rectus abdominis, and then only in the median operation. The inner border of the psoas magnus is, however, an undeviating and markedly prominent *deep* muscular guide.

The Operation.—Place the patient on the back (in the Trendelenberg posture if desirable), the body inclined to the opposite side, and with the thighs slightly flexed to relax the abdominal walls. The various layers of tissue composing the abdominal wall are divided down to the fascia transversalis, which is cautiously raised with forceps at the upper end of the wound, where it is less dense and less firmly attached; a small opening is made through it; the finger is then passed beneath it, and the fascia is divided to the full extent of the wound. An assistant standing on the opposite side of the body then introduces his hand into the wound and raises the peritonæum gently upward and inward, while the operator, by the aid of the finger or handle of the scalpel, sepa-

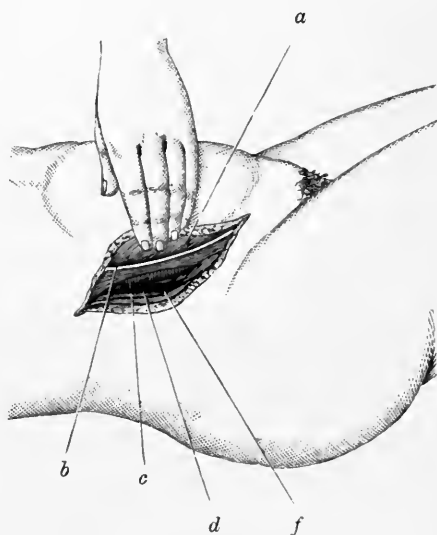


FIG. 182.—Incision for ligaturing common iliac artery. (Crampton.)

a. Peritonæum. *b.* Ureter. *c.* Common iliac artery. *d.* Common iliac vein. *f.* Psoas muscle.

rates it carefully from the tissues beneath. When the psoas magnus is reached, the surgeon should appreciate the relations of the dissection to the exact location of the artery. If the external iliac artery be felt first, it is to be followed upward to the common iliac; when the common iliac is reached, the areolar tissue surrounding it is scratched aside by the director, and the needle armed with the ligature is passed as already indicated—the needle with the adjustable end being preferable for this operation (Fig. 183).

The Dangers.—The dangers attending this operation are of considerable magnitude. The peritonæum may be lacerated, the ureter included in the

ligature, or the veins punctured by the needle. The assistant who raises the peritonæum should keep the fingers closely approximated, using both hands, if necessary, and being careful that the fingers do not become too much flexed, else they may lacerate it. If the patient struggle, vomit, or cough, the peritonæum should be permitted to return to its normal site until quiet is restored. The traction necessary to separate and elevate the peritonæum

can not be made too carefully, and it is better if it be done during the acts of expiration, since at this time the downward pressure of the abdominal contents takes place. Large, broad retractors are sometimes employed for this purpose, but they are much less reliable than the hands of an intelligent assistant.

The ureter crosses the artery at the point of bifurcation of the vessel, and it is in little danger, since it is usually raised along with the peritonæum and the subjacent tissue. The veins can be avoided by remembering to pass the needle away from them. This will be somewhat difficult on the right side, owing to the large venous trunks in close contact with either side of the artery. If the vein obscures the arterial trunk, pressure upon it below the point to be ligatured will diminish its size by obstructing the venous return, and thus permit the easy exposure of the artery.

The Fallacies.—The external iliac artery may be mistaken for the common iliac artery. The fact that the sacro-vertebral prominence is above the external iliac artery should settle the doubt as between the two. The ligature may be applied too near the bifurcation, owing to the difficulty of finding it on account of obscure light and the intimate relation of the vessels

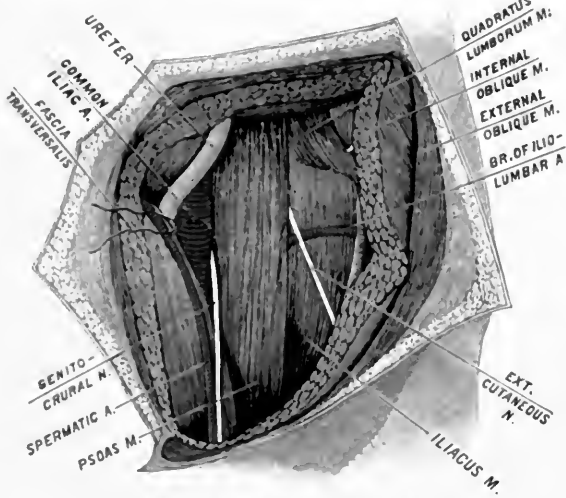


FIG. 183.—Ligature of common iliac artery.

with each other. Careful scrutiny only will prevent this mistake from occurring. The author once mistook temporarily the left for the right common iliac artery owing to an abnormality of the bifurcation of the aorta. However, pressure made on the vessel before tying rectified the error.

The Results.—Of 59 cases reported, 18 died and 41 recovered. Thirty-four of which were done for aneurism, of these, 13 lived and 21 died; 18 were done for hæmorrhage, 4 lived and 14 died; 7 were done for malignant disease, 1 lived and 6 died. Of the 59 cases, 53 were done before 1883, of these, 35 died and 18 recovered. Six were done aseptically since 1883, all died.

Ligature of the Internal Iliac Artery.—The internal iliac is ligatured to control the circulation of a pelvic viscus and to arrest of hæmorrhage.

The Anatomical Points.—The internal iliac artery is about an inch and a half in length, and extends from the bifurcation of the common iliac downward and forward to near the upper border of the great sacro-sciatic foramen.

The Contiguous Anatomy.

RELATIONS OF THE INTERNAL ILIAC ARTERY. (GRAY.)

<i>In front.</i>		
Peritonæum.		
Fascia.		
Ureter.		
<i>Outer side.</i>	{ Internal }	<i>Inner side.</i>
Psoas magnus.	{ iliac }	Internal iliac vein.
	{ artery. }	Peritonæum.
<i>Behind.</i>		
External iliac vein (<i>above</i>).		
Internal iliac vein.		
Lumbo-sacral nerve.		
Pyriformis muscle.		
Sacrum.		

The internal iliac artery possesses no practical *linear* or *muscular* guide other than its relation to the inner border of the psoas magnus muscle.

The Primary Incisions.—Either of the incisions employed in the ligature of the common iliac (Figs. 180 and 181); or an incision five inches in length, parallel with the epigastric artery; or a curved incision through the linear *semilunaris* (transperitoneal) about seven inches in length, made three inches to the outer side of the umbilicus, with its convexity outward, and ending just to the outer side of the external abdominal ring, can be employed. The intestines are carried upward, aided by the Trendelenburg posture, the brim of the pelvis is sought, the artery located as it extends into the pelvic cavity, peritonæum scratched through, carefully avoiding the ureter, and the needle is passed cautiously away from the vein. The vessel is tied through an incision made into the abdominal cavity in the median line below the umbilicus.

The Operation (Extraperitoneal).—The tissues are divided successively in the line of the primary incision, the peritonæum is elevated in a cautious manner, the ligature is carried around the vessel from within outward, carefully avoiding the ureter, and also the external iliac vein.

The internal iliac artery may be mistaken for the external.

The Results.—Of 31 cases of ligature by the *extraperitoneal* route, 22 died; of 29 for aneurism, 20 died; of 2 for hæmorrhage, both died; of 30 done before asepsis, 22 died; one with asepsis recovered. *Meyer* simultaneously thus tied both arteries under asepsis in 5 cases for prostatic hypertrophy, all recovered. *Transperitoneal* aseptic ligature gives the best result: of 9 cases, 2 died; of 5 done for aneurism, 1 died; 1 for hæmorrhage, 1 for tumor, both recovered; of 2 for prostatic disease, 1 died. *Pryor* simultaneously tied both vessels through a median abdominal incision for malignant disease of the uterus in 34 cases, with 1 death.

Ligature of the Gluteal Artery.—The gluteal artery may be injured by direct violence and require ligaturing to arrest the hæmorrhage.

The Anatomical Points.—The gluteal artery passes out of the pelvis at the upper border of the great ischiatic notch, above the pyriformis muscle.

It is accompanied by venæ comites, and is covered by the gluteus maximus muscle.

The linear guide to the vessel, *A, B*, is a line extending from the posterior superior spinous process of the ilium, to the trochanter major, with the thigh rotated inward. The artery lies beneath the junction of the upper and middle thirds of this line (Fig. 184).

The vessel lies at the upper border of the ischiatic notch, which is a deep bony guide to it.

The Operation.—Place the patient on the abdomen, with the thighs extended and rotated inward; make an incision five inches in length in the course of the line already indicated. The direction of the incision will correspond to the course of the fibers of the gluteus maximus muscle, which fibers can be readily separated with the handle of the scalpel and drawn apart and the notch sought for. The artery is then liberated from the accompanying veins, and the ligature is passed in the most convenient manner (Fig. 185).

The Fallacies.—The artery may be mistaken for either of the venæ comites; otherwise no fallacy need occur.

The Results.—The operation itself implies but little danger to the patients.

Ligature of the Sciatic Artery.—The sciatic artery, like the gluteal, may suffer from external violence.

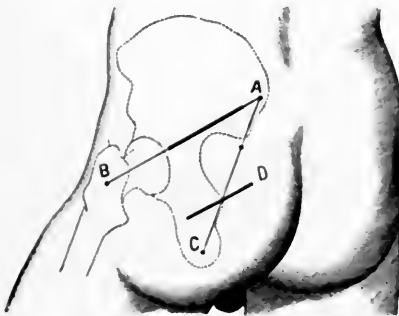


FIG. 184.—Linear guides to gluteal (*A, B*) and sciatic arteries (*A, C, and D*).

The Anatomical Points.—The sciatic artery escapes from the pelvis below the piriformis muscle, and passes downward in the interval between the tuberosity of the ischium and the trochanter major.

The Contiguous Anatomy.—The vessel is covered by the gluteus maximus; the sciatic nerve accompanies it, and it is posterior to the pudic artery.

The linear guides to the vessel are two in number, one (Fig. 184) of which (D) is drawn parallel with the linear guide to the gluteal artery, only

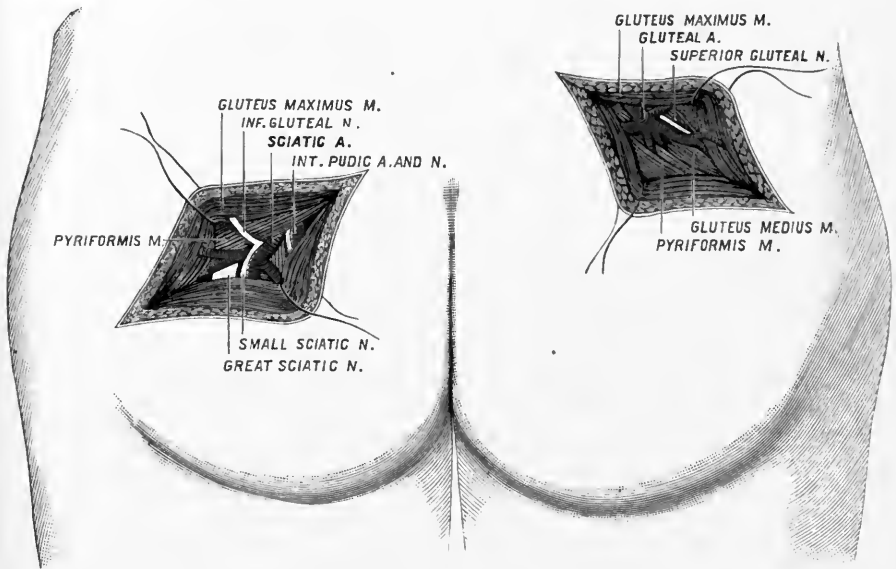


FIG. 185.—Ligature of sciatic artery.

Ligature of gluteal artery.

about an inch and a half lower down. The second, *A, C*, extends from just below the posterior superior spinous process of the ilium to the outer side of the tuberosity of the ischium.

The deep muscular guide is the lower border of the piriformis, beneath which the artery passes from the pelvis.

The Operation.—An incision is made three or four inches in length obliquely across the linear guide in the course of the fibers of the gluteus maximus; the fibers of this muscle are separated and drawn apart, the nerves and veins are pushed aside, and the ligature is carried around the vessel, care being taken to avoid the vein which lies to its outer side.

The Fallacies.—The sciatic artery may be mistaken for the pudic artery, which lies internal to it; however, the direction taken by the respective vessels should make the distinction between them easy.

The Results.—The prognosis as to life is always good so far as the operation itself is concerned.

Ligature of the Internal Pudic Artery.—The internal pudic artery can be ligatured or compressed in the perinæum to control bleeding at the penis.

The Anatomical Points.—The internal pudic artery escapes from the pelvis through the greater sacro-sciatic foramen below the pyriformis muscle, lying internal to the sciatic artery; it then enters the pelvis through the lesser sacro-sciatic foramen, and runs along the inner surface of the ramus of the ischium and pubes, till it divides into terminal branches.

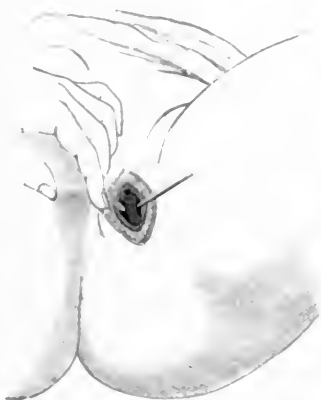

FIG. 186.—Passing needle around pudic artery.

The Contiguous Anatomy.—The vessel runs along the outer boundary of the ischio-rectal fossa, resting upon the obturator internus muscle, in a canal formed by the obturator fascia, and accompanied by the pudic veins and the internal pudic nerve.

The linear guide to the operation in the perinaeum extends from the arch of the pubes to the inner border of the tuber ischii. The artery is situated about an inch and a quarter above the lower margin of the tuber ischii.

This vessel may be ligatured in two situations: 1. At the greater sacro-sciatic foramen (Fig. 185). 2. In the perinaeum (Fig. 186). At the first situation, the incision for ligaturing the sciatic artery is sufficient for ligaturing

this one, the pudic being found internal to that artery, and lower down, accompanied by its veins and the pudic nerve.

The Operation (perinaeum).—The patient is placed in the lithotomy position, and an incision is made about four inches in length in the course of the line indicated; the tissues are carefully divided down to the vessel, which is then isolated from the veins and nerves and needle passed from the vein and vessel tied (Fig. 187). If care be not taken the crus penis will be cut. The introduction of a sound into the urethra will define its outlines, and the danger of wounding it will be obviated.

Ligature of the Dorsalis Penis Artery.—The dorsal artery of the penis may be tied on the dorsum of the organ by making an incision an inch in length at either side of the dorsum, and on a line parallel to the center of its long axis. The artery is superficial, and is attended by veins and nerves, which should be carefully avoided in passing the needle.

Ligature of the External Iliac Artery.—The external iliac artery is an important vessel, surgically, and is frequently ligatured.

The Anatomical Points.—The external iliac artery is about four inches long, and passes obliquely downward and outward to Poupart's ligament, nearly corresponding to a line drawn from the left side of the umbilicus to midway between the anterior superior spinous process of the ilium and the symphysis pubis.



FIG. 187.—Relations of the pudic artery.

The Contiguous Anatomy.

THE RELATIONS OF THE EXTERNAL ILIAC ARTERY. (GRAY.)

In front.

Peritonæum, intestines, and iliac fascia.

Near Poupart's Ligament.	{	Spermatic vessels. Genital branch of genito-crural nerve. Circumflex iliac vein. Lymphatic vessels and glands.
--------------------------------	---	---

*Outer side.*Psoas magnus.
Iliac fascia.

{	External iliac artery.	}
---	---------------------------------------	---

*Inner side.*External iliac vein and vas
deferens at femoral arch.*Behind.*External iliac vein.
Psoas magnus.
Iliac fascia.

It has no superficial muscular or bony guides. The psoas magnus, at the inner border of which it lies, is a most important deep muscular guide. It is ligatured at about the middle of its course.

The Operation.—A strong light should be at hand in this operation. Before beginning, evacuate the contents of the bladder and rectum of the patient. Place him in a recumbent position, with the thigh slightly flexed and the body inclined to the opposite side or in Trendelenburg's posture. A curvilinear incision is then made, with the convexity downward, beginning about an inch above Poupart's ligament and immediately to the outer side of the external abdominal ring, and terminating on a level with, but about two inches internal to, the anterior superior spinous process of the ilium (Fig. 181, *f*). The superficial fascia, aponeurosis of the external oblique, the muscular fibers of the internal oblique and the transversalis, are separately divided upon a grooved director.

The fascia transversalis is carefully picked up with the thumb forceps and a small opening made through it, into which the director is inserted and the fascia divided. The peritonæum and its subserous tissue are then carefully raised from the iliac fascia, and pressed upward and inward until the outer border of the psoas magnus is ascertained, when, after a little further separation, the vessel is felt pulsating at the inner margin of this muscle.

The condensed areolar tissue constituting its sheath is then opened, and the needle carefully inserted between the vein and artery, from within out-

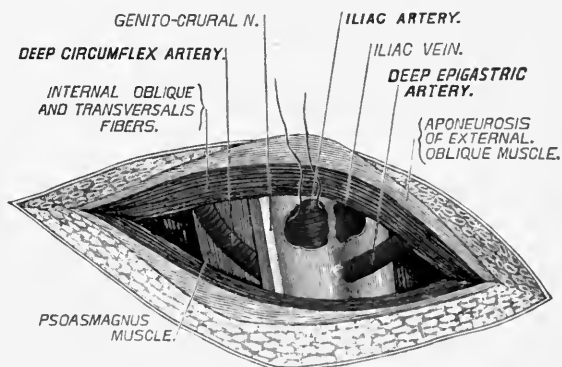


FIG. 188.—Ligature of external iliac artery.

ward (Fig. 188). If the incision be made about a third of an inch above Poupart's ligament (Fig. 181, *d*), the overlying fascia will be exposed without the appearance of the peritonæum, since the latter is reflected upward and backward into the pelvis at a little distance above this point. By this plan the vessel can be ligatured with a minimum amount of danger from disturbance of the deep tissues. The incisions for securing the deep epigastric and deep circumflex iliac arteries near to their origin can be utilized (Fig. 180, *d*) for tying these vessels and the iliac also when needful.

The *transperitoneal method* can be practiced in this instance through a vertical incision, or through the "gridiron" route for appendicitis (Vol. II) if desirable. We are disposed to regard the method favorably when employed for special reasons and with a knowledge of thorough asepsis.

The Fallacies.—The external oblique aponeurosis may be mistaken for the deep layer of superficial fascia. The muscular fibers of the internal oblique will then be mistaken for those of the external oblique. If, however, the direction of the fibers of the respective muscles be recalled, and, furthermore, that the external oblique has no muscular fibers in this situation, the mistake will be quickly rectified. The fascia transversalis may be mistaken for the peritonæum; this fallacy is easily detected by following it downward, when, if it be attached to Poupart's ligament, or passes beneath it, it can not be the peritonæum, and must be the transversalis fascia. If its relations to the previously divided tissues be taken into account, together with its density and opacity, this mistake can hardly occur.

The iliac fascia may be mistaken for the subserous tissue, and be raised together with the peritonæum. Under such circumstances the vessel will be raised upward together with the peritonæum and iliac fascia, and will be felt pulsating in the roof rather than the floor of the operation-wound. This mistake can be avoided by remembering that the iliac and psoas muscles are covered by a dense fascia, which passes out of the pelvis beneath Poupart's ligament, to which it is attached, and that the artery does not lie beneath but upon it.

If an irreducible inguinal hernia exist, or the vein be adherent to the artery, then much difficulty may be experienced in properly placing the ligature without injury to the intestines or the vein. After ligaturing, the wound must be thoroughly closed by carrying the sutures deeply, near to the peritonæum, the superficial tissues (integument and fascia) being united separately. If this be not done, the patient will be exposed to the danger of the occurrence of a hernial protrusion, due to the weakening of the abdominal walls. This is a precaution which should always be taken in operations involving the separation of the peritonæum.

The Results.—Of 164 cases, 129 recovered and 33 died; of 118 done before antiseptics, 93 recovered, 25 died; of 44 under asepsis, 36 recovered, 8 died. Of the 118, 81 were for aneurism, 74 recovered, 7 died; 35 for hæmorrhage, 20 recovered, 15 died; of 2 for tumor, both died. One of the 118 was done *transperitoneally* and recovered; 34 were for aneurism, 29 recovered, 5 died; 9 for hæmorrhage, 6 recovered, 3 died; one for tumor recovered. Of 25 done *extraperitoneally*, 20 recovered and 5 died; of 19 done *transperitoneally*, 16 recovered and 3 died.

Ligature of Deep Epigastric Artery.—This artery arises from the lower portion of the external iliac (Fig. 189) and runs upward toward the umbilicus, between the peritonæum and the transversalis. It lies at the inner border of the internal abdominal ring (see *Hernia*, Vol. II).

The Linear Guide.—A line extending from the umbilicus to the middle of Poupart's ligament corresponds to the course of the vessel. The vessel may be tied after successive division of overlying tissues near to the origin, as demonstrated by Fig. 188, as well as three or four fingers' breadths higher than this (Fig. 189).

The Operation.—An incision is made about three inches in length, at either of the foregoing situations, parallel with Poupart's ligament. The various layers of the abdominal wall are then divided separately upon a grooved director until the fascia transversalis is reached, which is opened over the artery, the connective tissue and the veins separated from it, and the

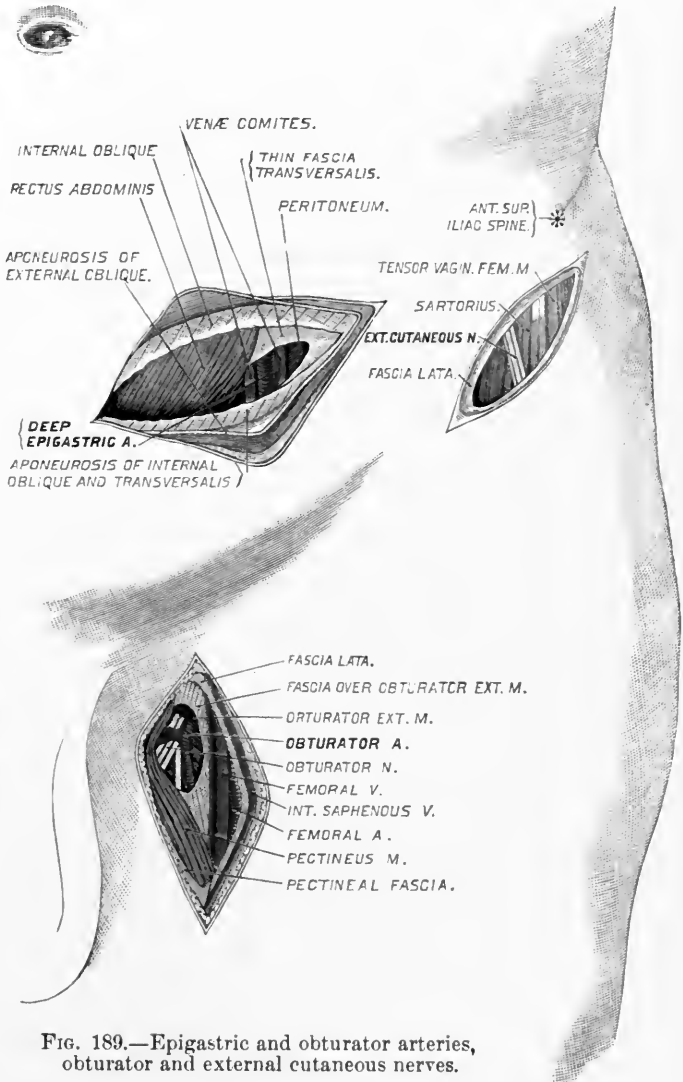


FIG. 189.—Epigastric and obturator arteries, obturator and external cutaneous nerves.

ligature properly placed (Fig. 189). The wound should then be carefully closed, and the patient kept quiet in a recumbent posture until the tissues are firmly united, else a weak point in the abdominal walls may follow at the seat of operation.

Ligature of the Deep Circumflex Iliac Artery.—The deep circumflex iliac artery can be secured at two situations: 1, at the internal abdominal ring; 2, near the anterior superior spinous process of the ilium. *In the first situation* it may be tied at the same incision as that for the epigastric artery (Fig. 180, *d*). *In the second* it may be secured through an incision made parallel to and just above Poupart's ligament, at the outer side of the course of the epigastric artery (Fig. 181, *e*), through the various tissues anterior to the transversalis fascia, which is then opened, the artery isolated (Fig. 188) and tied.

Ligature of the Femoral Artery.—The femoral artery is of special surgical significance on account of its exposed situation and the frequent presence of morbid growths in the thigh.

The Anatomical Points.—The femoral artery extends from Poupart's ligament to the lower extremity of Hunter's canal, at the junction of the middle and lower thirds of the thigh, where it terminates in the popliteal. About two inches below Poupart's ligament it gives off the profunda femoris or deep femoral artery.

The Contiguous Anatomy.

THE RELATIONS OF THE COMMON FEMORAL ARTERY. (GRAY.)

In front.

Skin and superficial fascia.
 Superficial inguinal glands.
 Iliac portion of fascia lata.
 Prolongation of transversalis fascia.
 Crural branch of genito-crural nerve.
 Superficial circumflex iliac vein.
 Superficial epigastric vein.

Inner side.
 Femoral vein.

{ **Common**
femoral
artery. }

Outer side.
 Anterior crural nerve.

Behind.

Prolongation of fascia covering iliacus muscle.
 Pubic portion of fascia lata.
 Nerve to pectineus.
 Psoas muscle.
 Pectineus muscle.
 Capsule of hip joint.

THE RELATIONS OF THE SUPERFICIAL FEMORAL ARTERY. (GRAY.)

In front.

Skin, superficial and deep fascia.
 Internal cutaneous nerve.
 Sartorius muscle.
 Aponeurotic covering of Hunter's canal.
 Internal saphenous nerve.

Inner side.
 Adductor longus.
 Adductor magnus.
 Sartorius.

{ **Superficial**
femoral
artery. }

Outer side.
 Long saphenous nerve.
 Nerve to vastus internus.
 Vastus internus.
 Femoral vein (below).

Behind.

Femoral vein.
 Profunda artery and vein.
 Pectineus muscle.
 Adductor longus.
 Adductor magnus.

The *linear guide* to the artery, throughout its whole course, is a dotted line drawn from midway between the anterior superior spinous process of the ilium and the symphysis pubis to the inner condyle of the femur (Fig. 184).

A dotted line drawn from the origin of the adductor longus to the insertion of the adductor magnus tendon into the internal condyle of the femur also corresponds to the femoral artery in Hunter's canal.

The Muscular Guides.—The sartorius is a muscular guide; the artery lies at the inner border in the upper third, behind the muscle in the middle, and at the outer side in the lower third. The better muscular guide to the lower third is the inner border of the tendon of the adductor magnus. This tendon can be quite easily felt, but care must be taken, otherwise it will be mistaken for one of the ham-string tendons.

The femoral artery is *ligatured at three situations*: 1, just below Poupart's ligament; 2, at the apex of Scarpa's triangle, or about four inches below the ligament; 3, in Hunter's canal. The most favorable situations are at the apex of Scarpa's triangle and in Hunter's canal. However, circumstances often arise which necessitate its being tied, irrespective of the stereotyped situations.

The Operation. The First Situation—Common Femoral (Fig. 190, a).—The vessel can be ligated immediately below Poupart's ligament through either of two incisions: one is made in the long axis of the vessel (dotted line), the other parallel with the lower border of the ligament (Fig. 181, g). The former is, however, the better incision. The patient is placed on the back and the thigh flexed and rotated outward. The pulsation of the artery is noted by the finger, then an incision about three inches in length is made through the integument and subcutaneous tissues; the lymphatic glands drawn aside, fascia lata divided on a director in the usual manner, and the arterial sheath, which is very dense, is opened, and the needle passed from within outward. The vein will be noticed at its inner side, inclosed in a common sheath with it, but separated from the artery by a fibrous partition. The attention of the surgeon should be directed to the pinkish-white pulsating vessel rather than to seeking for the vein (Fig. 191). If the attention and manipulations be directed toward the artery, the vein will remain undisturbed within its compartment. A ligature is rarely applied at this situation on account of the increased danger of the occurrence of gangrene and secondary hæmorrhage. Although the latter can be obviated by ligature of the branches of the vessels contiguous to the seat of the operation, yet this measure of security against hæmorrhage increases the liability of gangrene. Therefore, when possible, ligature of the external iliac artery is preferable to the ligature of the femoral at this location.

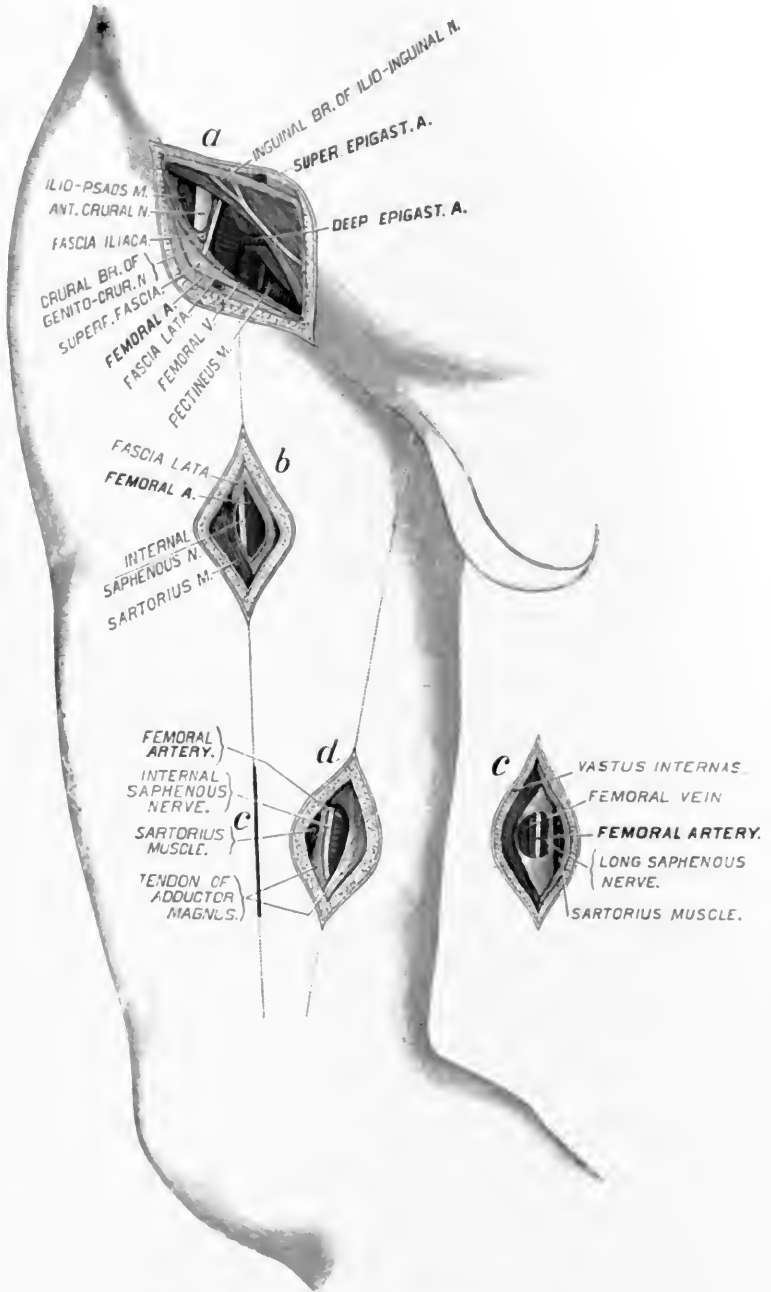


FIG. 190.—Ligature of femoral artery.

a. Ligature of common femoral. b. Ligature of superficial femoral at apex of Scarpa's triangle. c, d. Ligature in Hunter's canal.

The Second Situation—Superficial Femoral.—At the apex of Scarpa's triangle (Fig. 190, *b*), or about four inches below Poupart's ligament.

Anatomical Points.—The saphenous vein runs along the inner side of this region, and can be located by pressing it above, thus causing distention

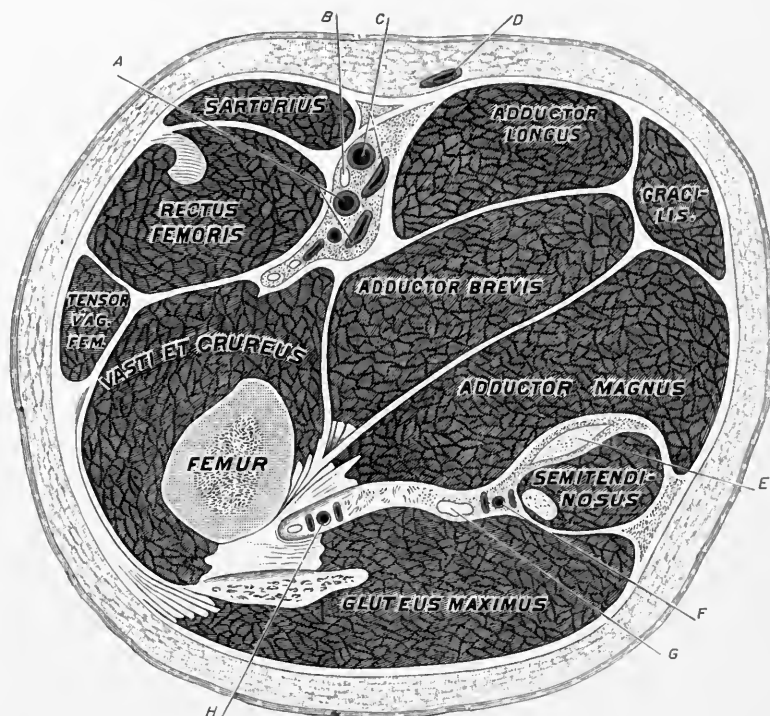


FIG. 191.—Transverse section at upper third of right thigh.

A. Profunda artery and vein. B. Long saphenous nerve. C. Common femoral artery and vein. D. Internal saphenous vein. E. Semimembranosus. F, H. Gluteal vessels. G. Sciatic nerve.

below. The femoral vein lies to the inner side, somewhat more posteriorly here than above (Fig. 192). Branches of the internal cutaneous nerve lie in front, and the long saphenous lies deeper and to the outer side of the vessel.

The Operation.—Place the limb as in the preceding operation, and make an incision about four inches in length along the inner border of the sartorius muscle; divide the tissues down to the fascia lata, draw the sartorius to the outer side, and the pulsation of the vessel can be felt and perhaps seen beneath the fascia; cautiously open the fascia lata and the sheath of the vessel, and pass the needle from within outward. The presence of a broad sartorius muscle diminishes the size of the triangle, correspondingly covers the vessel and thus obscures it, thereby adding to the difficulty of the operation.

The Third Situation—Superficial Femoral—In Hunter's Canal (Fig. 190, *c* and *d*).—Hunter's canal is located at the middle third of the thigh, and at the inner side.

The Operation.—Flex the thigh on the pelvis and the leg on the thigh, and rotate the thigh outward; an incision is then made along the outer border of the tendon of the adductor magnus, beginning at a point a little above the junction of the middle and lower thirds of the thigh, and extend-

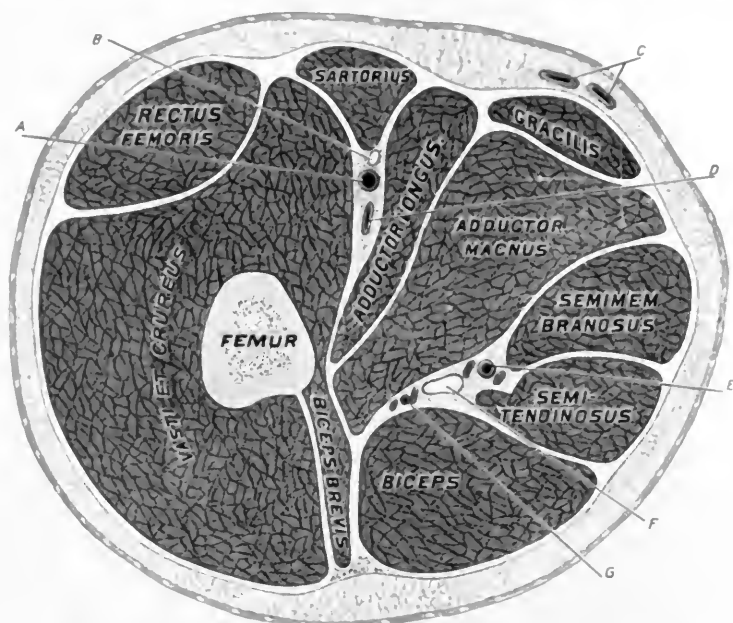


FIG. 192.—Transverse section at middle third of right thigh.

A. Femoral artery. B. Long saphenous nerve. C. Internal saphenous veins. D. Femoral vein. E. Profunda artery and veins. F. Sciatic nerve. G. Small sciatic artery and veins.

ing upward (Fig. 190, *d*) about four inches through the integument and fascia, when the tendon will be readily felt. If the sartorius be in the way, it should be drawn to the inner side. After the intervening soft parts are pushed aside, the fibrous canal (Hunter's canal) in which the artery is contained will be exposed. This structure is formed at the inner side, by the tendon of the adductor magnus, at the outer, by the inner border of the vastus internus muscle, and elsewhere by the fibrous reflections extending between the muscles. The canal is cautiously opened, and the long saphenous nerve is seen resting upon the vessel; the nerve is drawn aside and the needle is passed from without inward, thus avoiding the femoral vein, which is now located posteriorly and externally to the artery (Figs. 193, and 190, *d*). The vessel can be ligatured at this situation by making an incision of a similar length on the linear guide first described (Fig. 190, *c c*). It is not so satisfactorily secured, however, by this as by the former method.

The Fallacies.—The sartorius muscle may be mistaken for other muscles lying in the general course. If, however, it be recollected that no other muscles run in exactly the same direction on the anterior surface of the

thigh as the sartorius, and that it is superficial throughout the entire course, no great confusion can arise. The lymphatic glands that lie over the sheath of the vessel in the upper portion of its course may be mistaken for the vessel itself, owing to their color and to the transmitted pulsation. The glands are irregular, movable, and can be raised upward, when the apparent pulsation will cease; moreover, the artery is beneath the fascia lata, and the glands are above it.

The tendon of the adductor magnus may be mistaken for the tendon of the semimembranosus or semitendinosus. This mistake will be avoided if the tendons be traced downward; the two latter will pass behind the internal condyle, while the former will be inserted into it. Care must be taken in ligaturing the artery at the apex of Scarpa's triangle not to make the incision too low down.

The width of the hand below Poupart's ligament is a good practical guide to the apex. In ligaturing the artery in Hunter's canal, it should be remembered that the canal is located at the middle third of the thigh, or otherwise the incision will be made too low down, and the upper portion of the popliteal artery secured instead.

In a very small number of cases (four) the femoral was double; in a like number it passed behind instead of in front of the thigh. If it be double, the portion exposed will be smaller than normal, and the application of the ligature will not be

followed by the anticipated distal circulatory manifestations. If the vessel be not found in its common location it will be necessary to seek for it elsewhere, and deep pressure may enable one to detect its anomalous situation. It may be located behind the thigh or when continuous with the internal iliac, escape from the pelvis through the sacro-sciatic foramen. The femoral vein may lie at the inner side at the apex of Scarpa's triangle and behind in Hunter's canal. The author has met with an instance of this kind in ligaturing the artery at the latter situation.

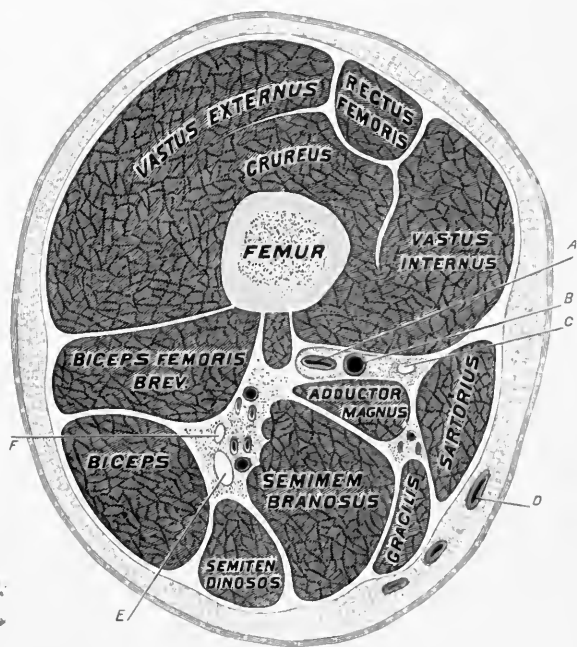


FIG. 193.—Transverse section at lower third of right thigh. *A.* Femoral vein. *B.* Superficial femoral artery. *C.* Long saphenous nerve. *D.* Internal saphenous vein. *E.* Internal popliteal nerve. *F.* External popliteal or perineal nerve.

The Results.—Of 41 ligatures of the common femoral, 10 died; of 29 done before asepsis, 9 died; of 11 for aneurism, 3 died; of 17 for hæmorrhage, 5 died; 1 done for tumor, which died.

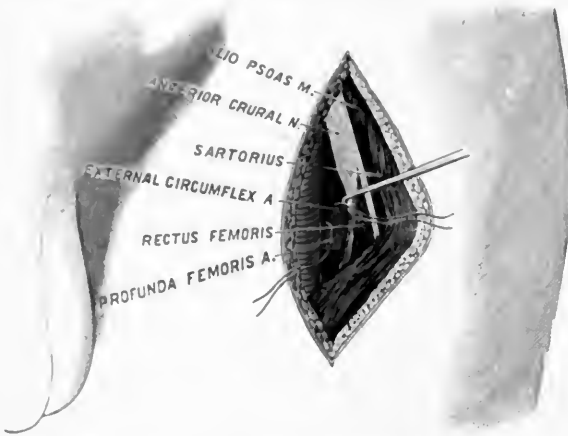


FIG. 194.—Ligature of the deep femoral and circumflex arteries.

Of 12 tied aseptically, 1 died; of the 12, 7 were for aneurism, 1 died; 5 for hæmorrhage, all recovered. Of 343 ligatures of the superficial femoral, 72 died; in 309 cases, tied before asepsis, 68 died; of 244 done for aneurism, 55 died; of 60 for hæmorrhage, 12 died; of 5 done for tumor, 1 died. Of 34 tied under asepsis, 4 died; of the 34, 24 were for aneurism, and 3 died; 10 for hæmorrhage, 1 died. An older series shows the following: The common femoral has been ligatured 31 times for aneurism, with a mortality of 40 per cent, hæmorrhage occurring in 60 per cent of the cases. The superficial femoral has been ligatured 204 times, with a mortality of 50 cases.

Ligature of the Deep Femoral Artery (the Profunda) and the External Circumflex.

—The relation which the perforating branches of this vessel bear to the femur and their liability to injury in fracture is of much importance. The author has seen a case of death from secondary hæmorrhage follow rupture of the third perforating branch, caused by fracture of the femur (Figs. 194 and 191).

The Operation.—The profunda and circumflex arteries are tied through the vertical incision for ligature of the common femoral, and sought for at the outer side of this artery.

The vessel is carefully isolated, that the ligature may be applied a proper distance from the collateral branches.

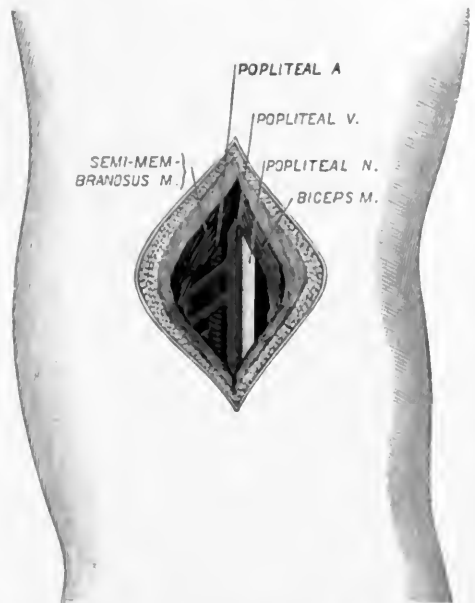


FIG. 195.—Ligature of the popliteal artery at the upper third.

The Fallacies.—The profunda may arise from the inner or back portions of the common femoral. If it be not found in the usual place, it should be sought for at the latter situations.

Ligature of the Popliteal Artery.—The intimate association of the popliteal artery with the posterior surface of the knee joint should not be forgotten, especially in excision. The author knows of an instance of the wounding of this vessel in excision of this joint.

The Anatomical Points.—The popliteal is continuous with the femoral artery, and begins at the junction of the middle and lower thirds of the thigh, at the termination of Hunter's canal, and passes with a slight obliquity downward and outward to the lower border of the popliteus muscle.

The Contiguous Anatomy.

—At the upper third of the space the internal popliteal nerve is more superficial than the vein and artery. The vein lies in close contact with the artery and between it and the nerve. The artery is the innermost of the three, and is the most deeply situated, resting close to the posterior surface of the femur. At the lower third the nerve is still the most superficial, but lies upon and to the inner side, and more superficial than the artery, which rests upon the popliteus muscle. The artery should *not* be tied at its middle third, on account of the large number of branches given off at this point, together with the fact of its contiguity with the knee joint (Fig. 196).

The Linear Guide.—The linear guide to the vessel begins a little to the inner side of the middle of the upper portion of the popliteal space, and passes midway between the condyles of the femur (Fig. 195).

The Muscular Guides.—The artery at the upper third lies to the inner border of the semimembranosus, at its lower third, midway between the heads of the gastrocnemius muscle.

The artery can be *ligatured at three situations*—upper and lower thirds, and below the inner tuberosity of the tibia. The position of the limb for ligaturing, the linear guide, and the anatomy are substantially similar at the last situation as in the upper part of the posterior tibial. Ligaturing here is rarely practiced.

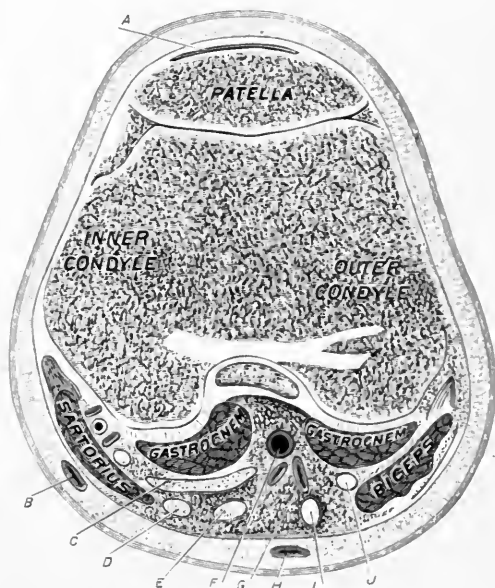


FIG. 196.—Transverse section through the right knee joint.

- A. Bursa patellæ. B. Internal saphenous vein. C. Semimembranosus. D. Gracilis. E. Semitendinosus. F. Popliteal artery. G. Popliteal vein. H. External saphenous vein. I. Internal popliteal nerve. J. External popliteal or peroneal nerve.

The Operation at the Upper Third (Fig. 195).—The patient can be placed on the face or the back; if on the latter, the thigh should be well flexed and rotated outward. The former position is more convenient for the surgeon, but is objectionable on account of greater difficulty in the administration of the anæsthetic. The patient may be placed on the side corresponding to that of the artery to be tied, with the thigh extended and the opposite one flexed on the pelvis.

An incision is made, about four inches in length, along the outer border of the semimembranosus through the integument and fascia, and is deepened by separating the areolar tissue with the handle of the scalpel. The nerve will be first seen, and, when drawn outward, the vein will be found lying more deeply and internal to it; if the vein be now carefully isolated and drawn outward, the artery will be noted at the inner side, and is then carefully separated from the surrounding tissues and the needle carried around it from without inward.

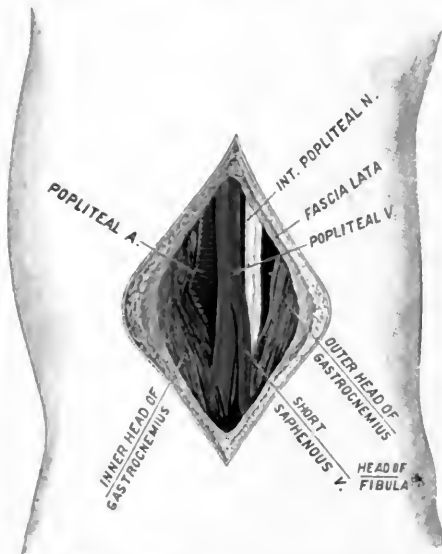


FIG. 197.—Ligature of popliteal artery at the lower third.

The Operation at the Lower Third (Fig. 197).—Make an incision midway between the heads of the gastrocnemius, carefully avoiding the external saphenous vein and nerve, as they pass between the heads of that muscle; separate the connective tissues with the handle of the scalpel, draw the vein and nerve to the inner side, and pass the needle from within outward.

The Fallacies.—The tendon of the semitendinosus may be mistaken for the tendon of the semimembranosus muscle. The semimembranosus has a large fleshy belly, which extends much nearer to the median line of the popliteal space than does the semitendinosus. Sometimes there are two popliteal veins, one on either side of the vessel, and rarely two popliteal arteries.

The Results.—The popliteal is seldom ligatured unless ruptured. Of 9 cases ligatured, 3 died. Of 5 tied before asepsis, the 2 for aneurism recovered; 3 for hæmorrhage died. Of four aseptically, 2 for hæmorrhage, 1 for aneurism, and 1 for elephantiasis, all recovered.

Ligature of the Anterior Tibial Artery.—This artery is often injured in fracture of the leg.

The Anatomical Points.—It arises from the popliteal just below the popliteus muscle, passes forward between the bones above the interosseous membrane downward on the anterior surface of this membrane to the ankle joint, becoming the dorsalis pedis artery.

The linear guide to the vessel is drawn on the anterior surface of the leg from the inner border of the head of the fibula (*) to midway between the malleoli (Fig. 198).

The muscular guide is the outer border of the tibialis anticus muscle. This vessel can be tied at three situations — at its upper, middle, and lower thirds; but two—the middle and lower thirds—are more than sufficient for all practical purposes.

The Operation. Upper Third (Fig. 198, a).—Ligature at this situation is tedious and difficult, on account of the great depth of the vessel, and should not be attempted unless circumstances demand it. Fig. 193 shows the deep relations of the vessel.

The Middle Third (Fig. 198. b).—The artery in this situation lies quite deeply, and a good light must be had to see the entire extent of the operation-wound (Fig. 200).

The Operation.—Place the patient on the back with the thighs extended, the leg turned inward, and the foot forcibly extended to mark the outlines of the tibialis anticus muscle. Make an incision four or five inches in length on the line indicating the course of the artery, down to the fascia, which is then carefully divided. The

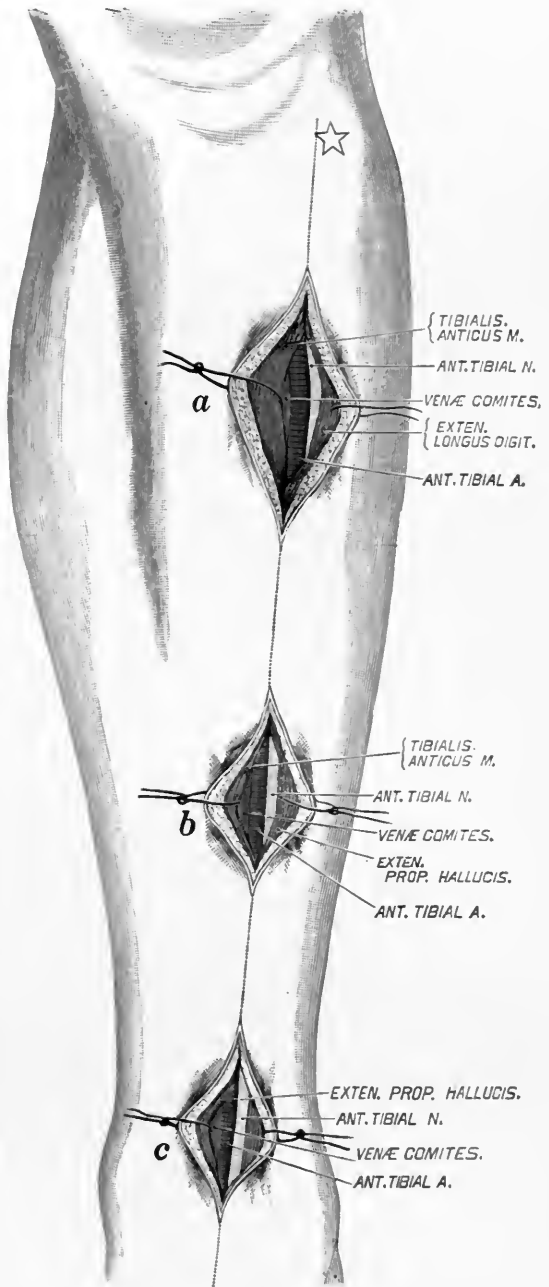


FIG. 198.—Ligature of anterior tibial artery.

a. At upper third. b. At middle third.
c. At lower third.

aponeurotic structure is then severed along the line of apposition between the tibialis anticus and the extensor longus digitorum muscles; it should

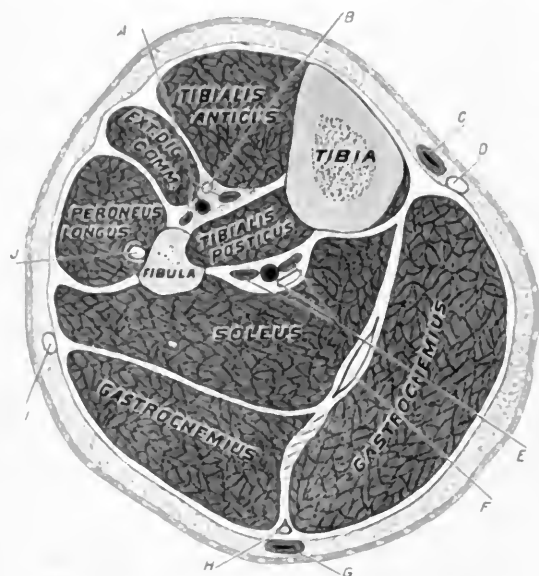


FIG. 199.—Transverse section at upper third of right leg.

- A. Anterior tibial artery and veins. B. Anterior tibial nerve. C. Internal saphenous vein. D. Internal saphenous nerve. E. Posterior tibial artery, veins, and nerve. F. Tendon of plantaris. G. External saphenous vein. H. Short saphenous nerve. I. External cutaneous nerve. J. Perineal nerve.

incision along the external border of the tendon on the linear guide about three inches in length. Divide the fascia, and seek with the finger for the space between the tibialis anticus and the extensor proprius pollicis muscle, which latter muscle is at the inner side of the vessel below; flex the foot, separate the muscles from each other, and the artery will be seen accompanied by its veins and nerve, the latter lying in front and a little to the outer side (Fig. 201); isolate the artery, and place the ligature by passing the needle from without inward.

The Fallacies.—The outer surface of the head of the tibia is very liable to be mistaken for the head of the fibula, which error will locate the linear guide too far to the inner side of the leg, and cause the incision to be made over the belly of the tibialis anticus muscle. To avoid this error it must be remembered that the head of the fibula is more posteriorly, and constitutes the most external bony prominence at this part of the limb.

The septum between the tibialis anticus and the extensor longus digitorum may be indistinct or absent; then the outer border of the tibialis anticus muscle should be sought for and determined—1, by the forcible extension of the tarsus; 2, by the resistance to lateral pressure; 3, by the line

likewise be divided transversely inward to a limited extent, to admit of the wider separation of these muscles. The foot is then flexed, and, with the finger, or the handle of the scalpel, the line of separation is extended directly down to the vessel; separate the surfaces of the wound with spatulae, then the artery with its nerve and accompanying veins will be seen (Fig. 200), the nerve being in front and on the outer side; separate the veins from the artery, and pass the ligature from without inward.

The Operation at the Lower Third (Fig. 198, c).—With the limb as in the preceding operation, extend the foot to mark the course of the tendon of the tibialis anticus; make an

indicating the interspace which may be seen at the lower extremity of the incision when invisible above.

The anterior tibial artery may be rudimentary or absent; it may run more superficially than common. So long, however, as it keeps in the proper line the pulsations will lead to its detection.

The venæ comites cling so closely to the vessel that persistent efforts at separation almost invariably lacerate the veins, and therefore it is better, on the whole, that they be tied along with the artery than that the efforts of separation be prolonged.

Ligature of the Dorsalis Pedis Artery. *The Anatomical Points.*—This vessel is a continuation of the anterior tibial (Fig. 202). It begins at the ankle joint and passes downward between the metatarsal bones of the great and second toes. The dorsalis pedis is tied in but one situation, which is on the linear guide directly continuous with that of the anterior tibial artery (Fig. 198).

The muscular guide is the outer border of the tendon of the extensor proprius hallucis (Fig. 202).

The Operation.—Extend the tarsus and forcibly flex the great toe to make prominent the tendon of the extensor proprius hallucis; make an incision about three inches in length along the outer border of this muscle, commencing at the bend of the ankle; divide the fascia and expose the fleshy inner portion of the extensor brevis digitorum muscle; draw the muscle outward, when the artery and its satellite veins will appear; separate the artery from the veins, and pass the needle as best suits the convenience of the operator.

The Fallacy.—The artery may pass outside of the line indicating its proper course.

Ligature of the Posterior Tibial Artery.—The posterior tibial artery is sometimes ruptured in fracture of the tibia.

The Anatomical Points.—The posterior tibial is an artery of considerable size

which comes from the popliteal at the lower border of the popliteus muscle. It passes obliquely to the tibial side of the leg, there goes downward between

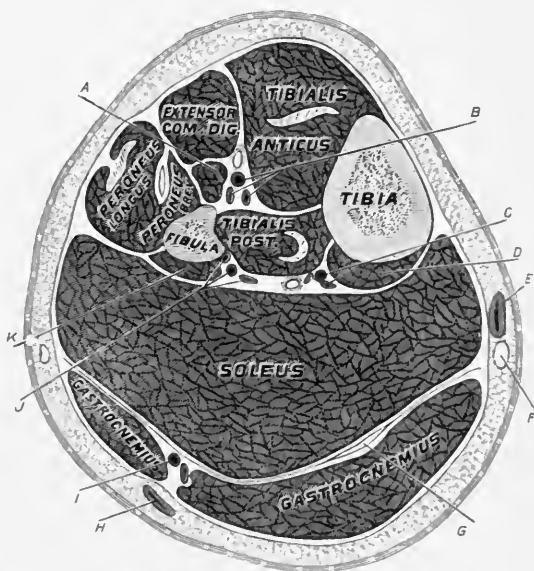


FIG. 200.—Transverse section of right leg at middle third.

- A. Extensor proprius hallucis. B. Anterior tibial artery, veins, and nerve. C. Posterior tibial artery, veins, and nerve. D. Flexor longus digitorum. E. Internal saphenous vein. F. Internal saphenous nerve. G. Tendon of plantaris. H. External saphenous vein. I. Muscular branches. J. Peroneal artery and veins. K. Flexor longus hallucis.

the superficial and deep layers of muscles to a point midway between the internal malleolus and inner tuberosity of the os calcis, terminating a little further on in the external and internal plantar arteries.

The linear guide to the vessel is drawn from the middle of the popliteal space to midway between the inner malleolus and the tuberosity of the os calcis. This guide is not a feasible one, since to reach the artery by cutting upon the guide necessitates the division of the fibers of the muscles of the calf of the leg.

The linear guide to the operation is a line located three fourths of an inch behind the internal border of the tibia at the middle and lower thirds of the leg (Fig. 203).

The Muscular Guide.—At the middle third the artery lies beneath the soleus; at the lower third, to the outer border of the flexor longus digitorum. *It may be ligatured at three situations:* at the middle third, at the lower third, and as it passes behind the inner malleolus.

The Operation at the Middle Third (Fig. 203, a).—Place the patient on the back, flex the leg on the thigh and the thigh on the pelvis, rotating

the thigh outward so that the leg will lie on the outer side. Make an incision on the linear guide to the operation about four inches in length; divide the deep fascia, recognize the inner border of the gastrocnemius, beneath which will be seen the fibers of the soleus, which should be divided carefully transversely or longitudinally—the latter preferable—down to the pale yellow aponeurosis on its under surface; draw apart the fibers of the soleus, and make an opening through the aponeurosis about an inch and a half from the inner border of the tibia, of sufficient size to expose the artery, which is found beneath attended by its veins and the posterior tibial nerve (Fig. 200); draw the nerve to the outer side, separate the vessel from the veins, and pass the needle from without inward.

The Operation at the Lower Third (Fig. 203, b).—Place the limb as before; make an incision in the course of the linear guide about three inches in length; divide the integument and fascia in the

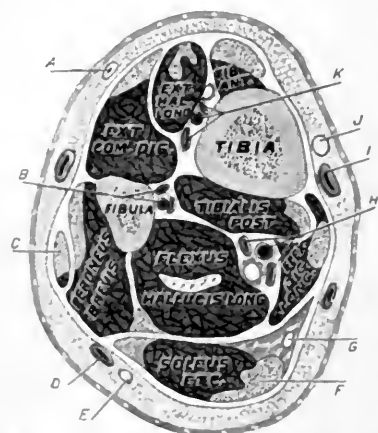


FIG. 201.—Transverse section through right leg at lower third.

- A. Musculo-cutaneous nerve. B. Peroneal artery and veins. C. Peroneus longus. D. External saphenous vein. E. External saphenous nerve. F. Tendo Achillis. G. Tendon of plantaris. H. Posterior tibial artery, veins, and nerve. I. Internal saphenous vein. J. Internal saphenous nerve. K. Anterior tibial artery, veins, and nerve.

usual manner; separate the borders of the wound, then divide the aponeurosis (which binds down the deep layer of muscles) at about one inch from the internal border of the tibia, push aside the fat, and the vessel with its nerve and veins will be found at the outer border of the flexor longus digitorum (Fig. 201); separate the artery from the veins if prac-

licable, push the nerve to the outer side, and pass the needle from without inward.

The Operation between the Os Calcis and Internal Malleolus.—Place the foot on its outer surface and make a curved incision about three inches in length, with the concavity uppermost and the center at a point midway between the malleolus and the inner tuberosity of the os calcis (Fig. 203, *c*). Divide the fascia and the internal annular ligament on a director, using caution, since the artery lies directly beneath the ligament; isolate the vessel from the veins, and pass the needle from without inward. In going through the superficial tissues, small branches of the saphenous vein will be divided unless care be taken. In old people both these and the venæ comites often become varicose, which condition increases the difficulty of finding and isolating the artery. It is better not to attempt to ligature the artery in this situation if marked evidence of varicosities are present.

The Fallacies.—The posterior tibial may be double, rudimentary, or absent. In either instance the peroneal is usually increased in size. If the veins are closely associated with the artery they should be tied along with that vessel. Carefully avoid opening the sheaths of the tendons that are contiguous to the vessel.

Ligature of the Peroneal Artery.—The peroneal artery is rarely ligatured except at the seat of the injury demanding it.

The Anatomical Points.—The peroneal artery arises from the posterior tibial at about one inch below the popliteus muscle, passes obliquely outward to the inner border of the fibula (Figs. 194 and 195), along which it descends to the lower third of the leg, and is finally distributed to the outer side of the ankle. It may be ligatured at the middle and at lower thirds of the leg.

The linear guide to the vessel is a line drawn from the posterior border of the head of the fibula (Fig. 204, *) to the external border of the tendo Achillis at its insertion.

The Operation.—Extend the foot and make an incision about four inches in length along the guiding line parallel with the external border of the fibula (Fig. 204, *a*). Separate the attachments of the soleus and the flexor longus hallucis from each other, and the artery will be found at the inner side

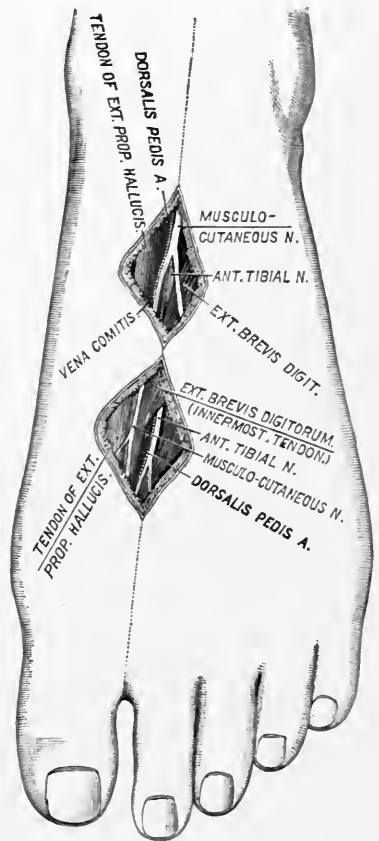


FIG. 202.—Ligature of dorsalis pedis artery.

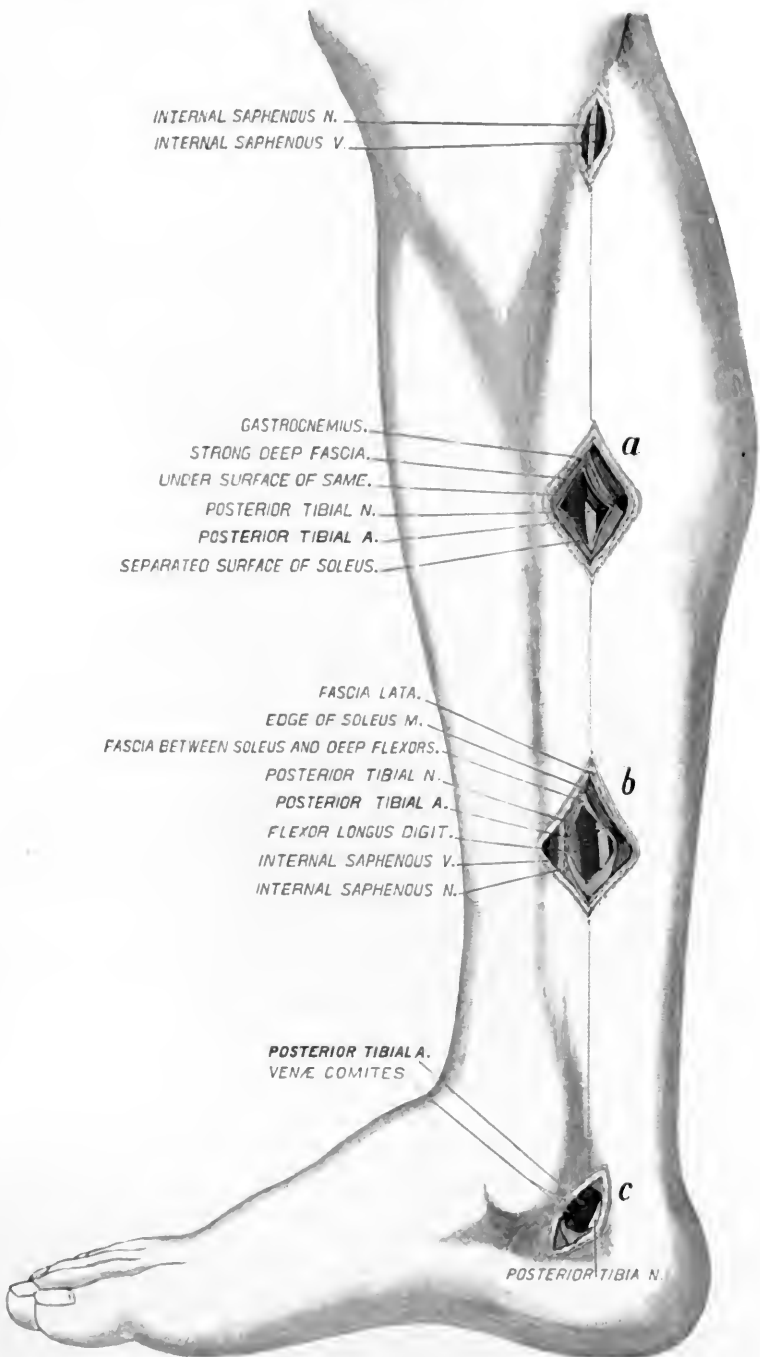


FIG. 203.—Ligature of posterior tibial artery.

a. At middle third. *b.* At lower third. *c.* Between os calcis and internal malleolus.

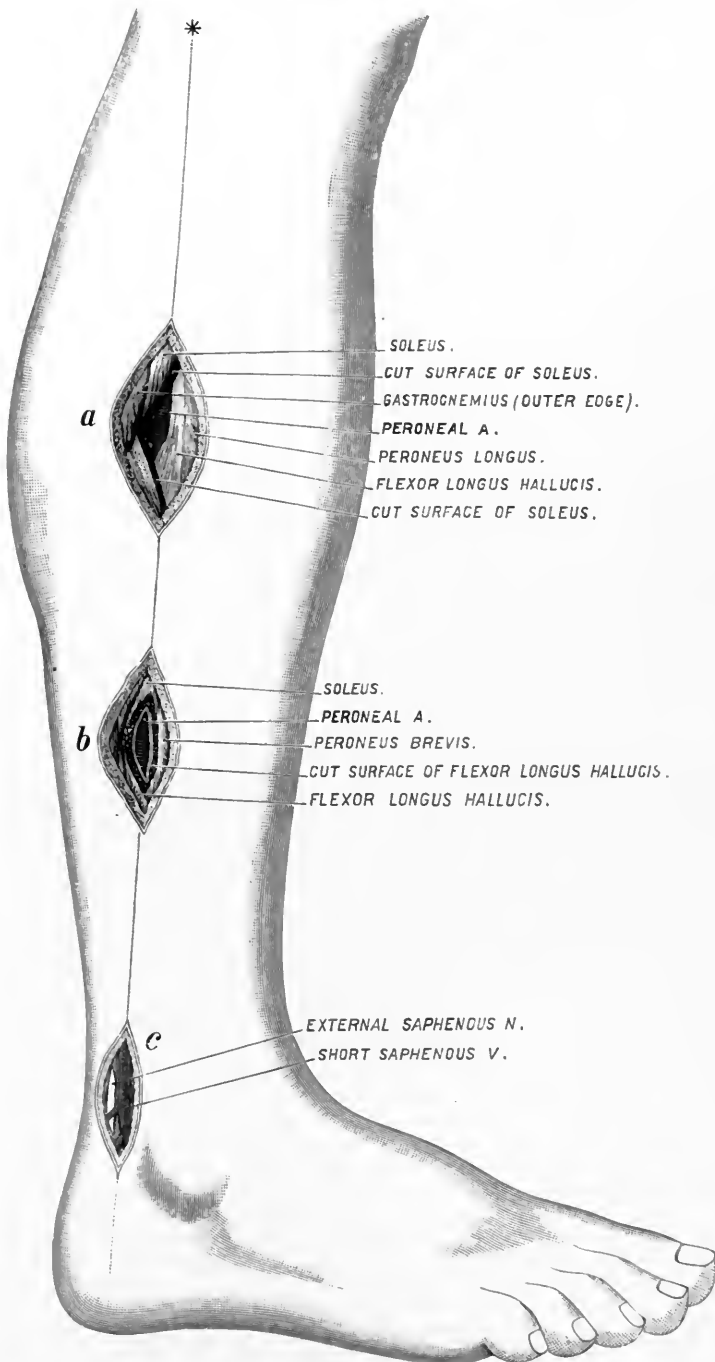


FIG. 204.—Ligature of peroneal artery.

a. At middle third. *b.* At lower third. *c.* The saphenous nerve and vein.

of the flexor longus hallucis close to the fibula. The venæ comites may be included in the ligature.

The Fallacies.—The peroneal artery is rarely absent. It may be overlooked, and the posterior tibial tied instead. If its close relation to the fibula be remembered this mistake will not occur.

Ligature of the Innominate Artery.—The innominate artery is invested with great significance on account of its relation to aneurism and its resistance of the curative effects of the ablest surgical endeavor.

The Anatomical Points.—The innominate artery arises from the beginning of the transverse arch of the aorta in front of the left common carotid, passes obliquely upward and outward to the upper border of the right sterno-clavicular articulation, where it divides into the right common carotid and right subclavian arteries.

The Contiguous Anatomy.

THE RELATIONS OF THE INNOMINATE ARTERY. (GRAY.)

In front.

Sternum.

Sterno-hyoid and sterno-thyroid muscles.

Remains of thymus gland.

Left innominate and right inferior thyroid veins.

Inferior cervical cardiac branch from right pneumogastric nerve.

Right side.

Right vena innominata.

Right pneumogastric nerve.

Pleura.

} **Innominate** }
 } **artery.** }

Left side.

Remains of thymus.

Left carotid.

Left inferior thyroid vein.

Trachea.

Behind.

Trachea.

While this vessel has no *practical linear* or *muscular* guides, still a line drawn from the junction of the first two pieces of the sternum to the right sterno-clavicular articulation indicates the substernal course of the vessel. However, it should not be forgotten that this course is not an invariable one, for in many instances it bifurcates above or below this point, more frequently at the latter situation.

The remaining guides to the vessel are the trachea, common carotid, and subclavian arteries. The trachea lies immediately behind the artery and is crossed obliquely by it. The carotid and subclavian arteries lead down to the point of the bifurcation of the innominate.

Numerous incisions are described for gaining access to the vessel. The one limited to the soft parts, which is best calculated to afford the greatest amount of room, was employed in 1818 by the late Valentine Mott, when the vessel was ligated first. Resection of sternum is practiced in same methods.

The Operation.—Place the patient on the back, with the shoulders somewhat raised and the head turned backward and to the left side. This position draws the artery upward from behind the sternum. An incision is then made three inches in length, extending along the upper border of the clavicle to opposite the center of the episternal notch, which is joined by another of

similar length directed along the anterior portion of the sterno-mastoid muscle (Fig. 205, *d*). The triangular flap thus formed, consisting of the integument, superficial fascia, and platysma, is turned upward and outward. The portions of the sterno-cleido-mastoid muscle corresponding to the horizontal incision, and the sterno-hyoid and sterno-thyroid muscles, are divided

on a director and turned aside. The inferior thyroid veins, if they now come into view, are cautiously drawn aside, the deep cervical fascia is torn or cut through, and the sheath containing the common carotid artery, pneumogastric nerve, and internal jugular vein is brought into view. Open the carotid compartment of the sheath, draw the vein and nerve to the outer side, and follow the carotid down to the subclavian, the origin of which should be promptly exposed. The upper portion of the innominate is then separated from its important connections by the finger or a blunt director; the left vena innominata is depressed, and the right vena innominata, right internal jugular, and the pneumogastric nerve are carried to the right, and the aneurism needle is passed from below upward, and from behind forward and inward, in close contact with the vessel (Fig.

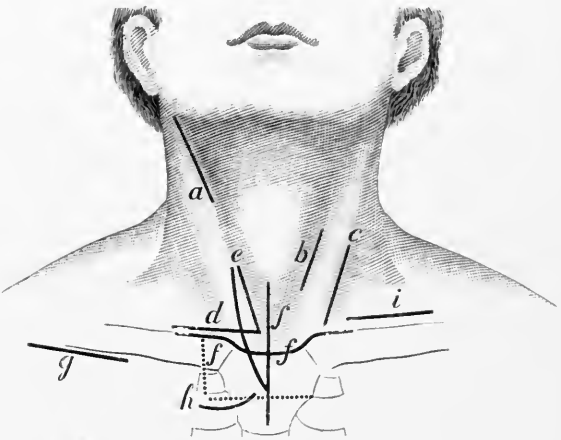


FIG. 205.—Linear guides. *a*. For ligature of external carotid. *b*. For ligature of common carotid. *c*. For ligature of vertebral. *d*. For ligature of innominate (Mott). *e*. For same (Kocher). *f*. For same (Bardenheuer). *g*. For ligature of subclavian below clavicle. *h*. For ligature of internal mammary. *i*. For ligature of subclavian above clavicle.

on a director; the left vena innominata is depressed, and the right vena innominata, right internal jugular, and the pneumogastric nerve are carried to the right, and the aneurism needle is passed from below upward, and from behind forward and inward, in close contact with the vessel (Fig.




FIG. 206.—Right subclavian and innominate arteries.

206). It is thought that cutting away the sternum will better preserve the nutritive integrity of the coats of the vessel by leaving its vascular connection with the sheaths undisturbed above. *Kocher's incision* (*a*)

begins at the junction of the lower and middle thirds of the anterior border of the sterno-mastoid and passes downward in a slightly curved manner and terminates on the anterior surface of the first portion of the sternum.

Ligature with resection of the sterno-clavicular articulation and the upper end of the sternum, although suggested some years before and practiced by Cooper, Bardenhauer, and the author on the cadaver, was not practiced on the living subject until 1895, when Burrell, of Boston, carried it into effect with eminent success—a success emphasized by the fact that the patient recovered, lived one hundred and four days, and then died suddenly from chronic heart disease and arterial sclerosis. On account of the importance of the case, liberal quotations will be made from the report of Dr. Burrell (Transactions of the American Surgical Association, vol. xiii, 1895).

The Operation.—“An incision was made at the anterior edge of the right sterno-cleido-mastoid muscle extending from the level of the cricoid cartilage to two inches below the upper border of the sternum. From this point another incision extended outward four inches in length to the junction of the outer and middle thirds of the clavicle. This skin-flap with the fascia and platysma muscle was turned back. The sterno-mastoid was severed close to its insertion into the clavicle and sternum. The sterno-thyroid, sterno-hyoid, and omo-hyoid muscles were also divided. This brought to view a fusiform aneurism in the right subclavian and right carotid arteries, extending down and on to the innominate. It was believed that enough of the innominate could be exposed to place a ligature between this fusiform aneurism and the aorta. By means of a half-inch trephine operated by a surgical engine, the right sterno-clavicular articulation and the right half of the notch of the sternum for about an inch down from the top were honey-combed. The bony parts were by this means weakened, and the removal of the articulation and the piece of the sternum were easily completed by bone forceps. A flat copper retractor was slid underneath the sterno-clavicular articulation and the sternum while the trephine was being used to protect the underlying parts.

“When this block of bone was removed there was exposed the right innominate vein and the left innominate vein going down to form the superior vena cava, with the vagus and recurrent laryngeal nerves resting on the innominate artery, all plainly to be distinguished. The wound at this time was filled with bubbling air, which had been sucked into the areolar tissue which surrounds the great vessels at the base of the neck. Its presence was ominous, and it was felt at this step by all of those who were present that if any large vein were pricked a fatal result would be inevitable. Precautions were taken to prevent the entrance of air by keeping the wound filled with sterile water.

“The sheath of the vessel was opened and the innominate artery was isolated. Then came the problem of how the ligatures should be passed. The rule, of course, is to pass the ligature away from danger. This was impossible, owing to the size of the vessel and the fact that it was surrounded by important structures on every side. The separation of the sheath of the artery was finally completed by means of the forefingers placed on either

side of the vessel. The artery was estimated to be an inch and a quarter in circumference. The ordinary curved aneurism needle was too small to pass about the vessel, and the blunt point of the aneurism needle, it was felt, might wound important structures posterior to the vessel. A flat (three quarters of an inch in width) copper spatula, curved on itself, was passed about the vessel. As soon as this copper spatula was in position a flat braided silk ligature was passed around the vessel by an aneurism needle and tied in a square knot. It was feared that the extra turn in the first part of a surgeon's knot might tear the vessel. Fully three minutes were taken in securing the first ligature. Gradually it was drawn tighter and tighter until the circulation was completely cut off. The coats of the vessels were felt to give way while tying this first ligature, which was placed three quarters of an inch from the aorta.

"The second ligature of silk was placed in the same manner one half inch higher up, but was not drawn as tightly as the other, for the coats were felt to give way, and the possibility of a tear of the innominate artery was recognized. Both ligatures were tied in square knots and cut short. It was my intention to sever the innominate artery between these ligatures, to place the vessel at rest by avoiding the tracheal tug; but the size of the vessel, and the feeling that came to my fingers while tying the second ligature that the artery was not completely closed at this point, led me to give up this step in the operation.

"The overlying muscles were sutured in approximately their original positions, and the wound was closed as rapidly as possible. An aseptic dressing was applied. The operation lasted one hour and a half."

Ligature of the Innominate Artery (Bardenheuer's Method).—In 1885 * Bardenheuer excised a portion of the sternum for removal of a tumour of the neck encroaching on the anterior mediastinum. The facility with which the substernal contents were exposed suggested to him the expediency of following this method of practice in securing the innominate.

The Operation.—Place the patient as in Mott's method of ligature of the vessel (page 158), make a vertical incision in the median line of the neck and sternum from the cricoid cartilage to the line of junction of the second ribs with the sternum—dividing the soft parts, including the deep cervical fascia (Fig. 205), divide through a transverse incision corresponding to the inner thirds of the clavicles and the episternal notch, the superficial soft parts, also the sternal portions of the sterno-mastoids, both sterno-thyroid and sterno-hyoid muscles; resect subperiosteally a half inch of the inner ends of the right clavicle and first rib; raise up the released border of the sternum sufficiently to permit of the separation of the periosteum from the upper half of the posterior surface of the manubrium; divide transversely the manubrium just below the lower border of the first rib with a Gigli-Haertel saw; separate periosteally the left clavicle, the left first rib from the sternum, remove the bone fragments thus formed and incise the posterior sternal periosteum in the median line, exposing

* Deutsche med. Wochenschrift, 1885, 40.

thereby the substernal structures; ligature the small veins, and depress and pull aside cautiously the larger ones in such a manner as to suitably expose the innominate for tying.

No effort is made to return and secure in place the separated bone. The almost certain failure to unite attended with the danger of infection

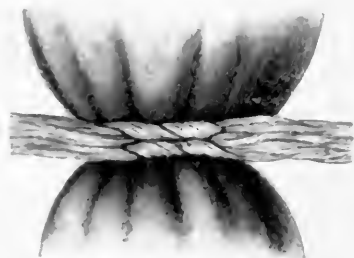


FIG. 207.—The Ballance and Edmunds stay-knot, floss silk, single fold, applied to the innominate.

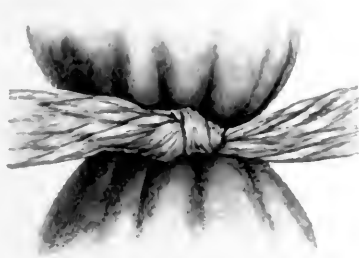


FIG. 208.—The Ballance and Edmunds stay-knot, floss silk, completed tie, applied to innominate external plaiting of vessel.

and its influence on the ligatured vessel, are much too great to invite the effort, though occasional success might attend the attempt. If the periosteum have not been disturbed, the bony flap attached at the left side by means of the soft parts can be turned over and afterward be restored and fastened in place with a fair chance of union in the absence of infection. At no better place than under ligature of the innominate can figures

illustrative of the Ballance and Edmunds stay-knot (page 84) be introduced and for reasons too obvious to require mention (Figs. 207, 208, 209, 210).

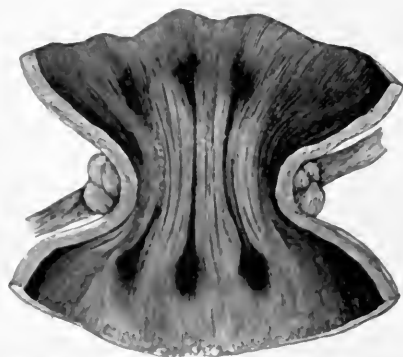


FIG. 209.—The Ballance and Edmunds stay-knot, floss silk, applied to innominate; knot cut showing internal plaiting of vessel.



FIG. 210.—The Ballance and Edmunds stay-knot, floss silk, applied to innominate, showing internal appearance at seat of ligature.

The Remarks.—E. S. Cooper, M. D., of San Francisco,* was the first to resect the upper portion of the sternum and the sternal extremity of the clavicle, in order to reach the artery.

The patient was placed upon his back, with the head and shoulders elevated, an incision four inches long, in a line parallel with and half an

* American Journal of Medical Sciences, 1859, vol. xxxviii.

inch above the upper margin of the clavicle, commencing internal to the sterno-clavicular articulation, and terminating near the anterior margin of the trapezius muscle, was made. A second incision was then made, commencing a little to the inner side of the center of the first, extending upward, external to the sterno-cleido-mastoid muscle, and terminating two and a half inches above. The parts were dissected away to expose the tumor, which it was soon ascertained extended beneath the clavicle, and that it pressed hard upon the posterior surface of the summit of the sternum.

After long trial and failure to make room for the application of a ligature to the innominate without removing important structures, Dr. Cooper proceeded to remove the summit of the sternum, and the sternal extremity of the clavicle, which barely made room sufficient to enable him to reach the innominate, owing to the large size of the aneurismal tumour at that point.

In fact, one-third of the innominate was already dilated by the aneurism, so that he had to ligate that vessel within three-fourths of an inch of the aorta. The patient lost but little blood during the operation, and was comparatively comfortable for five days. After that time he became restless, had dyspnoea, retention of urine, and gradually sank until the ninth, when he expired.

Ligature of the Innominate Artery (Splitting the Manubrium).—In this operation the manubrium is divided transversely and vertically without sacrifice of bone.

The Operation.—Place the patient as in the preceding instances; make a continuous curved transverse incision corresponding to the inner thirds of the clavicles and the line of junction of the upper and middle thirds of the manubrium (Fig. 205); divide the soft parts through this incision down to the bone, tying the bleeding points; reflect from the anterior surface of the manubrium to either side the soft parts; detach the fascia from the episternal notch outward at either side to the insertion of the sternomastoid muscles; separate and displace downward with the finger from the manubrium the structures lying immediately beneath it: divide the manubrium transversely at the junction of the upper borders of the second ribs, also vertically through the center with a Gigli-Haertel saw; retract and confine well apart the halves of the manubrium, exposing to view the sub-sternal structures at this situation; push to the left the overlying tissues, exposing the inferior thyroid veins, which ligature, divide, and push apart, revealing the innominate veins; depress the left innominate vein, draw forward and to the right the opposite one if practicable; note the relations of the pleura and of important nerves; expose the artery sufficiently for the purpose of ligaturing; pass the needle from the pleura, depositing the ligature as far from the aorta as practicable.

In the preceding description the subperiosteal technique is not practiced, since it is carried out effectively in associated methods of ligature of the vessel. This plan of procedure is quicker done, with less contusion of tissue, and therefore is a prompter technique than the subperiosteal

method. The substernal periosteum affords protection to underlying structures during sternal division, and also afterward in instances of infection. The splitting of the entire sternum, as advised by Milton (page 1052) for the removal of tumors and foreign bodies of the anterior mediastinum, seems in no essential respect to be contra-indicated when applied only to the upper end of the sternum in ligature of the innominate.

The following successful ligature of the innominate by Curtis* is of unusual interest in this connection. Because of the great importance of the successful cases this one is submitted substantially as reported by Dr. Curtis.

M. A., fifty-five years of age, a carpenter by trade, born in Sweden, was admitted to St. Luke's Hospital in November, 1899. Examination revealed a hypertrophied heart with a double murmur over the aortic valve and a systolic murmur at the apex. All the arteries were enlarged and hard, especially the right subclavian and axillary. Under the right clavicle was a swelling, apparently two inches in diameter, corresponding to the subclavian artery, having a true expansile pulsation with the heart systole, and a loud systolic bruit. Deep pressure upon the first part of the subclavian arrested the pulsation. The right axillary artery was as large as a man's thumb as far down as the border of the latissimus dorsi. The carotids were but little altered, and there was no increased pulsation of the first part of the right subclavian.

The Operation (Ether narcosis, December 2, 1899).

1. A median incision was made from the larynx to the middle of the sternum or lower, dividing the skin and deep fascia above and the periosteum also below.

2. The sterno-hyoid and sterno-thyroid muscles were followed down to their sternal insertion, retractors placed so as to draw the soft parts at the base of the neck widely apart.

3. A transverse incision was made through the periosteum along the upper border of the manubrium, and the periosteum and muscles detached from the posterior surface of the bone by blunt elevators and the finger as far as could be reached.

4. The ordinary amputation-saw was then applied to the bone in the line of the vertical incision in the periosteum, the soft parts in the neck and those behind the sternum being protected by flat metal strips. The saw was held with its point turned toward the neck and its handle toward the ensiform cartilage. It should cut most deeply above, and entirely divide the manubrium at its upper border, the cut being more shallow below, and only grooving the bone at its lower end. This obliquity of the cut necessitates the long skin incision which has been described.

5. A stout chisel was then applied in the saw-cut at the superior border of the manubrium, and the thin layer of undivided bone on the posterior surface was made to give way as the wedge action of the chisel forces the two halves apart.

6. The skin was well retracted, a transverse incision made in the peri-

* *Annals of Surgery*, vol. xxxiv, Oct., 1901.

osteum across the face of the bone at the lower level of the first intercostal space, and the chisel was applied in this line, directed obliquely outward from the middle line on each side, so as to divide each half of the sternum in two. The instrument should not be allowed to cut entirely through the bone at the outer border for fear of injury to the pleura or internal mammary artery. Both lie a little distance from the bone (Fig. 211), so that the danger of wounding them is not great.

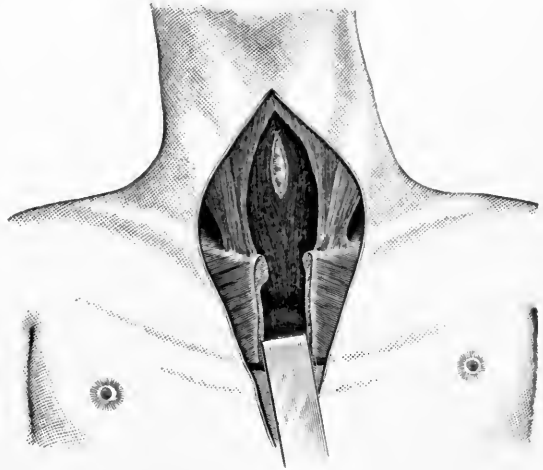


FIG. 211.—The upper end of sternum divided and retracted, exposing deep muscles and periosteum, also trachea through incision between muscles.

7. Strong retractors were then inserted in the median saw-cut, and with a little force the two halves were sufficiently separated to allow access to the periosteum, which was carefully incised with the point of the knife, beginning above, where the danger of damage to the subjacent parts is least.

As the periosteum was divided the halves of the bone were more widely separated, and the interval gradually increased from an inch to nearly twice that distance as the steady strong traction was maintained during the operation. A separation of three centimeters can be obtained in any case, and this is abundant. The small intercostal branches of the internal mammary artery are somewhat tortuous and sufficiently long to allow free motion of the bone without receiving injury. The appearance of the floor of

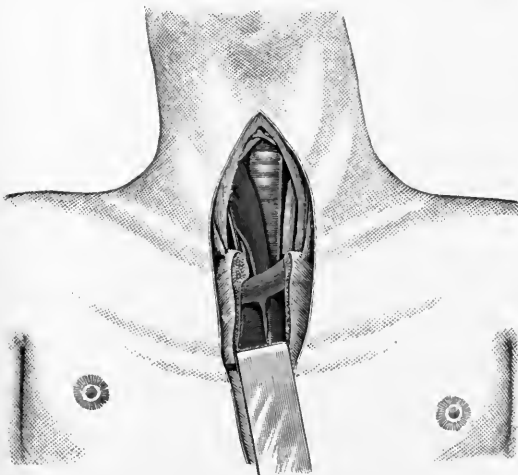


FIG. 212.—Trachea, innominate artery, arch of aorta and left innominate vein exposed. Right pneumogastric and recurrent laryngeal noted.

the wound is shown in the sketch from the cadaver (Fig. 212).

8. The muscles and fascia were then divided by blunt dissection, or with forceps and scissors, in the median line, beginning above, double ligatures being applied to the veins which cross the line of incision.

The innominate was isolated, and a double heavy chromicized catgut ligature was passed around it by means of a strong pedicle needle shaped like an iliac aneurism needle. The two threads were laid side by side, so as to make flat pressure, but were tied simultaneously, and not according to Ballance and Edmunds' directions (page 84), for the artery was so large and tense that it was feared the catgut would break if tied singly. While tying the knot the artery was folded in on itself smoothly by the pressure of a blunt instrument in the loop, so as to avoid crumpling up the wall, and the knot was drawn only tightly enough to arrest pulsation, and not so as to cut the internal coat. This ligature was placed about three-quarters of an inch below the bifurcation. A single ligature of catgut of the same size was passed through the same opening beneath the artery, but tied obliquely, so that in front it lay about a quarter of an inch distally from the first. This ligature was pulled a little tighter than the first, but not so as to cut the inner coat. It had been intended to slip this ligature along the artery farther from the first, but this intention was abandoned for fear of causing too great separation of the vessel from its sheath. The bone was allowed to return to its position, and the two halves united with a couple of silver-wire sutures. The wound was closed without drainage, except at the lower angle between the skin and the sternum, where a small gauze drain was inserted because of the rather abundant oozing from the divided bone.

Recovery was marked by disquieting symptoms, a temperature of 102° F. to 104° F. for two days, a leucocytosis of 19,800 (6,200 before operation), great restlessness, and much pain in the shoulder. The pulse was relatively slow (106 to 118) and of good quality, and there were no cerebral symptoms; the wound healed well, except that it became somewhat red at the upper angle, with a drop of pus around some of the skin sutures.

January 15th, six weeks after the operation, a small abscess formed in the upper angle of the scar and discharged half an ounce or less of pus, and left a sinus, which persisted for seven weeks longer. Four days after the ligation a very slight pulsation was observed in the aneurism and in the right radial artery. Pulsation in the carotid returned about the same time, evidently due to collateral circulation. In January there was almost no pulsation in the aneurism, but as this seemed to be increasing later, it was determined to apply additional ligatures.

Accordingly, on March 13, 1900, under ether, an incision was made along the inner border of the sterno-mastoid muscle and the common carotid exposed. No pulsation was observed in the lower part of the vessel, which appeared full of solid blood-clot, but for safety a ligature was placed around it and tied without dividing the coats of the vessel. Another incision was made along the clavicle from the lower end of the first, and a third obliquely downward and outward from the same point. The clavicle was thus exposed and divided between the inner and middle thirds with a Gigli wire saw. The first part of the subclavian was thus brought into view, and found to have a faint but decided pulsation. A ligature was applied to the first part of the subclavian just beyond the thyroid axis.

This arrested pulsation in the sac, but it continued in the first part of the subclavian. Beyond the ligature (distally) was a small vertical branch, which was assumed to be an irregular vertebral, although it was small and did not pulsate. Another ligature was thrown around the subclavian just beyond (distal to) this branch. No vertebral artery could be found arising centrally to the thyroid axis, and it was believed that the remaining pulsation in that part of the vessel came from the internal mammary artery.

The divided clavicle was then wired and the wound closed. The temperature rose again to 102° F., and there was considerable pain, and superficial infection developed in the upper angle. A sinus formed and burrowed to the bone, and the wire had to be removed.

The Remarks.—The subject from which this sketch was made shows a rather unusually low origin of the recurrent laryngeal nerve. In the case of operation for ligature of the innominate described the nerves were not seen at all; and even in a ligature of the first part of the subclavian by this method I do not believe there would be any danger to the recurrent laryngeal nerve, because the sheath of the vessel would be opened as soon as exposed, and the subsequent manipulations would take place within the sheath completely separated from the nerve. In applying a ligature to the innominate artery, it should not be forgotten that a small arteriole sometimes takes origin from that vessel on its posterior surface, which might give trouble to the operator. On October 24, 1900, the patient was in good health, with no trace of the aneurism, and a strong, although not bony, union of the clavicle.

The Fallacies.—If the innominate be shorter than usual, the lower extremity of the common carotid may be tied instead. If the aorta arches to the right side, the innominate will be on the left side instead of the right.

The General Remarks.—Rigid antiseptic measures should characterize each detail of the preparation for the operation, and also the operation itself. The wound should be promptly and thoroughly closed, and the inner surfaces kept cautiously applied to each other by means of graduated compresses held in position, if need be, by a rubber cushion. The pain and irritability of the patient excited by the operation and the after-treatment should be relieved by hypodermics of morphin given at regular intervals until the wound is properly healed. The use of a broad ligature, so tied that the knot shall not cause the ligature to make uneven pressure on the walls of the vessel, appears to be an important desideratum and one difficult of attainment. The ligature should be surely aseptic and be aseptically applied. Irregular foldings of the constricted vessel and harmful knot pressure should be avoided. The use of two or more strong ligatures so applied as to equalize as much as possible the strain of the blood-flow is a wise measure. Firm approximation of the walls of the vessel without rupture, by means of strong ligatures of floss-silk or flat braided silk, soft kangaroo tendon, or chromicized catgut, seems at this time to be the best plan of action. A small ligature should be insinuated between the tissues with the use of little force and with great caution to prepare the way and for use in drawing the larger and permanent one into place. The plans of approach through bony chan-

nels are no doubt the better, as they afford the opportunity of direct attack and careful manipulation under close inspection. However, the ever-changing relation of the parts dependent on the modifications of disease and pressure effect renders it well-nigh impossible to do more than speculate concerning the difficulties one will meet. A drainage-tube ought not to be employed at all, as its presence invites ulceration of the contiguous tissues and the establishment of a sinus in the course of its placement. Textile-fabric drainage only is proper for the wound, and this should not be used except when the attainment of primary union is defeated already.

Simultaneous ligation of the common carotid along with the innominate, and possibly also the vertebral, then or subsequently appears to be a justifiable and perhaps necessary step of the procedure. The surgeon should carefully consult the experience of the preceding efforts before attempting the operation, as by such means only can the lessons of the past be properly utilized.

The Results.—Of 43 reported cases, 36 died and 7 recovered; 38 were done for aneurism, of which 32 died and 6 recovered; 5 were done for hæmorrhage, 1 recovered; 28 were done before asepsis, of which 2 recovered; of the 15 done under asepsis, 5 recovered; 35 were done by simple incision, and in 8 either clavicle or sternum, or both, were resected. Of those done by simple incision, 30 died and 5 recovered; of those done by bone resection, 6 died and 2 recovered (Haubold).

Ligation of the Subclavian Artery.—The subclavian artery has for a considerable time afforded a field replete with occasions for varying surgical endeavor.

The Anatomical Points.—The subclavian artery, on *the right side*, arises from the arteria innominata, opposite the junction of the right clavicle with the sternum; on *the left side*, it arises from the arch of the aorta. These vessels, therefore, differ in the first part of their course in length, direction, and in relation to the contiguous anatomical structures. The right subclavian is about three, and the left about four inches in length, and each arches upward into the neck to the level of the sixth cervical vertebra. *Each vessel is divided into three portions*: the first portion is situated between the origin and the inner border of the scalenus anticus muscle, the second lies immediately behind this muscle, and the third is limited by the outer border of the scalenus anticus and the lower border of the first rib.

The Guides.—The posterior border of the sterno-mastoid muscle is the superficial and the scalenus anticus the deep muscular guide. The first rib and its scalenus tubercle are the deep bony guides. The scalenus anticus muscle is inserted into the tubercle of the first rib, and the tubercle varies in its physical characteristics, being sometimes high and pointed and easily felt, at other times scarcely discernible, and again being imperceptible.

Either artery may be ligatured at any one of its portions.

The Ligation of the First Portion, Left Side.—This division has no definite superficial *linear or muscular guide*. The inner border of the scalenus anticus is important as leading to and being the outer limit of this portion of the vessel which, owing to its origin from the arch of the aorta and

its great depth, is almost beyond the reach of a ligature. The close relation of the vessel to very important structures, the injury of which may be more grave than the condition calling for ligature of the vessel, renders the performance of the operation at this situation difficult and of questionable expediency.

The Contiguous Anatomy.

THE RELATIONS OF FIRST PORTION OF LEFT SUBCLAVIAN ARTERY. (GRAY.)

In front.

- Pleura and left lung.
- Pneumogastric, cardiac, and phrenic nerves.
- Left carotid artery.
- Left internal jugular and innominate veins.
- Sterno-thyroid, sterno-hyoid, and sterno-mastoid muscles.

Inner side.

- Trachea.
- (Esophagus.
- Thoracic duct.

{ **Left subclavian artery,** }
{ **first portion.** }

Outer side.

- Pleura.

Behind.

- Esophagus and thoracic duct.
- Inferior cervical ganglion of sympathetic.
- Longus colli muscle and vertebral column.

The Operation.—Place the patient on the back with the head extended and turned to the opposite side, the left shoulder well depressed; make an incision three inches and a half in length along the inner border of the sterno-cleido-mastoid down to the sternum; another, two inches and a half in length along the inner extremity of the clavicle, meeting the former near the trachea. It is seen that this incision is substantially the same as that for ligaturing the innominate artery (Fig. 205, *d*). The flap, consisting of

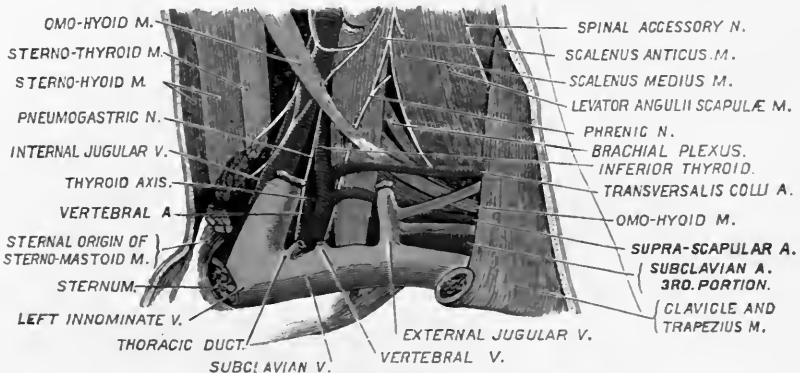


FIG. 213.—Left subclavian vein and artery.

the integument, superficial fascia, and platysma, is turned aside; one half of the clavicular portion of the sterno-mastoid and its whole sternal portion are then divided on a director, bringing into view the sterno-hyoid and sterno-thyroid muscles, and, to the outer side, the omo-hyoid. The sterno-thyroid and sterno-hyoid should be divided with great care after being liberated from the fascia which covers them. The inner edge of the scalenus

anticus muscle is now sought for; when found, it will guide the finger directly to the vessel. The important contiguous structures are now drawn inward and pressed away from the artery, using great caution to avoid the thoracic duct, which will be in the line of search, as it goes behind the jugular vein at its junction with the left innominate vein. The needle is carefully passed from before backward. The great depth of the vessel makes it difficult to pass the common needle, therefore the one with the adjustable extremity (Fig. 177) should be employed.

The Results.—This portion was tied by Dr. J. Kearney Rogers in 1845; the patient died from secondary hæmorrhage on the fifteenth day. It has been ligatured successfully by Halsted in extirpation of a tumor, and by Schumpert for cure of aneurism.*

The Ligature of the First Portion, Right Side.—The inner border of the anterior scalenus leads to this portion on the right the same as on the left side of the body (Figs. 206 and 207). This muscle may be called, therefore, the *deep muscular guide* to this portion of the artery.

The Contiguous Anatomy.

THE RELATIONS OF FIRST PORTION OF RIGHT SUBCLAVIAN ARTERY. (GRAY.)

In front.

Integument and superficial fascia.
 Platysma and deep fascia.
 Clavicular origin of sterno-mastoid muscle.
 Sterno-hyoid and sterno-thyroid muscles.
 Internal jugular and vertebral veins.
 Pneumogastric, cardiac, and phrenic nerves.

} **Right subclavian artery,** }
 } **first portion.** }

Beneath.
 Pleura.

Behind.

Recurrent laryngeal nerve.
 Sympathetic nerve.
 Longus colli muscle.
 Transverse process of seventh cervical or first dorsal vertebra.

The Operation.—The position of the head and neck of the patient are reversed in the operation, but the primary incisions and dissection are substantially the same in this as in the preceding operation. The internal jugular should be pressed aside and the needle passed from below upward, and from before backward, carefully avoiding the pleura, recurrent laryngeal, and phrenic nerves. The ligature of the vertebral and internal mammary arteries at the same time will lessen, it is believed, the danger of secondary hæmorrhage.

The Fallacies.—The right subclavian may arise from the arch of the aorta, when it will be more deeply situated; it often passes behind the œsophagus, or between it and the trachea. As at the left, the artery may perforate the scalenus anticus or pass in front of it, the vein being behind. It may rest on a cervical rib and be located higher, and be more prominent for this reason, or extend an inch or so above the clavicle, or lie behind it even. The supra-scapular artery may take origin from the third portion instead of from the thyroid axis.

* Medical Record, September 3, 1898.

The Results.—The first portion has been ligated twenty-one times; nineteen of the cases proved fatal, of which eight died of hæmorrhage. Clutton, of St. Thomas's Hospital, cured an aneurism of the third portion of the subclavian by ligature with floss silk at the inner border of the scalenus anticus of the first portion, followed the next day by ligature of the first portion of the axillary artery.*

Curtis, of New York, reports a case cured by ligature with two strands of catgut drawn sufficiently tight to occlude the lumen but not divide the inner coats of the vessel.†

The Ligature at the Third Portion, Either Side.

The Contiguous Anatomy.

THE RELATIONS OF THE THIRD PORTION OF SUBCLAVIAN ARTERY. (GRAY.)

In front.

- Integument and superficial fascia.
- Platysma and deep cervical fascia.
- External jugular, supra-scapular, and transverse cervical vein.
- Descending branches of cervical plexus.
- Subclavius muscle and supra-scapular artery and clavicle.

Above.

- Brachial plexus.
- Omo-hyoid.

{ **Subclavian artery,** }
{ **third portion.** }

Below.

- First rib.

Behind.

- Scalenus medius.

The *linear guide* to the operation upon this portion of the vessel at either side is drawn just above and parallel with the upper border of the clavicle, between the posterior border of the sterno-cleido-mastoid and the anterior border of the trapezius muscle, and for convenience should be about four inches in length (Fig. 214, *a*).

The Muscular Guides to the Artery, Second and Third Portions.—The second and third portions of the vessel have no direct superficial muscular guide. The deep muscular guide is the outer border of the scalenus anticus. The posterior belly of the omo-hyoid, while not in close contact with the artery, serves an important purpose in directing the attention of the surgeon to the artery. The situation of the outer border of the scalenus anticus is well in-

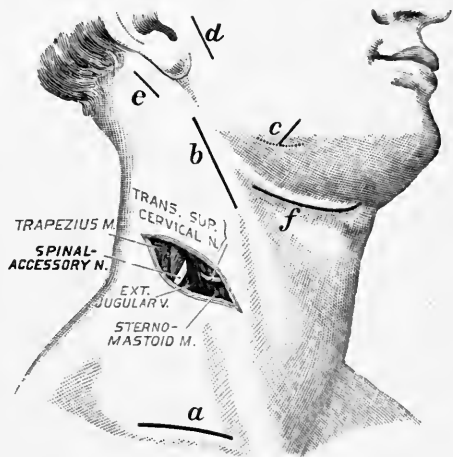


FIG. 214.—Linear guides to arteries and spinal accessory nerve. *a*. Subclavian artery. *b*. External carotid. *c*. Facial. *d*. Temporal. *e*. Occipital. *f*. Lingual artery.

* Medico-Chirurgical Transactions, vol. lxxx, 1897.

† Annals of Surgery, April, 1898, p. 540.

dicated by the lower part of the posterior border of the sterno-cleido-mastoid, provided the latter muscle be not uncommonly developed. The junction of the inner two inches of the clavicle with its outer portion is

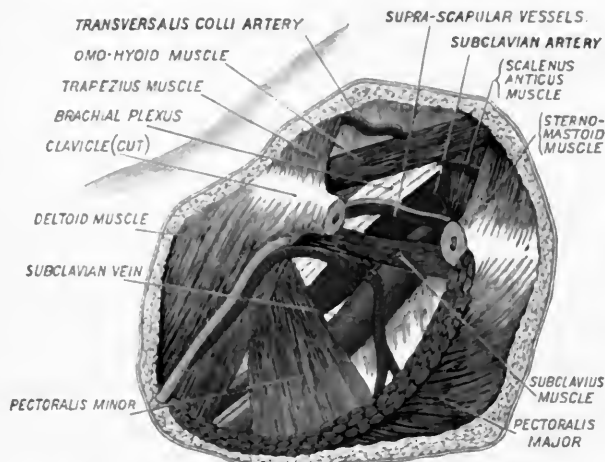


FIG. 215.—Anatomy of the third portion of the right subclavian and right axillary arteries.

a far more unvarying indication of the approximate deep location of the outer border of the scalenus anticus than is the posterior border of the sterno-cleido-mastoid muscle (Fig. 215).

The Bony Guide.

—The tubercle on the first rib, into which the scalenus anticus is inserted, is the bony guide to the vessel here, the artery being directly behind it. As already

stated, the tubercle varies considerably in its physical characteristics.

The Operation. Third Portion.—Place the patient on the back with the shoulders elevated, head bent backward and turned to the opposite side. Draw the shoulder of the corresponding side firmly downward to the side of the patient, and retain it in that position. Compress the external jugular vein above the clavicle long enough to cause its distention, thereby indicating its exact situation. The integument is drawn evenly downward and incised upon the clavicle, and it will, when allowed to retract, carry the incision upward to its proper situation—half an inch above the clavicle (Fig. 214, a); divide the superficial fascia and platysma on a director, being careful not to sever the external jugular, which can be either pulled aside or divided between two ligatures. The supra-scapular and transverse cervical veins should be treated in the same manner. The omo-hyoid is now sought for and drawn upward, if necessary, and the supra-scapular artery avoided.

The deep cervical fascia is torn asunder by the director, and the outer border of the scalenus anticus felt for on a line with the outer margin of the sterno-cleido-mastoid, if the latter have not been divided; if so, it should be located as described under the head of Muscular Guides to the Second and Third Portions of the Artery (page 171). If the head be turned forcibly to the opposite side, the scalenus anticus will be made tense and more prominent. When found, the muscle is followed downward along the outer border to the tubercle of the first rib, immediately behind which the pulsation of the artery is felt. The vessel is now carefully exposed and the needle passed from before backward (Figs. 215 and 216). Great caution

should be taken not to interfere with the subclavian vein, which lies in front of and on a lower plane than the artery.

The Fallacies.—The sterno-cleido-mastoid muscle may have an unusual breadth of origin from the clavicle, thereby causing the incision to be made too far posteriorly. Attention to the clavicular measurement (two inches from the sternal end) will prevent this error. The tubercle on the anterior surface of a transverse process of one of the lower cervical vertebrae may be mistaken for the tubercle of the first rib. This mistake, however, is easily rectified by remembering that the first rib extends downward and outward, and that neither pulsation nor the outline of the scalenus anticus is found contiguous to a transverse process. The tubercle of the first rib may be absent, then the muscular insertion into the rib must be relied upon as a guide to the vessel.

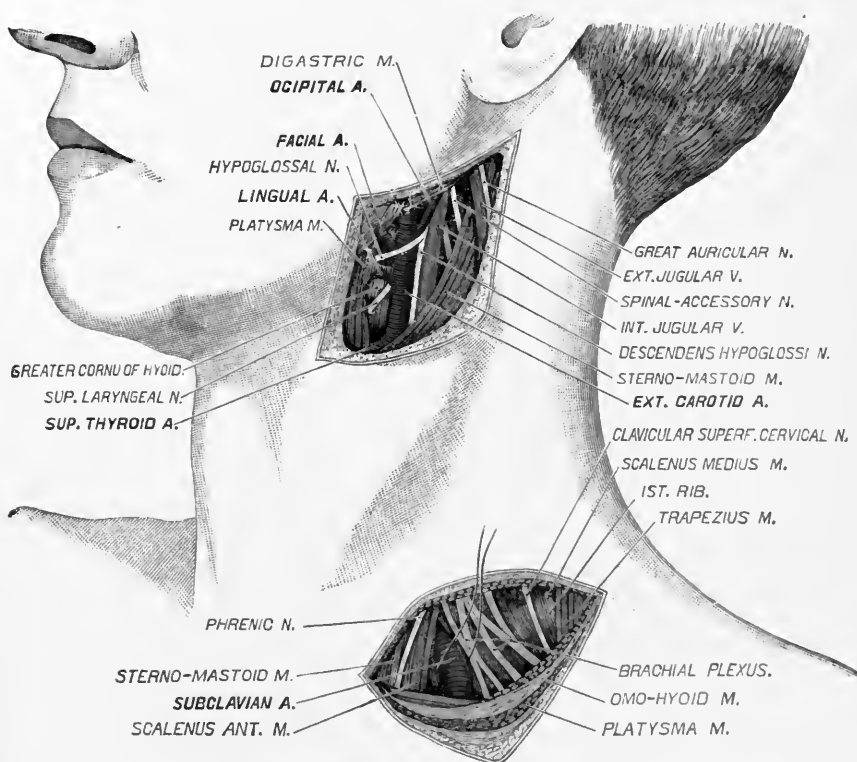


FIG. 216.—Subclavian and external carotid arteries.

The artery may perforate the scalenus anticus or pass in front of it, the vein being behind the muscle. It may rest on a cervical rib and be located higher, and be more prominent for this reason. It may extend an inch or so above the clavicle or lie behind it. The scapular arteries may come from the third portion instead of the thyroid axis.

The artery may be in front of the tubercle and the vein behind it. The pulsation, as well as the anatomical appearances, will determine the inter-

change of situations. The inner cord of the brachial plexus may be mistaken for the artery.

The Results.—Of 276 cases, 142 died; 254 were done before asepsis, with 137 deaths; 144 were for aneurism, 61 died; 99 for hæmorrhage, 70 died; 11 for tumor, 6 died. Of 22 done under asepsis, 5 died; 17 for aneurism, 5 died; 5 for hæmorrhage, none died.

The Ligature of the Second Portion.—The *linear and muscular guides* are practically similar to those of the preceding portion.

The Contiguous Anatomy.

THE RELATIONS OF SECOND PORTION OF SUBCLAVIAN ARTERY. (GRAY.)

In front.

Integument and superficial fascia.
Platysma and deep cervical fascia.
Sterno-mastoid.
Scalenus anticus.
Phrenic nerve.
Subclavian vein.

Above.
Brachial plexus.

{ **Subclavian artery,** }
{ **second portion.** }

Below.
Pleura.

Behind.

Pleura and middle scalenus.

The Operation.—The steps essential to arrive at the proper site in this instance are not varied from those given for the third portion until the outer border of the scalenus anticus is well determined; the phrenic nerve and subclavian vein should then be pushed aside and the muscle divided (Figs. 206 and 213), when the retraction of its fibres will expose the artery to view. The needle is then passed as before, closely hugging the artery to avoid the pleura below and posteriorly.

The Results.—Of 16 cases, 10 died; of 13 before asepsis, 9 died; of 9 for aneurism, 5 died; of 4 for hæmorrhage, all died. Three were done under asepsis for hæmorrhage, with 1 death.

Ligature of the Vertebral Artery.—The vertebral artery is rarely tied.

The Anatomical Points.—The vertebral artery arises from the upper and back part of the first portion of the subclavian artery close to the inner border of the anterior scalenus muscle, passes directly upward along the anterior surface of the vertebral column, and enters the foramen in the transverse process of the sixth cervical vertebra. It then ascends through the foramina in the transverse processes of all the vertebræ above this, inclining outward and upward between the transverse process of the axis and atlas, and finally runs in a deep groove on the upper surface of the posterior arch of the atlas, and ascending pierces the posterior occipito-atloid ligament.

The Contiguous Anatomy.

THE RELATIONS OF THE VERTEBRAL ARTERY. (GRAY.)

In front.

Internal jugular vein and its sheath.
Inferior thyroid artery.
Thoracic duct (left side).
Aponeurosis between longus colli and the scalenus anticus.
Vertebral vein.

<i>Outer side.</i>	} Vertebral }	<i>Inner side.</i>
Scalenus anticus.	} artery. }	Longus colli.
	<i>Behind.</i>	
	Cervical nerves.	
	Vertebral column.	

The *linear guide* to the artery in the first situation is drawn from the junction of the inner fourth with the outer three fourths of the clavicle to the posterior border of the mastoid process. This vessel has deep muscular and bony guides. The *deep muscular guide* is the inner border of the scalenus anticus, because the artery lies between it and the longus colli. The *tubercle on the transverse process of the sixth cervical vertebra* is the direct bony guide to the vessel. The vessel enters this process at a point just below the tubercle and the inner border of the scalenus anticus.

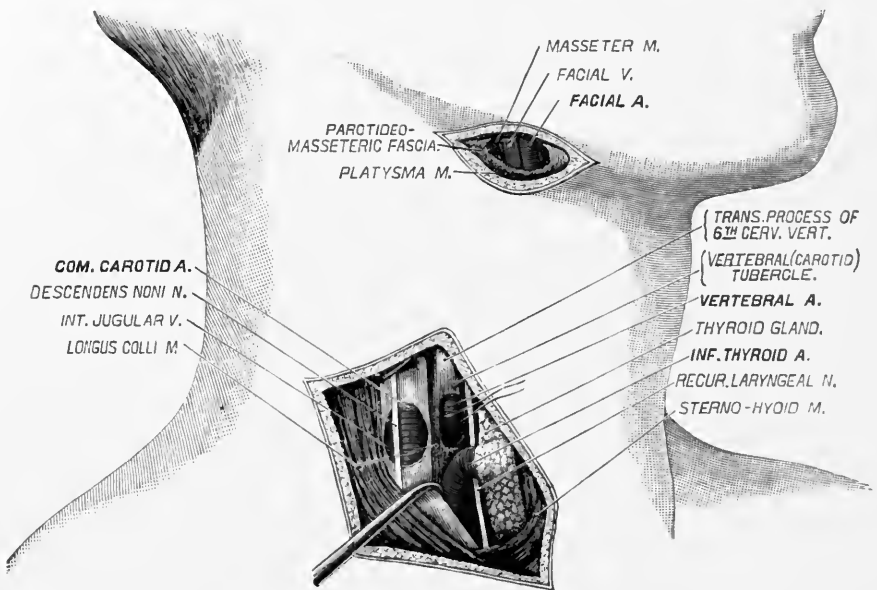


FIG. 217.—The common carotid, vertebral, inf. thyroid, and facial arteries.

The *vertebral artery* can be *ligatured at three situations*: 1, before entering the vertebral canal; 2, between the atlas and axis; 3, between the atlas and the occipital bone. At the first situation about an inch and a quarter in length of the vessel is available for ligaturing. The artery can be tied at the *first situation* through an incision made either behind or in front of the sterno-mastoid. The former is practiced more frequently.

The Operation at First Situation.—With the shoulders raised and the head turned to the opposite side as in ligature of the subclavian, an incision four inches in length is made through the superficial tissues along the posterior border of the sterno-mastoid down to the clavicle. This incision is carried carefully down to the deep cervical fascia, which is cautiously divided. The jugular vein in its sheath and the sterno-mastoid are drawn gently to the outer side, and, if necessary, the size of the wound is increased by a suffi-

cient division of the fibers of the clavicular attachment of the sterno-mastoid muscle (Fig. 217). The deep connective tissue is separated with a blunt instrument, and the interval between the scalenus anticus and the longus colli muscles is sought for. The head is now flexed sufficiently to permit the borders of the wound to be drawn widely apart; deeper structures are carefully drawn asunder, and the tubercle of the sixth cervical vertebra is located, below which the pulsations of the artery can be felt. The artery is exposed, and the needle is passed from within outward. The inferior thyroid artery, vertebral veins, and the thoracic duct on the left side are in front of the artery and should be carefully avoided. An incision at the anterior border of the sterno-mastoid affords inadequate access to the vessel.

The Precaution.—In exposing the vessel caution is exercised to prevent unnecessary injury of the sympathetic nerve, thus avoiding as much as possible the modification (contraction) of the corresponding pupil. It is proper to say that contraction of the pupil is so certain to follow ligation of the vessel that its occurrence is regarded as evidence of successful ligation.

Mr. Alexander, whose experience in tying these vessels on the living subject is greater than that of any other surgeon, describes his method of operating in the following language: "An incision three or four inches long is made in an upward and outward direction along the hollow which exists between the scalenus anticus and the sterno-mastoid muscles. The incision should begin just outside and on a level with the point where the external jugular vein dips over the edge of the sterno-mastoid muscle, or, if the vein is invisible, about half an inch above the clavicle. The external jugular vein is drawn inward with the sterno-mastoid muscle. The connective tissue now appearing, the wound is opened by a blunt director, until the scalenus anticus muscle, the phrenic nerve, and the transverse cervical artery are seen. It can not be too well remembered that the pleura is at the inner side of the wound, while below lies the subclavian artery. It is now only necessary to separate the edges of the scalenus anticus and the longus colli muscles to see the vertebral artery lying in the space between them. The artery is generally completely covered by the vein, which is drawn aside and the artery is then ligatured."

At the second situation the artery lies in a triangular space formed by the rectus posticus major and superior and inferior oblique muscles. It is covered by the rectus posticus major and the complexus muscles.

The Operation at Second Situation.—With the head turned to the opposite side and inclined forward, make an incision three inches in length along the posterior border of the sterno-mastoid, beginning half an inch below the mastoid process. A second incision is then made, beginning at the upper fourth of the first one and carried backward and downward one inch. The splenius muscle appears as soon as the integument and fascia are divided and pulled aside. The fibro-muscular structure of the splenius is divided, its borders separated, the layer of fat that now appears is pushed aside by the finger or handle of the scalpel, and the vessel is seen; its branches are drawn aside together with those of the second cervical nerve, the artery isolated, and the needle passed from without inward.

At the third situation the incisions are the same as in the preceding method, except that the first one begins half an inch above the mastoid process instead of half an inch below it. The skin, fascia, and splenius are divided as before, the occipital artery appears at the upper angle of the wound, and is held aside; divide the aponeurosis and cellular tissue, separate the wound borders, enter the triangle, separate the fatty tissue, and the artery will be exposed. Pass the needle from behind forward.

The Fallacy.—The vertebral arteries may enter the transverse processes of the fifth cervical vertebra, instead of the sixth.

The Results.—These vessels have been ligatured forty-two times, in thirty-six of which three died—one each from hæmorrhage, embolism, and pleurisy. When done for the cure of epilepsy, about twenty per cent were benefited, some of which it is claimed ultimately recovered. The permanent benefit derived thus far in such cases has not been sufficient to warrant the adoption of this measure for the treatment of epilepsy, and Dr. Alexander himself has ceased to advocate it for this purpose.

Ligature of the Internal Mammary Artery.—The internal mammary artery is ligatured most frequently in connection with operations on the ribs.

The Anatomical Points.—The internal mammary arises from the first portion of the subclavian. It descends behind the internal jugular and subclavian veins to the inner surface of the anterior wall of the chest, lying beneath the costal cartilages and about half an inch from the margin of the sternum. *It can be ligatured* in any of the five upper intercostal spaces.

The Linear Guide.—A line parallel with and located about half an inch to the outer side of the sternum is a fair linear indication of the course of the artery. At this situation the vessel is midway between the borders of the costal cartilages. It has no muscular guide.

The Operation.—Make an incision two inches in length along the upper border of a costal cartilage and rib. The integument, fascia, and pectoralis major muscle are divided down to the intercostal muscles. Beneath the intercostal, surrounded by the connective tissue, the artery, accompanied by the venæ comites, will be found. The vessel is isolated, and the needle carefully passed to avoid penetrating the pleura. If the vessel be tied in the uppermost intercostal space, a single vein will attend it.

Ligature of the Inferior Thyroid Artery.—The inferior thyroid artery is ligatured in operations on the thyroid body.

The Anatomical Points.—The inferior thyroid arises from the thyroid axis, and passes in a somewhat irregular course upward and inward behind the sheath of the common carotid and internal jugular vein to the thyroid body. It passes in front of the vertebral artery and the longus colli muscle. The middle cervical ganglion rests upon it. The recurrent laryngeal nerve and the thoracic duct at the left side should be carefully avoided.

The Contiguous Anatomy.—In front, the common carotid sheath and its contents, and the sympathetic nerve; behind, the recurrent laryngeal nerve, the œsophagus, and the vertebral artery; at the left side, if low in the neck, carefully avoid the thoracic duct.

The linear guide to the operation is located along the anterior border of

the sterno-mastoid, as for ligature of the common carotid. An approximate *bony guide* to the vessel is the body of the fifth cervical vertebra, opposite to which the artery enters the thyroid structure.

The Operation.—Make an incision three inches in length along the inner side of the sterno-mastoid, as for ligature of the common carotid. The carotid sheath and its contents, along with the sterno-mastoid, are drawn outward and the artery is found behind the carotid, running inward near the body of the fifth cervical vertebra (Fig. 217). The needle is passed from within outward, carefully avoiding the recurrent laryngeal nerve.

The Fallacies.—The vessel may be double or absent; it may arise from the vertebral or common carotid.

The Results.—The results are excellent, as no dangers attend the ligaturing other than those incurred by the manipulation necessary to reach the vessel.

Ligature of the Axillary Artery.—The axillary artery is ligatured for rupture and for cure of aneurism more often than for any other reasons.

The Anatomical Points.—The axillary artery begins at the lower border of the first rib and extends to the lower border of the tendon of the latissimus dorsi. It gives origin to numerous branches and is intimately associated with the brachial plexus. This artery *may be tied at three situations*—1, above the pectoralis minor; 2, behind; 3, below that muscle (Fig. 215). The first and last situations, however, are the only ones at which the vessel can be practically secured without ligature of collateral branches.

The Contiguous Anatomy.

THE RELATIONS OF THE FIRST PORTION OF THE AXILLARY ARTERY. (GRAY.)

In front.

Pectoralis major.
Costo-coracoid membrane.
External anterior thoracic nerve.
Acromio-thoracic and cephalic veins.

<i>Outer side.</i>	{ Axillary }	<i>Inner side.</i>
Brachial plexus.	{ artery, }	Axillary vein.
	{ first portion. }	

Behind.

First intercostal space, and intercostal muscle.
Second and third serration of serratus magnus.
Posterior and internal anterior thoracic nerve.

The First Portion.—There is no linear guide to the vessel at this portion. The *linear guide to the operation* is located about half an inch below the lower border of the clavicle, extending from within an inch or so of the sternal extremity, outward three or four inches.

The muscular guides are superficial and deep. The former is the space between the contiguous borders of the deltoid and pectoralis major muscles. The latter is the pectoralis minor, its upper border indicating the first portion, etc., as before stated. The vessel is rarely tied at this point on account of the great depth and the nearness to the seat of ligature of collateral branches. The third portion of the subclavian is tied instead.

The Operation.—Place the patient upon the back, with the head turned to the opposite side; elevate the shoulder, and carry the arm a little distance from the side of the chest. Make an incision about four inches in length on the linear guide through the integument, fascia, and platysma; separate the fibers of the pectoralis major from the deltoid, or divide those of the former muscle the full length of the wound (Fig. 218);

tear apart the costo-coracoid fascia at the upper border of the pectoralis minor muscle; bring the arm to the side to relax this muscle, which is then drawn outward; displace the areolar tissue carefully with a director, then the vein will be seen, which should be carried downward and inward with a blunt hook, and the artery

will be noticed beneath it and in close contact with the inner cord of the brachial plexus, which lies to its outer side and above. The needle is then passed from below upward. The cephalic vein, which empties into the axillary vein, should be cautiously avoided, as it passes between the borders of the pectoral and deltoid muscles to its termination.

The Fallacies.—The inner cord of the brachial plexus may be mistaken for the artery. If, before tightening the ligature, pressure be made upon the vessel, and the effect upon the radial pulse noted, this fallacy is eliminated.

The vessel may be reached through an incision carried between the deltoid and pectoral muscles about three inches in length, which should connect with the one previously made at the lower border of the clavicle. The fat and cellular tissue can then be removed or displaced, as in the previous instance.

The Results.—No definite records are given of the results of this operation.

The Second Portion.—The artery can be ligatured at this situation through the preceding incision, or through the space created by separation of the contiguous borders of the deltoid and pectoral muscles. The pectoralis minor is exposed, pulled downward, artery isolated, collateral branches tied, and main vessel ligatured in the usual manner.

Ligature in the Third Position.—The linear guide to the artery at this portion is a dotted line extending upward into the axilla corresponding to the junction of the anterior and middle thirds of this space (Fig. 219).

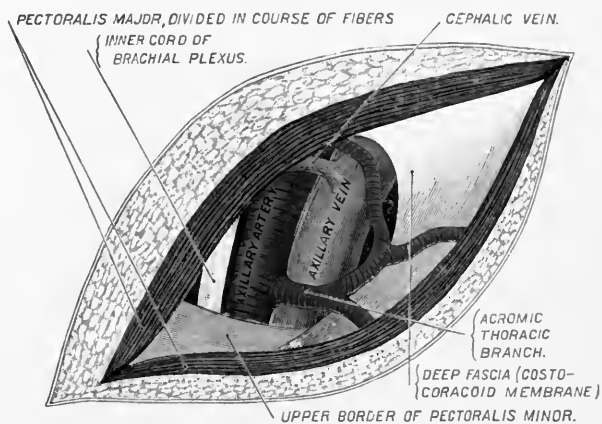


FIG. 218.—Ligature of axillary artery; first portion.

The Contiguous Anatomy.

THE RELATIONS OF THE THIRD PORTION OF THE AXILLARY ARTERY. (GRAY.)

In front.

Integument and fascia.
Pectoralis major.
Inner head of the mediate nerve.

Outer side.

Coraco-brachialis.
Median nerve.
Musculo-cutaneous nerve.

{ **Axillary**
artery,
third portion. }

Inner side.

Ulnar nerve.
Internal cutaneous nerve.
Axillary vein.

Behind.

Subscapularis muscle.
Tendons of latissimus dorsi and teres major.
Musculo-spiral and circumflex nerves.

The Muscular Guide.—The inner border of the coraco-brachialis muscle.

The Operation (Fig. 219).—With the arm abducted and rotated outward, make an incision three inches in length along the inner border of the coraco-brachialis muscle in line of the arterial pulsation, observing that its center be placed above the anterior fold of the axilla, cautiously divide the superimposed tissues, draw the median nerve and the axillary vein to the inner side, and pass the needle from within outward.

The Fallacies.—Large branches may be given off from the axillary at this situation, which will confuse the operator as to the identity of the vessel. Pressure made upon the vessel with the fingers prior to the tightening of the ligature will determine the influence of pressure on the circulation beyond. A nerve may be mistaken for the artery.

The Results.—The results are favorable, since the operation implies in itself no particular danger to the patient.

Ligature of the Brachial Artery.—The exposure to injury of the brachial artery calls for frequent ligaturing of this vessel.

The Anatomical Points.—The brachial artery extends from the lower border of the tendon of the latissimus dorsi to about an inch below the bend of the elbow joint, and is closely associated with the veins and nerves of the arm.

The Contiguous Anatomy.

THE RELATIONS OF THE BRACHIAL ARTERY. (GRAY.)

In front.

Integument and fascia.
Bicipital fascia, median basilic vein.
Median nerve.

Outer side.

Median nerve (above).
Coraco-brachialis.
Biceps.
Vena comes.

{ **Brachial**
artery. }

Inner side.

Internal cutaneous and ulnar nerve.
Median nerve (below).
Vena comes.
Basilic vein (upper half).

Behind.

Triceps.
Musculo-spiral nerve.
Superior profunda artery.
Coraco-brachialis.
Brachialis anticus.

The linear guide corresponds to the dotted line extending from the junction of the middle and anterior thirds of the axilla to midway between the apices of the bony condyles of the humerus (Fig. 219).

The Muscular Guide.—At its upper third the artery lies at the inner border of the coraco-brachialis, at the middle third at the inner border of the biceps, and the lower third it lies at the inner border of the biceps ten-

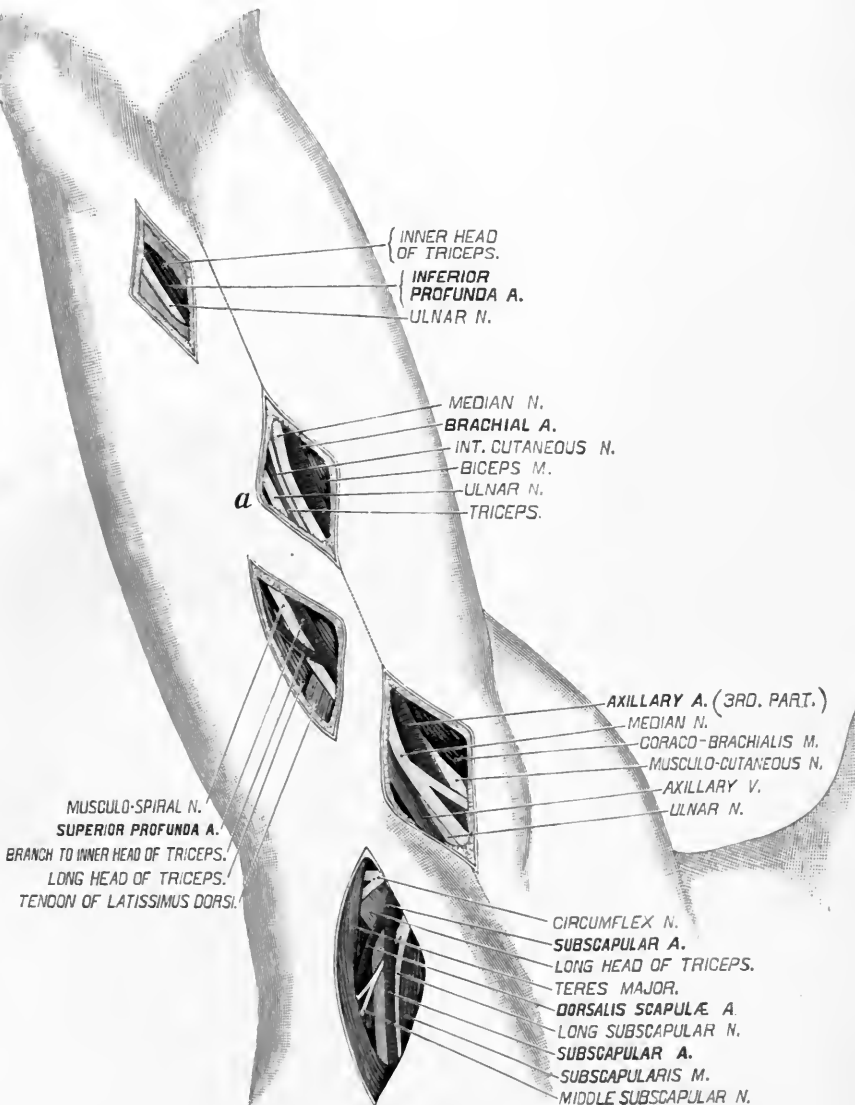


FIG. 219.—Ligature of axillary and brachial arteries. Exposure of the profunda artery and the various nerves associated with these vessels.

don. The brachial artery may be ligatured at three situations—at its upper, middle, and lower thirds.

The Operation, Upper Third.—Abduct the arm and rotate it outward. Make an incision about three inches in length along the inner border of

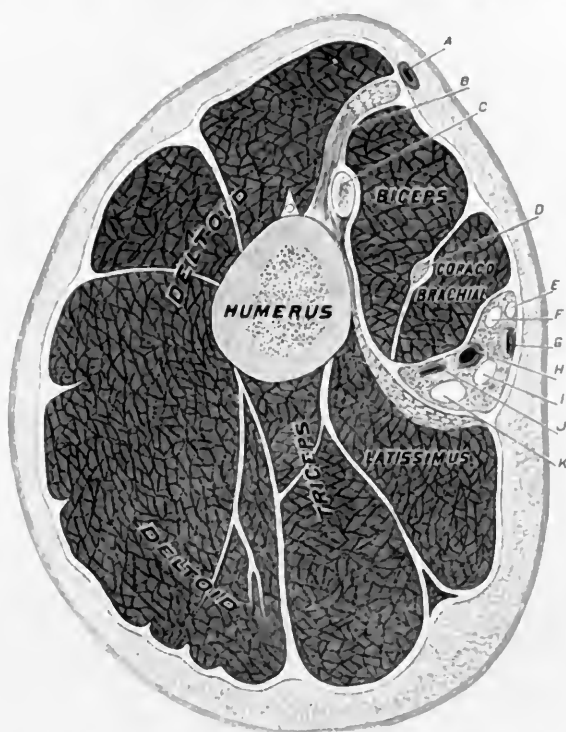


FIG. 220.—Transverse section of right arm at axilla.

- A. Cephalic vein. B. Pectoralis major. C. Biceps tendon. D. Musculo-cutaneous nerve. E. Internal cutaneous nerve. F. Median nerve. G. Basilic vein. H. Brachial artery. I. Ulnar nerve. J. Brachial vein. K. Musculo-spiral nerve.

the coraco-brachialis muscle. The artery, being very superficial, is quickly reached (Fig. 220). The median nerve is drawn to the outer side, and the ulnar nerve and basilic vein to the inner side; separate the artery from the vein, and pass the needle from within outward.

The Operation, Middle Third.—Place the arm as before. Make an incision three inches in length along the inner side of the biceps muscle (Fig. 219, a). The median nerve is found lying upon and a little to the inner side of the vessel (Fig. 221). Push it aside, isolate the artery from the venae comites, and pass the needle in the same direction as before.

The Operation, Lower Third (Fig. 222, f).—Abduct the arm and supinate the forearm. Compress the arm above to distend the median basilic vein. Make an incision about three inches in length along the inner border of the tendon of the biceps; draw aside the median basilic vein, and the artery will be felt pulsating beneath the bicipital fascia. A suitable-sized opening

is now cut through this fascia (Fig. 223, *E*), the forearm partially flexed, the vessel separated from its veins, and the needle passed from within outward. The importance of the bicipital fascia in connection with flexion and pronation of the forearm should limit as much as possible any destructive interference with it.

The Fallacies.—The arteries of the forearm may come from the axillary, or the brachial may bifurcate high up, thereby increasing the number of the large vessels in the arm. This fact is determined by the comparative size of the brachial, and the influence of pressure on its circulation at the distal side of the proposed ligature. The brachial artery may run behind the inner condyle along with the ulnar nerve. If the artery be not in its normal site, deep pressure on the arm may detect arterial pulsation elsewhere, which, together with the effect of the pressure on the circulation beyond, will determine the size and site of the vessel. Each of the profunda branches has been mistaken for the main vessel. The incision at the upper two thirds may be made too far inward, causing the surgeon to mistake the ulnar for the median nerve. If the forearm be flexed and gentle

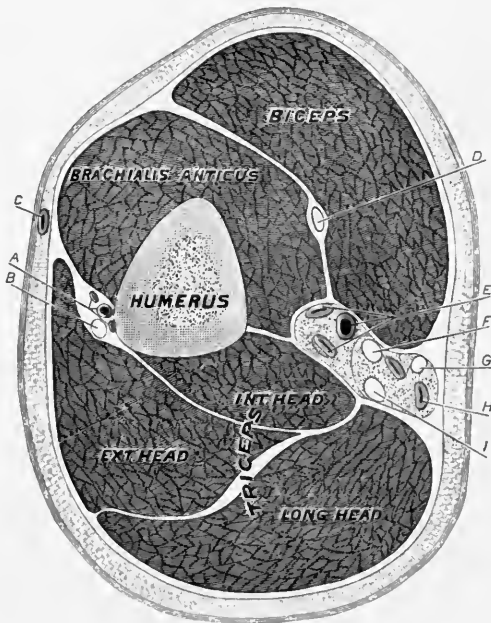


FIG. 221.—Transverse section of right arm at the middle third.

- A. Superior profunda artery and veins. B. Musculo-spiral nerve. C. Cephalic vein.
 D. Musculo-cutaneous nerve. E. Brachial artery and veins. F. Median nerve.
 G. Internal cutaneous nerve. H. Basilic vein. I. Ulnar nerve.

upward traction be made upon either, the course of the nerve will be determined, and the danger of this will be easily avoided.

The median nerve may pass behind the artery instead of in front of it; then, if the circulation from above be obstructed, the artery may escape

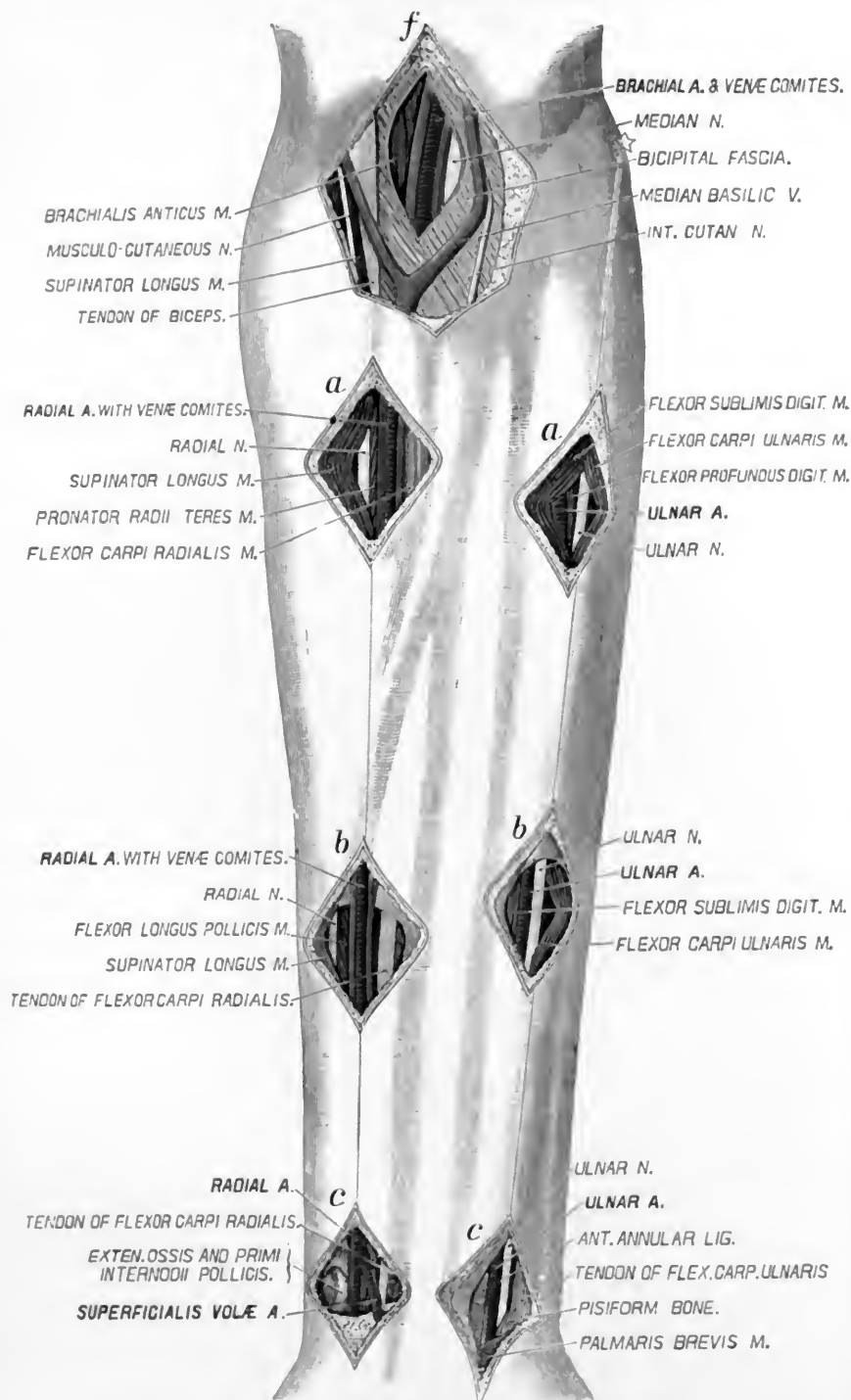


FIG. 222.—Ligature of radial and ulnar arteries.

a, b, c. Ligature of radial and ulnar at upper (*a*), middle (*b*) and lower (*c*) thirds respectively. *f.* Ligature lower third brachial artery.

notice. The artery not infrequently lies deeply between the brachialis anticus and biceps muscles.

Anomalous muscular slips and unusual muscular development may obscure the artery in its normal course. In such instances the pulsation will determine the location.

Occasionally, especially in female subjects, when the upper extremity is markedly concave on its outer surface, due to an unusual length of the internal condyle, the primary incision may be made unintentionally to the outer side of the vessel. If, however, it be made midway between the apices of the bony condyles, this error will not arise.

The Results.—Of 211 cases of ligature,

54 died; of 189 before a sepsis, for hæmorrhage and traumatic aneurism, 54 died; of 22 under it: 15 for hæmorrhage and 7 for aneurism, all recovered.

Ligature of the Radial Artery.—The radial artery on account of the exposed position is frequently injured.

The Anatomical Points.—It arises from the brachial, is an apparent continuation of it, and is superficial in its entire route.

The Contiguous Anatomy.

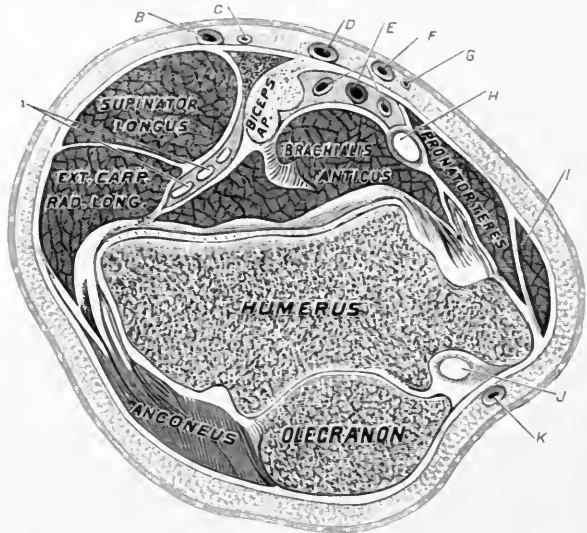


FIG. 223.—Transverse section through the right elbow joint.

A. Radial nerve. B. Cephalic vein. C. External cutaneous nerve. D. Median vein. E. Brachial artery and veins. F. Basilic vein. G. Internal cutaneous nerve. H. Median nerve. I, J. Ulnar nerve. K. Ulnar vein.

THE RELATIONS OF THE RADIAL ARTERY. (GRAY.)

In front.

Integument—superficial and deep fasciæ.
Supinator longus.

Inner side.

Pronator radii teres.
Flexor carpi radialis.

{ Radial artery }
{ in forearm. }

Outer side.

Supinator longus.
Radial nerve (middle third).

Behind.

Tendon of biceps.
Supinator brevis.
Pronator radii teres.
Flexor sublimis digitorum.
Flexor longus pollicis
Pronator quadratus.
Radius.

The linear guide (Fig. 222) to this vessel is drawn midway (dotted line) between the apices of the bony condyles of the humerus to the inner side of the extremity of the styloid process of the radius.

The muscular guide, at the upper portion, is the inner border of the belly of the supinator longus muscle, beneath which the vessel usually lies. At the lower portion of the course it lies at the inner side of the tendon of the same muscle. The pulsation of the vessel at the wrist is the best practical guide to it in this location. In fact, it is only when abnormalities in size or situation occur at this position that the other guides are taken into serious consideration in the living subject, and under these circumstances they are of but little aid to the operator. This same statement will apply with equal force to all arteries that are similarly associated with the superficial structures of the body.

While the artery may be ligatured in any portion of its course, it is, however, usually ligatured at three situations—at the upper and lower thirds, and at the apex of the styloid process.

The Operation, Upper Third (Fig. 222, a).—Supinate the forearm; press upon the arm above the seat of operation to distend the superficial veins; make an incision about three inches in length along the linear guide to the vessel. After going through the fasciæ, the inner edge of the supinator

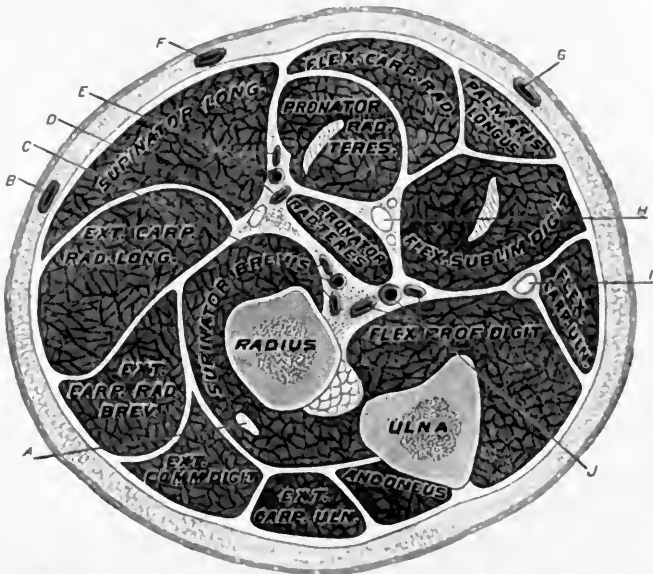


FIG. 224.—Transverse section of right forearm at upper third.

- A. Posterior interosseous nerve. B, F. Radial veins. C. Anterior interosseous vessels. D. Radial nerve. E. Radial artery and veins. G. Ulnar vein. H. Median nerve. I. Ulnar nerve. J. Ulnar artery and veins.

longus will be found extending beyond the line and overlapping the artery; separate and pull this muscle outward, when the artery will be seen lying

between its veins, with the nerve to the radial side (Figs. 224 and 225); isolate the artery, and pass the needle from without inward.

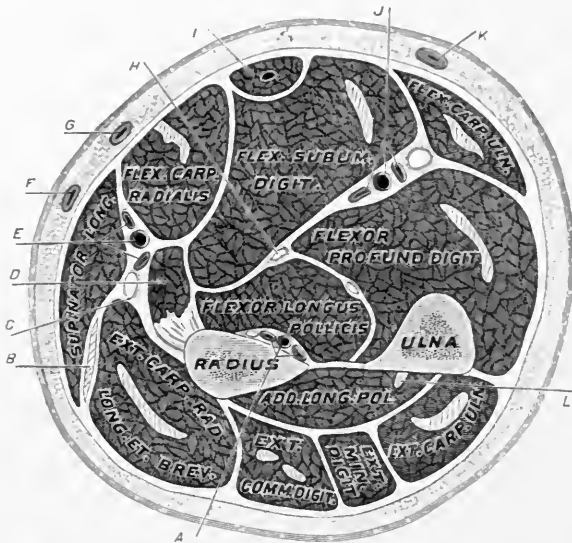


FIG. 225.—Transverse section of right forearm at middle third.

A. Anterior interosseous artery, veins, and nerve. B. Tendon of extensor carpi radialis longior. C. Radial nerve. D. Pronator radii teres. E. Radial artery and attending veins. F, G. Superficial radial veins. H. Median nerve. I. Palmaris longus. J. Ulnar artery, veins, and nerve. K. Superficial ulnar vein. L. Extensor longus pollicis.

The Operation, Lower Third, Upper and Lower Limits (Fig. 222. b. c).—At these situations the vessel is very superficial, its well-known pulsation being the best guide to it. With the arm placed as in the preceding position, make an incision, in either instance, two inches in length along the course of the vessel. After the division of the integument and fasciæ the artery will be seen surrounded by loose areolar tissue, accompanied by its veins, and lying to the inner side of the tendon of the supinator longus. Separate the tissues and ligature the artery, passing the needle from the nerve.

The Operation at Apex of Styloid Process (Fig. 226).—At this situation the vessel is found in a triangular-shaped space, bounded internally by the tendon of the extensor primi internodii pollicis, externally by that of the extensor secundi internodii pollicis, and the base corresponding to the apex of the styloid process of the radius. If the thumb be forcibly extended, the outlines of the space will be well marked.

The Operation.—Place the hand midway between supination and pronation, and, having ascertained the exact situation of the tendon of the extensor primi internodii pollicis, make an incision near to its outer border about an inch in length; use care not to divide the superficial veins. The areolar tissue and the extensor primi internodii pollicis are pulled aside, and the vessel found somewhat deeply situated. The needle can be carried in either direction.

The Fallacies.—The radial artery may lie upon the fascia and supinator longus instead of beneath them; it may pass over the extensor tendons of the thumb instead of beneath them.

The artery may be mistaken for a radicle of the radial vein. The latter is superficial, and has likewise other characteristics of a vein. In ligaturing the vessel at either of the last two positions sheaths of contiguous tendons will be opened if incautious vigor be exercised.

The Results.—During the late civil war the radial artery was tied twenty times, with four fatal results.

Ligature of the Ulnar Artery.—The ulnar artery is less frequently injured than the radial, and requires therefore less operative interference than the latter.

The Anatomical Points.—The ulnar artery is larger than the radial. It is given off from the brachial about one inch below the bend of the elbow, passes obliquely inward and downward deeply

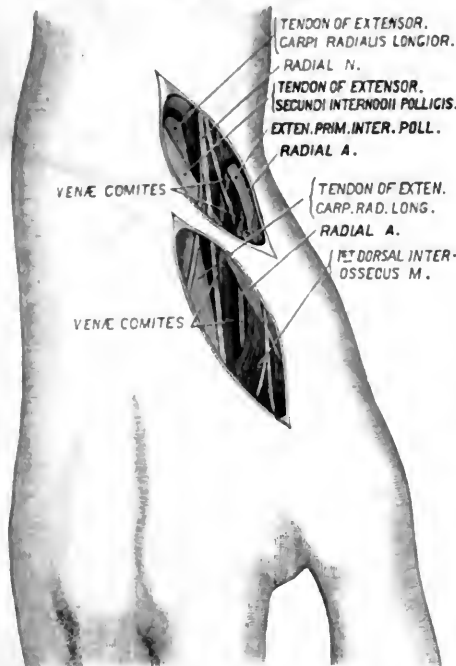


FIG. 226.—Ligature of radial at apex of styloid process.

beneath the superficial flexors of the forearm, and gains the ulnar side of the forearm a little above its middle; becoming more superficial, passes along the radial side of the flexor carpi ulnaris to the radial side of the pisiform bone, where it terminates in the superficial palmar arch.

The Contiguous Anatomy.

THE RELATIONS OF THE ULNAR ARTERY. (GRAY.)

In front.

- Superficial layer of flexor muscles. } Upper half.
- Median nerve. } Upper half.
- Superficial and deep fasciæ. } Lower half.

Inner side.

- Flexor carpi ulnaris. } **Ulnar artery** }
- Ulnar nerve (lower two thirds). } **in forearm.** }

Outer side.

- Flexor sublimis digitorum.

Behind.

- Brachialis anticus.
- Flexor profundus digitorum.

The linear guide to the lower two thirds of the vessel is drawn from the apex of the internal condyle (Fig. 222 *) to the radial side of the pisiform bone.

The muscular guide is the radial border of the flexor carpi ulnaris.

The vessel may be ligatured at three situations: 1, At the junction of the upper and middle thirds; 2, at the lower third; 3, at the wrist. It can be ligatured at its upper third, but such a step has no practical utility except when required on account of a direct injury of this portion of the vessel; it is then tied at the seat of injury.

The Operation, Junction of Middle and Upper Thirds (Fig. 222, a).—Supinate the forearm, and make an incision on the linear guide to the vessel, beginning at about four finger breadths below the internal condyle of the humerus, about three inches in length. Divide the fascia on a director; seek for a line of connection between the borders of the flexor carpi ulnaris and the flexor sublimis digitorum. It is of a yellowish-white color. Divide it in the long axis and pull the muscles apart, when the ulnar nerve will be seen, to the outer side of which will be found the artery with its accompanying veins; separate the artery and pass the needle from within outward.

The Operation in the Lower Third (Fig. 222, b).—Place the forearm as in the preceding operation; extend the hand to make the tendon of the flexor carpi ulnaris tense; make an incision about three inches in length along the radial border of this muscle down to the fascia. Divide the fascia, exposing the tendon of the flexor carpi ulnaris, which is drawn inward, and the artery is seen beneath it. Isolate the vessel from its veins and pass the needle from within outward.

The Operation at the Wrist (Fig. 222, c).—Place the hand on its dorsal surface, and make an incision about two inches in length along the radial side of the pisiform bone, with its convexity outward; carry it downward along the side of that bone through the fascia and fatty tissue to the vessel. Flex the hand and pass the ligature from within outward.

The Fallacies.—For an operation without special gravity the ligaturing of the vessel at the upper portion is attended with confusing circumstances that often defeat the object of the surgeon. Between the upper and middle thirds, the interspace between the flexor carpi ulnaris and flexor sublimis digitorum muscles may be mistaken for that between the flexor carpi ulnaris and the palmaris longus muscles, or the one between the palmaris longus and flexor carpi radialis. The “white” or “yellowish-white” interspace between the proper muscles may be indistinct, and even absent. It is best marked in muscular subjects; least observable and most frequently absent in aged and emaciated persons. The upper extremity of the linear guide should begin at the *apex* of the internal condyle. If the carpus and fingers be moved independently of each other after the division of the integument and fasciæ, the septum between the flexor carpi ulnaris and the flexor sublimis digitorum muscles can be easily ascertained.

In the upper third the vessel runs downward and inward to the ulnar side of the forearm to meet the linear guide of the lower two thirds; therefore an attempt to find the artery by the linear guide, in the upper third, will be futile. The artery may run beneath the fascia, or otherwise vary in its direction; if it be not in the normal situation, deep pressure may locate its presence and define its course.

The Results.—The ulnar artery was ligatured during the late war ten times, with three deaths.

Ligature of the Palmar Arches.—The superficial and deep palmar arches are liable to injury from traumatic violence, and it is from this cause that ligature of them is principally demanded. The free communication of the arches with other arteries through their numerous branches greatly exposes the patient to the danger of secondary hæmorrhage.

The Contiguous Anatomy.

THE RELATIONS OF THE SUPERFICIAL ARCH. (GRAY.)

In front.

Integument.
Palmaris brevis.
Palmar fascia.

Superficial palmar arch.

Behind.

Annular ligament.
Origin of muscles of little finger.
Superficial flexor tendons.
Division of the median and ulnar nerves.

The Linear Guide.—The linear guide to the superficial arch is a line extending across the palm directly along the palmar border of the thumb when abducted to a right angle with the index finger (Fig. 227).

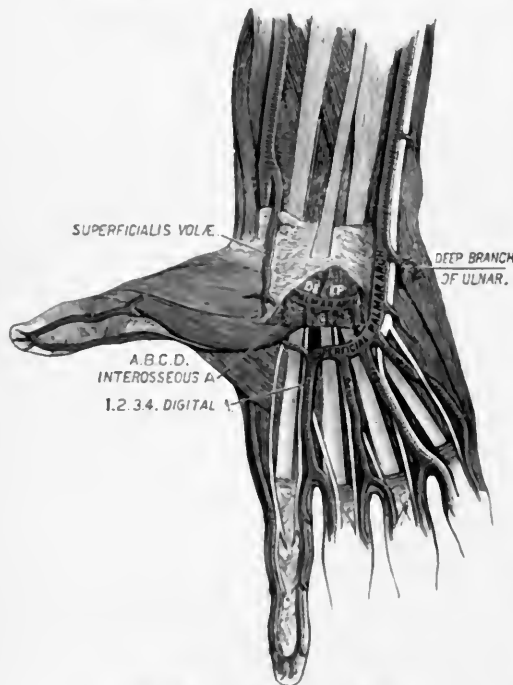


FIG. 227.—The palmar arches.

This line indicates the lower limit of the arch. The deep arch is from half to three quarters of an inch nearer the wrist joint than the superficial one.

The Operation.—Make an incision an inch in length at the seat of the injury, parallel with the nerves and tendons of the palm, through the superimposed tissue down to the vessel. Ligature all bleeding points, and also all uninjured branches arising close to the seat of the injury of the main vessel, to avoid the possibility of secondary hæmorrhage. The deep palmar arch is treated

in a similar manner. However, a greater degree of caution is necessary, for the vessel is more intricately and deeply placed than is the former.

Irrespective of the seat of the injury the superficial palmar arch can be exposed through an incision extending from the junction of the thenar eminences toward the ring finger. The deep palmar arch can be tied opposite the middle of the base of the thumb through an incision beginning at the junction of the thenar eminences and extending along the crease of the *opponens pollicis* toward the little finger.

The Precautions.—All incisions should be carefully made in the long axis of the palm, to avoid as far as possible injury of subjacent nerves, tendons, and arteries. Branches arising immediately adjacent to the seat of ligature should be tied, to afford room for the establishment of proper blood clots in the ligatured vessel. If the vessel be injured, it should be tied at either side of the seat of injury.

Ligature of the Common Carotid Artery.—The common carotid artery is the most important vessel in the neck, and frequently demands operative procedure.

The Anatomical Points.—The right common carotid arises from the innominate artery, and the left from the arch of the aorta. The left is consequently longer and more deeply situated in the chest. The left, after leaving the aorta, passes obliquely upward to a point opposite the left sterno-clavicular articulation; and from this point onward the right and left common carotids maintain substantially the same course to the upper border of the thyroid cartilage, where each divides into the internal and external carotids.

The Contiguous Anatomy.

THE RELATIONS OF THE COMMON CAROTID ARTERY. (GRAY.)

In front.

Integument and fascia.	Omo-hyoid.
Platysma.	Descendens noni nerve.
Sterno-mastoid.	Sterno-mastoid artery.
Sterno-hyoid.	Superior thyroid, lingual, and facial veins.
Sterno-thyroid.	Anterior jugular vein.

Externally.

Internal jugular vein.	} Common }
Pneumogastric nerve.	
	} artery. }

Internally.

Trachea.
Thyroid gland.
Recurrent laryngeal nerve.
Inferior thyroid artery.
Larynx.
Pharynx.

Behind.

Longus colli.	Sympathetic nerve.
Rectus capitis anticus major.	Inferior thyroid artery.
	Recurrent laryngeal nerve.

The linear guide to the vessel is a line drawn from the sterno-clavicular articulation to midway between the angle of the jaw and mastoid process.

The muscular guide to the operation is the anterior border of the sterno-cleido-mastoid muscle.

Each vessel may be *ligatured at three situations*: 1, At the root of the neck; 2, just below the omo-hyoid muscle; 3, above that muscle. The last two are the situations commonly selected, the first not being employed except under forced circumstances.

The Operation below the Omo-hyoid (Fig. 228, 1).—Place the patient on the back, with the shoulders slightly elevated, and the head turned to the opposite side; make an incision three inches in length, beginning a little above the level of the cricoid cartilage, on the line stated, and carry it down-

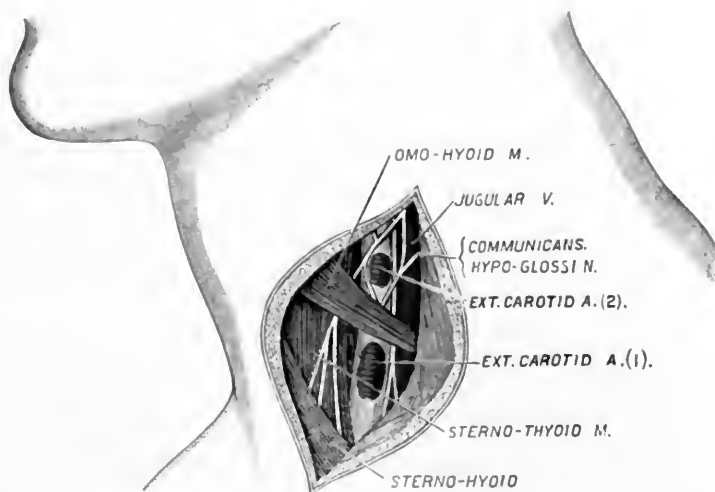


FIG. 228.—Ligature of common carotid artery.

1. Ligature below omo-hyoid.
2. Ligature above omo-hyoid muscle.

ward along the anterior border of the sterno-mastoid (Fig. 205, c); divide the superficial fascia, platysma, and deep fascia on a director, thus exposing the anterior border of the sterno-mastoid muscle. If the sterno-mastoid artery be divided, ligature it. If not injured, push it aside, together with the thyroid vein; draw the sterno-mastoid muscle outward and the sterno-thyroid and hyoid muscles inward, then the lower border of the omo-hyoid will be seen above; divide the fascia beneath these muscles and draw the borders apart, when the descendens noni nerve will be seen resting upon the inner portion of the common sheath of the carotid artery, internal jugular vein, and the pneumogastric nerve, the artery being to the inner side, the pneumogastric nerve behind and between the two and out of sight. Place the finger upon the sheath, to ascertain the exact location of the artery; raise the portion of the sheath corresponding to the site of the artery at the inner side with a tenaculum or the thumb forceps, cut a small opening into it, grasp and hold apart the borders with thumb forceps, and pass the needle from without inward, cautiously insinuating it between the vessel and the sheath (Fig. 228, 1). The manipulation should be carefully done, else either the vein, pneumogastric, or recurrent laryngeal nerves may be injured.

The Operation above the Omo-hyoid (Fig. 228, 2).—The vessel is more

superficial here than below the omo-hyoid, and this situation is therefore denominated "the site of election."

Place the patient as before, and make an incision along the anterior border of the sterno-mastoid, beginning at about the angle of the lower jaw, and extending it to a little below the cricoid cartilage; divide the superficial fascia, platysma, and deep fascia on a director, carefully avoiding the small veins; expose the anterior border of the sterno-mastoid, and slightly flex the head to relax the tissues of the neck; draw the edges of the wound apart, and the artery will be felt pulsating in its sheath. If the jugular vein overlap it, the vein should be emptied by pressure made above and below, and be drawn outward; then carefully open the sheath as before, avoiding the descendens hypoglossi nerve; pass the needle cautiously from without inward. It is well to observe the upper border of the omo-hyoid muscle before opening the sheath, so that the exact location to apply the ligature may be assured.

The Fallacies.—The artery may bifurcate at the cricoid cartilage, and even lower; however, this bifurcation is extremely rare; under such circumstances both branches should be secured. If the vessel be pressed upon before the ligature is tied, the pressure will determine the influence of the ligaturing upon the branches above, and thus obviate an error of application.

The jugular vein may be much dilated, overlie and receive the impulse of the artery, and therefore be mistaken for it. This fallacy will be avoided if the vein be emptied of its blood in the manner before described. The thyroid body may be enlarged and obscure the artery by displacing or overlapping it. Under these conditions it should be pushed aside. It is reported that the omo-hyoid muscle has been mistaken for the artery; the fact of its being muscular, taken in connection with the direction of the fibers, together with its anatomical relations, should eliminate any liability of this mistake. A large branch arising from the main trunk may be mistaken for the external carotid. However, the comparative size of the vessel and the influence of pressure on the circulation of the branch will effectually solve the question. If branches be given off from the common carotid near the site of the proposed ligaturing, they should be tied also.

A broad sterno-mastoid may cause confusion by the placing of the incision too far inward; if narrow, or the head be turned far outward, the muscle may again misdirect the incision, this time to the outer side of the vessel. Respiratory movements of the tissues of the neck, inflammatory processes, morbid growths, and dilated veins, each contribute more or less to the difficulties of the occasion. It should not be overlooked that ligature of the common carotid for hæmorrhage from either the internal or external divisions will not likely be effective, on account of the free communication of these two vessels at the point of bifurcation of the main trunk, to say nothing of the collateral flow from the opposite side.

The Results.—Of 834 cases of ligature, 327 died; of 789 before asepsis, 323 died; of 45 under asepsis, 4 died; i. e., 19 for aneurism, 11 died; 23 for hæmorrhage, 3 died; 3 for tumor, no death.

Ligature of Both Common Carotids.—Ligature of both common carotids, either simultaneously or at variable intervals, has been done thirty-six

times. The shortest interval between operations in which recovery has taken place is four and a half days. Instances where the interval varied from thirteen to thirty days are reported, with recovery of the patients.

Temporary Ligature of the Common Carotid.—The carotid may be temporarily ligatured. The procedure has been resorted to by Rivington and others, with the view of arresting hæmorrhage arising from branches of the common carotid without exposing the patient to the dangers of brain complications incident to permanent closure. The operation consists in exposing the vessel in the usual manner and passing around it a broad catgut or other ligature, which is tightened or raised sufficiently to close the lumen of the vessel and arrest hæmorrhage. If in troublesome bleeding during operation a ligature is passed around the vessel that supplies blood to the operative field, and raised from time to time sufficiently to control the blood current, finally being removed, much blood will be spared and valuable time gained. The external carotid is treated similarly for like reasons with equally good effects.

Ligature of the External Carotid Artery.—The external carotid artery is tied at one or both sides to prevent the free loss of blood that so often attends operations within the field of its supply. The fear of secondary hæmorrhage can not be urged in opposition to the measure if the collateral branches near to the seat of the ligature be tied at the same time. The author has practiced this plan repeatedly, and with eminent success in each instance but one. In this one the facial arose from the common carotid, just below the bifurcation, and the patient died from secondary hæmorrhage, caused by sloughing of a malignant growth in which the facial was involved, and for the amelioration of which both external carotids had been tied simultaneously. Dawbarn removes the vessels (page 209).

The Anatomical Points.—The external carotid artery arises from the common carotid at or just above the upper border of the thyroid cartilage. It ascends in a slightly curved course, with the convexity forward, to a point midway between the neck of the condyle of the lower jaw and the external auditory meatus. The upper part of its course lies in the substance of the parotid gland.

The Contiguous Anatomy.

THE RELATIONS OF THE EXTERNAL CAROTID. (GRAY.)

In front.

Integument, superficial fascia.
Platysma and deep fascia.
Hypoglossal nerve.
Lingual and facial veins.
Digastric and stylo-hyoid muscles.
Parotid gland, with facial nerve and temporo-maxillary vein in its substance.

{ **External**
 carotid
 artery. }

Behind.

Superior laryngeal nerve.
Stylo-glossus.
Stylo-pharyngeus.
Glosso-pharyngeal nerve.
Internal carotid artery.
Parotid gland.

Internally.

Hyoid bone.
Pharynx.
Parotid gland.
Ramus of jaw

The *linear* and *muscular guides* are substantially the same as those of the common carotid.

The *bony guide* is the greater cornu of the hyoid bone, which lies to the inner side of the vessel, above the bifurcation of the common carotid and near to the origin of the lingual artery. If pressure be made on one side of the hyoid bone the greater cornu will be made prominent on the opposite side and easy of determination.

The artery *may be tied at two situations*: above and below the posterior belly of the digastric muscle. The latter situation is the one to be selected, if possible.

The Operation below the Digastric Muscle.—With the patient on the back, head slightly extended and turned to the opposite side, make an incision along the anterior border of the sterno-mastoid, beginning opposite the angle of the lower jaw, and carry it downward to a point nearly opposite the cricoid cartilage (Fig. 214, *b*). Divide the superficial fascia, platysma, and deep fascia, and expose the anterior border of the sterno-mastoid. The edges of the wound should be drawn well apart, when the hypoglossal nerve and the digastric and stylo-hyoid muscles will come into view (Fig. 216).

The end of a grooved director should now be employed to separate and push aside the lingual and facial veins, together with the areolar tissue and lymphatic glands that rest upon the vessel. Expose the artery and pass the ligature from without inward. The internal jugular vein oftentimes overlaps the vessel, and should be carefully drawn aside, or treated as recommended in ligaturing the common carotid.

The Precautions.—Before the ligature is tied the following facts should be carefully observed: 1. If it be the external carotid around which the ligature is passed, this can be ascertained by raising the ligature and observing the effect upon the circulation of the facial. 2. The distance of the seat of the ligature from collateral branches; this fact can only be determined by carefully exposing the vessel for half an inch or so above and below the seat of the ligature. If vessels be found within this extent, they, too, should be ligatured independently to destroy the possibility of any interference with the formation of the internal clot. 3. That the ligature be not carried around the external and internal carotids at or just above their point of bifurcation; if it be around both, pressure or traction will check the pulsation of both; if but one, it will control only the circulation of the vessel acted upon. Expose and clamp the common facial vein early in the operation.

The Fallacies.—Enlarged lymphatic glands resting on the vessel may be mistaken for it. They need cause but momentary thought, since their circumscribed outline and mobility will determine their nature. If enlarged, they should be removed, otherwise they can be pushed aside. The superior thyroid branch may be confounded with the lingual. If the course of the respective vessels be observed, they can be readily distinguished from each other; the superior thyroid arises nearest the bifurcation, arches upward and forward, then passes quite directly downward. The lingual does not arch downward, but passes upward and inward to gain the upper border of the greater cornu of the hyoid bone, which can be easily outlined by the finger.

The Operation above the Digastric.—Make an incision from the lobule of the ear to the greater cornu of the hyoid bone, along the anterior border of the sterno-mastoid, carefully avoiding the parotid gland. Divide the superimposed tissues as before, down to the digastric muscle; pull it, together with the stylo-hyoid, downward, and if the jugular vein be in the way, push it outward, and pass the ligature from without inward.

The Results.—Of 143 cases of ligature of one external carotid, 20 died; 91 were done before asepsis, with 16 deaths; of 51 done under asepsis, 4 died; of 15 simultaneous ligatures of both external carotids, under asepsis, 1 died.

Ligature of the Internal Carotid Artery.—The internal carotid artery is tied sometimes at either side of the bleeding point, to arrest hæmorrhage.

The Anatomical Points.—The internal carotid begins at the bifurcation of the common carotid, at or a little above the upper border of the thyroid cartilage, and passes perpendicularly upward in front of the transverse processes of the three upper cervical vertebræ, to the carotid foramen in the petrous portion of the temporal bone, through which it enters into the cranial cavity. At its origin and in the lower portion of its course it is comparatively superficial, and lies *externally* and *posteriorly* to the external carotid artery.

The Contiguous Anatomy.

THE RELATIONS OF THE INTERNAL CAROTID ARTERY. (GRAY.)

In front.

Skin, superficial and deep fasciæ.
Platysma.
Parotid gland (above the angle of the jaw).
Stylo-glossus and stylo-pharyngeus muscles.
Glosso-pharyngeal nerve.
Hypoglossal nerve.

Externally.

Internal jugular vein.
Pneumogastric nerve.

} **Internal carotid** }
} **artery.** }

Internally.

Pharynx.
Superior laryngeal nerve.
Ascending pharyngeal artery.
Tonsil.

Behind.

Rectus capitis anticus major.
Sympathetic.
Superior laryngeal nerve.

The *linear* and *muscular guides* of the external carotid artery are suitably adapted to properly locate the internal carotid.

The angle of the jaw is located directly externally to the tonsil, and it therefore may become a *practical bony guide* to the incision for ligaturing the artery in this situation. Although it *may be ligatured in any part of the course* between its origin and the angle of the lower jaw, still the point of election is that just above the bifurcation. It may become necessary to ligature this artery on account of a penetrating wound received from without or from within the mouth. Ulcerations of and operations on the tonsils have been complicated with injuries to this vessel that have caused death

from hæmorrhage. It is therefore very important to recall the relations of the tonsil and pillars of the pharynx to this artery, in connection with all injuries and morbid processes of their structures.

The Operation.—The position of the neck of the patient and the location of the primary incision are similar to those for the ligaturing of the external carotid. The respective tissues are carefully divided on a director down to the muscles, which are separated and pulled aside, and the ligature is passed from without inward, carefully avoiding the jugular vein and the pneumogastric nerve at the outer, and the pharynx at the inner side.

The Fallacies.—The internal carotid may arise from the arch of the aorta, and when this occurs hæmorrhage from it can be checked only by ligaturing the internal carotid itself. If but one ligature be applied to the internal carotid for hæmorrhage, or if the common carotid be ligatured alone for the same reason, the collateral circulation may cause a continuation of the bleeding. A ligaturing of the internal carotid at both sides of the bleeding point is the only certain means of arresting the hæmorrhage permanently. The internal carotid may lie internal to the external carotid. It may be tortuous, or even be absent.

The Results.—This vessel has been tied singly several times; with either the common or external carotid, or both, fifteen times. Six of these patients died, from causes demanding the operation. Simultaneous ligature caused death in 15 per cent of the cases from cerebral sequels.

Ligature of the Superior Thyroid Artery.—The superior thyroid is ligatured in the removal of some morbid growths and for the arrest of bleeding due to direct injury of the structure.

The Anatomical Points.—The superior thyroid vessel comes from the external, or from the common carotid near the point of its bifurcation. It passes upward and forward, at first quite superficially, then runs downward and less superficially to enter the thyroid gland. The artery is closely associated with the superior laryngeal nerve. The vessel may be absent, single, or double in arrangement.

The Operation.—Make an incision about three inches in length along the anterior border of the sterno-mastoid, its center corresponding to a point opposite the thyro-hyoid space. The carotid sheath should be exposed as in the ligature of the carotid, and the artery sought for along the inner border (Fig. 216). The ligature is applied near to the origin of the vessel or close to the larynx, the latter being the better situation. Cautiously avoid the superior laryngeal nerve.

Ligature of the Lingual Artery.—The lingual artery is ligatured more often to control hæmorrhage during removal of the tongue than for any other purpose.

The Anatomical Points.—The lingual artery arises from the external carotid opposite the hyoid bone, about three quarters of an inch above the bifurcation of the common carotid, and runs upward and inward to about a quarter of an inch above the upper border of its greater cornu, passes horizontally inward parallel with it, resting upon the middle constrictor of the

pharynx, and covered first by the digastric and stylo-hyoid muscles, and more internally by the hyoglossus muscle. It then ascends between the hyoglossus and genio-hyoglossus muscles, and terminates in the ranine artery.

It has *no superficial muscular guide*; a *linear guide* may be drawn parallel with and a fourth of an inch above the greater cornu of the hyoid bone (Fig. 214, *f*); practically, however, the upper border of the greater cornu of the hyoid bone marks its location. The vessel *can be ligatured at three situations*: 1, At the apex of the greater cornu; 2, between the greater cornu and the posterior belly of the digastric; 3, in the triangle made by the digastric and mylo-hyoid muscles and hypoglossal nerve.

The Ligature at the First Situation.—In this situation the vessel is tied between the point of origin and the tip of the greater cornu of the hyoid bone (Figs. 216 and 229).

The Operation.—Make an incision three inches in length running obliquely downward and forward as for ligature of external carotid, its center corresponding to the greater cornu. The various tissues are carefully divided, as for ligature of the external carotid, and the hypoglossal nerve is exposed. The numerous veins located in the course are now pushed aside, and the artery carefully sought for at the point of the cornu and ligatured. This operation, on account of the absence of a definite deep guide to the location of the vessel, and the uncertainty of its point of origin, together with the great number of large veins in the course of the search, is much less feasible than either of the other two. While ligature at this portion controls the circulation of the dorsalis linguæ, yet the difficulty attending the step is in excess of the advantages gained by its employment.

The Ligature at the Second Situation.—Place the patient on the back, and turn the head to the opposite side; carefully define the greater cornu of the hyoid bone. If the neck be fleshy this will be somewhat difficult. The cornu can be made more prominent on the side of the operation by pushing against the body of the bone on the opposite side, being careful to press the bone directly toward the cornu, otherwise the operator may be misled. After the patient is thoroughly anæsthetized (to prevent spasmodic movements of the muscles attached to the hyoid bone) make a slightly concave incision just above and along the upper border of the greater cornu of the hyoid bone, downward and outward to nearly the anterior border of the sternomastoid muscle, about three inches in length (Fig. 214, *f*). Divide the superficial fascia, platysma, and deep fascia on a director; draw upward the submaxillary gland and divide the deep aponeurosis transversely, when the digastric and stylo-hyoid muscles and the hypoglossal nerve will be exposed. Accurately locate the greater cornu with the finger, and fix and drag it forward into the wound with a tenaculum; draw up the digastric and the stylo-hyoid muscles and hypoglossal nerve with a blunt hook; push aside the lingual vein if seen, and pick up the fibers of the hyoglossus with forceps, and incise them for three quarters of an inch in the direction of the external incision, about a quarter of an inch above the greater cornu; beneath them will be found the vessel, sometimes accompanied by the lingual vein. Ordinarily the vessel will “elbow” itself into the incision

as soon as all the intervening muscular fibers are divided (Fig. 229). Pass the needle from the vein. Before tying ascertain if traction on the ligature will stop the pulsation of the artery.

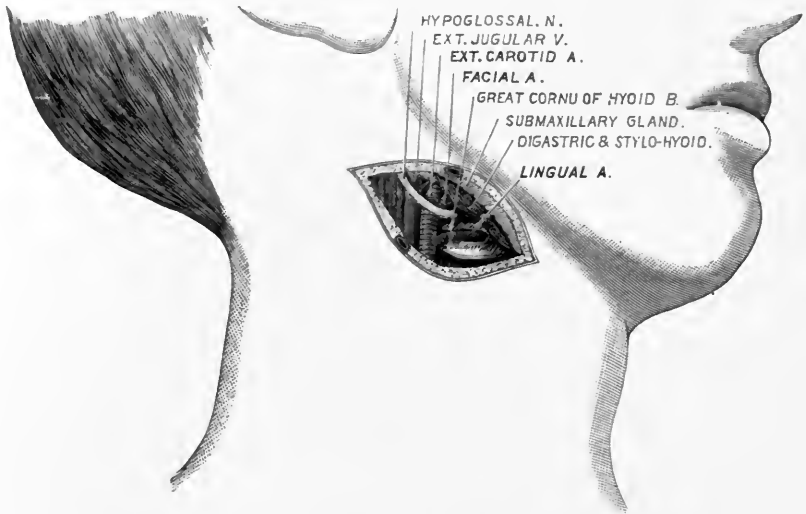


FIG. 229.—Ligature of lingual artery. First and second situations.

The Ligature in the Third Situation.—The third situation is often called “the place of election.” Make an incision transversely two inches long, concavity upward, and its center just within the middle of the greater cornu of the hyoid bone. Divide the integument, superficial fascia, and platysma, carefully avoiding the superficial veins; sever the deep fascia and pull upward the submaxillary gland, when the posterior belly of the digastric will come into view, as will also the posterior border of the stylo-hyoid muscle,

the mylo-hyoid muscle, and the hypoglossal nerve, accompanied usually by the lingual vein (Fig. 230). Carefully outline the triangle before mentioned; pinch up the fibers of the hyoglossus, and divide them midway between the hyoid bone and the nerve, when the artery will be seen beneath.

Separate it from the vein if the vein lie beneath the muscle, and pass the ligature from above downward.

The Fallacies.—The hypoglossal nerve may be mistaken for the artery. The nerve rests *on* the hyoglossus, the artery runs *beneath* it. These facts, together with the pulsation of the artery and other distinctive anatomical features, should render the discrimination easy. It is well to know, however,

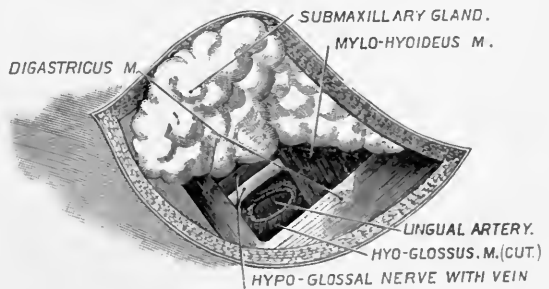


FIG. 230.—Ligature of lingual artery. Third situation.

that the movements of the tissues dependent on the acts of respiration make it somewhat difficult, and often impossible, to detect the arterial impulse. If, however, the supposed artery be carefully isolated, the ligature passed around it, and a good light thrown into the wound, its tortuous outline will be noticed with each pulsation. The pulsation can be seen best in the interval of the respiratory acts when the tissues are quiet. However, firm fixation and forward traction of the cornu by means of a tenaculum will prevent movements of the tissues, render them superficial, and otherwise greatly aid in the exposure, recognition, and ligature of the vessel.

The lingual vein may be mistaken for the artery, especially in old people with heart lesions, as in old age the coats of the vein are usually much thickened, and pulsation in the vein may attend heart disease. The vein sometimes runs with the artery behind the hyoglossus muscle; more frequently, however, it rests on this muscle. It has the characteristic color of a vein, and is larger than the artery. The lingual artery may be absent, run higher than common, or lie in the structure of the hyoglossus. After the division of the fibers of the hyoglossus muscle the search for the vessel must be conducted cautiously to avoid opening into the pharynx. If the vessel can not be found above the cornu, and ligation be imperative, it should be sought for at the origin.

The Results.—This artery has been tied repeatedly with great advantage, for the purpose of controlling hæmorrhage from the tongue and delaying the development of morbid growths of that structure.

Ligature of the Facial Artery.—The facial artery is one of the large branches of the external carotid, and is divided into a cervical and facial part.

The Anatomical Points.—The artery arises just above the tip of the greater cornu, or about an inch from the bifurcation of the common carotid, passes forward and upward beneath the horizontal ramus of the lower jaw, going through the substance of the submaxillary gland, and gains the external surface of the ramus at the anterior inferior angle of the masseter muscle, lying there in a groove at the outer border of the bone. The masseter, therefore, is the *muscular guide* at this portion of the course of the vessel. It may be *ligatured at three situations*—in the neck, and as it crosses the ramus of the jaw and near the angle of the mouth, the second being the best situation.

The Operation in the Neck.—The head is turned to the opposite side, and an incision of about three inches in length is made obliquely downward and forward a little in front of the anterior border of the sterno-mastoid, its center being at a point about a third of an inch above the tip of the greater cornu (Fig. 216). The dissection is carefully made, as in ligaturing the lingual at the first portion, by pushing aside the facial and other contiguous veins, drawing up the digastric, and passing the ligature.

The Operation at the Ramus of the Jaw.—Place the patient as before; draw the integument upward over the ramus, so that when retraction of the tissues occurs the cicatrix will fall beneath the jaw; make an incision about two inches in length along the border of the jaw; divide the tissues on a

director (Figs. 214, *c*, and 217) down to the vessel, isolate it, and pass the ligature from behind forward away from the vein. If a resulting cicatrix be of no moment, the primary incision can be made in the long axis of the vessel along the anterior inferior angle of the masseter muscle (Fig. 214, *c*). It is rarely tied at the angle of the mouth (Fig. 313).

The Fallacies.—At its origin this vessel may be mistaken for the lingual. Interruption of the circulation will easily make the distinction if the respective areas of supply be examined.

Ligature of the Temporal Artery.—The temporal artery is one of the terminal branches of the external carotid.

The Anatomical Points.—The temporal artery begins in the substance of the parotid gland between the neck of the lower jaw and the external meatus, and passes upward across the root of the zygoma, subcutaneously, where its pulsation can be distinctly felt. About two inches above the zygomatic process it divides into its terminal branches. This artery has *no muscular guide*. The zygomatic process is the *bony guide*.

The Operation (Fig. 214, *d*).—Make an incision in the line of the vessel, as indicated by its pulsation, an inch in length; about one fourth of an inch in front of the tragus divide the skin and fascia; avoid the vein lying behind the artery, the temporo-facial nerves lying in front, and the auriculo-temporal nerve beneath the vessel; expose the vessel and pass the needle from behind forward (Fig. 313).

Ligature of the Occipital Artery.—The occipital artery is often severed in injuries of the scalp.

The Anatomical Points.—The occipital artery arises from the external carotid a trifle above the facial, and passes upward and outward to the interval between the transverse process of the atlas and the mastoid process of

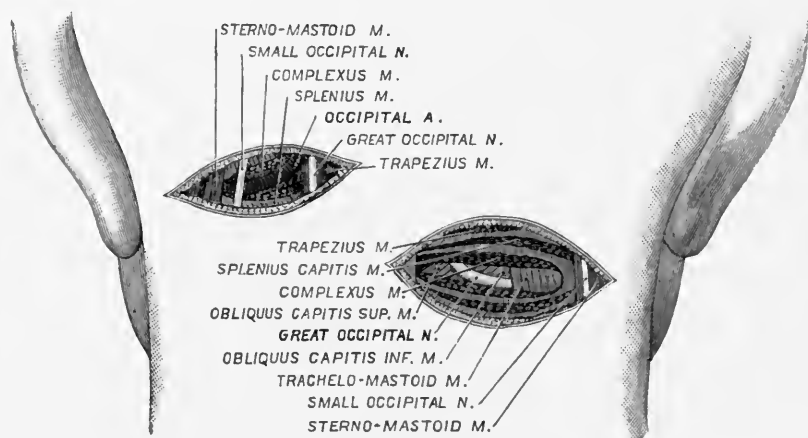


Fig. 231.—Occipital artery and great occipital nerve.

the occipital bone. It then passes over the posterior portion of the skull midway between the external occipital protuberance and the mastoid process

(Fig. 214, e). It has *no intimate bony or muscular guide*. It is tied at its origin and behind the mastoid process.

The Operation at the Origin (Fig. 216).—Make an incision along the anterior border of the sterno-mastoid, about three inches in length, the center corresponding to a point a little above the apex of the greater cornu of the hyoid bone. Divide the superficial tissues carefully on a director, separate the areolar tissue with its blunt extremity, push aside the veins, and find the posterior belly of the digastric. A little below will be seen the ninth nerve winding around the object of search. Pass the needle from the nerve. The relation between the hypoglossal nerve and the vessel is constant, irrespective of the deviations from normal in other regards of either of these structures. Very rarely, indeed, the occipital artery arises from the internal carotid.

The Operation behind the Mastoid Process (Fig. 231).—Make a transverse incision about two inches in length, beginning half an inch behind and a little below the mastoid process and extending inward. Divide the integument and attachments of the sterno-mastoid and the splenius muscles; feel for the pulsation at the bottom of the wound. Isolate the artery and pass the ligature.

SPECIAL OPERATIONS ON ARTERIES.

Extirpation of Aneurism.—Latterly the extirpation, especially of traumatic aneurisms mainly of the arterio-venous type, has been given much thought, and experience prompts the belief that this operation is a method of practice to be commended. Naturally the technique is considerably varied by the seat and size of the vessel involved. The following is illustrative of the procedure as practiced by *Matas** in the case of an arterio-venous aneurism of the subclavian performed nine days after the injury.

The Operation.—For the purposes of systematic description *Matas* divided this operation into seven stages.

The First Stage.—Free infiltration of tissues overlying the clavicle with *Schleich's* No. 1 solution followed by denudation of the clavicle of periosteum and the making of two holes at either side of the junction of the middle and outer thirds of the bone and its division at that point with a *Gigli* saw.

The Second Stage.—Free eucaïn infiltration of tissues below and about the seat of the procedure followed by the formation of an osteo-plastic flap beginning at the line of section of the bone, going downward two inches, then inward and upward crossing the right sterno-clavicular joint to the median line of the neck, ending at the lower border of the thyroid cartilage. Disarticulation of the clavicle and œdematous infiltration with solution of eucaïn.

The Third Stage.—The dissection and elevation of the flap, exposing the sterno-thyroid and sterno-hyoid muscles and the superficial veins of that region. A rest of ten minutes with heart stimulants given.

* *Transactions American Surgical Association, 1902.*

The Fourth Stage.—The division and removal of the subclavius muscle followed by careful exposure, recognition and preparatory securing of the veins of the region.

The Fifth Stage.—This stage was directed to the exposure of the arterial trunks at the proximal aspect of the aneurism. The innominate being absent, the first portion of the subclavian was controlled by a temporary traction loop. Chloroform was given.

The Sixth Stage.—“The detachment of the subclavian vein from the artery at the point of injury after failure to identify the third portion of the vessel outside the scalenus anticus on account of a mass of exudate which masked it completely. Profuse hæmorrhage from the artery at the anastomotic orifice in spite of complete control of this vessel at its origin. Final ligation of the artery at each side of the bleeding point. Closure of the venous orifice by suture without obstructing its lumen.”

The Seventh Stage consisted in the readjustment of the flap, drainage and closure of the wound.

The subject of this unusually difficult case made a good recovery.

The Results.—*Matas* reports 15 analyzed cases, 11 of which were treated expectantly. Of these latter one died from hæmorrhage after healing of the wound, three weeks later. The remaining ten recovered. Four were operated on, three within 12 days, all recovered; one after 32 years, for aneurismal complications, who died.

Moynihan * in 1897 extirpated a spontaneous aneurism of the subclavian. Secondary hæmorrhage on the fifty-ninth day after the operation

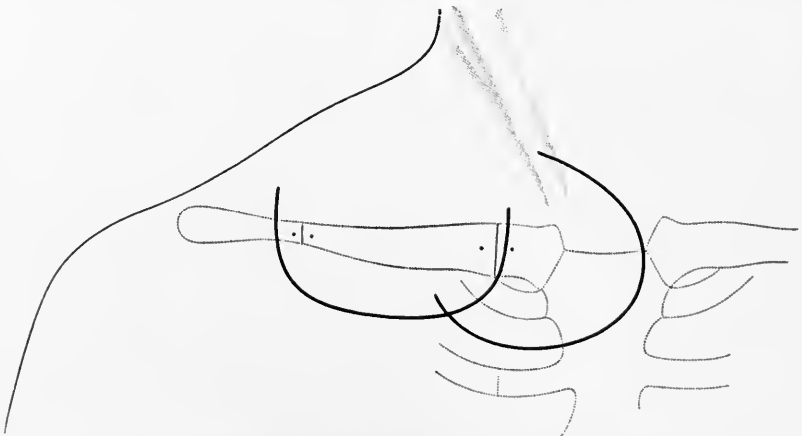


FIG. 232.—The bony landmarks and the outlines of flaps for extirpation of aneurism and for subsequent ligation of innominate.

requiring ligation of the innominate, which was followed by death of the patient in a few hours.

The Operation.—A curved incision with the convexity downward was made, commencing over the trapezius muscle internal to and above the

* *Annals of Surgery*, July, 1898.

acromio-clavicular joint and ending above and external to the sterno-clavicular joint, its lowest point being about one and a half inches below the center of the clavicle (Fig. 232). The flap thus marked out was reflected upward, and the full extent of the subclavian triangle exposed (Fig. 233). The outer half of the clavicular attachment of the sterno-mastoid muscle was divided about three-fourths of an inch above the clavicle, leaving

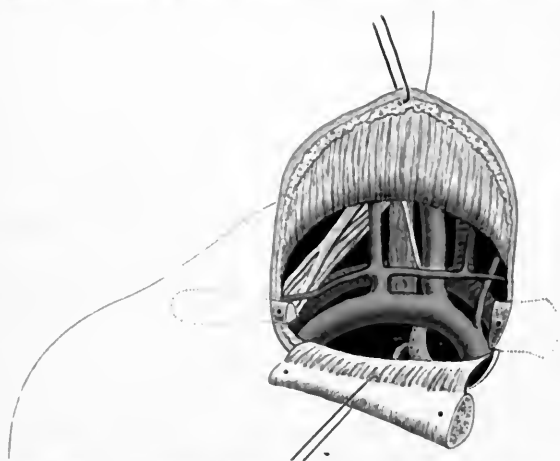


FIG. 233.—The flaps reflected, showing subclavian vessels, scalenus muscle, phrenic nerve, and brachial plexus.

sufficient of the muscle attached to the bone to enable the divided fibres to be readily stitched after the completion of the operation. The clavicle being cleared on its anterior surface, four holes were now drilled through it, two about half an inch apart, at a distance of one and a half inches from the sterno-clavicular articulation, and two, the same distance apart, at the junction of the middle and outer thirds of the

bone. Between the inner two and between the outer two the bone was sawn through by Hey's saw, and the middle portion, connected with the subclavius muscle, liberated. Round the bone a large curved Hagedorn needle threaded with a fairly stout silk traction loop was passed, by means of which the mid portion of the clavicle was pulled downward (Fig. 233). The aneurismal sac was now exposed and cleared, and the dissection to expose the outer edge of the anterior scalenus, and the artery beneath it, was commenced. After a brief and somewhat tedious clearing of parts, during which a vein was divided about one-fourth inch from its junction with the subclavian vein and ligatured, the scalenus anticus was well exposed. It was now seen that the aneurismal swelling began almost exactly at the outer border of the scalenus, and on raising this latter with a retractor the second portion of the subclavian artery was readily exposed. The phrenic nerve lying on the scalenus was quite distinctly visible (Fig. 233).

There was no difficulty in passing an ordinary aneurism-needle threaded with four strands of thoroughly well-sterilized .00 catgut round the second portion of the vessel, and tying tight at a distance of about one-third inch from the aneurism. Between this ligature and the sac a thin silk ligature was passed and tied as close up to the sac as was possible. The subclavian artery was then cut through between these ligatures, and the aneurism freed on its inner side. All adhesions to the sac were now rapidly and very easily stripped away, and the dissection carried on till the first part of the axillary artery was reached. This was ligatured with catgut in the

same manner as the subclavian, at a distance of about one inch from the aneurism. On cutting the vessel through internal to the ligature the aneurism was free, and was removed, and the mid portion of the clavicle, freed from its silk retractor, replaced.

Through the holes previously bored in the bone silver-wire sutures were passed, and the loose middle fragment thus firmly fixed in position. The cut portion of the sterno-mastoid was sutured. A little loose iodoform-gauze packing was passed into the wound from the outer angle of the flap, and the skin wound united with interrupted sutures of silkworm gut. At the end of the operation the patient's condition was excellent. He was put to bed and kept lying flat on his back, without pillows.

On February 6th, the fifty-ninth day after the operation, the patient felt "something burst," deep in his neck. Digital pressure and the subsequent application of a pad and bandage checked the hæmorrhage for a time, but on the morning of February 8th a fresh gush of blood occurred. It was therefore determined to open up the subclavian triangle and deal with what one should find. A terrific hæmorrhage occurred from the lower and inner part of the subclavian triangle. The forefinger passed down in this direction entered, at a great depth, an aperture in the subclavian artery into which the tip of the finger just fitted. To reach this opening from the posterior triangle was quite impossible, and therefore it was decided to *ligature the innominate artery*.

A curved incision was made with the convexity to the left, beginning about two and a half inches above the clavicle over the sterno-mastoid muscle, and terminating about two and a half inches below the clavicle, at, approximately, the junction of its inner and middle thirds (Fig. 232 *a*). The incision extended to the left sterno-clavicular articulation. The flap

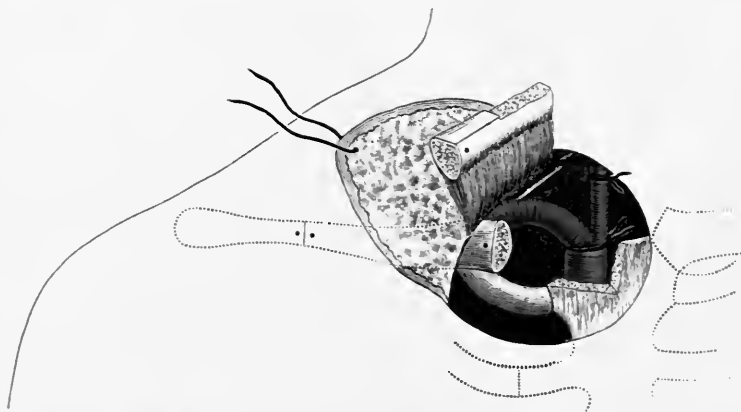


FIG. 234.—The flap reflected, bones divided, innominate and carotid arteries tied.

so outlined was turned outward, exposing the sterno-mastoid, the inner end of the clavicle, the sterno-clavicular articulation, and a portion of the upper end of the sternum. The clavicle was then pierced with two holes about half an inch apart, the internal one being at a distance of about one

inch from the inner extremity of the bone. Between these two holes the bone was divided with a Hey's saw. A piece of the sternum was then outlined and removed by sawing or chiselling from the upper end of the cartilage of the first rib to the middle line of the bone or a little beyond, and from the end of this incision a second was carried upward to the upper border of the sternum about its middle. The posterior surface of the sternum was cleared by passing the finger behind it. The inner end of the clavicle and the piece of the sternum were then turned upward, and access was readily given to the innominate artery just before its bifurcation (Fig. 234). A ligature was then applied without the least difficulty, and with the confident assurance that no neighboring structures were included, the bones were replaced.

The Remarks.—Silver wire or silkworm gut can be used to unite and fix the divided clavicle, and the sternum is quite easily held in position by a few silkworm-gut or catgut sutures, passed through its periosteal covering. Though my patient did not live to demonstrate the after-effects of this operation, there can be little doubt that all the tissues would heal satisfactorily, and that the bony union would eventually be complete and sound.

In this operation I ligatured the common carotid, and subsequently the innominate, with fine silk. The patient, in spite of all attempts at restoration, died about one hour after the completion of the operation.

The Results.—Souchon * reports 58 cases of spontaneous aneurism of the third portion of the subclavian with only 8 recoveries. Forty-three were treated with proximal ligature, 3 recovered; 6 by distal ligature, 1 recovered; 6 by amputation at shoulder-joint, 2 recovered; 2 by opening sac, 1 recovered; 1 by extirpation, with recovery. Halstead † and Curtis have each recorded a successful case.

Aneurism of the Extremities of common or arterio-venous type can be treated more satisfactorily by extirpation than can those located in connection with the trunk. In the former instances, after controlling the circulation by an Esmarch's bandage or other means, the sac is exposed in the long axis, carefully avoiding injury of intervening important structures; the vessels above and below, mainly contributing to its growth, are ligatured, the sac opened and the contents removed.

Ligature of apparent collateral branches should be carefully done before removal of the constricting agent, which latter should be slowly practiced, supplemented perhaps with digital pressure, so as to permit the catching of bleeding points as they may become manifest. After the arrest of hæmorrhage the sac should be dissected out as completely as may be consistent with the integrity of the important contiguous structures. The remaining cavity is closed by means of buried and other sutures, perhaps a drainage-tube introduced, and the wound is dressed in the usual manner.

* *Annals of Surgery*, 1895.

† *Bulletin of Johns Hopkins Hosp.*, July and August, 1892.

The Remarks.—Proximal ligation of the main vessel leading to the aneurism should be practiced when other means of control are not feasible. The introduction from within the sac into the open mouths of vessels of such exploring agents as probes, sounds, etc., enables one to locate the vessels and the better secure them from without the sac, or within by circumscribing with a sharp knife their open mouths. Portions of the sac adherent to important contiguous structures ought not to be removed to the detriment of the tissues in question. The entire limb should be thoroughly cleaned in approved manner, and after the operation wrapped in cotton, elevated, and the circulation noted in order to avoid so far as possible the occurrence of gangrene.

Matas' Method of Radical Cure of Aneurism.*—This method of practice is adapted to aneurisms having distinct sacs and in which the proximal end of the vessel constituting the aneurism can be temporarily controlled. Aneurisms of the large vessels of the extremities, whether of idiopathic or traumatic nature, afford a suitable field of effort in this regard.

The Operation (Fusiform Aneurism).—Elevate the limb and apply Esmarch's bandage or other suitable agent so as to arrest the circulation in the tumor; expose and open from end to end through a free incision in its long axis the aneurismal sac; retract fully the divided borders of the sac; evacuate the contents, exposing the interior to view; examine carefully the interior for collateral openings, closing those that bleed by pressure until all are securely shut by sewing; scrub gently and thoroughly with gauze wet with saline solution the interior of the sac, removing laminated

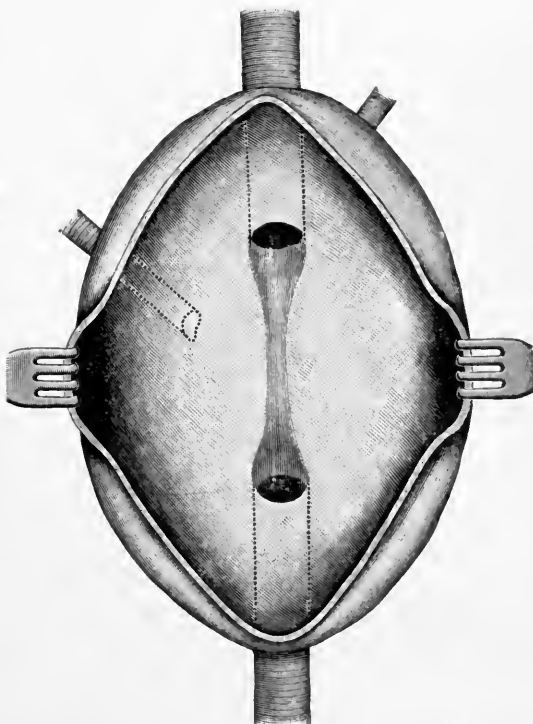


Fig. 235.—The interior of a fusiform aneurismal sac, showing openings and groove of main vessel and opening of collateral branch.

blood and stimulating the surface to quicker plastic action, (Fig. 235), close with a suitable curved needle armed with chromicized catgut by continuous or interrupted sutures carried, as indicated (Fig. 236), through the borders

* Transactions of American Surgical Association, 1902.

of the two main openings and those of the corresponding intervening wall of the sac; remove all agents of constriction and permit restored circulation to

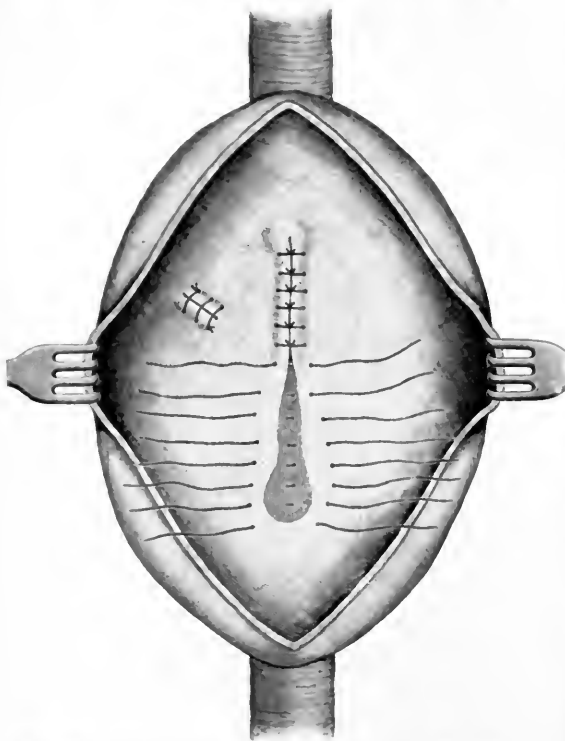


FIG. 236.—The fusiform aneurism. The first row of sutures firmly closing the orifices by fine chromicized catgut or silk.

test the security of the sewing; close bleeding points by additional sutures if needed, and introduce if practicable a second row of sutures (Fig. 237), thus lessening the size of the cavity and burying the first row; insert two or more chromicized catgut sutures into each side of the floor of the sac, then pass their free ends through the infolds of the sac (Fig. 238), thence through the skin to the external surface (Fig. 239); unite the free borders of the

skin with sutures carried so as to secure the line of union to the immediate underlying structures; tie firmly in place over gauze pads the transfixion sutures, thus completely obliterating the sac (Fig. 247).

In the Sacciform Aneurism (Fig. 240) the single opening is closed by sewing (Fig. 241), as in the preceding illustration (Fig. 242), but without encroaching materially on the diameter of the lumen of the main artery.

The Operation.—Expose, open and treat the aneurismal sac as in the operation for cure of fusi-

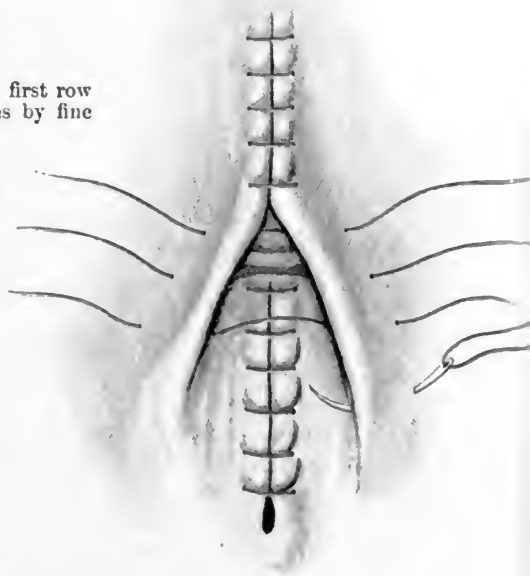


FIG. 237.—The fusiform aneurism. The second row of sutures. These may be the interrupted or continued. If floor be rigid the second row may be omitted.

form aneurism (Fig. 243); close by interrupted or continuous sutures, passed as indicated in illustrations, and without or with the introduction of the catheter (Figs. 243, 244), the openings of the main artery (Fig. 245); practice the remaining steps of the operation as in the preceding one, causing the outline of the transverse section to conform with that of Fig. 246).

The Remarks.—This method of practice does not interfere with the structures contiguous to the sac, as in extirpation. The wound is of minimum size and with circumscribed boundaries. Superfluous sac-wall should be excised. Since the sac is nourished by perivascular structures, as little separation of it as possible should take place. Various agents for control of hæmorrhage can be utilized when the Esmarch bandage is not suitable for the purpose. Kangaroo tendon or

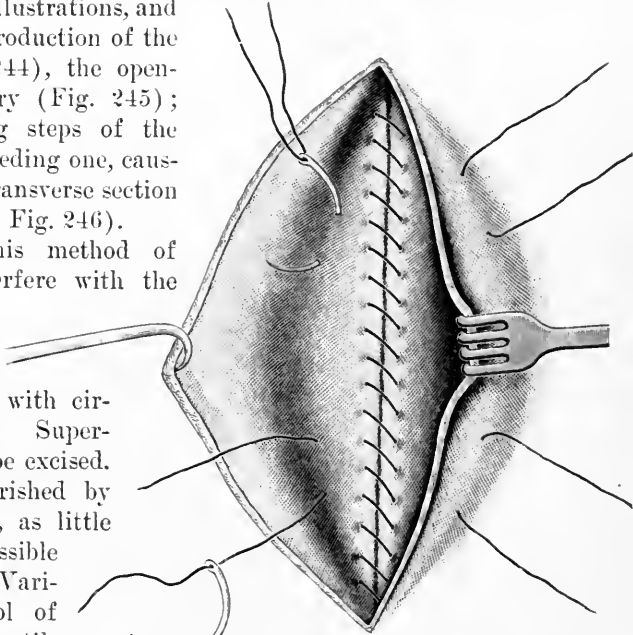


FIG. 238.—The fusiform aneurism.

The second row of sutures (continuous) introduced: the final obliterating sutures passed at either side. On the left, transfixion of floor is made. On the right, ends of similar sutures passed through integuments.

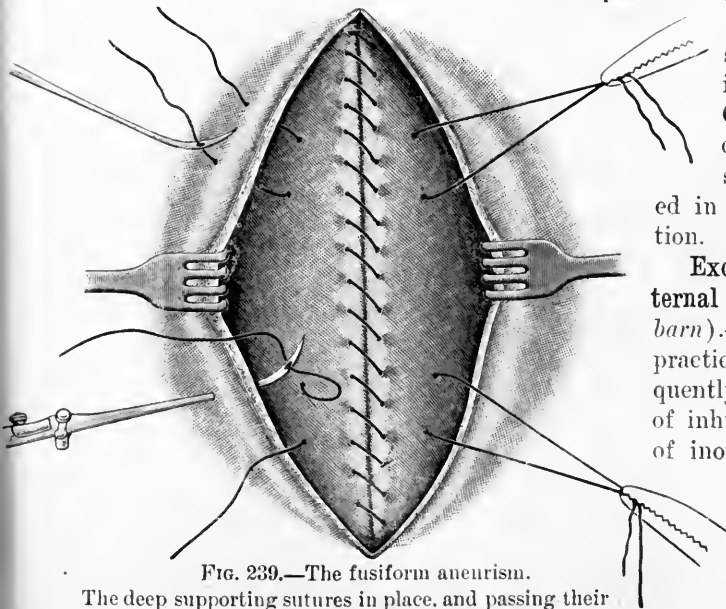


FIG. 239.—The fusiform aneurism.

The deep supporting sutures in place, and passing their ends, through skin and aneurismal wall.

silk may be used instead of catgut. Carefully recorded experience should be consulted in advance of operation.

Excision of the External Carotid (*Dawbarn*).—This measure is practiced not infrequently for the purpose of inhibiting the growth of inoperable malignant and other tumors nourished by the external carotid and its branches.

The Operation.—Raise the patient's shoulders, extend the head and turn the face to the opposite side; make a curved incision from near the level of the tip of the ear downward closely behind the angle of the jaw,

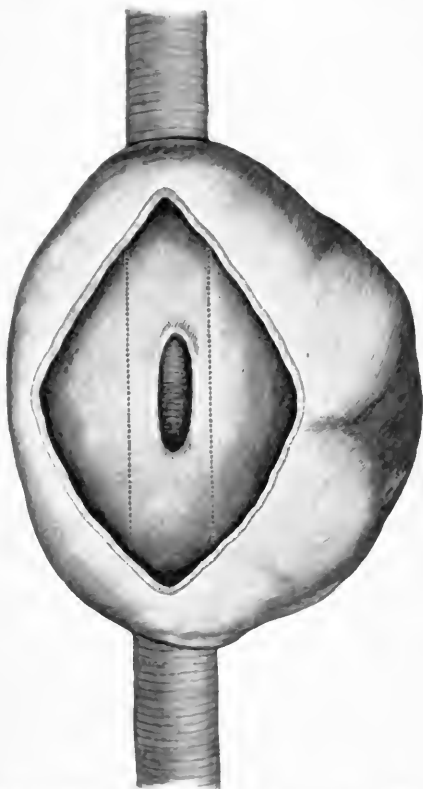


FIG. 240.—The sacciform aneurysm, its main orifice and the dotted outline of the main vessel.

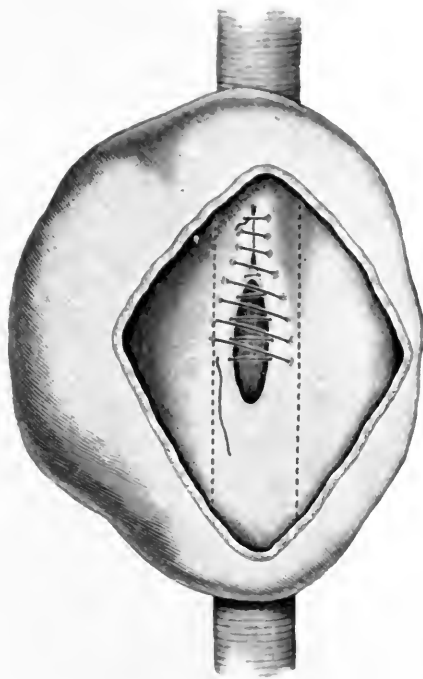


FIG. 241.—The sacciform aneurysm. The closure of main orifice by continuous sutures without special removing of lumen.

forward to the greater cornua of the hyoid bone; expose and identify the superior thyroid branch by its course and its relations to the bifurcation of the common carotid, passing a ligature around the external carotid and leaving it untied; trace the external carotid upward, or the common and internal in the absence of the former, tying twice each branch in the order of exposure, dividing each between the ligatures; expose the terminal branches as high above the digastric muscle as practicable, carrying a ligature around each; tie the ligature already passed around the external carotid, also those of the terminal branches; sever the vessels ligatured and remove the intervening trunk.

The Comments.—The removal quite simultaneously of both external carotids much the better meets the indications. The absence of a well-defined external carotid may give rise to confusion. The primary branches, especially of the lingual, may be tied. Careful asepsis is essential in the

entire measure. Dr. Dawbarn sometimes uses a blunt probe instead of an aneurism-needle to secure the vessels; oftener, however, he places the ligatures by means of his curved artery forceps. The occipital, superior thyroid and facial arise sometimes from the internal carotid and common carotid, respectively.

The Results.—There seems to be no doubt that this method of procedure delays and, possibly in rare instances, arrests the growth of inoperable tumors which might otherwise cause prompt death. Also it reduces to a minimum the loss of blood in operable cases, and no doubt inhibits the local return of the disease in such instances. Dawbarn reports a primary operative fatality of 2 in 48 instances.

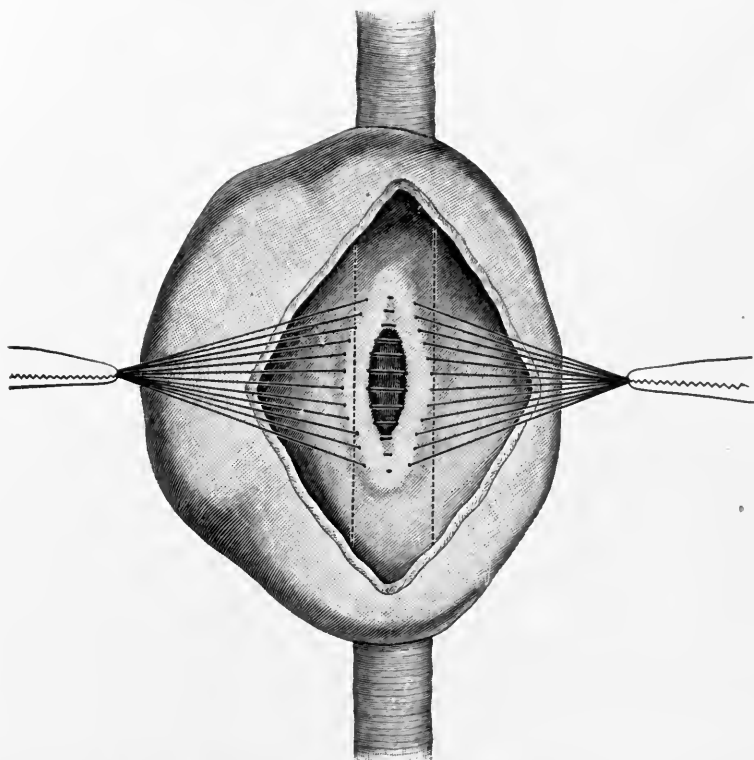


FIG. 242.—The sacciform aneurism. Closure of the main orifice by interrupted sutures without special removing of lumen.

Arteriorrhaphy, or suture of an artery for repair or injury to the vessel, is advisable, especially when closure of the vessel by ligature, as is common in such cases, exposes the patient to increased danger. If the suturing be carefully practiced, the patient is given the advantages of increased opportunity without additional danger. The wounds vary in direction and extent, and are the outcome of common and operative traumatism.

The Operation.—Under strict aseptic care and complete control of the circulation expose the vessel at the seat of injury, cautiously preserving the

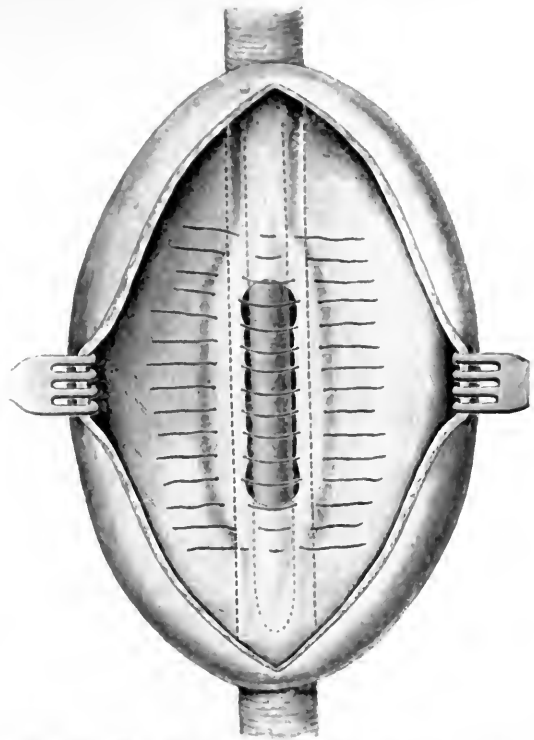
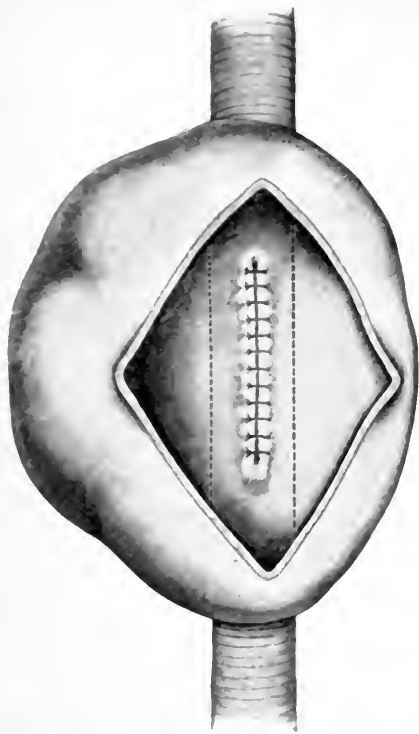


FIG. 243.—The sacciform aneurism. Obliteration of orifice completed, lumen intact. Operation completed as in fusiform aneurism.

FIG. 244.—The sacciform aneurism, with catheter introduced to maintain caliber of lumen; sutures placed over catheter.

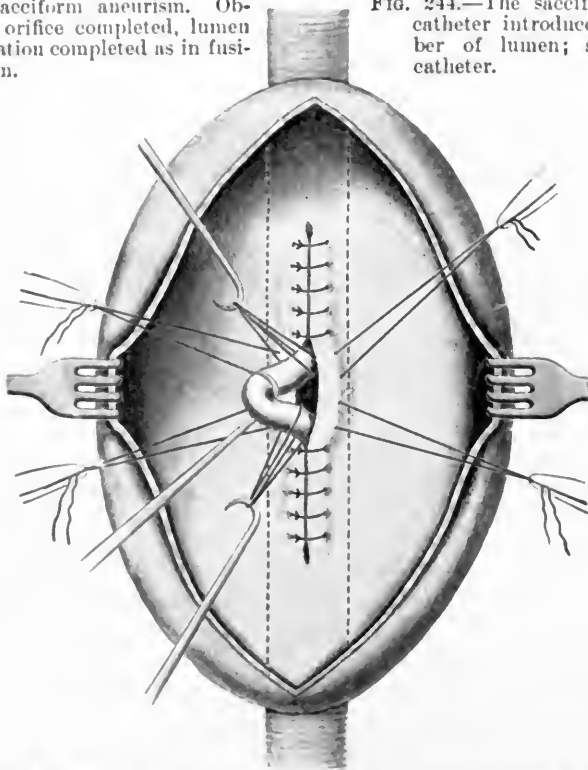


FIG. 245.—The sacciform aneurism. The removal of catheter before final closure of the main channel.

integrity of its sheath. In longitudinal, oblique and in transverse injuries not exceeding more than half its circumference transfix in turn, about a

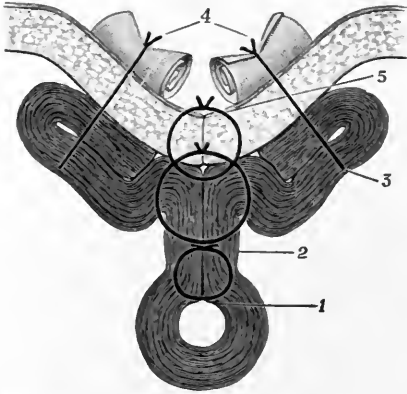


FIG. 246.—The sacciform aneurism. Transverse section. 1. The line of sutures closing the orifice over catheter—new lumen (Fig. 244); 2. The second row of sutures reducing size of sac (Figs. 237 and 238); 3. The supporting obliterative sutures that bring in contact the floor and roof of aneurismal sac (Figs. 238 and 239); 4. Gauze pads under obliterative sutures; 5. Superficial integumentary sutures.

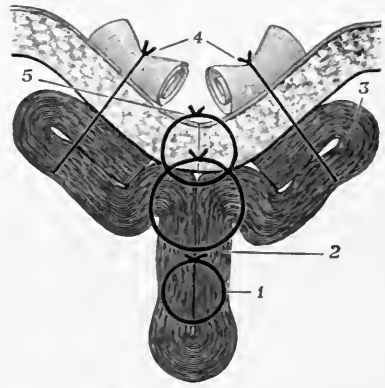


FIG. 247.—The fusiform aneurism. Transverse section. 1. First row of obliterating sutures (Fig. 236); 2. Second row covering the first (Fig. 237); 3. Inverted sac walls; 4. Supporting obliterative sutures (Figs. 238 and 239); 5. Superficial integumentary sutures.

line from the edge, down to the interna, as in phleborrhaphy (Fig. 250), the apposing borders at opposite points, interruptedly about a line apart, with a fine curved needle armed with fine silk or chromicized catgut; tie each suture, carefully avoiding inversion of the borders of the wound, suture separately the sheath of the artery, and close and dress the remaining wound in the usual manner. When the wound exceeds more than half of the circumference of the vessel, sever it completely and repair according to one of the following methods:

Murphy's Method (Fig. 248).—Arm each end of three fine silk or chromicized catgut sutures with a cambric needle; introduce each suture at an equal distance from the other through the outer and middle coats, near to the proximal end of the vessel; pass the needles from within outward through the coats at the distal end at points corresponding to those of the proximal, about a third of an inch from the end of the vessel; slit the distal end briefly, draw the proximal end into it with the sutures and tie in place by uniting each end with its fellow when the invagination is completed; unite the border of the exposed end to the contiguous wall, also close the slit at the distal extremity (Fig. 249). As will be noted hereafter, the

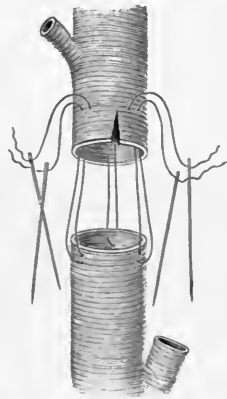


FIG. 248.—Arteriorrhaphy Murphy's method. Sutures placed, ready for closing.

methods of repair of Murphy, of Salomon and of Bangle in complete division of an artery are respectively similar to those of Robson and Winslow, of Schaffe and Cushing, and of Poggi, uretero-ureteral anastomosis (page 854, Vol. II). In fact, Van Hook's plan in the latter has met with success in the former operation.



FIG. 249.—Arteriorrhaphy. Murphy's method. Union completed.

Veins may be closed (phleborrhaphy), the same as arteries when wounded, by longitudinal or oblique incisions (Fig. 250). If a vein be nicked the opening is closed by ligature, as illustrated (Fig. 250) and expressed in the text (page 215). The continuous suture is often employed in sewing wounds in veins.

Ligature of the middle meningeal artery is considered in connection with injuries of the skull, as then it is often required (page 237).

The Remarks.—The portion of artery resected ought not to exceed half an inch in length, except at flexures of joints where greater relaxation can be secured; traction loops, temporary ligatures, or forceps guarded by rubber tubing, may be employed to control the circulation. The rat-tooth forceps used in eye surgery; a fine cambric needle with elongated eye; fine twisted silk the size of the needle and not too firmly tied, are desiderata of importance in these measures.

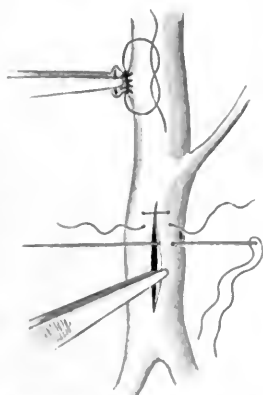


FIG. 250.—Phleborrhaphy, seen below. Ligaturing stitch, seen above.

CHAPTER V.

OPERATIONS ON VEINS, CAPILLARIES, ETC.

VEINS and capillaries often require vigorous treatment, not only for the purpose of arresting hæmorrhage, but also to remedy the troublesome and distressing symptoms and the unsightly deformities that arise from unusual development incident to obstructed circulation and telangiectatic growth. Veins are ligatured principally to arrest hæmorrhage and cure phlebectasy.

The Ligature of Veins.—Veins, like arteries, may be ligatured in their continuity or at their divided extremities. Large venous branches, when divided in the course of an operation, should be tied, otherwise they may give rise to an objectionable amount of bleeding, which will hinder the operator, interfere with the rapidity of union, and possibly require reopening of the wound to arrest hæmorrhage. If a large vein—as the internal jugular, the femoral, etc.—be nicked during an operation, a ligature may be thrown around it, above and below the opening, or the nicked portion only may be sewed or tied. Tying the opening exposes the patient to greater danger of (Fig. 250) hæmorrhage than does sewing, especially if the catgut ligature be applied. A fine, firm silk ligature is better for this purpose, as it can be more securely tied. The practice of sewing the divided borders with fine catgut, is highly extolled by many writers. The application to a cut in a vein of a ligature is followed quite surely by thrombosis and closure of the vessel. The repair by suture in the manner of intestinal sewing is not often followed by a similar result. If it be determined to tie the vessel, it should be done above and below the wound, otherwise troublesome hæmorrhage may follow. In the instance of complete ligature of the femoral vein, it is advised that the femoral artery be not ligatured at the same time.

The Results.—In fifty-one cases of ligature of the internal jugular, six died of secondary hæmorrhage, the result of infection. With complete asepsis but little danger attends the procedure.

According to Braunn, death from secondary hæmorrhage followed lateral ligature of the internal jugular in three of twelve cases. In one case each of the external jugular and subclavian veins and in five of the axillary all recovered. In eight of lateral ligature of the femoral, six died—five caused by pyæmia. Simultaneous ligature of the femoral vessels in twenty-four cases was followed by gangrene of the limb in fourteen. In twenty-five instances of ligature of the vein alone gangrene did not occur.

Operations for Varicose Veins.—When the veins of the lower extremities and elsewhere become too much distended to be amenable to palliative measures, it is often advisable to resort to operative interference, with the view of

occluding the distended canals. Injection, acupressure, ligaturing, and excision are the common means employed for this purpose.

Injection.—The vein is compressed at points an inch or less above and below the seat of operation with the fingers, or by small pads confined in position with adhesive plaster. The latter plan is the better. Before the injection is introduced the selected portion of the vein is emptied by divergent pressure of the fingers upon the vessel, after which it is allowed to fill again. The emptied portion is allowed to fill from below—not from a collateral branch—and then the operation is completed by injecting slowly into the isolated portion twenty or thirty drops of a twenty-per-cent solution of subsulphate of iron and water. Almost immediately the contents of the vessel become coagulated, when the limiting pressure can be removed. The patient should be kept quiet for a few days, and any tendency to undue inflammation combated. It is wise to remember that portions of the vein having collateral branches should not be injected for fear of embolism. This method is rarely employed.

The Results.—Of the one hundred and three cases some time since reported, seventy-nine were cured, one died, and of the remainder, sixteen were failures.

Acupressure.—Acupressure is applied here in substantially the same manner as for arresting the circulation of arterial trunks (page 75). Thoroughly purified needles or pins, which may or may not have been constructed for the purpose, are carried beneath the vein at intervals of an inch or so, and caused to compress the superimposed tissues by means of carbolized silk or cotton yarn wound over their protruding ends. The pins are removed on the sixth or seventh day, depending on the degree of ulceration produced. Caution should be observed that the pins be not passed through instead of beneath the vein, or a serious phlebitis may follow.

Subcutaneous Ligaturing.—Subcutaneous ligaturing is employed less now than formerly. It is best applied to veins of the lower extremities, and the use should be supplemented with vigorous antiseptic measures. The location of the veins can be indicated by marking the integument over them with iodine, while they are fully distended by upright posture, or by obstruction of the return circulation with the patient in the recumbent position. The latter method is the better, because it brings the vessels more directly under command and reduces the liability of their puncture or the involvement of contiguous important structures to a minimum.

The Operation.—Pass a common straight or curved sterilized needle, armed with a catgut ligature, beneath the vein, through the skin, causing it to emerge at the opposite side of the vessel, then re-enter the needle at the point of emergence, pass it in front of the vein, after which the direction is changed so as to carry it in front of the vessel and out at the point of entrance. The ligature is tied, cut short, and the wound treated antiseptically. Often these ligatures are applied at intervals of an inch or so the entire length of the dilated vessel. The limb is then surrounded with antiseptic dressing, elevated somewhat, and the patient kept in bed for a week or ten days, and longer if indications demand it. If the blood in the inter-

vening spaces becomes necrosed, giving rise to fluctuation, it should be evacuated. If ligature abscesses appear, the offending ligatures should be removed and the suppurating foci kept well cleansed. A special straight or curved unthreaded needle, with an eye at the end provided with a handle, is admirably fitted for this purpose (Fig. 251). The needle is threaded after



Fig. 251.—Keyes' needle for treatment of varicocele.

the passage, behind and in front of the vessel respectively, and the ligature placed by its withdrawal in each instance; thus a prompter and better application of the ligature is secured than by the former implement.

The Precautions.—In the subcutaneous ligaturing of veins, as the long and short saphenous, the accompanying nerves may be accidentally included in the ligature. However, if the vein be drawn forward (Fig. 200, *e, f*) away from the nerve and the needle passed as closely as possible to the vessel, but little trouble will result from their association. In many instances it is difficult to properly outline the dilated vessels, owing to their depth and tortuous course, and in such cases the passage of the needle is followed by brisk hæmorrhage, notwithstanding the great caution exercised in the insertion. The lack of surgical precision in the application of the ligature, the frequency of stitch-hole abscess and increased temperature following it, are strong objections to the method, as they suggest the possibility of phlebitis and thrombotic infection—complications that are reported to have ensued and been followed by death from pyæmia in rare instances.

The Results.—As yet there is no good reason known to us to regard this method as less annoying or more effective than treatment by excision.

Incision and ligaturing (excision) is a wise plan of treatment in all instances, more especially in those cases where the veins are tortuous or ill defined. The dilated vessels are exposed by incision along the course of greatest tortuosity, tied above and below, excised, and the wound closed in the usual manner. Many authorities advise excision as preferable to any other method of treatment. The writer has simultaneously tested on several occasions, as far as possible, the comparative worth of this and the preceding method on the same patient. The recovery was prompter, the pain and annoyance less in the limb subjected to the latter method in every instance. The final result can not yet be estimated.

The ligature of the internal saphenous vein (Trendelenburg), near to the saphenous opening, is advised for the cure of varices involving the branches of this vessel. Ligaturing the vessel relieves it of the pressure of the column of blood below the point of tying, and thereby permits the restoration of vascular tone. Four or five inches of the vein may be removed, carefully tying the collateral branches. If this method fail, extirpation or multiple ligature of the veins of the leg may be done. As in all operations on veins, strict asepsis should be practiced. The wound is closed, the extremity wrapped in cotton, snugly bandaged, and immobilized for ten days. The fact, as reported, that pad pressure on the saphenous vein (Landerer)

cures the discomfort in ninety per cent of the cases emphasizes the importance of ligaturing the vessel. In the experience of the author this method is unreliable in those cases with free communication between the superficial varices and deeper venous circulation, and for apparent reasons. *Ferguson* ties the saphenous vein at two points near the femoral and cuts out a section, then makes a semilunar incision through the skin, from the lower part of the thigh along the inner side of the leg, forming a flap which overlies the varicosities. The incision is deepened, the vessels severed and tied, the flap turned over, the normal and abnormal veins and their branches dissected away, the flap restored, borders united, the limb dressed and confined as before.

Schede makes a circular incision around the leg down to the veins, which he exposes for a distance above and below by means of circular flaps. The vessels are tied between two ligatures, the portions excised, the flaps replaced, borders united, and limb dressed and confined as usual. The long and short saphenous nerves should not be divided, if possible to avoid them.

Venesection.—Although venesection can hardly be classed as an operation of much moment, in a surgical sense, yet the infrequency of its employment at the present time is apt to render a knowledge of the details connected therewith somewhat uncertain in the minds of a majority of the practitioners of the present generation. The veins selected for the procedure are the internal saphenous at the ankle,

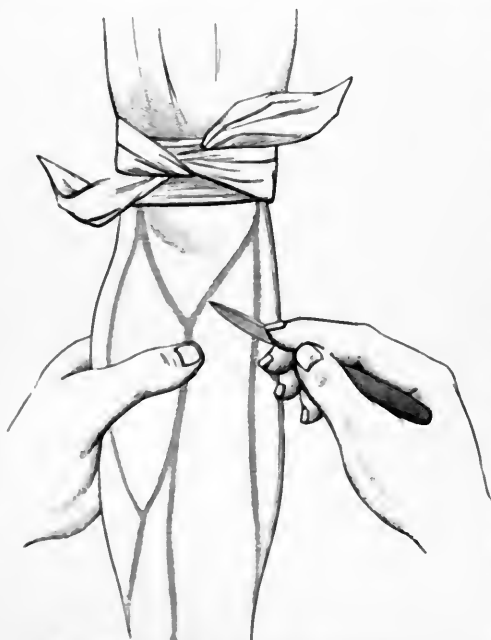

FIG. 252.—Opening the vein with scalpel.

the median basilic, or median cephalic at the bend of the elbow, and the external jugular vein. *The instruments required* for the purpose is the ordinary thumb lancet, or a curved or straight sharp-pointed bistoury. The first, however, possesses the greatest number of traditional virtues. If the region of the elbow be selected, the median cephalic vein is preferred, on account of its greater distance from the brachial artery and the posterior relation to cutaneous nerves. The arm should be constricted by a bandage drawn sufficiently tight to obstruct venous return without interfering with arterial circulation; this will cause the veins to appear prominently distended, unless the patient be very

fleshy, in which case the sense of touch must be relied on to indicate the exact situation of the vessel. The vein should be well defined by the finger, and held in position by the thumb or finger placed just below the point of

incision. After thorough cleansing, the incision is made obliquely to the transverse diameter of the vein, and of sufficient depth to freely open the vessel without severing it (Fig. 252). The flow of blood may be increased by causing the patient to grasp firmly a stick or broom handle; it may be impeded by the interposition of the subcutaneous fat, which should be pushed aside. The amount of blood taken will be regulated by the strength of the patient, whether he be standing or lying, and by the demands for depletion. If standing or sitting, the effects will be sooner felt than if in a recumbent posture. Usually, however, from half a pint to a pint will suffice. The flow is arrested by removing the bandage above and applying the finger to the bleeding point, after which a small aseptic compress is placed over the incision, and confined in position by adhesive plaster so arranged as not to impede the venous return.

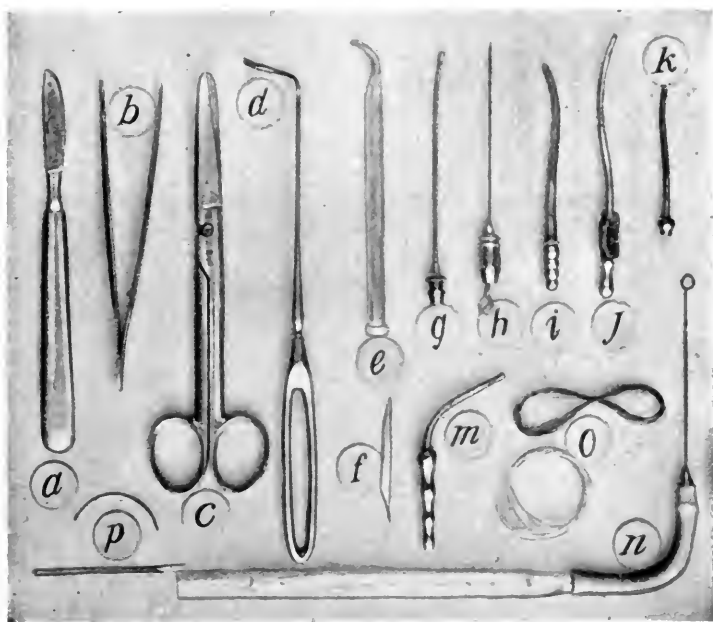


FIG. 253.—Instruments employed in the operation of infusion.

- a. Scalpel. b. Thumb forceps. c. Scissors. d. Aneurysm needle. e. Ordinary dropper with curved point, extemporaneous cannula. f. Toothpick for same purpose. g. Cooper's cannula. h. Kelly's needle. i. Lockett's cannula. j. Fowler's cannula. m. Harris's cannula. n. Fowler's thermometer for cannula. o. Catgut and silk wormgut. p. Needles.

If the external jugular vein be selected, the compress is placed just above the clavicle, and confined in position by a bandage carried under the opposite axilla. The pressure is then applied to the vessel above the point of proposed incision, and the vessel is opened at a right angle with the fibers of the platysma myoides muscle. The finger must always be placed on the incision before the compress is removed, in order to prevent the entrance of air into the circulation.

Transfusion.—Transfusion is a means employed to overcome the exhaustion caused by disease and shock from the loss of blood. In the latter, however, it is of the greatest practical utility. Blood, defibrinated blood, and saline solutions (infusion) are employed to meet the demands. The employment of saline solutions has, however, superseded entirely the use of blood.

The fluid may be introduced into *an artery* or *a vein*, either of which may be chosen at a part distant from the wound, causing the need for infusion, or at the wound itself, in the latter instance possibly utilizing for the purpose a vessel already exposed. The former course is the better, and commonly the bend of the elbow is well adapted for the requirement. *The fluid* especially employed is composed of six parts of pure table salt to one thousand of boiled filtered water, practically a heaped teaspoonful of the former to a quart of the latter. Special fluids are commended by some because of their closer approach to the composition of the blood serum. However, these special fluids appear to be of insufficient practical importance to militate against the use of the simpler fluids on all occasions. Various apparatus are employed for the purpose of infusion. Some are simple, others of a complicated nature. The simpler and the handier the means, the better for the prompt and full measure of benefit.



FIG. 254.—Apparatus for infusion.

Ordinary fountain syringe. Kelly's apparatus. Graduated glass reservoir and infusion tube. Fowler's apparatus with thermometer attachment.

The Operation of Infusion (Venous).—Cleanse the field of operation thoroughly; constrict the arm three or four inches above the elbow joint (Fig. 252) with a rubber cord or a bandage; choose the most prominent vein, usually the median basilic (Fig. 252); make an incision down upon the vein in the long axis, of proper length to freely expose it; separate the vessel from the contiguous tissues with a probe, a grooved director, or an aneurism needle; ligature the vein at the lower aspect of the wound; pass a second ligature an inch or so above the preceding one, leaving it untied; divide the vein between the ligatures, transversely upward, through half of

the circumference, with scissors (Fig. 255); insert the end of the cannula (the solution slowly escaping from it) upward into the vein and tie it in place with the second ligature, making a bow-knot; remove the constriction above, and introduce the fluid slowly at the proper temperature (118° F. to 120° F.), carefully watching the effect on the vein above the incision; divide the vessel between the

The Precautions.—Certain that salt is introduced, will cause death. Immerse before using, to maintain the

ligatures after completion, and sewing, and dress it aseptically. cure complete asepsis. Be certain the infusion of water only the apparatus in hot water before proper temperature of the fluid

while entering the vessel. Be sure that the proper temperature is maintained by

constant scrutiny. Insert the tube while fluid is escaping, to avoid the introduction of air. The observance of these precautions may obviate the occurrence of chills at the time of operation. A blunt, not a sharp cannula should be introduced, for the latter may puncture the vessel and otherwise hinder prompt action. Avoid leaky, defective apparatus. The amount infused should depend on the case and the effect on the patient, from a pint to a quart, introduced during half to three quarters of an hour, ceasing at once with unfavorable signs. Embarrassment of the action of the heart and œdema of the lungs or brain may follow a too free introduction of the fluid. Filtration can be rapidly done by passing the fluid through sterilized absorbent cotton surrounded with sterile gauze.

Injection of Saline Solutions.—The introduction into the veins or the arteries of various saline solutions, the chief ingredients of which are common salt and carbonate of soda, is highly recommended.

Szumann recommended the following:

℞ Water, sterilized..... 32 ounces;
Common salt..... 1½ drachm;
Carbonate of soda..... 15 grains.
M. Heat to 110° or 112° F.

Dawbarn's prompt method of practicing saline transfusion by "needling" may be serviceable. The saline solution is quickly prepared by adding a heaped teaspoonful of table salt to a quart of warm boiled water. The

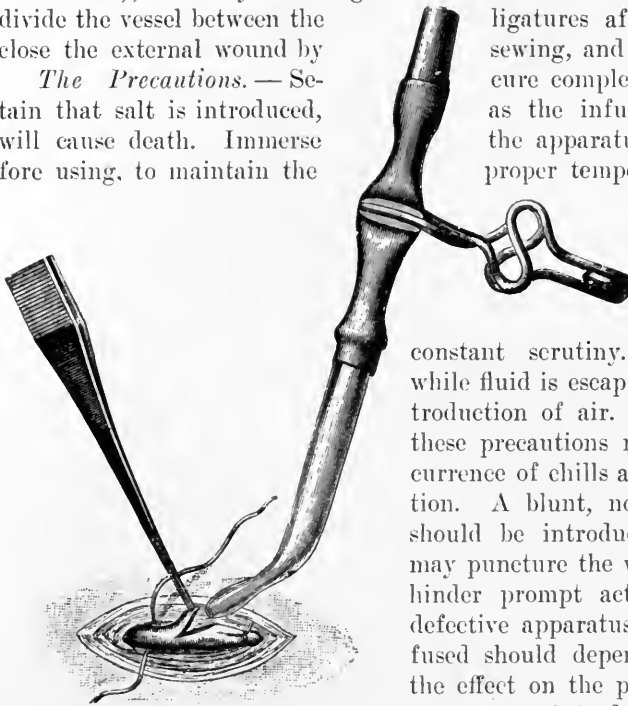


FIG. 255.

Introducing the tube in infusion.

method requires "an ordinary Davidson's syringe, an ordinary soft-rubber catheter, or a small rubber drainage tube and an ordinary hypodermic needle—large size preferred, though this is not essential. After thorough aseptic preparation, the needle is pushed slowly into the radial, posterior tibial, or femoral artery until arterial blood appears at the outer extremity, the catheter is then slipped

over the base of the needle and tied, the nozzle of the syringe is inserted into the eye of the cath-

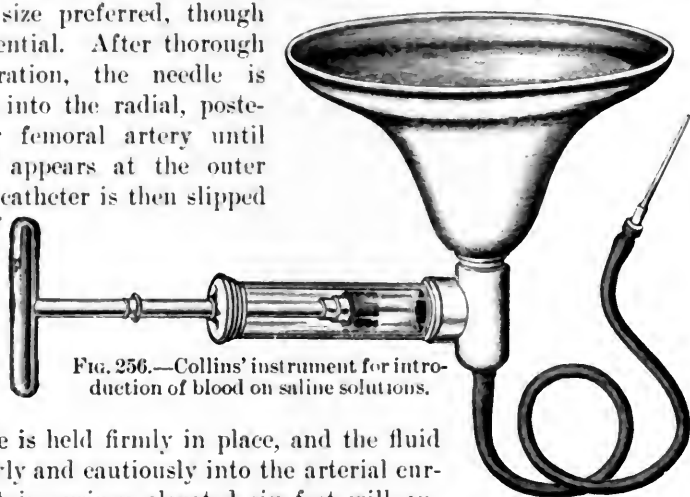


FIG. 256.—Collins' instrument for introduction of blood on saline solutions.

eter, the needle is held firmly in place, and the fluid is pumped slowly and cautiously into the arterial current. A fountain syringe elevated six feet will answer the purpose equally well. A pint of this fluid can be thus introduced within half an hour. If the shock from loss of blood be profound, it is advised that the fluid be as hot as the hand can well bear (118° F.). In any event the temperature of the fluid should be not less than 110° F.

The Fallacies.—The needle may not enter the vessel, or it may be unconsciously withdrawn from it. Under either of these conditions the injected fluid will cause distention of the connective tissues adjacent to the point of puncture. If the salt be omitted, the effect of the water on the blood corpuscles will quickly kill the patient. If minute foreign bodies be present in the fluid, the needle may become obstructed; therefore, the fluid should be strained before it is used. The introduction of air into the circulation will not happen with the use of a fountain syringe, but care should be taken or air will be introduced with the use of Davidson's, especially if the valves be defective; then the instrument should be immersed in a saline solution while in operation. The saline fluid will become cooled before it is entirely used, unless the vessel containing it be placed in another filled with fluid kept still hotter than this by frequent additions of boiling water.

Subcutaneous injection of saline fluid (Hypodermoclysis) is done independently of the preceding method of use, and supplemental to it. A pint or two in divided portions can be injected at different situations into the connective tissue of the thighs or ilio-lumbar region beneath the female breasts (Kelly), aided by rubbing to disperse the fluid, for the purpose of relieving shock. If time will permit, only sterilized fluids should be employed and antiseptic methods practiced in other respects.

Copious enemata (Enteroclysis) of hot saline fluid, carried high up into the large intestine by means of a tube, are now employed frequently in cases of shock from loss of blood of a lesser degree than that calling for its injection into the tissues and vessels. Instrumental outfits for the employment

of enteroclysis to meet the various indications referable to disease of the kidneys and other morbid conditions now find ready and serviceable use, and can be procured at the shops for the sale of instrumental supplies.

Arterial infusion has been advocated on the basis that it conveys the fluid more equably to the heart, and therefore with less danger of exciting undue disturbance of the circulation. The admission of a small amount of air does no great harm, and the danger of phlebitis is avoided. The vessel selected should be the radial at the wrist or the posterior tibial at the ankle, either one of which is exposed, and three ligatures are placed around it at a little distance apart; the distal one is tied, and the proximal one tightened sufficiently to interrupt the circulation in the vessel. The vessel is now opened and the tube inserted and tied in position by the third or middle ligature, then the proximal one is loosened and the fluid injected into the circulation. It is better to inject the fluid against than with the natural flow of the blood current, to avoid over-distention of the capillaries. As soon as the injection of the fluid is completed the proximal ligature is tied, and the intervening portion of the vessel removed along with the tube. Arterial infusion is practiced much less often than venous. Permanent dilatation of the walls of the artery, and even sloughing of the soft parts, have followed the practice. Kelly no longer employs it in females, but advises submammary infusion instead.

Operations on the Capillaries.—The capillary system of vessels, like the venous, may undergo dilatation of sufficient degree to create distinct but slowly developing and painless deformities and tumors. The morbid process is limited usually entirely to the capillaries of the integument; however, the deeper and larger vessels are not infrequently involved also, not only at the beginning, but during the development of the growth. These growths vary in situation, size, shape, and color. The simplest variety is known as the “mother’s mark,” “birthmark,” etc.

A *birthmark* can be treated by pressure, caustics, hot needles, vaccination, and galvano-cautery, depending upon its size and situation and the fancy of the operator. It is not well to interfere at all in early life except by simple means, unless the growth increases rapidly in size. The majority of these growths will disappear of themselves before their presence becomes a source of annoyance or regret to the possessor. There are, however, several means which will often hasten their departure—as the use of simple compresses, repeated application of collodion, or vaccination if the birthmark be located suitably for the act. The following method, introduced by *Dr. Squire*, which seemed likely at one time to meet the desired end in the great majority of cases, can be employed:

The “mark” is frozen with an ether spray, and numerous superficial parallel incisions are made about one sixteenth of an inch apart, and the whole is covered with blotting paper, which is pressed upon with sufficient force to prevent any gaping of the cuts or hæmorrhage; after fifteen or twenty minutes the paper is thoroughly wet with water and removed. Sometimes a thin underlying clot of blood will be found; this must be washed away carefully with water aided by a soft brush, and the part dressed asep-

tically. When it is necessary to repeat the operation the incisions should be made at right angles to the previous ones. In simple cases and with proper care a perfect cure is secured by this method, without scarring.

The injection of ergot, the solution of subsulphate of iron, and undiluted carbolic acid, etc., has been recommended. They are, however, uncertain in their action, and are liable to be followed by inflammation, ulceration, and sometimes by embolism. The solutions can be injected by the ordinary hypodermic syringe, three or four drops at a time, in various portions of the growth. This method can not be commended. The use of red heat around the base and over the surface of the growth by means of the Paquelin cautery is an admirable method, provided the growth involves the skin alone or only the capillaries in the tissue immediately beneath it. If vigorously applied it is usually followed by more or less disfigurement, depending, of course, upon the degree and extent of the cauterization.

*Needles heated to a marked degree of redness, either by electricity (see Fig. 109) or the ordinary means, are admirable agents of cure in pronounced cases. They are thrust into the vascular growths and allowed to remain until the tissues and fluids adjacent to them are cooked, after which they are carefully withdrawn and inserted as before at another part of the growth. The number of insertions is controlled by the size, vascularity, and situation of the abnormality. Usually five or six introductions will suffice, and these should be made at the border rather than at the center of the growth, the idea being to establish a cure by gradual encroachment from the border rather than by direct attack. *Electrolysis* often secures favorable results.*

The Comments.—Needles heated by electricity are the best agents of treatment. A needle should be introduced and removed slowly and cautiously, as a rapid introduction will bend and destroy it. A rapid removal will often cause unnecessary hæmorrhage on account of the adherence to the needle of the cooked tissues that environ the point of puncture. The patient should be kept quiet for a few days after the employment of galvanopuncture, and the seat of the operation should be treated antiseptically.

Subcutaneous Ligaturing.—If the nævus be of large size, persistent, of a dark color, and markedly elevated, it may be suitably treated by the employment of subcutaneous ligature. Subcutaneous ligaturing may be performed in several ways, depending on the size and shape of the tumor and the fancy of the operator. Treatment by ligature is inferior to that by needles.

Fig. 257 represents a simple method. In this the needle, armed with a strong, well-carbolized silk or catgut ligature, is thrust beneath the integument at the base of the tumor and carried subcutaneously as far as possible around the base, and then passed out through the integument, to be again introduced at the point of exit and carried still farther around and pushed through as before, and so on until the needle is caused to emerge at the point of primary insertion. The ends of the ligature are then tied in a firm, hard knot.

Fig. 258 represents a double ligature carried through the base of the growth and divided; each portion of the ligature is then carried subcuta-

neously around half of the base and tied independently of the other part. This method of procedure is applicable to growths having large bases. Fig. 259 represents the application of the ligature to quarter sections of the

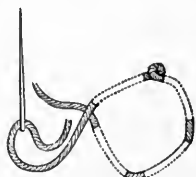


FIG. 257.
By a single ligature.

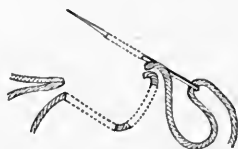


FIG. 258.
By a double ligature.

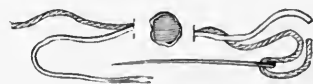


FIG. 259.
Ligation in quarter sections.

base. It is employed in still larger growths. Pass a double ligature through the center of the base, cut the loop near the middle, leaving one end of the divided thread in the eye of the needle; then, after threading the needle besides with the other end emerging at the opposite side which corresponds to that portion of the ligature which was liberated by the division of the loop (Fig. 260), pass it through the base at right angles to the primary course.

Before tightening the ligature the integument in the course of constriction should be deeply incised, not only for the purpose of avoiding the pain and ulceration incident to the pressure, but also to allow the proper adjustment of the constricting agents (Fig. 261). It will simplify the discriminating and tying of the extremities if one half the ligature be colored before the primary introduction. Fig. 262 represents the ligation of a growth with an elongated base. In this instance a double colored ligature is required, which is passed through the base from side to side, commencing and terminating just outside the extreme limits of the growth; if the white loops be now divided on one side and the black on the other, independent sets of ligatures will be formed, which should be firmly tied after the skin falling

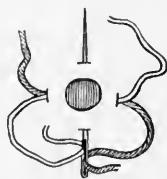


FIG. 260.
Quarter sections, second step.

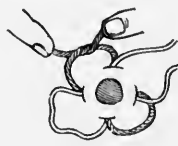

FIG. 261.
Tying ligature.

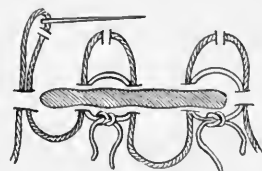


FIG. 262.
Ligation of elongated base.

within the grasp of each ligature *has been first incised*. The separation of the growth is hastened by the use of a rubber ligature applied in a similar manner. *The introduction* into the vascular growth of *threadlike setons* which are charged with a solution of subsulphate of iron from time to time, and drawn into the vascular structure with the view of causing coagulation of the fluid contents, is advised, and thus far the results of this method of treatment justify its further employment. It is open to the same objection as the introduction of constricting fluids by other means—the liability of infection from the presence of the opening in the integument for the passage of the threads.

Division and Ligature.—Cirsoid growth of the scalp can be successfully treated by making a free incision outside and nearly around it, down to the periosteum, leaving that portion of the growth that contains the largest vessel undisturbed to form a pedicle to nourish the flap. The flap is raised and all bleeding points are tied, after which it is kept separated from its former bed by antiseptic gauze until the surfaces granulate. The surfaces are then apposed and soon unite, thus destroying the growth without loss of substance. If the pulsations in the flap continue for four or five days, the dilated vessel entering it should be tied at a distance from the pedicle. The hæmorrhage attending the operation is controlled to a degree during the primary operation by a strong rubber band passed around the head, beneath which compresses corresponding to the course of the main vessels that supply the scalp are placed. The bleeding can also be arrested by direct pressure against the underlying bone; yet, notwithstanding these means, the loss of blood may be quite severe, and the operation should not be attempted if the patient be already exsanguinated or otherwise debilitated. Care should be taken to form a pedicle of sufficient width to nourish the flap; from half an inch to an inch, depending on the size of the flap, has, in the author's experience, been ample for the purpose. If the dressing be applied too firmly, the integrity of the flap will be endangered. The author has practiced this method in three cases of cirsoid change of the vessels of the scalp with prompt and entire success. In one instance—involvement of the occipital—the loss of blood during the operation was considerable.

Wyeth commends the injection into vascular growths of water varying from 190° F. to 212° F., with the idea of effecting a cure by causing coagulation of the contained blood and the albuminoids of the tissues. A syringe with a metallic barrel having an adjustable piston and needles of assorted sizes and lengths are required, together with a suitable receptacle for the fluid and a flame to keep the water at the boiling-point.

The Operation.—Render the operation field aseptic and administer an anæsthetic, insert the needle in *arterial* and *venous* growths, deeply into the tumor and discharge half a drachm to a drachm of the fluid into its various aspects, withdrawing the needle partially and changing its direction with each injection until the tumor is hardened; *inject in capillary* growths with a suitable needle, two to six drops at a temperature of 190° F. at various parts of the disfigurement, beginning at the borders.

The Remarks.—Apply pressure around the border of the growth during injection to lessen danger of emboli gaining the circulation. If the fluid be too hot or be injected in too large amounts, or too forcibly, local sloughing may follow. The injection should cease when slight blanching of the skin is noted. The amount injected should depend on the size of the growth; not more than four or five ounces should be employed at a treatment in extreme cases. Treatment may be repeated at intervals of a week or ten days.

The Results.—Several cases are reported with favorable outcomes. An instance of infection is noted. We are not disposed as yet to regard the measure as offering any advantage over galvano-cautery.

CHAPTER VI.

OPERATIONS ON THE NERVOUS SYSTEM.

THE brain, spinal cord, and the nerves arising from the cerebro-spinal axis, together with their coverings, are often the seat of important surgical procedures addressed to the relief of traumatic and pathological conditions that not infrequently affect these tissues. The delicate nature of the tissues and their important functions demand not only cautious manipulation, but also the strictest aseptic technique.

Chronic Hydrocephalus.—Tapping the ventricles for the purpose of removing the fluid incident to this disease is as yet the only operative procedure to which it is amenable. The tapping is done with a small trocar or aspirating needle, and often the needle is supplemented by the aspirator itself. In either instance the puncturing agent may be introduced through the anterior fontanelle close to its outer border to avoid the longitudinal sinus, and passed perpendicularly into the fluid, cautiously avoiding the cerebral lobes when possible (Fig. 263). If the fontanelle be closed the fluid is reached through a small trephine opening made at one of various situations. In the selection of a site for entry, the motor zone, the Sylvian fissure on account of the meningeal and middle cerebral arteries,

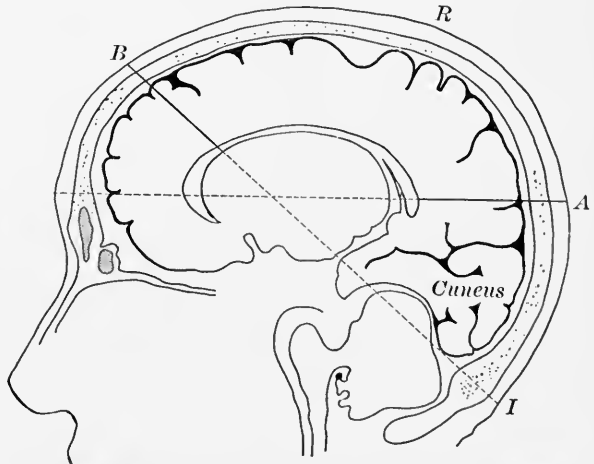


FIG. 263.—Antero-posterior section of the head half an inch from the median line. *R.* Fissure of Rolando. *I.* Inion. *A* and *B.* (Solid) lines of puncture, the dotted lines showing their imaginary continuation to the fixed points.

and the sense centers generally, should be avoided. Also the dangers of puncture of a vein lying on the surface of the brain should be anticipated by careful scrutiny of the part after opening the dura. *The situation usually chosen* for tapping is at a point one inch and a quarter above and the same distance behind the external auditory meatus, as drainage is thus facilitated by depend-

ent position (Keen). If the trephine be placed a half inch higher the lateral sinus is more surely avoided. Also a point an inch and a half above the meatus is advised (Fig. 292, *H*). The puncturing agent, after the dura has been incised sufficiently to admit it, is introduced and pushed toward the oppo-

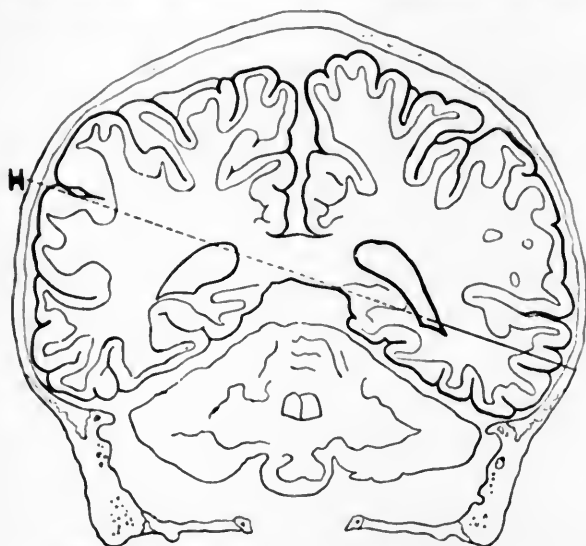

FIG. 264.—The direction of puncturing agent.

site side, the extremity being directed toward a point two inches and a half above the opposite external auditory meatus (Keen) until the fluid is reached (Fig. 264). In the normal brain the distance to the lateral ventricle is about two and a half inches. In the hydrocephalic, this distance is lessened proportionately to the degree of the fluid distention. In the latter method the point of the needle is directed away from the basal

ganglia; in the former it approaches the ganglia on account of the higher point selected for the introduction. The fluid should be evacuated slowly and the flow attended with moderate and equable pressure on the cranium by a skull-cap bandage. If unpleasant manifestations happen during the withdrawal of the fluid, the flow is promptly arrested for a time, after which it is permitted to begin again cautiously, or is stopped entirely, as circumstances demand. Often the removal of three or four ounces of fluid or less will cause feebleness of the pulse, contraction of the pupil, and evidences of approaching convulsion. The injection into the ventricles of a moderate amount of an ordinary saline solution at the temperature of the body is advisable if alarming evidences of cerebral disturbance arise at the time of operation. The almost certain reaccumulation of the fluid has prompted the employment of drainage and the injection into the distended ventricles of a weak solution of iodine, of Thiersch's or other suitable medicated fluids. *The drainage agents* are introduced at the time of the evacuation through the canula used for withdrawing the fluid. Either a small rubber tube, wicking, horsehair, or gauze can be utilized for this purpose. Horsehair is the best drainage agent; it is not too stiff and a portion of it can be withdrawn from time to time, thus meeting the demands of the case, and, moreover, it inhibits the escape of the fluid in a manner consistent with the greatest security to the patient. However, the employment of drainage favors additional risk of infection and meningitis without materially adding to the recovery of the patient. The completion of the operation

is followed promptly by closure of the wound, the application of aseptic dressings, and the establishment of gentle and uniform pressure on the skull. *Southerland* and *Cheyne* established drainage anteriorly between the lateral ventricles and the subdural space through an opening made near the anterior fontanelle by means of several straight pieces of catgut running from the ventricle downward and backward for two or three inches along the subdural space.* The cases best suited for tapping are those in which severe pressure attends recent simple meningitis, the later stages of the tubercular variety, hydrocephalus with inherited syphilis and chronic meningitis with much expansion of the head, and cases with loss of functions, such as vision, etc. (*Baltzie*). It has been proposed recently to drain the ventricles by tapping the membranes of the spinal cord (*vide* page 316).

The Results.—The rate of mortality from the operation alone is small indeed if aseptic care be taken. The percentage of cures is variously stated at five, ten, and even greater rates; the results are much influenced by the care taken in the selection of cases. Cures need hardly be expected to follow a single tapping; so-called cures are often transient.

Acute Hydrocephalus.—There is good reason to believe that the symptoms of cerebral compression incident to an acute collection of fluid in the subarachnoid and ventricular spaces dependent, usually, on tubercular meningitis, can at least be temporarily relieved by drainage. To effect this, a small trephine can be applied to the cranium as in the preceding instance and the ventricles evacuated in a similar manner. If the fluid be subarachnoid a free opening is made through the membranes of the brain and the fluid is encouraged to flow by the employment of aseptic textile fabrics placed in contact with the opening and covered by a generous pad of aseptic gauze. If centrally located, tapping of the ventricle may be advisable. Lumbar puncture is often followed by excellent results.

The Results.—As yet the data of the operation are insufficient to commend the procedure except as one calculated to offer temporary though perhaps trivial relief from the cerebral compression, thus gaining time which may contribute to final recovery.

Meningocele.—Meningocele is a protrusion of the meninges of the brain caused by an accumulation of hydrocephalic fluid in the ventricles, and occurs, therefore, before closure of the fontanelles. Meningocele occurs more frequently at the posterior fontanelle than elsewhere. When at the sinciput it is the most favorably located for treatment. The communication between the protrusion and the cranial contents may be large, quite small, or be closed entirely, and upon the dimensions of this passage much, indeed, depends, since the freer and shorter is the communication the greater are the dangers of operation, and consequently the more guarded should be the prognosis. The tumor should be protected from irritation at all times by a covering of cotton wool or of other suitable material, to which may be added also another measure, the employment of gentle, equable pressure applied to the tumor by means of suitably adjusted cloth pads and bandages. *The operative measures are ligature, puncture or tapping, injection, and excision.*

* *Brit. Med. Jour.*, Oct. 18, 1898.

Ligature.—In the instances of small openings into the cranium, the isolation of the neck of the sac and its ligature with silk or chromicized catgut offers a favorable outlook, as not infrequent trials have demonstrated.

Puncture or Tapping.—Puncture or tapping is employed as a palliative measure rather than with the hope of establishing a cure. The removal of the fluid in this manner often mitigates and may relieve entirely for a time the unpleasant symptoms attendant upon a rapid development of the tumor, thereby prolonging life directly, and also affording the surgeon an opportunity to act with deliberation and forethought in the selection of sterner measures of relief. The fluid should be withdrawn slowly and with strict aseptic care, to avoid, as far as possible, cerebral disturbance and subsequent meningitis.

Injection.—The injection of a drachm or two of equal parts of the compound tincture of iodine and water—or a similar amount of the iodoglycerin solution*—can be safely employed if all communication be shut off between the tumor and the cranial cavity. If the channel be not occluded already, or the lumen easily controlled by pressure or other simple means, during the process of injection, this measure of treatment should be regarded as unwise and not permissible, except for special reasons. Before the introduction of the curative agent into the sac of the tumor a small portion of the fluid should be withdrawn. The amount of the curative fluid introduced should equal that withdrawn. After the injection of the fluid the patient should be kept quiet, and great care exercised to prevent the entrance into the cranial cavity of any of the medicated contents of the sac.

Excision.—Excision of the tumor with proper care is the most satisfactory method of cure.

The Operation.—The head and the tumor should be shaved and rendered thoroughly aseptic. An incision is then made down to the dura through the scalp and fasciæ at the neck of the tumor, and so located as to admit of the formation of flaps of ample size and proper shape to cover the final wound. These flaps are separated carefully from the dura and pulled aside. A sufficient amount of fluid is then withdrawn from the tumor to permit the walls of the neck of the sac to be readily approximated with each other on a line with the cranial bones. While thus held with a clamp or the fingers the neck of the sac is divided cautiously for a short distance with scissors, and the serous surfaces of the divided borders are approximated by fine silk or catgut sutures applied in a continuous overhand manner. The cutting and sewing are repeated alternately until the neck of the sac is finally severed and the divided borders of the membranes are united completely and securely. If the neck of the sac has been already occluded, the operative measure is much simplified. The wound is closed in the usual manner and dressed with an abundance of antiseptic gauze confined somewhat tightly in place.

The Precautions.—Carefully distinguish between meningocele and encephalocele. If possible avoid a too free escape of fluid since convulsions and death

* The iodoglycerin solution is made by dissolving ten grains of iodine and thirty grains of iodide of potassium in an ounce of glycerin.

may follow as the result. If evidences of impending misfortune arise for this reason, the introduction into the sac of a small amount of warm aseptic saline solution may give prompt relief. As meningitis is to be feared most, antisepsis before and after exposure of the membranes is commended. Drainage should not be employed unless bruising or tearing of the tissues has attended the operation.

The Results.—The number of reported cures following treatment by excision encourage continued trial of the measure in similar cases, especially as no other method offers like favorable results.

Encephalocele.—Encephalocele is located in like situations as meningocele, and must be distinguished from the latter. The contents of encephalocele are composed of cerebral substance and dropsical membranes attended often with more or less fluid. The operative measures are quite futile, but in general are similar in character to those for meningocele. Repeated puncturing with a fine needle, followed by pressure carefully and uniformly applied, offers the safest and most rational method of practice for cure of this infliction.

The Operation of Craniotomy.—Craniotomy is a term commonly applied to the opening of the cranium for obstetrical purposes. It is used here to denote the opening of the cranium for the purpose of relieving cerebral pressure, of stimulating mental development, etc. Surgically speaking, craniotomy may be divided into the *circular*, *linear*, and *irregular* varieties, according to the outline of the opening made in the cranium.

Circular Craniotomy.—Circular craniotomy consists in making a circular opening in the cranium, usually with a trephine, and therefore is called trephining the cranium. There are two patterns of trephines with similar handles (Fig. 265) deserving of special attention—the crown or circular (*e*) and the conical or Galt's (*c, d*). The latter is a much safer instrument, because as soon as the inner table of the cranium is sawn through, the instrument, on account of the conical shape and spiral peripheral teeth, assumes a screwlike character and is arrested in its track. In the case of the former pattern, the arrangement of the teeth is different, and for this reason the membranes are promptly torn and the brain injured, unless great caution be exercised in the use. The diameters of these instruments vary from one half inch to two inches and a half. Circular craniotomy with a trephine of small caliber is commonly practiced for relief of depressed fracture of the cranium and epidural hæmorrhage. The large sizes are used in operations for brain tumors.

Craniotomy for Fracture of the Skull.—Circular craniotomy is commonly practiced for this injury. The field of operation is prepared by cutting the hair short, scrubbing and disinfecting the scalp, and shaving it for a considerable distance around the seat of the injury. The patient is anæsthetized if not completely unconscious, preferably with chloroform, as it causes less cerebral excitement. However, the choice of an anæsthetic is a matter of opinion. The head is conveniently raised and supported by a firm pillow.

The Operation of Circular Craniotomy (Trephining).—With a scalpel (Fig. 265, *a*) make an oval incision of the scalp, through sound tissue if

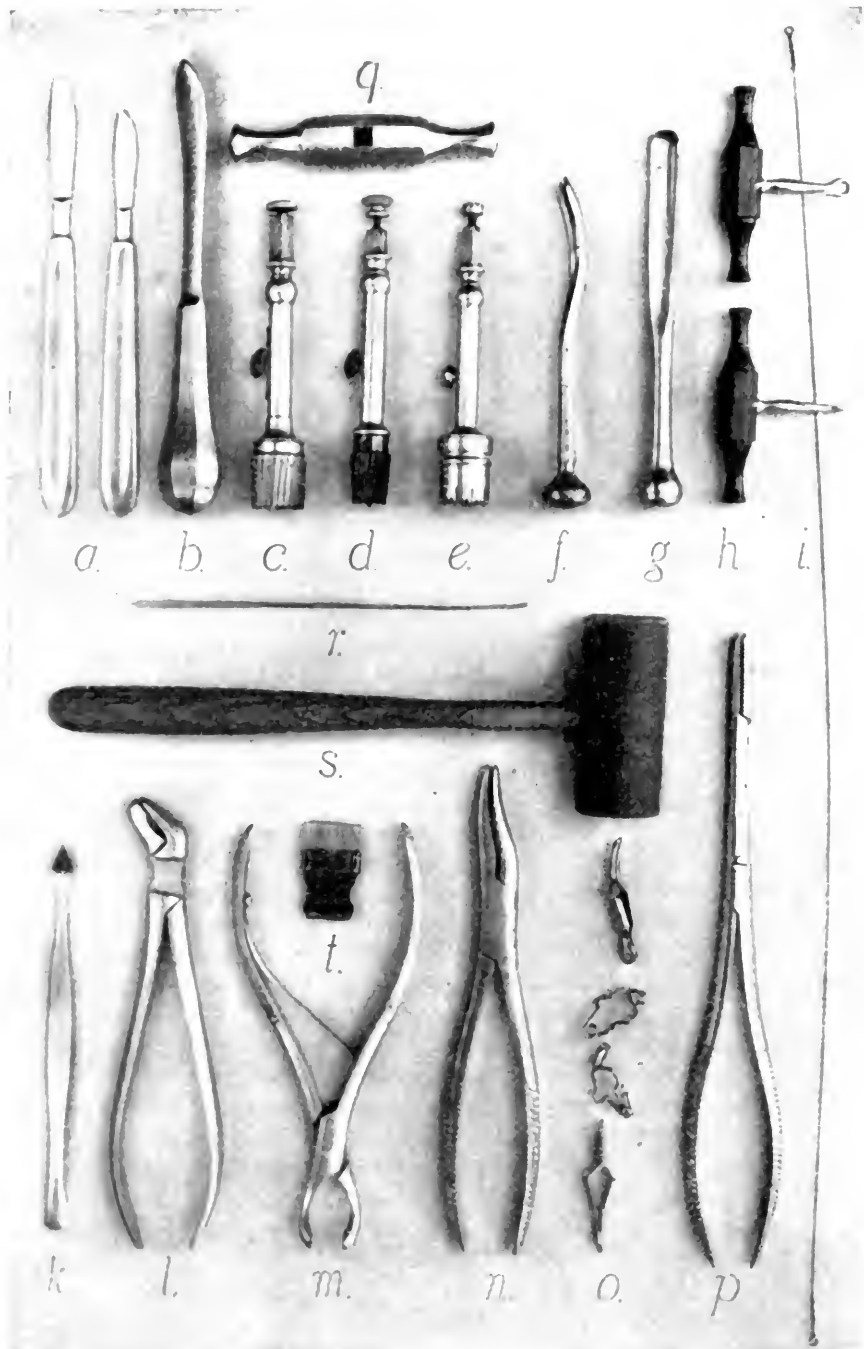


FIG. 265.—Instruments used in craniotomy for fracture of skull.

a. Scalpels. *b.* Periosteotome. *c, d, e,* and *g.* Trephines and handle. *f, g.* Gonges. *h, i.* Gigli-Haertel saw. *k.* Bone elevator. *l, m.* Bone-gnawing forceps. *n, p.* Sequestrum forceps. *o.* Serre-fines. *r.* Probe. *s.* Rawhide mallet (*don't boil it*). *t.* Trephine brush.

possible, down to the perieranium (Fig. 266), of adequate size to expose the fracture and well suited for drainage. The crucial, T- or Y-shaped incision can be substituted for the oval if injury of the soft parts be extensive, or the loss of blood incident to the formation of the oval flap be especially objectionable. The bleeding can be quickly arrested by clamping the scalp at the seat of the flow with *serre-fines* (Fig. 265, *o*); later ligatures are applied.

Raise the periosteum with a periosteotome (Fig. 265, *b*) at the seat of fracture sufficiently to permit the proper application of the trephine. Select a trephine of moderate caliber—say one half to three quarters of an inch—push down the pin for about an eighth of an inch below the teeth of the instrument; fasten the pin firmly in position, and place the point on solid bone (*a*) as near to the line of depression as is wise (see p.

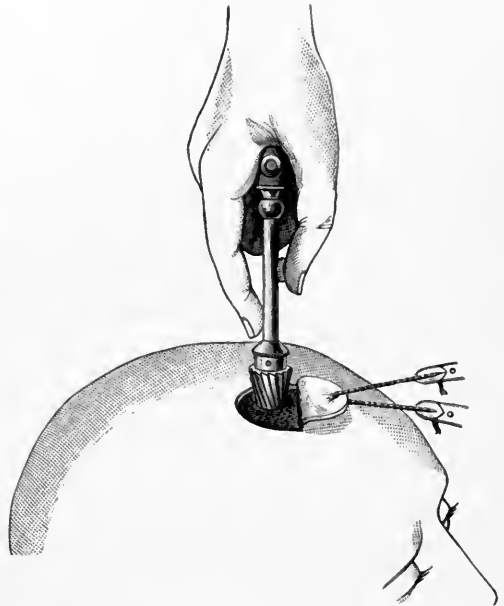


FIG. 266.—Circular craniotomy (trephining).

236, Important Considerations), and at the point best calculated to facilitate elevation (Fig. 267), provided it be not located above an important vessel.

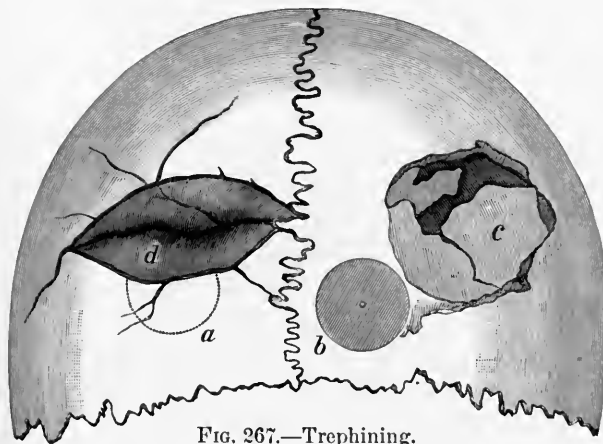


FIG. 267.—Trephining.

Bear firmly on the trephine to introduce the point into the bone; turn the instrument quickly and lightly from right to left, and the reverse until a groove is made in the bone of sufficient depth to retain the instrument in place during further action. During this step of the operation it is wise to hold the head of the trephine in place with the thumb and index finger of the disengaged hand, or by the index finger of the other extended along the trephine down to the skull. When a suitable track is made withdraw

the center pin and fasten it back in place, to prevent puncturing the membranes of the brain. Continue the operation, raising the instrument from the track and freeing it from bone dust with a brush provided for the purpose

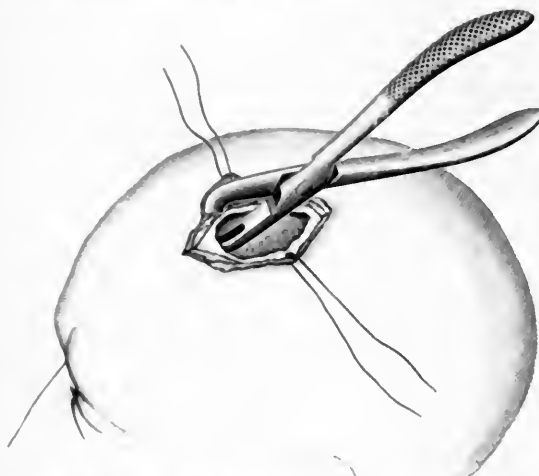


FIG. 268.—Increasing the size of the opening in the skull with the rongeur.

ordinarily the appearances of bone dust vary according to the advance of the trephine; that of the diploë being deeply stained with blood, while that of the tables of the cranium is grayish in color. *The passage through the diploë* is marked by bloody detritus, by an easier and more rapid advance of the instrument, and is attended with a softer sound. While going through the internal table less pressure should be made on the instrument, and the circular movements should be made lighter and quicker than before to avoid a precipitate entry of the cranium. At frequent intervals the end of a grooved director or of a trephine probe (Fig. 265, *r*) is introduced into the track of the instrument to ascertain if any part of the circle be deeper than another, and if the bone be cut through at any point. If the button be percussed with a light metal instrument it gives forth a low-pitched sound if complete division to any extent be present. When but a moderate penetration of the inner table is present, the button can be moved and perhaps tilted out by an elevator, or possibly it may come away with the trephine, if the latter be carefully tilted. If, after the removal of the button, additional room be required, the rongeur (Fig. 265, *l* or *m*) is brought into use (Fig. 268).

The removal of the button of bone enables the surgeon to insert the point of the elevator (Fig. 265, *k*) beneath the depressed portion (Fig. 269)

(Fig. 265, *l*). Ordinarily the appearances of bone dust vary according to the advance of the trephine; that of the diploë being deeply stained with blood, while that of the tables of the cranium is grayish in color. *The passage through the diploë* is marked by bloody detritus, by an easier and more rapid advance of the instrument, and is attended with a softer sound. While going through the internal table less pressure should be made on the instrument, and the circular movements

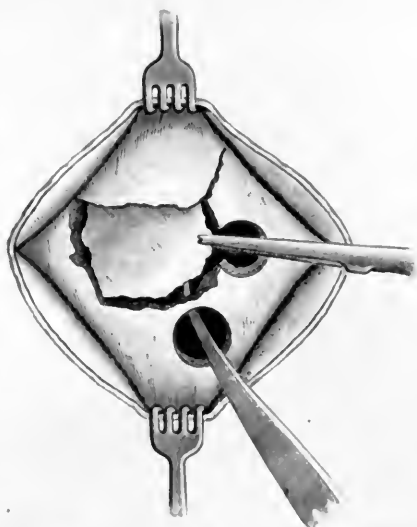


FIG. 269.—Raising a depressed fragment with an elevator passed through a trephine opening.

and to pry it into place through the agency of the finger or the solid bone border (*a*), acting as a fulcrum. Great care must be taken in doing this or the sudden giving way or tilting of the fragment will injure the soft parts, and also disconnect the fragment from nutrient associations. The utilization of the rongeur and the mallet and gouge (Fig. 265, *f*, *g*, *s*) to liberate the points of impaction and binding makes the elevation of the fragments easier and safer (Fig. 271). Projecting points of bone are cut away and loose portions are sought for, especially beneath the bony border of the wound (Fig. 272). The loose pieces of bone are kept and fitted to each other to ascertain if any portion of bone be missing, especially if the membranes have been lacerated, for then a portion of bone may be driven into the brain and remain there unsuspected. Rents of the dura are closed with fine catgut stitches. After proper scrutiny of the wound the technique of closing and dressing it must be considered. Much difference of opinion is expressed regarding the best plan of procedure. *The cranial opening may be repaired* by replacement of the fragments, by the introduction of a foreign body, or by allowing Nature to cure it after her own manner. If the first proposition is to be adopted, the fragments, as fast as removed, are wrapped in an aseptic towel saturated with hot sterilized water to preserve their vitality and purity.

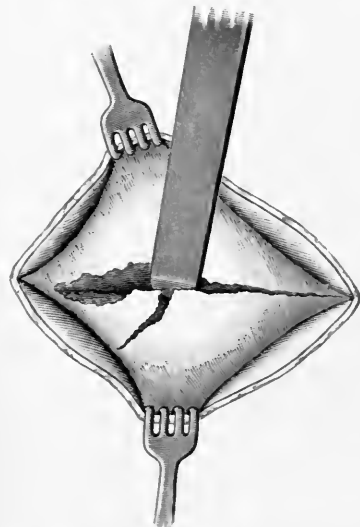

FIG. 271.—The chiselling of a fissure to liberate a point of impaction.

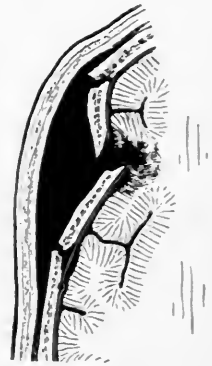


FIG. 270.—Fractures of skull. Depressed fragments. Compression of brain from bone and blood. Illustrates need of care in manipulation of bony fragments.

Whether the replacement of the button intact or the fragmentation of it and return of the pieces is the better plan has caused some discussion. The experience of the author emphasizes a preference for the latter plan since the bony fragments when bathed in blood are more viable than is the button, which often necroses. The introduction into the opening of a metallic, gutta-percha, or celluloid plate is a refinement in surgery which often is successful under strict asepsis. The conditions that make success attainable in this instance will quite likely achieve a similar result in the use of bone fragments, and provide for the patient a vitalized rather than an inanimate repair. The too frequent occurrence of necrosis of the fragments and the little practical utility gained by the success of the measure

in the majority of cases, has led to its discontinuance, except for some special reason. The torn borders of the dura and the borders of the

reflected periosteum are united with fine catgut, the flaps are placed in proper position and united, horsehair or silkworm-gut drainage is provided, antiseptic dressings are loosely applied, the head is elevated, and the patient kept quiet by anodynes if need be, followed by a brisk cathartic.

The Important Considerations.—Crania vary in thickness, the average in the adult being about a fifth of an inch. In youth and old age they are much thinner. The irregularities of the inner table for the reception of the convolutions of the brain cause inequalities in the thickness of circumscribed portions of the bone at numerous situations. Some cranial bones are thinner than others—for example, both in early life and in the aged the diploë is absent from the squamous part of the temporal, the contiguous

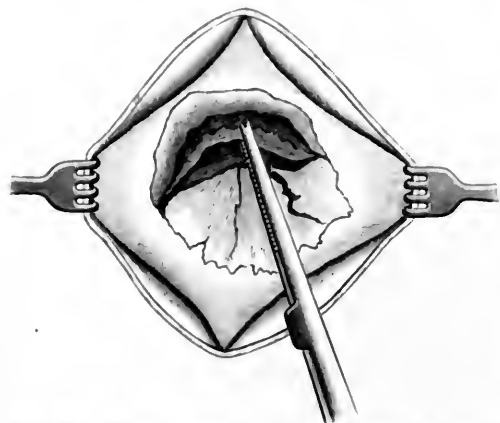

FIG. 272.—The lifting out of loose pieces of bone; of the internal table in this instance.

portion of the parietal and the fossæ of the occipital bone. If these facts be not recognized during operation the danger of injury to the cranial contents is manifest. Holden's maxim for using the trephine—"Think that you are operating on the thinnest skull ever seen, and thinner in one half of the circle than in the other"—is a good one. The trephine should be applied vertically to the plane of the part of the skull attacked and kept in this relation to maintain an equality

in the depth of the circular cut, thus avoiding as far as possible injury of the membranes from a premature division of one side of the button.

Free hæmorrhage from the divided bone is usually arrested by elevating the fragment. If not, temporary tamponing with sponge or gauze will quite easily overcome it. However, if this be not the case, plugging, ligature, crushing, actual cautery (page 252), and Horsley's wax (page 568) are yet available for use. If the bone be comminuted and the fragments movable, they may be elevated without the use of the trephine (Fig. 272). In any event the trephine should be so placed (Fig. 267, *b*) as not to disturb movable fragments (*c*), for fear of causing them to cut or puncture the tissues lying beneath. In such cases the fragments should be removed with sequestrum forceps (Fig. 265, *n, p*) and the trephine placed on solid bone. In a case with firmly depressed fragments (Fig. 267, *d*), the application of the trephine should not be delayed by attempts with less effective means.

In punctured fracture a large trephine is usually employed and so placed over the fracture, if possible, as to provide by a single button ample room for the removal of the fragments of the internal table.

The lodgment in fissures and in bony asperities of hairs, threads, etc., should be noted, and their removal secured to prevent infection.

Trephining over the course of important vessels should be avoided, except for special reasons. The middle meningeal artery and its branches, and the cerebral sinuses are of special significance in this regard.

The Middle Meningeal Artery.—After entering the cranium the middle meningeal divides into two branches, anterior and posterior. The anterior

branch runs in a canal or groove on the inner surface of the antero-inferior angle of the parietal bone (Figs. 273 and 275), upward and a little backward to the sagittal suture lying about three quarters of an inch behind the coronal suture. At this angle of the bone it is about one inch behind the external angular process of the frontal bone, and one inch and a half to one

and three quarter inches above the zygoma (Fig. 292, *F*). The posterior branch passes upward and backward along the inner surface of the squamous portion of the temporal bone, lying in a shallow groove (Fig. 275), at an angle of about 9° with the upper border of the zygoma (Figs. 273, *b*, and 292, *G*). If the meningeal branch be severed with the trephine, the hæmorrhage may be arrested by ligature, by tamponing by instrumental pressure of the bleeding point against the inner table, trephining and tying the vessel at the proximal side of the injury, and by ligature of the external carotid. The simpler

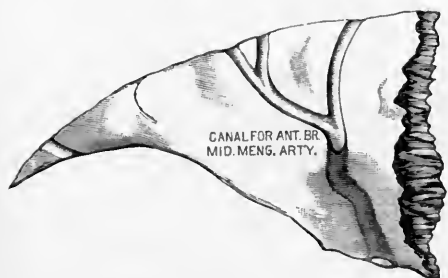


FIG. 274.—Anterior branch of middle meningeal artery occupying a canal at anterior-inferior angle of parietal bone.

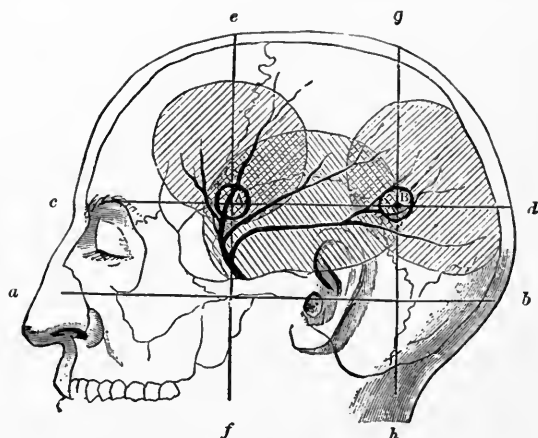


FIG. 273.—Course of middle meningeal artery. *a, b*. Reid's base line. *c, d*. Krönlein's line. *e, f*. Vertical line, inch and a half behind external angular process. *g, h*. Vertical line at posterior border of mastoid process (page 240, Fig. 276).

methods usually are sufficient for the purpose in all instances except when the bleeding complicates a fissured fracture of the skull. The presence of the anterior branch of the meningeal artery in a canal (Fig. 274) exposes the vessel to much greater danger of injury from fracture or trephining at that situation than when running in a groove (Fig. 275), for obvious reasons.

The location of the sinuses are indicated sufficiently, to avoid injury to them, under the heading of "Dangers" on page 244 and "Precau-

tions" on page 239, and by Fig. 292, *A, B*. If a sinus be opened the wound is tied or sewed with catgut or closed by compression with aseptic gauze.

The Results.—The nature of the injury, delay in the performance of the operation, and the inability to execute the proper technique are the important factors that modify the prognosis. A fatality of from four to fifteen per cent is a fair estimate of the results in civil practice. The death rate from trephining alone is scarcely two per cent.

Craniotomy for Meningeal Hæmorrhage.—Meningeal hæmorrhage may be either *epidural* (Fig. 277) or *subdural* (Fig. 279). The former is easier treatment and offers by far the better prognosis. Either variety is commonly

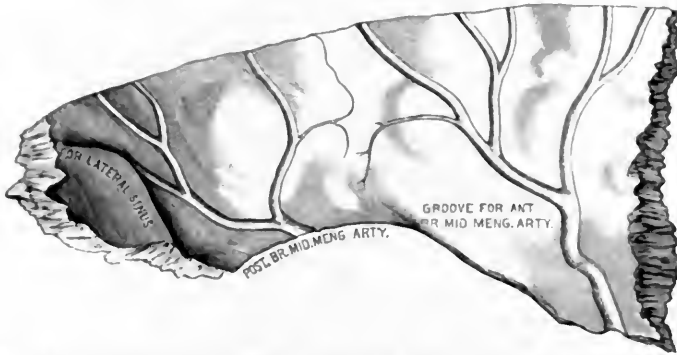


FIG. 275.—Anterior branch of middle meningeal artery occupying a groove on anterior-inferior angle of parietal bone.

associated with severe injuries of the head, such as fracture of the skull, laceration of the brain, etc. In depressed fractures the blood often escapes externally, or is easily removed coincident with elevation of the bone. Fisured fractures of the cranium are complicated frequently with extradural hæmorrhage, especially when the fissure passes through the route of the branches of the middle meningeal artery. This variety of hæmorrhage, although circumscribed, is frequently extensive. After the localization of the seat of the blood clot, the preparation of the patient is the same as in trephining for other purposes (page 231). The formation of the flap, the control of the hæmorrhage, and the general technique are similar. The operation should be done promptly—and with chloroform when practicable—if anæsthesia is required.

The Operation.—Make a flap of large size at the seat of injury, provided the injury corresponds with the seat of the hæmorrhage, as indicated by the symptoms. After exposure of the cranium seek for a fissure of the skull. Apply a full-sized trephine to the cranium—in the line of the fissure if practicable—and expose the blood clot beneath. Remove the blood clot carefully with the finger or with a scoop—a teaspoon will do—aided by flushing with hot sterilized water. If all hæmorrhage has ceased, drain the cranial wound with horsehair or silkworm gut, return the soft parts to the normal places, unite and dress the wound in the usual manner. If hæmorrhage be progressing at the time of operation the occurrence is indicated by the following facts:

1. The presence of extensive extravasation of the soft parts with fluid blood.
2. The free escape of blood from a fissure fracture.
3. The pulsation of the epidural clot.
4. The appearance of fluid blood in the epidural cavity after removal of the blood clot.
5. The discovery of the bleeding point itself (Figs. 276 and 277).

The prompt arrest of the bleeding is of obvious importance. If the bleeding point can be seen when it lies in the bone tissue the flow may be stopped by plugging the point with catgut; by tying or by pressure of the vessel against the internal table by means of properly curved long-bladed forceps, one blade being placed without and the other within the cranial cavity. If the bleeding point can not be seen the application of cold to the head, temporary sponge or gauze pressure, or pressure on the common carotid should be tried. However, in either case, if the bleeding persist, it can be arrested by ligature of the external carotid, or better by trephining, and ligaturing the vessel at the proximal side of the bleeding point, after which the wound is drained and treated antiseptically (Fig. 278).

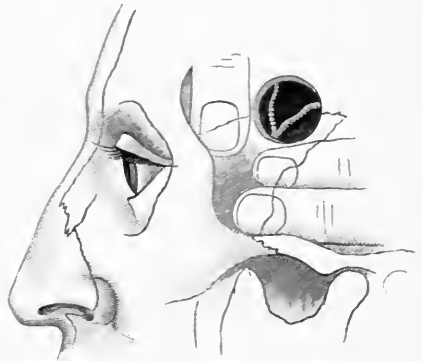

FIG. 276.—Vogt's method of locating middle meningeal artery.

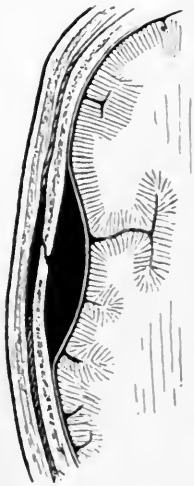


FIG. 277.—Fissure of skull with epidural hæmorrhage.

If the compression symptoms be of indefinite character and no fracture be found, Krönlein advises as follows: "Draw a line around the skull from the upper margin of the orbit (Fig. 273, *c, d*) parallel throughout with Reid's base line (Fig. 273, *a, b*). At a point from one inch and a quarter to one inch and a half—according to the size of the head—from the external angular process, apply the trephine (*A*) and explore for hæmorrhage (Fig. 276). If the conditions indicate involvement of the posterior branch, the latter may be exposed by a trephine opening (*B*) on the same line where it is intersected by a vertical line drawn from the posterior border of the mastoid process." Thumb in front and two fingers below (Fig. 276).

The Precautions.—The absence of a fissure of the cranium at the seat of external injury is no proof that a fissure is not present. Not infrequently in these cases the fissure begins at an extreme limit or even outside of the external wound, therefore the injured and adjoining areas should be carefully searched, otherwise the fracture will escape notice. A minute fissure may be confounded with a suture, or with an incision through the pericranium. The irregularity and direc-

tion of the former and the shallow and fickle borders of the latter will readily discriminate between them. The tamponing of the clot cavity to arrest hæmorrhage should not be favorably regarded,

since to be effectual the tampon must exercise as great pressure at least as did the blood clot itself.

Ligature of the common carotid should not be entertained in this connection because of the high rate of mortality (forty per cent) following this procedure; the external carotid should be tied instead, as the rate following its ligature is less than four per cent. If no epidural clot (Fig. 278) be present a subdural one should be sought for (Fig. 279).

The Results.—The results depend very much indeed on the character and

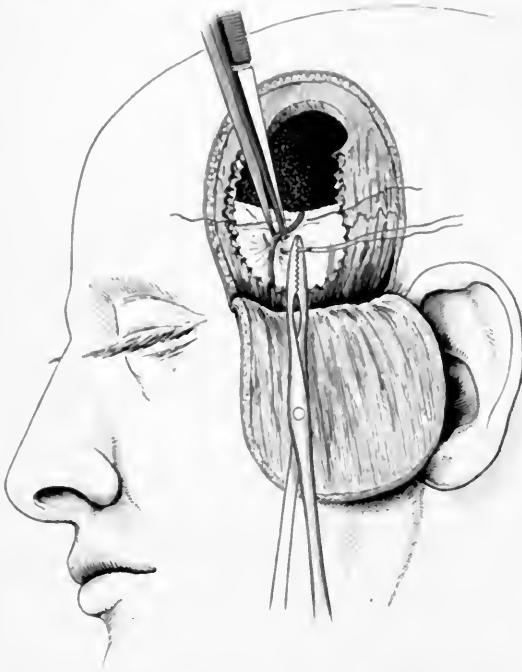


FIG. 278.—Epidural clot. Rupture of middle meningeal artery. Trephine followed by rongeur to local seat of bleeding. Arrest with suture.

extent of cerebral complications. However, the statistics of Weisman amply demonstrate the wisdom of the measure. According to his report 89.1 per cent died with the expectant treatment, and but 32.7 per cent died after operative treatment.

Subdural Hæmorrhage.—Subdural hæmorrhage arises from the effects of traumatism, from pachymeningitis, and from unknown causes. The clot may be a recent or an old one, and may be of arterial, venous, or capillary origin. If arterial the middle meningeal or basilar vessels are usually at fault. If venous it is frequently associated with abnormalities of the veins

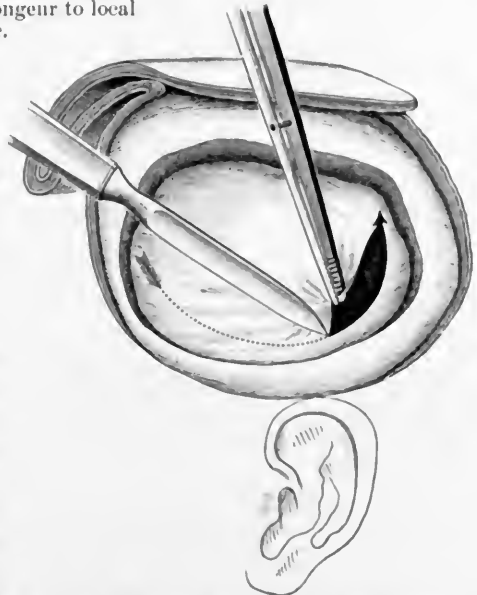

FIG. 279.—Subdural clot, exposed by division of dura after removal of part of skull.

connected with the superior longitudinal sinus. If capillary it is often the result of local traumatism. It is of special importance to note the possibility of the presence of free blood beneath the dura subjacent to a fracture of the skull. Subdural hæmorrhages are rarely indeed circumscribed, and often cover the entire surface of a cerebral hemisphere. If subdural hæmorrhage complicate a fracture of the skull the elevation of the bone or the removal of the epidural clot gives but little if any relief to the patient. In such cases the exposed dura bulges into the cranial opening somewhat, and the brain pulsations can not be seen or felt, or are present only in a limited degree.

The Operation.—Increase the size of the opening in the cranium so as to correspond to the recognized area of compression; at the most dependent point make an oval incision in the dura with a curved bistoury a quarter of an inch from the bone margin; arrest all bleeding; carefully draw aside the dural flap with a tenaculum; incise the arachnoid membrane cautiously with bent scissors, and draw it aside so as to expose the blood clot, which is then, with bits of sponge, wiped carefully away. If firmer agents than these be employed to remove or dislodge the clots, great care is needed to prevent injury of the brain and increase of hæmorrhage. Hæmorrhage of the dura is promptly and finally controlled by a catgut ligature passed by the aid of a needle through the membrane near to the border around the vessel and tied. Hæmorrhage from the pia is commonly arrested by patiently applied sponge or gauze pressure. Serre-fines (Fig. 265, *o*) and fine catgut ligatures are employed if pressure be inefficient. Hæmorrhage from the brain is usually controlled by sponge or gauze pressure; adrenalin ought and cautery can be employed. Park advises a solution of 1 to 40 of antipyrin, and Keen a solution of cocaine 1 to 100 for this purpose. After the removal of the blood clot and the arrest of hæmorrhage, the borders of the divided dura are united by a continuous suture of fine catgut, except for a short distance at the most dependent portion; at this point horsehair drainage is provided and the remaining portion of the wound lightly packed with aseptic gauze, which is in turn covered with an abundance of carbolic or bichloric gauze, bound tightly in position. The head and shoulders are elevated, and the patient is quieted by anodynes if necessary. *Subdural hæmorrhage unassociated with fracture*, when the seat of the extravasation is established, and when the condition of the case will justify, should be treated in a similar manner. The author has in three instances removed what was possible of an extensive subdural extravasation of blood. In one instance only was there evidence of fracture. In all cases temporary amelioration of the symptoms followed the escape of an abundance of sero-sanguinolent fluid. In each instance the patient succumbed, on account of extensive fracture of the base of the skull and the extravasation of blood.

The Results.—The not infrequent favorable reports of operations for relief in subdural hæmorrhage of both recent and remote occurrence are sufficiently assuring to justify continued efforts in this direction in proper cases and with strict aseptic technique.

Craniotomy (Linear) for Microcephalus.—The term microcephalus is applied to an abnormality of the brain characterized by diminished size, and

also enfeebled and distorted functions of the organ, associated with congenital and premature closure of the fontanelles and sutures of the cranium. This unnatural closure of the osseous envelope of the brain was regarded at first as the chief cause of the singular mental exhibitions of these patients, and they were thought to depend on the arrest of cerebral development coincident with the pressure imposed on the organ by the limited capacity of the cranial cavity. In the presence of this belief, it is not strange that operative measures contemplating the loosening of the brain from the unnatural besetment were promptly planned and executed. It is to be regretted, however, that the operative procedure itself often proves unexpectedly and unaccountably fatal, and that the curative outcome is very disheartening.

Having carefully determined the case to be a proper one and in suitable condition for operation, prepare the patient in the manner proper in craniotomy for fracture (page 231). Before making the scalp flap, suitable measures should be taken to avoid loss of blood. Circumferential elastic pressure made by strong rubber bands resting on and holding in position small firm compresses placed over the main arteries supplying the scalp, or the control of these vessels by acupressure and digital pressure are advised. However, if the bleeding points be promptly caught the loss of blood from the scalp will play no important part in the result.

The Operation of Linear Craniotomy.—The site of the operation is exposed by a free incision of the scalp down to the pericranium, and from the hair line in front backward to the occipital protuberance, an inch from and parallel with the sagittal suture. This incision is supplemented by a short one at either end passing downward and outward. The scalp flap is drawn aside and held with loops of silk passed through the border at two or three situations. A button of bone about an inch in width is removed from the center of the operation field by a trephine applied not less than one inch and a half from the sagittal suture. Beginning at the opening first made, separate the dura from the bone with a narrow, flexible spatula (Fig. 290, *i*), allowing it to remain in position to protect the dura from injury (see Meningitis, page 244), the bone is cut through parallel with the sagittal suture nearly to the limits of the incision of the soft parts by means of Hofmann's bone-cutting forceps, rongeur (Fig. 265, *l, m*), chisel and mallet, or by sawing. The use of the chisel and mallet requires the employment of much force, causing objectionable vibration of the structures of the head; they are therefore used now less frequently than before, the saw and bone-cutting forceps being employed instead. Sawing is the quicker and, perhaps, the safer means, and should be employed when practicable. In order to secure a prompt and greater increase of capacity of the cranial cavity, lateral divisions of the skull are sometimes made. Various other forms of bone incision are also recommended (Chipault) (Fig. 280). If the lateral bone sections are to be made by sawing, the removal of a small button of bone at the point of beginning of each will enable the operator to apply the saw more satisfactorily and effectively at these points for obvious reasons. The immediate and forcible elevation of a parietal bone when thus divided does not commend itself as wise or essential in a known degree to the purpose of

the operation. But that the bone may be sprung upward at this time sufficiently to test its yielding nature with no harm, and perhaps with benefit, is a reasonable conclusion. Whether or not a narrow strip of bone should be removed along the antero-posterior line of section must be decided at the time of the operation, for certainly it should not be attempted if the safety of the patient will be compromised by the act. The removal *en masse* of large

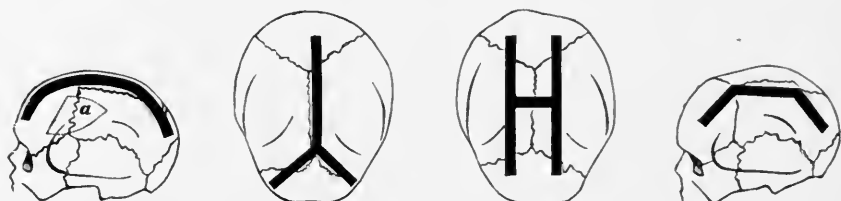


FIG. 280.—Sections of cranial bones.

areas (Fig. 280, *a*) of bone corresponding to a depressed surface is practiced with comparatively no unfavorable results, and seemingly with prompt benefit than from more limited removal. Powell's electric saw, driven by an easily portable motor, is a capital contrivance for the purpose (Fig. 281). When a change in the direction of the sawing is desirable, an additional trephine opening at the proper site meets the requirement. The dental engine can be used to drive the saw, but is less effective in all respects than is the former.

The *Gigli-Haertel wire saw* (Fig. 265, *i*) is a recent and valuable addition to the armamentarium of bone sawing. In the instance of craniotomy the saw is carried through the trephine openings beneath the bone and above the spatula employed in the detachment of the dura by means of a long

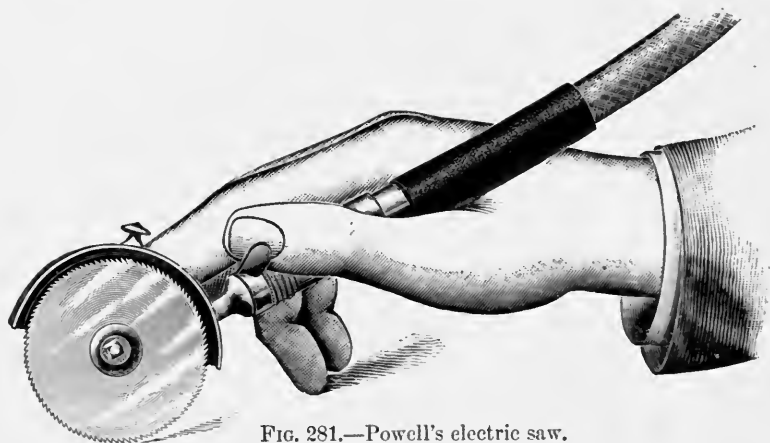


FIG. 281.—Powell's electric saw.

probe with string attachment. The handles (Fig. 265) are then affixed and the instrument operated as is the chain saw. Bone flaps of varying size and shape can be formed with this instrument.

It may happen in this operation that the bone section should extend farther to the front than has been described above or be limited to the an-

terior part of the cranium or to the motor area alone, depending on the manifestations exhibited by the patient; and, too, exploration beneath the dura mater may be regarded as admissible and even necessary in some cases. After the arrest of hæmorrhage the skin wound is closed with silkworm gut and dressed antiseptically. The patient should be kept quiet by the use of the bromides, if advisable, until the wound is healed. Drainage need not be employed unless for some special reason.

The Dangers.—The danger from hæmorrhage is considerable, especially in those cases possessed of highly vascularized diploëic structure. In such cases it is sometimes necessary to stop the operation on account of the great loss of blood. The author once encountered a case of this kind. If the bleeding come from definite points of the cancellous tissue, it can be arrested by plugging the opening with catgut, or by aid of the actual cautery or the heated point of a probe (see page 236). If the bleeding from the bone be general the gauze tampon firmly applied along the line of section will arrest it. Injury of the longitudinal sinus will cause free hæmorrhage. Fortunately, however, the demands of the operation do not require a close approach to this important vessel. It is not amiss to recall the fact that *the sinus* is quite narrow in front and increases in width as it passes backward, and also that it encroaches more on the left than the right parietal bone at the posterior part.

Shock is an important element of danger in these cases. It is caused sometimes by the loss of blood and also by the violence inflicted in the operation. In not a few instances the depth of the shock can not be satisfactorily accounted for. While cases differ much in this regard, still the rule is, the longer the time employed in the operation and the greater the measure of violence, the more profound is the degree and the danger from shock. For this reason, operation on both sides of the head at the same sitting is not favorably regarded; and, moreover, if a considerable interval between the operations be allowed, one is enabled to judge of the advisability of a second operation by the results arising from the first.

Meningitis.—Meningitis is an infrequent sequel of the operation, and is often provoked by the rough handling or carelessness of the operator. The danger of injuring the dura, except with the saw, is trivial, and can be easily obviated by passing between it and the cranium a thin, flexible strip of metal which is held firmly in position during the act of sawing (Fig. 290, *i*). If the strip of metal be grooved along the uppermost surface sufficiently to leave an appreciable space between it and the bone, the bone can then be divided entirely with a minimum danger of injury of the soft parts.

Thrombosis and Pyæmia.—If the wound becomes infected and the cancellous tissue of the cranial bones is involved, then much danger from pyæmia arises. If proper aseptic precautions are taken at the outset and maintained during the operative and subsequent treatment, there is no likelihood of infection.

The Results.—While the ultimate results do not as yet establish the operation on a firm basis, still it offers to many cases the only known hope of even a temporary improvement. The present inability to determine the patholog-

ical condition of the brain before exploration has much to do with the unfavorable results that follow it. Still, the hopelessness of the condition, and the undoubted benefits that have followed operation in isolated cases, should encourage a studied perseverance in this direction until a better means of relief is ascertained. Promptly after the operation the temperature reaches a high figure in some cases, and with fluctuations remains there for days, unless death ensues. The author has in mind a case of his own in which death, with high temperature, happened within a week, with no physical or bacteriological evidence to account for it. *The death rate* from the operation is variously stated as being from two to seventeen per cent. The best results occur in those over ten years of age.

Craniotomy for Brain Tumor.—The brain, like other tissues of the body, suffers from the presence of nearly every variety of morbid growth. The ascertainment of the functions of certain portions of the encephalon enables the diagnostician to locate the situation of tumors in many instances by a careful analysis of the disordered manifestations provoked by the presence of these growths in the brain. In order to indicate on the cranium the proper seat of operation for the removal of brain tumors, it is necessary to recognize the situation of certain established points of reckoning, and, from a knowledge of these, indicate the definite part of the cranium that covers the disordered brain center.

Cranio-cerebral Topography.—The expression cranio-cerebral topography applies to the localization of important brain fissures and centers by aid of

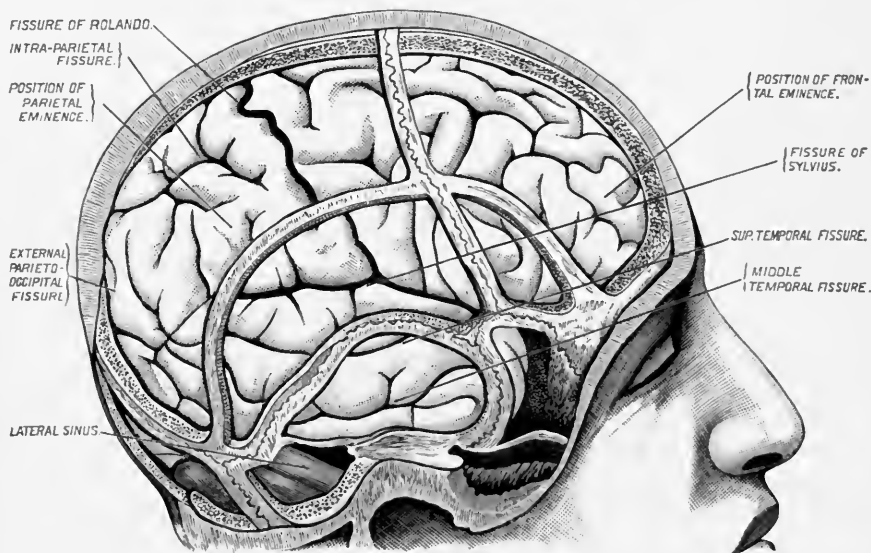


FIG. 282.—Relation of cerebral fissures to the cranial sutures in the adult.

the bony landmarks of the skull. The *prominences, ridges, sutures*, and the specially *designated points* of reckoning need not be considered in detail now, since their location and importance will develop during the cranial

survey. In order to locate important cerebral parts it is necessary to make definite measurements of the cranium. The relations of the sutures to the cerebral fissures and convolutions are matters of great consequence in these measurements (Fig. 282).

It is wise to note at the outset that the relations between sutures and eminences of the skull and the fissures and convolution of the brain are not unvarying. For instance, the squamous suture may be above, below, or quite on a line with the Sylvian fissure. The parietal eminence may vary half an inch in the vertical and an inch in the horizontal direction (Anderson and Makin). The relation between the bregma and lambda and glabella and inion vary considerably in different cases. The Sylvian fissure is more oblique in children up to the third or fourth year, and lies farther above the squamous suture (Fig. 283) (Foulhauze). At this age, too, the upper end of the Rolandic fissure is usually a little anterior to its site in adults.

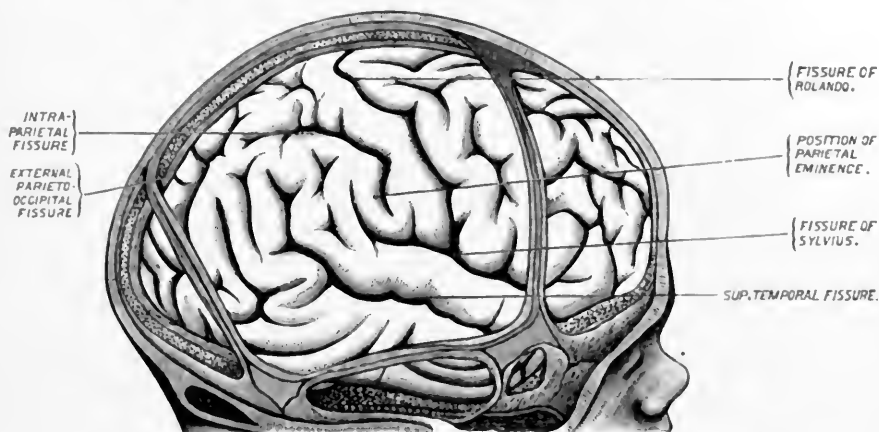


FIG. 283.—Relation of cerebral fissures to cranial sutures in the child.

The Central or Fissure of Rolando.—The central or fissure of Rolando is the most important of the fissures connected with cerebral localization. It passes downward and forward on the outer surface of the cerebrum between the ascending frontal and parietal lobes, about three and a half inches, forming an angle of sixty-seven degrees with the median line of the cranium (Figs. 282 and 289). It is located by either of the following topographical plans (Figs. 285, 286, 287, and 288) or by mechanical means (Fig. 284) devised for the purpose. *Horsley's fissure meter* is calculated to fulfill the requirements of each class of cases. Horsley, finding that the angle between the central and longitudinal fissures varied somewhat with the shape of the head, as modified by the cephalic index, devised an instrument provided with a rotating arm corresponding to the central fissure, which can be varied to meet the deviations of the various cranial indices. The degree of the cranial index is determined by dividing the transverse diameter of the head by the antero-posterior diameter. According to Horsley, in a head with a cranial index of 0.75 the central fissure runs at an angle of 69°, the angle increasing

or diminishing one degree for every two degrees increase or decrease in the cranial index. The instrument is so applied to the head (Fig. 284) that the movable arm at its center of rotation will correspond to the upper end of the central fissure. The arm can be rotated to conform to the cranial index as established by measurements already stated.

Chiene's method of determining the position of the fissure is ingenious, available, and effective (Fig. 285). He folds a square piece of paper once, so as to form a triangle $A B C$, the corners B and D coinciding. The angle $B A C$ is one of 45° . The dotted edge $D A$ is folded back so that the dotted edge $D A$ is applied to the dotted line $C A$. Each of the angles $D A E$ and $E A C$ is evidently half of 45° —that is, 22.5° . Leaving the flap $D A E$ folded, the paper is unfolded at the line $C A$, forming the figure $A B C E$. The angle $B A E$ being made up of one of 45° and one of 22.5° , is evidently 67.5° , which is, for practical purposes, near enough to the direction of the fissure of Rolando. The side $A B$ (B in front)

is then applied to the middle line of the head, the angle A being placed half an inch behind the midpoint between the glabella and inion, when the line $A E$ corresponds to the fissure of Rolando. In all instances the lower third of the fissure is more nearly vertical than the remaining portion of it. In children under nine years of age the fissure lies farther forward, and is placed more obliquely than as just described.

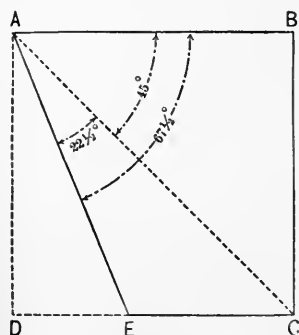


FIG. 285.—Chiene's method of locating the direction of the fissure of Rolando.

lies over the fissure of Sylvius (Reid). The first three quarters of an inch of this line lies over the main fissure, and the remainder over the horizontal portion. The main fissure bifurcates, therefore, two inches behind and a quarter of an inch above the external angular process of the frontal bone. The ascending arm of the fissure (*Sy. a. f.*) is about three quarters of an inch long, and lies directly behind the coronal suture. The horizontal arm is about four inches in length. The schemes of Anderson and Makin (Fig. 287) and Lucas-Championnière (Fig. 288) are commended for the localization of this fissure.

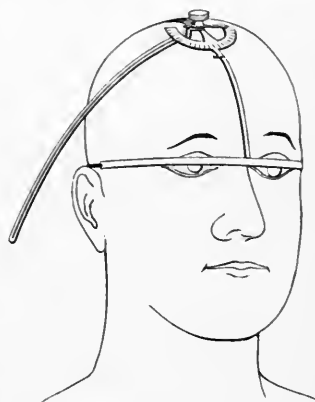


FIG. 284.—Horsley's fissure meter.

The Parieto-occipital Fissure.—The portion of this fissure on the upper surface of the cerebrum runs outward for about an inch at right angles with the longitudinal fissure (Figs. 282 and 283). If the line indicating the location of the fissure of Sylvius be extended directly to the median line (Fig. 286, A) of the cranium, the last inch of the line (*p. o. f.*) lies above the upper portion of the parieto-occipital fissure. The external portion of the fissure varies more in location than any of the other important fissures. However, the whole or some portion of it is easily exposed through a properly located opening an inch in diameter.

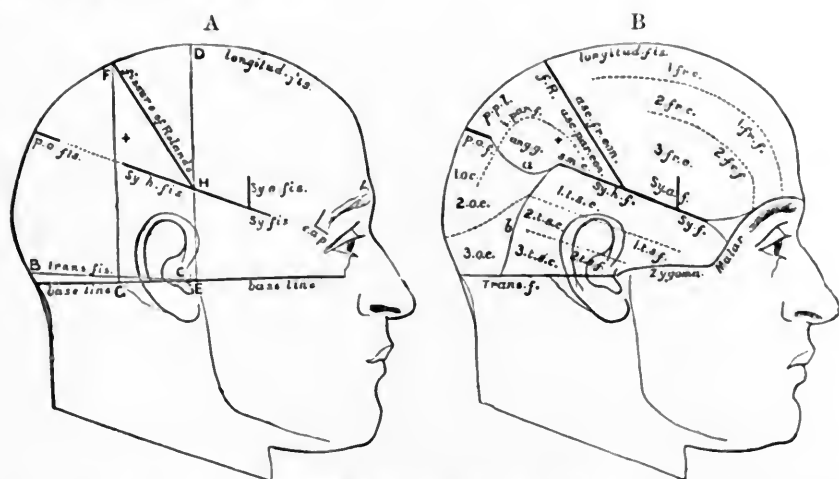


FIG. 286, A and B.—Reid's Lines.

A *base line* (Fig. A) is formed extending from the lower margin of the orbit to the center of the external auditory meatus, thence directly backward, *E, G.* *F, G, D, E* are two perpendicular lines drawn from the longitudinal fissure to the base line, one passing across the depression in front of the ear, the other along the posterior border of the mastoid process. *F, H* a line drawn from the upper end of the posterior perpendicular line to the point of junction of the anterior perpendicular one with the line indicating the course of the fissure of Sylvius, and corresponding to the central or fissure of Rolando; *e. a. p.*, external angular process. + The parietal eminence; *a* (Fig. B), convex line indicating lower boundary of the parietal lobe; *1. fr. c.*, first or superfrontal convolution; *1. fr. f.*, first frontal or superfrontal fissure separating the first from the second frontal convolution (*2. fr. c.*); *2. fr. f.*, second frontal fissure separating second (*2. fr. c.*) from third (*3. fr. c.*) frontal convolutions; *f. R.*, central or fissure of Rolando; *asc. fr. con.*, ascending frontal convolution; *asc. par. con.*, ascending parietal convolution; *Sy. f.*, fissure of Sylvius; *Sy. h. f.*, horizontal, and *Sy. a. f.*, ascending limb of Sylvian fissure; *p. o. f.*, parieto-occipital fissure; *i. par. f.*, interparietal fissure; *ang. g.*, angular gyrus; *s. m. c.*, supermarginal convolution; *1. t. s. c.*, supertemporal convolution; *1. t. s. f.*, supertemporal fissure, separating first supertemporal convolution (*1. t. s. c.*) from the second temporo-sphenoidal convolution (*2. t. s. c.*); third temporo-sphenoidal convolution (*3. t. s. c.*) separated from the second (*2. t. s. c.*) by the second temporo-sphenoidal fissure (*2. t. s. f.*); *1. 2.* and *3. o. c.*, first, second, and third occipital convolutions; *p. p. 1.*, superior parietal convolution (post-parietal lobule).

The Longitudinal Fissure.—The longitudinal fissure is situated beneath a line drawn from the glabella to the inion (Fig. 287, *G, I*).

The Transverse Fissure.—The position of this fissure is indicated by a line drawn directly from the outer auditory meatus to the inion. The line

corresponds with the superior curved line of the occipital bone, and marks, therefore, the junction of the head and neck posteriorly—a fact of great importance in connection with operations directed to the cerebellar fossæ.

The Intra-parietal Fissure.—Preparatory to localizing this fissure (Fig. 289), define the positions of the central, Sylvian, and parieto-occipital fissures and the parietal eminence (Fig. 286, *B*). This fissure corresponds to a curved dotted line drawn from a point four fifths of an inch behind the bend of the fissure of Rolando (Fig. 286, *B*) upward and backward midway between this fissure and the parietal eminence, thence downward and backward in a curved manner midway between the parietal eminence and the longitudinal fissure to and a little below the outer end of the parieto-occipital fissure.

The precentral or Vertical Frontal Fissure.—This fissure lies nearly parallel with and just behind the coronal suture. Its lower end is two fifths of an inch (one centimetre) above the Sylvian fissure and a twelfth of an inch behind the coronal suture. It is placed about four fifths of an inch in front of the central fissure (Figs. 282 and 289).

The subfrontal fissure extends from the precentral fissure to a little above the superior Stephanion, thence forward, corresponding nearly to the frontal part of the temporal ridge (Figs. 282 and 289).

The superfrontal fissure commences at a point four fifths of an inch in front of the central fissure and about an inch and a half from the longitudinal fissure (Figs. 282 and 289), and passes forward in a varying line practically parallel with the latter, and ends opposite the supra-orbital notch.

The posterior cornu corresponds to a point one and three quarter inches

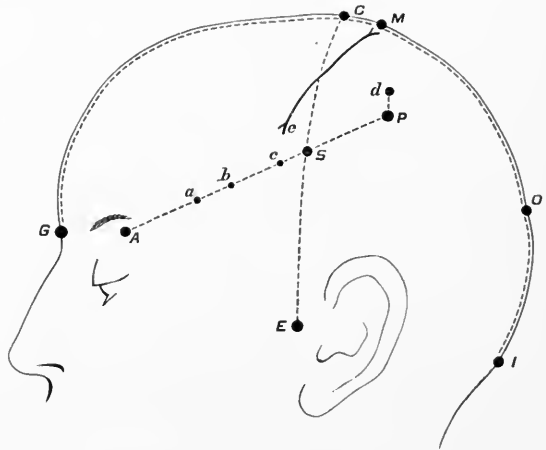


FIG. 287.—Anderson and Makin's Lines.

G, glabella; *I*, inion; *G I*, sagittal line; *M*, mid-sagittal line point; *A*, external angular point (most external point of the external angular process, and on a level with the superior border of the orbit); *S*, squamosal point (at intersection of frontal line, *E M*, and middle and upper thirds of the oblique line, *A P*); *P*, parietal point (termination of oblique line and equidistant with *b* from squamosal point, *S*); *E*, preauricular point (just in front of the ear and at the level of the upper border of the meatus); *a*, beginning of the fissure of Sylvius (five twelfths of the distance from *A* to *S*); *b*, bifurcation of the fissure of Sylvius (seven twelfths of the distance *A* to *S*; an inch and a half to two inches from *A*); *d*, termination of the fissure of Sylvius (half an inch above *P*, in direction parallel with frontal line, *E M*); *Ce*, central fissure (the upper end, *C*, three eighths of an inch behind mid-sagittal point, *M*); *e*, lower end of central fissure (three eighths of an inch in front of squamosal point, *S*); *O*, parieto-occipital fissure (seven twelfths of the distance from *M* to *I*); *A P*, oblique or squamosal line; *E M*, frontal line.

below the parietal eminence (+) and two inches and a quarter from the surface (Agnew).

The *angular gyrus* corresponds to the point of junction of the posterior perpendicular line (Fig. 286, B) with a direct extension to it of the Sylvian line (Agnew).

Poirier's Nasolambdoidal Line.—Beginning at the naso-frontal groove, draw a line outward around the base of the skull, passing a quarter of an inch above the external auditory meatus to a point two fifths of an inch above the lambda, or to a point two and four fifths inches above the union if the lambda can not be felt. This line passes over Broca's convolution, one and a half to two and a half inches of the posterior limb of the Sylvian fissure, the inferior border of the supra-marginal convolution, base of the angular gyrus, and terminates at the parieto-occipital fissure.

Inasmuch as the relations of the foregoing fissures to all the intracranial areas now open to surgical approach can be definitely determined, any further elucidation in this direction is not necessary. The ability to fix the seat of operation by cranio-cerebral topography only leaves for consideration the

technique of operative procedure.

The Preparation of the Patient.

—The administration of bromides for a week or so before the operation and of morphin or ergot a short time before, is sometimes practiced with the belief that both cerebral vascularity and excitability are lessened by these means. Certainly a judicious use of these agents can do no harm, and they are likely to do good. The bowels should be moved freely the night before the operation,

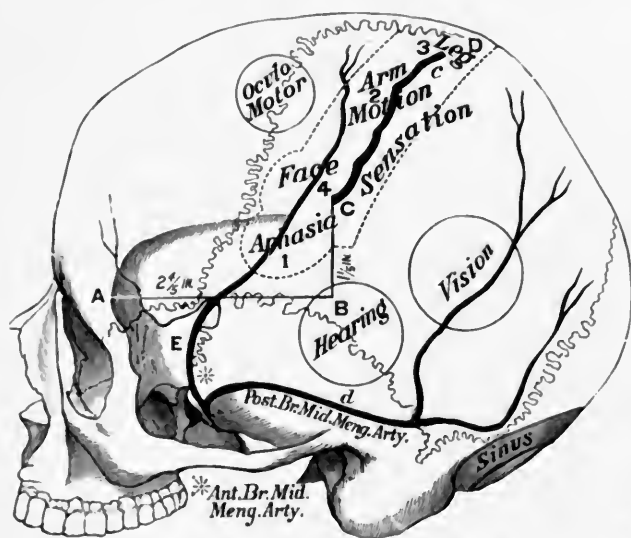


FIG. 288.—Lucas-Championnière's Lines.

A B. Horizontal line extending from outer angle of orbit (two and four fifths inches long). B C. Line extending upward to lower end of central fissure (one and a fifth inches long). D. Upper end central fissure (half inch behind mid-sagittal point). C D. Course of central fissure. 1. Speech center. 2, 3, and 4. Centers of arm, leg, and face respectively.

and light diet only should precede it and at a proper interval. The patient's scalp should be closely shaved, scrubbed, disinfected thoroughly, and surrounded with antiseptic gauze bound firmly in place with antiseptic bandages on the day before the operation, if possible. Before the administration of the anæsthetic the situation of important fissures and the pro-

posed seat of the operative attack should be indicated on the scalp with tincture of iodine, an aniline pencil, fine cautery lines, or by other suitable agents. Put the patient on the operating table, with the head elevated, exposed to a good light and placed on a firm support covered with an antiseptic rubber sheet. Chloroform is the preferable anæsthetic in these cases, because the administration is followed by a minimum of cerebral congestion and excitement. Morphiu should be given more cautiously with chloroform anæsthesia than with that of ether. The markings on the scalp should be made indelible with delicate actual cautery lines, and the cranial surface beneath them vigorously punctured at frequent intervals of their course by a sharp-pointed instrument. If these precautions be not taken, the final scrubbing of the scalp will blur or erase the markings before their presence can be utilized, and the elevation of the scalp flap will expose an unmarked surface beneath on which the seat of operation can not then be satisfactorily traced. The author has not infrequently driven through the scalp into the skull at the proper places short, sharp, headless steel brads, to indicate the site of operation. The scalp slips over them readily, and they are left standing firmly fixed in the skull. The final cleansing of the scalp, the placing of the antiseptic towels around the head, the arrangement of the assistants, instruments, etc., should be completed by the time the patient is properly anæsthetized, in order to avoid unnecessary delay, as promptness of action in these cases is an important element of success.

The Operation of Craniotomy for Cerebral Tumor.—*Make a skin flap of large size, horseshoe shape, with the base so formed and directed as to afford good drainage of the wound, proper vitality of the flap, and complete opportunity for the scrutiny and technique of the surgeon.*

The flap should be of sufficient size to permit the removal of an ample amount of the cranial bone without undue encroachment on the soft parts. The hæmorrhage attending the formation of the flap is profuse and persistent, owing to the great vascularity and peculiar structure of the scalp. While the loss of blood can be limited somewhat by elastic circular constriction and by acupressure, still it is controlled best by prompt digital and instrumental pressure. Serre-fines (Fig. 265, *o*), forcipressure, bulldog and T-shaped forceps are interchangeably employed for the arrest of hæmorrhage. In any event the bleeding points are controlled as fast as they appear, and are tied thereafter when it suits best the desire of the operator.

The periosteum covering the portions of bone to be removed is reflected by a crucial incision, and may thereafter be replaced or cut away according to the demands of proper drainage and closure of the wound. The desired amount of bone is removed by repeated applications of a large-sized trephine, supplemented by those of the rongeur or chisel. The forming and turning aside—with or without raising the superimposed soft parts—of a beveled-bordered \sqsubset -shaped bone flap with the saw, or of a Ψ -formed one in the manner devised by Hartley (Fig. 318), can be done if practicable. However, separation of the dura from the bone by means of a spatula (*i*) or dural separators (Fig. 290, *f, g*) should precede the use of the saw. Hæmorrhage from the bone is arrested by pressure with antiseptic gauze or sponge; by plugging

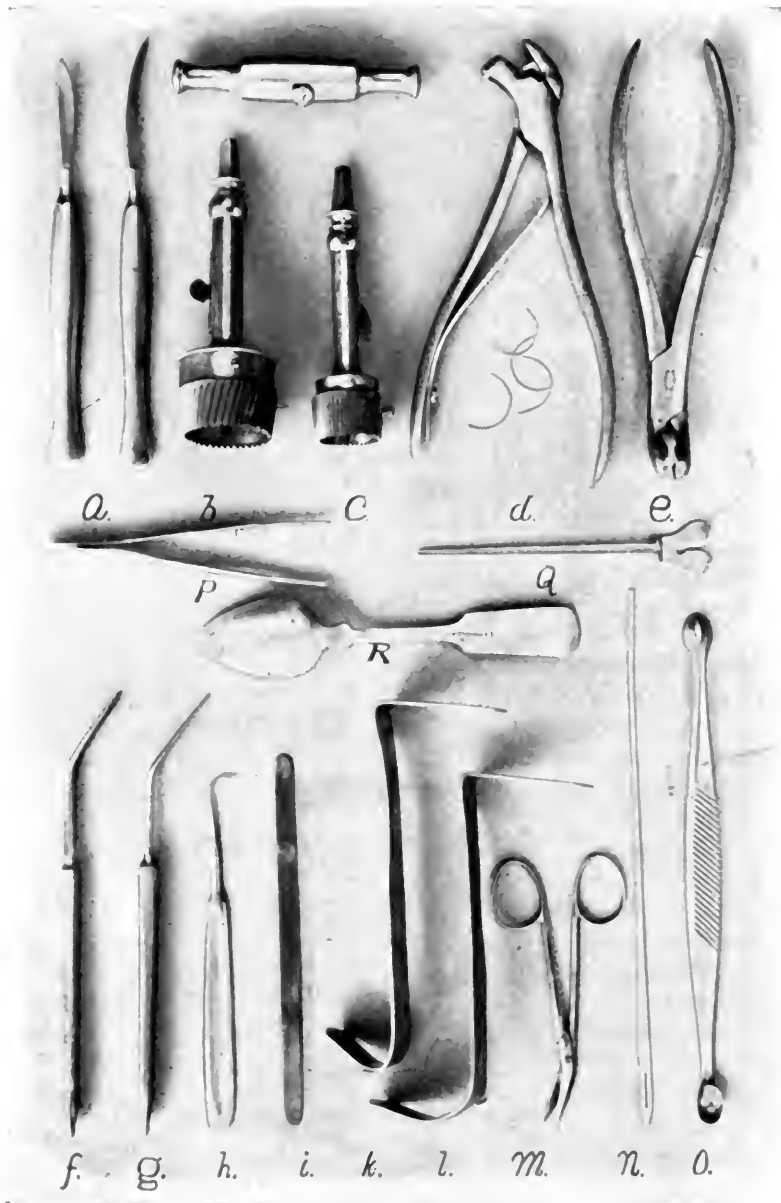


FIG. 290.—Instruments used in operations for brain tumor.

a. Scalpels. *b, c.* Large trephines. *d, e.* Bone-cutting forceps. *f, g.* Horsley's dural separators. *h.* Tenneulum. *i.* Flexible spatula. *k, l.* Flexible retractors. *m.* Curved probe-pointed scissors. *n.* Probe. *o.* Scoop. *P, Q.* Mouse-tooth forceps and grooved director. *R.* Silver teaspoon. Fine curved needles.

the bleeding point with catgut or a bit of aseptic wool; by means of actual cauterization, or by crushing together the tables of the skull with a strong forceps at the seat of hæmorrhage. The manner of division of

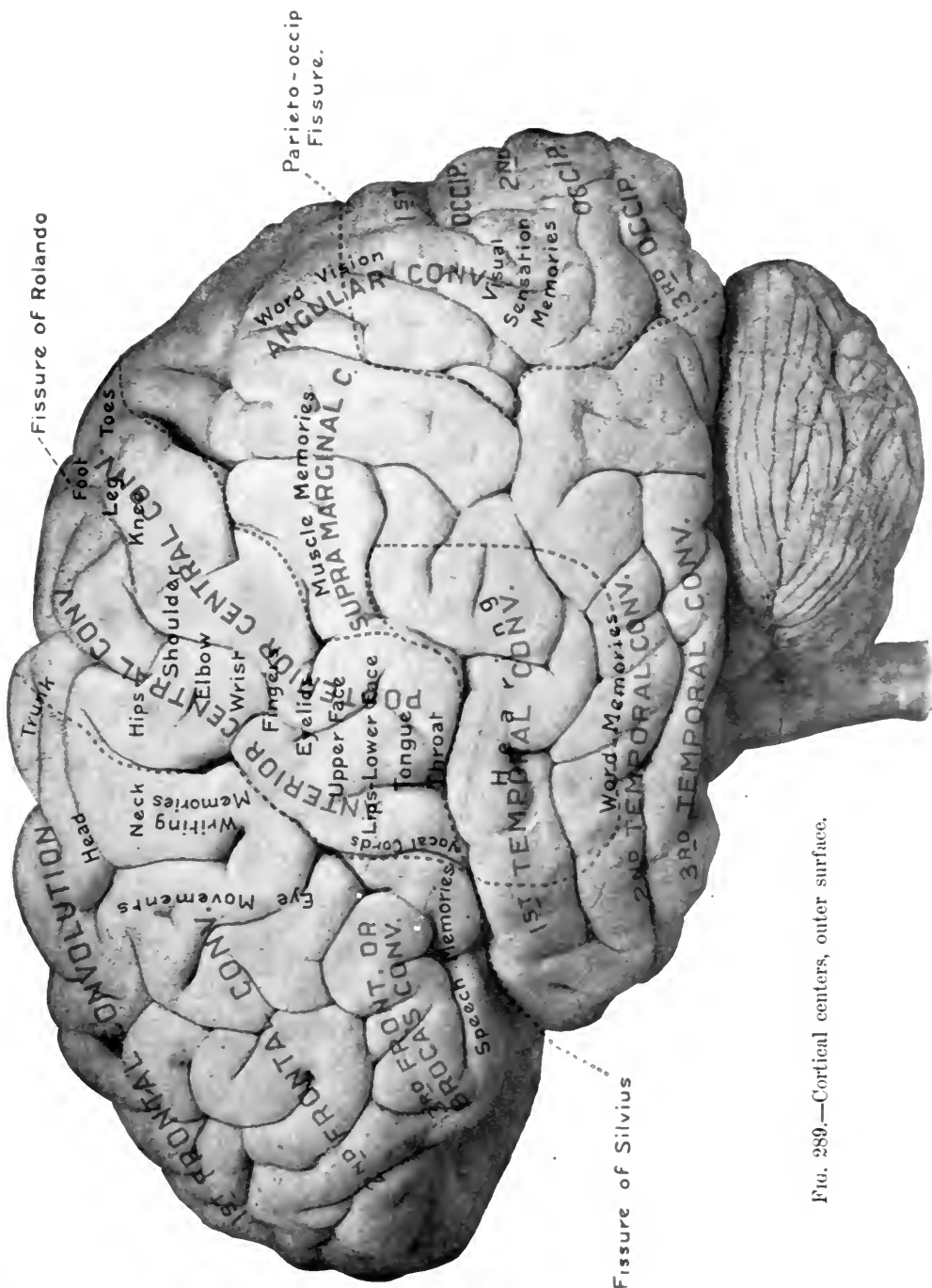


FIG. 289.—Cortical centers, outer surface.

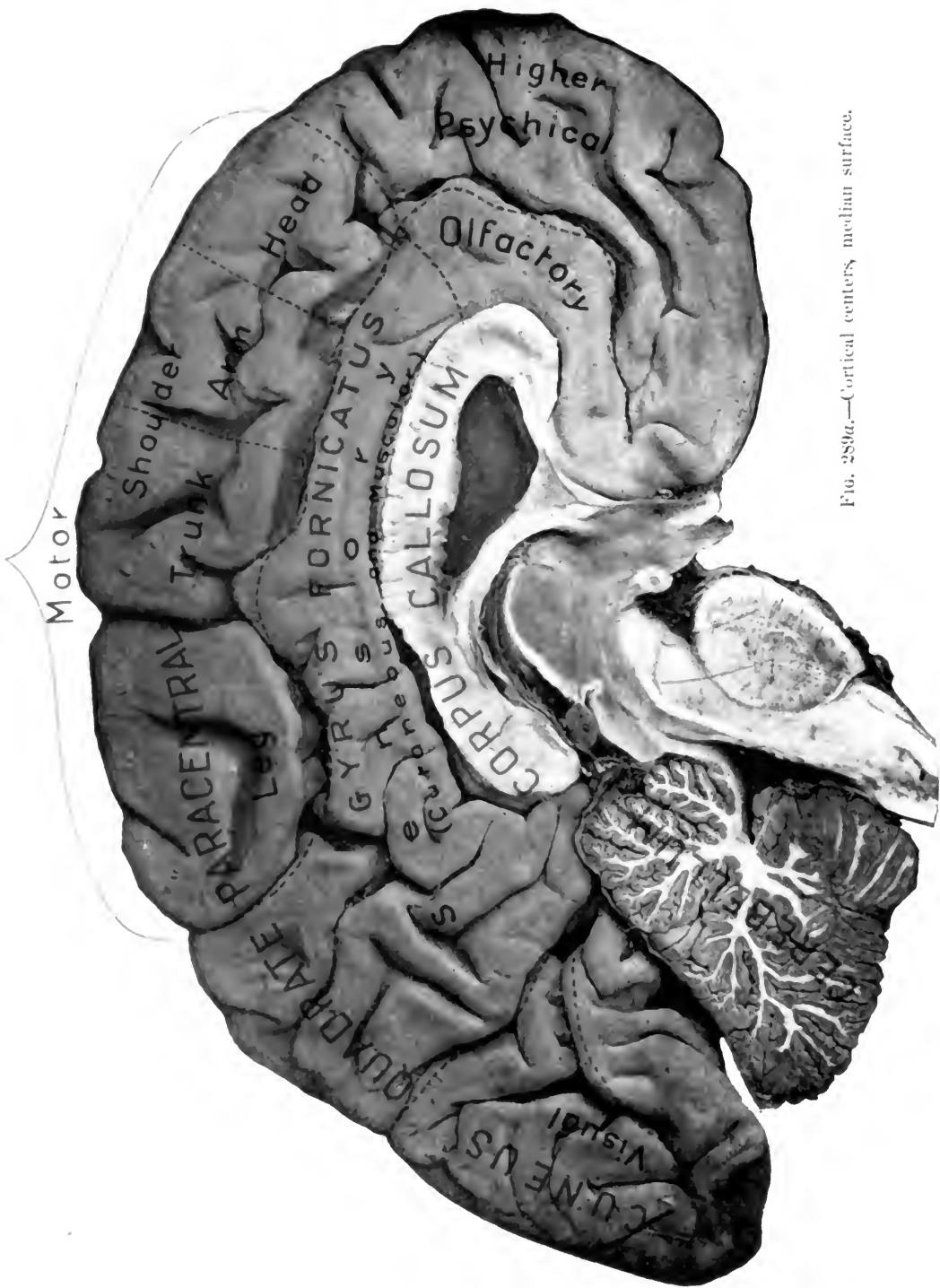


FIG. 289a.—Cortical centers, median surface.

the dura mater and the control of hæmorrhage are described elsewhere (page 241). Horsley's wax may be applied to the bleeding point (page 568).

Fashion and pull aside the dural flap and observe the cerebral characteristics. In making the flap insert a small tenaculum (Fig. 290, *h*) into the dura at the most dependent part—if consistent with the vascular integrity of the flap—about a quarter of an inch from the border of the bone. Raise the dura from off the brain and make a small incision through it with the point of a scalpel. Introduce through the opening the blade of a small, curved, blunt-pointed scissors (Fig. 290, *m*), and divide the membrane equally at either side of the tenaculum a quarter of an inch from the bone for four fifths of the entire circumference of the opening, if this amount of space be needed, and the nutrition of the flap be not imperiled. If the membranes be œdematous, congested, or adherent; if the brain bulge into the opening and its pulsations be feeble or absent, its structure unduly firm and the convolutions flattened, intracranial pressure is indicated and the morbid process will be in sight or near to hand. Further exploration of the brain can be made by puncturing it with a small probe, a hypodermic needle, or by free incision with a bistoury. Punctures and incisions of the brain should begin at the apex of a convolution and be continued in the direction of the commissural fibers, not dividing but separating them as much as possible, thus preserving their function. Exploration with needles and probes is often quite unnecessary, even useless, and perhaps dangerous. Unnecessary when the solidity of the tumor permits the finger to determine its presence; useless when the growth is so soft that touch can not detect its existence, and dangerous from the liability of the wounding of vessels, ganglionic centers, etc. Therefore the educated finger is the best means of exploration and can be safely introduced an inch or more beneath the skull and carried around the borders of the opening for this purpose.

The employment of the faradaic current by means of the electrode (Fig. 291) devised for the purpose of stimulating the motor centers with which it is brought in contact, to indicate the relations of the resultant movements to the seat of the disease, and also the degree of excitability of the diseased center, is a commendable practice.

These manifestations, while both interesting and instructive, bear no necessary association with an operation not directed to the removal of a motor center.

Divide the pia in the long axis of the tumor if possible and carefully draw it aside.

The hæmorrhage arising from a division of the pia can be reduced to a minimum by raising the membrane from the sulci and surface carefully and drawing it aside, or by ligature *en masse*. If drawn aside, it can be returned to the original site if circumstances will permit. *The treatment of the tumor depends on the environment, etc.* If the tumor be in view and encapsulated, it should be enucleated with the curved blunt-pointed



FIG. 291.—Keen's electrode.

scissors or a spatula, aided by the finger of the operator. If it be not encapsulated, it may be if desirable removed with a knife, sharp scoop, or a spoon (*o, R, Fig. 290*). If the tumor be located beneath the brain surface, a free incision is made down upon it and the wound borders held apart with retractors while the tumor is enucleated or cut away as before. The cavity in the brain caused by the removal of the tumor should be lightly packed with a single long narrow strip of iodoform gauze cleared of loose threads, and so placed at the bottom and sides of the cavity that it can be removed gradually or promptly without hindrance. A *cystic tumor* of the surface is dissected away when possible; if not advisable, the superficial portion is removed, the interior cauterized with nitrate of silver and packed with gauze; if beneath the surface of the brain, it is opened, cauterized, and packed as before; when of unusual size, of indefinite outline and association, it can be tapped, drained with horsehair or catgut, and lightly packed with long strips of gauze. Pure carbolic acid followed by alcohol is useful.

In all instances of packing, the gauze should be so introduced that it can be removed slowly and at intervals to avoid any undue disturbance of the brain. If packing of the wound be dispensed with, the dural opening should be closed with fine catgut, leaving an opening at the most dependent part through which horsehair, a strip of gauze, or of lightly rolled rubber tissue is introduced for drainage purposes. If the brain wound be packed with gauze, the sewing of the dura is limited to the proper accommodation of the protruding gauze and its subsequent withdrawal. The scalp, like the dura, is closed in conformity with the demands of drainage, silkworm gut being employed for the purpose in this instance. After a final cleansing, the wound is covered with rubber tissue, upon which is placed in turn layers of aseptic gauze, loose gauze, and aseptic cotton, all of which is held in position with antiseptic bandages.

Horsley and Macewen divide the operation into two stages to avoid the ill effects of the shock so often due to continuous effort. In the first stage the dura is exposed and the wound packed with gauze. In the second stage—some days later—the operation is completed.

The Precautions.—The strong tendency of brain matter to escape and to the development of hernia cerebri requires that the gray matter be disturbed as little as possible, that infection be prevented, and that the opening of the dura be promptly and securely closed. If the proper sewing of the membrane be opposed by brain pressure, it should be restrained if practicable by counter pressure with a single broad or two narrow spatulæ until the sewing is completed. If two narrow spatulæ be passed beneath the dura, while lying on each other, and separated, like the blades of scissors, the area of resistance will be correspondingly decreased; a manifest advantage is thus gained in aid of the complete closure of the membrane. If it be impracticable to close the gap in the dura with stitches, the advisability of restraining further escape by means of a thin celluloid plate placed in contact with the opening in the dura and so fitted to the divided borders of the skull as to prevent further protrusion, should be considered. If brain have escaped already beyond the opening in the skull further advance may be prevented

by the application to it of a closely fitting metallic cover confined in place with straps. The shaving off of the protruding brain should be regarded as an after and final step rather than as an early and unavoidable one, especially when the portions to be removed possess functional activity and have not yet been subjected to repressive influences. Not long since the author in a case of threatening protrusion following immediately the removal of a cicatrix from the brain and dura applied a thin celluloid plate at once to the lesion in the manner described (see page 256), with a successful outcome so far as the control of the tendency to protrusion was concerned. *If the electrode* (Fig. 291) *be used*, it is important to recall that, 1, a strong current burns the cortex, and that one of a strength to cause contraction of the thenar muscle is sufficient for the test; 2, that antiseptics, especially bichloride in solution, prevent electric reaction, and that sterilized water is the best agent for use at this time; 3, that not infrequently the reaction can be excited if the electrode be applied to the uncut dura, and that this fact is important as the brain substance is not then exposed; and, 4, that the electrode should be thoroughly aseptic when applied to the brain.

The Results.—The results of operation for brain tumor depend on the situation, the depth, the nature, and environment of the growth. Encapsulated, non-malignant, and superficial cerebral tumors are the most favorable for operation. Infiltrating tumors are of bad prognosis on account of the loss of brain and blood attending the removal, and the frequent and prompt return of the growth. Cystic growths offer a fair prognosis if they be excised, or be treated by caustic, or drainage and packing. The bare emptying of the cyst and closure of the wound is useless, as it rapidly refills. The prompt the operation the better the prognosis will be in all cases.

Total Results of Operation for Brain Tumor (Starr).

	Cere-bral.	Cere-bellar.	Total.
Total number of cases operated on.....	81	16	97
Cases in which tumor was found.....	26	9	35
Cases in which tumor was found but not removed.....	1	2	3
Cases in which tumor was removed and patient recovered.....	39	3	42
Cases in which tumor was removed and patient died.....	15	2	17

Somewhat later Starr reports two hundred and twenty similar operations, in seventy-three of which the tumors could not be found, and in seven could not be removed. The death rate for removal of the remaining one hundred and forty cases was + 34 per cent, which is no doubt much too small to represent the outcome of all cases operated on, as many indeed are not reported. McCosh believes that seventy-five per cent is much nearer the true figure.

Craniotomy for Cerebellar Tumor.—Owing to the difficulty of diagnosing the exact situation of a cerebellar tumor, a surgical operation for the patient's relief is largely of an exploratory character. The differences in the technique of this and the operations for cerebral tumor consist in the

formation of the flap and the entrance to the cranial cavity. In other respects their technique is substantially similar. *The flap of the soft parts* is limited above by the upper border of the superior curved line of the occipital bone, below it terminates opposite the second cervical vertebra, the median line of the head limits the inner border, and the posterior margin of the mastoid process the outer. It is horseshoe shaped, and the incision forming it is carried down to the bone. The flap is reflected, the periosteum remaining undisturbed except at the area of entrance to the cranium; here the membrane is turned aside before division of the skull is made. *The opening through the skull* is formed with a chisel and mallet, is about two inches in diameter, and may be increased thereafter by a rongeur (*d, e*, Fig. 290) as circumstances demand. On account of the thinness of the bone at this situation the surgeon must exercise great care. The dura is divided, the cerebellum explored with the finger or aspirator, etc., and the tumor manipulated as in cerebral cases. The deep soft parts are united with catgut independently of the main flap, which is sewed with silkworm gut after necessary drainage is provided. The usual antiseptic dressings are bound in place with gauze bandages.

The Precautions.—As before remarked, the bone at the site of operation is very thin and devoid of diploëic structure, hence thoughtless use of force is likely to injure the soft parts beneath. The lateral (*A, B*, Fig. 292) and occipital sinuses may be invaded if the crest and superior curved lines be encroached upon in opening the skull. Care must be taken not to disturb the middle lobe of the cerebellum, unless the removal of the tumor requires that it be done. (Frazer, N. Y. and Phil. Med. Jour., Feb. 11–18, 1905.)

The Results.—The results of the operation for the removal of these growths are registered already under the preceding topic.

Craniotomy for Epilepsy.—When the motor center primarily involved in the epileptic convulsion can be determined, or when the disease has been preceded by a head injury that is manifest, craniotomy is often performed, and usually with a large-sized trephine. The electrode plays an important part in these cases, as it often serves to locate the center primarily affected. The technique of the use of the trephine and of the removal from the brain and its membranes of a morbid exciting cause has already been sufficiently discussed. The scalp flap should be large enough to afford a broad margin between its borders and those of the bone opening, in order that the healing of each may be entirely independent of the other. Primary union of the entire wound should be sought for as the cicatrization following delayed union may become a provoking element in the production of convulsions thereafter. The introducing into the cranial opening and placing on the freshened surface, of a metallic substance, of gutta-percha, or of rubber tissue, celluloid, decalcified bone plate, etc., for the purpose of preventing or limiting cicatricial action, is advised in those cases where the irritation is thought to have arisen from the influence of previous cicatricial contraction.

In the opinion of the author, the stable qualities of thin celluloid plate ($\frac{1}{16}$ inch) establish its worth for this purpose above that of other foreign substances of a simple nature. Harris commends highly silver foil.

Gold-leaf, gutta-percha, and rubber tissues are placed in contact with the pia, the edges underlying somewhat those of the cranial opening, to prevent extending cicatrization. These substances, however, are not trustworthy, as they often become disarranged and disintegrated by the vital influences to which they are subjected. A reliable substance for this purpose is a great desideratum.

If, after the removal of the bone, a small cut be made through the dura and a silver probe properly curved be passed through the opening and beneath it, and swept around, the near-to-hand adhesions can often be determined. The removal from the brain of a cicatrix or motor center for relief from epilepsy is rarely followed by cure, since the repair of the wound produces a cicatrix which, later, usually causes the convulsions to recur.

The Remarks.—No patient should be operated on unless the attacks have been scrutinized as to the part first affected and the order of advance of the convulsion by one competent to make the observations. The statements of relative and of sympathetic and ignorant observers can not be relied on in these cases. *A motor center is removed cautiously* in the direction of the fibers (page 253) with knife or scissors, and the removal should be complete, or the attempt at cure will be useless. If the condition of the membrane will permit, the pia should be raised up and pushed aside, rather than torn or cut; thus hæmorrhage will be lessened, and then, if advisable, the membrane can be replaced. The bleeding from large vessels of the pia can be controlled if the vessels be tied independently in two situations with fine catgut ligatures passed around them by the aid of a needle, and cut between the points of tying.

The Results.—The procedure itself is not devoid of danger by any means, and the results of operations for the Jacksonian, focal, and long-standing traumatic varieties of this disease are almost invariably followed by grievous disappointment. It is difficult, indeed, to say as yet whether the removal of a motor center of the brain for the cure of epilepsy is justified by any other fact than that of the sad hopelessness of the case. Operation for traumatic epilepsy offers better results than in other forms, especially if performed before the development of the convulsion habit that too often complicates the cases of long standing. As a whole, the results from operative procedures in the latter variety of cases may be regarded as quite satisfactory. However, those reports announcing a cure of fifty per cent should be accepted with great reserve, as much time should elapse before the final estimate of a case is made.

Craniotomy for the Evacuation of Pus.—A knowledge of the presence and situation of abscess following injury of the cranium is based on the facts of the location of the injury, the local and constitutional symptoms of inflammation and suppuration, and the later development of the symptoms of cerebral compression. The proper site for operation in traumatic abscess is over the area of cerebral compression irrespective of the seat of the injury. If hemianopsia be the first symptom to occur, the trephine should be applied over the occipital lobe involved in the morbid manifestation. *If the pus be between the dura and cranium*, the removal of a button of bone affords a prompt discharge of the fluid and relief to the

patient unless pyæmia complicates the recovery. The pus cavity should be thoroughly flushed with a five-per-cent solution of carbolic acid, loosely packed with iodoform gauze, and covered with a moist antiseptic dressing. *If the pus be not found at this situation*, raise a flap of dura and explore the brain with an aspirator, passing the needle in various directions until pus is found, being careful to withdraw the needle and insert it at a different point each time the direction is changed. If pus be found deep in the brain, the needle should be left in position as a guide to the purulent collection. If the pus be superficially located, the needle is withdrawn. Before evacuation of the pus the diploëic structure should be protected from the danger of infection by smearing it with a compound of glycerin and iodoform or some other antiseptic mixture. The pus is then liberated directly or by careful separation of the brain along the course of the needle with a grooved director or dressing forceps. The liberation of the pus is quickly followed by the introduction into the abscess cavity of a double-barreled drainage agent formed by placing two small soft drainage tubes parallel with each other and fastening them together. The cavity can then be quickly washed out through one tube by pouring through the other a gentle stream of warm sterilized water or a boric-acid solution. The tubes are fastened in position with a large safety pin to prevent their further entrance into the cavity. The wound is then packed loosely a little beyond and around the tubes with iodoform gauze, the whole covered lightly with antiseptic gauze and confined in place with gauze bandages. If the discharge be free, at the next dressing one tube can be removed and the other shortened if necessary. The wound is dressed once or twice daily to insure free drainage, the remaining tube being shortened from time to time to keep pace with the closure of the cavity. Two or three weeks are sometimes required to effect this process. The opening in the dura and the scalp should be closed as soon as possible to avoid the formation of hernia cerebri.

Cerebral abscess is usually a sequel of otitis media and of suppurative processes of the orbital and nasal cavities. About half of all cases of cerebral abscess of either the acute or chronic form are due to otitis media. Abscess also develops in the cerebellum as the result of this disease. The comparative rate of occurrence is about four in the temporo-sphenoidal lobe of the cerebrum to one in the cerebellum, and much more often at the right than the left side of the cerebrum. Rarely do they appear in the pons and crura cerebri. Abscess from this cause often develops insidiously, and the diagnosis is frequently obscure and delayed. Cerebral abscess may be confounded at first with sinus thrombosis or meningitis, either of which is as frequent a sequel of otitis media as is abscess.

The Operation for Cerebral Abscess.—Shave and scrub the scalp; draw Reid's base line; indicate on the scalp a point located an inch and a quarter above and the same distance behind the center of the meatus. At this point, according to Barker, a space three quarters of an inch in diameter corresponds to the location of nine tenths of the abscesses of the temporo-sphenoidal lobe. Birmingham adds half an inch to the perpendicular line to avoid more certainly the lateral sinus (Fig. 292). The technique is simi-

lar here to that for abscess elsewhere in the brain, until after the button is removed. Then place the finger lightly on the dura. If pulsation be absent or feeble, the presence of abscess is indicated, especially in the absence of a depressed circulation. Open the dura sufficiently to expose the brain surface, and if pus be not seen introduce a good-sized aspirating needle inward, forward, and downward toward the apex of the petrous bone, about two inches. The pus in these cases is usually too thick to pass through other than a fair-

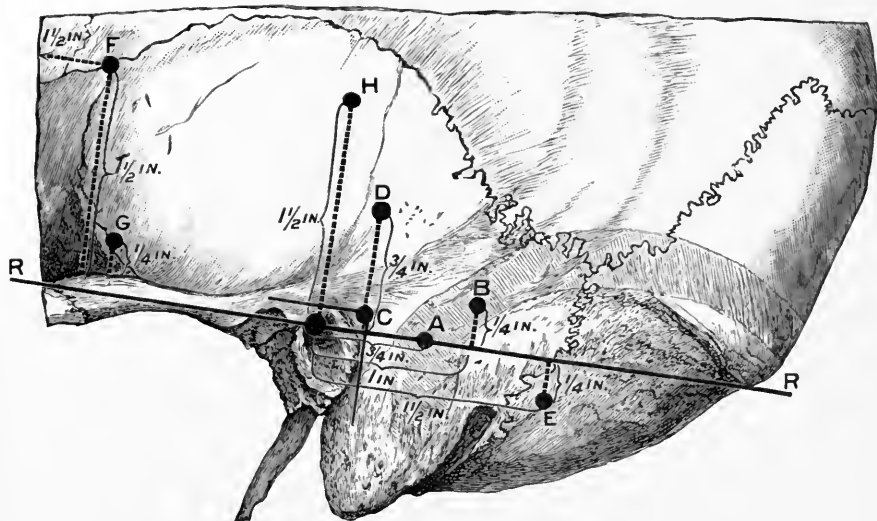


FIG. 292.—Diagram of adult skull, illustrating various points for craniotomy.

Horizontal measurements are made from the centers of the auditory meatus along Reid's base line, *R R*. Vertical measurements meet this line at a right angle. *A*. Sigmoid portion of lateral sinus, a point on the base line three quarters of an inch from the center of the meatus. *B*. Transverse portion of the sinus, a point an inch behind the meatus and a quarter of an inch above the base line. *C*. Mastoid antrum, the point of meeting of a line drawn along the upper wall of the meatus parallel with the base line, and one drawn at the posterior wall at right angles with the base line. *D*. A point for cerebral abscess (temporo-sphenoidal), three quarters of an inch above the base line at posterior border of meatus. *E*. A point for cerebellar abscess, an inch and a half behind the meatus and a quarter of an inch below the base line. *F*. A point for anterior branch of middle meningeal, at an inch and a half behind external angular process of frontal bone and the same distance above zygoma. *G*. A point for posterior branch of middle meningeal, one inch and three quarters behind external angular process and a quarter of an inch above zygoma. *H*. A point for tapping the lateral ventricle, an inch and a half above center of meatus.

NOTE.—It will be noted that some of the measurements indicated above vary considerably from those of the text, but inasmuch as all are the outcome of extended experience and observation of competent men, it is difficult indeed, even if wise, to express a decided preference. If either prove unsatisfactory, another should be tried, using the trephine again, or extending the primary opening with the rongeur. The illustration (Fig. 292) can be utilized for other measurements than those stated in the description, and with equal facility and exactness.

sized needle; for this reason the use of ordinary hypodermatic needles should be discouraged. Failing to find pus with the first insertion, the effort is repeated in different directions as described on the preceding page. If pus be not found thus, the presumption should be that it is not present. However,

if the evidence of intracranial pressure, as indicated by flattened convolutions, congested vessels, marked protrusion of the brain into the opening, modified pulsation, etc., be noted, a needle of larger caliber should be introduced ere the procedure is relinquished. If pus be found, the manner of evacuating, draining, and the subsequent treatment of the abscess and wound are the same as already described. The fact that these abscesses are due to direct infection and contain foul and offensive pus should stimulate attention in the highest degree to antiseptic care. Frequent washing out of the abscess cavity with Thiersch's fluid is required for some time if the offensive discharge continues.

The anterior surface of the petrous portion of the temporal bone, roof of the tympanum, and the petro-squamous fissure can be examined for abscess through a half-inch opening located directly above the external meatus seven eighths of an inch. Through this opening the entire anterior surface of the petrous bone can be explored by passing a small probe cautiously along between the dura and the bone. If pus be found, it should be liberated and the pus cavity thoroughly drained. If necrosed bone is present, it should be removed if loose; if not, thorough drainage and cleanliness should be established until the diseased bone comes away or is removed, after which the wound is treated in the manner usual in cases of this nature.

The Precautions.—If the needle be inserted too far, the basal ganglia may be injured; if misdirected and carried too far, the petrosal sinuses may be entered. The use of a needle of small caliber is unresponsive and therefore undecisive and deceptive. However, if the aspiration be negative, the examination of the contents of the lumen of the needle with a microscope may disclose the presence of pus. A small opening only should be made in the dura before the detection of pus, for if pus be not found, the opening can be easily closed. The oval flap of the dura should be made after pus is found and in the manner before described (page 253). Great cleanliness and care are necessary to prevent secondary meningitis from purulent contact.

Cerebellar abscess from otitis media can be reached through a half-inch opening in the cranium made either at a point an inch and a half behind and a quarter of an inch below the center of the meatus (Fig. 292, E), or two inches behind and an inch below this opening (Birmingham), to avoid the occipital artery. At the former place the anterior border of the trephine rests directly behind the posterior border of the mastoid foramen. An escape of pus from the mastoid foramen, due to lateral sinus involvement, should be looked for at the time, since a diseased sinus may be mistaken for a cerebellar abscess.

The Results.—The insidious development, the late recognition, and the persistency of the exciting cause in abscess of the brain invest the outcome with a somber hue. The death rate from all causes after operation is forty per cent. The rate from abscess due to middle-ear disease alone is much greater than this.

Craniotomy for Thrombosis of Lateral Sinus and Jugular Vein.—The operative measures for this condition are the recent outcome of increased diagnostic acumen and of improved surgical technique. The thrombosis is

a sequel of otitis media, and it happens quite as frequently as does abscess of the brain. Inasmuch as these cases terminate fatally if unaided, operative measures should be prompt and decisive.

The Operation.—In the presence of rigid antiseptic technique, carefully expose the lateral sinus through a trephine opening, three quarters of an inch in diameter, the center of which is located a quarter of an inch above and an inch behind the middle of the bony meatus (Fig. 292, B). This opening can be extended as circumstances require by aid of the rongeur. An extension forward (A, C) is advised, so as to open the sigmoid portion of the sinus and the mastoid antrum to permit removal of diseased tissues. Examine the sinus with the finger and explore it with a hypodermic syringe also, if any doubt exists as to a thrombotic condition of the vessel. If thrombosed, it is advised by some to expose the internal jugular vein in the neck and ligature it, to prevent the escape into the circulation of loosened clots from the sinus. It is possible, however, for the disease to extend inward through the upper tributaries of the vein, in spite of every preventive effort. Then open the sinus and remove the thrombi with a small scoop aided by antiseptic douching. If severe hæmorrhage occurs, plug the bleeding point instantaneously with a strip of iodoform gauze already prepared for the purpose. If hæmorrhage from the sinus is feared on account of incomplete closure with thrombi, ligature the sinus before opening it. If feasible, the clots are removed from the vein and sinus and the lumen is cleansed by a through-and-through stream of antiseptic fluid. If the thrombi can not be safely removed, the wounds are then drained with small rubber tubes and packed with iodoform gauze. They should be cleansed and dressed frequently during the course of treatment, especially if thrombi still remain in the vessels. Excision of trunk so as to include its branches is practiced.

The Precautions.—If severe hæmorrhage occurs from the sinus, apply a tampon to the bleeding point and allow it to remain for two or three days until further bleeding is obviated. Be careful not to shut into a sinus or vein any of the thrombosed contents by tying through a diseased point. In the removal of the central thrombus, cleanse thoroughly the parts as the clot is removed, so that the stopping of a sudden gush of blood with the tamponade will not push inward loose infecting agents, nor will the previous site of an infected clot provoke infection of one newly formed. If the central clot be firm and inoffensive, presenting no evidence of disintegration, the question of the wisdom of its removal may properly arise, and it should be decided by the other circumstances that attend the case.

The Results.—About fifty per cent of cases recover with operation; without it a recovery need not be expected.

Craniotomy for General Paralysis of the Insane.—The trephine has been applied to the parietal region and at the seat of defined headache in a few instances with and without opening the dura for drainage purposes to afford relief in this condition. Tapping the ventricles has been practiced also, but little encouragement has resulted from either method of practice.

Opening the Mastoid Antrum.—The mastoid antrum is opened to relieve it of inflammatory products that enter from an inflamed middle ear or result from inflammation of the antrum and mastoid cells themselves.

The Important Facts.—In the infant, the mastoid process is not present, but the mastoid antrum is, and in the form of a cell communicating with the middle ear. Later the mastoid process appears and the antrum becomes more deeply placed, until at the age of ten when the outer wall is about two fifths of an inch in thickness. At puberty numerous other cells are




FIG. 293.—Instruments employed in operation on the mastoid antrum.

a. Scalpels. *b.* Bone-drill. *c.* Periosteal elevator. *d.* Small trephine. *e.* Forcipressure. *f.* Thumb forceps. *g.* Long-nosed rongeur. *h.* Small scoop. *i, j, k.* Bone chisels. *l.* Mallet. *m.* Scissors. *n.* Fine probe. *o.* Long curved neck rongeur. *p.* Common rongeur. *q.* Gimlet. *r.* Retractors. *s.* Needles.

present in the process. In the adult the area of cell development is limited below by the masto-occipital suture; anteriorly it extends above the meatus, and superiorly to within half an inch of the temporo-parietal suture. At this time the antrum is the size of a pea and is separated from the cranial cavity by a wall one twenty-fifth to six twenty-fifths of an inch in thickness, and from the lateral sinus and the external surface of the mastoid process by walls one half to three quarters of an inch in thickness. It now corresponds to a point immediately behind the meatus and below the level of its upper border. The lateral sinus varies somewhat in its relations with the mastoid bone (Fig. 292). It approaches to within one inch and a half behind and three quarters of an inch above the center of the bony meatus, then turns more or less abruptly downward and passes one half inch behind the

external meatus, and runs to a point one sixth to one quarter of an inch below the floor of this opening before reaching the base of the skull.

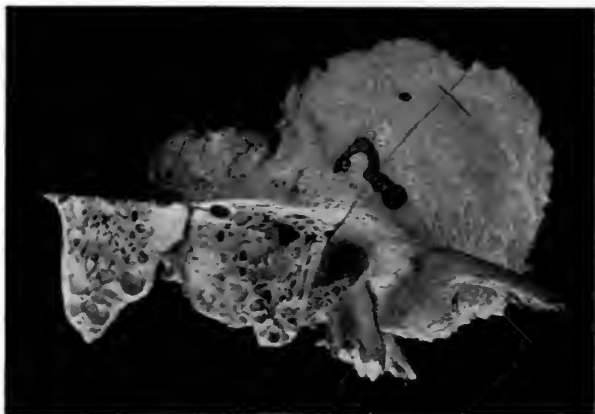

FIG. 294.—Transverse section of mastoid process showing the cells, the upper largest one being the *mastoid antrum*. Note its relation to the external auditory meatus. The upper and outer sharp point of the reflected bone flap is a portion of the meatal spine.

The *supra-meatal spine* placed at the upper margin of the bony meatus is found in 82 per cent of young and 87 per cent of adult subjects. This

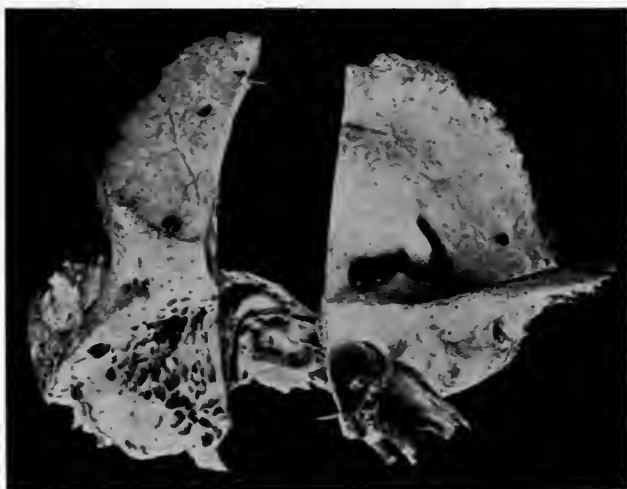


FIG. 295.—Reflected portion of mastoid cells removed, showing mastoid antrum above communicating with attic, seen through the window caused by separation of the halves of bone. Note the thinness of the bony roof of the attic, the Fallopian canal, external auditory walls, and the relations of the important intracranial parts to those without.

spine is an important guide to the upper margin of the bony meatus (Fig. 294), to the mastoid antrum, and to the lower limits of the middle cerebral

fossa. The upper limit of the bony meatus corresponds to the spine (Fig. 294); the lower limit of the middle fossa is a trifle more than a quarter of an inch above it; the mastoid antrum is located half an inch posteriorly and

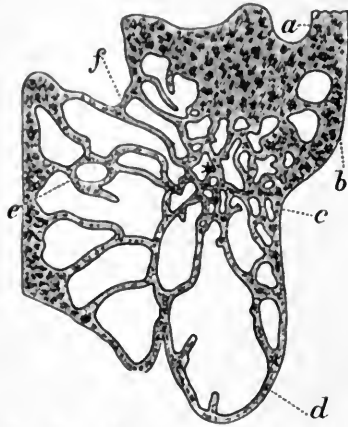


FIG. 296.—A vertical section of mastoid process made at right angles with the auditory canal. * The mastoid antrum. *a*. The squamous bone. *b*. The zygoma. *c*. The posterior border of the external auditory meatus. *e*. A vein. *f*. The sigmoid fossa.

about two fifths of an inch below the surface of the bone at that point (Fig. 294). If the fingers be thrust into the external meatus and pressed upward and backward, the supra-meatal spine can usually be felt (Fig. 295). The mastoid cells vary in size and shape in different subjects, and are arranged in a radiating manner with the mastoid antrum (Fig. 296). From a surgical point of view, the sigmoid fossa (Fig. 296), the dura, and brain of the middle cerebral (Fig. 296) and the cerebellar fossæ, and the facial nerves are of special significance on account of their liability to injury during operative practice, and in this condition it is wise to note at the outset that the common variations of their relations to the mastoid antrum and the varying thickness of its bony partitions require for their protection an exercise of the greatest caution in all instances (Fig. 295). “Operating in each as though the most dangerous exceptions were present, at least until the contrary is proven” (Hartmann).

instances (Fig. 295). “Operating in each as though the most dangerous exceptions were present, at least until the contrary is proven” (Hartmann).

The Operation.—Shave and cleanse the external surface much beyond the seat of operation, also cleanse and tampon with antiseptic gauze the external ear; wrap the head in a towel saturated with an antiseptic solution; pull the auricle forward and make a curved incision down to the bone, just behind the auricle, from its upper border to the tip of the mastoid process; push aside the periosteum with an elevator (Fig. 293, *c*), exposing the entire bony surface; carefully examine it to disclose a carious point or fistulous opening, which, when noted, is enlarged by means of gonges and (Fig. 293, *i, j, k, l*) mallet and the diseased bone is carefully removed with small sharp spoons (Fig. 293, *h*) aiming to reach the antrum. If no external disease is manifest, open the antrum directly with a chisel, a small trephine (Fig. 293, *i, d, q*), or a small gimlet (Treves), removing in advance the overlying bone in the last instance, and, in all, remove with a sharp spoon, in a line parallel with the external auditory meatus, the contents and diseased cellular structure contiguous to the antrum, forming a cone-shaped cavity extending inward and slightly upward, not more than three quarters of an inch wide in adult cases, and communicating with the attic. Examine and remove from the middle and lower parts of the process any diseased tissue in a similar manner; irrigate the entire field with an antiseptic solution, passing it in through the external

meatus, if the condition of the tympanic membrane will permit. A perception of diminished resistance, and the appearance of pus on the withdrawal of the instrument, indicate the attainment of the object. The cavity is then drained and dressed with iodoform gauze, supplemented with dry antiseptic gauze and bandages. The dressing should be changed often, that the wound may be properly cleansed.

The Precautions.—If the incision of the soft parts be carried too far upward, the posterior auricular artery will be severed. If the penetration of the bone be not made parallel with the long axis of the auditory canal, either the lateral sinus, the external ear, or the cranial cavity may be entered with the instrument. The depth of the penetration and the penetrating force employed must be carefully estimated, otherwise the cranial cavity will be entered and infective meningitis will follow. The use of the trephine devised for this purpose should be limited to adults, owing to the small size of the petrous bone in infants and children. Gouges and drills are inferior to the gimlet for this purpose, as the latter may be used slowly and deliberately while the force necessary to drive the former is estimated with some difficulty. If the index finger be placed along the side of the instrument, or it be grasped firmly with the disengaged hand, the advance of the instrument will be properly controlled. The great desiderata are to remove all of the dead bone, and to thoroughly cleanse and drain the wound, especially through the external meatus. A strong light, preferably electric, should be at hand during the operation. The frequent introduction of a silver probe (Fig. 293, *n*) to note the extent, direction, and compactness of the limitations of the field of operation should be made during the procedure. The layer of bone intervening between the sigmoid sinus and the brain fossa has a blue look as one approaches these cavities, acting as a signal to arrest incautious manipulations. Painstaking effort should be exercised in the removal of all cancellous tissue, since it may harbor infecting products and cause delay to the recovery. The cavity of the external ear should be cleansed and tamponed with gauze at each dressing of the wound, to maintain proper cleanliness.

The Results.—The results are favorable if the operation be done with sufficient promptness to anticipate the development of the important sequels. The operation itself, when cautiously performed, is devoid of danger.

Trephining the Frontal Sinus.—Trephining the frontal sinus is practiced for the removal of foreign bodies, necrosed bone, etc., from this cavity. The frontal sinuses are absent in the infant, rudimentary in children, and have no surgical significance until after puberty. They differ much in size and extent in adults, and sometimes communicate with each other at the median line.

The Operation.—Cleanse and shave the surface; make a vertical incision down to the bone, an inch and a half in length, from the root of the nose upward or one transversely outward so that the eyebrow will hide the cicatrix (Fig. 308); push aside the periosteum at the point of attack; open the sinus with a small trephine or sharp gouge applied to the anterior wall; cleanse the cavity with Thiersch's fluid, remove foreign bodies, diseased products,

etc. If the infundibulum be closed or constricted, open it with a bougie. Drainage can be made through this canal into the nose or through the external wound, and perhaps through both, according to circumstances. The external wound is treated in the usual way.

The Precautions.—Strong antiseptic fluids should not be employed here, neither should the unrestrained escape of inflammatory products be permitted, on account of the proximity of the eyes.

Gunshot Wounds of the Cranium.—Much change has taken place in the treatment of this form of injury since the advent of antiseptic surgery and the localization of brain centers. The consecutive steps of treatment divide themselves quite naturally into, 1, the aseptic technique; 2, the arrest of hæmorrhage; 3, the enlargement of the opening and the elevation of depressed fragments of bone; 4, the removal of foreign bodies from the wound; 5, the establishment of good drainage; 6, the control of inflammation.

The antiseptic technique should be rigid throughout in all respects and in each detail. The scalp is shaven, and thoroughly scrubbed and cleansed, and the face, neck, ears, and auditory meatus made thoroughly clean, and the latter plugged with iodoform gauze. The surgeon and the entire outfit are antiseptically prepared.

Hæmorrhage from the scalp, skull, and membranes of the brain are controlled as already indicated (pages 236 and 241). Hæmorrhage from a sinus, if accessible, can be arrested promptly by an antiseptic tampon and thereafter the wound in the sinus can be closed by sewing or tying the opening, or by continued tamponing, as the character of the injury suggests. Hæmorrhage from the brain substance will likely have stopped before the patient is seen by the surgeon. Hæmorrhage from the wound track in the brain is difficult, indeed, to arrest, especially if it be severe. In fact, ligature of the carotid of the same side is advised by some in obstinate cases. The careful introduction along the track of the wound to the bottom by means of a probe of a long, thin, infolded strip of iodoform gauze serves not only to arrest the hæmorrhage in the great majority of cases, but also acts as a drainage agent at the same time, which is a matter of great importance, especially if the wound requires tamponing before being cleansed. However, as soon as the patient's condition permits, steps should be taken to measure the surgical aspects of the case.

The Operation.—Chloroform anæsthesia is advised if the patient be not already unconscious or at least insensible to manipulative procedures. Place the patient in a good light; make a liberal-sized, oval scalp flap, leaving the pericranium in place; with the rongeur increase the size of the cranial opening sufficiently to permit the arrest of the bleeding points of the bone and membranes of the brain; also, to permit of a suitable examination of the extent of the injury. All depressed and loose fragments of bone and foreign bodies that appear on the surface of the brain and at the wound are removed, except when the depressed bone can be properly restored.

The foreign bodies found within the brain are the bullets, fragments of

bone, and perhaps hair and textile fabrics. *The bullet must be located before it is removed.* Probes and the X-rays are employed for this purpose. The probe should be light, about a quarter of an inch in diameter at the advancing end, and when used carried along the track of the ball with a degree of gentleness and care that will lead to a prompt appreciation of a change



FIG. 297.—Fluhrer's probe.

in the course or the presence of increased opposition to the passage. *Ruth* has determined that a probe a quarter of an inch in diameter is caused to penetrate normal brain tissue by a pressure equaling two and a half to three ounces. Of course a smaller end lessens proportionally the amount of pressure required for penetration. The probe devised by Fluhrer, composed of aluminium (Fig. 297), and the one devised by Girdner, known as the telephone probe, are as yet by far the best for the purpose. Fluhrer's probe is so light and blunt that its passage along the wound can do no harm, and, too, it can be manipulated with a delicate, unweighted touch. Girdner's

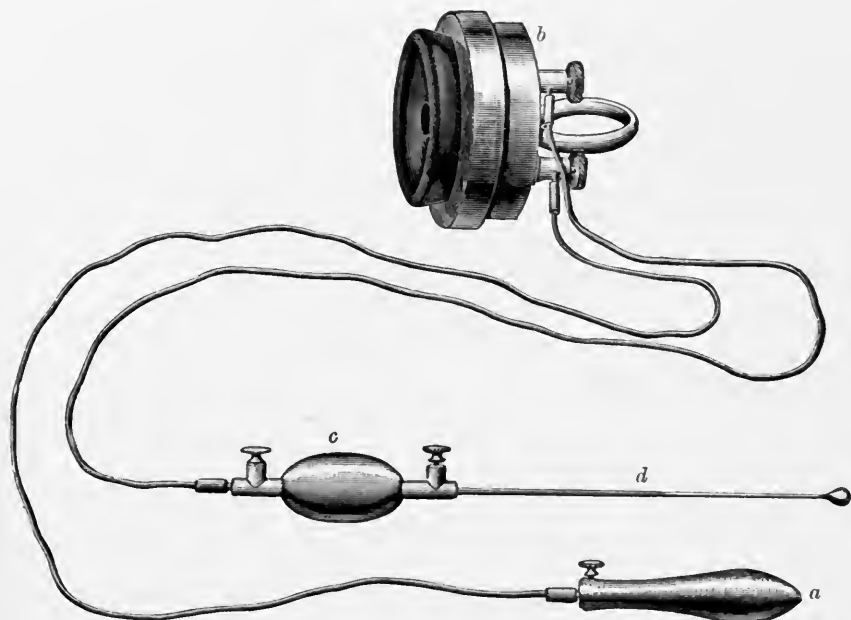


FIG. 298.—Girdner's electric probe.

telephone probe is already so well known as not to require a detailed description (Fig. 298). The author is indebted to Dr. Girdner for the following brief statement of the use of his probe: "Place the metal bulb (*a*) in the patient's buccal cavity between the teeth and check. Hold the receiver (*b*) to the (your) left ear with the left hand. Take the probe

handle (*c*) in the right hand and explore the wound for the bullet or other metallic substance. No sound will be heard in the receiver when the probe (*d*) touches soft tissues or bone, but the slightest contact of the probe with a metallic body produces a sharp clicking, grating, or rustling sound in the




FIG. 299.—Bullet forceps.

receiver. *No battery of any kind is used.* The current which operates the instrument is derived from the body of the patient; in

other words, each patient supplies from his own body the current necessary to locate the missile it contains." Not only will this instrument indicate the site of the bullet, but it will locate also the lead fragments that are shed by it along its passage through bone, a fact that may mislead the surgeon, unless the probe with the insulated stem be used. This instrument finds its most significant use in locating missiles in the brain, since it responds to the most delicate touch of a metal substance. *If the bullet be located,* the question of removal through the point of entrance, through a counter-opening, or leaving it alone must be considered. If it be in the opposite hemisphere of the brain,

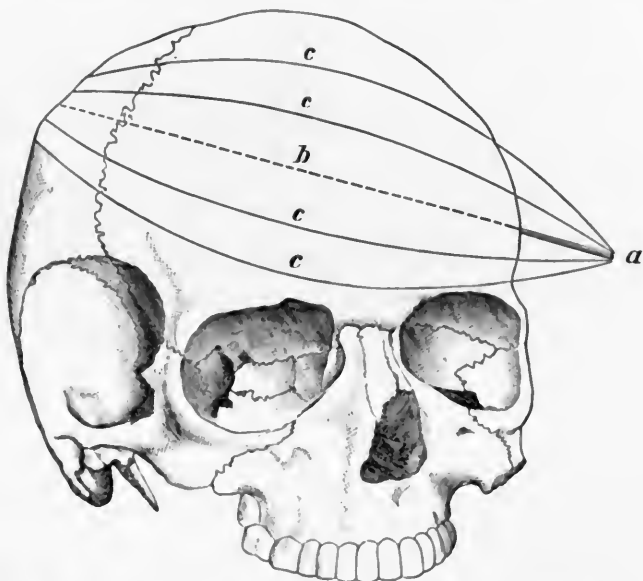


FIG. 300.—Author's method of locating site of counter-opening.

and can be reached with forceps (Fig. 299), carefully introduced, grasped and withdrawn without force, well and good. However, it is better practice, in my judgment, to make a counter-opening promptly, remove the missile and establish good drainage, than to encounter the dangers of prolonged and uncertain effort that too often attend attempts of direct approach and re-

moval. *If the missile have gone through the head*, good drainage can then be easily established. This is accomplished by passing the Fluhrer probe carefully along the track of the wound, and out through the opposite opening, attaching a thread to the end, withdrawing the probe, and leaving the thread in the track of the wound, by aid of which a No. 9 or 10 French fenestrated catheter, thoroughly disinfected, is drawn into the wound and left for drainage purposes. *If a bullet can be approached safely through a counter-opening*, the proper site for this opening can be found by pushing a long probe past the bullet through the brain to the skull (Fig. 300, *a, b*). Now, if a string be attached to the outer end of the probe, and be carried across the head at various points (Fig. 300 *c, c, c, c*), while placed each time in a direct line with the protruding portion of the probe, it is manifest that the point of crossing of these lines will correspond to the point of impingement on the skull of the intracranial end of the probe, at which point the opening should be made (Fig. 301, *d*). The end of the probe is then carried through the opening, and the bullet is sought for by a grooved director passed successively through the tissues on all sides of the probe. When found the bullet is removed by forceps passed along the grooved director. After this the fenestrated catheter is drawn into position the same as before. This plan which was devised in 1887 by the author and employed at once with success on a case in Bellevue Hospital is eminently practical and can be promptly utilized, requiring only a long probe and a string for the purpose. If the bullet strikes the opposite side of the skull, the probe is introduced to the point of impingement, and the seat for the counter-opening is indicated and made as in the preceding instance. However, the bullet in

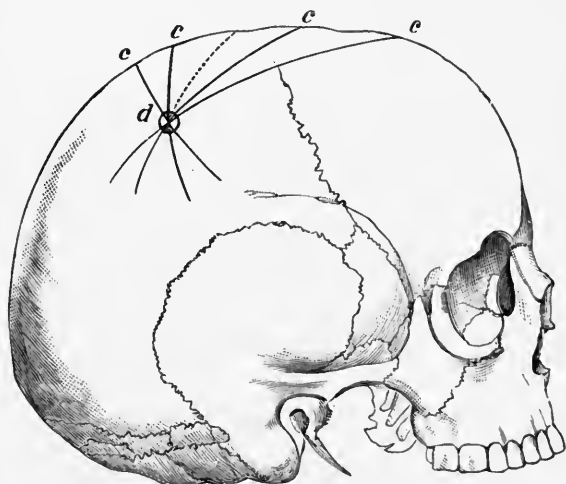


FIG. 301.—Site of counter-opening (*d*) located by author's method.

this instance is likely to be at a distance of an inch or so from the point of impingement, in the direction indicated by the angle of incidence. In such cases the counter-opening should be not less than an inch and a half in diameter, to admit of easy exploration for the ball. The course of the reflected ball through the brain is sometimes apparent; again, it may be necessary to locate it with the aid of a sharp needle passed into the brain in the direction of the line of incidence. In efforts of this kind the needle probe of the Girdner apparatus is of great value, as by its use the bullet can be located with certainty and with a minimum injury of the brain. If a deep-

seated bullet be touched with a probe, and the direction of the wound be such that the establishment of a counter-opening in its course is impossible or unwise, then perhaps a large opening can be made through the skull at a point nearest to the ball. Through this opening the ball is sought for and located with the needle probe of Girdner, which if left in position in the brain affords a certain guide to the missile, which can then be removed as before. In such instances as this suitable drainage for each portion of the wound is necessary, as a drainage agent can not be carried through an angular wound of the brain for obvious reasons. If a bullet can not be found, or if removal be inadvisable, a small fenestrated rubber tube is introduced gently into the wound as far as practicable, fastened in position, and flushed gently with warm Thiersch's fluid or the warm saline solution.

After-treatment.—After the tube is fastened in position and the wound is carefully dressed with dry antiseptic gauze bound lightly in place, the patient's head is so arranged, if feasible, that the force of gravity will favor the escape of discharges from the wound. The controlling of inflammation requires that the head and shoulders be raised, a cold water coil applied to the head, bowels freely moved, and that anodynes be administered according to circumstances. The wound should be dressed as often as proper cleanliness requires for the purpose of hastening repair and the prevention of septic meningitis. Thiersch's fluid and the saline solution used warm are the best agents for flushing purposes, as they are unirritating. After the repair of the wound is well under way, horsehair as a drainage agent should be substituted for the rubber tube. The interchange can be easily and safely made by pushing into the end of the rubber tube for a short distance a small wisp of aseptic horsehair, which is then left in position by the withdrawal of the tube. As the wound heals, the increase in repair is accommodated from time to time by the withdrawal of a proportionate amount of the hair.

The Precautions.—Avoid the cranial sinuses in making counter-openings, and also the basal ganglia in explorations. If a bullet be in the lateral ventricles it is dangerous and useless to attempt the removal. If a bullet be near the ventricles it is very liable indeed to be pushed into them by efforts of removal. A much spent bullet will not rebound at an angle equal to that of incidence, but will remain in contact with the skull and membranes at a point near to that of primary impingement. Fragments of bone and other foreign bodies lying in the course of the wound must be carefully sought for and removed before using the Fluhrer probe, to avoid their being carried still farther into the brain by the introduction of this agent. In fact, after the removal of these bodies, the introduction along the track of the ball of a small fenestrated rubber tube and the backward flushing incident to the careful introduction into it of a warm saline solution, may not only cleanse the wound but check the oozing from the brain substance.

The Results.—The following tables, which were a part of a paper read before the New York State Medical Society in 1888 by the author, speak for themselves of the wisdom of operative procedure, although not

with sufficient emphasis, as these results are not the product of aseptic method :

LOBES OF BRAIN IMPLICATED.	BALLS REMOVED AND ESCAPED PRIMARILY.			BALLS NOT REMOVED.		
	No.	Died.	Recov- ered.	No.	Died.	Recov- ered.
Frontal.....	33	17	16	27	13	14
Parietal.....	6	1	5	5	4	1
Temporo-sphenoidal.....	15	3	12	9	6	3
Occipital.....	8	3	5	6	3	3
Cerebellar.....	4	4	0	2	1	1
Frontal and parietal.....	3	1	2	1	1	0
Frontal and temporo-sphenoidal.....	6	3	3	0	0	0
Frontal, temporo-sphenoidal, and occipital....	5	3	2	3	3	0
Parietal and occipital.....	2	1	1	0	0	0
Temporo-sphenoidal and occipital.....	2	1	1	2	1	1
Temporo-sphenoidal, pons, and crura cerebelli	1	1	0	0	0	0
Total.....	85	38	47	55	32	23

Tabulated Statement of the Cases in which the Missiles Escaped Primarily.

FROM	No.	Died.	Recov- ered.
Frontal lobes.....	3	1	2
Parietal lobes.....	0	0	0
Temporo-sphenoidal lobes.....	8	1	7
Occipital lobes.....	3	1	2
Cerebellar lobes.....	3	3	0
Frontal and parietal lobes.....	0	0	0
Frontal and temporo-sphenoidal lobes.....	6	3	3
Frontal, temporo-sphenoidal, and occipital.....	3	2	1
Parietal and occipital lobes.....	1	1	0
Temporo-sphenoidal and occipital lobes.....	1	1	0
Temporo-sphenoidal, pons, crura cerebelli.....	1	1	0
Total.....	29	14	15

The showing favoring surgical interference in this series of cases is greater than that of many others, notably those of Huhn, which only slightly favor removal. *Fowler*, however, reports sixty cases treated under aseptic and antiseptic methods with the following results: Bullet removed in twenty-four cases, mortality sixteen per cent; not removed in thirty-six cases, mortality fifty-nine per cent.

THE SPECIAL OPERATIONS ON NERVES.

It often becomes necessary, on account of neuralgia, spasm, tremor, violence, etc., to operate on the trunk of the nerve involved after other means have failed either by, 1, nerve-section or neurotomy; 2, nerve-resection or neurectomy; 3, nerve-stretching or neurectomy; 4, nerve-avulsion, or tearing away; 5, nerve-suture or neurorrhaphy; 6, nerve-grafting.

Nerve-section and *nerve-resection* differ in the extent of the operative

procedure. In the former, the nerve is divided at one point; in the latter, at two separate points, and the intervening portion of the nerve is removed. Either of these measures can be practiced singly or in conjunction with nerve-stretching, the latter always taking precedence. The portion of the trunk of the nerve attacked either in section or resection should, 1, be healthy at the seat of operation; 2, be located at the proximal side of the seat of the disease calling for the operation; 3, should command the sensory fibers of the diseased area, for otherwise the operation can not be entirely successful; 4, should not include important motor fibers. Nerve-section is not much employed now, as it affords but temporary relief, owing to the more or less prompt repair of the divided nerve. Nerve-resection is commonly employed instead, and the length of the portion removed depends, of course, on the size and length of the nerve trunk involved; not less than two inches should be removed if practicable; and even then in some instances the divided extremities are turned away from each other, or tissues are interposed between them to fortify against the possibility of a future reunion. Nerve-section is done by either the subcutaneous or open methods; the latter is the more successful measure and less liable to cause injury of contiguous structures; but it invites the presence of cosmetic defects. While in the great majority of instances these operations assume no special magnitude, still strict aseptic measures should be a part of the entire procedure.

Nerve-stretching.—Nerve-stretching has a greater range of application than has the division of nerves, and its employment usually antedates the use of the severer operative measures. A failure of this means of treatment is not followed by a long or grievous disturbance of function, as the immediate effects are of comparatively short duration. The following facts relating to this procedure are of practical interest: Nerves can be stretched about one twentieth of their length; nerves in central locations are less extensile than are those in peripheral; nerves near to the spinal cord are more extensile than are those at a distance; those of the upper are more so than those of the lower extremities.

The traction is made with the thumb and finger, the finger alone, or with a hooked instrument; it is made gradually and forcibly, the force employed corresponding to the size and seat of the nerve, and is directed to the central and peripheral extremities alternately. If a sense of a limited and sudden giving away happens traction should cease at once, as rupture of the entire nerve may quickly follow. In *dry stretching* these measures are unnecessary. The degree of traction exercised will be expressed in connection with the operations on the respective nerves.

Nerve-avulsion consists in the tearing away of a nerve from the central or peripheral ends, aided, perhaps, by division of branches or trunks.

Nerve-suture.—There is now no question of the fact that the ends of divided nerves should be united with each other, when possible, with sutures. Although this course is not followed by restoration of function in all instances, still the frequent happy results that follow the measure admonish the surgeon to be prompt and urgent in the treatment of these cases.

Primary and *secondary suturing* are practiced; the former relates to recent, the latter to old cases of nerve division. In both instances, however, only recently divided or freshened nerve extremities are united with each other. In *primary suturing* (Fig. 302), with no loss of substance, the extremities can be united at once with two fine catgut or silk sutures passed through the ends of the nerves at right angles to each other (*a*) with a fine needle and tied. The sutures should be passed as near to the periphery of the nerve as is consistent with proper repair, even if the sheath of the nerve only be transfixed (*b*). Any tension at the line of junction of the extremities should be avoided, as it greatly prejudices the chances of cure. The tying of the ends (*c*) is seldom practicable, and in no event a suitable substitute for sewing. Tension of a nerve is commonly the result of a loss of substance or retraction of the nerve, due to injury, or is the outcome of the freshening of the divided ends for reparative purposes. Tension or separation of the extremities may be lessened, or overcome entirely, by stretching the nerve, by flexion of the part containing it, and by nerve-grafting. The shortening of a limb by excision of the bone to meet curtailment of the nerve is such a harsh method of action that it should not be contemplated, except under the most urgent demands. Various arranged sutures are advised for the union of divided nerves, but usually the one just described is quite as good as any. Fig. 302, *d*, *e*, *f*, shows another and a serviceable method of repair.

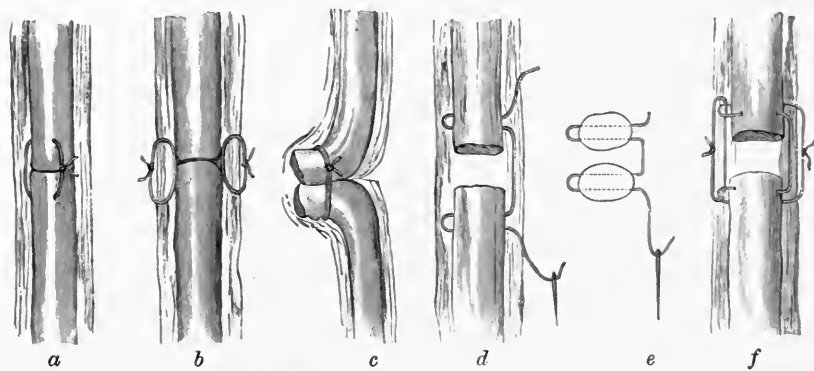


FIG. 302.—Primary suturing of nerves.

In a few instances and under favorable circumstances, union has taken place in three or four days, as indicated by returning sensation. However, a like number of weeks is the common period, and in some cases months and even years may elapse before the evidences of union appear, if at all.

Secondary suturing is applicable to cases of old injury of nerves in which loss of function and atrophy have supervened. The ends of the nerve are usually widely separated, and are adherent to the contiguous tissues. The proximal end is bulbous, the distal atrophied, and both are imbedded in cicatricial tissue. The operation is aseptic in every detail. The Esmarch bandage is sometimes employed. The nerve ends are exposed, the nerves

stretched, and cicatricial tissue removed. Thin layers are sliced off from the end of the bulbous extremity until healthy nerve tissue is reached. If any part of the bulbous extremity remain, it is utilized as a firm basis for

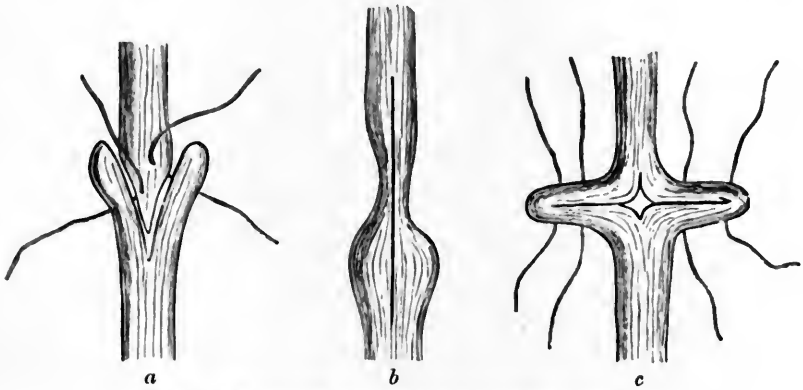


FIG. 303.—Gleiss's method of secondary suture.

sewing purposes. The distal end is trimmed but little, scarcely a quarter of an inch, for, says Bowlby, "It is seldom necessary to remove as much as a quarter of an inch, and, however unhealthy the section may look, no good is ever to be gained by a further sacrifice." From three to four sutures of fine catgut, silk, or kangaroo tendon, are passed through the nerve at about a quarter of an inch from the extremities and tied. A cambric needle or any small needle with non-cutting borders should be employed to carry the sutures. Owing to the cicatrix it may expedite matters if the nerve be isolated outside of the cicatricial tissue, and then followed to the seat of injury, rather than that it be directly approached at that point. Gleiss advocates the following methods of union in these instances, and reports ten complete cures in eleven cases—grafting is practiced in one instance (*a*); linear division (*b*), followed by approximation and sewing in the other (*c*) (Fig. 303). The wound is closed without drainage and the tissues are relaxed by posture, if possible, and the limb firmly fixed by an immovable splint until the wound is healed. After this, massage and galvanism should be employed to restore the tone of the parts.

The Results.—The results are flatteringly exhibited in the following table (Bowlby):

	Suc- cessful.	Im- proved.	Fall- ure.	Total.
Primary suture.....	32	34	14	80
Secondary suture.....	32	26	15	73

Neuroplasty is utilized to fill in the gap between the ends of nerves which nerve-stretching, position of the limb, etc., have failed to accomplish. Single (*a, a*) and double (*b, b*) flaps of the extremities of the nerves are made as occasion demands, and are united with each other or with the

nerve extremity, as indicated in the illustration (Fig. 304). In neuroplasty for cure of old injuries the method of Duncan commends itself for trial (Fig. 305). The connection of the extremities by one or several strands of fine catgut by sewing (Fig. 306), and

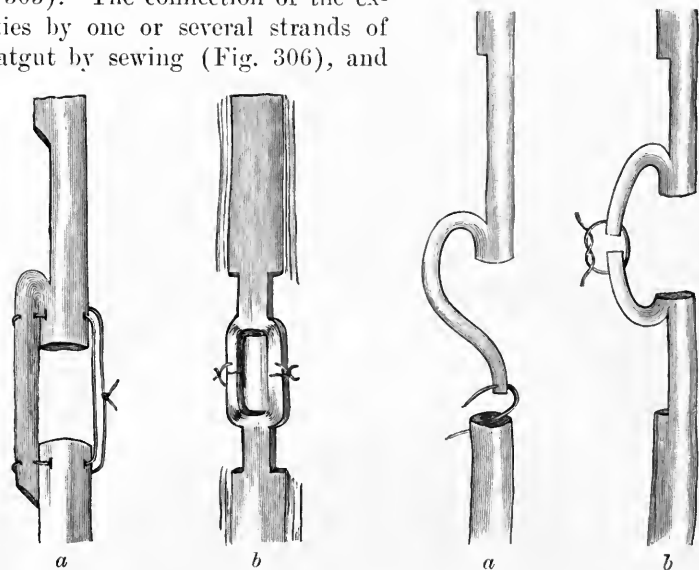


FIG. 304.—Neuroplasty. Secondary suturing of nerves.

the grafting of one nerve to another (Fig. 307), as in cases where impaired nerves run parallel with each other—*i. e.*, the arm, forearm, etc.—and the ingrafting the gap with recent human or animal nerve tissue by means of sutures, aided with bone ferule, are sometimes followed by results which offer encouragement for continued effort in this direction.

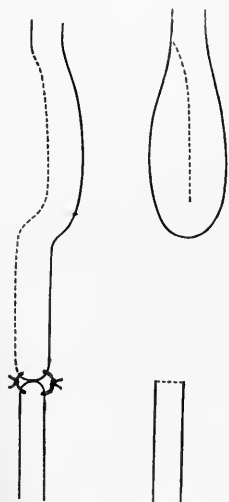


FIG. 305.
Duncan's method of neuroplasty.



FIG. 306.
Repair of nerves by catgut.

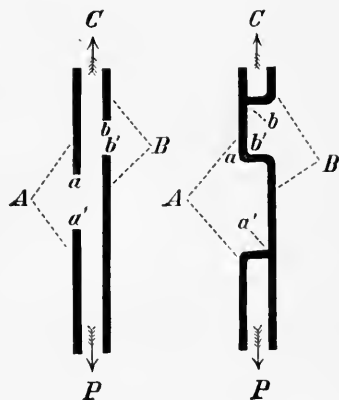


FIG. 307.—Grafting of adjacent nerves for a nerve defect. *C.* Central organ. *P.* Peripheral.

OPERATIONS ON SPECIAL NERVES.

In the consideration of special nerves only such points as are distinctly applicable to each of them will be stated, as the general technique of operations on nerves has been considered sufficiently already.

FIRST DIVISION OF THE TRIFACIAL NERVE.

The Supra-orbital Nerve.—The supra-orbital nerve can be divided, resected, and stretched at its exit from the supra-orbital foramen or notch located at the junction of the inner and middle thirds of the supra-orbital arch. If a notch be present, it can be readily felt with the finger. At this

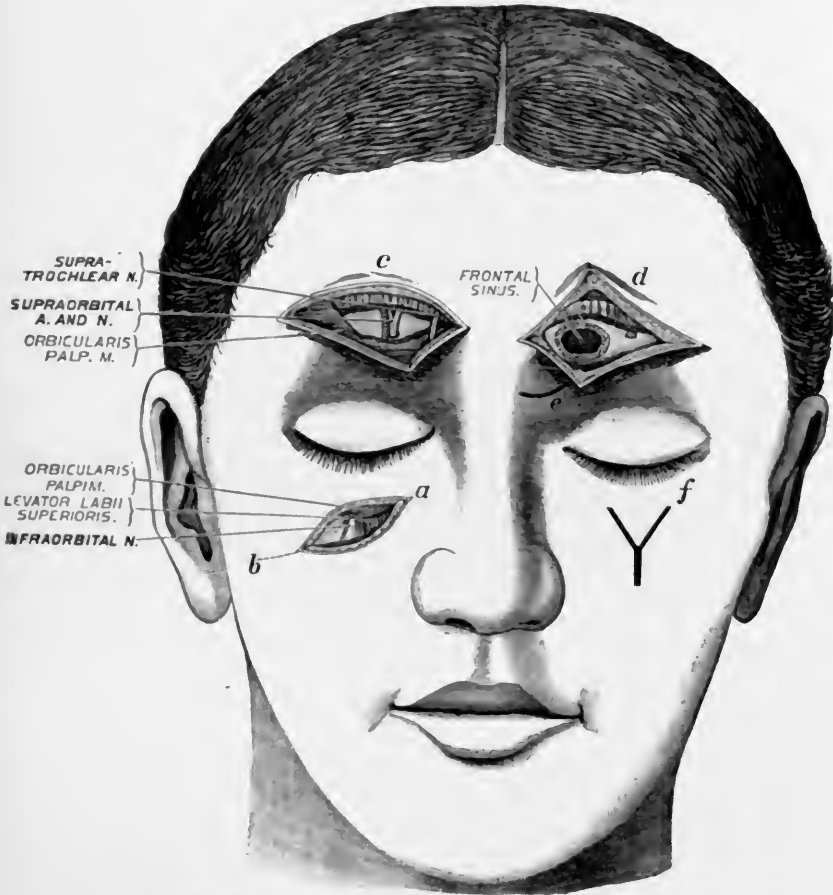

FIG. 308.—Supra-orbital and infra-orbital nerves and frontal sinus.

situation the nerve is covered by integument, fascia, and the combined fibers of the orbicularis palpebrarum, occipito-frontalis, and corrugator supercillii muscles. It is accompanied by vessels of the same name as itself. The

nerve often divides into two branches before reaching the seat of operation. It may be divided by the *subcutaneous* or by the *open method*. If by the former, steady the eyebrow and locate the notch with the left hand; then pass the point of a narrow bistoury beneath the integument from within outward, turn the edge, and cut strongly across the notch toward the upper boundary. A firm compress should be applied to the wound at once to control the bleeding from the supra-orbital vessels. The nerve can be *divided*, *resected*, or *stretched* through either of the following cutaneous incisions:

The First Operation.—Steady the eyebrow with the left hand; with the right draw the eyelid downward and hold it with the thumb of the left. Make a horizontal incision about an inch in length along the superior margin (Fig. 308, *c*) of the orbit—the center corresponding to the notch—through the tissues down to the nerve; expose and treat the nerve, avoiding the vessels. A *vertical incision* (Fig. 311, *a*) at the notch would be the better one, were it not that a freer division of the muscles is made and a greater danger of scarring incurred.

The Second Operation.—Elevate the brow with the left hand; with the right draw down the lid and hold it as before. Make an incision between the brow and the lid one inch in length through the tissues down to the site of the nerve (Fig. 312, *a*). Push aside the connective tissue and isolate the nerve. In stretching, seize the nerve with an aneurism needle curved at the side. Since in the dead subject this nerve parts under a six-pound strain, much caution must be exercised in stretching it in the living, otherwise it will rupture. The nerve can be pulled out from the roof of the orbit with a small, blunt hook, and treated before it enters the foramen or notch.

The Supratrochlear Nerve.—The supratrochlear nerve is stretched in certain cases of glaucoma and ciliary neuralgia. The nerve escapes from the orbit above the pulley of the superior oblique muscle (Fig. 308, *c*). A line drawn from the angle of the mouth through the inner canthus to the margin of the orbit indicates the course of the nerve at this situation.

The Operation.—Make an incision with the convexity downward at the upper part of the inner angle of the orbit (Fig. 308, *e*) directly below the eyebrow; draw apart the borders of the wound; locate the pulley of the superior oblique, and find the nerve just above it; raise the nerve with a hook and stretch it cautiously.

SECOND DIVISION OF THE TRIFACIAL.

The Infra-orbital Nerves.—The infra-orbital nerves are the terminal branches of the second or supra-maxillary division of the fifth pair. They are present at the infra-orbital foramen, which is located about four lines below the lower edge of the orbit, and nearly on a line extending from the bicuspid teeth to the supra-orbital foramen.

The infra-orbital nerves (nasal, palpebral, etc., Fig. 309) can be divided through the mouth by first recognizing the location of the infra-orbital foramen and placing the finger upon it. Then turn up the cheek and make a narrow incision, beginning at the fold of the cheek and maxilla, and carry it upward in the line of the foramen until within a short distance of it, when

the nerves are divided with a sharp-pointed scissors as they appear at the opening. The nerves can be exposed through an incision made as follows:

The Operation.—Make an incision with the convexity downward at the lower margin of the orbit, with the center at the infra-orbital foramen (Fig. 308, a). Divide the orbicularis and levator labii superioris; pull asunder the margins of the wound and expose the nerves, avoiding the infra-orbital vessels. The nerves can now be treated as indicated. It is wise to remember, however, that these nerves arise from the superior maxillary in the infra-orbital canal but a short distance behind the foramen. The division at the foramen can do no good if the lesion be behind the point of section.

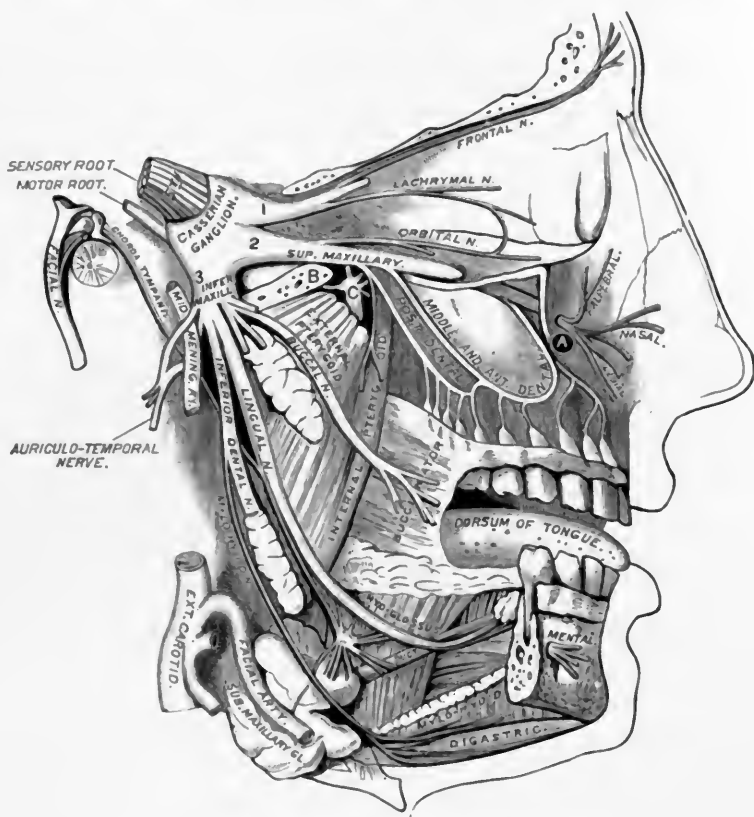


FIG. 309.—Divisions of the trifacial nerve.

Even the sensation of the teeth supplied by the anterior dental branch of the superior maxillary is not disturbed by it. This nerve can be divided subcutaneously at its exit from the foramen by a short, thin knife directed against the posterior wall of the opening. The division of the infra-orbital vessels will cause quite severe hæmorrhage.

The Superior Maxillary Nerve and Meckel's Ganglion.—The superior maxillary nerve is one of the divisions of the great sensory nerve of the

face. It has three portions of much surgical interest: 1, the infra-orbital portion; 2, the spheno-maxillary portion, with Meckel's ganglion; 3, the intracranial portion. The first or infra-orbital portion lies in a canal or groove of the floor of the orbit, which extends from the spheno-maxillary fossa to the infra-orbital foramen. The walls of this passage are exceedingly thin, except at the terminal foramen. The dental branches arising from the nerve as it passes along the floor of the orbit are the anterior, middle, and posterior (Fig. 309), the first and last of which, respectively, come from the extremes of this portion of the nerve. The infra-orbital portion of the nerve can be exposed in the infra-orbital canal by one of two or more procedures. However, the presence in the posterior wall of the antrum of the posterior dental branches demands that great care be taken, or they will remain undisturbed. *The nerve can be divided* at the floor of the orbit by passing a sharp-pointed tenotome backward on the floor in the course of the nerve for an inch or so, then turning the edge downward and cutting through the bony walls of the canal at a right angle with the antero-posterior axis of the orbit. The infra-orbital foramen is then exposed, the nerve grasped and pulled out, leaving behind the posterior, and perhaps middle dental branches. *The nerve can be stretched* at any situation in its course, after elevation from the canal, by means of a blunt hook passed along the floor of the orbit through a narrow incision of the soft parts, made at the lower margin of the orbit with a sharp-pointed bistoury. The nerve is hooked up and stretched, then resected if need be. The breaking strain in the dead subject is twelve pounds. *The division and removal of the nerve at the anterior border of the spheno-maxillary fissure* is a brilliant procedure, although not commonly practiced on account of the guarded manipulation essential to success.

An Operation for Division and Removal.—Through either a vertical incision an inch in length made from the lower margin of the orbit, or a curved one of the same length made at this margin, expose the infra-orbital nerve on the face. Now, through a narrow incision made below the inferior tarsal ligament at the outer angle of the orbit, introduce a curved, blunt, narrow-bladed tenotome and pass it along, with the edge downward, in the direction of the apex of the orbit, until it reaches the posterior part of the spheno-maxillary fissure;* then press the edge downward and draw the blade forward and outward along the anterior border of the fissure to near its outer extremity, thus dividing the submaxillary nerve at the entrance to the groove. The nerve is then carefully pulled away by gradual traction addressed to the infra-orbital branch. The coincident division of the infra-orbital artery causes considerable hæmorrhage, which is often followed by a transient exophthalmos. The ultimate results of this method are better by far than are those of the other infra-orbital methods, as it assuredly severs the dental branches from any central connection. However, the depth of the wound, the importance of the structures of the orbit, the delicacy of the operative technique, and the liability of severe hæmor-

* See Articulated Bones of Orbit.

rhage and of missing the nerve entirely, make this plan of action so risky and uncertain that the following mode of procedure for division and removal of the nerve is recommended:

The Operation.—Make an oblique or Y-shaped incision (Fig. 308, *f*) below the lower border of the orbit down to the bone, so as to expose the nerve; isolate and tie with a strong ligature the terminal branches of the nerve as they emerge from the infra-orbital foramen; cut away with a chisel or rongeur the orbital border of the foramen (Fig. 309); separate the periosteum from the floor of the orbit back to the speno-maxillary fissure with a thin periosteotome; raise upward the periosteum and the contents of the orbit with a thin right-angled retractor; raise the nerve upward into the orbit as it is liberated from its channel with scissors, back to the fissure; carry beneath the nerve from before backward as far as possible a hook with a right-angled upward curve, thus freeing the nerve from the canal and rupturing the smaller branches; carry backward around the nerve as far as possible a strong silk ligature and tie it; stretch the nerve by strong traction on the string; carry along the under surface of the nerve in the course of the hook a fine pair of short-bladed, blunt-pointed scissors sharply curved on the flat; cut the nerve as close to the foramen as possible, and remove it; arrest hæmorrhage, remove the spatula, and allow the contents of the orbit to return to the natural position; close the wound and apply a soft compress to the eye and wound, and fasten in place with a bandage.

The Precautions.—The only bleeding of any account comes from the infra-orbital vessels, and this can be easily controlled with sponge pressure. The periosteum beneath the orbital plate must not be torn, since blood will then escape into the antrum of Highmore. The manipulation of the tissues of the speno-maxillary fossa should be practiced with care to avoid injury of the internal maxillary artery, causing hæmorrhage which may require ligature of the external carotid to arrest. The optic nerve, lying some distance above and to the inner side, should be carefully avoided.

The Remarks.—If the hook have an advancing cutting border calculated to sever the branches of the nerve (Fig. 310) at their origin, then the nerve can be removed back to the foramen with no danger to the contiguous tissues. In this instance the ganglion is not removed, but its branches and those going to the superior maxilla are severed. Subconjunctival ecchymosis of a moderate amount appears, but is rapidly absorbed, and the parts resume their usual appearance in a few days, only a trivial cicatrix remaining at the seat of incision. If the nerve be divided behind the roots of the ganglion and firm traction be made, the ganglion and its branches are stretched, and perhaps the ganglion may be drawn into the orbit and removed along with the nerve. The disfigurement from this operation is



FIG. 310.—Author's curved cutting hook.

trivial; and the technique is simple and attended with little danger and perplexity. In the experience and observation of the author the outcome also is quite as favorable as when the ganglion is removed. Inasmuch as some doubt exists as to whether the benefit comes

from removal of the ganglion or the nerve trunk associated with it, it seems wise to cultivate this the simpler method and establish its status rather than practice the latter and graver one with an unwarranted faith.

The following operations have the decided advantage of being applicable to the surgical treatment of both the first and second portions of the nerve and also of Meckel's ganglion:

Kocher's Operation.—Make an incision from a point located about a quarter of an inch below the bony margin of the orbit and half an inch inside the infra-orbital foramen, obliquely downward and outward to the lower part of the body of the malar bone, as far as the zygomatic arch (Fig. 308, *a, b*); divide the periosteum between the lower border of the orbicularis palpebrarum and the origin of the levator labii superioris muscles; detach the periosteum upward and downward, exposing the infra-orbital nerve,

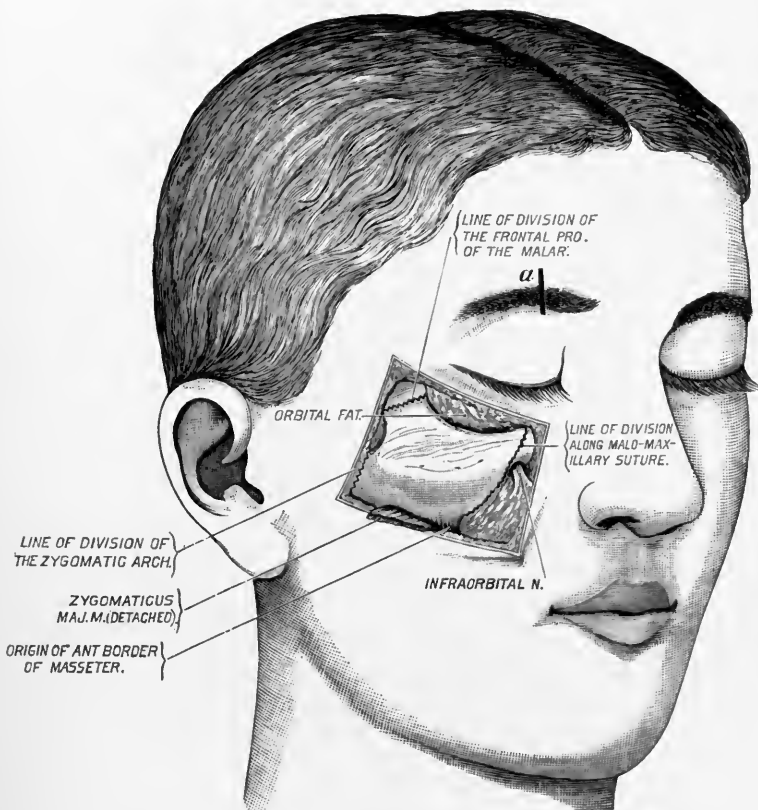


FIG. 311.—Resection of the second division of the trifacial nerve.

which is liberated and secured with a ligature. Draw the zygomatic muscles downward and detach the anterior fibres of the masseter from the malar bone; elevate the periosteum from the outer and inner surfaces of the malar bone; bare the anterior surface of the malar process of the upper jaw (Fig. 311) to the infra-orbital foramen and its upper surface back to the

spheno-maxillary fissure; draw the upper border of the wound upward, so as to expose the fronto-malar suture; so chisel through the fronto-malar suture toward the posterior part of the spheno-maxillary fissure that its upper border, the orbital process of the malar, a portion of the orbital plate of

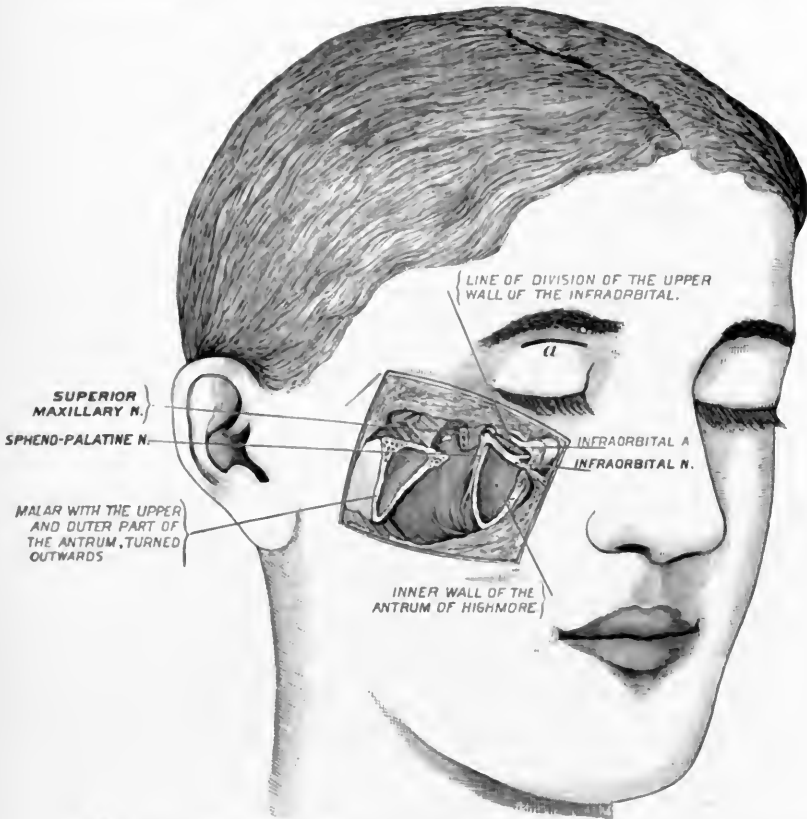


FIG. 312.—Exposure of the second division of the trifacial at the foramen ovale.

the sphenoid, and a part of the zygomatic crest can be raised; draw up the orbital nerve and chisel from above the infra-orbital canal downward and outward (Figs. 311 and 312) to below the anterior border of the origin of the masseter, then upward through the outer wall of the antrum, so as to meet posteriorly the preceding division of the orbital structure, thus permitting the outer wall of the orbit, the supero-external wall of the antrum, and its posterior angle to remain connected with the malar bone when the latter is pried outward. Dislocate the bony mass upward and outward with a strong hook, raising the orbital fat with a blunt retractor; expose backward to the foramen rotundum the nerve; pass a small hook behind the descending spheno-palatine nerves around the main trunk, which can then be divided or twisted out. The bony flap is returned to and fastened in place by sutures, and the borders of the wound are closed in a similar manner. With careful adjustment of the parts, but little disfigurement results.

The Remarks.—The incision is an extension to that for exposure of the infra-orbital nerve (Fig. 308, *a, b*). The infra-orbital artery may be pushed aside or ligatured, as seems best.

Carnochan-Chavasse Operation.—Through a V-, U-, Y-, or I-shaped incision (Fig. 308, *f*), the center corresponding to the infra-orbital foramen, expose the infra-orbital nerves at that point, and tie a silk ligature carefully around them; raise the periosteum from the bone and perforate the anterior wall of the antrum, including the floor of the foramen, with a trephine or gouge and mallet, making the opening about three quarters of an inch in diameter (Fig. 309, *A*). Make an opening in the posterior wall of the antrum half an inch in diameter, as near to the roof as possible, in a similar manner. Control the hæmorrhage from the antrum with aseptic gauze packing and from the soft parts with ligatures; raise the periosteum from the roof of the antrum in the line of the orbital canal till the canal can be localized with a probe; divide the mucous membrane of the roof of the antrum in the line of the canal in the floor, and with a small, short chisel, brad awl, or with scissors, break through the floor of the canal from before backward, drawing down on the nerve, with the string, as it is liberated from the bony canal. With a blunt end of a director, guided by the liberated nerve, gently disengage the second portion of the nerve from the tissues of the sphenomaxillary fossa back to the foramen rotundum (Fig. 309, *B*), into which the point of the instrument can be readily inserted. After a thorough stretching the nerve is divided at the foramen rotundum with sharp curved scissors. Gentle traction on the divided nerve brings the ganglion (Fig. 309, *C*) forward into the antrum, and, after division of its branches of distribution, the ganglion is drawn away with the nerve which is about two inches in length. The wound cavity is packed with gauze till bleeding is arrested, then the gauze is removed, the wound drained, closed, and dressed in the usual manner. In the opinion of the writer, it is better to adopt the plan of Abbe and pack the wound with gauze for eight hours to control hæmorrhage than to take much time in arresting hæmorrhage, or the risk of orbital infiltration from persistent oozing of blood, especially since the delayed measures of treatment, sewing, etc., will cause no pain after division of the nerve.

The Precautions.—Almost invariably severe hæmorrhage is caused by the opening of the posterior wall of the antrum, due to the rupture of vessels running in the posterior dental canals at that situation. At the outset this hæmorrhage is quite brisk, leading one for the moment to fear injury of the internal maxillary artery; but the patient application of firm pressure with sponge or gauze checks the flow and reassures the surgeon. If care be not exercised in the making of the opening at the posterior wall of the antrum the internal maxillary artery will be torn. In this instance the bleeding will be both severe and persistent, and can be more wisely and surely controlled by prompt ligature of the external carotid than by any other means. The antrum must be well lighted during operation, if the surgeon expects to see the ganglion or to remove the nerve entirely from its canal, without dividing it in the attempt. Although the electric headlight (Fig. 111) is the best means for the purpose, still, in its absence, the reflections of a

laryngeal mirror will be of great service. Thorough drainage of the wound is necessary, and frequent cleansing as well, since the free communication between the nasal meatus and the antrum exposes the latter to infection.

Lücke reached the sphenomaxillary fossa and the foramen rotundum through a quadrangular-shaped flap limited below by the lower border of the zygoma, above and in front by the frontal process of the malar bone, and behind by a vertical line an inch in length crossing the origin of the zygoma. Divide the masseter at the lower border of the zygoma, saw the zygoma at either end, turn the flap upward, remove intervening structures, separate the two heads of the external pterygoid muscle, and expose and resect the nerve at the point of exit from the foramen. Although the masseter muscle is united thereafter with sutures, it does not unite kindly, and a crippling of the movements of the jaw from this cause is quite sure to follow. *Löszen* was led by this sequel to advise that the temporal fascia be divided instead of the masseter, and the zygoma turned downward, instead of upward, as before, and the divided borders of the temporal fascia united subsequently with sutures. The reversal of this portion of the original plan obviates the crippling effects of division of the masseter muscle. Not a few modifications contemplating an attack on the nerve from this quarter are advised. However, while the opportunity for open work is often enhanced by these methods, still they are severe in character and expose large surfaces to the action of the suppurative and infective processes incident to faulty technique.

The Results.—Section of the nerve in any part of the course is usually of temporary use only, and it should not be done except with that understanding. Stretching before section may add somewhat to the time of exemption from pain in many instances, and stretching alone will often afford relief. Removal of the entire infra-orbital portion of the nerve is of much greater benefit than the removal of any part of it, as in the latter procedure some of the dental nerves may remain behind, and, moreover, regeneration is prompter in this than in the former instance. Removal of the entire nerve with or without the ganglion is frequently followed by cure, and merits professional confidence and prompt action.

	Number of cases.	DURATION OF RELIEF.				
		6 months.	6-12 mos.	1-2 years.	2-3 years.	3 years.
Nerve and ganglion removed....	26	5	3	9	6	3
Nerve only removed.....	26	4	7	7	3	5
Total	52	9	10	16	9	8

—*Fowler.*

THIRD DIVISION OF THE TRIFACIAL NERVE.

The intracranial and extracranial portions of the third division of the fifth nerve, together with the dental, lingual, auriculo-temporal and buccal branches, are each amenable to surgical procedure.

The Inferior Dental Nerve (Fig. 309).—The inferior dental nerve is the largest of the branches of the third division. It passes downward, along with,

at the front, and to the inner side of the inferior maxillary vessels, beneath the external pterygoid muscle, then between the internal lateral ligament and the ramus of the jaw to the dental foramen. It passes forward in the dental canal of the lower jaw, supplying the teeth, and finally terminates at the mental foramen in the incisor and mental branches. The inferior dental nerve can be exposed at three situations: 1, before entering the dental foramen; 2, in the dental canal; 3, at the mental foramen. Operation at the first situation is the only one of the three methods that affords the patient satisfactory relief. At this situation the nerve can be reached by either of two methods, known respectively as the internal or buccal route, and the external or facial route.

The Internal or Buccal Route.—Although the nerve is deeply situated in the mouth, yet it has superficial and deep guides that lead to it unerringly.

The superficial guides are the anterior border of the ascending ramus of the jaw and of the internal pterygoid muscle. These guides can be easily distinguished with the finger through the widely opened mouth, before the operation.

The deep guides are the spine of Spix and the internal lateral ligament which is inserted into the spine. Although the deep guides can be located with the finger before the operation, still they are of far greater significance after the making of the primary incision. After a thorough cleansing of the teeth and buccal mucous membrane at the site of the operation, with antiseptics and scrubbing, the patient is anæsthetized, placed in a good sunlight, or an electric headlight is provided.

The Operation (Paravicini).—Fix the mouth widely open with a Denhard (Fig. 4), Goodwillie (Fig. 848, *f*), or extemporized mouth gag, placed at the side opposite to the operation. With two narrow retractors pull the cheek backward and away from the field of operation; pull the tongue to the opposite direction; locate the inner edge of the anterior border of the ascending ramus of the jaw, and of the internal pterygoid muscle with the finger; make an incision through the mucous membrane between these guides, about an inch in length, close to the bone, with a long-handled scalpel. Separate the tissues with a firm spatula or a small periosteal elevator, aided by the finger, from the bone down to the spine of Spix. The periosteum is not disturbed. The spine of Spix is usually well developed and, consequently, is easily located at this time, along with the internal lateral ligament which is inserted into it. At the base of the spine the foramen can be felt, and occasionally also the nerve and vessels as they enter it. If additional space be required divide the internal lateral ligament with scissors; draw inward the internal pterygoid with a retractor; sponge out the wound cavity and expose it to a strong light. A blunt hook, curved at the side, or an aneurismal needle, curved in the same manner, is passed into the wound, the nerve hooked up, if possible at a point half an inch from the foramen, and drawn forward. Remove the artery from the hook if included with the nerve, and then pass around the nerve at this point a strong silken ligature, and tie it firmly to the nerve. The nerve is then stretched by means of the ligature and divided with scissors above and as near to the internal maxillary artery as is safe.

The lower end is then stretched and cut off at the foramen in the same manner, carefully avoiding the dental artery. About three quarters of an inch to an inch in length can thus be resected.

The Precautions.—The lingual nerve, which may be mistaken for the dental, can be easily differentiated by making upward traction; then, if the latter be the one grasped, firm resistance is noted; if the former, the tongue and its contiguous tissues are easily and freely moved by the traction. The dental nerve may be ruptured if too severe traction be made upon it; a

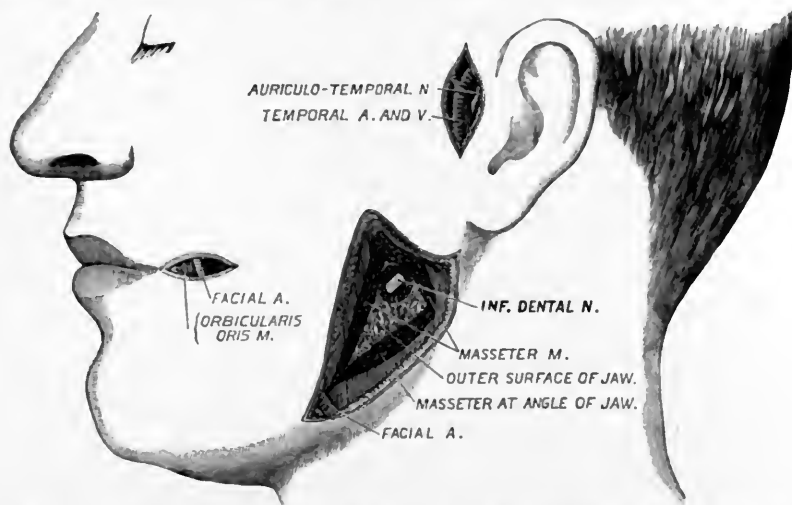


FIG. 313.—Resection of inferior dental nerve. The temporal and facial arteries.

resistance of from ten to fifteen pounds is safely borne. Division of the inferior dental or of the internal maxillary arteries will cause troublesome hæmorrhage. Pressure of the vessel against the bone will control the former; for control of the latter, ligature of the external carotid may be necessary.

The Comments.—During the after-treatment the mouth should be kept thoroughly cleansed to obviate or lessen, as far as possible, subsequent inflammatory action at the seat of the operation. If suppuration occur, we regard it wise to establish drainage externally by means of a small rubber tube carried through an opening made from the bottom of the wound out near the angle of the jaw, by means of a curved, sharp-pointed scissors thrust while closed through the tissues at this situation. The patient should be thoroughly anæsthetized before the operation is commenced, or his struggles will delay the procedure, cause undue injury of the soft parts, and otherwise embarrass the surgeon. Since the operation is a troublesome and annoying one at the best, the surgeon should claim for his support the advantage of every resource at his command.

The External or Facial Route.—In this route an opening is made through the cheek, and sometimes through the ascending ramus of the jaw, at a point corresponding to the situation of the inferior dental foramen. *The guides* to the operation are the masseter muscle, the angle of the jaw, and the anterior

and posterior borders of the ascending ramus. The chief objections to the external route are: 1, the difficulty in dividing satisfactorily the soft parts without injury of some of the infra-maxillary branches of the facial nerve; 2, the crippling of the jaw that may follow interference with the masseter muscle; 3, the production of an objectionable cicatrix. The first objection can be met by carefully locating the line of incision. *Keen* recommends that an incision two inches in length be made along the lower border of the jaw, beginning a little behind the angle (Fig. 315, *d*), and so located as to reduce to a minimum the expanse of the scar. Through this incision the masseter muscle is raised from the ramus with a sharp periosteal elevator. The tissues are pulled aside and a half-inch opening is made with a trephine one inch and a quarter above the angle and directly below the sigmoid notch—i. e., at about the middle of the perpendicular ramus of the jaw (Fig. 313). Through this opening the nerve is exposed as it enters the foramen, is hooked up with a needle and stretched, and as much as possible of it removed without injury to the contiguous tissues. If removal of the nerve farther forward be desired, the incision can be extended anteriorly, even to the mental foramen (*d*, *f*), after tying, or by careful avoidance of the facial vessels. *Kühn*, through an incision around the angle of the jaw corresponding to the borders of insertion of the masseter (Fig. 315, *e*, *d*) muscle, and after resecting a portion of the angle of the jaw, exposed the nerve from below. *Lücke*, through a similar incision, raised the insertion of the internal pterygoid and other soft parts from the jaw with a periosteotome, until the nerve could be felt with the finger, when it was hooked, drawn down and resected. *Horsley* has proposed to accomplish the purpose by raising a flap composed of the skin and subcutaneous tissue only, limited behind by a vertical incision extending from just above the zygoma to the angle of the jaw, followed by its continuance forward beneath the jaw in a horizontal direction to the facial artery. The flap is lifted and turned aside, leaving Stenson's duct and the branches of the facial nerve undisturbed. The masseteric fascia is then divided between Stenson's duct and the temporo-facial branch of the facial nerve, and the opening increased to an inch and a quarter in diameter; the parotid is drawn toward the ear, and the situation of the posterior border of the jaw defined. Now the posterior two thirds of the masseter muscle are divided, and the outer surface of the bone is exposed until the sigmoid notch is clearly seen, when, with the aid of a bone drill, trephine, etc., the sigmoid notch is prolonged directly downward to the inferior dental foramen. With this method the nerve can be followed up and resected to within one third of an inch of the foramen ovale. The nerve can be reached promptly from the outer surface through a vertical (*Linhart*) (Fig. 315, *a*) or U-shaped incision, made directly down to the bone, beginning just below Stenson's duct and extending downward about two inches. The periosteum is then raised along with the associated masseteric fibers, sufficiently to expose the center of the ramus; the soft parts are drawn aside and the nerve is exposed at the foramen by aid of the trephine, or farther forward, if desired, by removal of the external table of the jaw with the chisel and mallet. In either case the nerve is stretched and as freely resected as possible.

The Precautions.—The external incisions expose to danger Stenson's duct and the branches of the facial nerve. The former runs forward on the external surface of the masseter to the buccinator muscle, which it enters opposite the second molar tooth, parallel with, and a finger's breadth below the zygoma. The directions of the branches of the nerve should be carefully studied before making the external incision, to avoid any motor paralysis of the face that may follow their division. On opening through the ramus of the jaw, the mylo-hyoid nerve may be mistaken for the inferior dental. However, the former is much the smaller, and if pulled upon is unfixed and enters soft intrabuccal tissues, while the latter is fixed when pulled upon, as it supplies bony tissues. The separation from the bone, or the division of the fibers of the masseter, must be performed carefully and aseptically, otherwise the advent of suppurative processes will prolong the recovery and impair the movements of the jaw. In resections of this nerve at either aspect of the jaw, the divided ends should be turned aside or tissues interposed between them so as to prevent regenerative union.

The inferior dental nerve can be exposed in the dental canal from the inferior dental to the mental foramen, if need be, by making a free incision down to the bone along the under surface of the jaw (Fig. 315, *d, f*), then raising the soft parts along with the periosteum with the elevator, drawing aside the flap, and exposing the nerve in the canal by the use of the electro-motor trephine, chisel and mallet, etc. The exposure of the nerve here is more a matter of labor than of skill; the final removal, however, is easily accomplished with scissors and forceps. The wound should be closed promptly, the same as are incised wounds in other situations. If undue violence be employed in the use of the chisel and mallet, the jaw may be fractured. *The termination of the inferior dental nerve and its mental branch* can be treated surgically by exposure of them at the mental foramen. *In stretching*, the breaking strain of the mental nerve is five and a half pounds. The mental nerve escapes from the mental foramen along with the mental vessels, opposite to the interval between the bicuspid teeth of the same side.

The Operation.—Draw the angle of the mouth downward and outward; make a horizontal incision one inch in length at the buccal fold, with the center opposite the interval before mentioned, through the mucous membrane down to the bone; raise the mucous membrane and periosteum with a director, so as to expose the mental foramen; dissect out the nerve, seize and stretch or remove it. If a trephine or chisel be applied to the jaw posteriorly to the foramen, and the outer table be removed, then the anterior extremity of the inferior dental can be exposed and resected, thus exercising some command over the incisive branches of that side.

The Lingual or Gustatory Nerve.—The lingual nerve is the sensory nerve of the anterior two thirds of the tongue. It is often treated surgically for the relief of the pain and sialorrhœa incident to cancer of the tongue.

The Anatomical Points.—The nerve passes between the internal pterygoid muscle and the internal lateral ligament of the lower jaw, and is located

internally and anteriorly to the inferior dental nerve. Although deeply placed at first, it becomes quite superficial as it reaches the floor of the mouth. *The guides* to the nerve are the last molar tooth of the lower jaw and the pterygo-maxillary ligament. The nerve is situated half an inch below and behind the last molar tooth, and in front of the pterygo-maxillary ligament, where, with the mouth widely opened and the tongue placed on the stretch, it can be felt as it passes beneath the mucous membrane to gain the anterior portion of the tongue. The pterygo-maxillary ligament is easily noted beneath the mucous membrane just inside the coronoid process, and it is somewhat tightened by opening the mouth widely.

The lingual nerve can be reached by either the intrabuccal or extrabuccal routes, the former being employed much the more frequently.

The Operation (intrabuccal route).—Open the mouth amply with the gag; draw the cheek aside with the retractor, and the tongue forward and to the opposite side with a tongue forceps; indicate the location of the nerve with the index finger placed at the point of insertion of the pterygo-maxillary ligament, then with a scalpel make a longitudinal incision one inch in length through the mucous membrane from this point forward, or make a vertical one of the same length over the nerve midway between the tongue and the gum at the root of the last molar tooth, thus easily exposing the nerve, which can be drawn forward with a hook and stretched or resected. *Neurotomy* may be practiced on this nerve by means of a bistoury passed through the mucous membrane at a point three quarters of an inch behind and below the last molar tooth, and curved forward and upward toward the jaw on an imaginary line extending between the last molar tooth and the angle of the jaw for the distance of half an inch. The comparatively brief relief afforded by this method does not commend its employment except as a temporary expedient.

The Operation (extrabuccal route).—The nerve can be reached through the submaxillary triangle by an incision extending from the anterior border of the masseter muscle to near the symphysis menti. The facial artery is exposed but not tied; the submaxillary gland is liberated of its facial connections and drawn downward and forward, thus exposing the mylo-hyoid vessels and nerves as they lie on the mylo-hyoid muscle. This muscle is drawn forward by means of a retractor applied to the posterior border. The lingual artery is displaced downward, and the lingual nerve then appears at the posterior border of the muscle, lying beneath the mucous membrane near to the last molar tooth. This method of procedure is not advisable on account of the intricate technique, unless the lingual artery is to be tied for malignant disease of the tongue, when the nerve can be wisely resected through the same opening. This nerve can be reached from without by the same procedures as those addressed to the inferior dental (page 285).

The auriculo-temporal nerve is easily exposed, as it crosses the base of the zygoma through a short vertical incision made immediately in front of the pinna (Fig. 313). Here the nerve lies behind the temporal artery, the pulsation of which serves as an excellent guide to it. Care should be exercised in the dissection at this point, otherwise the parotid gland will be injured.

The Buccal Nerve.—The buccal nerve can be exposed through either an *intra*buccal or *extra*buccal incision, the former being the preferable. Two methods of intra-buccal exposure are noted. *In one* the nerve is bared as it reaches the buccinator muscle, through a vertical incision in the mucous membrane and fibers of the muscle, made with its center at the middle of the anterior border of the ascending ramus of the lower jaw. The nerve at this situation divides into two branches; therefore care must be exercised in observation lest one or both branches, and even the trunk itself, escape notice. The operation will be futile unless the trunk of the nerve be secured and treated. *In the other method* open the mouth widely and make an incision along the anterior margin of the coronoid process through the mucous membrane, and grasp the nerve as it crosses this margin of the process. The fact that the nerve sometimes reaches the buccinator by passing through the temporal muscle invests the latter method with a reasonable degree of uncertainty, since then the nerve is not found at the anterior border of the coronoid process.

The Extrabuccal Method (Zuckerkan dl).—The extrabuccal method consists in making a short incision forward from the anterior margin of the masseter muscle between the zygoma and Stenson's duct down to the fatty cushion of the cheek. The cheek fat is pushed aside so as to expose the anterior border of the coronoid process along the inner surface of which the nerve is found to pass. This method of procedure exposes to the danger of injury the transverse facial artery and branches of the facial nerve.

The Results.—The results of division and excision are similar here to those of the preceding trials and like those results justify the trial before the others of graver import are attempted. Stewart, of Montreal, contributes the following conclusions regarding nerve-stretching in inveterate trigeminal neuralgia: "1. Nerve-stretching gives either complete or great relief in the majority of cases. 2. Relief is not permanent in more than five per cent of cases. 3. If pain should return, the operation should be repeated, even several times, before resorting to neurectomy or ligature of the common carotid. 4. If the pain is not strictly and always limited to one branch of the nerve, several branches should be stretched. 5. As relief does not always immediately follow stretching, a second operation should not be undertaken until some time has elapsed."

TRUNK OF THE NERVE AT THE FORAMEN OVALE.

The important anatomical points connected with the nerve at this situation are: 1, the large size—larger than either of the other divisions of the fifth; 2, the junction of the motor and sensory roots just after leaving the foramen ovale; 3, the numerous branches given off from the common trunk after the junction; 4, the relations of the middle and small meningeal arteries, the external pterygoid muscle and pterygoid plexus of veins and internal maxillary artery, all of which should be carefully studied before attempting the operation. The localization of the foramen ovale is a matter of the greatest importance. *Bony* and *muscular guides* indicate the situation with practical accuracy. The junction of the zygoma and emi-

nentia articularis is located about an inch and a quarter directly outside of the foramen; the free edge of the external pterygoid plate at the root of the process is just in front of the opening; the pterygoid muscles cover in the foramen and the trunk of the nerve. If the finger be inserted into the zygomatic fossa in front of the eminentia articularis, the nerve is

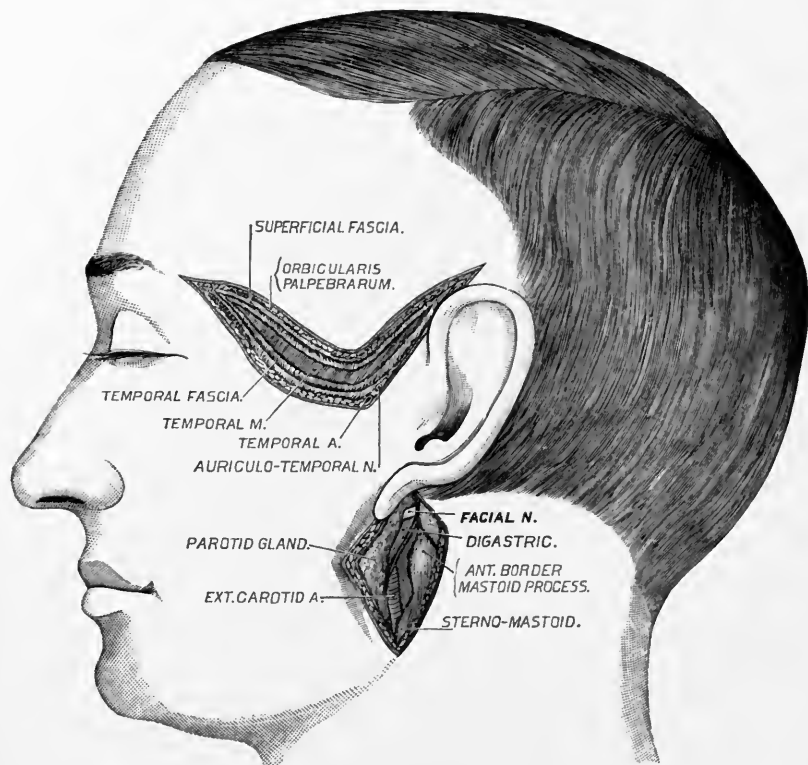

FIG. 314.—Incision for exposure of third division of trifacial nerve at foramen ovale and of facial nerve.

found between the base of the external pterygoid plate and the spinous process of the sphenoid, either of which can be easily felt. If now, as MacCormac says, “a knife be passed along the outer surface of the greater wing of the sphenoid and between the middle meningeal artery and the nerve trunk, the latter may be divided from behind forward with perfect safety.” However, if the middle meningeal artery escape injury at this time, the small meningeal and the lesser superficial petrosal nerve will quite surely be divided along with the motor root of the third division. Motor paralysis of the muscles of mastication, the mylo-hyoid and anterior belly of the digastric, the tensor tympani and tensor palati muscles, on the side of the section, will follow. attended with loss of sensation and relief from pain if the central end of the divided nerve be not involved. However, the motor paralysis has not sufficient significance to contraindicate the operation.

Kocher's Operation.—An incision beginning just behind the frontal process of the malar bone is carried obliquely downward and backward to the posterior extremity of the zygomatic arch, thence upward and backward in front of the ear at nearly right angle to the first part of the incision (Fig. 314), dividing fibers of the orbicularis, the superficial and temporal fasciæ at the first, and all tissues down to the bone at the second part of the incision. Draw the borders of the wound apart; expose the malar bone behind the frontal process and divide it vertically with a chisel; divide the zygoma posteriorly close to its anterior root, and draw the fragment down

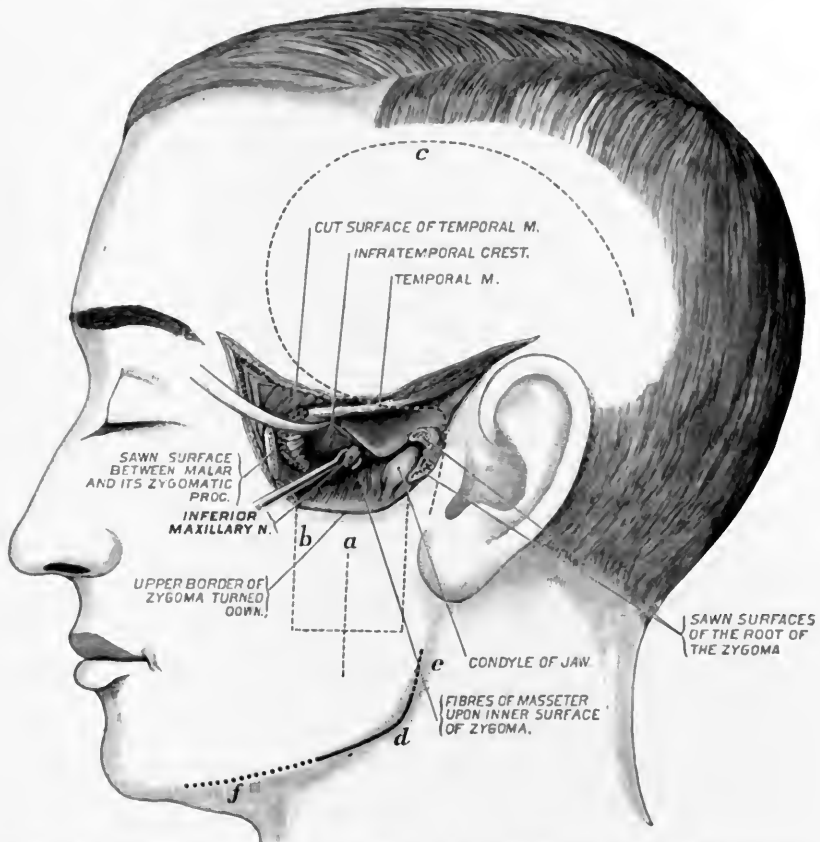


FIG. 315.—Exposure of the third division of the trifacial in its course and at the foramen ovale.

with a strong hook; expose the outer surface of the temporal muscle, separate its posterior and lower border from the skull, and draw it forward with a hook (Fig. 315); divide the periosteum from the anterior edge of the root of the zygoma forward along the pterygoid ridge; detach with it the soft parts from the under surface of the great wing of the sphenoid down to the base of the pterygoid process with a periosteotome; locate the foramen ovale with the finger, and expose the nerve to view, carefully avoid-

ing the middle meningeal artery lying posteriorly; stretch and resect the nerve; place and wire in position the zygomatic arch, unite the borders of the wound, and dress antiseptically. This plan of procedure exposes the vessels to the minimum amount of danger, and therefore gives rise to the least amount of hæmorrhage.

Pancoast's Operation.—Make a horizontal incision, near to where the ramus joins the body, the entire breadth of the perpendicular ramus of the lower jaw down to the bone; connect to the extremities of this incision two perpendicular ones of a similar depth as the first, carried upward to Stenson's duct, then superficially from that point to the zygoma and malar bone, carefully avoiding the duct (Fig. 315, *b*); raise the flap and saw through the coronoid process at the base, and remove the fragment along with the insertion of the temporal muscle; push the temporal muscle upward beneath the zygoma, and take away the fatty tissue thus exposed to view; tie the internal maxillary artery as it passes close to the internal surface of the neck of the jaw in two places and divide the nerve between the ligatures; detach the upper head of the external pterygoid from the great wing of the sphenoid with the finger; check hæmorrhage and expose the nerve at the bottom of the fossa and divide it with scissors close to the bone.

Krönlein's Modification.—In the modification of Krönlein the temporal fossa is uncovered by means of two flaps, a superficial and a deep one. The former corresponds in all essential respects to that of Pancoast. The latter is of similar shape and dimensions as the former, is composed of masseter muscle and the zygoma, the bone being sawn across anteriorly downward and forward through the zygomatic process of the malar at the point of articulation, and posteriorly, immediately in front of the articular tubercle, and the whole reflected downward on the masseter as a hinge. The inner flap is stretched rather than divided, to avoid injury of Stenson's duct and the facial nerve. The infra-maxillary nerve is then exposed and resected without loss of other essential structure. Through the pterygo-maxillary fissure the second division is then resected with a thin cutting instrument, and if possible without widening the fissure by chiseling. The separated structures are returned into position and fastened there; thus the aim is attained without the sacrifice of an essential part.

Credé's Modification.—In Credé's modification the nerve is reached through the sigmoid notch while the temporal muscle is drawn backward with a blunt hook. The internal maxillary artery is not seen. In other respects the procedures are similar.

Salzer's Modification.—In Salzer's modification the free end of the flap is formed a finger's breadth above the zygoma, going through the temporal muscle down to the bone. After the arrest of hæmorrhage, the flap is raised, including the zygoma, and carried down sufficiently to expose the roof of the zygomatic fossa. The upper part of the external pterygoid muscle is removed from the sphenoid with the finger, as before, and the nerve is exposed.

Mixter, by means of a curved incision commencing about half an inch below the zygomatic process of the malar bone and going upward along the posterior border of this bone and of the external angular process of the

frontal bone to the temporal ridge, thence along the temporal ridge, downward in front of the ear to a point half an inch below the zygoma, followed by severing of the zygoma at each end, forms a flap which when drawn downward, attended with separation of the temporal and pterygoid muscles, permits of a quite ready exposure of the superior and inferior maxillary nerves as they escape from their respective foramina at the base of the skull. *If the former nerve and its foramen* of exit is to be exposed the temporal muscle is drawn strongly forward, the jaw depressed, and the pterygo-maxillary fissure located by passing the finger along the posterior wall of the superior maxilla to the projecting spur at the upper end of the external pterygoid plate, which latter may be cautiously chiseled off, thus better exposing the nerve as it crosses the spheno-maxillary fossa just above Meckel's ganglion. *If the latter nerve and its foramen* of exit are to be exposed, the temporal muscle is drawn forward, the jaw relaxed, the pterygoid muscles so displaced by traction as to permit the finger to pass upward along the external pterygoid plate to a point just posterior and external to the base of the plate where directly inward, at a distance of about an inch and a half from the zygoma, the nerve will be felt as it escapes from the foramen ovale.

The Comments.—It will be noted that the details of this plan are not essentially distinctive from those just preceding, directed to similar purposes. And, too, they may be varied in technique by acceptable features of those methods when desirable. The further division of the zygoma should be made at a safe distance anterior to the eminentia articularis to avoid the joint.

The Precautions.—The internal maxillary, the meningeal vessels, and pterygoid plexus of veins must be carefully avoided. If exposed they should be ligatured at two places and severed between the ligatures to avoid the possibility of hæmorrhage. The middle meningeal is sometimes so closely associated with the nerve as to be scarcely separable from it. In such cases the contiguity can be determined with the finger by noting the pulsation. In fact, in each instance the artery should be thus located, if possible, before the nerve is divided. Pressure, direct ligature, and ligature of the internal maxillary and external carotid are the means for arrest of hæmorrhage. The average relation of this nerve and artery will appear in connection with intracranial operations on the nerve. The facial nerve and Stenson's duct have been mentioned sufficiently already to call for the exercise of extreme caution in this regard in the operative technique. The nerve should be divided close to the bone, to secure severance of all the branches. Free excision should be practiced, and the proximal end pushed upward into the foramen, when feasible, to secure as wide separation of the divided ends as possible.

The treatment consists in closing the wound after bleeding is completely arrested, and applying a firm compress to it; then dress antiseptically. If oozing persist, tampon with gauze and unite borders, leaving room for withdrawal of the tampon.

The Results.—The danger to life is not significant in this operation, unless infection of the wound or severe hæmorrhage supervene. Therefore

asepsis should be practiced sedulously and all bleeding controlled. The curative outcome of the operation is not infrequently discouraging.

INTRACRANIAL NEURECTOMY.

The operation of intracranial neurectomy is employed for the purpose of curing intractable cases of trigeminal neuralgia that have resisted medicinal and other operative means of relief. The operation contemplates the intracranial section of the second and third divisions of the trifacial nerve at the points of entry to the foramina of escape, the removal of the proximal ends of the divided nerves, and excision of the ganglion itself. *Two methods* of attainment of these objects are frequently practiced, one devised by Rose, the other by Hartley and Krause. In both the operation field is extra-dural.

Rose's Method.—The patient is prepared by giving proper attention to the bowels, stomach, kidneys, etc. The side of the head corresponding to the side of the face involved is carefully purified, the ear cleansed and plugged with gauze, the conjunctival sac made aseptic, and the lids stitched together.

The Operation.—For convenience of description the operation is divided into six stages:

The First Stage (incision through the skin and reflection of the flap).—A semicircular flap is made extending from about half an inch below the external angular process of the frontal bone backward along the upper border of the zygoma its entire length. From this point the incision is continued downward over the parotid region of the jaw, to just in front of the angle of the jaw, then forward along the lower border of the horizontal ramus to the facial vessels (Fig. 318, A). This flap is raised, carried forward, and fastened by a temporary suture to the upper part of the chin, and securely covered with protective gauze.

The Second Stage (section of the zygoma and coronoid process, displacement of masseter and temporal muscles).—The zygoma is cut down upon at either extremity and bared by a periosteotome or raspator. Two holes fitted to carry a silver wire of a twenty-two-inch gauge are drilled one third of an inch apart through the zygoma at the points of exposure—i. e., at the base of the projection and at the zygomatic process of the malar bone. The bone is then divided between the holes with a fine saw, the anterior section being directed obliquely downward and forward, the posterior more transversely, and as near to the root of the process as possible. The fragment of bone is now displaced carefully downward along with the masseter as far as practicable; the coronoid process and the tendon of the temporal muscle are easily and promptly exposed by the displacement and removal of a small amount of intervening cellular tissue; the coronoid process and a portion of the attached muscle are removed by the aid of bone forceps, scissors, or the Gigli-Haertel saw, etc.

The Third Stage (search for the foramen ovale).—Displace the pterygoid fat, locate the internal maxillary artery as it passes between the heads of the

external pterygoid muscle, tie it with two ligatures and divide the vessel between them. Detach the external pterygoid muscle from the great wing of the sphenoid and the pterygoid plate with a periosteotome, and push it downward. The base of the posterior border of the outer pterygoid plate is carefully located with the finger, and at a distance posteriorly of sixteen (in female) to eighteen (in male) millimetres is found the foramen with the nerve escaping through it.

The Fourth Stage (entering the base of the skull).—In order to effect this purpose, a half-inch trephine is applied a little anterior and external

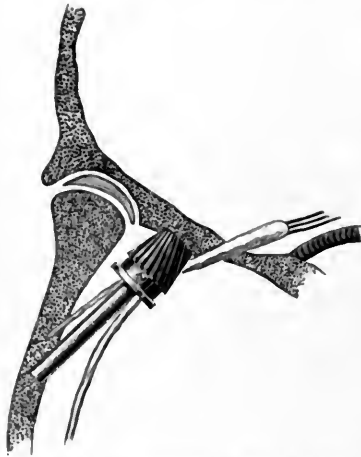


FIG. 316.—Trephining base of skull.

to the foramen, and in such a manner that the groove made in the bone will impinge on the outer wall of the foramen (Fig. 316). This opening can be enlarged subsequently in any direction by the use of bone forceps and chisels.

The Fifth Stage (division of the nerves and removal of the ganglion).—After making the opening in the bone, the trunk of the nerve serves as a guide to the ganglion. The ganglion is removed with forceps or a small curette directed along the course of the nerve leading to it. The nerve is a better guide when cut as far back as possible, and traction be made on the stump. The traction draws the ganglion forward somewhat, and thus facilitates the efforts at

destruction. The posterior part of the ganglion can be displaced more readily and removed than can the anterior and upper part, as the latter is closely connected with the dural sheath of the nerve. The second division is found and divided either before or during the removal of the ganglion (usually during) as best meets the indications for the accomplishment of that act. The ophthalmic division is not disturbed.

The Sixth Stage (replacement of structures and closure of the wound).—The zygoma is replaced and wired in position, and the skin flaps are properly approximated and sutured. If asepsis has been complete, no drainage is necessary. Continuous pressure with sponges or properly arranged pads for two or three days will cause suitable apposition for prompt union. The eyes should be protected from light by unirritating aseptic pads fastened lightly in position.

The Hartley-Krause Method.—The Hartley-Krause method can be divided into five stages, but, unlike the Rose method, it offers better opportunity for manipulation and aseptic technique, and, therefore, is followed by better results than the latter (Fig. 318).

The First Stage (forming and raising the flap).—After thorough disinfection of the ear, scalp, etc., a horseshoe-shaped incision is made down to the bone in the course of a line drawn from just behind the external angular

process of the frontal bone upward with an anterior convexity to the supra-temporal ridge, then backward and downward with a posterior convexity to just in front of the tragus of the ear (Fig. 318; *B*, Hartley; *C*, Krause). The base of the flap in this instance corresponds to the zygoma, and lies

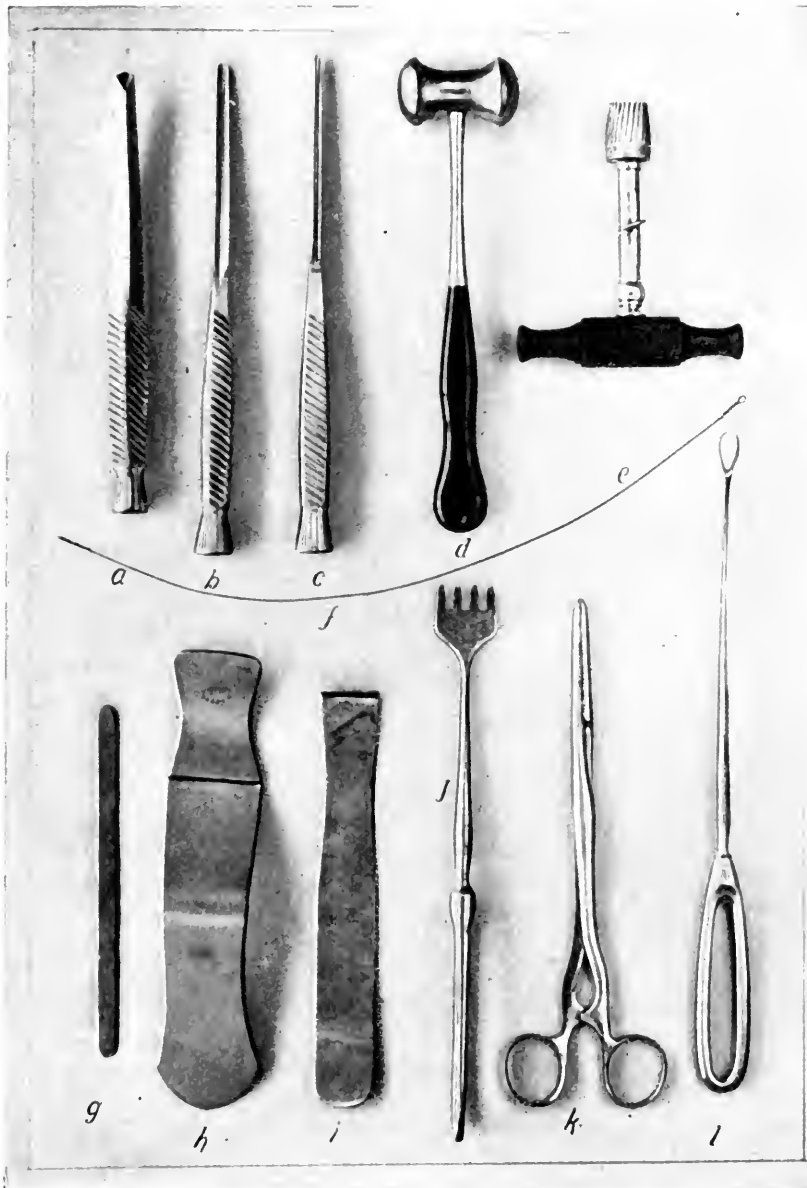


Fig. 317.—Instruments employed in intracranial neurectomy.

a. Pyle's chisel. *b*, *c*. Hartley's chisels. *d*, *e*. Mallet and trephine. *f*. Gigli-Haertel saw. *g*. Flexible spatula. *h*. Hartley's brain retractor. *i*, *j*. A common flexible and a hooked retractor. *k*, *l*. Forceps to twist away and eurette to scrape (?) away the ganglion.

between the points of starting and termination of the curved incision. The flap thus formed is three inches in both the vertical and transverse diameters. Arrest the hæmorrhage; retract the borders of the incision carefully; cut a groove in the line of periosteal division down to the inner table in a beveled manner (Fig. 319) at all parts except at the upper border, and here through both tables, and here through

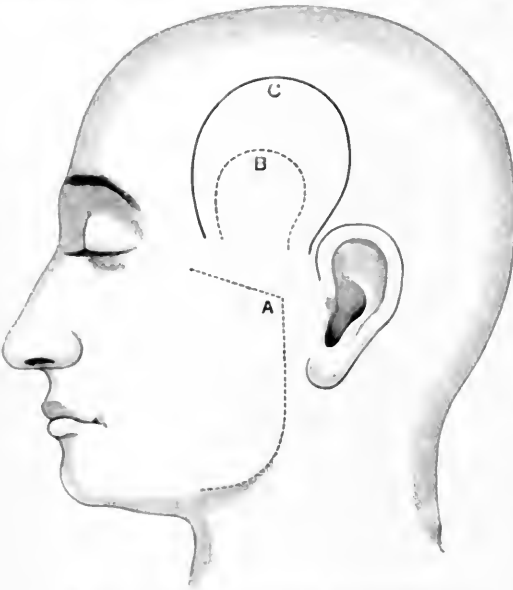


FIG. 318.—Lines of incision in intracranial neurectomy.

both tables, and here through both tables with the chisels of Hartley or that of Pyle (Fig. 317, a, b, c). The flap is now pried off by inserting beneath the bone at the completely divided border a bone elevator, which act causes fracture at the basal end of the undivided vitreous table. Expose the dura by turning down the flap (Fig. 320), the bony portion of which is securely held by a hinge composed of integument, muscle, and periosteum.

The Second Stage (treatment of the middle meningeal artery).—Hæmorrhage from the middle meningeal and its branches often happens, and is

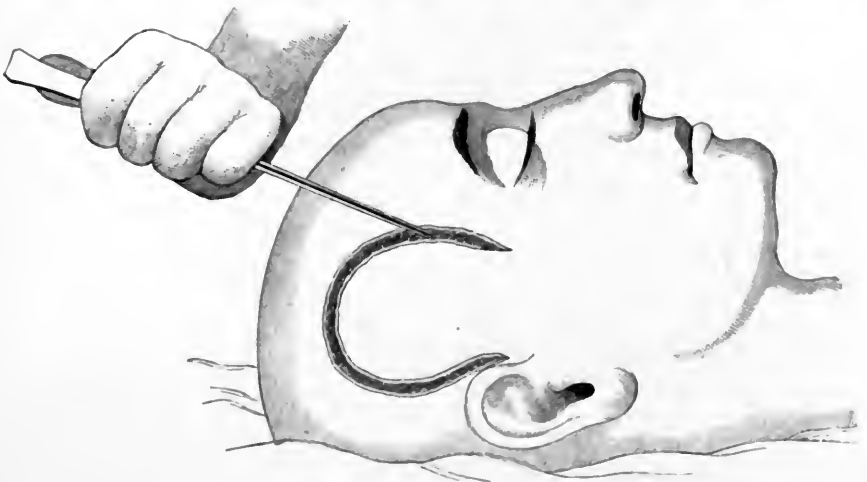

FIG. 319.—Making the bone flap.

frequently very troublesome. If the anterior branch happens to run in a canal instead of a groove at the base of the flap, it will be almost surely torn

across (Fig. 274). In separating the dura from the bone at the entrance to the fossa, the main trunks may be ruptured. After exposure of the dura, the vessel should be isolated and tied as promptly and securely as possible. If the vessel be torn, prompt pressure is applied, the vessel exposed by cutting away the bone and then tied with silk. If the main trunk be ruptured, and can not be otherwise secured, prompt pressure, followed by plugging of the foramen spinosum with gauze for three days, will permanently arrest the bleeding (Keen).

The Third Stage (raising temporo-sphenoidal lobe).—Separate the dura from the bone carefully with the fingers; raise the brain cautiously with a broad spatula from the middle fossa preparatory to exposure of the Gasserian ganglion and the second and third divisions of the nerve. The separation of the dura is attended with quite free hæmorrhage in nearly every case, but in most instances patiently employed sponge pressure will arrest it. Failing in this the fossa is packed with iodoform gauze and the wound closed and dressed; the gauze is removed on the third day and the operation completed.

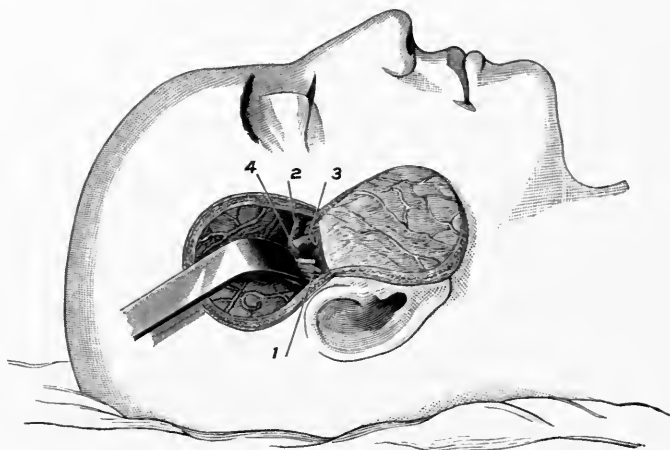


FIG. 320.—1, 2, 3. Branches of fifth nerve. 4. The ganglion.

Keen advises this course, and has practiced the introduction freely in three separate instances: in one, a strip 37×6 inches, in another 23×14 inches, in a third 16×6 inches, was introduced, and “in each instance the gauze remained in place for three days without any material symptoms.”

The Fourth Stage (recognition and removal of ganglion and nerves).—It is very important at this time that a good light be at hand (Fig. 111), in order to enable the surgeon to act in an exact and intelligent manner. The carotid artery and the cavernous sinus may each be opened, if careless, blind, or mis-directed attempts be practiced in removal of the ganglion. Keen advises that the head rest on the occiput, and that a side light be employed, for in this position the blood flows away from the ganglion instead of obscuring it, as when the head lies on the side. Arrest the hæmorrhage and locate the nerve by either the sense of sight or touch. The middle meningeal artery

as it passes through the foramen spinosum lies from one fourth to one half inch outside of the foramen ovale which transmits the third division, and it is therefore a guide to this division. Lifting the dura will cause two lines of tension of the membrane, which will lead to the foramina of exit of the second and third divisions respectively. Expose and separate the nerves from the dura; follow the nerves backward to the ganglion, separating the membrane from them, and then from the ganglion itself by blunt dissection and traction of the membrane. Isolate the ganglion and the second and third divisions on all sides; seize the part of the ganglion corresponding to second and third divisions with hæmostatic forceps, divide with scissors the second and third divisions at the foramina, then rotate the forceps gently and firmly, thus twisting away the ganglion and the divisions, including possibly the motor root.

The Fifth Stage (closure of the wound).—After complete arrest of hæmorrhage and the introduction of drainage when required, return the temporal flap to its place and confine it there by sewing the borders of the divided periosteum and scalp independently of each other with catgut. Dress the wound aseptically, put the patient in bed, and treat indications as they arise.

The Precautions.—In fashioning the skin flap in Rose's method avoid going so deep as to injure the branches of the seventh nerve or Stenson's duct. As the tendon of the temporal muscle is attached lower on the inner than on the outer surface of the coronoid process, more difficulty will be experienced in its division at the former situation. The possession of a strong electric light and reference to a dry skull will help much, indeed, in the localization and inspection of important parts. In making the opening with the trephine at the base of the skull, it must be remembered that the thickness of the bone at this situation is unequal, being thinner at the outer than at the inner margin of the trephine track. And, inasmuch as the instrument must be applied to the bone obliquely, the division of the outer part of the circle will be made more quickly. If these facts be not heeded or proportionate care be not exercised, the dura will surely be lacerated by the instrument.

The Complications.—Hæmorrhage is the only complication of special significance. The middle and small meningeal arteries may be injured during approach to the ganglion, and the cavernous sinus, during its removal. It has been demonstrated recently (Taylor) that the foramen spinosum is sufficiently far from the foramen ovale so that the approach to the latter can be safely made without injury to the middle meningeal artery in a majority of instances. However, in some cases the foramen spinosum is so nearly in the line of approach to the foramen ovale, that hæmorrhage from the middle meningeal is avoided only by finding, ligaturing, and dividing this vessel in advance of the extended procedure. Brisk hæmorrhage from the small meningeal which passes through the foramen ovale is to be expected. If the vessel can be secured in advance, well and good; if not, then ligature at the time of the bleeding will suffice. Sometimes free hæmorrhage arises at the time of removal of the ganglion, due, perhaps, to involvement of the sinus.

For this reason, great pains should be taken to limit the manipulations to the ganglion alone, as a deviation therefrom may involve a contiguous sinus. If hæmorrhage arise from this source, a tamponade of iodoform gauze should be applied and permitted to remain until the bleeding is finally arrested.

The Remarks.—The right side is affected twice as often as the left; the third division alone, ten times; second, six times; all divisions, twenty-two times. The first division is never affected singly (Tiffany). If the bony opening be too small, it can be increased with a rongeur at will. Tiffany in his "later operations" has omitted replacement of the bone flap, and now sees "no special reason for so doing—i. e., replacing it." Evacuation of the cerebro-spinal fluid by limited incision of the dura, which is closed promptly thereafter, greatly facilitates the raising of the brain from the floor of the skull. An unusual depth of the anterior fossa and adhesion of the dura increase the difficulty of the operation. The first division of the fifth nerve should not be disturbed, as this part of the nerve is not affected singly. However, the second and third divisions and the corresponding parts of the ganglion should be completely removed, also the remaining part of the ganglion if practicable. The saving of the motor branch of the third division is not necessary, except both sides be subjected to the operation, when, of course, the muscles of mastication would be incapacitated. Keen regards it scarcely possible to save this branch.

Many surgeons use the electro-motor (Fig. 281) and Gigli-Haertel saw (Fig. 317, *f, i*) in making the bone flap, since the concussion incident to the use of chisel and mallet is thus avoided. These saws, along with a small trephine, placed at *intervals*, serve to establish the size and shape of bone flaps, which can be made nearly square or otherwise modified.

The Results.—*Lexer* reports two hundred and one cases with 94.4 per cent apparently cured, with seventeen per cent mortality.* *Keen* reports twenty-two cases with four deaths from *Rose's* operation, and fifty-one cases with five deaths from the *Hartley-Krause* method. *Tiffany* reports one hundred and eight cases with a death rate of twenty-two and a fifth per cent. Shock and sepsis each caused a third of the deaths. The recurrence of pain more or less severe after presumptive removal of the nerves happens in four or five per cent of the cases. But recurrence of pain after "known removal" of the ganglion is not yet recorded (*Tiffany*).

The Sequels.—Corneal ulceration is a sequel of significance, and perhaps may be due to too free meddling with the first division and the upper part of the ganglion. Some atrophy of tongue and eye follow in many cases.

Loss of sensation of the face and meningitis are also sequels of this operation. The former is inevitable, but sensation is regained in an astonishing manner. The danger of sloughing of the eye can be reduced to a minimum by exclusion of light and other forms of irritation, and the maintenance of cleanliness by stitching together the lids at the center and washing beneath them from time to time with a warm boric acid solution for four or five days, followed by their liberation and the use of a proper shield (*Keen*).

* Arch. f. klin. Chir., Bd. lxx, H. 4.

The division with the nerves of the tubular meningeal prolongations that surround them exposes the meningeal space to danger of infection. Still, if the wound be aseptic, little fear of this complication need be entertained.

Doyen's Method.—Doyen's method seems to offer proper access to the ganglion with less injury of the brain, and perhaps better observation than the preceding methods. However, the trials necessary to establish its worth are lacking. The following excellent description of the procedure is quoted from the *Annals of Surgery*, January, 1896:

"1. A sickle-shaped incision is made through the soft parts over the temporal region (Fig. 315, *c*). The vertical portion, corresponding to the handle of the sickle, is from five to six centimetres long and is made in the space between the external auditory meatus and the outer angle of the orbit. This incision should pass not more than fifteen millimetres below the zygomatic arch, and should avoid as far as possible the branches of the facial artery and nerve.

"2. Resection of the zygomatic arch close to the condyle, division of the coronoid process, and denudation of the temporal fossa.

"3. Identification of the inferior dental nerve, which divides two or three centimetres lower down; identification of the lingual nerve. Both are then divided and the cut ends held by toothed forceps. The internal maxillary artery is ligated close to the point of origin.

"As soon as the isolation of the trunk of the inferior maxillary division as far as its point of exit from the foramen is assured, the skull is opened by a trephine or other suitable means at the level of the speno-temporal suture. By means of suitable cutting forceps the greater wing of the sphenoid and the squamous portion of the temporal bones are removed bit by bit over the entire area of the lower portion of the temporal fossa exposed by the previous resection of the zygomatic arch.

"As soon as the antero-posterior ridge formed by the union of the vertical portion of the greater wing of the sphenoid with its base is reached, the basal part is attacked, and progressively removed as far as the foramen ovale. The external semicircumference of this is removed by the final cut of the forceps. The area of bone removed in the course of the operation is shown in Figs. 321 and 324.

"The forceps are still attached to the inferior dental and lingual nerves, and with their aid the trunk of the inferior maxillary is raised, and the intradural pocket in which the ganglion lies is opened from the outer side. Traction can then be made upon the ganglion itself, and with a little care its anterior and posterior aspects are exposed and freed from attachments. The superior maxillary division is made free in like manner as far as the foramen rotundum where it is divided; finally, the ophthalmic division is cut at the sphenoidal fissure.

"When, as was the case in the first patient upon whom Doyen operated, the superior maxillary division has previously been severed beneath the orbit, a little tension and manipulation will usually suffice to remove the remainder of the nerve.

"The ophthalmic division is divided at its entrance into the sphenoidal

fissure. By the aid of a small elevator the entire periphery of the ganglion is completely freed, and made movable by traction upon its efferent nerves, which renders it possible to expose the superior border of the petrous portion of the temporal bone and the dural canal which serves as a sheath for the primary trunk of the trigeminus beneath the superior petrosal sinus. This

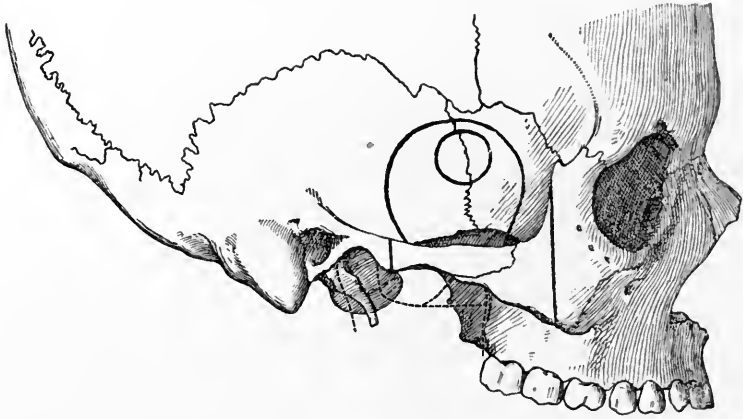


FIG. 321.—Outline of bone removed at side of skull.

last nerve trunk is isolated in its turn, and then divided instead of the ganglion upon the posterior aspect of the petrous bone beneath the venous sinus.

“The carotid artery is seen at the bottom of the wound protected by a thin, fibrous sheath. It is easy to avoid wounding the cavernous sinus, provided the operator be careful and skillful.”

Cushing's Method.*—Cushing by this method avoids the middle meningeal artery while approaching the ganglion through a comparatively straight route, thus limiting the danger from hæmorrhage and from manipulation of the brain—i. e., securing a maximum exposure with a minimum danger from cerebral involvement and hæmorrhage.

The Operation.—Make a horseshoe-shaped flap, with the base at the zygoma, about 4 centimeters ($1\frac{1}{2}$ inch) wide and 5 centimeters (2 inches) high; turn downward the skin flap to just below the zygoma, tying the temporal vessels and exposing the corresponding temporal fascia down to the zygoma; make through the temporal fascia an incision concentric with and just within the border of the skin incision, down to the middle of the outer surface of the zygoma, then along this surface, through the periosteum to the opposite border of the flap; separate from the zygoma the periosteum, except at the attachment of the masseter muscle, and sever the bony arch at the anterior and posterior extremities with saw or forceps; make an incision through the temporal muscle down to the bone, concentric with the preceding one; raise the divided muscle and turn it firmly downward along with the fascia and resected part of the zygoma, thus exposing down to the

* Jour. Amer. Med. Ass'n, April 18, 1900.

zygomatic ridge (infra-temporal crest) the lower portion of the temporal fossa; make an opening about 3 centimeters ($1\frac{1}{4}$ inch) in diameter—limited below and perhaps involving the zygomatic crest—through the most prominent portion of the wing of the sphenoid down upon the dura with

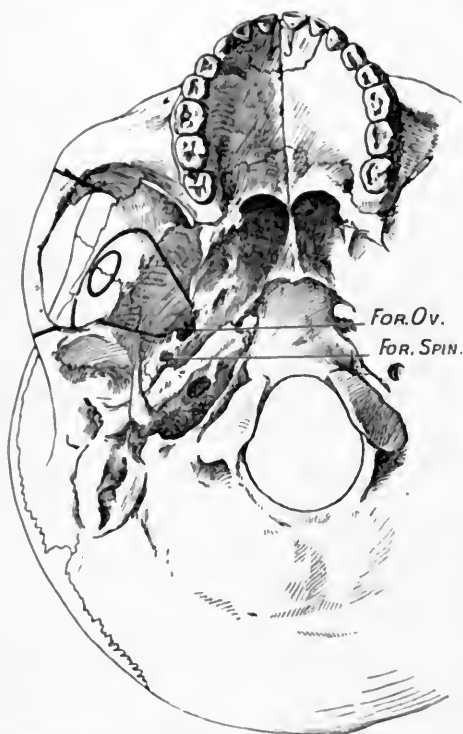


FIG. 322.—Outline of bone removed at base of the skull.

trephine, mallet and gouge, and rongeur, thus revealing the dura and the meningeal artery as it crosses the opening; expose the upper surface of the ganglion and its branches, especially (Fig. 323) the sensory root by, 1, raising from the base of the middle fossa the dura, back to the foramen ovale by, 2, careful blunt dissection of the dura from about the oval and round foramina and the space between by, 3, splitting the edge of the dural envelope encasing the ganglion and its peripheral branches, raising up the superior covering of these structures, permitting them to remain undisturbed on the underlying part of the envelope; liberate the ganglion, its anterior branches and its sensory root from the underlying connections by, 1, liberating by blunt dissection the second and third branches and the ganglion by, 2, freeing the superior (Fig. 324) and internal borders of the sensory

root and the first anterior branch by similar means by, 3, grasping with hæmostatic forceps the ganglion at the trigeminal root, followed by cutting with scissors the peripheral branches just before their escape from the skull, finally the evulsion of the sensory root with the attached forceps and the removal of the entire mass.

After arrest of hæmorrhage and thorough cleansing of the wound restore the superficial tissues to their respective places, stitching each in turn to corresponding structures, including the zygoma, cover the eye with rubber protective, dress the wound in the usual manner, carefully avoiding pressure upon the eye.

The Remarks.—It is very important to heed the fact that the opening into the skull is sufficiently low to permit of the elevation of the dura and of approach to the ganglion *beneath* the meningeal artery, thus avoiding the danger of hæmorrhage so often attendant on the approach from above. Paralysis of the corresponding occipito-frontalis muscle is a com-

mon sequel. The firm attachment of the masseter suggests the preservation rather than the removal of the resected zygoma. The small size of the opening, its comparatively obscure and protected situation, renders a bony flap of no special benefit. The bone at the *upper* part of the area of approach is thin and should be attacked with caution, to avoid injury, especially of the meningeal artery, which passes immediately beneath. The thickest portion is below, and can be removed with the rongeur. Fragments of bone should be carefully excluded from the wound, as they may cause much trouble. The ganglion should not be liberated until after the superior covering is raised and the branches are exposed and liberated, thus postponing the bleeding that so often attends the elevation of the ganglion, also facilitating the uncovering of the ganglion and the elevation itself. The lib-

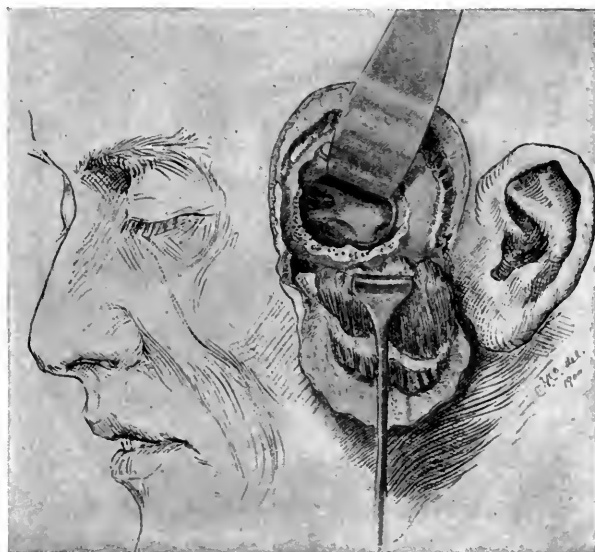


FIG. 323.—Intracranial neurectomy, Cushing's method. The exposure of the ganglion.

eration and extraction of the ganglion and its connections are difficult, and are greatly facilitated by preliminary training on the dead body. Only experience can practically adjust the degree of force needed to safely accomplish the purpose. Manipulation at the foramen ovale, injury of the cavernous sinus in freeing the first division and the ganglion, and injury from attendant mishaps, each causes a hæmorrhage more or less severe, but which usually yields to gauze pressure of a few moments' duration. The sixth nerve is frequently injured in isolating the ophthalmic division, and the sympathetic always because of its direct and indirect connection with the ganglion itself. However, the effects of these injuries may soon subside.

The Results.—The following communication to me from Dr. Cushing, written March 9, 1904, explains itself: "I have personally had twenty cases, one of which did not survive the operation; the fatal result, however, being explainable on grounds other than the craniotomy itself. The operation

should be conducted between the two fixed points of the meningeal, which should not be injured either at the foramen spinosum or at the sulcus arteriosis. In addition to the twenty cases of my own, I know of about

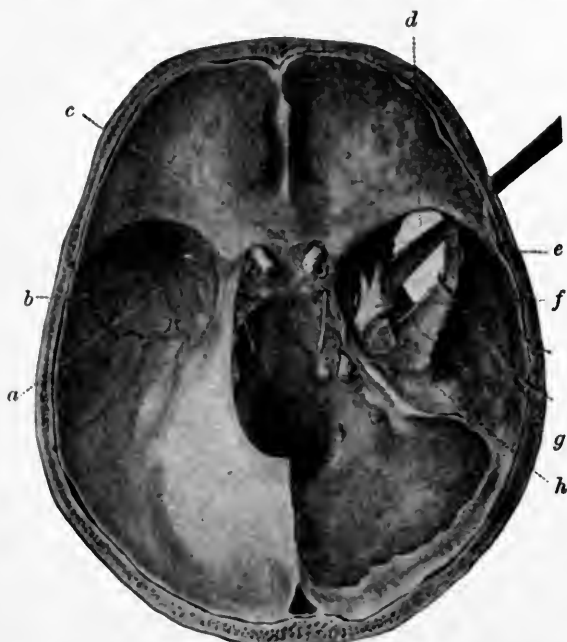


FIG. 324.—Intracranial neurectomy, Cushing's method. The liberating of the ganglion. *a.* The middle meningeal artery. *b.* The size of operative opening. *c.* The abducens nerve. *d.* The opening in skull. *e.* The middle meningeal artery. *f.* The semilunar ganglion. *g.* The reflected dura. *h.* The dura propria of ganglion.

thirty more, in which only one or two deaths occurred. The method applies, of course, only to the approach. The treatment of the ganglion itself is or should be the same in all methods. I have always endeavored to remove the ganglion in its entirety and have succeeded in about 80 per cent. of the cases."

Abbe's Method.*—Make a vertical incision through the soft parts of the temporal region down to the bone upon the middle of the zygoma; draw the borders of the wound apart by retractors, exposing the sphenoid bone; make an opening an inch and a half in diameter through the bone, disclosing the dura; raise the dura from the middle fossa, revealing the second and third divisions of the nerve; grasp each nerve trunk with an artery clamp close to its foramen of exit and divide it with scissors; cut off with scissors, or avulse the branches from the ganglion by means of the forceps already closed in place; arrest hæmorrhage by packing, and then place over the foramina of exit of these nerves a sterilized piece of gutta-percha tissue an inch and a half long and three fourths of an inch wide; press carefully into place this tissue with iodoform gauze, leaving the gauze in place for

* *Annals of Surg.*, Jan., 1903.

a few moments, then withdraw it, permitting the ganglion to rest upon the gutta-percha tissue; close the wound by deep stitches in the usual manner, providing drainage for a short time to secure dry healing.

The Remarks.—Abbe reports several cases of his own showing excellent primary results, all of which are cured, the extremes being six years and six months respectively. If this method of practice should prove equally as efficient as those of greater severity, then, indeed, will much have been accomplished. However, since there are reasons inviting doubt in this regard, further experience is quite essential for final determination.

The Spiller and Frazer Method.*—This method essentially consists in substituting division of the sensory root of the ganglion for other methods of practice. Should the outcome show that failure of regeneration of the divided or resected nerve prevents the return of the affliction, then, indeed, will the technique be simplified and the dangers and sequels correspondingly lessened. The technique of approach to the special operation field in this instance need not essentially differ from others already described.

Horsley's Intradural Operation of division of the nerve at the base of the skull through an opening into the middle fossa made in the temporal region is a bold conception, which, however, appears to be needlessly dangerous for the purpose and even unnecessary, in view of the results and the increased thoroughness of removal by the extradural methods.

The Facial Nerve.—The facial nerve is exposed for the purpose of stretching to arrest spasm of the muscles supplied by it, and also it is bared not infrequently in some part of its course at the outset of an operation contiguous to the nerve, to avoid the effects of unnecessary injury of the trunk or the larger branches at that time. *The bony guides* to the nerve are the mastoid process, the zygoma, and the angle of the lower jaw. The insertions of the sterno-mastoid, the digastric, and the prevertebral muscles can be classed as the muscular guides. A point about midway between the angle of the jaw and the zygomatic arch indicates the situation of the nerve as it passes forward from the foramen of exit. The nerve can be exposed through an incision made behind (Baum) (Fig. 314) or in front (Hucter) of the pinna. The former method is the better one.

Baum's Operation.—Begin the primary incision just behind the pinna and on a level with the external auditory meatus, carry it downward and forward to nearly the angle of the jaw, passing immediately below the lobule, and curve it upward slightly at this point. Divide the superficial and parotid fasciæ; expose the posterior border of the parotid gland and the anterior border of the tendinous fibers of insertion of the sterno-mastoid muscle, and draw these structures apart with hooks. Expose carefully the anterior border of the mastoid process, and at a point about one third of an inch in front of the center of this border the nerve is found at a point about half an inch from the foramen of exit. The origin of the digastric muscle is seen close at hand, posteriorly. The nerve is then caught up and stretched by means of a blunt hook with a force equal in weight to five or six pounds.

* University of Pennsylvania Med. Bull., Dec., 1901.

The Comments.—The operation is easy in those of spare development, but in fleshy and muscular subjects it is often accomplished only with considerable difficulty. After the exposure and clearing of the space between the gland and the insertion of the sterno-mastoid, the employment of electricity

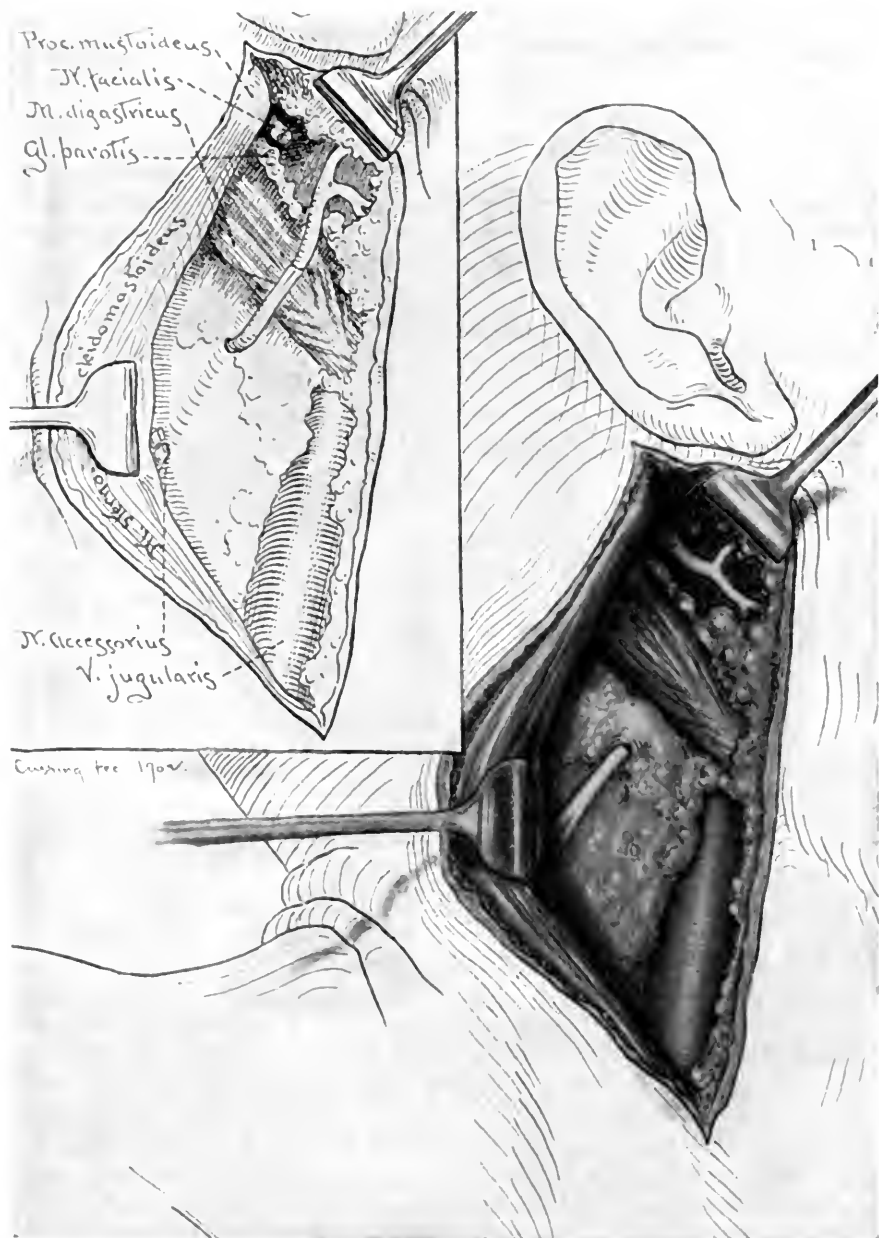


FIG. 325.—The repair of facial nerve by means of spinal accessory nerve.

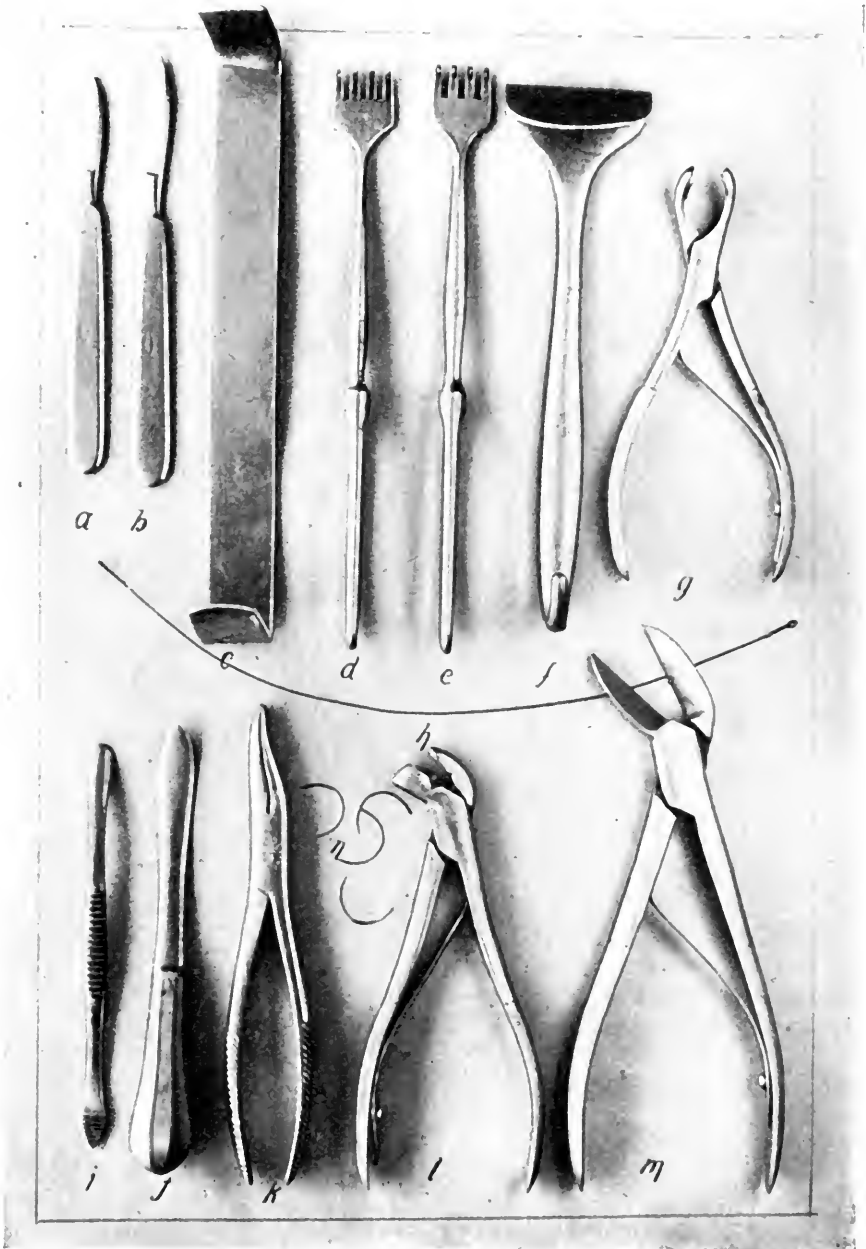


FIG. 326.—Instruments employed in laminectomy.

a, b. Scalpels. *c, d, e, f.* Retractors. *g.* Rongeur. *h.* Gigli-Haertel saw. *i.* Bone elevator. *j.* Periosteotome. *k.* Sequestrum forceps. *l.* Keen's bone-gnawing forceps. *m.* Liston's bone-cutting forceps. Forcepressure and ligatures in abundance, drainage agents, etc., are needed.

by means of a wet sponge to the face and a fine wire electrode in the course of the nerve will promptly demonstrate the situation of the nerve, and thus avoid unnecessary delay and injury of the tissues (Keen). The irritating of the nerve in the wound with a probe will likewise cause diagnostic manifestations of its presence there. If the nerve be seized too far down, the fibers of the posterior auricular and styloid branches will escape the full effect of the stretching, therefore the trunk should be followed upward and stretched at a point above the origin of these branches. A strong light, good retractors, and vigorous sponging greatly facilitate the securing of the nerve.

The Results.—Temporary relief is secured promptly; but since the function of the nerve is restored in from a few days (seven) to twelve months in the majority of cases, a satisfactory cure can not be promised. However, as a number of cases have been relieved for a year or more, the outlook can be regarded as justifying further attempts in this direction.

Facial Paralysis, Extra-cerebral Origin, Operation for (Cushing).*—In this operation the facial is repaired at the expense of the spinal accessory in the following manner: Expose each nerve by the methods already described (pages 307, 319) a sufficient length to permit of unrestrained contact of the divided extremities; omit dividing either nerve until both are suitably prepared for final transfer and union; pass a delicate silk traction suture through the perineural sheath of the selected portion of each nerve, close to the point of proposed division; sever in turn and carefully raise, aided by the traction sutures, each nerve for the requisite length from their respective beds, preserving their perineural connective tissue; unite without tension the apposed ends of the divided nerves at those points by means of curved intestinal needles armed with delicate threads of split silk (Fig. 325); arrest all oozing, unite the borders of the wounds carefully and apply moderate pressure to the surface; dress and care for the wounds with the greatest degree of caution.

The delicacy of this operation in all essential details is of such an important character as to preempt a full and unstinted outlay of the precautionary minutiae. The great aim to be achieved and the gloom of disappointment that would attend defeat in such cases as these is a matter of prime significance. The presence of infection in the wound or the employment of a too vigorous or thoughtless technic might easily result in defeating the purpose, leaving the parts involved less suited for surgical effort than before the attempt. In instances of successful union of the transferred parts the function of the impaired nerve is restored gradually and only after considerable time. Stimulating the transferred nerve causes grotesque and unmeaning facial movements, which, although active at first, progressively diminish and finally cease entirely, or at least are a source of no annoyance. These facts suggest that the nerve selected for the purpose of repairing of function be one where normal combined function may be depleted without signal loss of power of the part supplied, also where transferred influence will cause a minimum degree of disfigurement of facial

* *Annals of Surgery*, May, 1903.

expression. It seems to us wise that the patient or the friends be made aware of the effect of the operation at the outset.

The Remarks.—Other contiguous motor nerves may be utilized for the purpose, as the hypoglossal (Frazer*) and spinal. The accessory nerve enters the mastoid muscle about two inches below the tip of the mastoid process. The division of the nerve at the point of entering the muscle should afford sufficient of its structure for transplantation. The usual muscular changes incident to division of the accessory nerve follow here, but are of minor importance compared to the infliction of the face calling for remedy. Some time is required for the abatement of the associated movements incident to stimulation of the transferred nerve.

OPERATIONS ON THE SPINAL CORD AND SPINAL NERVES.

Inasmuch as approach to the spinal cord for the removal of agents or conditions that impair or annul its functions requires the displacement or removal of superimposed tissues at the seat of involvement, and since the character of these tissues is substantially similar throughout the entire course of the cord, the explorative operative procedure differs in no essential respect at the various parts of the spine.

Laminectomy.—The operation of laminectomy is one of comparatively modern birth, and as yet of a limited application. It is employed to relieve the spinal cord of otherwise irremediable pressure. The dangers of the operation are pronounced, and all available measures should be employed to forestall and counteract their occurrence. Sepsis, hæmorrhage, shock, and impaired respiratory force are each of decided significance, and if perchance they be combined in an individual case, the outcome is scarcely a matter of conjecture. While these dangers are not enumerated here in the order of probable occurrence, still the enumeration is one of logical sequence in the forethought of prevention.

Sepsis.—Thorough antiseptic preparation of the patient and of the details of the procedure will prevent infection, if it has not already happened as the result of the injury, or has been invited by the oversights and accidents of subsequent treatment. Considerate treatment of the tissues during the operation, and intelligent drainage and dressing subsequent to the act, are very important factors in this respect.

Hæmorrhage.—The hæmorrhage is free and often persistent, on account of the size and great number of the vessels involved in the procedure. However, the prompt use of forceps and the liberal employment of hot water and sponge pressure robs this danger of grave significance.

Shock.—The mutilation of the parts and the loss of blood attendant on the operation, combined with the mental and physical depression resulting from the original injury, should not be underestimated or considered lightly. When circumstances will permit, the patient should be prepared for the operation with due consideration to mental and physical complaisance, and the need of heart tonics. Physical warmth as provided by an abundance of hot-water bottles and woolen blankets should be employed. All unneces-

* Progressive Medicine, March 1, 1904.

sary exposure of the body or limbs should be avoided with sedulous care during operation.

Impairment of Respiratory Force.—The impairment of the auxiliary forces of respiration dependent on interference of the functions of the spinal cord, together with the impediment to breathing incident to necessary abdominal decubitus of the patient, incite not infrequently troublesome and even dangerous respiratory manifestations. Therefore the patient should be so placed and supported as to interfere as little as possible with the respiratory forces, the head being placed over the end of the table to meet the requirements of the anæsthetist.

The Operation of Laminectomy.—Make an incision in the median line four or more inches in length down upon the apices of the spinous processes of the vertebræ, the center of the incision corresponding to the seat of the disease or injury. Separate the tissues at one side from the spinous processes and laminae of the vertebræ by carefully directed incisions made with a knife, drawing the structures aside with broad, thin retractors as soon as severed from their connections, thus exposing completely the posterior bony wall of the spinal canal. Arrest hæmorrhage by forcipressure and packing with sponges saturated with hot water, withdraw the retractors, and allow the tissues to return toward the median line. Having treated the opposite side in a similar manner, again expose the primary wound to the fullest extent, and with a raspatory scrape off and remove the muscular tissue remaining attached to the bones. Repack the wound, and repeat this procedure upon the opposite side (Fig. 327). Draw aside the tissues from the median line, and divide the supraspinous and infraspinous ligaments with a scalpel, carefully avoiding the membranes of the cord; gnaw away successively the spinous process and lamina of one or more vertebræ with the rongeur forceps or remove with the Gigli-Haertel saw sufficiently to admit to the spinal canal the laminectomy forceps, with which the laminae are divided, and when removed the contents of the spinal canal are exposed to view (Fig. 328). A sharp hæmorrhage often arises from the superficial plexus of veins at this time, but it is arrested easily by sponge pressure and hot water. Lying beneath the arches of the vertebræ and upon the dura there is a considerable amount of closely woven connective tissue, supporting in its meshes a troublesome plexus of veins. This tissue is carefully divided in the median line down upon the dura, bleeding being arrested in the usual manner, as it occurs.

The Examination of the Contents of the Canal.—A posterior concavity of the spine should be established by a pad placed at either extremity of the trunk (Chipault) before examination is commenced. (A bluish dura indicates the presence of blood, and a yellowish of pus beneath it; increased tension and firmness denote tumor; absence of pulsation indicates interference with the subdural space by adhesions, pressure, etc.) After exposure of the contents of the spinal canal, and before opening the dura, a careful scrutiny of the bony outline of the canal should be made at the various aspects, to detect the presence of any encroachment of bone or diseased products in a degree that causes symptomatic pressure of the cord. In fracture of the

spine and in Pott's disease this step is of obvious importance, since it may be possible to remedy the impingement without division of the membranes. To obviate the danger of infection diseased products should be scraped away with a small spoon, aided by a gentle stream of hot sterilized water. The correction of the bony trespass is not so easily made, owing to the greater necessity of drawing the contents of the canal upward, out of the way of the instrumental manipulations necessary for the removal of the projecting bone. To meet this indication properly, it may be necessary to sever the roots of one or more of the spinal nerves at one side of the canal. The offending bone structure is cut off at a proper line (Fig. 329) with sharp-

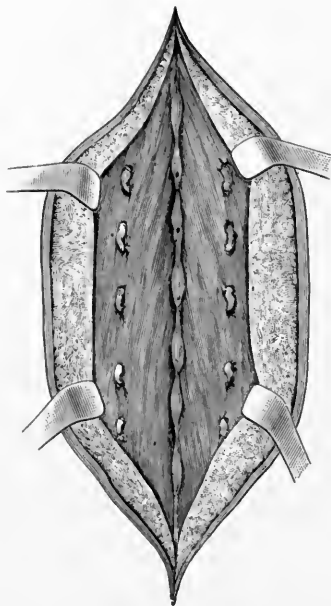


FIG. 327.—Exposure of posterior structures of spinal column.

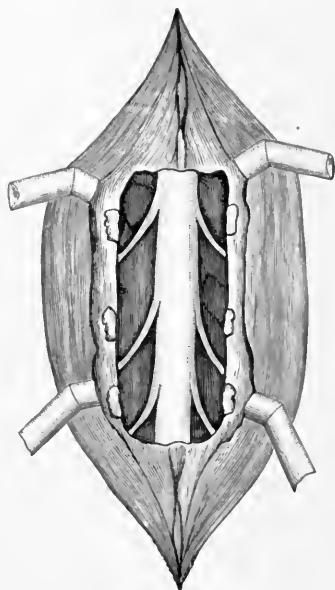


FIG. 328.—Spinal cord exposed.

curved chisels, or dug away with suitable scoops. After proper alignment of the bony surface and thorough cleansing of the parts, the divided roots of the nerves are united with sutures, and then, if advisable, the dura is opened.

The Opening of the Dura.—In the majority of instances it is advisable to open this membrane to be assured of the condition of the cord. However, the principles relating to removal of depressing agents of the brain can be applied with satisfactory outcome to the cord. The dura may be opened at the median line with forceps and scalpel for a sufficient distance to permit the examination of its contents. The subdural space is explored carefully in all directions with a bent silver probe, to determine the presence of disease or injury. Tumors are removed if not infiltrating, and bony irregularities, spiculæ, and diseased products are similarly treated. All efforts to repair the cord itself have as yet proved futile. Whether or not the theca should be sutured after treatment of the contents depends not a little on the nature

and extent of the disease and the character of the products disclosed. In some instances of large tumors both Horsley and Keen omitted the closure. If infecting agencies be already present within the membranes, closure of the dural incision should be omitted and suitable drainage be established in-

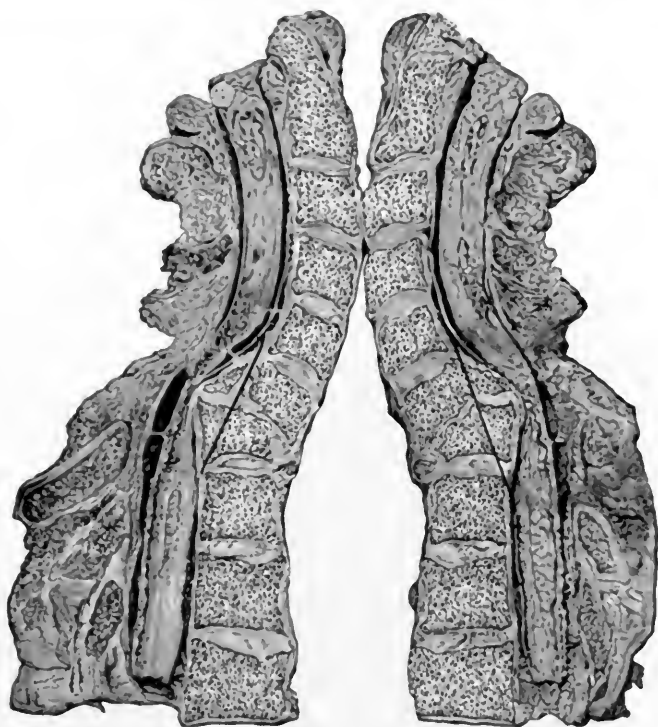


FIG. 329.—Removal of bone pressure.

stead. The liability to fistulous formation, which may happen in any event, is increased with non-sewing of the membranes, and this occurrence invites infection and is often of perplexing duration. The escape of cerebro-spinal fluid in such cases is often excessive and dangerous, but not so much on account of the loss of fluid as of the irritation and annoyance imposed, and the increased liability of infection. A fine needle armed with silk or catgut is used for suturing. If a coarse one be employed, the punctures may permit the escape of the fluid, and thus invite fistulous formation, delayed union, and consequent infection. Employ deep drainage for a day or two, and longer if advisable; unite the deeper layers of muscles with buried catgut sutures, close the integumentary wound with silkworm gut, apply abundant antiseptic dressings, fix them with a firmly applied binder, and place the patient on the back. Remove the dressings in twenty-four hours, or sooner if soiled. Thereafter renew them with aseptic care as often as is consistent with the comfort and security of the patient.

The Osteoplastic Flap.—The making of an osteoplastic flap is preferred by some surgeons, with the view of securing greater solidity of the spine

after recovery. There appears to be as yet no good reason for this proposition, except perhaps in case of Pott's disease, in which the bodies of the vertebræ are not sufficiently solidified to properly support the trunk in the absence of excised laminae and spinous processes. However, it is deemed proper to say, even in this connection, that a flap of this kind, when employed in stationary or advancing Pott's disease, can scarcely be expected to unite at the bony points; and it will, moreover, be illy fitted to meet the demands of drainage and the prevention of infection, to say nothing of the greater operative dangers attending its formation. The osteoplastic flap is quadrilateral, attached above, and includes the laminae or spinous processes which are cut away and turned upward along with it (Fig. 330). The construction

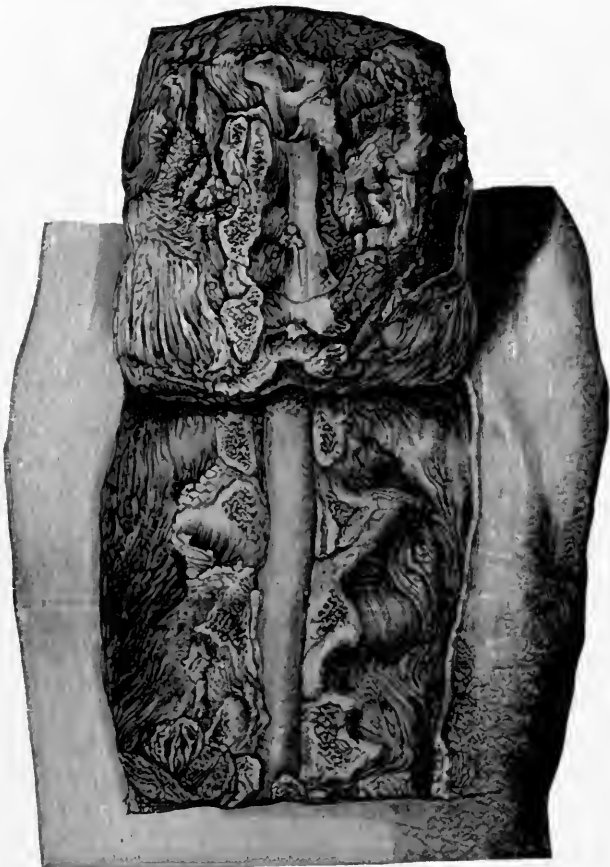

FIG. 330.—Osteoplastic flap.

of the flap is difficult and tedious, and necessarily attended with a greater loss of blood than is the former method. If the latter be employed, the bony asperities should be removed before replacement, and the osseous fragments sutured in place, if possible, before final union of the soft parts is made.

The Results.—Of 270 cases reported by Genet, 53 recovered. Chipault analyzed 160 cases, with the following results: 20 were cured, 33 improved, 22 unimproved, 65 died, and in 20 the results are unknown. The death rate of laminectomy for Pott's disease is about forty per cent.

Spinal Meningeal Drainage.—The draining away of the cerebro-spinal fluid with a small trocar inserted between the lamina of the cervical or lumbar vertebræ, or at the seat of a primary laminectomy, for the relief of pressure in cerebral disease, has of late been practiced to a considerable extent. The lumbar region is the one commonly selected for the purpose.

The Anatomical Points.—As the spaces immediately connected with the lamina of the fourth lumbar vertebræ are the ones through which the procedure is commonly conducted, it will not be amiss to direct attention to certain anatomical facts concerned in the operation at these points. In infants these spaces have a transverse diameter of about three quarters of an inch and a vertical of about half an inch, the latter being increased by flexion of the spine. The requisite depth of the puncture is about four fifths

of an inch in infants; in adults it is twice that distance. The lumbo-sacral space being the larger, and farthest removed from the spinal nerves, is recommended as a suitable place for puncture (Chipault).

The Operation.—Administer an anæsthetic; place the patient in the sitting posture with the body slightly flexed; make a short incision down to the bone at the point through which the puncture is to be made, and introduce the trocar slowly and continuously into the spinal canal (Fig. 331). Various directions are given to the

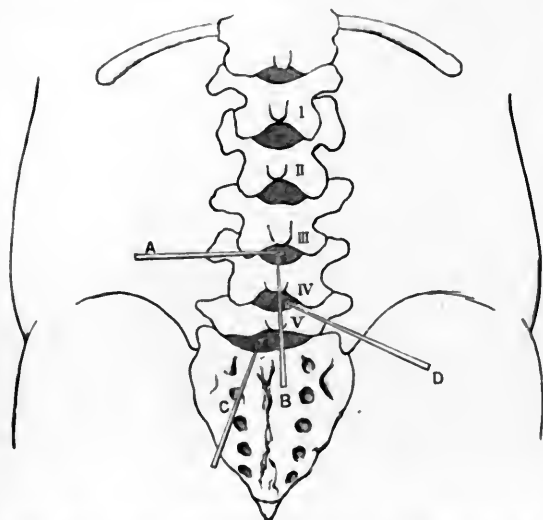


FIG. 331.—The different directions of introducing a trocar in spinal drainage. A. Quincke's. B. Marfan's. C. Chipault's. D. Tuffier's.

trocær, as, forward toward the median line, A (Quincke), upward and forward between and along the course of the spinous processes, B (Marfan), and upward and forward through the lumbo-sacral space at either side of the spinous process, C (Chipault), D (Tuffier).

Parkin's Operation (Fig. 332).—Parkin proposed, in lieu of spinal puncture, to enter the basal subarachnoid space by trephining the occipital bone (*c*) at a point low enough to permit tapping of the subarachnoid space (*a, b*) under the cerebellum. The comparative success thus far attained by Parkin certainly encourages continued effort in this direction.

The Results.—Five cases are reported, with three recoveries.

The curative effects of spinal drainage are not of a reassuring character. However, amelioration of the symptoms frequently follows, which of itself is comforting, and may offer the way to the only chance for recovery. The importance as a diagnostic measure appears to rest on a substantial foundation. The operation alone presents no especial dangers if cautiously and aseptically performed.

Spina Bifida.—Spina bifida is a not infrequent defect, since it is noted in one in about eight hundred births. It may appear at any portion of the vertebral column, but most frequently in the lumbosacral region. The defect may involve one or more of the laminae, and rarely, indeed, even the body of a vertebra itself. *Three varieties* of arrangement of the tissues involved are noted, viz.: 1, in which the membranes alone protrude (meningocele); 2, in which both the membranes and cord protrude (meningo-myelocele); 3, in which to the latter condition is added distention of the central canal of the cord, reducing the cord to a thin internal covering lying against the membranes (syringomyelia). These tumors vary also in size and shape, being large and small, and sessile and pedunculated in form.

If, after two or three months, palliative treatment affords no relief or the symptoms increase in gravity, one of two measures of radical cure should be attempted—i. e., injection or excision.

The Injection Method.—The iodoglycerin solution is advised especially for use in this method (page 230). After complete antiseptic preparation, the patient is placed on the side and an anæsthetic is given if necessary. The needle is introduced as far from the median line of the tumor as possible, in order to avoid puncturing the nervous tissue and also to utilize the soundest integumentary covering, and while pressure is made on the neck of the sac. A drachm or two of fluid is drawn from it—sufficient to cause perceptible relaxation—followed by the slow introduction of a drachm or a drachm and a half of the iodoglycerin fluid. This fluid may remain or be permitted to escape and distilled water be introduced, the needle withdrawn and the opening so closed as to prevent the escape of fluid and carefully protect the puncture. If the communication between the sac and the cord be small, long, or closed, the danger of the injection method is proportionately diminished. If, however, the opening to the sac be large and the capacity of the sac be small, then the amount injected should be lessened and the caution in the use increased. The slight reaction that follows in favorable cases sub-

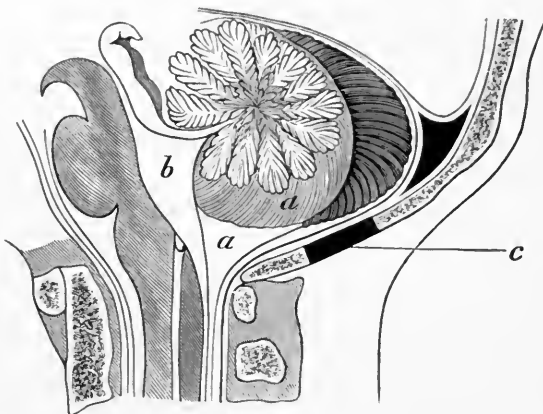


FIG. 332.—The opening in the skull in Parkin's operation.

sides within two weeks, when a second injection may be employed. Spinal meningitis due to infection or to the medication may ensue. Ulceration may follow at the point of puncture, leading to the escape of the cerebro-spinal fluid and to death from convulsions or infective meningitis.

The Results.—The death rate is from twenty-seven to twenty-eight per cent. Repeated injections are sometimes needed to effect a cure. In about seven per cent of the cases no effect is noticed.

The Excision Method.—The treatment of spina bifida by excision is now regarded with comparatively great favor by the majority of surgeons. It is applicable, however, only to the first two varieties of the anomaly, the simple meningocele being the best adapted to the procedure. The advantages of thorough asepsis are of superlative importance in this operation.

In **meningocele** an elliptical incision is made down to the sac, leaving sufficient integument at either side to close the defect. The sac is exposed down to the base, and if the neck be small it is ligatured with silk or strong catgut and removed, and the wound closed and dressed in the usual manner. If the neck of the sac be large it should be sutured through and through with silk or catgut, so as to bring the serous surfaces in apposition with each other, carefully avoiding in the meantime the escape of cerebro-spinal fluid, not so much on account of immediate as of subsequent danger to life from infective meningitis, the result of a fistulous communication with spinal membranes. Division of skin and sac in same course weakens union.

The Results.—The number of cases thus far treated is considerably over one hundred, with a rate of mortality varying from twenty to twenty-six per cent, showing somewhat better results than follow the injection method.

Meningo-myelocoele.—In this variety of infliction the spinal nerves play an important part, as it is necessary to eliminate them from the remainder of the tumor and return them to the spinal canal. More commonly the nerves are associated with the posterior wall of the sac, but when present within it they are more frequently adherent at either side of the median line of the tumor. In both instances the sac is approached the same as in meningocele, the nerves dissected out and returned to the spinal canal, and the sac treated as in the preceding instance. The difficulty attending the elimination of the nerves from the tumor without great damage to the sac, free escape of cerebro-spinal fluid and subsequent fatal meningitis, is manifest. Nerves that are limited to the tumor alone, or perchance pass outside, may be removed entirely; but all those that may be replaced in the spinal canal should be treated with scrupulous care and be returned to their normal environment. If the establishment of a fistulous opening with the spinal canal be regarded imminent, suitable drainage should be provided, and every anti-septic measure rigorously enforced to prevent meningitis and lessen its danger. In other respects the wound is treated by common aseptic methods. The great desideratum is the proper strengthening of the posterior wall of the spinal canal, and it is in this line of achievement that modern surgical effort has been directed. The union in the median line of detached muscles at either side of the spine (Bayer); similar union of the forcibly detached rudimentary arches of the dorsal (Dollinger) and sacral (Senenko) verte-

bræ; the employment of a portion of the iliac crest (Bobroff) while attached to the erector spinæ muscle; the utilization of foreign periosteum or bone, are each advised. The last has been tried, but the outcome can not be regarded with the favor that characterizes autoplasty. The use of the celluloid plate, sprung into place, offers a comparatively encouraging outlook.

The Results.—The operative outcome in meningo-myelocele is so unfavorable that many authorities discourage the attempt.

Tumors of the Spinal Cord.—The prospect for relief in some forms of this affection is not discouraging. Tumors of the membranes of the cord and those outside are favorably situated for operation. Circumscribed tumors of the cord offer a degree of hope of relief over the diffuse variety. A knowledge of the technique of laminectomy, plus that of the removal of tumors of the brain, meets the requirements of surgical procedure of the cord.

The Results.—About fifty per cent recover from the operation; but as yet it is impracticable to express in numbers the functional benefits thus far received.

The Spinal Accessory Nerve.—The spinal accessory nerve is subjected to the various surgical means directed to the cure of torticollis.

The Anatomical Points.—After escaping from the jugular foramen, the nerve runs in front of the jugular vein, beneath the digastric and stylo-hyoid muscles and the occipital artery, and enters the deep portion of the anterior border of the sterno-mastoid at a point about two inches below the tip of the mastoid process. It then passes obliquely downward and backward in the structure of the muscle to the center of the posterior border, escapes and crosses the lower part of the occipital triangle, passes beneath the anterior border of the trapezius muscle at the upper part of the lower third, and disappears in the muscular structure. The nerve can be exposed at either the upper or lower portions.

The Operation (upper portion).—Raise the shoulders, extend the head, and turn the face to the opposite side; make an incision from the tip of the mastoid process along the anterior border of the sterno-mastoid muscle (Fig. 216) three inches in length; divide the integument and superficial fascia; expose the anterior border of the sterno-mastoid muscle and divide the deep cervical fascia; flex the head slightly, draw the sterno-mastoid outward, thus making the nerve tense and appreciable to touch; expose the nerve with thumb forceps and scissors and carry around it and tie a strong ligature; stretch the nerve and divide it at either side of and as far from the ligature as is practicable. Close and dress the wound in the usual manner and keep the head quiet. *The nerve can be exposed in the lower portion* of the occipital triangle at the posterior border of the sterno-mastoid (Fig. 214). It is then followed upward until the posterior border of the sterno-mastoid is reached and resected; or resection is done before it enters the sterno-mastoid, depending on the effect desired. The writer once approached the nerve by going between the anterior fibers of the sterno-mastoid. The nerve was quickly and easily reached before it entered the muscle, and the wound healed promptly.

The Remarks.—Division of the nerve is followed quite soon by atrophy of the muscles, attended with drooping of the shoulder. Irritation of the nerve on exposure with the forceps will cause contraction of the trapezius, even with the patient under anaesthesia, a fact of manifest diagnostic importance.

The Results.—Stretching and simple division of the nerve do but little good; neurectomy, however, is followed by a fair degree of success.

Operations on the Branches of the Cervical Nerves.—Many of the branches arising from the anterior and posterior cervical plexuses are treated surgically for the cure of neuralgia and spasmodic affections.

Excision of the Posterior Divisions of the First Three Cervical Nerves (Keen).—This operation is advised for the relief of spasmodic wryneck dependent on the action of the posterior rotator muscles of the head.

The Operation.—Make a transverse incision three inches in length from half an inch below the lobe of the ear to the middle line of the neck posteriorly; divide the trapezius transversely (Fig. 231); recognize the occipitalis major nerve as it escapes from the complexus muscle half an inch below the line of incision; divide the complexus transversely on the level with the nerve; expose the nerve down to its origin from the inner division of the posterior trunk of the second cervical nerve; resect this division as low as possible to paralyze the inferior oblique muscle; recognize and divide the suboccipital nerve as it passes outward across the arch of the atlas, carefully avoiding the vertebral artery. An inch below the second is found the third branch of this plexus—i. e., the internal division of the posterior trunk of the third cervical nerve. This operation is one in which a knowledge of anatomy will do much to facilitate the efforts and comfort the operator. The wound is dressed as in other cases, and the head fixed until repair takes place.

The Results.—Nothing can as yet be said of this operation, except that in cases calling for it the outlook should be quite as favorable as in those cases already benefited by a similar proceeding elsewhere.

The occipitalis major can be divided or stretched higher up in its course than is indicated above, if desirable.

The Operation.—Locate the occipital protuberance, and, beginning about an inch above the protuberance, make an incision one inch and a half in length downward, forward, and outward at its anterior border; carefully separate the tissues in the line of the incision, and the nerve will be exposed where it escapes from beneath the trapezius muscle.

The Auricularis Magnus Nerve.—This nerve is one of the ascending branches of the cervical plexus. It emerges at the posterior border of the sterno-mastoid muscle near its middle, and ascends on that muscle to the lobule of the ear (Fig. 216).

The Operation.—Make an incision two inches in length obliquely upward and backward, its center corresponding to the lower extremity of the lobule of the ear. On dividing the skin and fascia the nerve will be found resting on the sterno-mastoid muscle, from which it can be raised with a hook and stretched or cut.

Intraspinal Division of the Roots of Spinal Nerves (brachial plexus).—This operative procedure was first performed by Abbe, and for the relief of intractable neuralgia of the brachial plexus.

The Operation.—Locate the vertebral spinous processes that correspond to the nerves to be attacked; place the patient, and open the spinal canal and dura, as in laminectomy; identify the posterior roots of the affected nerves and resect from each as long a segment as practicable, dividing the corresponding anterior roots (Fig. 333); close the dura mater by sewing with catgut; unite the wound as indicated in laminectomy.

The Remarks.—The operation is in all essential regards similar to laminectomy aside from the surgical treatment of the roots of the nerves. Carefully indicate on the skin the spinous processes that correspond to the nerves involved before beginning the operation.

The Results.—Several cases have been thus treated, but with an outcome not at all encouraging so far as relief from pain is concerned. The operation itself can be regarded as free from danger in the presence of proper aseptic technique.

The Branches of the Brachial Plexus.—It may be necessary, on account of a severe neuralgia involving the branches of this plexus directly, or located in a painful stump, to excise or stretch the nervous cords near their origin. It is best done at the seat of the three primary branches.

The Operation.—Place the patient upon the back, raise the shoulders, and turn the head backward and to the opposite side. Determine the course of the external jugular by pressure just above the clavicle; make an incision along the posterior border of the sterno-mastoid three inches in length extending down to the clavicle; a second incision of the same length is made outward from this point, along the upper border of the clavicle, carefully avoiding the external jugular; turn the flap upward and seek for the posterior belly of the omo-hyoid; when found, draw it upward with a hook or ligature, push aside the loose connective tissue, and the cords will appear located above and to the outer side of the third portion of the subclavian artery, which should be carefully avoided. The inner cord is cautiously hooked up and a ligature applied to it, by which it can be raised from its bed and stretched, then divided with a pair of scissors near the outer border of the scalenus anticus muscle, being careful to avoid the muscle and the phrenic nerve. If gentle traction be made upon the ligature, the distal extremity will be raised, and can be again divided an inch or so from the point of the first section and

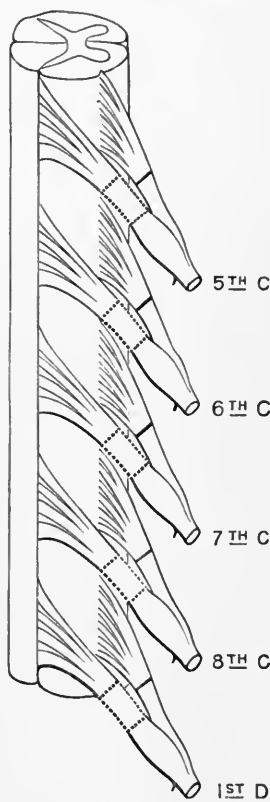


FIG. 333.—Intraspinal division of the roots of spinal nerves.

the portion removed. The remaining cords can then be divided in the same manner.

The Musculo-Cutaneous Nerve.—The musculo-cutaneous nerve can be exposed at two situations: 1. As it escapes from the axilla. 2. Near to the elbow joint.

The Operation.—At the first situation, carry the arm from the body and rotate it outward; make an incision three inches in length along the inner border of the coraco-brachialis muscle (Fig. 219); divide the skin and fascia on a director, draw the muscle inward, and the nerve will be easily found at its inner border. The nerve is exposed at a lower point than this, after perforating the coraco-brachialis muscle, by making the incision at the outer border of that muscle.

At the second situation it is found by making an incision two and a half inches in length between the biceps and the supinator longus, through the integument, fascia, and aponeurosis; separate the muscles and the nerve will be readily seen (Fig. 222, f).

The Musculo-Spiral Nerve.—The musculo-spiral nerve can be exposed at three situations: 1. Make an incision about four inches in length between the outer border of the triceps and the brachialis

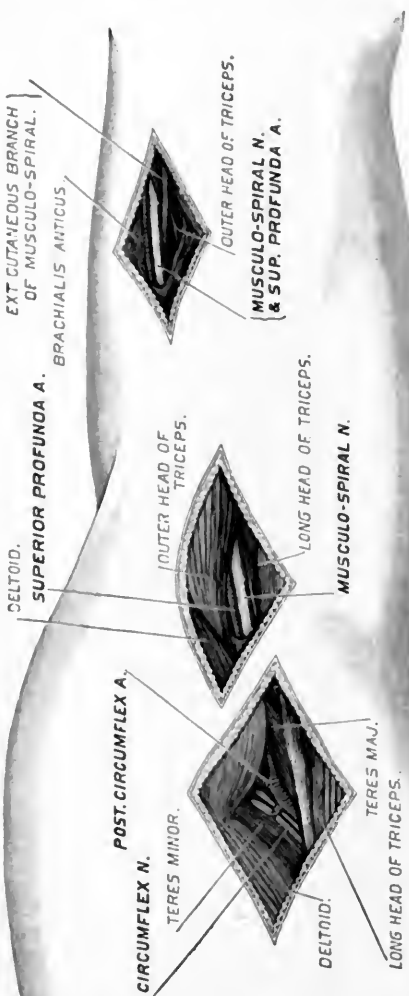


FIG. 334.—Musculo-spiral nerve, etc.

antis muscles (Fig. 334), beginning two and a half inches above the external condyle. Divide the fascia on a director, separate the connective tissues with a handle of a scalpel or the finger, and the nerve will be easily found. 2. Make an incision three or four inches in length at the inner aspect and upper third of the arm (Fig. 219). The tendon of the latissimus dorsi above, the long head of the triceps muscle at the inner, and superior profunda artery at the outer, mark the situation of the nerve. An incision made at the posterior and inferior aspect of the upper third of the arm, located below the deltoid and passing between the outer and long heads of the triceps, promptly exposes

to view the nerve, attended by the superior profunda artery (Fig. 334). 3. Make an incision three inches in length in the space between the supinator longus and the brachialis anticus muscles; divide the fascia, separate the connective tissues beneath it, and the nerve will be readily exposed.

The Circumflex Nerve.
 —Abduct the arm and press the posterior border of the deltoid muscle toward the surgical neck of the humerus, noting the angle formed by this and the posterior scapular muscles; expose the posterior border of the deltoid through a longitudinal incision made at this point; draw the border forward and expose the lower edge of the teres minor and the long head of the triceps, and observe in the angle between them the circumflex nerve attended by the posterior circumflex artery (Fig. 334). The circumflex nerve can be exposed near its origin through an incision carried from the beginning of the arm along the axillary surface of the posterior axillary fold. Divide the fascia; separate the loose cellular tissue at the upper borders of the insertion of the latissimus dorsi and teres major muscles. At the upper end of the incision will be seen the circumflex nerve, with the scapular vessels and nerves on a lower plane (Fig. 219).

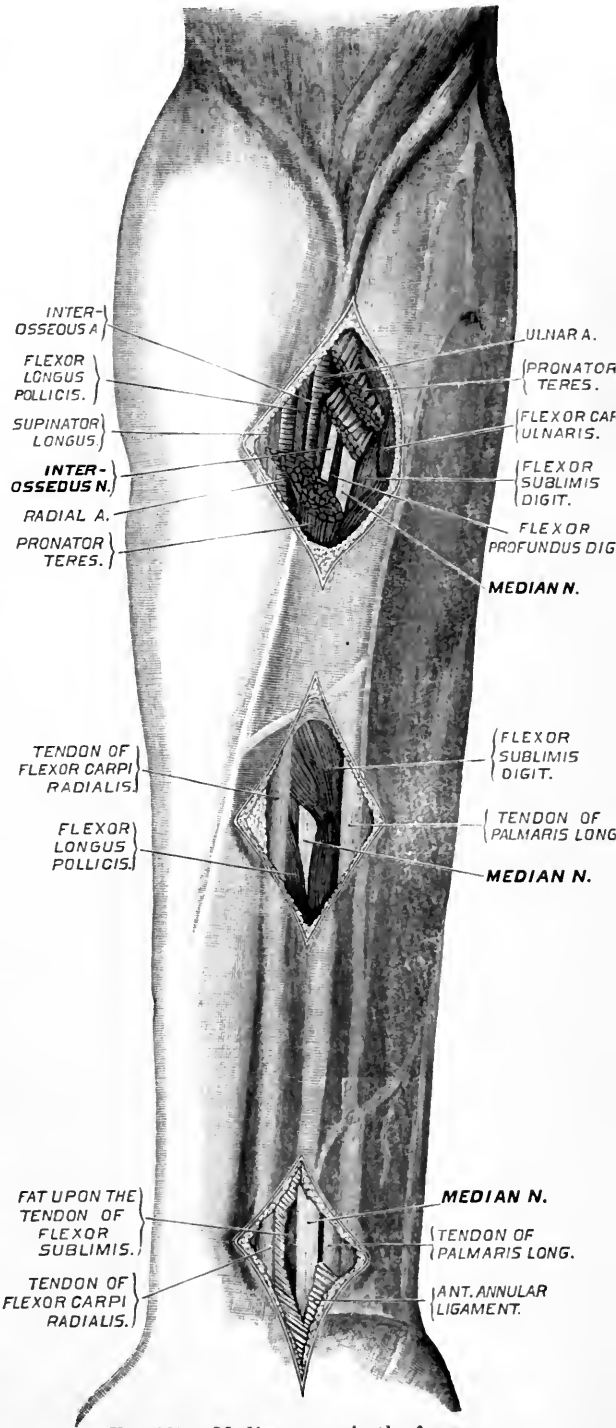


FIG. 335.—Median nerve in the forearm.

The Median Nerve.—The median nerve can be easily exposed in its course along the arm by modifying either of the incisions for ligaturing the brachial to correspond to the relations of the median nerve to that vessel (Figs. 219 and 222, f).

In the forearm, the median nerve can be exposed at three situations: 1, at the upper third; 2, below the middle; 3, above the wrist joint.

At the upper third, supinate the arm and make an incision as for ligature of the radial artery at that situation (Fig. 335); divide the pronator radii teres and the tendinous arch of the flexor sublimis digitorum, thus exposing the nerve contiguous to which lies the anterior interosseous branch.

Below the middle the nerve is exposed through an incision made between the flexor carpi radialis and the palmaris longus muscles, after drawing inward the interposing fleshy belly of the flexor sublimis digitorum. The median artery is present at this situation.

Above the wrist joint the nerve is quickly seen through an incision of the skin and fascia made at the radial side of the palmaris longus tendon.

The Ulnar Nerve in the Arm.—At the upper and the middle thirds of the arm this nerve lies near to the inner aspect of the brachial artery, and can be readily exposed at these situations by properly located incisions of similar dimensions to those employed to expose like portions of the artery (Fig. 219).

The ulnar nerve at the elbow is of special importance because of its relations to the internal condyle and to the olecranon process (Fig. 223, J) in connection with excision of the joint, and also its liability to injury and displacement at this situation.

Displacement of the ulnar nerve is rare. However, this condition may complicate fracture or dislocation at the elbow, and it may arise from other causes.

MacCormac advises that the nerve be exposed by a free incision, dividing the tissues back to the inner condyle, thus providing a bed into which the dislocated nerve is placed and fastened by sutures of kangaroo tendon passed through the borders of the wound and the triceps tendon.

The radial and ulnar nerves in the forearm can be easily exposed through the incision employed to ligature the vessels bearing similar names (Fig. 222).

Branches of the Sacral Plexus.—The gluteal, pudic, and small sciatic nerves can each be exposed through the same incisions used to ligature the arteries of a similar name (Fig. 185).

The Great Sciatic Nerve.—The great sciatic nerve, though lying deeply, can be reached through the incision for ligature of the sciatic artery (Fig. 185).

At the posterior surface of the thigh this nerve can be exposed just below the gluteal fold and at the seat of bifurcation (Fig. 336); it is best approached after its escape from beneath the lower border of the gluteus maximus.

The Operation.—Place the patient on the abdomen or side, and make an incision three or four inches in length, beginning at the gluteal fold, at a point midway between the tuber ischii and the trochanter major, or the vertical incision may be joined by a short horizontal incision; divide the in-

tegument and fascia on a director, separate the connective tissue with the fingers and handle of the scalpel down to the nerve, bringing into view the biceps muscle, small sciatic nerve, etc. (Fig. 336). It can then be

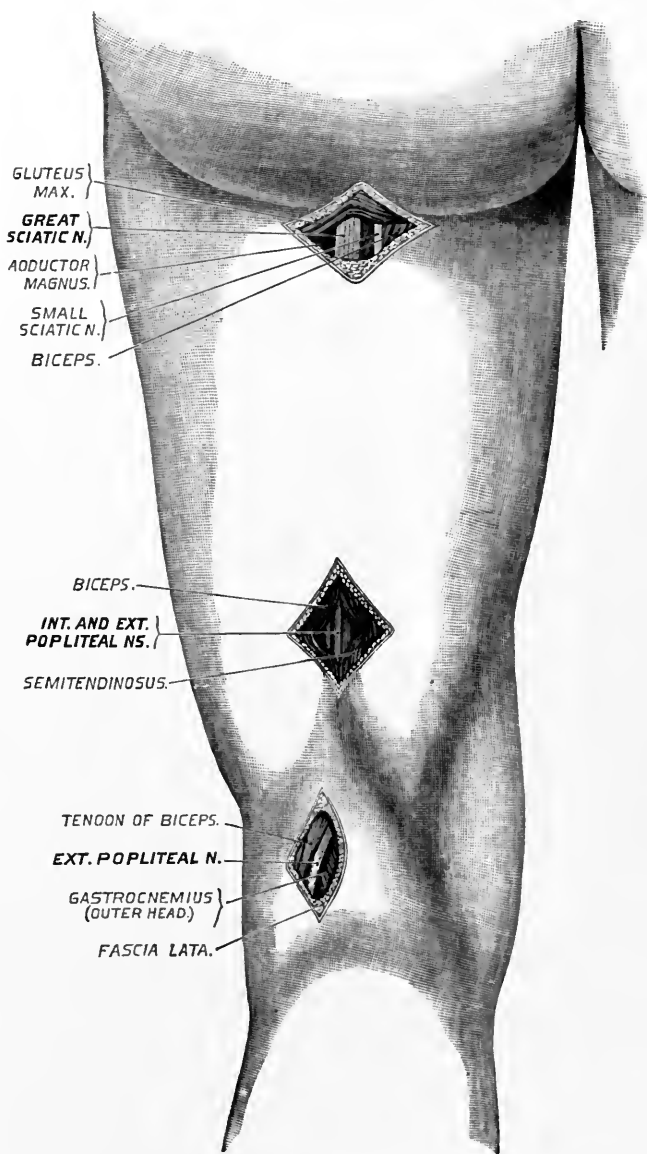


FIG. 336.—Exposure of great sciatic and popliteal nerves.

stretched by passing one or two fingers around it and making firm and steady traction upon it (sufficient to raise the limb). The wound should be carefully closed and dressed under antiseptic precautions.

The Bloodless Stretching of the Sciatic.—Administer an anæsthetic and place the patient on the back or side. Extend the leg fully on the thigh, and hold the pelvis firmly. Flex the thigh on the pelvis while full extension of the leg on the thigh is continued, thus causing extreme tension of the muscles and other structures on the posterior surface of the thigh, thereby stretching the nerve. The manipulation must be firmly yet cautiously made

to attain the object, and at the same time not tear asunder the hamstring muscles.

At the Seat of Bifurcation (Fig. 337).—At this situation—just below the middle of the thigh—the nerve is exposed through an incision directed between the semitendinosus and semimembranosus muscles internally, and the biceps externally. It lies deeply, near the posterior surface of the femur, and may have divided already into its terminal branches (Fig. 192).

The Fallacy.—Rarely this nerve divides into its terminal branches in the pelvis, presenting, therefore, two branches at either site of operation. Some confusion may occur in its detection and incomplete treatment of the affliction result, if this abnormality be not discovered.

The Results.—Obstinate sciatica has been relieved, and even cured, by stretching. Not infrequently the degree of the resulting ecchymosis indicates rupture of the muscular structures in bloodless stretching.

The Internal Popliteal Nerve.—The internal popliteal nerve can be reached by the same method and with the same caution as the popliteal artery (Fig. 336). It is, however, less deeply situated and somewhat nearer the center of the popliteal space than are the vessels (Fig. 195). Extreme caution should be exercised in operating upon it, on account of its nearness to the popliteal vein, which lies beneath it and to the inner side.

The External Popliteal Nerve.—The external popliteal nerve can be easily reached by making an incision two or three inches in length along

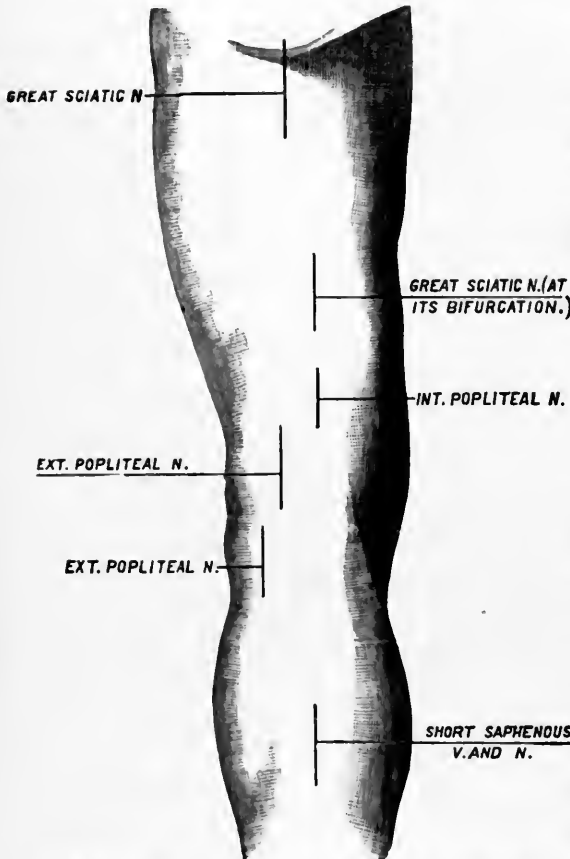


FIG. 337.—Incisions in exposure of great sciatic and branches.

the inner side of the tendon of the biceps cruris (Figs. 336 and 337), when the nerve can be readily found beneath the fascia, surrounded by fat (Fig. 196, J).

The anterior and posterior tibial nerves can be exposed and stretched through the incisions adopted in ligaturing the vessels of the same names (Figs. 198 and 203).

The Plantar Nerves.—The plantar nerves are the terminal branches of the posterior tibial, and are given off just after the nerve winds around the internal malleolus. They can be exposed by making an incision about three inches in length, beginning just in front of the center of a line extending from the anterior border of the internal malleolus to the inner tuberosity of the os calcis, and carried forward along the external border of the abductor pollicis. If the space between the short flexor and the abductor be now opened at the posterior portion, the nerves will be found accompanied by the arteries of a similar name.

The Perineal Nerve.—The perineal nerve may be exposed in the perineum of the male by making an incision along the ramus of the pubes and ischium at either side in the same manner as directed for ligaturing the pubic artery at this situation (Fig. 187). In the female perineum the nerve may be exposed either by an incision made *without* or *within the vagina*. In the former instance, make it through the superficial tissues, about three inches in length, in the groove between the labium and the perineum, just inside the rami of the pubes and ischium. The nerve is surrounded by connective tissue, and it is difficult to find in this situation; however, if the blade of the knife be turned inward and the outer coats of the vagina be divided down to the inner one, the nerve will not escape section.

The nerve is more easily severed from within the vagina. If the finger be introduced an inch or more and lateral pressure be made, the nerve will be felt, cordlike in character and sensitive to the touch. Make a vertical incision through the coats of the vagina, and the nerve will be exposed for division or excision.

The Branches of Lumbar Plexus.—Operations on the branches of this plexus are not practiced as frequently as on those of the other plexuses.

The Anterior Crural Nerve.—The anterior crural nerve is the largest branch of the lumbar plexus, and enters the thigh beneath Poupart's ligament, about three quarters of an inch to the outer side of the femoral artery. It lies beneath the iliac fascia (Fig. 338).

The Operation.—Make an incision three inches in length directly downward, beginning about an inch below Poupart's ligament, in the line of the nerve. The superimposed layers of tissue are carefully divided on a director down to the groove between the iliac and psoas muscles, between which it rests. The pulsations of the femoral artery will always suggest the location of the nerve.

The Obturator Nerve (Fig. 189).—The obturator nerve and artery, and the internal circumflex branch of the profunda artery, are each exposed through a vertical incision beginning just below and a finger's breadth inside of the center of Poupart's ligament. The integument and fascia are

divided carefully, avoiding the internal saphenous vein. Divide the pectineal fascia just external to the femoral vein, define the border of the pectineus muscle and separate the muscle from the pubis and obturator fascia, and draw it inward. Divide the obturator fascia, pass the finger above the upper border of the obturator muscle, and feel for the artery and nerve as they pass through the obturator foramen under the horizontal ramus of the pubis.

The Internal or Long Saphenous Nerve is given off from the anterior crural, and supplies the inner surface of the leg. It is accompanied by a vein of the same name in its course along the leg. It can be reached easily at many situations, but practically, however, it is best exposed at the inner condyle of the femur, where it escapes from beneath the sartorius (Fig. 203), and at the middle of the leg. *At the former situation* recognize the tendon

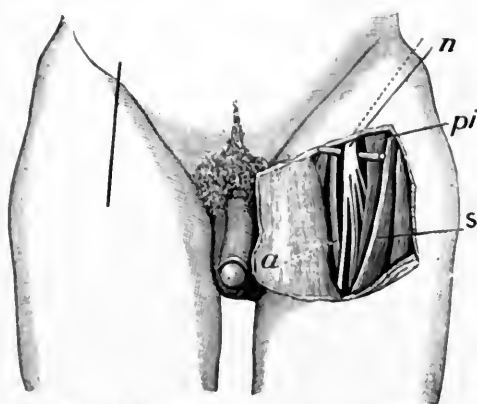


FIG. 338.—Anterior crural nerve exposed. *a.* Femoral artery. *n.* Anterior crural nerve. *pi.* Psoas and iliac muscles. *s.* Sartorius muscle.

of the sartorius. Press upon the internal saphenous vein above this point to distend it; make an incision two inches in length close to and parallel with the vein, draw it aside, and the nerve will be found emerging from beneath the tendons of the sartorius and gracilis. *At the middle of the leg* (Fig. 200, *F*) make an incision three inches in length parallel with the properly distended vein, which should then be pulled aside, and the nerve will be found close to and behind the vein.

The External or Short Saphenous Nerve (Figs. 204, *c*, and 337) arises from the internal popliteal, escapes from between the heads of the gastrocnemius, pierces the fascia below the middle of the leg and becomes subcutaneous, and passes down on the fibular side of the posterior surface to the malleolus, accompanied by the external saphenous vein. Distend the vein by pressure; make an incision close to and parallel with it, near the border of the tendo Achillis; pull the vein aside, and the nerve will be seen.

CHAPTER VII.

OPERATIONS ON TENDONS, LIGAMENTS, FASCIAS, MUSCLES, AND BURSÆ.

TENDONS, muscles, ligaments, and fascias suffer often from the effects of strain and rupture, and from chronic disease, and various degrees of deformity and modified function of parts are frequent sequels. The remedial measures directed to the alleviation of the effects of these pathological conditions on tendinous and muscular tissues are *tenotomy*, *tendon suture*, *tendon transplantation*, *tendon lengthening*, *tendon shortening*, *tendon anastomosis*, and *myotomy*.

The bursal structures are of great mechanical importance in the human economy, and are subject to different grades of inflammation and degrees of traumatic violence, for the relief from which various operations are practiced.

Tenotomy.—Tenotomy consists in making a subcutaneous or open division of a tendon for the purpose of overcoming or alleviating a deformity dependent usually on muscular contraction. Since the advent of antiseptic surgery open division can be practiced with comparative impunity if a rigid adherence to its tenets be maintained. However, it is wiser to hold to the subcutaneous method than to invite unnecessarily the mishaps that may follow a faulty technique in the open one. In order to practice tenotomy successfully the exact location of the offending structure should be determined, together with the important contiguous vessels, nerves, etc. Many of the large tendons are easily located by their natural prominence. Others that ordinarily lie concealed become apparent if contraction and deformity have occurred, and still more conspicuous if placed upon the stretch by the surgeon. The principles governing tenotomy should be well considered before a tendon is divided, otherwise an expedient of great good may become mischievous and even destructive in its results.

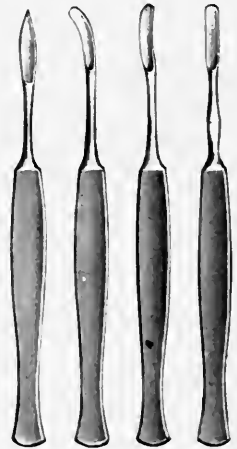


FIG. 339.—Tenotomes.

The instruments employed in tenotomy are few in number and simple in character. Fig. 339 represents the tenotomes in ordinary use. They are excellent instruments for the purpose. Fig. 340, representing the ordinary tenotome found in the pocket cases of the day, is usually too fragile to be safely employed in the division of tissues requiring any special outlay of

force, as the delicate point is liable to be broken if brought in contact with tough, fibrous or bony tissue; moreover, it is with difficulty made aseptic.

The Operation.—The operation of tenotomy is simplified by attention to the following order of procedure:

1. Secure complete aseptic technique.
2. Indicate on the handle of the scalpel the direction of the cutting edge.
3. Carefully note the length of the blade, so as to regulate the extent of the division of the tissues.
4. Avoid, if possible, the division of a tendon as it passes through a special sheath.

5. Divide the tendon at the point of greatest forced prominence, provided the division be consistent with the safety of important contiguous structures. If reflex




FIG. 340.—Pocket-case tenotome.

spasm be provoked by "point pressure," the tendon should be divided at the point exhibiting the greatest reflex manifestation (Sayre).

6. Make tense the structure to be divided, and so pinch up or push aside the skin at the point of proposed division that when the skin is relaxed the opening in it will not correspond to the divided tendon.

7. Insert the blade on the flat close to the surface of the tendon to be divided; turn the edge toward the tendon and carefully sever it with a guarded sawing motion, aided by pressing the tendon on the cutting surface of the knife. If incautious force be made, not only the tendon but the superimposed tissue may be divided, thus complicating the treatment and recovery.

8. Carry the edge of the blade *from* important structures when possible.

9. Withdraw the blade while upon the flat; follow the withdrawal with firm pressure upon the parts with the thumb, which should finally rest on the incision. This act will press the blood and air from the wound, as well as prevent air from entering it. Close the wound with a catgut stitch and seal it with antiseptic collodion. The application and confinement to the wound of an antiseptic pad is often quite sufficient for the requirements of healing.

10. Rectify the deformity, and confine the part immovably until repair is well advanced.

The degree of rectification is, according to some authorities, regulated by the size of the divided tendon; the smaller the tendon the completer should be the degree of restoration, and *vice versa*. If the tendon be closely associated with important structures, it is advised to use the sharp-pointed tenotome to prepare the way for the blunt-ended one with which the abnormal tissues are then divided, and with less danger than if the former be used through-

out. The injection into the tissue adjacent to the tendon of an aseptic solution of cocaine will reduce the pain of the procedure to a minimum.

Tenotomy—Upper Extremities. *The Division of the Tendons of the Flexor Sublimis and Flexor Profundus Digitorum Muscles.*—These tendons can be divided at the middle of the first row of anatomical phalanges by a transverse, subcutaneous incision carried through them down to the bone. After division of the tendons, reduce the deformity and keep the parts quiet for five or six days till the danger from inflammation has subsided, when they may be cautiously moved. Aseptic precautions should be observed throughout, otherwise inflammation of the sheaths of the tendons will follow.

The Division of the Tendons of the Extensor Communis Digitorum Muscle.—The tendons of this muscle can be readily divided as they pass along the carpus and upon the dorsum of the phalanges. *In the former instance* pinch up the skin, pass the knife beneath the tendon, as before directed, and cut toward the surface. They may be divided by passing the blade above the tendons and cutting down through them upon the bone. *On the dorsum* of the phalanges the blade should be passed beneath the skin and the tendons divided upon the bone.

The Precautions.—In the division of the tendons of both flexor and extensor muscles, the carpal joints, the palm of the hand above the transverse line (Fig. 504), the course of the vessels, and the spaces between the metacarpal bones should be avoided.

The Division of the Tendons of the Extensor Brevis, Longus, and Osis Metacarpi Pollicis Muscles.—These tendons can readily be made prominent simultaneously or in turn by forcible extension with alternate supination and pronation of the thumb, with the forearm midway between supination and pronation. The *brevis* and *ossis metacarpi pollicis* tendons form the inner boundary of the “snuffbox” at the apex of the styloid process of the radius, the *ossis metacarpi pollicis* being the more internal of the two. The tendon of the *extensor longus pollicis* forms its outer boundary. These tendons can be divided at this situation by making them as prominent as possible, then introducing the knife from the anterior surface of the wrist beneath the tendon and cutting toward the integument.

The Precautions.—The radial artery is to be avoided as it passes beneath them, and likewise the radicle of the radial vein as it crosses the intervening space.

The Division of the Tendon of the Flexor Carpi Radialis Muscle.—The tendon of this muscle, at the lower third of the forearm, is situated immediately to the inner side of the radial artery, and can be readily divided there by passing the knife away from the artery beneath the tendon.

The Division of the Tendon of the Flexor Carpi Ulnaris Muscle.—The tendon of the flexor carpi ulnaris, the most internal on the anterior surface of the forearm, is inserted largely into the pisiform bone and has the ulnar artery at the outer border. This tendon can be easily divided at a half inch or so above the insertion by passing the knife beneath it, away from the artery and nerve, and cutting toward the surface.

The Division of the Tendon of the Biceps Muscle of the Forearm.—The tendon of insertion of this muscle may be divided either above or below the giving off of the bicipital fascia (Fig. 222, *f*). The former situation is the safer. Division at the latter point contemplates the leaving intact of the bicipital fascia. This is a matter of some importance, for if the fascia is contracted also, the deformity will be maintained in lesser degree after section of the tendon at the lower point. But when the fascia is not involved, some advantage will be gained in pronation of the forearm if the influence of the fascia be not impaired by section.

The Operation.—Make the veins at the elbow prominent by constricting the arm above; extend the forearm to make the tendon prominent and tense; enter the knife at its inner border and pass it cautiously between the tendon and the brachial artery; cut outward, being careful not to injure the distended veins.

Tenotomy—Lower Extremities. *The Division of the Tendon of the Tibialis Posticus Muscle.*—The tendon of this muscle is intimately associated with the deformity of talipes varus. It runs along the inner border of the tibia, behind the internal malleolus, in a separate sheath, being the innermost tendon at this situation; after leaving the internal malleolus it passes beneath the calcaneo-scaphoid ligament to its insertions. In the normal foot it lies well concealed within a closely fitting groove, but it can be readily outlined between the tip of the malleolus and the astragalo-scaphoid articulation.

In talipes varus the tendon is raised from its groove and becomes prominent above and below the tip of the internal malleolus. The tendon can be divided either above or below the malleolus, but it is better done at a point about an inch and a half above the tip in the adult, and one inch in the child or infant. The tendon is made tense by strongly abducting the foot, and the knife is passed with the usual precautions between the internal border of the tibia and the tendon; the division is made by cutting backward.

The division between the tip of the malleolus and the astragalo-scaphoid articulation is not advised on account of the contiguity of the ankle joint and the internal plantar artery. If, however, it be thought advisable to operate at this situation, the foot should be strongly abducted, the point of the tenotome carefully insinuated beneath the tendon between it and the plantar artery; the handle is then depressed so as to carry the point away from the joint, and the section made from within outward. In fat infants it often happens that neither the tendon nor the inner edge of the tibia can be located. In such cases a puncture is made in a line exactly between the anterior and posterior borders of the leg at the inner aspect with a sharp-pointed tenotome down to and through the sheath of the tendon. The sharp-pointed blade is then withdrawn and a blunt-pointed one is passed beneath the tendon, which is divided by cutting upward. It is wise to recall the fact that while the space between the tendon and the tarsal bones is of limited extent, yet it is quite sufficient to admit the blade of the tenotome.

The Division of the Tendon of the Flexor Longus Digitorum Muscle.—The tendons of this muscle are sometimes productive of flexion of the

toes, after the correction of the deformity of the tarsus caused by the contraction of the tibialis posticus. The flexor longus digitorum tendon lies immediately posterior to the tendon of the tibialis posticus, behind the internal malleolus, and is often divided by the same cut which severs the tendon of that muscle. It can, however, be divided independently.

If, after the division of the tibialis posticus tendon, the influence of the flexor longus digitorum muscle on the toes be objectionable, its tendon can be divided by introducing the tenotome beneath it through the same incision, and cutting toward the surface as before.

The Precautions.—The posterior tibial artery and its venæ comites, which in the adult are often varicose in this situation, must be carefully avoided by pressing them outward with the finger. If for contraction of the toes, unassociated with deformity due to the tibialis posticus, it be deemed advisable to sever the tendon of this muscle, the posterior tibial vessels must first be detected and pushed outward by the thumb, which should then be pressed firmly between them and the tendons at the inner side; then pass the tenotome perpendicularly through the integument, midway between the internal margin of the tibia and the end of the thumb; carefully insinuate it between the tendons of the tibialis posticus and the flexor longus digitorum down to the bone; turn the edge toward the surface, and carefully divide the tendon.

The Division of the Tendon of the Flexor Longus Pollicis Muscle.—It may become necessary to divide the tendon of this muscle on account of the crippled action of the foot in walking dependent upon undue flexion of the great toe. The toe should be forcibly extended, and the knife carefully inserted beneath the tendon at the point of greatest prominence, which will be anteriorly at the inner border of the foot. The blade of the instrument should be passed from the internal plantar artery.

The Tendo Achillis is the largest and most prominent tendon of the human system. It is about six inches long, three quarters of an inch broad, and a quarter of an inch thick, and is inserted into the lower part of the posterior tuberosity of the os calcis. The narrowest portion in the adult is at a point about two inches above the insertion. The posterior tibial vessels and nerves are to the front and inner side at a considerable distance from the tendon, and in no danger of injury if ordinary care be exercised. The short saphenous vein lies superficially and closely to the outer border.

The Division of the Tendo Achillis.—Place the patient on a bed with the foot extending over the edge; forcibly flex the foot to make the tendon tense (Fig. 341); draw the skin outward away from the tendon to remove the saphenous vein from danger; introduce the blade of the tenotome with the flat surface parallel with the tendon close to its outer or inner border, as is most convenient; carry the point of the blade to the opposite side of the tendon and depress the handle to a horizontal position; turn the edge toward the tendon and cut carefully through the structure with a guarded sawing motion, while the foot is firmly flexed and the tendon is pressed upon the edge with the finger. At the last stage of the procedure great caution is essential, otherwise a sudden giving way of the tendon may cause

the severance of the superimposed tissues. All of the precautions previously enjoined in tenotomy should be exercised in this instance. After carefully pressing the air and blood from the wound by carrying the thumb and finger of the left hand toward the cut, the wound is closed by a catgut stitch or by an antiseptic compress held in place by a fold of sterile gauze. When the position of the foot is properly rectified, it should be

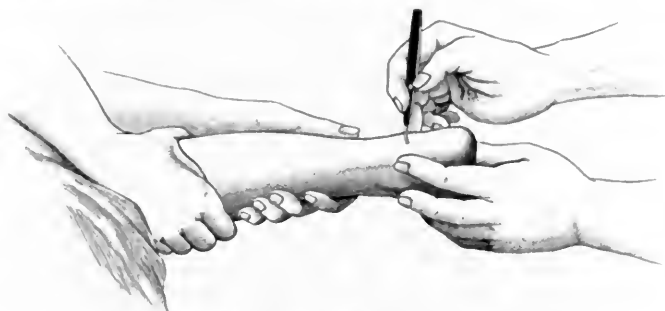

FIG. 341.—Dividing tendo Achillis.

held thus (Fig. 342) by a long adhesive strip (2, 3) carried up the leg from a thin strip of wood (4) strapped (1) to the sole of the bandaged foot and held in position by adhesive plaster or bandages. A thin plaster-of-Paris splint applied to the leg and foot with the latter in the rectified position will hold them in proper relation. If gradual rectification be practiced, these restraining influences should not be employed until three or four days later.

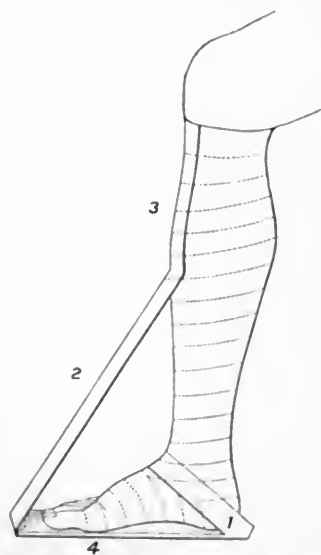


FIG. 342.—Foot, rectified and held in position.

The Division of the Tendons of the Peroneus Longus and Brevis Muscles.—The tendons of these muscles pass in a common groove behind the external malleolus, and are inclosed by the same sheath, the brevis passing the more anteriorly. The peroneus brevis leaves its fellow after passing behind the malleolus, and is inserted into the base of the metatarsal bone of the little toe at the outer side. The peroneus longus, after passing behind the malleolus, gains the sole of the foot, enters the calcaneo-cuboid groove, and is inserted into the internal cuneiform and the base of the metatarsal bone of the great toe, at the outer side. The tendon of either muscle may be divided at two situations: 1.

About an inch and a half above the tip of the malleolus; 2, at three fourths of an inch in front of the malleolus. These tendons are commonly divided at the former situation, but can be severed connectively or singly at either place.

If it be decided to sever both simultaneously above the malleolus, seek the antero-external border of the fibula about an inch and a half above its tip; pass the knife between the bone and tendons; turn the edge outward and cut toward the surface. The short saphenous vein should be pushed inward to avoid injury.

If either tendon is to be divided separately above the malleolus, push the integument aside with the thumb to protect the vein, then push the thumb down firmly to the bone behind the tendons; pass the tenotome perpendicularly at the end of the thumb and carefully insinuate it between the tendons, after which it is passed outward or inward, as the case may be, beneath the tendon to be severed, the edge turned toward the surface, and the division made as in the preceding instances.

If the division is to be made below the malleolus, make the tendons tense; enter the knife about one half or three fourths of an inch in front of the tip of the malleolus, between the tendons, when either may be divided by cutting outward or inward, as the case may be.

The Division of the Tendon of the Tibialis Anticus Muscle.—The tendon of this muscle, like the tibialis posticus, is of importance in connection with talipes varus. It is the innermost tendon of the leg and foot on their anterior surface, and can be easily outlined unless the foot be fat and chubby, when some difficulty may be experienced.

In well-marked cases of talipes varus the tendon is displaced considerably to the inner side, and, if the foot be abducted, will become quite prominent. It is best divided about one inch above its insertion into the internal cuneiform bone. Make the tendon tense and pass the knife from without inward, to avoid the dorsalis pedis vessels.

The Division of the Tendon of the Extensor Proprius Hallucis Muscle.—As the tendon of this muscle passes across the dorsum of the foot, it can, like the preceding tendon, be quite easily distinguished. It may be necessary to divide it after the division of the extensors of the tarsus, on account of its causing undue extension of the great toe. The toe should be forcibly flexed and the tenotome carried beneath the tendon from without inward, to avoid the dorsalis pedis vessels.

The Division of the Tendons of the Extensor Longus Digitorum Muscle.—The tendons of this muscle may cause not only an obstinate extension of the toes, but may also aid in maintaining the tarsus in a state of forced flexion. They can be divided separately, as they pass along the dorsum of the foot, or all may be cut at once by flexing the toes, entering the knife beneath the tendons a little below the bend of the ankle, from within outward, to avoid the dorsalis pedis vessels.

The Division of the Tendon of the Peroneus Tertius Muscle.—The peroneus tertius may be divided together with the extensor longus digitorum tendons. It can be divided separately before its insertion into the dorsum of the metatarsal bone of the little toe by extending the tarsus and passing the knife beneath it from without inward. It is the most external tendon on the dorsum of the foot in front of the external malleolus.

The Division of the Biceps Tendon at the Leg.—The tendon of the biceps cruris forms the *external hamstring*, and is inserted into the head of the fibula and the outer tuberosity of the tibia. The external popliteal nerve is located immediately at its inner side (Fig. 196, J). To divide the tendon extend the leg, press the nerve aside with the thumb, and pass the tenotome from within outward beneath the tendon about an inch and a half above the head of the fibula, and divide the tendon toward the surface while it is supported by the finger.

The Inner Hamstring Tendons are the tendons of the semitendinosus, semimembranosus, gracilis, and sartorius muscles; the first two, however, are the ones principally concerned in deformities. The tendon of the semitendinosus is the longest, smallest, and nearest to the median line of the popliteal space; that of the semimembranosus is much deeper and runs parallel with the former. Either of these tendons can be divided by extending the leg to make the tendon tense, and entering the knife beneath it from the outer side, at the most prominent portion, and cutting toward the surface.

The Remarks.—Their division to relieve flexion of the leg will not always admit of its complete extension, due, among other things, to the contraction of the heads of the gastrocnemius, which are inserted into the condyles of the femur. The forced extension of the leg under these circumstances often causes the tearing asunder of the attachments of this muscle, especially the inner head, which is the larger and stronger and is inserted higher than the external. The hæmorrhage resulting therefrom may be severe enough to infiltrate the tissues of the popliteal space, thus simulating rupture of more important vessels. The liability to this rupture and consequent bleeding may be lessened, if not obviated, by first dividing the tendo Achillis; or, what is perhaps better, by first dividing the hamstring tendons, after which if, on attempting to straighten the limb, the foot becomes extended, the tendo Achillis can then be divided. After division of the hamstring tendons, fibrous bands and bands formed by tense nerves and vessels may be apparent to sight and touch in the popliteal space. The external popliteal nerve is often made quite prominent by the act of extension, and for this reason may be mistaken for undivided fibers of the biceps tendon. Forced extension in the presence of great and vigorous deformity exposes the popliteal vessels to the danger of rupture, and often causes pain and other disagreeable modifications of sensation of the areas supplied by the overstrained nerves.

The Division of the Tendons of the Gracilis and Sartorius Muscles.—The gracilis and sartorius tendons can be divided at the under side of the knee after forcible extension of the leg, by passing the blade of the tenotome close to the inner side of the tendon of the semimembranosus, between it and the gracilis, depressing the handle outward or inward, as the case may be, and dividing the structures toward the skin. The sartorius can be divided at a point two inches or so below its origin. For this purpose the thigh should be strongly abducted, and a blunt tenotome passed beneath the muscle and carried toward the surface.

The Division of the Tendon of the Quadriceps Extensor.—The quadriceps extensor tendon may be divided above the patella by making an incision down to the tendon parallel with the base of the patella; enter the point of the knife above the patella cautiously, and divide the tendon with a sawing motion. A careful and continuous effort to flex the leg should be made while the tendon is being cut, in order that its deepest fibers may be ruptured, thus avoiding, as far as possible, entering the synovial extension of the knee joint which lies beneath it. However, the limb should not be flexed further than is necessary for this purpose, and after the division it should be placed in a comfortable position till repair is well advanced.

The Division of the Tendon of the Adductor Longus Muscle.—The adductor longus muscle is situated at the inner side of the thigh, forming the inner border of Scarpa's triangle. It is, however, located on about the same plane as the pectineus muscle. It is tendinous at its origin from the pubes, and can be easily divided when made tense by passing the knife beneath its outer border an inch or so from the origin, and cutting upward and inward.

The Division of the Pectineus Muscle (Myotomy).—The pectineus muscle acts as a flexor and adductor of the thigh, and may require division on account of malposition of the limb. The pelvis is steadied, the thigh extended and abducted, which causes the fibers of the pectineus to become tense and prominent. A long-bladed myotome (Fig. 363) is then introduced at the outer border, about an inch below its origin, and carried inward and upward till the division is complete. The internal circumflex artery, which runs between the psoas magnus and the outer border of the pectineus, is the only vessel of any size exposed to injury. The danger to this is insignificant unless it arises higher than usual. If the division be made downward and inward, the femoral vessels will be less exposed than when made in the opposite direction.

The Tensor Vaginæ Femoris Muscle can be severed without difficulty by introducing a long-bladed tenotome beneath it, at either border, about an inch below its origin, and cutting toward the surface.

The Muscles of the Trunk. *The Multifidus Spinæ Muscle.*—This muscle lies at either side of the spinous process, in the groove formed between the spinous and transverse processes, extending from the sacrum to the axis. It is quite superficial in the sacral region opposite to the posterior superior spinous process of the ilium.

The Division of the Multifidus Spinæ Muscle (Myotomy).—Raise a fold of skin parallel with the long axis of the muscle; pass a long-bladed myotome from the spinous processes outward beneath the muscle to its outer border, and cut toward the surface.

The Division of the Latissimus Dorsi.—The tendon of this muscle may be divided separately at the lower border of the axilla, or conjointly with that of the teres major muscle, a short distance below their insertion into the bicipital groove of the humerus.

In either instance the arm is forcibly raised to render the muscle tense and prominent, and a long, narrow-bladed tenotome is inserted along the

anterior border, the edge directed posteriorly, and either tendon is carefully severed by an outward sawing motion.

The Latissimus Dorsi Muscle may be divided at the lower angle of the scapula in the following manner: Make the muscle tense as before, pass a long, strong tenotome beneath it, and cut carefully outward toward the surface; close the incision with an aseptic compress.

The Division of the Erector Spinae Muscle (Myotomy).—The erector spinae muscle forms the principal portion of the muscular prominence at either side of the spine in the lumbar region. It is a thick, strong muscle, which arises from the sacrum and contiguous structures, and divides at the lower border of the last rib into the longissimus dorsi and sacro-lumbalis, which muscles are inserted respectively into the transverse processes of the dorsal vertebrae and the angles of the lower ribs. The erector spinae can be divided with a long tenotome passed from the outer border of the muscle, just below the last rib, downward and inward toward the spine.

The Division of the Trapezius Muscle (Myotomy).—The trapezius muscle has an extensive origin. The portion which arises from the inner third of the superior curved line of the occipital bone is often divided on account of abnormal deviations of the head.

The division is readily accomplished by making the muscle tense, and severing it with a tenotome entered beneath it, just below the occipital protuberance, with the edge turned toward the integument.

The Division of the Sterno-Cleido-Mastoid Muscle.—Division of this muscle is often necessary in cases of wryneck dependent upon abnormal muscular force. It is divided at its lower extremity, either at its sternal or its clavicular attachment, often at both. For the division at either part, the muscle is put on the stretch by turning the head to the opposite side, a blunt-pointed tenotome is passed beneath it from the outer side, about half an inch above its insertion, and it is divided toward the surface.

The Remarks.—The division of the clavicular portion may be ample to correct the deformity; if not, the sternal portion should be severed in the same manner. It is necessary to hug closely the under surface of the portions to be divided, otherwise the deep-seated and important vessels may be injured. It is not safe to attempt a subcutaneous section of the muscle above this point on account of its relation to the common carotid artery and the internal jugular vein.

Tenorrhaphy or Tendon Suturing.—Tenorrhaphy is employed for the purpose of uniting the divided ends of tendons by sewing. General anaesthesia and entire absence of bleeding are essential to a satisfactory technique. Both recent and old divisions are amenable to this treatment, the more recent the better, however, as the older the division the greater the degree of the separation and the difficulty of uniting the divided extremities. It is very necessary that antisepsis be thorough, as a failure in this regard not only defeats the efforts of repair, but also may cause a destructive inflammation of the sheaths of the tendons and contiguous tissue.

The Special Considerations.—The chief difficulty of the operation consists in finding the divided ends of the tendons and uniting them with their

fellows. When any doubt arises regarding their identity, the ends of the tendons of those muscles having similar functions should be joined together. At all events, those having dissimilar functions should not be united. The distal ends are usually easily found, as they retract but little. The proximal ends are often found with difficulty, and may be lost on account of strong retraction, especially in those cases where division takes place during great muscular effort. Sometimes simple flexion or extension of the limb, as the case may be, will bring them into view. The proximal ends can be forced downward by grasping with both hands the circumference of a limb, where muscles are divided, and drawing downward; also by the application of an Esmarch's bandage from above downward to almost the seat of the injury. If these measures fail, a longitudinal incision is made parallel with, but not over the tendon, for when thus approached the danger of subsequent adhesion of the superficial and deep tissues is reduced to a mini-

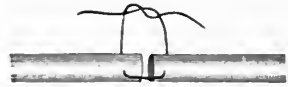

FIG. 343.—Tenorrhaphy, simplest method.



FIG. 344.—Tenorrhaphy, quilt suture.

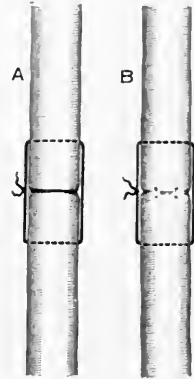


FIG. 345.—Witzel's method.

mum. If this plan be not feasible, then introduce into the vacant sheath up to the end of the tendon a probe, upon the end of which a short incision is made from without down into the sheath; push the probe through the opening, and raise the end of the tendon through also; connect the end of the tendon with the end of the probe by means of a small cord tied

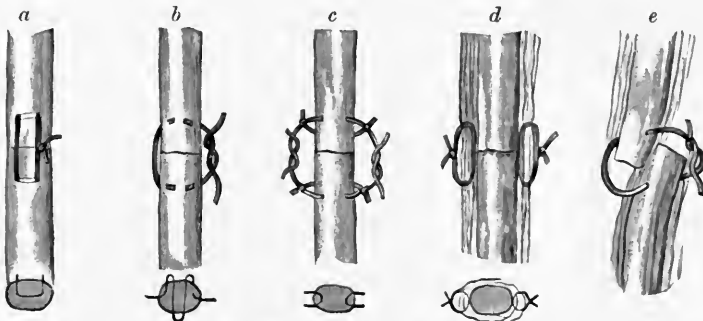


FIG. 346.—a, b, c. Wöfler's quilt suture. d, e. Hueter's peritendinous suture.

firmly; withdraw the probe, dragging the tendon after it down to the open mouth of the sheath. Silver wire, chromicized catgut, fine silk, and

kangaroo tendon are acceptable for tendon suturing. The ends of a divided tendon can often be held in proper place by means of one or more sutures passed through them and tied (Fig. 343). If there be danger of the sutures tearing out, another method of arrangement may be used instead (Fig. 344). Witzel's method is a simple one and quickly utilized (Fig. 345). Witzel introduced a single tendon suture of medium-sized catgut at a distance from the tendon ends, drew them together (Δ), and then supplemented this one by smaller adjustment sutures (B). The quilt suture of Wöller (Fig. 346) is suited to meet a considerable degree of tension. In instances of great tension, Nicoladoni advises that the central part of the tendon



FIG. 347.—Billroth's bundle-suture.

be fixed to the integument at some distance above the wound by a deep suture or an acupuncture needle, after which the ends are united by ordinary sutures. The central part can be stitched to a contiguous unimpaired tendon with catgut for a similar purpose. The method practiced by Billroth is, however, better and simpler than Nicoladoni's. Billroth tied a suture to a bundle of fibers (Fig. 347) at either side of each end of the severed tendon, and drew the ends together. When thus placed the suture grasps the fibers at a right angle with their long axis, and thus obviates the tearing out so much dreaded with great tension.

Oblique division of the extremities, and union by a suture carried directly through them (Fig. 348), can be practiced when the sacrifice of the tendon structure in the accomplishment of the coaptation does not cause undue shorten-

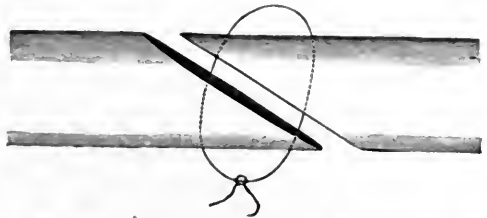


FIG. 348.—Oblique coaptation of divided ends.

ing. If but little tendency to separation be present, suturing together the peritendinous tissues of the extremities may suffice (Hueter, Fig. 346, *d, e*). However, this plan is of infrequent and uncertain utility.



FIG. 349.—*a*. Hueter's method, single flap. *b*. Glück's method, catgut repair.

In order to bridge an unavoidable gap in a tendon, several strands of fine catgut are connected with and caused to extend between the separated ends, thus laying the foundation for a possible repair (Fig. 349, *b*). The introduction of a tendon graft in these cases, of sufficient length to fill the gap, taken from a cat or other suitable source, is entitled to further trial. However, if the tendinous sheath have been destroyed, there is little chance, indeed, of benefit from the last-mentioned expedient.

Tendon lengthening may be utilized to remedy deformities due to otherwise irremediable short-

ening of tendons dependent on contraction and sloughing, which are often the sequel of traumatism and inflammation.

A tendon can be lengthened by a single flap (Figs. 349, *a*, and 350), or it may require for the purpose the union of double flaps, one from the end of each extremity (Fig. 351). The making of alternate free incisions at the borders of a tendon—the accordion plan—so as to cause the tendon to assume an accordion-like appearance when lengthened (Fig. 353), is much more ingenious than practical. Less pronounced cutting (Fig. 354) followed by tendon lengthening is called the incision method (Fig. 355).

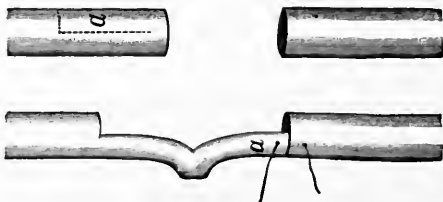


FIG. 350.—Single-flap method.

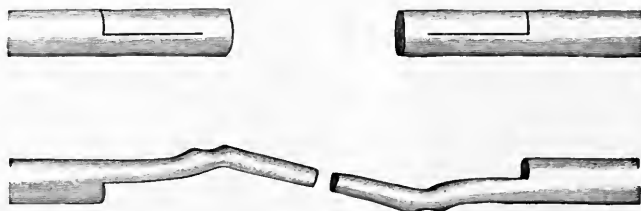


FIG. 351.—Double-flap method.

Lengthening of the tendo Achillis to overcome contraction is sometimes practiced. Through a free incision the tendon is exposed and divided according to the plan of Anderson (Fig. 352), or by still another resembling Anderson's. In this the ends *a* and *b*

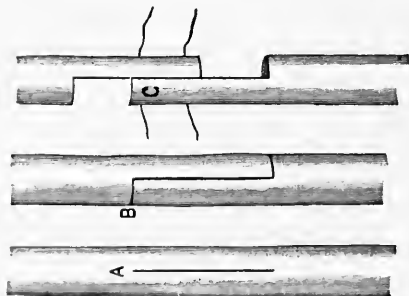


FIG. 352.—Anderson's double-flap method. A. Longitudinal division. B. Flaps formed. C. Tendon lengthened, flaps united.

are united together (Fig. 356), or the accordion method can be utilized. The former, however, is much the better.

Transplantation upward of the

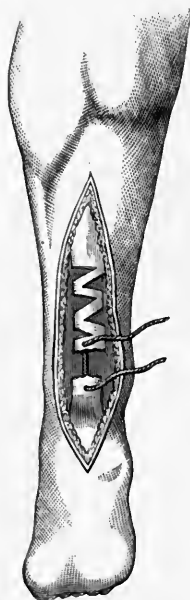

FIG. 353.—A. Poncet's accordion method.



FIG. 354.—Incision method.

tubercle of the os calcis can be practiced by division of the os calcis through a U-shaped incision (Fig. 357) made immediately behind the insertion of the tendon, followed by extension of the foot and the nailing together of the sawed surfaces, as a supplementary measure to the lengthening of the tendon by direct method of practice (Fig. 358). However, the small gain thus achieved by the former is not commensurate with the risks incurred, to say nothing of the ill effect of the measure on the functions of the heel.



FIG. 355.—Tendon lengthened in incision method.

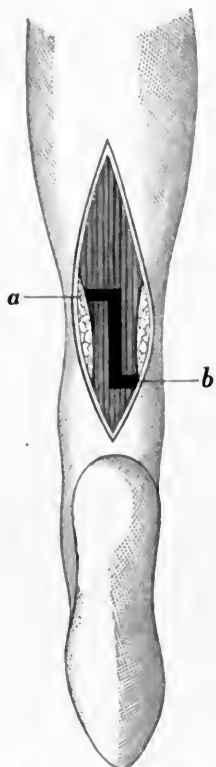


FIG. 356.—Lengthening tendo Achillis.

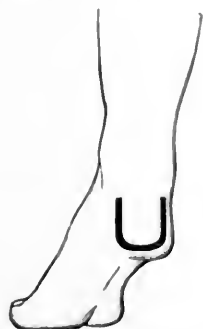


FIG. 357.—Incision for transplantation of tubercle of os calcis.

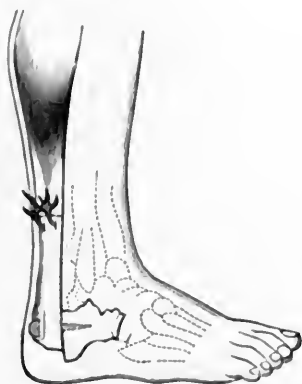

FIG. 358.—Transplantation of tubercle of os calcis; tendon already lengthened.

Tendon shortening is practiced for the purpose of improving the action of muscles where power is lessened by the elongation of their tendons. The removal of a proper segment of a tendon and union of the divided extremities can be accomplished by either a simple oblique division and lateral apposition and union (Fig. 348), or simple division followed by intergrafting of the extremities and union; i. e., the introduction of the wedge-formed extremity of one into the split end of the other and fixation with sutures.

Shortening of the tendo Achillis to remedy talipes calcaneus is sometimes practiced.

Gibney's Method.—Expose the tendon through a Y-shaped incision, di-

vide it from behind forward and below upward very obliquely; draw the upper portion downward as far as possible and suture it to the lower; confine the foot firmly in place until union of the divided ends to each other is secured.

Willett's Method.—Make a Y-shaped incision two inches in length down to the tendo Achillis at its lower end; expose the tendon at the superficial and lateral surfaces only, corresponding to the stem of the Y; sever the tendon at the points of junction of the vertical portion with the arms of the Y; dissect along the deeper surface of the tendon and raise the proximal part with its connection to the integument intact for three quarters of an inch; cut from the deep surface of the proximal end and the superficial surface of the distal one a wedge-shaped slice, with the base corresponding to the point of transverse division of the tendon in each instance; press the heel upward and draw down the proximal portion, thus apposing the cut surfaces of the respective portions with each other, and while the parts are thus held pass two sutures at either side through the integument, the apposed extremities of the tendon, and out through the integument, and tie them; unite the borders of the integumentary incisions with sutures, leaving a V-shaped appearance to the cut. Confine the foot until repair is complete.

The Z Method (Fig. 359).—Expose the tendon through a vertical incision, dividing the skin horizontally at the upper and lower ends of this incision, if necessary; divide the tendon from one border half-way through (*A B*); split the tendon from this point downward far enough to meet the demands of the required shortening (*B C*); then sever the remaining portion of the tendon at a right angle with the vertical incision (*C D*); remove *A B A' B'* and *C D C' D'* from the respective extremities; unite the borders *C D* and *C' D'* and the borders *A B* and *A' B'* with each other respectively with sutures, and also the vertical borders *B C*. Each part cut away is equal in length to the shortening required.

The Remarks.—The union of the ends of the tendon by sutures after the removal of a section by transverse division is of questionable utility, as the deformity may soon return on account of undue yielding of the bond of union and the stretching of the paralyzed muscles of the calf. In cases of infantile paralysis plastic operations on tendons are useless unless active fibers be present in the muscle, as indicated by electric stimulation.

Transplantation downward of the tubercle of the os calcis, to overcome lengthening of the tendo Achillis, can be practiced by nailing the posterior fragment to the lower rather than to the upper aspect of the sawed surface of the anterior fragment (Fig. 358).

Tendon Transplantation (anastomosis).—By tendon transplantation movement is imparted to tendons of paralyzed muscles by grafting them with those of animated muscles having a similar action. Grafting was first practiced by Nicoladoni in 1882.

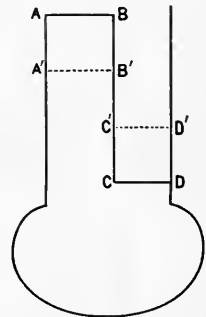


FIG. 359.—Z method of shortening tendo Achillis.

In Figs. 360 and 361 the healthy tendon is situated on the right, and is of a uniform color, while the tendon of the paralyzed muscle is on the left and of a dotted appearance.

In the first series (Fig. 360) the tendon of the muscle from which the power is derived is functionally unimportant.

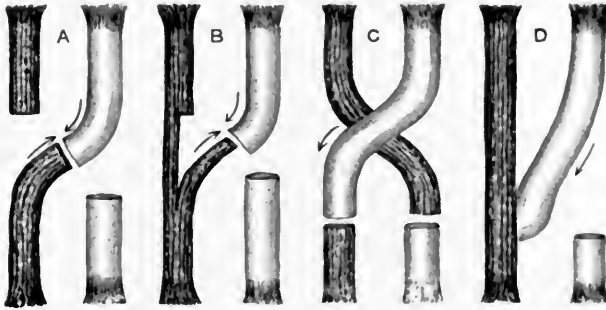


FIG. 360.—Tendon transplantation. First series.

In the second series the tendon of the healthy muscle is functionally important.

In the first series one is warranted in diverting the muscle completely from its natural course and making use of the entire tendon.

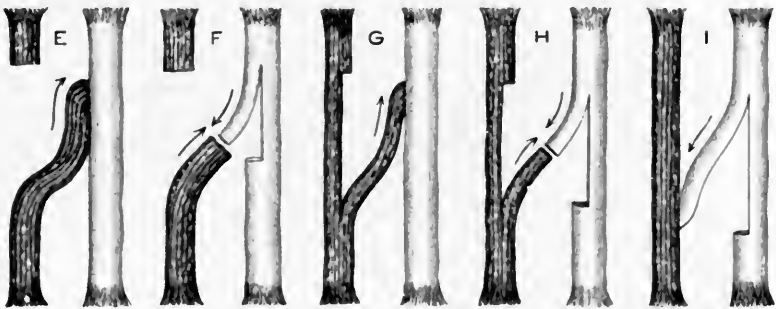


FIG. 361.—Tendon transplantation. Second series.

A is employed where the muscle is completely paralyzed.

B, *C*, and *D* are employed where some function still remains in the paretic muscle.

In the second series (Fig. 361) power is obtained from muscles the normal function of which can not be wholly spared and whose action therefore can not be entirely diverted into another course. The continuity of the healthy tendon is here preserved.

In *E* the diseased tendon is completely paralyzed; the healthy tendon is completely intact.

In *F* the healthy tendon is split in half; the diseased tendon is completely paralyzed.

In *G* the diseased tendon is paretic; the healthy tendon is entirely intact.

In *H* each tendon is split in half; the diseased tendon has still a little power left in it.

In *I* the healthy tendon is split in half; the diseased tendon may be either paretic or completely useless.

The arrows indicate the directions in which the loosened tendons and parts of tendons are drawn in the methods of transplantation.

The arrows are arranged in three fashions:

1. *The descending transplantation method* shows the arrows pointing downward toward the diseased tendon (*C, D, I*).

2. *The "double-sided" transplantation method* shows sets of arrows pointing toward each other (*A, B, F, H*).

3. *The ascending transplantation method* shows arrows pointing from the diseased tendon upward toward the healthy tendon (*E, G*).

The Operation (Vulpius).—Lay open the tendon sheaths by long parallel cuts, so that the strengthening ligaments which hold the tendons in place are saved. The tendons to be transplanted are either entirely or partially loosened for some distance in order to permit of a considerable distortion. A piece of the muscle belly is perhaps separated by blunt dissection and left in connection with the tendon.

If thick tendons lying close together are transplanted, the operation is simple. If they are widely separated, it is necessary to effect a blunt sub-facial dissection. A forceps is pushed beneath the soft parts, deep under the fascia, because here deformities of the tendons are less to be feared, rather than to await the quick building up of a tendon sheath. The bridge of soft parts must be of such a length that the tendon can be brought in a direct line to its new point of insertion. The diseased tendon need not be divided. When not divided, draw the healthy and diseased tendons toward each other, by means of instruments, and make a buttonhole in the diseased tendon at the proper place, into which the transplanted tendon can be slipped. Afterward a second similar slit could be made nearer the periphery, so as to make a true braid. Stitches fix the tendons at the situations where they pass through slits and also between them. When divided they are joined as indicated in Fig. 362.

The Remarks.—The presence of atrophy of tendons verifies the loss of power of their muscles and makes the diagnosis sure.

It is recommended to bring the end of the muscle bundle in sight, which, if it presents a white, pink, or dark red color, would indicate paralysis, paresis, or a normal condition respectively.

In order to avoid tearing out of the tendons, employ a strong stitch, the tendons being put on the stretch.

In correcting the deformity as it is brought into normal and even over-corrected position, the extremity should obey light pressure.

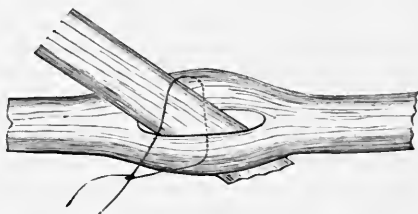


FIG. 362.—Tendon anastomosis; tendon divided.

If the transplantation is well made, one should be able to recognize, while the patient is still under the anæsthetic, that the extremity no longer hangs as loosely as before, and no longer shows the strong tendency to a faulty position, but with a sure elastic tension, remains in at least a partially corrected position. Care must be exercised in the selection of a healthy muscle, the tendon of which is to be joined to the tendon of an unhealthy one, that its action be similar in nature to that of the paralyzed muscle.

The Choice of Methods.—The descending transplantation method, if possible, as well where the whole tendon is transplanted (*D*) as where it is partially transplanted (*I*), is the acceptable method.

After eight days the patient is allowed to get up, wearing an "overshoe," and in all wears the bandage from four to seven weeks, according to the degree of the existing deformity.

The after-treatment consists in the employment of massage, gymnastics, baths, electricity, etc., and the more faithfully they are practiced the quicker and more perfect is the recovery.

The Results.—*Vulpinus* reports twenty-one tendon transplantations on nineteen patients.

One case completely failed as a result of suppuration of the tendon sutures.

Two cases failed on account of very extensive paralysis and unsatisfactory technique.

The results of all the others were thoroughly good and satisfactory considering the individual proportion of strength. Sometimes the result was a perfect one beyond expectation. Furthermore, it was shown that the result not only was lasting, but that in the course of months it improved still more.

Tabulated Statement of Thirty-three Cases of Tendon Transplantation, with Results (Vulpinus):

Results good.....	20 cases.
Results good, or satisfactory, but not perfect.....	4 "
Improved.....	3 "
Not improved.....	2 "
Doubtful or unknown results.....	4 "
Total.....	33 "

Nicoladoni grafted the peroneal tendons to a freshened surface of the tendo Achillis to restore motion to a paralyzed calf. *Goldthwait* connected the sartorius muscle with the fascia over the rectus femoris and vastus internus portions of a paralyzed quadriceps extensor. An active extensor of the great toe can be caused to contribute a portion of its vitality to a powerless anterior tibial muscle by grafting. Numerous examples illustrating the idea are reported.

Certainly there is much to encourage the belief that substantial benefit will follow the practice. The foregoing figures suggest the method of procedure. Thorough asepsis and strict quietude of the parts should be enforced until union has taken place.

Muscles and their sheaths are ruptured either conjointly or separately from the effects of muscular and other forms of violence. Muscles require division to overcome deformities incidental to their contraction.

Myotomy, or division of muscle, is performed in substantially the same manner, and for similar purposes as the division of tendons. The liability to hæmorrhage is greater in the former, on account of the greater vascularity of the divided tissues. *The open and the subcutaneous* methods of division can be employed, the latter being the better. The blade of the myotome should be long, narrow, and blunt, for obvious reasons (Fig. 363). The direction of the division in myotomy is determined by the demands of the case. The transverse, oblique, and V-shaped sections are the ones in common use. If the transverse open incision be made, and the separation of the divided extremities be extensive, the space between them can be bridged with numerous catgut sutures connected with each end of the divided muscle. The sutures and the blood clots entangled in them after the closure of the wound soon lay the foundation of repair in favorable instances.

The oblique division of a muscle consists in making the section of the entire structure in an oblique direction from without, inward and downward, or *vice versa*, as circumstances dictate. The length and the degree of obliquity will be regulated by the extent of the shortening of the muscle, as indicated by the degree of the deformity and the ability to correct it by division of the contracted muscle. This measure is practiced best through an open incision made parallel with but not in line of the proposed muscular section, for if thus placed the cicatrix of the skin may unite to that of the soft parts beneath and thus cripple the muscular action. After oblique division and rectification of the deformity, the divided borders are stitched together with fine catgut. If the contraction of the divided muscle be so pronounced as to narrow the line of repair to a serious degree, the muscle can be supplemented in width at this situation by the use of catgut threads employed at either side of the muscle in the manner already described. The external wound is closed carefully, the limb bandaged and confined in a fixed position, that will contribute to relaxation of the severed muscle.

The V-shaped division is employed frequently in connection with the broader muscles with the idea of rectifying a deformity or fortifying a weak point. As an illustration of the former proposition, the quadriceps extensor is sometimes thus divided—after the necessary separation of the vasti portions—to enable one to approximate properly the upper and lower fragments of an old fracture of the patella attended with otherwise irreducible separation. This method is practiced best through an oval flap reaching down to the quadriceps itself. The length and obliquity of the arms of the V will depend on the degree of shortening of the muscle, i. e., the greater the shortening, the greater their obliquity and length should be. The sliding of a portion of a broad muscle by the agency of the V-shaped incision, for



FIG. 363.
Myotome.

the purpose of strengthening a weakened point, as of the abdominal wall, is a measure that befits the repair of weakened points of this part of the body. The incision should be so placed with reference to the direction of the muscular fibers as to comply readily with the demands of repair, as referable to the extent of the sliding and the magnitude of the displaced tissue. Incisions of other forms than those already cited can be devised for the purposes in question.

The deltoid muscle can be divided at either border, at the central part, or through its entire thickness near the point of insertion, depending on whether or not the entire muscle or isolated portions of it are involved. In either case the muscle is relaxed, the myotome inserted beneath the fibers, which are divided by cutting toward the surface. The blood is squeezed out of the opening on withdrawal of the blade, as in tenotomy.

The pectoralis major can be divided at the tendinous insertion or further inward at the axillary fold. In either instance the long, blunt-bladed tenotome is pressed beneath the muscular tissue, and the division is made toward the surface.

The rupture of a muscle or of its sheath often requires active surgical treatment, especially if the skin be involved. In the former injury, with skin involvement, the ruptured ends of the muscle are trimmed, united with catgut sutures, the wound is closed and the part immovably fixed in such a position as to relax the injured muscle. If the common method of introduction of sutures into the borders of the divided muscle be not effective, bundles of muscular fibers at either side of the wound may be tied separately by the ligatures, the loose ends of which are then drawn so as to bring the muscular surfaces together, and tied the same as in tenorrhaphy (Fig. 347).

If the sheath be ruptured, the rent is exposed by an incision made at the seat of the injury. The muscular fibers are pushed back into the sheath and the borders of the rent are sewed together with fine silk or catgut. The remaining dressing is the same as for the rupture of a muscle.

Ligaments not infrequently become shortened, elongated, or ruptured, as the result of disease and traumatism. In order that the afflicted part may be promptly and properly restored to position, the ligaments must be divided and repaired in many cases.

Syndesmotomy is the operation of the division of ligaments either by the subcutaneous or open method, the latter being more frequently practiced. The technique of this procedure will appear in connection with operative treatment of deformities of the foot, since it is most frequently employed in that class of cases. The best illustration of *elongation or rupture* of a ligament is seen when such conditions affect *the ligamentum patellæ*. *If elongated*, it can be shortened in the same manner as in elongated tendons elsewhere, or the tuberosity of the tibia into which it is inserted can be displaced downward by means of a mallet and chisel, and fastened to the bone with nails or silver wire. *If ruptured*, a free incision should be made down to the rend in the long axis of the ligament, the extremities united together with kangaroo tendon, catgut, or silk, the wound closed and the

limb slightly elevated and confined firmly in the extended position for three or four weeks. If the tendon be so much damaged as not to permit proper apposition of the ends, the catgut bridging employed for the repair of the tendons can be utilized. Another plan is to displace upward the tubercle of the tibia with the mallet and chisel, and fasten it in the new position with small nails or silver wire. But little advantage, however, can follow this step on account of the limited bone surface above. Moreover, necrosis of the fragment may ensue for this reason. Our experience in this measure is not flattering. The part should then be dressed antiseptically and otherwise treated as for fracture of the patella.

Fascia.—Although the entire body is wrapped in fascia, it is only to certain parts, as the palm of the hand, the sole of the foot, and to the fascia lata, that special attention is directed, on account of morbid manifestations.

The *plantar fascia* is an exceedingly dense, white fibrous membrane of great strength, with the fibers arranged longitudinally. *It is divided into three portions*, the middle and two lateral. The former is the one especially concerned in those deformities requiring division. It is narrow behind and attached to the inner tubercle of the os calcis; broader and thinner in front, and divides into five processes opposite the middle of the metatarsal bones, there being one for each of the toes. Each of these processes divides opposite the metatarsophalangeal articulations into two slips, which embrace and are inserted into the sides of the flexor tendons, blending with their sheaths and with the transverse metatarsal ligament. It likewise sends prolongations between the groups of the plantar muscles. This fascia serves the important function of assisting in maintaining the integrity of the plantar arch. It is frequently contracted in deformities of the foot, and requires division to accomplish a cure.

The Operation of Plantar Fasciotomy.—Extend the foot firmly, thus placing the fascia on the stretch. "Point pressure" is then made to establish the proper seat for division. Introduce beneath the inner border of the fascia at the point of greatest pressure-irritation a long-bladed, sharp-pointed fasciotome (Fig. 364), turn the edge toward the sole and cut through the fascia to the integument. If the foot is vigorously extended at this time, the last fibers of the fascia will be ruptured. Press out the blood, close the opening with a suture or an antiseptic pad, rectify the deformity, and confine the foot in proper position (Fig. 342) until the wound is healed. The internal plantar artery should be avoided by keeping the blade close to the inner border and deep surface of the fascia. The division of the bands at the phalangeal junction must be carefully made, or the digital arteries and nerves will be severed. Care should be practiced in overcoming a pronounced deformity, or rupture of the digital nerves will happen. Relapse sometimes follows this method of treatment.



FIG. 364.
Fasciotome.

The Palmar Fascia.—The palmar, like the plantar fascia, is divided into three portions, the middle being of special significance. This portion is narrow above and is connected to the lower border of the annular ligament; below it is broader and thinner, and opposite the heads of the metacarpal bones divides into four slips, one for each finger. Each slip subsequently divides into two processes, which inclose the tendons of the flexor muscles, and are attached to the glenoid ligament and to the sides of the meta-

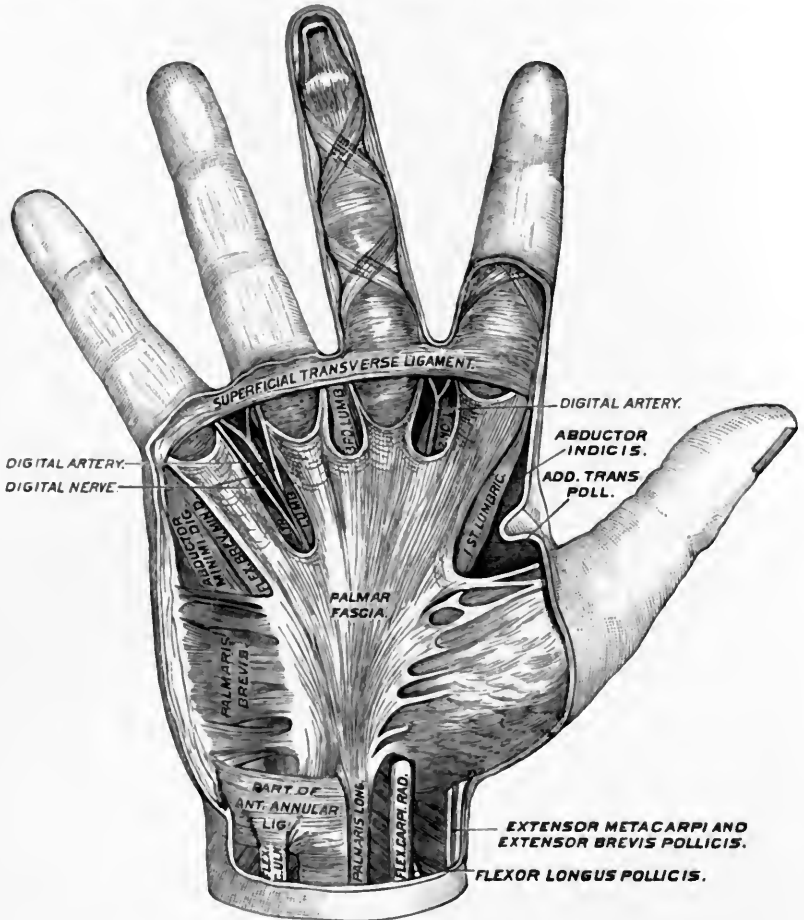


FIG. 365.—Palmar fascia.

carpal bones, and extend upward over the flexor tendons nearly to the tips of the fingers (Fig. 365). This fascia is intimately connected with the integument of the palm, and sends vertical septa between its muscles. From various causes it may undergo structural changes which result in contractions of the fingers on the palm, as well as shortening of the palm itself. The anatomical arrangement of the fascia fully explains the mechanism of these deformities.

Dupuytren's Contraction.—This deformity depends upon the contraction of the elongations of fascia of the palm, connected with the digits (Fig. 366); the morbid process more frequently manifests itself in the ring and little fingers, oftentimes causing them to become opposed to the palmar surface of the hand.

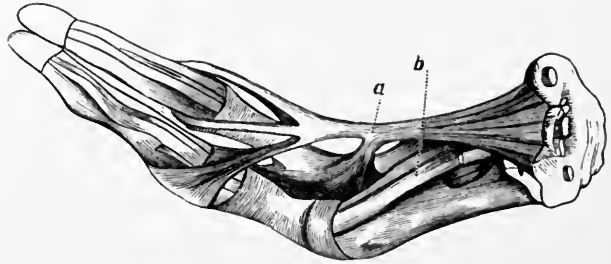


FIG. 366.—Fascial contractions.
a. Fascial contractions. b. Flexor tendons.

The Fallacy.—This deformity may be confounded with that dependent upon

contraction of the flexor tendons. An examination of Fig. 366 will enable the surgeon to make a clear distinction between the two conditions.

Adams's Method.—Anæsthetize the patient, render the constricting bands tense by a firm extension of the affected digits, and then, under anti-septic precautions, divide the restraining bands at short intervals, subcutaneously (Fig. 367), at unattached points of the skin, with a sharp-pointed, narrow-bladed, strong, short fasciotome (Fig. 368), the edge being directed from the surface of the palm. When sufficiently liberated the digits can be freely extended, in which condition they are to be confined by dorsal splints until repair is completed. Passive motion and forcible extension until the tendency to contraction is overcome, comprise the important elements of the after-treatment. The outcome is often unsatisfactory.

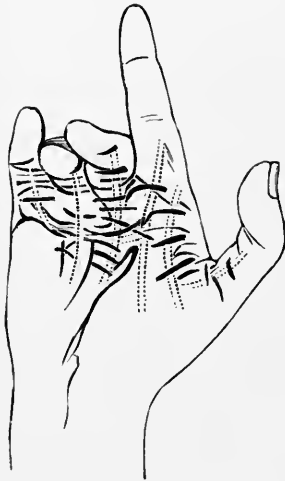


FIG. 367.—Transverse incisions in Dupuytren's contraction.

The Results.—Relapse not infrequently takes place owing to the continued presence of the primary cause and the inheritance by the new tissue of the characteristics of the old.

Goyraud's Method.—Goyraud made longitudinal incisions over the tense digital elongations of the fascia, dissected the integument from them, after which they were divided transversely sufficiently to permit extension of the digits. He closed the integumentary incisions and confined the fingers in a straight position until healed. The success of this method is gratifying.

Hardie's Modification of Goyraud's Method.—Apply an elastic bandage to the hand, make an incision from half an inch above the principal transverse fold of the palm to beyond the bone of the last phalanx involved down to the band, and carefully expose the con-



FIG. 368.
Strong, short fasciotome.

tracted tissue; sever the bands at the webs of the fingers between this and the adjacent contracted elongations; divide the main bundle at the upper end of the incision and completely extend the phalanx. If required, make transverse incisions opposite the bundle of the first and second phalanges, cut away portions of fascia that oppose complete extension of the finger, and remove entirely isolated projecting portions of fascia. Treat likewise the remaining fingers of the hand similarly deformed, remove the bandage, tie briskly bleeding points, drain the wound the entire length with horse-hair, close the incision with silver wire, apply an antiseptic pad to the palm and a straight splint to the fingers, and bandage both in position. The dressing is renewed on the following day, again applied, and not disturbed for a week without special reason. The use of the splint is continued for two or three weeks and the fingers are occasionally flexed and extended. *Treves* omits the elastic bandage and drainage and closes the wound with silkworm gut. He excises as much of the contracted fascia as can safely be removed, causes the splint to be worn for a month, after which massage of the palm and passive motion of the fingers is practiced until a satisfactory result is obtained.

The Remarks.—Complete antiseptic technique should be practiced, as the wound is severe and exposes the patient to the danger of extensive and destructive inflammation of the hand. Radical measures are the better, and expose the patient to no unusual dangers when practiced with thorough antisepsis. Adams's method can be done well with cocaine anæsthesia in many instances.

The fascia in other situations may become contracted, as the fascia lata at its upper or lower extremities. Whenever these contractions cause a persistent deformity they should be divided, and upon the same principles as like tissues in other portions of the body.

Bursæ.—The synovial and mucous bursæ are each liable to annoying enlargements, the result of chronic and acute inflammatory processes of traumatic or idiopathic origin. The enlargements communicate so frequently with the general synovial cavity of a contiguous joint that they should be approached with great care and strict antisepsis. The characteristic pathological manifestations of this variety of infliction occur in connection with the synovial sacs of the carpus and the tendinous sheaths of the tendons of the wrist, and are known respectively as *ganglion* and *chronic thecitis*, the latter being usually of tuberculous origin.

Ganglion (Weeping Sinew).—Ganglion is developed on the dorsal surface of the carpus and is connected with the sheath of a tendon at this situation or with the synovial sac of a carpal articulation.

The Operative Methods of Cure of Ganglion.—After the failure of simpler methods of relief the sac of the tumor may be ruptured by a sudden pressure of the thumb, by a sharp blow from the back of a book, or a similar agent. These measures cause rupture of the sac and the escape into the connective tissue of the contents, which are subsequently absorbed. However, they frequently recur when thus treated. Another simple and quite effective means of cure is the injection into the sac, after withdrawal of a portion of the fluid by a hypodermatic syringe, of a few drops of a five- or ten-per-cent

solution of carbolic acid and glycerin. Not infrequently in this instance a quite severe inflammation follows the injection. Therefore, after the injection the hand should be kept quiet, and, if indicated, cold lotions are applied to the part. If the sac be so tough as to withstand the force used for the purpose of rupture, it may be incised subcutaneously and under strict antiseptic precautions with a small, sharp-pointed tenotome. The fluid, when thus liberated, escapes into the connective tissue and is absorbed as in the first instance. Finally, if the tumor be very large or hard, or have resisted the simpler methods of cure, a free incision is made down upon it, and the sac is dissected from the tendon or cut away from the synovial membrane of the articulation. In the latter case a sufficient amount of the membrane should remain behind to permit of the sewing together of the borders with fine catgut or silk, thus closing the cavity of the joint. In every instance of free incision a strict antiseptic technique should be enjoined for obvious reasons. In the synovial bursæ associated with other and larger joints of the body, attempts at cure by aspiration and the injection of antiseptic stimulating fluids should be made before free incision is practiced. And in the latter instances great care must be exercised to avoid the disastrous results incident to unwise aggression and faulty technique.

Mucous Bursæ.—Mucous bursæ are situated between the integument and subcutaneous bony prominences at situations exposed to friction or pressure. Those located over the patella and olecranon process are the best illustrations of the variety, and will suffice for the proper consideration of the morbid processes of this class of bursæ.

Prepatellar Bursitis (Housemaid's Knee).—Aspiration, tapping, and injection, the seton or incision, are the methods of cure applied to this disease. Aspiration is simple and inefficient; tapping and injection are frequently successful; the seton is beneficial though troublesome; incision is the surest of all means of cure. The withdrawal of a portion of the fluid, and the injection of a small amount of a solution of carbolic acid and glycerin, is frequently followed by cure. The patient should be kept quiet for two or three days, and cold lotions applied to the part when essential to comfort. The introduction through the tumor of one or two silken threads saturated with stimulating fluids, such as the compound tincture of iodine, solutions of carbolic acid, etc., frequently lead to satisfactory results. This plan is, however, often annoying and protracted, on account of the discharge and tardy therapeutical action. Free incision and packing with gauze after scraping the cavity is the surest plan of cure. The incision can be made at one or both sides of the tumor at the most dependent part, as may seem the best. The making of a straight or crucial incision at the summit of the tumor is sometimes practiced in order to reach the remotest limits of the sac, which can be dissected out if deemed advisable. However, this plan localizes not infrequently a sensitive scar at the point of common pressure. If the sac be dissected away, close apposition of the divided borders can be secured, and prompt union and rapid recovery will follow. If the sac remain *in situ* the wound is usually packed with antiseptic gauze, and permitted to heal slowly from the bottom.

Post-olecranon Bursitis (Miner's Elbow).—Bursitis at this location can be cured by either of the methods directed to the relief of the prepatellar variety. In this instance, however, the dissection of the sac from its environments must be carefully done, or the joint cavity will be invaded, or the tendon of the triceps impaired.

Thecitis.—Thecitis is an obstinate and troublesome affection usually of the synovial sheaths of the flexor and extensor tendons of the carpus, characterized by a fluctuating deformity dependent on the presence in the dilated sheaths of a fluid of varying character and consistency, and often containing the so-called rice or melon-seed concretions of fibrin. Tubercle bacilli, too, are frequently present in these cases. The extent and communicability of the sheaths of the flexor tendons are well exhibited in Fig.

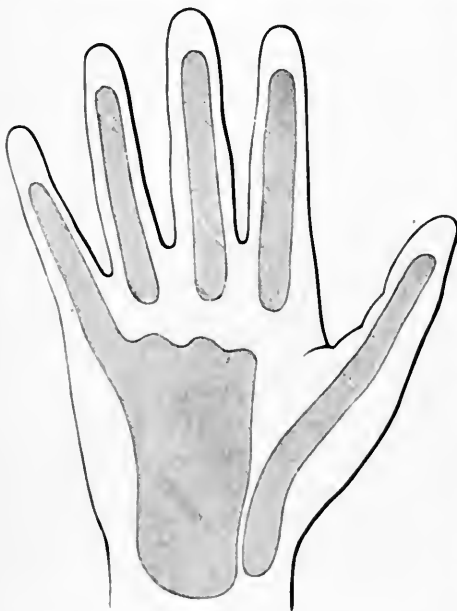

FIG. 369.—Tendinous sheaths of digits, palm, and wrist.

369. Operative treatment holds out the only reasonable hope of cure in these cases. *Tapping and injection, evacuation and scraping,* and *excision* are the operative measures employed. Tapping and the injection of curative fluids require but brief mention here, as their therapeutic efficacy and practical technique are properly measured by a like treatment of similar conditions elsewhere in the body. The introduction into the sac of a mixture of iodoform and glycerin is regarded by some observers as having a special virtue.

The operation of evacuation and scraping contemplates a free incision into the tumor at the most commanding point, and a thorough scraping of the sheaths of the tendons with properly shaped curettes and scoops. The strictest antiseptic surveillance must be

practiced, or serious inflammatory results will follow. The wound should be closed with silkworm gut and covered with firmly applied pads of antiseptic gauze combined with sponge pressure. Then the wrist joint is immovably fixed until inflammatory reaction is in abeyance, after which the fingers are frequently though carefully manipulated.

Excision.—Excision offers the best means of cure, especially if the fibrous connections and tuberculous infection be present.

The Operation.—Apply an elastic bandage to the hand and forearm, make a free incision into the tumor, and, if necessary to reach the disease, through the annular ligament as well. Carefully and patiently dissect away and remove all diseased structure, harming as little as possible the contiguous

healthy tissues. If a portion of a tendon be involved, the diseased part should be excised and the tendon repaired. The ligaments, fascia, and integument are each united independently with fine catgut or silk sutures, leaving a small opening at either end. An antiseptic compress is uniformly and firmly applied to the wound, and the extremity immovably fixed with a splint. This dressing need not be renewed for a week or ten days, except for some special reason. After the first forty-eight hours the patient is directed to move the fingers actively at intervals until repair is established, in order that the new tendinous tissue may become suitably fitted for use. Relapses of the disease may occur, and in fact the patient may succumb to tuberculous involvement of remoter and more important parts.

Acute Thecitis or Tenosynovitis.—It is very important to note in connection with this, so often functionally disastrous inflammation of the hand, the relations which its tendinous sheaths bear to each other; for an infected little finger is often followed by rapid involvement of the palm, causing a destructive palmar abscess. Again, infection of the palm inflicts the little finger, but not usually the ring, middle, and index fingers, for apparent anatomical reasons (Fig. 369). For like reasons the thumb only may become involved from above, or it may, when infected, lead to extensive invasion of the forearm without much palmar complication.

The Treatment.—Prompt and free incisions of only the regions invaded, attended with thorough cleansing and perhaps removal of infected membranes, should be practiced, followed by careful drainage and aseptic dressing. Later, passive motion, massage, etc., should be patiently and persistently employed.

CHAPTER VIII.

OPERATIONS ON BONES.

THE injuries and diseases to which bones are liable, although not differing in any essential particular from similar conditions of the soft parts, require an independent consideration on account of the difference in function and structure of the osseous system. The integument and soft parts generally are each the seat of inflammation, ulceration, and gangrene. Bony tissue is likewise afflicted by the same morbid processes, named, however, differently: caries of bone being comparable to ulceration of the soft parts, while necrosis of bone finds its synonym in gangrene of soft parts. The unimpaired preservation of the mechanical functions of tissues is the great aim in surgery. Therefore since the practical functions of bones are to support the body, protect important organs, and serve as levers for purposes of prehension and locomotion, one has but to act with a knowledge of these facts and of the methods to maintain them, to give to the patient the full benefit of our art.

The operations upon bone are denominated *gouging*, *sequestrotomy*, *excision*, *osteotomy*, and *osteoplasty*.

Gouging.—Gouging is applied to the removal of carious bone, and should not be attempted until the process has become chronic (Fig. 370).

The Operation.—Having arranged the patient in a position suitable for the convenience of the operator, administer an anæsthetic, apply the elastic bandage if practicable, carrying it lightly over the site of the disease, locate the diseased bone with a probe, make a free incision down upon it, separate the soft parts with retractors, then with the gouge, bone burr, etc., remove the diseased structure.

The Comments.—Dependent drainage and scrupulous care in the separation of muscular structure without needless bruising of the tissues should always be practiced. It is important and often very difficult to determine the line between the healthy and diseased bone. If the portions removed when washed present a whitish, grayish, or blackish appearance, and are porous and fragile instead of being vascular, red, and tough, the operation should be continued. If the gouged surfaces bleed freely from numerous points and have a normal firmness and color, the operation should cease.

It is important in gouging the extremities of bones to use extreme caution or the joint cavities may be opened directly or become secondarily involved.

After the removal of the elastic constriction all hæmorrhage should be arrested, the wound washed thoroughly with a suitable antiseptic solution, good drainage secured, the soft parts united, and dressed antiseptically.

It frequently happens in these cases that a cavity in the bone of considerable size results from the operation. If the diseased tissue of both the

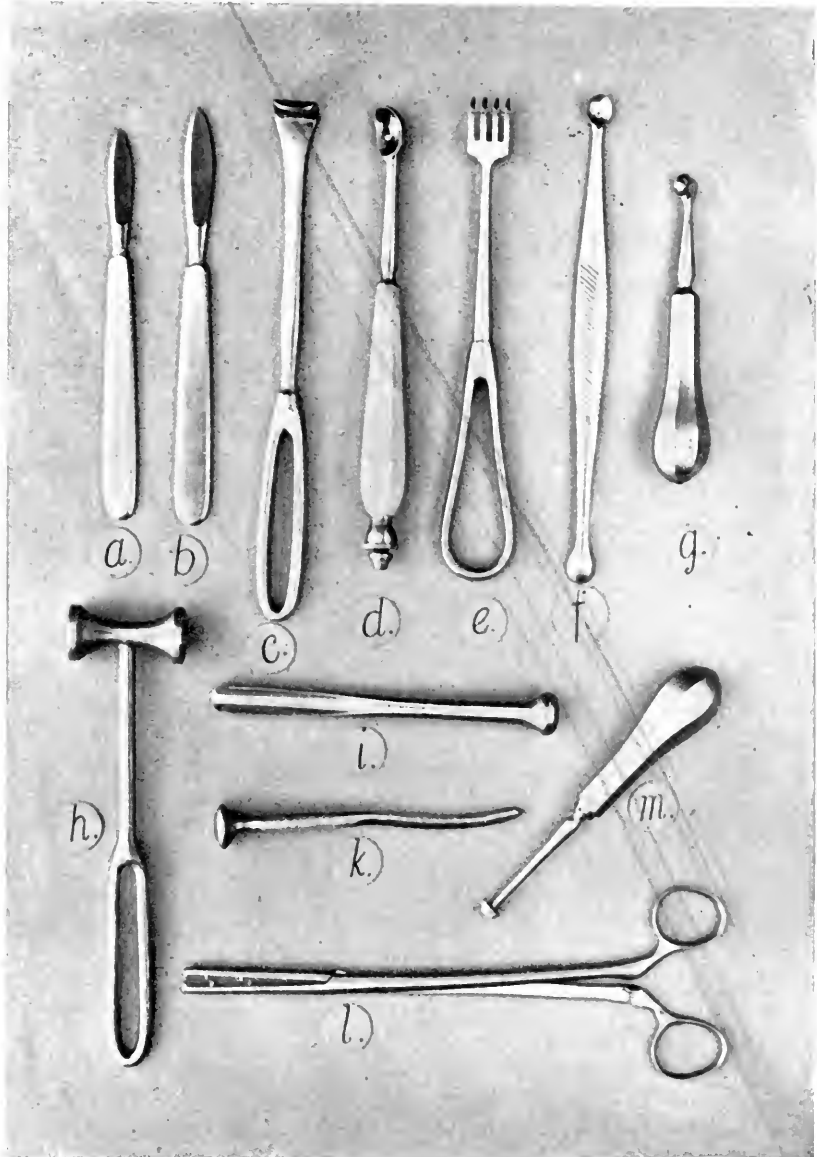


FIG. 370.—Instruments employed in gouging.

a, b. Strong scalpels. *c, e.* Retractors. *d.* Barker's douching scoop. *f, g.* Scoops. *h, i, k.* Mallet and gouges. *l.* Sponge holder. *m.* Bone burr. Forcepressure, sutures, needles, drainage agents, etc., are likewise needed.

hard and soft parts can be removed, and there be no sinus communications with other diseased areas, an attempt should be made to repair the defect promptly by a *method of healing devised by Schede* (Fig. 371). In this pro-

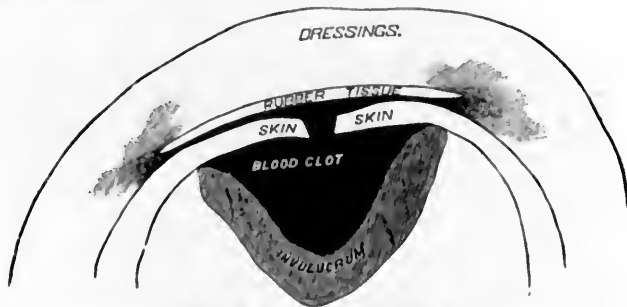


FIG. 371.—Schede's method.
Diagram showing relations of organizing blood clot.

cedure the soft parts are not closed until the oozing of blood from the bone is nearly arrested or only sufficiently active to be arrested by closure of the soft parts, thus leaving the cavity filled but not distended with blood. The wound of the soft parts is then closely united with fine aseptic catgut or silkworm gut, and the surface covered widely with a layer of aseptic rubber tissue, which is bound firmly in place with antiseptic gauze. Additional dressings are applied in the usual manner, confined in place, and the part is kept quiet. If the effort fail, local evidences of deep-seated inflammation will be manifest when the dressings are removed a few days later, and the lips of the wound should then be separated by the surgeon, the cavity cleaned out, and per-

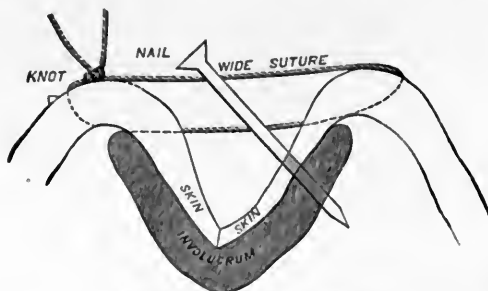


FIG. 372.—Neuber's method.
Top of involucrum removed, skin-flaps turned into the bottom of the bone cavity.

mitted to heal from the bottom. The canalization method of Neuber may be employed instead of Schede's plan of repair (page 107).

Sequestrotomy.—Sequestrotomy is employed for removal of dead bone *en masse*, and is therefore applicable to the treatment of necrosis. *Two methods of procedure are employed*, depending on the nature of the case—viz., the direct and indirect methods (Fig. 374).

The Operation by the Direct Method.—Having determined the situation of the necrosed bone, and being satisfied either from the long course of the

disease, or by movement of the dead portion, that detachment of the dead from the living bone has taken place, apply the elastic bandage if expedient, using care not to force deleterious matters into the circulation, select a strong scalpel, and connect the fistulous openings with each other down to the bone with the aid of a grooved director or a probe, choosing such openings as

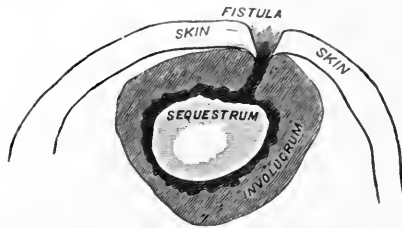


FIG. 373.—Diagram of a transverse section, showing relations of sequestrum, involucrum, fistula, and skin.

will cause the connecting incision to be consistent with good drainage, easy access to the diseased parts, safety to the underlying structures, and a minimum disfigurement. Separate the borders of the incision with retractors so as to fully expose the openings in the involucrum. If the sequestrum can be drawn out of the opening with suitable forceps (Fig. 374, *d*) it should be done carefully, otherwise the reparative tissue upon which it rests will be injured and the process of recovery delayed. If it be too large or interlocked with healthy bone, the opening must be increased sufficiently to admit of its withdrawal; or, if this be impracticable, another incision should be made corresponding to the long axis of the sequestrum. The periosteum should be carefully raised on either side of the incision to permit the application of a crown trephine (*i*) to the involucrum, with which it should be perforated a sufficient number of times to permit of the easy removal of the dead portion either with or without chiseling (*k*) away the irregular bony borders.

The gnawing forceps (*c*), chisels, and saws (*f*, *g*, *i*) may be used in lieu of or in conjunction with the trephine for removal of the sequestrum.

If there be but one sinus opening, and evidences of disease exist above or below it, the center of the incision should correspond to the course of the sinus if the anatomical relations will permit.

The Precautions.—It is necessary in making these incisions in the vicinity of joints to exercise great care to avoid opening contiguous synovial pouches. It therefore follows that the anatomy of the joint under consideration ought to be well understood, not only with the idea of locating the sites of the bursæ associated with it, but also the common and exceptional relations of these bursæ with each other. A bursa communicating with a joint indirectly by means of an intervening bursa may be more dangerous than one with a direct communication; as, in the latter instance, a knowledge of the fact obviates all peril, while in the former, ignorance of the possibility of communication might so relax the vigilance of the operator as to beget disaster. The writer has in mind an instance of this kind. Flexion of the limb at the joint in question usually reduces to a minimum the area of exposure to operative injury the synovial elongations of the joint.

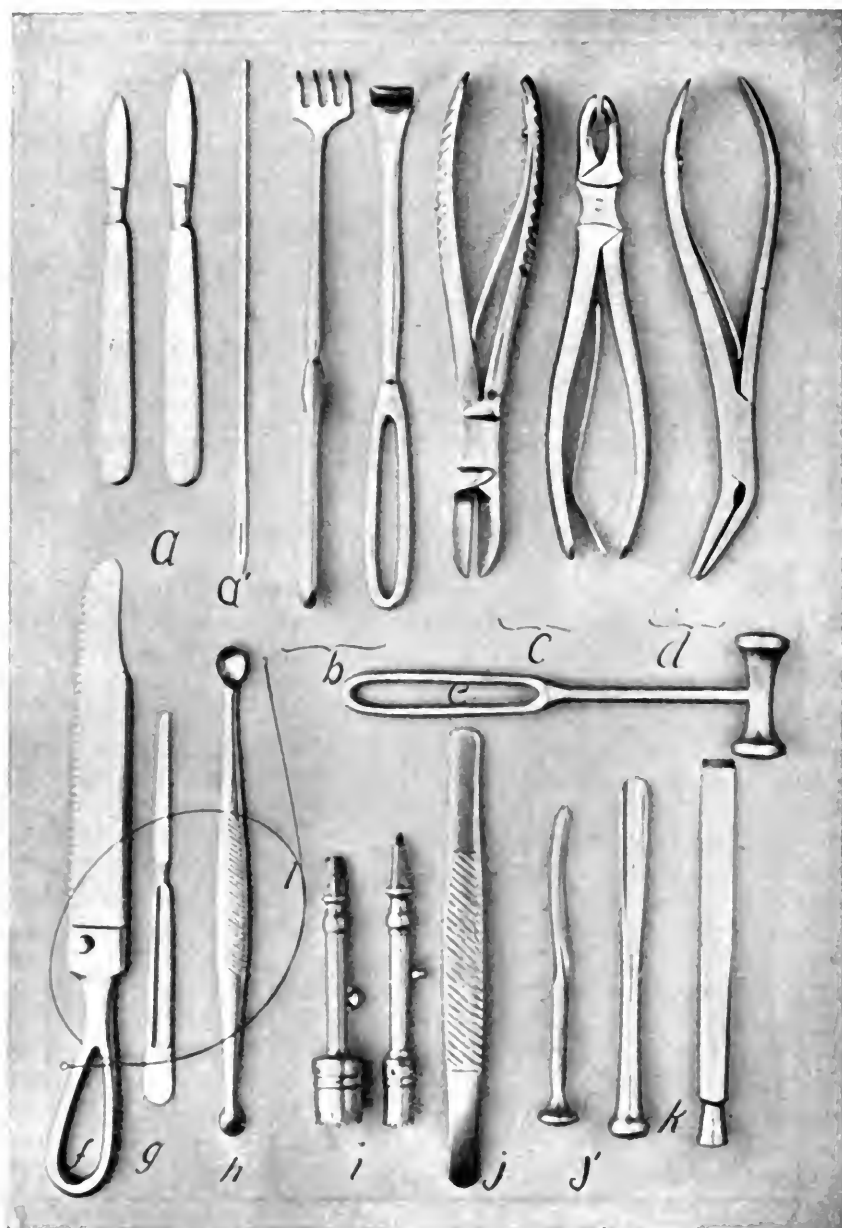


FIG. 374.—Instruments employed in sequestrotomy.

a, a. Strong scalpels and probe. *b.* Retractors. *c.* Bone-cutting forceps and rongeur. *d.* Sequestrum forceps. *e.* Mallet. *f, g, l.* Lifting back, keyhole, and Gigli-Haertel saws. *h.* Scoop. *i.* Large and small crown trephines. *j.* Periosteotome. *J, k.* Gonges and chisels. Grooved director, bone elevator (Fig. 236, *k*), forcipressure, ligatures, sutures, needles, drainage agents, etc., are required.

When the portion of bone removed is large, or the remaining part is small and fragile, the limb must be supported by a splint, otherwise the bone may bend or break and thereby modify unfavorably the ultimate result.

If the sequestrum be not wholly separated from the healthy bone it should be allowed to remain in part until the process of separation is completed, then it can be removed.

After the removal of the dead bone the cavity throughout its whole extent should be thoroughly scraped and cleansed, and suitable drainage provided. The soft parts should then be closed and an antiseptic dressing applied.

Subperiosteal removal of healthy and of injured bone will be noted further along, when requirements demand, for special purposes.

The Indirect Method.—The indirect method is preferable when the bone is superficial and the disease progressive, as in osteitis of the lower jaw, clavicle, bones of the arm, forearm, or tibia; in fact all the long and many of the flat bones can be reproduced by this method. The indirect method consists in making a free incision through the periosteum down upon the diseased bone and separating the former by means of the handle of a scalpel, spatula, or periosteal elevator. The separation must be renewed at intervals and each time not extend beyond the diseased portion of bone. The length of the intervals will depend upon the activity of the morbid process and the rapidity of bone reproduction. This plan is necessarily tedious both in detail and in time, but, sooner or later, the dead bone can be raised from its new osseous trough, which will soon become filled with new bone that rarely fails to serve the purposes of its predecessor. The free incision necessary to expose the dying bone will provide good drainage. The wound is kept clean by ordinary antiseptic means. This is sometimes called subperiosteal.

Excision.—Excision of bone is a conservative measure directed to the extraction of such portions of bone as are inconsistent with future usefulness or the symmetry of the part, together with the removal of the diseased condition calling for operation. Excision is often employed in lieu of the more radical measure—amputation. It is practiced at the articular extremities or the shaft of a bone, and in either instance it may be a *partial* or *complete excision*. The articular extremities or joints are excised on account of injury, disease, or ankylosis in a faulty position.

The General Remarks.—In estimating the prognosis as to life, the surroundings of the patient, the previous habits, present conditions, and the existence of constitutional taint must be considered, also the nature and extent of the cause demanding operative procedure. The prospective usefulness of the limb will depend on the ability of the surgeon to leave the muscular attachments intact, and also upon the condition of the nerves that animate and the blood vessels that nourish the structures. If the patient be a manual laborer, or one oversensitive of deformity, it is well to consider whether additional advantages can be derived from artificial limbs and appliances, and if so it may be deemed wiser to sacrifice the offending member by amputation. The incisions for the necessary exposure of the parts to be removed should be free, and, when possible, made in the long axis of the bone. They are often, however, varied to suit the peculiar demands of the

individual cases. They are likewise varied in the different joints, being in one instance longitudinal, in another U-, H-, or V-shaped, according to the proposed extent of the operation and the importance of the contiguous structures. In every instance, however, they should be made with a view to securing good drainage, provided they will render the parts accessible, and not expose adjacent important structures to unwarranted interference. Future usefulness being one of the most important factors, the insertions of the muscles having especially defined functions, as flexion or extension, must if possible be carefully preserved. If it be necessary to divide tendons they should be incised obliquely, the better to facilitate subsequent union (Fig. 348). Should it be needful to remove the bony surfaces, into which tendons or ligaments are inserted, the periosteum covering these surfaces should first be carefully peeled off, together with the tendinous attachments. All diseased and loose pieces of bone should be removed, together with bony irregularities and isolated portions of articular cartilage. The synovial membrane should be preserved entire unless it be diseased, and if so the diseased portions should be cut or scraped away. The removal of the entire shaft of a bone may be necessary on account of injury or disease, notably the latter. In such cases the incision should be a free one and made over the most superficial aspect of the bone, provided that important structures do not intervene. The periosteum is then elevated proportionately to the extent of the disease, gradually or rapidly, as the circumstances indicate, and the diseased bone removed, in young persons, leaving intact, if possible, the epiphyseal extremities. If the epiphyseal cartilage be destroyed, the growth of the bone in its long axis will be interrupted. It is important to observe this fact in operations upon the bones of adolescents, since to destroy this cartilage will cause a subsequent shortening of the limb. The consultation of any standard work on anatomy will enable the surgeon to accurately locate the epiphyseal junctions, and will likewise inform him of the age at which the shafts and epiphyses become united.

The Time for Operation.—The time for operation must be governed by the condition of the patient and of the part to be operated upon. If the patient be suffering from shock, reaction should have taken place prior to operative interference. If inflammation of the bone and contiguous tissues have occurred, good drainage should be established, and the operation deferred until the acute symptoms subside. If the operation be for necrosis, the diseased bone should have separated before the attempt is made.

The instruments employed in excision are varied in number and shape, and must be selected according to the peculiarities of the case (Fig. 375). The scalpels should be broad and strong. The retractors must likewise be strong, and possess a hooklike curve, otherwise they will slip from the wound. The periosteotomes, elevators, and rugines vary in shape, but should possess a blunt, non-cutting edge. These instruments must be used with care, otherwise the function of the periosteum will be destroyed, and may even be followed by sloughing. The bone-cutting instruments are bone-cutting forceps and saws of various sizes and shapes. The straight bone




FIG. 375.—Instruments employed in excisions of the extremities.

a. Scalpels. *b.* Thumb forceps. *c.*, *e.* Straight and curved bone-cutting forceps. *d.* Rongeur. *f.* Sponge holder. *g.* Periosteotome. *h.* Farabœuf's bone-holding forceps. *i.*, *k.* Strong straight and curved scissors. *l.*, *m.* Rugines. *n.* Strong retractor. *p.* Spatula. *q.* Lifting back, keyhole, and Gigli-Haertel saws. Forepressure, ligatures, etc., are required.

forceps is the most available for general purposes. The gnawing forceps or rongeur is of inestimable value in removing bony projections.

The Bone-holding Forceps.—The bone-holding forceps vary somewhat in their grasping and holding powers, consequently the surgeon is governed

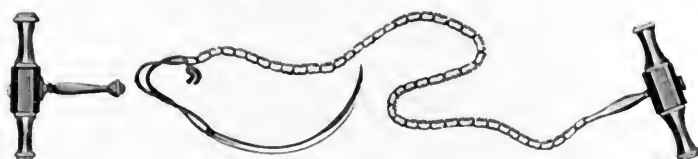


FIG. 376.—Chain saw.

in the selection of this instrument by its suitability for the purpose at hand (Figs. 375, *h*, and 378, *c*). The varieties of saws are numerous, among which are the chain saw and the straight saw with or without an adjustable back (Fig. 375, *q*). *The chain saw*, as the name indicates, is composed of numerous links or sections, having a handle at each extremity on which to draw while sawing (Fig. 376). To apply the saw, remove the handle from the hook and carry the end beneath the bone—the cutting edge being upward—by means of a thread and a curved needle; or the “chain-saw carrier” (Fig. 377) may be employed instead. Readjust the handle, and carry the saw around the bone at an angle of about forty-five degrees and draw the instrument from side to side. The saw should not be jerked or be allowed to kink, but should be kept taut while being used for fear of clamping or breaking. This instrument is employed in dividing bones which are nearly surrounded by the soft parts. *The Gigli-Haertel saw* bids fair to displace the chain saw, in minor work, as it is cheap, easily cleansed, not liable to clamp or bind; the latter being expensive, often of uncertain utility, and difficult to cleanse. Fig. 437 represents a saw of great practical worth. The blade is adjustable, and its cutting surface can be turned in any direction. It has therefore a universal application which renders it superior to the chain saw except in isolated cases. The gouges, chisels, and mallet are required to thoroughly remove all diseased bone. The former of these instruments differ in size and shape in order that the intricacies of the wound may be reached.

The Surgical Engine.—The surgical engine is the outcome of the dental engine, the former being the stronger and provided with suitably constructed knives, burrs, drills, and saws. These addenda are connected to a hand piece which is attached to a flexible wire cable that permits the easy holding and directing of their rapidly revolving surfaces. The rapidity of their action—two to three thousand revolutions per minute—lessens the pain and the injury done to important parts. The engine can be used with advantage in bone surgery. It is expensive, somewhat cumbersome, and therefore better fitted for hospital than for general practice. The various

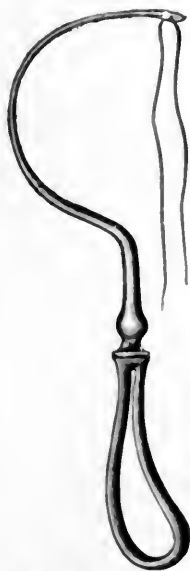

FIG. 377.—Chain-saw carrier.

appliances that characterize the surgical engine can be attached equally well to the electrical motor that propels the excellent saw devised by Powell (Fig. 281).

The treatment of excision wounds in nearly all instances is at the outset substantially the same. Rest and thorough drainage, together with strict antiseptic measures, constitute the basis of treatment. Rest can be secured by the use of various forms of movable or immovable splints. The special treatment of individual instances will be stated in connection with the respective operations.

EXCISION OF THE BONES OF THE FACE.

The great vascularity of the soft parts of the face and the need of avoiding unnecessary disfigurement require ample preparation for the control of hæmorrhage and call for localization of the incisions in the course of existing and prospective facial lines. An abundance of ligatures and forcipressure, together with assistants competent to catch bleeding points and control the escape of blood by digital pressure, should be at command. In some instances temporary or permanent ligation of one or both of the external carotid arteries to control bleeding may properly be considered (Fig. 378).

Excision of the Upper Jaw.—Excision of the upper jaw is performed for various diseases connected either with the bone structure itself or the cavities with which it is associated. In all instances the periosteum should be preserved except in those in which the bone is invaded by malignant disease, and the mucous membrane of the part be well scrubbed before operation.

The Remarks.—The patient is anæsthetized and placed upon the back, either with the head slightly raised or markedly depressed (Rose). In the latter (Fig. 796) blood does not escape into the larynx, but into the upper and posterior part of the pharynx. This position impedes respiration somewhat by undue stretching of the tissues of the anterior cervical region. However, if the foot of the table be raised, the need for depression of the head will be obviated in a degree. If the head be elevated, the blood can with care be kept from the larynx either by constant sponging, or tamponing the pharynx around a large catheter or rubber tube, or permitting the patient to be sufficiently conscious to dislodge it. Still another method is to confine the patient in a rocking chair, tipped forward or backward as circumstances require. In this instance morphin-chloroform narcosis induced by a hypodermic injection of morphine followed by the inhalation of chloroform until excitement is manifested when the chloroform is decreased, can be employed. The patient suffers but little pain, is conscious and spits out or swallows the blood, as directed. However, the danger of cerebral anæmia while in the upright position must be kept in view and its slightest manifestation heeded and the patient placed on the back with the head lowered during the remainder of the operation. The surest of all is to perform a preliminary tracheotomy and then tampon the floor of the pharynx. Preliminary tracheotomy is not, as a rule, necessary unless the operation be complicated with a very vascular morbid growth requiring re-

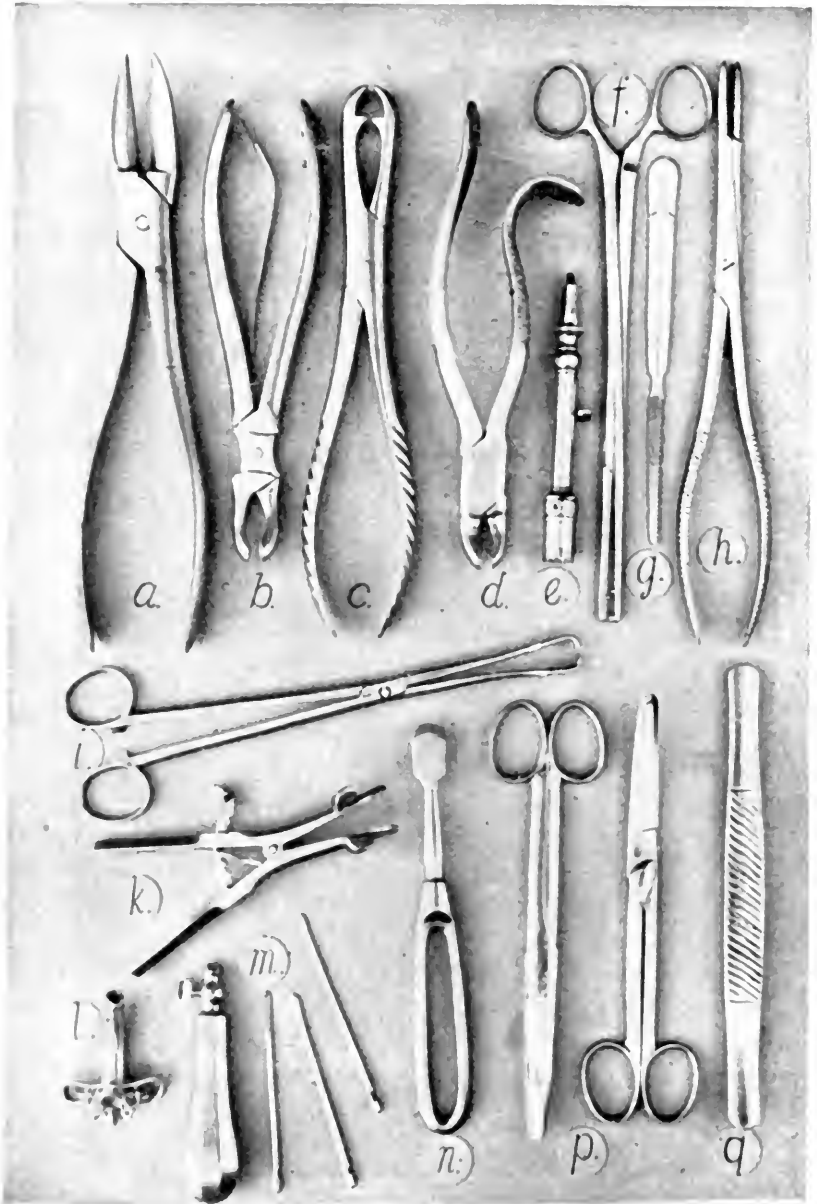


FIG. 378.—Instruments employed in excision of bones of the face.

- a. Liston's curved bone-cutting forceps. b. Rongeur. c. Fergusson's lion-jaw forceps. d. Tooth-pulling forceps. e. Small crown trephine. f. Sponge holder. g. Keyhole saw. h. Sequestrum forceps. i. Volsellum forceps. k. Mouth gag. l. Tracheotomy tube. m. Bone drills. n. Ruginé. p. Curved and straight scissors. q. Periosteotome. Scalpels, mallet and chisels (Fig. 374), harelip pins, silkworm gut, and aseptic cotton yarn for the pins, are required.

removal. However, there seems to be little doubt of the fact that the post-operative dangers are lessened sufficiently by preliminary tracheotomy to warrant its frequent employment. Whether the operation of tracheotomy shall be merged with the profounder one or be practiced a few days in advance of the latter, can not be wisely determined except by careful consideration of the demands in this respect of individual cases. If the important associated anatomy be carefully regarded before beginning the operation, much time and not a little loss of blood will be saved.

Partial and complete excision of the upper jaw are practiced. In the former the seat of the operation, the means of accomplishment, and the method of practice will be suggested by the principles of action that characterize the more extensive operative procedures of excision.

Complete Excision—Anatomical Considerations.—The bony connections to be divided are (Fig. 379): 1. Through the nasal process of the superior maxilla and the lachrymal and ethmoid bones (1, 1'); across the floor of the orbit, then either through the malar process of the superior maxilla (2); or, if the malar bone also is to be removed, through the frontal process of the malar and the zygoma (2', 3'). Finally, division of the palate process of the superior maxilla and horizontal plate of the palate bone (3, 4') is required. The internal maxillary artery in the sphenomaxillary fossa and the branches of the facial artery running through the external soft parts are the only vessels that will cause troublesome hæmorrhage. Stenson's duct must be avoided, as it passes from the parotid gland on a line extending from the lobule of the ear to midway between the border of the lip and the ala of the nose to empty into the mouth opposite the second molar tooth. The superior branches of the facial nerve may be divided unnecessarily if the course of the incision be irregular or the extent or depth be too great. All anticipated complications should be carefully studied and provision made for their prevention and treatment. Loss of blood, however, is the only one, in addition to the shock common to all operations, that demands close attention at the outset. Hæmorrhage from the facial and internal maxillary arteries, while often profuse, can be promptly controlled by pressure.

The Lines of Incision.—The lines of incision may be made within or from without the buccal cavity (Fig. 380). The removal of the bone from within the buccal cavity is tedious, as the space is limited and the opportunity to control hæmorrhage comparatively inadequate. At the present time external incisions only are employed in all except special cases. These incisions can be classed as the outer and the median. The former (Lizar's) is begun at the angle of the mouth and carried in a curved course upward and outward to the malar process (Fig. 380, *a*); if more room be needed the first incision may be extended (*a'*), and also a second may be made through the upper lip to the nostril. This method exposes Stenson's duct and the

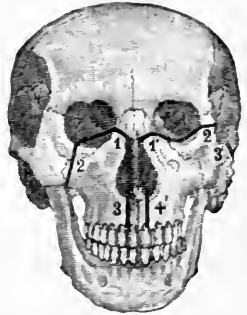

FIG. 379.—Division of the bony connections of the superior maxilla.

branches of the seventh nerve to injury, and is followed by a conspicuous scar.

Liston made an incision from just below the external angular process of the frontal bone to the angle of the mouth (Fig. 380, *c*); if necessary, a second (*c'*) along the zygoma joining the first, and even a third from the nasal spine of the maxilla downward through the lip in the median line (Fig. 382). *Velpeau*, like *Lizar*, made a single curved incision with the convexity downward from the angle of the mouth to the center of the malar bone, and even to the angle of the orbit (Fig. 380, *a, a'*), if necessary. *Langenbeck* made a U-shaped incision through the cheek, with the convexity extending downward to near the line of junction of the upper lip with the cheek, reaching from the point of attachment of the nasal bone with its cartilage to the middle of the malar bone (Fig. 384, *a*). In this operation *Stenson's* duct may be cut and many branches of the facial nerve are divided, besides which a conspicuous scar remains. Another and an admirable incision, *Fergusson's*, begins from a point half an inch below the inner angle of the eye, and following the furrow between the cheek and the nose terminates by passing through the middle of the upper lip (Fig. 380, *b*). To this may be added an incision (*b'*), at a right angle with the vertical one, an inch or so in length, extending outward half an inch below the orbit (*Weber*); it may be extended to the external angle of the orbit and the zygoma if necessary. In this incision the coronary and angular arteries only are divided. *Fergusson* sometimes supplemented the vertical median incision with an outer one similar to *Lizar's* (Fig. 380, *a*).

Gensoul, beginning just below the inner canthus, made a nearly vertical incision down to the bone, through the lip opposite the bicuspid tooth (Fig. 382, *b*); a second incision of similar depth and joining the first at a right angle on a level with the floor of the nose was made outward to the malar bone; a third was carried upward from this point to the external angular process, thus completing a flap of commodious dimensions, but one followed by considerable disfigurement and rarely employed.

The Operation by the Median Incision; Removal of the Whole Bone (Fergusson).—The middle incisor tooth corresponding to the side to be operated upon is drawn, the facial artery compressed on both sides by

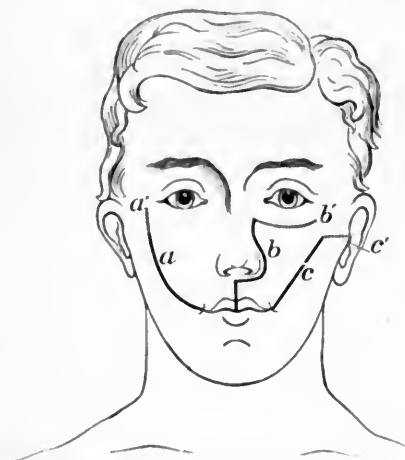

FIG. 380.—Lines of incision in removal of upper jaw. *a, a'*. *Lizar* and *Velpeau*. *b, b'*. *Fergusson-Weber*. *c, c'*. *Liston*.

an assistant, and the posterior nares are plugged. *The primary incision* is begun half an inch below the inner angle of the eye, and carried along the side of the nose around the naso-labial junction to the median line of the lip, thence downward through its free border (Fig. 380, *b*). Firm sponge pres-

sure promptly follows the course of the knife. The hæmorrhage, after the division of the lip, is controlled at either side of the incision with the thumbs and fingers of an assistant or by strong Langenbeck serre-fines (Fig. 103, *b*). The latter are tireless, thoroughly effective, and no hindrance to the operator. The *secondary incisions* along the border of the orbit (*b'*), etc., are made only when necessary. The knife is carried rapidly down to the bone, and the flap dissected outward as far as the malar bone above and the tuberosity of the maxilla below. During the dissection the bleeding points are controlled by the fingers of the assistant or by forcipressure. The vessels should be ligatured with catgut before the bone is removed. The cartilage of the nose is separated from the bone and turned inward; the edge of the orbit is gained, and the periosteum on its floor separated and pushed backward and upward to the border of the spheno-maxillary fissure by means of an elevator or the handle of the scalpel.

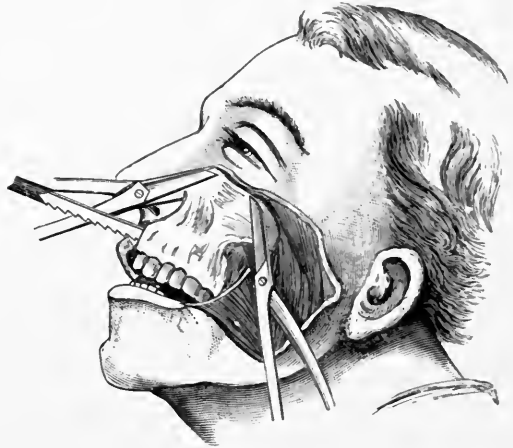


FIG. 381.—Division of processes of superior maxilla.

The malar process is now divided by a saw or with bone forceps from the outer extremity of the spheno-maxillary fissure (Fig. 381). The thin floor of the orbit is divided with a scalpel from the inner extremity of the spheno-maxillary fissure obliquely forward and inward to the nasal process, and the nasal process severed with forceps or strong scissors. The soft palate is separated from the hard transversely inward to the center, on a line with the last molar tooth; an incision is made through the mucous membrane from the center forward in the median line to the incisor teeth, also through the nasal mucous membrane at the side of the septum from behind forward. The hard palate is divided at the side of the septum corresponding to the bone to be removed by a saw or bone forceps (Fig. 381), and the bone is seized and pressed downward to break up its posterior connections, after which it is raised and twisted slightly from side to side and pulled out, bringing with it some portions of the palate bone and pterygoid process of the sphenoid, together with the muscular fibres connected with them. If the mucous membrane of the hard palate be not diseased, it can be saved by making an incision through it along the alveolar border and pushing it inward, together with the periosteum, to the median line. After the removal of the bone the periosteum and membrane can be stitched to the side of the cheek, thus excluding the mouth from the cavity above.

The Operation by the Median Incision; Removal below the Floor of the Orbit.—After the exposure of the external surface of the superior maxilla, as in the preceding method, perforate the anterior wall of the antrum with

a drill or trephine; then, with the bone forceps or saw inserted into the opening, divide the bone inward to the nasal fossa, and outward through the malar bone. Aside from this the steps are similar to those of the preceding operation.

The Operation by the Subperiosteal Method.—The subperiosteal method can be accomplished through either of the median incisions, although an external one is preferred by some surgeons (Fig. 382). The external incision (Ollier) is made from the middle of the malar bone to a point at the upper lip one third of an inch from the angle of the mouth (Fig. 382, *a*). It is sometimes necessary to make a second incision from the middle of the lip upward to the nose. The mucous membrane on the external surface of the alveolar process is divided down to the bone by an incision beginning at the line of junction of the lateral incisor and canine teeth, and carried backward to and around the posterior molar to the inner surface of the alveolar process, thence forward along this surface parallel with the external incision to a point opposite the commencement of the former incision, then obliquely backward and inward to the median line on a line corresponding to the intermaxillary suture of that side. The anterior extremities of the external and internal incisions are now connected by a transverse incision carried between the lateral incisor and canine teeth. The periosteum is then peeled off from the external and orbital surfaces of the bone, and also from the inner surfaces of the alveolar process and the hard palate of that side; the soft palate is carefully separated from the hard.

The nasal and malar processes are divided as before, the canine tooth is drawn, and the intermaxillary bone separated, together with the hard palate of the maxilla, from the contiguous bone borders, by the chisel, saw, or forceps. The maxilla is then twisted out, and the periosteal borders of the outer and inner surfaces of the alveolar process are united. Langenbeck's incision admits of subperiosteal removal, but its limited extent hinders considerably the necessary manipulative measures, and correspondingly exposes the tissues to undue violence. *The incisions*—of Lizar, Velpeau, Langenbeck, Liston, etc.—are better adapted to removal of a limited portion of the maxilla than of the entire bone, because of the comparatively small amount of bone surface exposed by them; and, too, they are objectionable because of greater disfigurement and the danger of injury of the branches of the facial nerve and of Stenson's duct.

Although it is more dangerous and perplexing to remove the entire maxilla through intra-buccal incisions, still any part of it or the entire lower

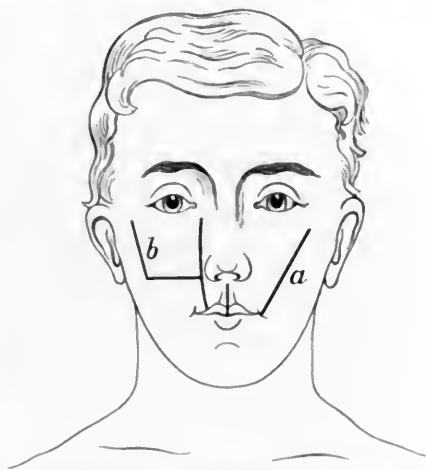


FIG. 382.—Lines of incision in removal of upper jaw. *a*. Ollier. *b*. Gensoul.

half can be thus removed with but little additional trouble to the surgeon and danger to the patient. When cosmetic reasons dominate the policy of action, the latter method should be adopted, even though the entire jaw require removal.

The Removal below the Infra-orbital Foramen—Intra-buccal Method.—Extract the teeth in the line of proposed bone section; pass a short retraction suture through the upper lip; draw the cheek of the affected side backward with a buccal retractor, the fingers of an assistant, or an extemporized retractor; separate the mucous membrane of the cheek from the gum from the site of proposed section of the jaw back to the posterior molar tooth; push the soft parts upward in the line of the incision to the site of proposed section of the bone, being careful to avoid injury of the internal maxillary artery behind and the infra-orbital in front; break into the antrum in front with a small chisel, and with a chisel and mallet cut the outer wall in either direction to the extent of proposed removal; sever the mucous membrane of the inferior meatus from behind forward at the objective side with a long-bladed knife; divide the soft parts at the roof of the mouth in the line of proposed bone section through the hard palate with a scalpel; separate the soft from the hard palate, and then with a long-bladed bone forceps or a bone chisel divide the alveolar process and hard palate, cutting toward the center with a quick, sharp action; grasp the fragment with bone forceps and remove it in the manner previously described. Check hæmorrhage by prompt, firm pressure, and pack the wound as in other methods.

The Comments.—It is very important indeed to preserve the canine tooth in this operation, if possible, because the disfigurement is then not noticed from the front; the tooth also affords attachment and support to the compensatory appliance made by mechanical dentists for the correction of speech and disfigurement. When the bone-cutting forceps is carried crosswise of the hard palate, the bone is liable to fracture at either side of the line of section; when applied antero-posteriorly, however, the division is easily made without fracture. The horizontal portion of the hard palate may escape notice and remain behind unless this contingency be anticipated and the parts examined with the finger after removal of the maxilla.

The Partial removal of the bone is practiced for relief from limited disease of the jaw. The alveolar process can be readily removed with gnawing forceps, or chisel and mallet, through the mouth; the hard palate by a saw or the chisel and mallet.

The Removal below the Infra-orbital Foramen—Extra-buccal Method.—Make a curved incision with the convexity outward from the ala of the nose to the angle of the mouth, lying if possible in the facial crease; dissect up the soft parts and open the nostril; expose the malar process of the superior maxilla; introduce a narrow saw into the nose and saw outward horizontally in a line just below the infra-orbital foramen to the outer surface of the bone and through the malar process; detach the soft from the hard palate; divide the hard palate antero-posteriorly and remove the bones with the lion jaw forceps as before. If the orbital plate alone is to be preserved, employ when practicable the vertical portion of Ferguson's incision, the line of section of

the bone being located just below the orbital plate. In other respects the procedure is substantially similar to removal of the entire jaw. The middle and upper portions of the jaw when diseased can be removed independently through a like incision of the soft and hard parts, supplemented with a horizontal section of the bone from the nose outward, just above the alveolar process, thence upward, when practicable, to the sawed malar surface.

The superior maxilla may be removed simultaneously by either one of two methods (Fig. 383): 1. Make an incision from the angle of the mouth to the middle of the malar bone on each side (Fig. 383, *a, a*), and dissect upward the intervening flaps; or, 2, make a vertical incision (*b*) along the ridge of the nose, beginning above at a point a quarter of an inch below the level of the lower borders of the orbit, and continuing through the lip (Dieffenbach). To this may be added a transverse incision passing through the upper end of the vertical one and extending on either side to a point a quarter of an inch below the middle of the orbit (*e, e*); the outer bony attachments are divided, as in the single operation; the nasal processes are divided either by forceps or the saw, and both bones are removed at once, not separately. In all operations for the complete removal, the superior maxillary nerve should be divided as far back as possible. The bones may be removed consecutively in the same manner as for the removal of a single superior maxilla.

After operation the wounds are washed in each instance with antiseptic fluid, all bleeding points checked either by ligature, pressure, or cautery, and the cavity is packed with antiseptic gauze. The external incisions are closed with

sutures and readily unite in three or four days. These cases make a satisfactory recovery from the operation, although some deformity will remain.

The stitches are removed from the soft parts on the third or fourth day; union, as a rule, then being complete.

The After-treatment.—The degree of success of these operations will depend on the cleanliness of the part and the nourishment and vigor of the patient. The wound is packed lightly with gauze, frequently cleaned with antiseptic fluid, and the patient's head so placed as to prevent discharges collecting in the wound or entering the mouth and throat.

The patient should be nourished freely with milk, eggs, etc., from the outset. If the taking of food by the mouth be inexpedient, rectal alimentation and the employment of the stomach tube are enjoined. If food be taken in the usual manner, rinsing of the mouth and repacking of the

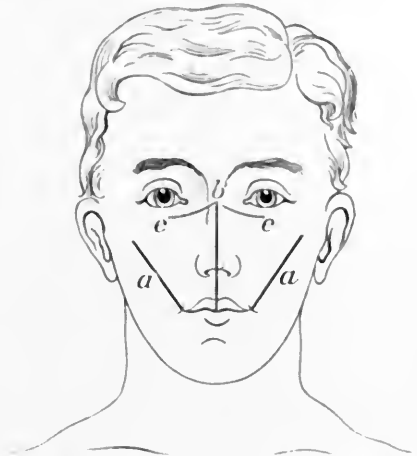


FIG. 383.—Lines of incision in simultaneous removal of the superior maxilla. *a, a*. Lateral incision. *b, e*. Median transverse incision.

wound should follow promptly to prevent decomposition. The strength of the patient ought not to be depleted by long or close confinement in bed. A prompt getting up is an important factor of success. Fresh air is needed, not only for the usual reasons, but also for the special purpose of purification of the upper respiratory passages.

The Results.—The results of these operations are good so far as immediate loss of life is concerned, as death rarely happens from the operation alone. If the removal be done for malignant growths the prognosis for ultimate recovery is unfavorable. In substantially complete removal primary hæmorrhage caused death in four per cent; erysipelas, septicæmia, and other complications in about twenty-five per cent of two hundred and thirty cases, as analyzed by the author. The influence on speech arising from the defect in the hard palate can be completely remedied by the application of a rubber plate to the entire roof of the mouth by an expert mechanical dentist. The plate should be placed *on the surface* and *not* in the opening, for if it be permitted to thus encroach on the latter the continuous and active tendency of the opening to closure by growth from the hard borders will be arrested by the appliance, to the great discomfort of the patient. If unhindered, the opening will be reduced in a few years to at least one third or one fourth the original size by Nature's efforts alone. In order that the artificial appliance may be held in proper place the canine tooth and the intermaxillary bone of the affected side should be preserved if possible. If the operation is done for the removal of malignant disease of the jaw no chafing of the roof of the mouth or side of the cheek by the plate should be allowed. Therefore, in these cases artificial teeth should be omitted, in order to avoid the pressure and friction of the plate incident to their use.

About thirty per cent die when both bones are removed simultaneously.

Excision of the Lower Jaw.—Excision of the lower jaw requires no additional instruments; however, the precautions referable to the patient are of almost equal importance with those relating to excision of the upper jaw, and the contiguous anatomy is here even more important.

The Anatomical Considerations.—The facial artery runs beneath and across the lower border of the bone on the outer surface, and at the anterior border of the masseter muscle; the parotid gland lies behind the ramus, and often overrides it. The external carotid artery, as it passes through the gland, is closely associated with the posterior border of the bone. The internal maxillary artery runs closely behind and to the inner side of the neck of the condyle. The inferior dental artery passes along the inner surface of the ramus to enter the inferior dental canal. The superior division of the facial nerve crosses the outer border of the neck of the condyle. Stenson's duct extends across the masseter muscle on a line parallel with and about an inch below the lower border of the zygoma, opening into the mouth opposite the second molar tooth of the upper jaw. The lingual nerve lies near the inner surface of the ramus, close to the bone, just below the last molar tooth.

The genio-hyo-glossus muscles are attached to the superior genial tuber-

cles, and, if incautiously detached, will permit the tongue to fall backward and close the glottis. It is important, when possible, to preserve the attachments of the muscles of mastication on account of their action on the lower jaw.

Partial and complete removal is practiced; a partial removal may include any fractional portion of the bone.

The Remarks.—The incisions for removal of the lower jaw may be made *within the mouth* or *on the external surface*. If the whole or a lateral half is to be removed, an external incision must be made. The portion in front of the molar teeth, and even that in front of the ramus, can be excised through an internal incision alone; the latter method is, however, often attended by vexatious difficulties, and is hardly warrantable except in selected cases. The ramus and portions of the body of the bone behind the teeth can be removed through an external incision without opening into the buccal cavity, provided the periosteum be carefully raised. In the same manner the body, or any portion of it, may be taken away if the corresponding teeth be absent. If the teeth be present the periosteum should be carefully detached and the bone with the teeth removed, after which the opening in the buccal membrane, caused by the withdrawal of the teeth, can be closed by sutures. If the jaw be the seat of phosphoric or other necrosis, it may be gradually enucleated from its surrounding involucrum through an external opening by the indirect method (page 361), and the teeth may even remain in the new growth of bone. Unfortunately, however, when processes of a malignant nature call for the operation, these conservative methods are of no avail, since the operation must be directed to the removal of all the diseased tissues. When possible the incision in the buccal lining should be closed and the wound drained externally. This course will keep the mouth clean and prevent swallowing the discharges.

The Operation of Excision of the Central Portion of the Lower Jaw.—Pass a stout ligature through the tongue well behind its tip to prevent tearing out, and tie the ends to form a loop which will be convenient for keeping the tongue from falling backward. The assistant stands behind the head of the patient, holds the loop firmly, and at the same time compresses the facial arteries where they pass across the jaw, or seizes the lower lip at the angles, between the thumbs and fingers, rendering it tense, and at the same time arresting the circulation. The operator, standing in front, makes a vertical incision through the median line down to the bone, to the lower border of the symphysis menti, raises the periosteum, if practicable, to the extent of the proposed section, draws a tooth at each point where the bone is to be divided, saws the bone at these points, and, drawing the fragment forward, separates the attachments of the muscles as closely as possible to their insertion and removes the part. The flaps are united with silver wire or silkworm gut extending through the mucous membrane. The vermilion border of the lip is carefully adjusted and united with hare-lip pins or silkworm-gut sutures. If the tongue falls backward its severed muscular attachments can be drawn forward and connected with the incision in the median line by a deep suture passed through the lip. *The anterior portion* of the

bone can be easily reached through a curved incision made along its lower border, or by an internal one corresponding to the fold of the buccal mucous membrane. The lip is depressed over the symphysis menti, and the bone is divided and removed as before. In complete removal of a portion of the body of the bone, the bone need not be sawed through entirely at either place, but nearly so at both, and finally fractured at these points with bone-cutting forceps. The excision of the central or any part of the bone requires that the divided ends be subsequently kept properly separated, or their approximation will destroy the contact of the biting surface with that of the upper jaw during mastication. A perfect approximation of the biting surfaces is, however, almost impossible, and the operation should not be attempted with the expectation of securing complete functional restoration. If the condition of the tissues will permit, the separating agent can be properly fixed to the divided ends at the time of operation, and may serve for a time to keep the fragments apart. The interdental splint prepared before operation and applied to the remaining teeth afterward offers the best solution of the problem known to the writer. Even by this means the tendency to internal displacement of the posterior fragment is rarely entirely controlled.

The Operation of Excision of a Lateral Portion of the Lower Jaw.—Make an external incision along the under border of the portion to be removed down to the bone (Fig. 384). If necessary, the incision may be turned upward anteriorly at a right angle toward but not through the lip. If the condition of the parts will permit, the periosteum is reflected off, the bone divided in front, external to the insertion of the genio-hyo-glossus muscle, and if possible turned outward, and the tissues separated back to the point of posterior section; the bone is then divided at this latter situation with a saw, the fragment removed, and the wound dressed as before.

The Operation of Excision of a Lateral Half of the Lower Jaw.—Commence the incision about an inch and a half below the zygoma, and carry it downward along the posterior border of the ramus and beneath the body of the jaw to the

symphysis menti, carefully exposing the facial artery and tying it. If the operation be for necrosis this incision will be sufficient; if for other disease, the lower lip is cut perpendicularly through its center to meet the longitudinal incision (Fig. 384, *b*). The bone is exposed in front by peeling off the periosteum and sawed through just to the outer side of the insertion of the genio-hyo-glossus muscle (Fig. 385, *G*) if possible, the end of the portion to be removed is pulled outward, and the remaining attached tissues

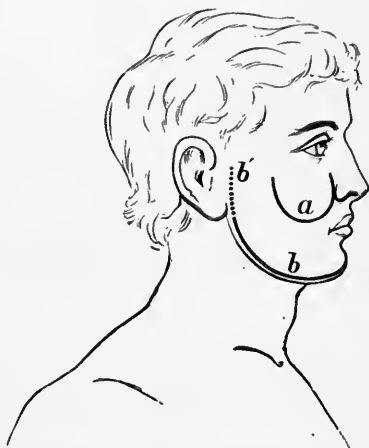

FIG. 384.—Lines of incision in the removal of upper and lower jaws. *a*. Langenbeck. *b*, *b'*. Removal of lower jaw.

separated either by cutting or by a periosteotome, back to the beginning of the incision. Depress the fragment forcibly, and if possible detach the temporal muscle with scissors or the periosteotome, otherwise divide the coronoid process with a fine saw; turn the bone outward and sever the insertions of the pterygoid muscles, being careful to avoid cutting the lingual nerve; draw the bone forward forcibly and twist it from its socket (Fig. 386).

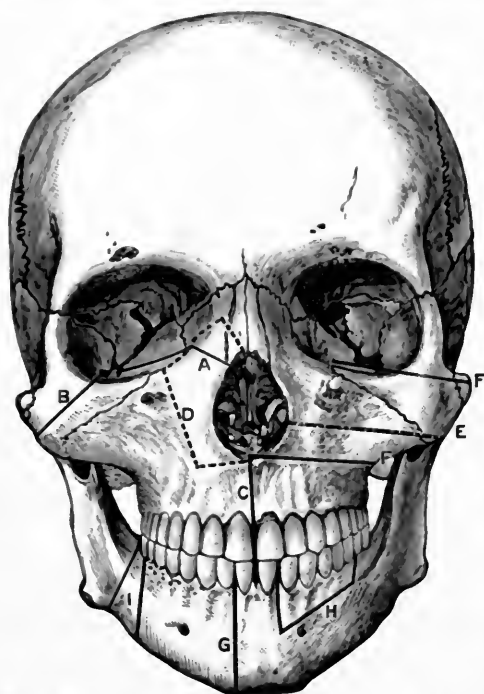

FIG. 385.—Lines of incisions in maxillæ. *A, B, C.* Excision of the upper jaw. *D.* Boeckels's incision. *E, C.* Guérin's incision. *F, F.* Langenbeck's incision. *G.* Incision in removal of lower jaw. *H.* Incision for removal of portion of alveolus. *I.* Esmarch's incision in ankylosis.

If the primary incision be sufficient to expose the bone above the seat of the disease, the diseased portion is removed and the upper part allowed to remain. If, however, it be important to accomplish the complete removal, extend the incision upward to the neck of the bone (Fig. 384, *b'*), avoiding, if possible, Stenson's duct and the cervico-facial branch of the facial nerve, and enucleate the condyle. At this situation the condyle must be hugged closely, otherwise the internal maxillary artery may be injured, as it passes immediately behind it.

The Operation of Excision of the Entire Lower Jaw.—Remove first the half of the jaw that best suits the convenience of the operator in the manner before described. A ligature is then passed through the tongue, given to an assistant, and the remaining half of the bone excised in a similar manner. Arrest all hæmorrhage, and close the wounds with sutures in such a way as to accurately coapt the divided buccal borders.

The Operation of Excision of a Portion of the Alveolar Process.—When the extent of the disease will permit, the alveolar process can be removed down to the body of the jaw through either an external or internal incision, the former being the better, by rongeur, chisel and mallet, or saw (Fig. 385, *H*). The diseased part is then removed and the wound closed as before.

The Comments.—In all situations, when the nature of the disease will permit, the periosteum should be reflected by a careful yet vigorous use of the elevator. The insertions of ligaments and tendons will offer the only obstacle, and these should be carefully detached by a sharp knife or rugine so that a continuity of the periosteal and fibrous tissues will remain.

The periosteum in young subjects may reproduce enough bony material to give a fair outline to the face and serve an important function in mastication.

If bone be not reproduced, the periosteum will furnish a firm, fibrous base, which may be utilized for artificial appliances. If the anterior portion of either or both sides be removed, the gap may be filled in by an artificial dental appliance, which will often happily maintain the symmetry of the face and become useful in mastication.

When prudent to do so, as much as possible of the body of the lower jaw should be preserved, since it will form an excellent foundation for a compensatory dental appliance. Whenever the disease is malignant the periosteum should be removed with the bone and care be taken that none of the diseased membrane remains in the wound. It is also necessary in such cases to remove all associated structures when diseased, such as glands, floor of the mouth, and even a part or the whole of the tongue itself.

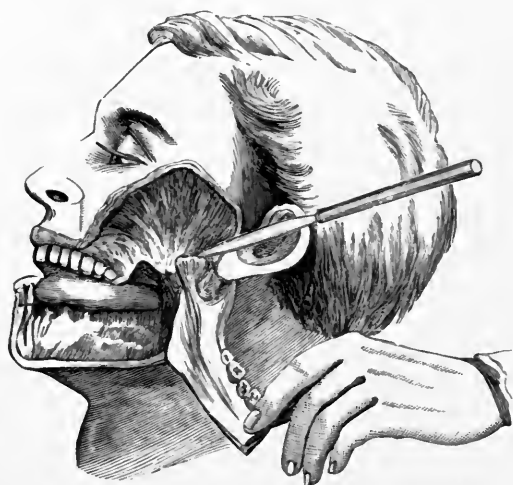

FIG. 386.—Severing connections of inferior maxilla.

death has followed in twenty per cent of all the cases. Pyæmia, erysipelas, and exhaustion were the principal causes.

Immobility of the Inferior Maxilla.—Immobility of this bone is overcome wholly or in part by the establishment of a false joint in front of the seat of the cause. The loss of function is usually dependent on cicatricial contraction, irreducible dislocation, or ankylosis. The removal of a wedge-shaped piece from the lower border of the jaw or from the alveolar process has been practiced, or transverse section of the ramus with a sharp chisel introduced through the mouth, or even fracture of the neck when the condyle is involved, with and without its removal of the latter, has relieved the condition.

The Operation by Removal of a Wedge-shaped Piece (Esmarch).—Make an incision two inches in length down to the bone, along the lower border of the jaw, beginning at or in front of the angle, depending upon the location

The after-treatment in operations on the lower jaw differs in no essential respect from that of the upper. Cleanliness of the parts, liberal alimentation, and the avoidance of swallowing the discharges, appeal to the common sense of all.

The Results.—Out of two hundred and forty-six excisions in the continuity forty-six died; of one hundred and fifty-three disarticulations of half the bone thirty-six died; in twenty operations for removal of the entire jaw one died. It will be seen that

of the cause of the immobility. Avoid or tie all important vessels in the course of the incision, expose both surfaces of the bone up to the summit of the alveolar process, and pull a tooth at that situation if necessary. Divide the bone with a saw at one extremity of the exposed surface, force the other extremity through the wound, and remove a wedge-shaped portion (Fig. 385, *I*) with the rongeur or saw, the base of which should not exceed a third or half an inch. While the patient is still under the influence of the anæsthetic and before the wound is closed, ascertain the distance that the liberated portion can be separated from the upper jaw with moderate force. Provide suitable drainage, close the wound, and prevent union of the bones by passive motion.

Rizzoli, of Bologna, recommends a simple section of the bone instead of the removal of a wedge-shaped piece. However, the results of this method do not warrant its substitution for the former. If the cause of the immobility be due to ankylosis of the temporo-maxillary articulation, the condyle should be removed, or the ramus be so divided as not to seriously impair the functions of the masseter muscle—that is, divided beneath that muscle.

The division of the neck of the bone by a straight chisel introduced through the mouth (*Grube*) has been practiced. After either operation it may be necessary to divide the masseter muscle before the full benefit can be experienced from the division or the removal of the bone. If it be determined to remove the condyle, an incision an inch and a quarter in length is made from the tragus along the lower border of the zygoma, the soft tissues, including the branches of the facial nerve, are drawn downward and the joint exposed, then by means of a chisel, saw, or forceps the neck of the bone is divided at the proper place, the fragment turned outward by forceps, its attachments divided, and the fragment removed. Passive motion should follow the same as before.

The Excision of the Condyle.—Excision of the condyle of one or both sides is practiced for cure of immobility of the temporo-maxillary articulation.

The Operation.—Make a vertical incision through the skin and fascia, about three fourths of an inch in length from the lower border of the zygoma, along the neck of the bone in front of the temporal artery; connect the upper end of the incision with a horizontal one of similar depth, an inch and a half in length, passing forward along the lower border of the zygoma, and turn the flap thus formed downward and forward; expose the neck of the bone and capsule of the joint, and during the time carefully guard from injury the transverse facial artery, the duct of Stenson, and the facial nerve as they pass forward below and parallel with the zygoma, in the order above stated; retract downward and backward respectively the borders of the wound; open vertically the capsule of the joint, expose the condyle, and saw it transversely close to the head with a Gigli-Haertel saw, saving, if practicable, the lower fibers of the external pterygoid; turn out the condyle, seize it with forceps, sever the remaining connections, remove the fragment preserving the capsule and the intra-articular fibro-cartilage;

open the jaw and estimate the effects of the above measures on its mobility. If ample, then introduce the sawed end into the joint, close the capsule with buried sutures, establish drainage, close the wound of the soft parts with subcuticular sutures and apply the dressing with the jaw closed.

The Remarks.—The operation may be practiced successfully through the horizontal arm of the incision only, thus avoiding the dangers incurred to the structures below in making the vertical one. Thorough asepsis is essential to final success. The detached fibers of the pterygoid may be stitched to the periosteum of the neck of the bone. Free opening of the jaw with a gag, if needed, should be done with the patient still under anæsthesia. An anæsthetic may be needed thereafter in passive motion, because of the pain and rigidity incident to it. In severe cases, removal of the coronoid process may be practiced to secure wider range of motion. Sometimes temporary facial paralysis follows a too free or careless handling of the soft parts associated with the facial nerve.

Excision of the Sternum.—No definite plan for this operation can be outlined. The form and length of the incisions must be governed by the location and extent of the disease. The diseased bone should be freely exposed and removed in the usual manner. Care must be observed and the bone closely followed, else the pleural cavity will be opened. When possible, subperiosteal excision should be done, as the bone is quite readily reproduced. The entire sternum is reported to have been removed by König on account of a sarcomatous tumor involving its structure, and although the pericardium and pleural cavity were opened the patient ultimately recovered.

The Results.—Partial excision results most favorably; only one in eighteen has died. Under asepsis these results are improved.

Excision of the Clavicle.—The clavicle is excised, entirely or in part, on account of various morbid conditions and extensive injuries of the bone. The anatomical relations are somewhat intricate and perplexing, especially when the normal relations are changed by extensive diseased action and traumatism. The muscular and ligamentous attachments of this bone must be carefully studied, for it is with a knowledge of them that the surgeon is enabled to remove the bone readily and safely from its more important relations. A careful scrutiny of the "contiguous anatomy" on the following page emphasizes in no uncertain way the need, not only of well-tested anatomical knowledge on the part of the operator, but also of definite ideas regarding the influence of various forms of disease on the structures associated with the clavicle as well as on the bone itself. Morbid processes and injuries involving the outer end of the clavicle invest operation there with but little difficulty or danger as compared with similar conditions when located at the inner extremity. Many structures at the inner and middle parts of the bones are of such vital importance as to beget of themselves special dangers. However, it should not be assumed that all growths of the clavicle of imposing mien are necessarily of specially dangerous import, since the direction of the growth may be of greater operative significance than the size. In any event, the surgeon should be prepared for the difficult rather than for the easy problems of a case. With the patient in the

proper position for operation, the important relations are well expressed by the following scheme:

The Contiguous Anatomy.

In front.

Attachments of

- The pectoralis major muscle.
- The sterno-mastoid muscle.
- The trapezius and deltoid muscles.

Above.

- The external jugular vein.
- The branches of the thyroid axis.

Below.

- The cephalic vein.

Clavicle.

- The subclavian artery.
- The brachial plexus.

Behind.

- The internal mammary artery.....
 - The subclavian vein.....
 - The external jugular vein.
 - The innominate vein at the right.
 - The thoracic duct at the left.
 - The pleura.
- } sternal half.

The Operation of Excision of the Entire Clavicle.—Anæsthetize and place the patient in a position for ligature of the subclavian artery. If the operation is for necrosis, make an incision the whole length of the bone parallel with its long axis. If necessary, short transverse incisions are added. Expose the clavicle, divide the periosteum, and with the elevator enucleate the diseased bone from the surrounding tissues. The clavicle can be divided through the center and each half removed separately, or the acromial end can be detached and the entire bone raised from without inward. In either instance the articular ends and their connecting ligaments should be preserved if possible.

If the involucrum be weak and liable to bend or break after the bone is removed, the shoulder must be held outward, backward, and upward by means of the method employed in treatment of fracture of that bone. The indirect method of sequestrotomy (page 361) can be performed in some instances.

If the operation is for the removal of a tumor of this bone, especially of one acutely malignant and involving any considerable portion of its surrounding tissues, it is certain to be an exceedingly tedious and bloody procedure.

The smaller the size of the tumor and the less its vascularity the easier will be the removal.

The Operation for Malignant Growth of the Clavicle.—Make an incision in the long axis of the bone from its sternal to its acromial extremity. If necessary, this is crossed by a vertical incision extending from the posterior border of the sterno-mastoid muscle to the upper third of the pectoralis major muscle. Make these incisions as deep as the nature of the growth will permit, and dissect the flaps from the tumor; separate the attachments

of the deltoid and the trapezius muscles on a director, cutting them either with a knife or strong curved scissors, being careful to avoid the cephalic vein which lies at the anterior border of the deltoid muscle. Divide the coraco-acromio-clavicular ligaments, raise the acromial extremity of the clavicle, and thus elevate the morbid growth, which should then be cautiously separated from the surrounding tissues. The nearer the approach to the sternal extremity of the clavicle the greater will be the necessity for caution, since the growth may be connected with the important structures located in this situation. Finally, divide the insertions of the sterno-mastoid and the pectoralis major muscles and the rhomboid ligament, and carefully disarticulate the sternal extremity while the tumor is lifted upward and inward together with the clavicle.

Either extremity, or a part, of the clavicle may be excised by making a crucial incision down to the bone, at a site corresponding to the portion to be removed, exposing and dividing it with a saw, and removing the fragment with the same precautions as before described.

The Precautions.—At the middle third the large vessels lying beneath the bone should be considerably treated to prevent hæmorrhage and the admission of air to the veins. The subclavius muscle at this situation is a valuable guide, as it lies between the vessels and the bone.

The results of the operation of complete excision have been quite favorable. Of seventy-three cases six died from the operation. Exhaustion, due to loss of blood, erysipelas, etc., may cause death. *Norkur*, and later *McBurney*, have each had a case with perfect function of the arm after complete excision.

Partial excisions give a death rate of about eight per cent from all causes.

Excision of the Scapula.—The scapula is excised on account of gunshot injuries, necrosis, and morbid growths.

The whole bone may be removed, or the body, angles, or spine may be removed separately. The contiguous anatomy is extensive, but not of the dangerous character of that associated with the clavicle. To its spine, borders, and surfaces numerous and powerful muscles are attached.

At the upper border are found the suprascapular vessels and nerves. The posterior scapular artery passes down its vertebral border, while at the axillary border the subscapular and dorsalis scapulæ arteries, the axillary artery itself and the brachial plexus are in close association with the bone.

The Operation of Excision of the Entire Scapula (Fig. 387).—Place the patient on the sound side close to the edge of the table. Make an incision from the tip of the acromion process along the spine to the posterior border

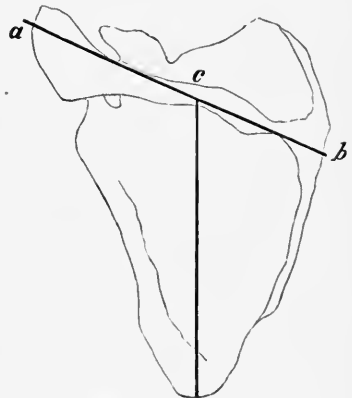


FIG. 387.—Excision of entire scapula.

of the scapula, *a, b*. Join it by a second incision extending from near the middle of the spine, *c*, to the inferior angle of the bone. If necessary, a third may be made from the base of the spine to the posterior superior angle. Dissect up and turn aside the flaps thus indicated.

Divide the attachments of the deltoid and trapezius; disarticulate the acromio-clavicular articulation; secure the subscapular artery; divide the ligaments and tendons around the glenoid cavity; raise the coracoid process and carefully sever its ligaments and muscular attachments; raise the scapula by the inferior angle and divide its remaining muscular attachments with a knife or strong scissors, carefully avoiding the subscapular and posterior scapular vessels; remove the bone and tie all the bleeding points; wash with an aseptic solution; thoroughly drain and close the wound and dress antiseptically. *Sir W. Ferguson* and *Mr. Pollock* thought it better to raise the vertebral border of the scapula first that the subscapular artery might be better controlled. *Spence* advised that the anterior angle should be raised first, the better to control the sub-

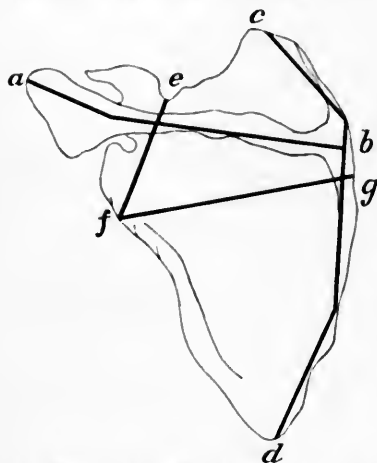


FIG. 388.—Excision of scapula. *f, g*. Subspino-glenoid excision. *e, c, f*. Retro-coraco-glenoid excision.

clavian artery. *MacCormac* advises that the clavicle be divided with a fine saw just internal to the conoid ligament, "for then time is not lost in detaching the outer extremity of the clavicle from its connection with the scapula." All danger of hæmorrhage during the operation is easily obviated by pressure on the subclavian artery above the clavicle by means of a short crutch or a large key (Vogel), also by direct pressure on the subclavian after the anterior angle of the scapula is elevated.

The Operation of Excision of the Body of the Scapula (Fig. 388).—Make an incision the whole length of the spine, *a, b*; begin a second incision at the posterior superior angle and carry it along the posterior border of the bone to the inferior angle, *c, d*; dissect the resulting triangular flaps from their corresponding fossæ, carefully avoiding the suprascapular artery and nerve; saw through the acromion process close to the body; divide the muscles attached to the anterior and superior borders of the scapula; raise the bone upward and saw through the angle just behind the coracoid process; turn the bone outward and sever its posterior connections with a knife or strong scissors.

The acromion process and angles of the scapula may be removed separately. To remove the former make an incision, which is curved if necessary, along its upper border, expose the process, divide its muscular attachments, and with a bone forceps sever and remove the desired amount of bone. This process can also be removed by making a curved or crucial incision over it, exposing its upper surface, dividing the muscular attachments, dis-

articulating the clavicle, and removing the requisite amount of its structure with a chain saw.

To remove an angle make a V-shaped incision over it, dissect off the flaps, separate the muscles from the bone, and sever the exposed portion with the bone forceps. Chalot favors removal of larger portions (Fig. 388, *e, f, g*).

The Operation of *Subperiosteal Excision of the Scapula* (Ollier, Fig. 389).—Make an incision from the outer extremity of the acromion process along the spine of the scapula to its posterior border, *a, b*. Make a second incision from the posterior superior angle of the scapula along its posterior border, crossing the former incision to the inferior angle, *c, b, d*. Sever the muscular attachments to the acromion process and spine; divide the periosteum at the posterior border of the scapula between the attachments of the rhomboideus major and infraspinatus muscles and separate it from the infraspinous fossa; remove the muscular attachments of the superior border of the scapula. The periosteum is then raised from the suprascapular fossa, being careful not to injure the suprascapular vessels, as they pass in close contact with the suprascapular notch; cut the remaining muscles attached to the borders of the scapula, closely hugging the bone; raise the bone upward by its inferior angle, denude the subscapular fossa, leaving the periosteum connected with the subscapularis muscle; liberate the posterior border, allowing the cartilaginous portion to remain when present. Turn the bone upward and forward, remove the remaining periosteum from its under surface up to the neck of the scapula, and divide the bone at the neck with the chain saw. If the extent of the disease will not permit the sawing at this situation, the neck can be enucleated, leaving the ligaments connected with the periosteum.

Excision of the Glenoid Angle of the Scapula.—This operation is only applicable to those conditions of injury or disease that are limited to the articular surface of the glenoid angle of the scapula. If a penetrating wound be present its course should be followed to reach the bone; if not, then a curved incision is made around the posterior border of the acromion process, dividing the fibers of the deltoid and exposing the posterior and upper surface of the joint (Fig. 390, *a*). Commencing at the center of this one, a second incision is then made, from the upper margin of the glenoid cavity, and passing downward through the deltoid in the direction of its fibers, also through the capsule upon the center of the greater tuberosity, going between the tendons of the supra- and infraspinatus muscles. Open the wound widely by means of retractors and divide the tendons of the heads of the biceps and triceps above and below the cavity at their respective origins; separate the periosteum from around the neck of the scapula, if possible, leaving the attachments

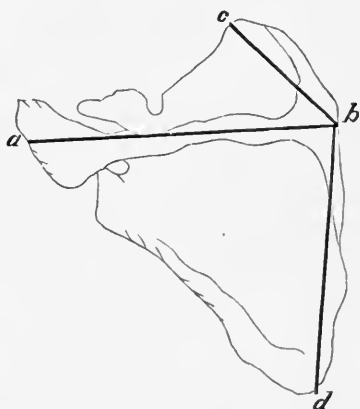


FIG. 389.—Subperiosteal excision of scapula.

of the capsular ligament. Cut through the exposed bone with a saw, and remove the fragment carefully to avoid injury to the periosteum.

The Remarks.—Excision of a considerable amount of the bone is quite as fatal as the complete excision, owing to the greater difficulty of catching the bleeding points in the former, which promptly retract between the bone and adjacent muscles, and also to the comparatively greater injury inflicted by reason of the limited field of action. The glenoid cavity and the points of insertion of important muscles, as the acromion and the coracoid processes, should be preserved when practicable, for manifest reasons.

If the head of the bone be placed beneath the end of the clavicle, and the capsule connected with the upper end of the humerus be sewed to the under surface of the deltoid muscle, much gain in the use is thus accomplished.

The After-treatment.—Complete drainage must be maintained with the patient in the recumbent posture, and with the arm and shoulder supported in a comfortable position. After healing is completed the extremity should be supported by a sling until the tone of the parts is sufficiently restored to meet this indication unaided.

The results of these operations are good. Of sixty-six cases of complete excision fourteen died. The rate of mortality is greater when removed for traumatic causes than for disease. Astonishingly good use of the limb frequently follows,

FIG. 390.—Incisions in excisions of angle of scapula and head of humerus.

especially in the performance of those requirements not connected with the function of the deltoid muscle.

EXCISIONS OF THE UPPER EXTREMITY.

Excision of the Humerus.—The humerus can be removed entirely or in part, as circumstances demand. This operation is done for the relief of old dislocations, caries, necrosis, gunshot injuries, arthritis, malignant disease, etc.

The Anatomical Points.—In excisions of this bone the insertions of the muscles acting upon the upper end, the course of the superior profunda and circumflex arteries, the relations of the circumflex, musculo-spiral, and ulnar nerves, the points of insertion of the ligaments of the joints, together with the connections of the important muscles, must be carefully considered before beginning the operation.

The bicipital groove looks forward at all times in the normal arm, and with the arm at the side and forearm supinated it corresponds in direction with the palm. The surgical neck of the humerus is located between the tuberosities above and the insertions of the tendons of the pectoralis and teres

major and the latissimus dorsi muscles below. The circumflex nerve and posterior circumflex vessels pass around the surgical neck at a point about one inch above the center of the deltoid. About one fourth of the epiphyseal junction of the upper end is subperiosteal and located at the outer aspect; the remainder is subcartilaginous and intracapsular (Fig. 391).

The Operation of Excision of the Upper End of the Humerus—Vertical Incision (Langenbeck).—Place the patient upon the back close to the edge of the table, with the shoulders raised. Make an incision about four inches in length downward from the anterior border of the acromion process, close to its articulation with the clavicle, in the line of the bicipital groove (Fig. 392, *b*). The bone at this region is quite superficial. Liberate the long head of the biceps tendon from the groove by carrying the point of the knife upward in the groove at the outer side through the capsule to the acromion and raise the tendon out of the groove (Fig. 393); rotate the arm outward and divide the subscapularis tendon and inner portion of the capsule; then rotate the arm inward and cut the external rotators at their insertions, also the posterior portion of the capsule (Fig. 394); force the head of the bone through the opening in the soft parts, seize it with a strong pair of bone-holding forceps, divide the inferior portion of the capsule, and remove the head of the bone with a chain saw, Gigli-Haertel, or

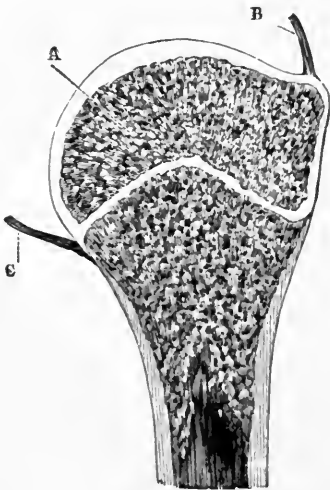


FIG. 391.—A. Epiphysis. B, C. Attachment of capsular ligament. Epiphyseal junction noted.

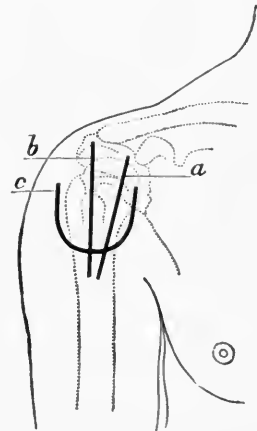


FIG. 392.—Incisions in excisions of end of humerus. *a*. Baudens, Hueter, Ollier. *b*. Langenbeck. *c*. U-shaped.

a small straight saw (Fig. 395), carefully avoiding the circumflex vessels and nerves.

The Operation of Excision of the Upper End of the Humerus—Oblique Incision (Baudens, Hueter, Ollier).—Place the patient as in the preceding operation; make an incision from the outer side of the tip of the coracoid process downward and outward along the anterior border of the deltoid three or four inches in length (Fig. 392, *a*); expose the coraco-acromial

ligament and bare the capsule in the line of the incision; locate the biceps tendon, and divide the capsule at its outer side from below upward; draw apart the borders of the wound and separate the soft parts from the upper end and outer surface of the bone with a knife as the bone is rotated inward; divide the insertions into the great tuberosity of the supraspinatus, infraspinatus, and teres minor muscles; clear the inner aspect in the same way as the humerus is rotated outward; locate the lesser tuberosity; divide the subscapularis insertion and the attachment of the capsule beyond; flex the elbow and displace the biceps tendon inward; cause the head of the bone to project through the wound; seize the extremity with bone-holding forceps and sever it with a saw.

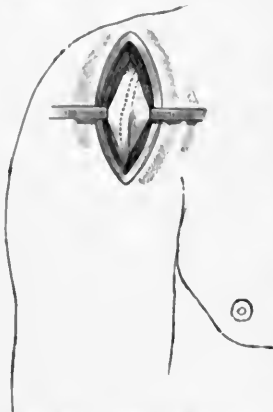


FIG. 393.—Raising tendon.

and borders from the sawed end of the bone, so that they can cause no injury to the axillary vessels and nerves. A V- or the U-shaped (Fig. 392, *c*) incision should not be practiced when the vertical or oblique ones can be utilized, as the former may needlessly damage the deltoid muscle. The circumflex nerve must be carefully avoided, because division or bruising will destroy or impair its function.

MacCormac suggests excision through a posterior incision, when the bone need not be divided below the tuberosities.

The Operation.—With the patient placed on the sound side, the arm abducted and rotated outward so that the outer condyle looks backward, and the forearm flexed, make, from the angular projection of the acromion downward through the posterior part of the deltoid and through the capsule, an incision four inches in length (Fig. 390, *b*); expose the great tuberosity

The Comments.—Good drainage should be secured by posterior puncture, if need be. The tuberosities should be saved when possible, on account of their important muscular insertions. In children carefully avoid injury of the epiphyseal cartilage, if practicable. Remove sharp, bony points

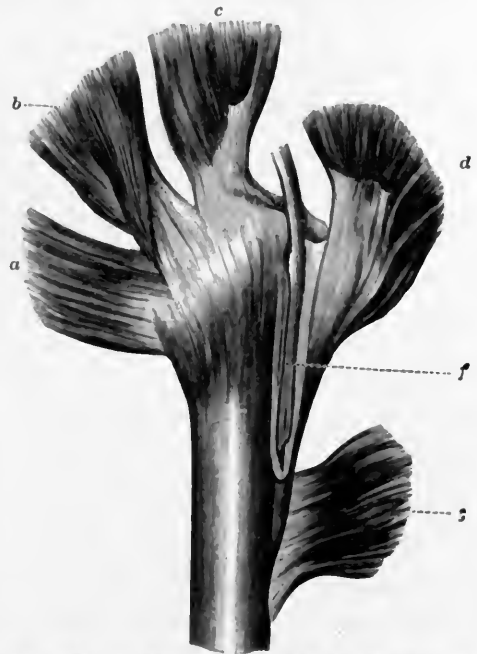


FIG. 394.—Attachments to tuberosities of humerus. *a*. Teres minor muscle. *b*. Infraspinatus muscle. *c*. Supraspinatus muscle. *d*. Subscapularis muscle. *f*. Tendon of long head of biceps muscle in the groove. *g*. Latissimus dorsi tendon.

and the bicipital groove, removing the muscles from the former at their attachment; rotate the arm outward still farther, raising the periosteum and capsule till the bicipital groove is reached; dislodge the tendon and raise it upward; rotate the arm strongly inward, bringing the insertion of the subscapularis into view, and separate it from its attachment; push the head of the bone through the wound and separate the remaining soft parts as the arm is rotated alternately outward and inward; extrude still farther the head of the bone and saw it off.

The Comments.—The circumflex nerve (Fig. 404) will be divided in this method unless great caution be exercised, nor is ample room afforded.

The Operation of Subperiosteal Excision of Head of Humerus (Langenbeck).—Expose the bicipital groove and split up the capsular ligament as in the non-periosteal operation (Fig. 392, *b*). Divide and raise the periosteum from the inner border of the bicipital groove, passing inward and separating it together with the subscapularis and the fibrous capsule from the lesser tuberosity. Rotate the humerus outward and complete the separation to the required extent with the elevator and knife; rotate the humerus inward, displace the tendon of the biceps to the inner side of the head of the humerus, and separate the periosteum from the latter in connection with the capsule and the insertions of the external rotators, being very careful not to sever the connection of the periosteum with the bone below. The forcing of the head of the bone through the external opening is practically impossible without destroying the periosteal connections. It is necessary, therefore, to divide the bone with a chain or narrow-bladed saw without displacement.

Subperiosteal excision is practiced *through the oblique incision* of Baudens and others (Fig. 392, *a*) with almost equal facility to that of the vertical one. After exposure of the capsule and localization of the biceps tendon, the former is divided upward vertically at the outer side of the tendon. The upper end of the bone is then freed of its periosteum and muscular attachments to the proper distance with a rugine, the humerus being rotated outward and inward as before described, to meet the requirements of the procedure.

The Comments.—The removal of the periosteum along with muscular attachments is quite difficult, and must be carefully practiced, especially in the latter instances, to prevent destruction of tissues from too vigorous effort. Subperiosteal excision should be practiced whenever it is possible to do so, since the outcome obtained is superior to that of the less conservative methods.

Partial removal of the upper extremity of the humerus is often necessary on account of disease or injury. The variety and extent of the incisions necessary to reach the part must be governed by the amount of the disease, which may be so great as to demand the U-shaped flap (Fig. 392, *c*).

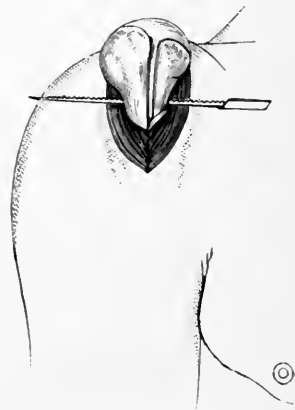


FIG. 395.—Sawing head of humerus.

*The Operation of Excision of the Head of the Humerus (Senn).—*This plan of procedure places the scar resulting from the operation beneath the protecting prominence of the shoulder and provides free access to every portion of the joint and the contiguous parts.

The Operation.—Form a semilunar flap of integument and fascia, beginning over the coracoid process and going with a gentle curve downward

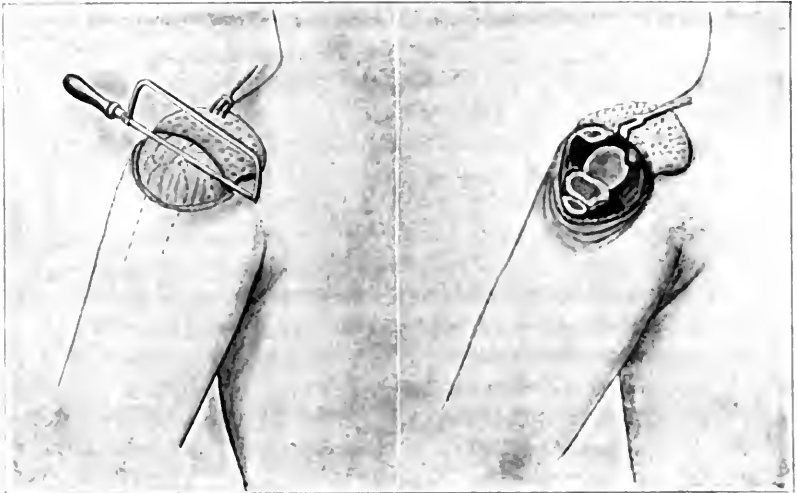


FIG. 396.—Senn's method of resection of shoulder joint. External incision, flap reflected, and saw applied over base of acromion.

FIG. 397.—Senn's method of resection. Division of acromion. Reflection downward of fragment with deltoid muscle. Head of humerus resected.

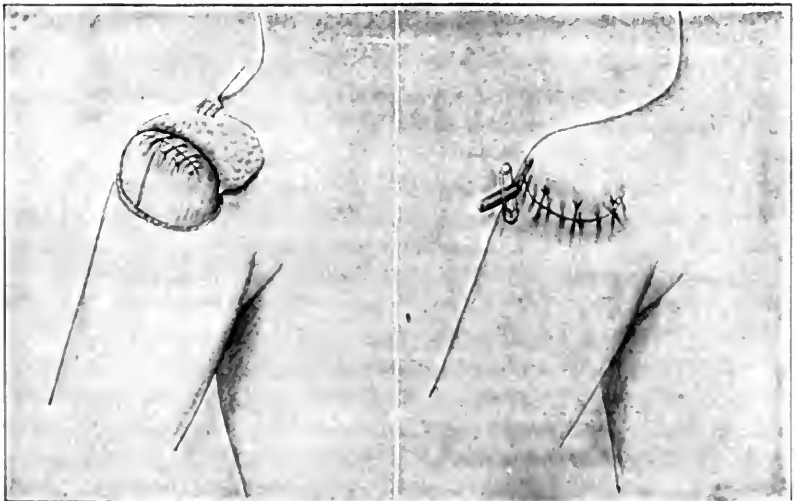


FIG. 398.—Temporarily detached acromion replaced and fastened in position with strong catgut sutures.

FIG. 399.—Operation completed.

and outward across the line of junction of the upper and lower halves of the deltoid muscle, thence with a similar curve upward and backward to the posterior border of the axillary space to a point opposite the beginning; dissect up and reflect the semilunar flap to the base of the acromion process; saw transversely (Fig. 396) through this process, detach downward the fragment along with its deltoid connections, thereby freely exposing

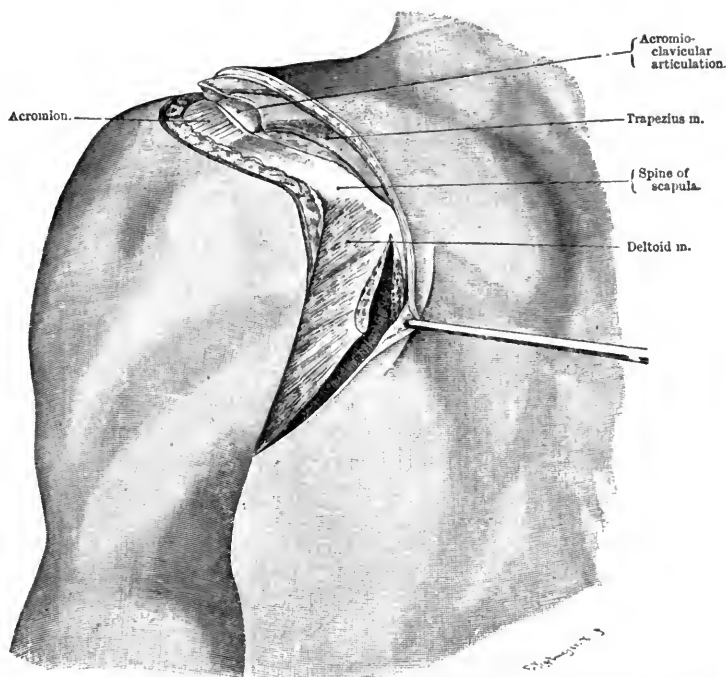


FIG. 400.—Kocher's method of excision of the shoulder joint from behind. Muscles divided and acromion process exposed for sewing.

(Fig. 397) the capsular ligament; open the capsule and examine the joint cavity to determine, in case of disease, the direction and requisite extent of the operation; perform a complete arthrectomy if the disease be limited to the soft structures, dislocating the head of the humerus in different directions to facilitate the procedure; resect the head of the humerus if sufficiently diseased, and remove it to make easier any steps of subsequent arthrectomy; remove all diseased tissues, thoroughly cleanse the wound, introduce drainage if needed, replace the acromion process and suture it in position with strong chromicized catgut (Fig. 398); unite the divided portions of the deltoid muscle with buried sutures; return the cutaneous flap, suturing it in place in the usual manner (Fig. 399); apply abundant aseptic dressing to the wound and confine the arm to the side of the chest by means of a light plaster-of-Paris bandage. If the exposure of the joint be made for cure of irreducible dislocation, the head of the humerus can be located as soon as the deep flap is turned down and the causes of

the resistance to reduction determined and removed by division or other means, and the head of the bone is restored to its proper place. In these instances drainage, as a rule, is not employed.

The Comment.—Bardenheuer's incision is made directly over and through the acromion process, thus placing the scar in an exposed situation.

Kocher practices excision of the *shoulder joint from behind* through a curved incision carried from and into the acromio-clavicular joint over the top of the shoulder along, then across the acromion corresponding to its root, severing the corresponding insertion of the trapezius, thence downward in a curved direction toward the posterior fold of the axilla, dividing the dense fascia and exposing the posterior border of the deltoid to a point about an inch and three quarters above the fold (Fig. 400). He frees the infraspinous muscle with the finger from the outer border of the spine and root of the acromion process, detaches the supraspinous muscle from the spine with a blunt director, so as to permit the finger to pass from above beneath the root of the acromion. He then chisels obliquely through the acromion at the inner limit of the roots and pushes the fragment (Fig.

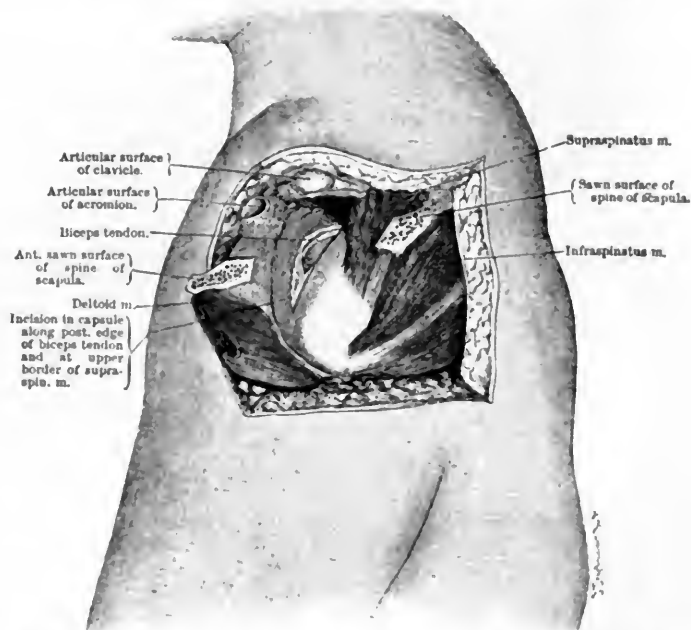


FIG. 401.—Kocher's method of excision of shoulder joint from behind. Flap reflected and the capsule excised behind the long tendon of the biceps.

401) over the head of the humerus along with the attached deltoid, thus exposing the upper and posterior aspects of the head of the bone, revealing the muscles and tendons associated therewith. The arm is then rotated outward and curved forward and an incision is made down to the bone, commencing at the upper part of the posterior lip of the bicipital groove, passing upward through the capsule along the anterior edge of the inser-

tion of the external rotators over the uppermost part of the head, exposing the tendon of the biceps to its point of origin (Fig. 402). The insertions of the external rotators are now exposed from the great tuberosity and drawn backward, the biceps tendon is raised from its groove and drawn forward, exposing the joint cavity to free inspection and to the relief of such radical or conservative steps as may be advisable.

The Comments.—The view thus afforded is obtained without damaging any important functional muscles of the joint, and without injury to the

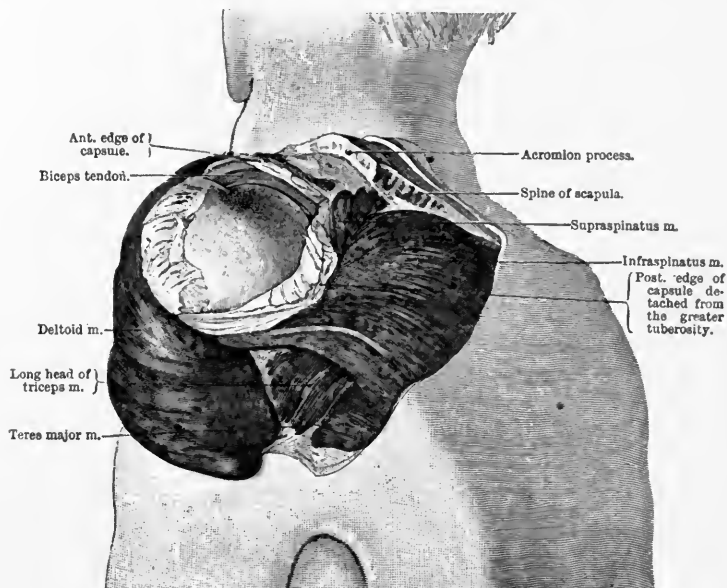


FIG. 402.—Kocher's method of excision of the shoulder joint from behind. The head of the humerus exposed and ready for displacement upward for complete excision if required.

circumflex nerve and vessels, if reasonable care is exercised. If the head of the bone be removed, increased observation, especially below, is secured. This plan offers special opportunity to examine and treat conditions referable to the posterior part of the joint.

The Operation of Arthrotomy for Irreducible Dislocation of the Humerus.—This unfortunate condition may happen with and without fracture of the upper end of the humerus, and the latter may occur primarily or be secondary to efforts at reduction. In all instances of dislocation, reasonable attempts at bloodless reduction by manipulative methods should be practiced. The operation is indicated either before decided inflammatory changes and extravasation have ensued, or at a period immediately following their practical cessation. In instances of fracture, the earlier period is apt to be the better time to effect reduction. Whenever approach for purposes of reduction can be made without invading the cavity of the joint, or going through ruptured structures, the earlier the endeavor is made the better.

The Operation.—Expose freely the capsule of the joint through an anterior incision of not less than three inches in length, made in the line of the bicapital groove; draw apart the borders of the wound, remove from the field thus disclosed all extravasated blood and carefully examine the structures concerned, and also the patient, with the idea of determining if the head of the bone or the glenoid cavity be much damaged; also the need of extended dissection and the ability to restore and retain in place with useful outcome the dislocated head; if the vitality be ample to obviate necrosis, and if the condition of the patient justifies prolonged and profound efforts at restoration; also, consider if the capacity for complete and continued asepsis be assured. Should one or more of these propositions oppose reduction with practical emphasis, then prompt resection should be considered, whether fracture be present or not; if otherwise, efforts at reduction should as promptly be made. *In the absence of fracture*, efforts at restoration will demonstrate the special structures that oppose return of the head to the glenoid cavity. These structures in turn should be partly or completely severed, as circumstances require, or their opposing influences obviated by manipulations of the arm and of the tissues, by proper tractile agents. The tendon of the long head of the biceps, the subscapularis, the external rotators and portions of the capsular ligament are singly or variously combined prominent agents of obstruction to return.

In the presence of fracture the loss of fulcrumage due to fracture of the bone adds its potent hindrance to that of the restraining agents already cited. Fulcrumage is supplied in a lesser degree than natural by bone forceps (Fig. 375, *h*), the McBurney hook (Fig. 403), and similar agents, sup-

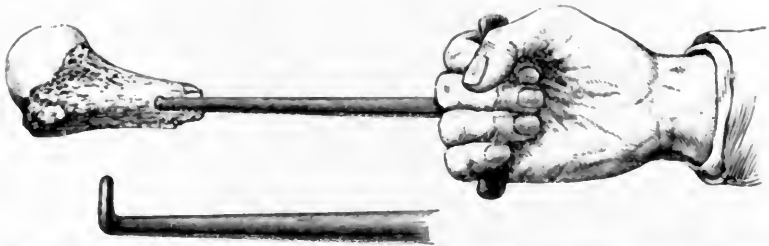


FIG. 403.—The McBurney hook for supplying fulcrumage in dislocation with fracture.

plemented by digital manipulation, aided by prying agents directly applied. No definite technique of reduction can be established, the indications being met as the varying circumstances of cases arise. After reduction, the fragments of bone should be sutured together, the capsule repaired, ligaments united and muscular insertions fastened in place, by sewing with kangaroo tendon or chromicized catgut. The wound should be drained and dressing held in position, and the arm confined to the side by several turns of plaster-of-Paris bandage.

Careful observation of the temperature should be made to note the approach of any inflammatory manifestations; when noted, the dressings should be promptly removed and the wound examined for hidden infection.

The Remarks.—The anterior incision is better than the posterior or the axillary. The latter affords easy resection, but is objectionable in reduction, especially with fracture. Various anatomical associations also oppose it.

Senn's incision is a commendable one for the purpose. Consult Souchon's* able and finished article on Operative Treatment of Irreducible Dislocations of the Shoulder-Joint, Recent or Old, Simple or Compound, if possible, before taking final action.

The After-treatment.—Early, careful and persistent passive motion, massage, electric stimulation and gymnastic exercise should be practiced.

The Results.—In dislocation with fracture, digital manipulation succeeded in restoring the parts in 36 of 80 cases (McBurney). According to Souchon, "mere improvement" is noted in 5 per cent of reductions and in 28 per cent of resections. "Fair results" in 16 per cent of the former and in 16 per cent of the latter. "Good results" in 50 per cent of the former and 42 per cent of the latter; "death-rate," 10 per cent in reductions and 12 per cent in resections.

The Operation for Habitual Dislocation of the Humerus.—Gerster, Ricard, Burrell and others have cured the above infirmity by removing the redundancy of the anterior part of the capsular ligament of the shoulder joint and closing the wound with sutures. The following is the operative method, as practiced by Burrell.†

The Operation.—Place the patient on the back with the arm slightly abducted; make an incision from the coracoid process downward and outward, along the groove formed by the junction of the deltoid and pectoralis major muscles (avoiding the cephalic vein), to below the upper border of the tendon of insertion of the pectoral muscle; draw the vein aside, separate the muscles from each other, exposing the coraco-brachialis, short head of the biceps and the upper part of the tendon of the pectoralis major below; avoid the acromio-thoracic artery, divide the upper three fourths of the tendinous insertion of the pectoralis major, retract the muscle so as to expose the head and much of the bone. After the tendon of the coraco-brachialis and the short head of the biceps are cleared, and the wound extended quite up to the coracoid process, rotate the arm externally, letting it fall backward, thus revealing the insertion of the subscapularis stretched over the head of the bone, the upper portion of which tendon is at once divided; abduct the arm to an angle of 45 degrees, and press the head of the bone backward, thus relaxing the front portion of the capsule; grasp with three-pronged forceps the loose part of the front of the capsule and insert through this portion with a curved needle three sutures, placed so as to permit of excision from the capsule of a portion three quarters of an inch in length and three eighths of an inch in width; tie the sutures firmly, thus shortening and tightening the capsule; irrigate, dry and close the wound in the usual way; apply aseptic dressings and fix the arm to the side, with the hand across the chest.

The Results.—Several cases are reported with satisfactory results.

* Transactions of the American Surgical Association, vol. xv, 1897.

† Transactions of the American Surgical Association, vol. xv, 1897.

The Operation of Excision of the Shaft of the Humerus.—In this operation, unless great caution is observed, the musculo-spiral nerve and the superior profunda artery will be injured in their course along the musculo-spiral groove, as will also the circumflex nerve and vessels, if the incision be extended (Fig. 404) too far upward. The upper portion of the shaft is easily exposed by making an incision of sufficient length through the outer surface of the deltoid, commencing at its lower third and dividing it carefully upward, to avoid the circumflex nerve and artery. The bone denuded of its periosteum is then removed, or, should there be a morbid growth connected with it, the bone and tumor should be removed together. If the lower por-

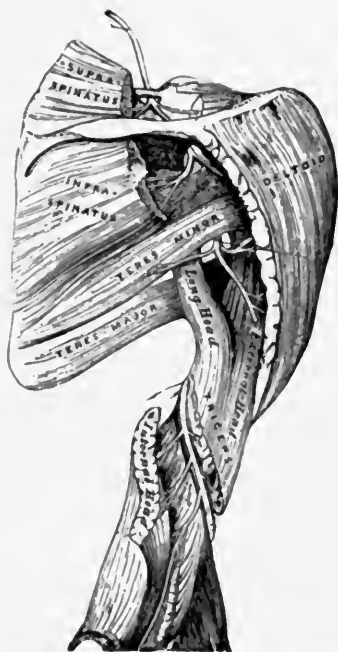


FIG. 404.—Musculo-spiral and circumflex nerves.



FIG. 405.—Relation of ulnar nerve to elbow joint. *a.* Inner condyle of humerus. *b.* Ulnar nerve. *c.* Olecranon process.

tion of the shaft is to be operated upon, make the incision along the outer border of the brachialis anticus muscle, carefully avoiding the musculo-spiral nerve. Expose the bone and remove it as before.

The Excision of the Lower Extremity of the Humerus.—The relation of the ulnar nerve (Figs. 405, *b*, and 223, *J*) to the internal condyle, *a*, and of the brachial artery to the anterior surface must not be forgotten. Make an incision on the posterior and external surface of sufficient length to thoroughly expose the bone; elevate the periosteum and divide the bone with a saw; pull the upper end of the fragment downward and disarticulate it from without inward.

If it be necessary to remove the entire humerus, make incisions as if to remove the upper and lower portions, observing the same precautions relative to the anatomy of these parts as before expressed. The musculo-spiral nerve in this operation is to be cautiously avoided.

The After-treatment.—In the preceding operations substantially the same treatment is required: Arrest the hæmorrhage, provide drainage, close the lips of the wound, envelop the entire limb with antiseptic dressing, and place it upon a splint or a triangular-shaped axillary pad, affording an easy support at the proper angle. Thereafter redressing is practiced in the manner and with the frequency required. As early as practicable passive motion of the joints of the extremity, with massage and electricity, are carried into effect. Extension with a weight is often necessary during the early healing process in order to maintain the limb at a suitable length and to avoid ankylosis.

The Results.—The results depend much upon the nature of the injury or of the disease, the period of the operation, and the employment of antiseptics. Of 984 cases done before sepsis, 856 were done for gunshot injury, with a mortality of 36.68 per cent, and 128 for disease, 22.77 per cent of which died; (Culberston) of 164 cases done under sepsis for all causes, 12.1 per cent died. In nearly all cases the limbs were useful.

Excision of the Elbow Joint.—Excision of the elbow joint consists in the removal of the articular surfaces and more or less of the shafts of the three bones composing it.

The Anatomical Points.—While the anatomical points associated with the elbow joint are numerous, yet the really essential ones can be quite briefly stated. The time of union and the lines of junction of the epiphyses should be carefully noted in order if possible to avoid disturbance of the epiphyseal structure. The internal condyle is longer, thinner, and more prominent than the outer. The olecranon and coronoid processes and the tubercle of the radius afford attachment to important muscles, and should therefore be preserved when possible. The triceps is inserted into the olecranon and the periosteum and is continuous with the fascia of the forearm posteriorly. The biceps through the agency of the bicipital fascia alone can flex and pronate the forearm. Through the influence only of the tendon of insertion flexion and supination are accomplished. The ulnar nerve lies in the groove between the olecranon process and the internal condyle close to the bone in a fibrous environment of its own (Figs. 223, *J*, and 405, *b*). The supinator brevis should be treated carefully in removal of the head of the radius, not alone for the preservation of its own function, but likewise for protection of the posterior interosseous nerve that passes through it.

The Operation of Excision of the Elbow Joint (Hüter).—With the forearm extended make a slightly curved incision about an inch in length down upon the tip of the internal condyle and carefully separate the muscular and ligamentous attachments to the condyle. Make a second longitudinal incision from three to four inches in length from above the outer condyle to

just below the head of the radius (Fig. 406). Draw aside the soft parts and cut the external lateral and orbicular ligaments (Fig. 407, ligaments of elbow joint). Expose the head and neck of the radius and cut off the head with a saw or bone forceps. Separate the capsular ligament from its attachments on the anterior and posterior surfaces of the humerus and force the extremity of the humerus out of the external wound. This movement admits of division of the bone and at the same time draws the ulnar nerve from its bed and away from the inner condyle. Saw off the lower end of the humerus and carefully expose and remove the olecranon.

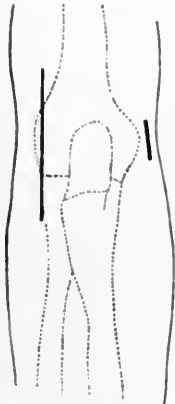


FIG. 406.—Hüter's incision.

The Operation of Subperiosteal Excision of Elbow Joint (Langenbeck).—Beginning at a point a little to the inner side of the middle of the olecranon process, and about two inches and a half below the tip, make a longitudinal incision toward the humerus down to the bone about four inches in length, carefully avoiding the ulnar nerve (Fig. 408, *a*, Langenbeck's incision). Remove the periosteum

from the portion of the olecranon process and ulna at the inner side of the incision. Separate by short parallel incisions the attachments of the inner half of the triceps tendon to the olecranon process. Push the tissues at the internal condyle, together with the ulnar nerve (Fig. 410), inward toward the tip of the condyle, and elevate the periosteum from the inner condyle sufficiently to separate the internal lateral ligaments and the attachments of the muscles from the bone and leave them connected with the periosteum. The liberated tissues are now permitted to return to their former position, and the outer portion of the tendon of the triceps is drawn outward and disconnected from the olecranon process by short transverse incisions, closely hugging the bone and allowing it to remain continuous with the periosteum which is reflected upon the outer surface of the olecranon and shaft of the ulna. Expose the external condyle by separating the capsular ligament at its attachment above the trochlea and capitellum. The tissues, including the detached periosteum and tendon of the triceps, are separated well from the bone by retractors. Flex the forearm and force the extremities of the bones through the opening; saw off the head of the radius, then the lower end of the humerus, and finally the olecranon process.

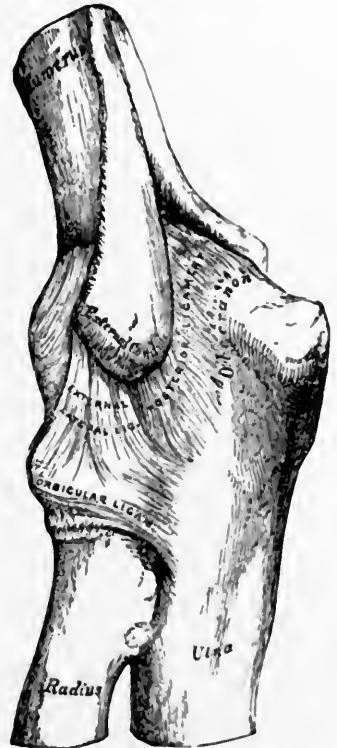

FIG. 407.—Ligaments of elbow joint.

The Operation of Excision of the Elbow Joint by the \perp - Shaped Incision (Liston).—Flex the elbow to an obtuse angle, the operator facing its posterior surface; open the capsule between the olecranon process and internal condyle by a longitudinal incision about four inches in length made along the inner border of the olecranon (Fig. 409); dissect and draw the soft parts over the internal condyle with the thumb (Fig. 410), increasing the flexion gradually till the condyle is fully exposed; divide the internal lateral ligament, extend the arm, and carry a transverse incision from the point of articulation of the radius with the humerus directly across to the center of the former incision.

The periosteum on the inner surface of the olecranon process and ulna is raised and left connected with the tendon of the triceps, which is carefully separated from the bone. Open the flaps widely and divide the external lateral ligament, flex the forearm, and the articular surfaces will separate. Seize and saw off the lower extremity of the humerus, the olecranon process, and finally the head of the radius.

The Operation of Excision by the Bayonet-shaped Incision (Ollier, Fig. 408, *b*).—The terminal portion of the bayonet incision is vertical, begins two and one half inches above the line of the articulation, and passes downward between the triceps and supinator longus muscles and terminates at the tip of the outer condyle. The middle or oblique portion of the incision extends from the tip of the condyle downward and inward to the base of the olecranon, thence along the posterior border of the ulna for one and a half to two inches. An internal incision an inch in length is then made with the center

at the internal condyle, the bone exposed, and internal lateral ligament detached. The external condyle, olecranon and coronoid processes and head of the radius are exposed in the usual manner, bones dislocated forward, lower end of humerus is entirely freed, and the bones are severed with a fine saw.

The Remarks.—It would appear that the saving of synovial membrane exerts a more conservative influence on the usefulness of the joint than the saving of bone, provided, of course, that the bony insertions of the muscles acting directly on the joint be respected. If the operation be for traumatism, remove the fragments; if for disease, remove the diseased portion; and in both conditions trim the extremities of the bones so as to afford symmetrical support to opposite bony surfaces. The wounds are closed in the usual manner, drained, and dressed antiseptically. It is necessary to remem-

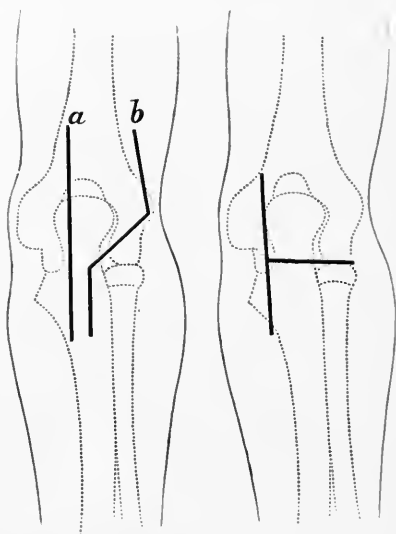


FIG. 408.—*a*. Langenbeck's incision. *b*. Ollier's incision.

FIG. 409.—Liston's incision.

ber in all cases of excision of the elbow joint to respect the insertions of important muscles, such as those of the brachialis anticus, biceps, triceps, etc. To unnecessarily destroy the power of one of these is to be guilty of an unpardonable neglect. Various formed incisions other than those described have been employed, as the H (Moreau), with the horizontal por-

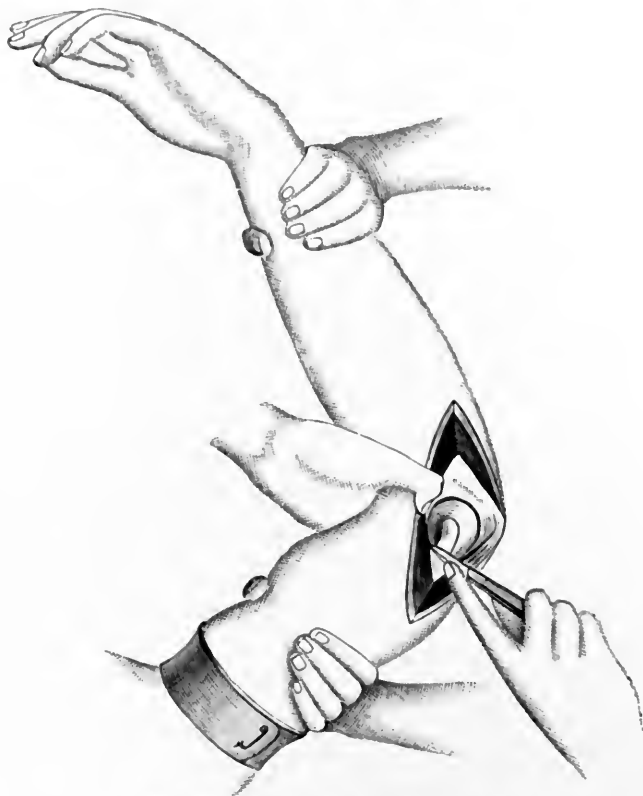

FIG. 410.—Exposing internal condyle.

tion corresponding to the articulation; U-shaped or semilunar, with the convexity downward. Either of these imperil the insertion of the triceps.

The After-treatment.—Ankylosis and flail joint are not infrequent sequels of excision of the elbow joint. The former depends very often, indeed, on a too limited and the latter on a too free removal of bone. At the outset the divided extremities should be, when undisturbed, not less than half to three quarters of an inch apart, with the forearm midway between supination and pronation, and be thus maintained during the major portion of the healing by a properly constructed splint to avoid ankylosis. The splint should be light, easily cleansed, and have a movable joint corresponding to the elbow. A bracketed plaster-of-Paris splint with proper suspension is serviceable during confinement in bed (Fig. 411). At first the forearm is placed at a right angle or, better still, at one of one hundred and thirty-five degrees

as suits the case, which angle is frequently varied during the healing process. Passive motion of all the joints of the extremity should be employed early and continued during recovery, along with massage and the use of electricity. Supination and pronation of the forearm and passive motion at the seat of the false joint is begun about the tenth or twelfth day, according to the demands of the case. It should not be forgotten that the aim is to secure a false joint, and that every consistent effort to that end must be exercised for the first two months after the operation, even though much pain be inflicted. The grasping and carrying of a weighted pail in the hand is an important measure of treatment to overcome obstinate flexion of the forearm.

The Results.—Excision of the elbow joint has been performed with such good success that its high rank is thoroughly established. Although when due to injury the rate of mortality is about twenty per cent, when due to disease it is less than eleven per cent. Of 92 cases under asepsis for all causes, four per cent died.

The Operation of Excision of the Ulna.—In excision of the ulna an incision is made along the posterior border of sufficient length to expose the diseased bone, the periosteum is pushed aside, and section is made at the requisite point and the diseased bone is removed. The dorsal branch of the ulnar nerve at the lower third of the bone is carefully avoided.

If it be a partial excision of the upper extremity, expose that portion by an incision in the same line as for removal of the entire bone; elevate the periosteum, leaving if possible the attachments of the brachialis anticus and triceps muscles and avoiding the ulnar nerve at the inner condyle.

The Operation of Excision of the Radius.—Make an incision extending from the styloid process of the radius, along the outer border of the anterior surface of the forearm to the radio-humeral articulation, through the integu-

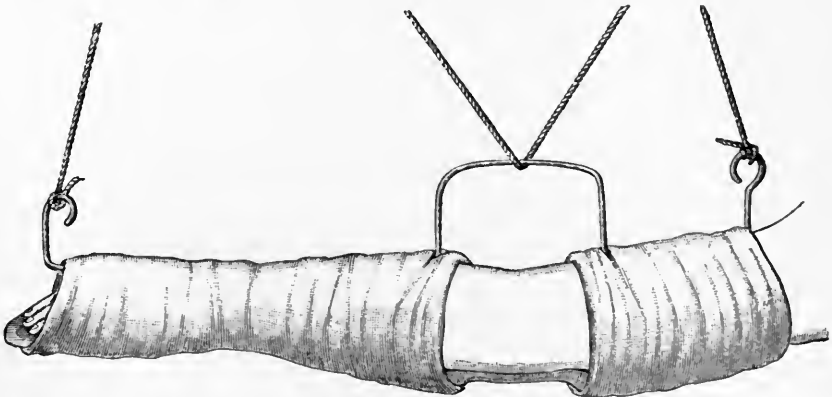


FIG. 411.—Bracketed plaster-of-Paris splint for elbow.

ment and fascia. Seek the outer border of the supinator longus, pass upward, separating it from the flexor longus pollicis, and going down to the bone; divide the supinator brevis, also the periosteum in the long axis of the radius; elevate the periosteum; divide the bone in the center and remove each half separately. The insertion of the biceps and pronator radii

teres should be carefully preserved. If an extremity of the bone is to be excised, expose the portion to be removed by an incision made in the same line as the preceding; raise the periosteum with equal caution and remove the diseased portion.

The results of excision of these bones are good, provided the excision be subperiosteal and the epiphyses be not disturbed.

The Operation of Excision of the Lower Extremities of the Bones of the Forearm (Bourgary).—Make a longitudinal incision from just below the apex of the styloid process two inches in length along the dorsal surface of the ulna (Fig. 412, lateral incisions).

Divide the periosteum at the interspace between the extensor and flexor carpi ulnaris muscles and reflect it from the dorsum of the bone inward to the interosseous membrane. A second longitudinal incision is made from just below the apex of the styloid process two or three inches upward along the outer side of the radius. The periosteum is divided through the same incision, the attachment of the supinator longus separated, and the periosteum raised on the dorsal surface together with the sheaths of the extensor tendons.

The periosteum is then elevated from the like portions of the palmar surface of the lower ends of both bones around to the interosseous membrane. Protect the soft parts carefully while the bones are being sawed through. The operation can be extended to the bones of the carpus if necessary by continuing the lateral incisions downward.

Excision of the Wrist Joint.—Excision of this joint is associated with difficult and tedious details. The wrist joint consists properly of the radius, articulated with the outer two of the first row of carpal bones. In cases where excision is necessary it is not usual to find the disease or injury limited entirely to these structures. It is important, however, to remove all bony structures

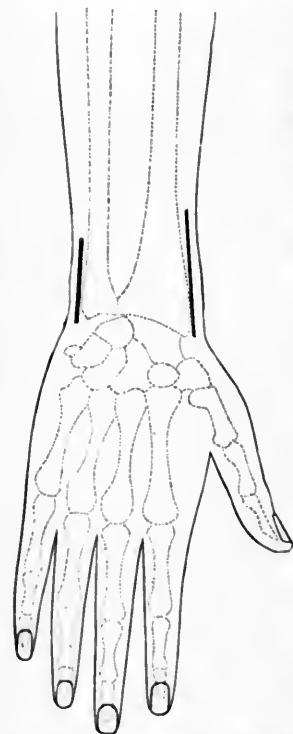


FIG. 412.—Lateral incisions.

involved even though they include the two rows of carpal and the contiguous extremities of the metacarpal bones.

The Important Considerations.—The intimate relation existing between the carpal bones and the continuity of their synovial surroundings renders them especially liable to progressive disease as well as to acute inflammatory processes (Fig. 413). Therefore their relations to each other must be carefully scrutinized, to avoid needless involvement of contiguous synovial sacs, and to impress the necessity of their removal when diseased. A knowledge of the periods of development of the epiphyseal structures and the bones of the carpus is of pronounced significance in the conservative sense. The apices of the styloid processes are about

half an inch below the radio-carpal line. The bones are firmly bound together by strong ligaments admitting of but limited movement between their surfaces (Figs. 414, 415). They are in close relation to the tendons of important muscles, which should be scrupulously preserved together with their sheaths (Fig. 416).

All diseased or detached bone should be removed. If a portion of a carpal bone be diseased it is better that the entire bone be removed. The insertions of the muscles acting on the carpus should be preserved if possible. It therefore becomes necessary for the surgeon to carefully observe the relations of important tendons, vessels, and nerves to the structures to be removed in order to secure the best results. The trapezium, because of its relation to the thumb and the bases of the metacarpal bones of the index, middle, and little fingers, on account of the important muscles inserted there-

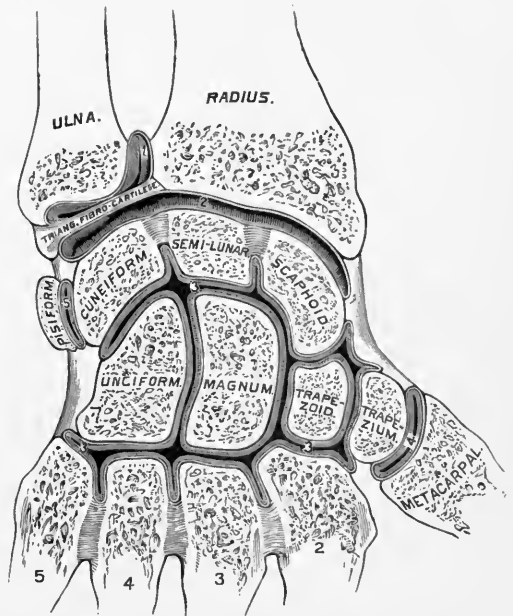


FIG. 413.—Synovial membranes of the carpus.



FIG. 414.—Ligaments of dorsal surface of carpus.

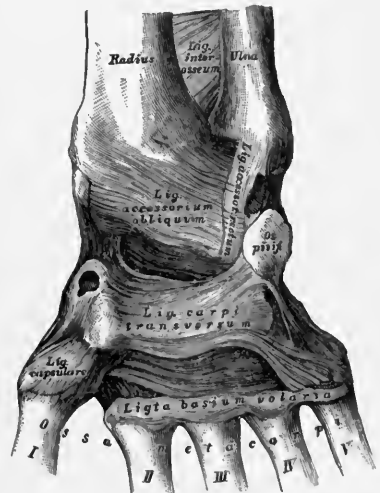


FIG. 415.—Ligaments of palmar surface of carpus.

into, are important. To avoid hæmorrhage, the relations of the deep palmar arch, anterior and posterior carpal branches, and dorsal interosseous branch

to the osseous structures must be noted, as well as those of the radial artery to the dorsum of the wrist, to the styloid process of the radius and the carpal articulation of the thumb. Subsequent adduction of the hand is opposed by leaving the styloid process of the ulna behind.

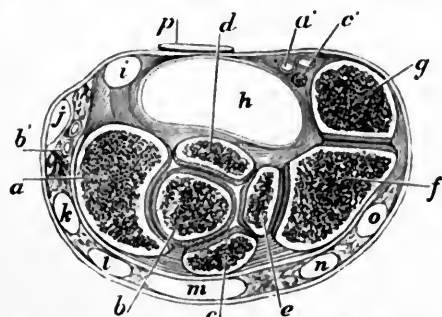


FIG. 416.—Section through the wrist. *a.* Scaphoid. *b.* Os magnum. *c.* Semilunar. *d.* Semilunar. *e.* Unciform. *f.* Cuneiform. *g.* Pisiform. *h.* Compartment for flexor tendons. *i.* Flexor carpi radialis. *j.* Extensor ossis metacarpi pollicis and extensor primi internodii pollicis. *k.* Extensor carpi radialis longior and brevior. *l.* Extensor longus pollicis. *m.* Extensores communis and indicis. *n.* Extensor minimi digiti. *o.* Extensor carpi ulnaris. *p.* Palmaris longus. *a'.* Ulnar vessels. *b'.* Radial vessels. *c'.* Ulnar nerve.

Tendons are not divided except they form an insurmountable obstacle to making the incision necessary for removal of the bones; if cut they should be promptly sutured. If the tendons be divided at a distance from the immediate seat of the operation and sutured, the chances of their union will be increased.

The fact that subperiosteal technique should be followed when practicable in either partial or complete excision of the wrist, seems to be well established.

The Operation of Complete Excision of the Wrist Joint—Subperiosteal (Langenbeck).—Place the

forearm and hand of the patient with the palm downward on a table of convenient height for the operator and his assistants. Make an incision through the integument, beginning at the middle of the metacarpal bone of the index finger at its ulnar border, and extend it longitudinally to three fourths of an inch above the lower extremity of the radius at its middle (Fig. 417). The deeper course of the incision passes to the radial side of the extensor indicis without opening its sheath, upward, over the tendon of the extensor carpi radialis brevis to the radial side of its insertion; push the tendons going to the index finger to the ulnar side and extend the incision upward to the tendons of the extensor longus pollicis and the extensor indicis, dividing the lower portion of the posterior annular ligament. Draw the tissues apart with suitable retractors and separate from the bone with a periosteal elevator the fibrous sheaths of the extensors of the carpus on the posterior surface of the radius; the insertion of the supinator longus muscle and the annular and capsular ligaments are then disconnected and drawn to the radial side together with the periosteum; the tendons, ligaments, and periosteum on the posterior surface of the ulna are separated in the same manner and drawn to the ulnar side. Open well the radio-carpal joint, flex the carpus and expose the articular surfaces, and separate the bones of the first row from their connection with each other, leaving the periosteum if possible. Liberate the scaphoid from the trapezium and trapezoid, the semilunar from the os magnum, and the cuneiform from the unciform. Lift them out, together with the trapezium and pisiform bones. The inner bones of the second row are taken out if necessary after severing their con-

nections within the trapezium and the bases of the metacarpal bones. The extremities of the radius and ulna can now be forced through the wound, carefully exposed, and sawed off, avoiding the radial and ulnar vessels. The resulting wound is treated by antiseptic measures.

The tendon of the extensor carpi radialis brevis lying in the course of the incision may require division to facilitate the proper separation of the deeper parts. Its insertion into the base of the second metacarpal bone may, however, be chiseled off instead, and repair by tenorrhaphy in the one instance and by nailing the bony insertion at the proper site in the other should be promptly practiced. When necessary for convenience of removal, the excision should be extended upward to the distance of an inch or an inch and a half above the line of the articulation. Boekel's operation consists substantially in the extension of Langenbeck's.

*The Operation of Complete Excision of the Wrist Joint; Subperiosteal (Ollier).—*Place the patient as in the preceding instance, and, beginning opposite the center of the second metacarpal bone (Fig. 417, 2), *make a radial incision* along the radial side of the extensor indicis upward to a point an inch and a half above the line of articulation of the wrist joint; expose the tendon of the extensor indicis without opening the sheath, draw it gently outward by the aid of a hook, and locate the insertion of the extensor carpi radialis brevis; expose the base of the third metacarpal bone at the radial side of the last-named tendon; divide the posterior annular ligament and open the capsule of the joint between the tendons of the extensor indicis and extensor longus pollicis; draw the former tendon outward along with those of the extensor longus digitorum; *make an ulnar incision* down to the bones at the inner side of the tendon of the extensor carpi ulnaris, from a point an inch and a quarter above the tip of the styloid process to the same distance below the base of the fifth metacarpal bone, avoiding the nerves going to the little finger; through the incision already made divest the carpal bones of their ligamentous and periosteal coverings by small rugines preferably introduced first at the radial side; free the bones, expose

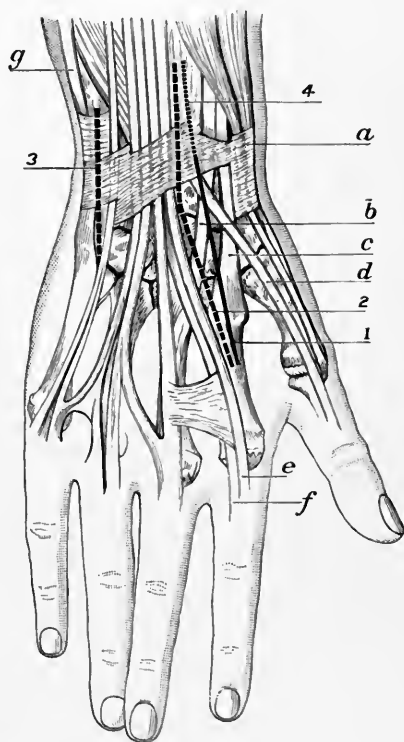


FIG. 417.—Excision of wrist joint. 1. Langenbeck's incision. 2, 3. Ollier's incisions. 1, 4. Boekel's incisions. *a*. Annular ligament. *b*. Extensor carpi radialis brevis. *c*. Extensor carpi radialis longior. *d*. Extensor longus pollicis. *e*. Extensor communis digitorum. *f*. Extensor indicis. *g*. Extensor carpi ulnaris.

the carpal bones of their ligamentous and periosteal coverings by small rugines preferably introduced first at the radial side; free the bones, expose

and remove them through the corresponding incisions, saving if possible the pisiform, the unciiform process, and the trapezium; bare the radius and ulna of periosteum as high up as needful, protrude the ends through the opening and divide them with a saw.

The Comments.—In recent injuries it is difficult indeed to separate the tissues from the bones, especially in adult subjects. In young subjects and in those in whom the parts are affected with chronic inflammation, the separation is easier. The tendons and their insertions are preserved much better in the subperiosteal than in the open method.

The Operation of Complete Excision of the Wrist Joint; Subperiosteal (Lister).—Begin the first or radial incision at the middle of the dorsal aspect of the radius on a level with the styloid process, and carry it toward the inner side of the metacarpal articulation of the thumb parallel with the tendon of the extensor longus pollicis to the radial border of the second metacarpal bone, thence along that bone half its length (Fig. 418); cut the tendon of the extensor carpi radialis brevis, detach with a knife the tendon of the extensor carpi radialis longior; push outward these tendons along with that of the extensor longus pollicis and the radial artery; separate the trapezium from the carpus in the line of the incision with cutting forceps, carefully avoiding the radial artery; bend the hand backward to relax the extensor muscles and dissect up the soft parts at the ulnar side.

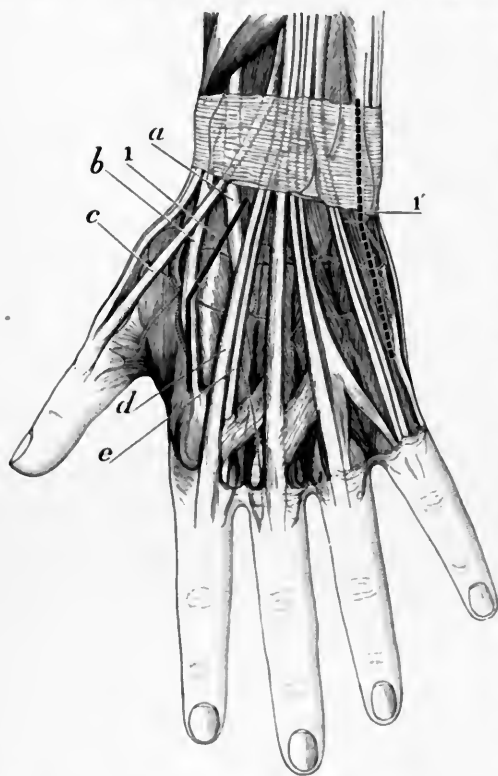


FIG. 418.—Lister's incisions. 1. Posterior radial incision. 1'. Anterior ulnar incision. a. Extensor carpi radialis brevis. b. Extensor carpi radialis longior. c. Extensor longus pollicis. d. Extensor communis digitorum. e. Extensor indicis.

Begin the second or ulnar incision at the anterior aspect of the ulna, at a point two inches above its lower end, and bring it downward in a straight line between the bone and the flexor carpi ulnaris to the middle of the palmar aspect of the fifth metacarpal bone; raise the posterior lip of the incision; expose at the insertion and divide there the tendon of the extensor carpi ulnaris, dissect it from its groove without separation from the tissues overlying it; separate the extensors of the digits from the carpus, divide the dorsal and internal lateral ligaments of the wrist joint. Flex the

middle of the palmar aspect of the fifth metacarpal bone; raise the posterior lip of the incision; expose at the insertion and divide there the tendon of the extensor carpi ulnaris, dissect it from its groove without separation from the tissues overlying it; separate the extensors of the digits from the carpus, divide the dorsal and internal lateral ligaments of the wrist joint. Flex the

carpus, expose the anterior surface of the ulna, closely hugging the bone to avoid injury to the ulnar vessels and nerves, open the articulation of the pisiform bone, and cut at the base the unciform process with pliers. Divide the anterior ligament of the wrist joint; sever the carpus from the metacarpus with bone-cutting forceps; extract the carpus through the ulnar incision, dividing restraining ligamentous connections therewith at the same time; cause the ends of the radius and ulna to protrude through the ulnar incision by forcible eversion of the hand; remove from these bones all diseased tissue, disturbing as little as possible the extensor tendons of the thumb; remove disease from metacarpal extremities, seize and remove the trapezium without cutting the tendon of the flexor carpi ulnaris as it lies in the groove in the palmar aspect.

All hæmorrhage having ceased, suture the divided tendons and close the wounds, allowing the more dependent incision to remain open for drainage. Envelop the limb in antiseptic dressings, causing the whole to be properly supported by a splint (Fig. 419).

The Precautions.—Avoid the radial artery in making the primary incision, and in the removal of the trapezium, which bone is removed last for this purpose. In attacking the heads of the metacarpal bones, recall their relation with the deep palmar arch. The intimate association between the tendons and their contiguous tissues must be disturbed as little as possible, otherwise the vitality of the tendons will be much impaired and perhaps destroyed. The radius and ulna should be maintained as nearly the same length as practicable, to suitably support the head. Therefore, as little as need be of healthy bone should be removed from either, the styloid process

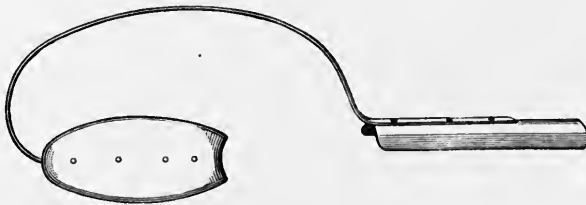


FIG. 419.—Esmarch's interrupted splint for exsection of the wrist.

of both, that of the ulna especially, being preserved when possible. Any sound portion of the pisiform should be preserved on account of the relation of the bone to the anterior annular ligament and flexor carpi ulnaris. The metacarpal bone of the thumb should be held at the same level as those of the remaining digits, to secure better symmetry of the hand. In excision the adhesions ought to be broken before the operation is begun. In instances of local disease the application of the Esmarch bandages should be applied with caution, if at all. In traumatic cases the use of this agent may lead to a too scant regard for the safety of important vessels.

The After-treatment.—The indications for this treatment are perfect cleanliness and the use of a splint that will keep the forearm midway between pronation and supination, thumb and fingers free, and the hand slightly extended and abducted. The wound should be frequently observed and passive

motion of the digits made early and often. After the wound is healed, passive motion of the false joint and the use of massage and electricity should be persistently employed. The simple wooden splint devised by Lister and

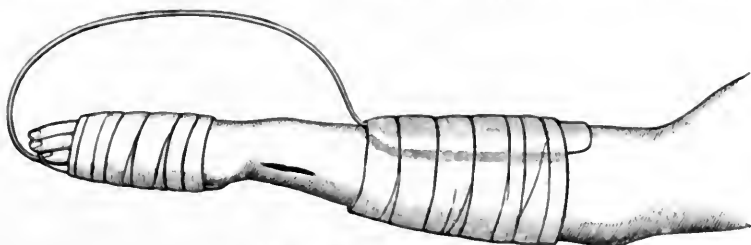


FIG. 420.—Esmarch's splint applied.

the splint of Esmarch (Figs. 419 and 420) are well adapted for the after-treatment. However, a plaster-of-Paris splint molded to meet the indications and protected with oiled silk and suspended or not as required, can be employed instead (Fig. 421).

Incisions of other shape are made through which to effect the removal of the wrist joint; but the longitudinal incisions are advisable, since the transverse, or any modification thereof, may cause the needless sacrifice of important structures.

The Results.—Ten per cent die after excision for disease, and fifteen per cent after excision for gunshot injuries without antiseptic treatment. In

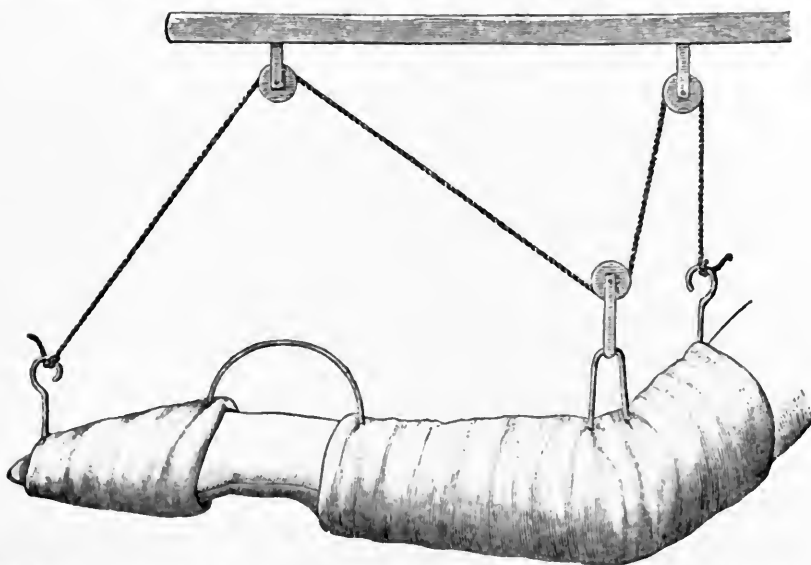


FIG. 421.—Bracketed suspended plaster-of-Paris splint for excision of the wrist joint.

about thirty-three per cent of those who recover the operation is of little or no service, in about eleven per cent entirely satisfactory, in the remainder of an indifferent outcome. Usefulness is better when done for injury than for disease. Of 178 cases under asepsis for various causes, 3 died.

Excision of the Metacarpo-phalangeal Joints.—These joints can readily be excised by making an incision about one inch and a half in length along the dorsum of the bones composing the joint at one side of the extensor tendon. The tissues in contact with the bone are carefully raised and turned aside, the joint exposed, and the requisite amount of bone removed by the chain or Gigli-Haertel saw, or bone-cutting forceps.

The Comments.—The excision of these joints should not be practiced in the young, as the epiphyseal tissues are thus destroyed and a digit of questionable utility soon becomes an absolute disfigurement. Even in adults they are often a source of greater inconvenience than of service. However, on account of its functional importance, these statements do not apply with equal force to the thumb. The operation is commended here, especially when the proximal epiphysis can be preserved.

Excision of the Phalangeal Joints.—These articulations may be approached either through a longitudinal incision made along the side of the joint or by a curved incision at the same situation with the convexity downward. In either instance separate the tissues carefully down to the extremities of the bones, which when properly exposed can be caused to protrude through the incision by lateral flexion and the extremities can then be removed. A terminal phalanx is best excised by means of a U-shaped palmar incision, leaving if possible the base of the bone so as to preserve the attachments of the flexor and extensor tendons.

The Remarks.—Excision of interphalangeal joints offers a fair outlook for symmetry and usefulness, especially if practiced after epiphyseal union has taken place. The removal of an entire metacarpal bone, even subperiosteally, is not followed by pleasing success, except perhaps when associated with already established bone production dependent on periostitis. The removal of small portions of the shafts is followed with satisfactory outcome in the majority of instances.

The after-treatment consists in placing the fingers in an immovable position properly protected by an antiseptic dressing, and when repair begins passive motion is made and continued until the recovery is complete.

EXCISIONS OF THE LOWER EXTREMITIES.

The principles of action governing excisions of the bones of the hand apply with equal force to excisions of the bones of the foot. The importance of the great toe especially, and of the other osseous structures of the anterior part of the inner arch of the foot in locomotion, gives to them and the operations directed to their relief a specific significance. The phalanges and metatarsal bones of the other toes are also invested with cosmetic and mechanical importance, and the former importance exceeds in degree that of the latter in the order of their location from within outward. The proximal interphalangeal joint of the second toe and the metacarpo-phalangeal of the third are removed for the cure of hammer-toe and of metatarsalgia respectively.

The Phalangeal Joints of the Tarsus are removed in a manner similar to those of the upper extremity.

A Metatarso-phalangeal Joint is removed through a longitudinal incision made over the dorsal surface of the bones constituting the joint, at the inner or outer aspect of the extensor tendon, which is pushed aside together with the remaining surrounding soft parts; the ends of the bones are then exposed, and severed by the chain or Gigli-Haertel saw, or the bone forceps. *The metatarso-phalangeal articulation of the great toe* is excised often through a U-shaped incision made at the inner side of the joint, with the convexity downward, the center corresponding to the middle of the joint, and of sufficient length to freely expose the portions of the bones to be removed (Fig. 422, *a*, U-shaped incision). Dissect the soft parts from the bones, carefully pushing aside the tendons; expose and remove the necessary amount of the articulation with a saw or forceps. If the operation be done for the correction of the deformity caused by prominence of the head of the metatarsal bone (hallux valgus), enough should be removed to permit the

easy return of the displaced toe to its natural position, where it is retained quietly till repair is well advanced, when passive motion is commenced.

The Tarso-metatarsal Joints can be excised through a straight incision or by raising a semilunar flap over their dorsal surfaces, avoiding division of the extensor tendons which are raised and pushed aside, while

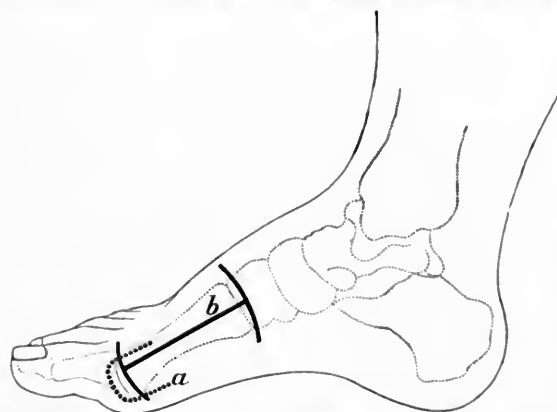


FIG. 422.—Lines of incision for removal of head (*a*) and entire bone (*b*).

the dorsal ligaments connecting the bones are divided and the joint cavity exposed by forced flexion, after which the bones of the distal row can be divided with a saw or bone forceps. The corresponding extremities of the tarsal bones can then be treated likewise.

The Remarks.—This joint of the great toe is removed best in the manner already indicated (Fig. 422, *a*). However, as in the other toes, it can be removed through a straight incision. The metatarsal bone of the great toe can be removed through an incision extending its entire length, connected at each end with short vertical incisions (Fig. 422, *b*), or through a flap of similar length as the preceding incision, turned up from below so as to secure good drainage and locate the sear in an unexposed position (Fig. 428, *b*).

Operations on the Tarsal Joints.—When separate tarsal joints become involved by disease or the effects of traumatic violence they can be removed by making an incision over the injured or diseased portions, often following the line of the seat of violence or in the track of sinuses leading to the disease.

This treatment is, however, better adapted to those joints having a limited synovial membrane than to those where the membrane extends between

several contiguous bone surfaces. In the latter case it is often better to remove the bones entire by aid of the chisel, saw, or gouge. In either instance curved incisions are preferable, provided they do not divide important tendons and vessels (Fig. 423).

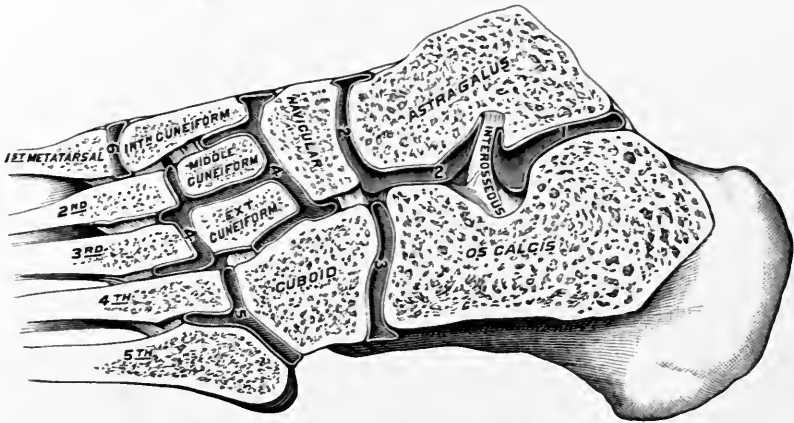


FIG. 423.—Section of bones and synovial membranes of the tarsus.

Excision of the Calcaneum.—It is necessary that as much as possible of this bone be saved, as it forms through important ligaments the posterior pillar of the arch of the foot and also gives attachment to the tendo Achillis which exerts a powerful influence in locomotion. A knowledge of the periods of ossification of the centers of this bone is important indeed in young subjects, and emphasizes the wisdom of being conservative and careful. When *gouging* fails to remove the diseased bone excision becomes the final resort.

The Operation.—A horseshoe-shaped incision is begun a little in front of the calcaneo-cuboid articulation and carried backward along the side of the foot around the base of the os calcis to a corresponding point on the opposite aspect. This flap, with the knife hugging the bone, is dissected up, exposing the entire under surface of the os calcis (Fig. 424, excision of os calcis). A second perpendicular incision about two inches in length is then made through the middle of the tendo Achillis down to the preceding one. The

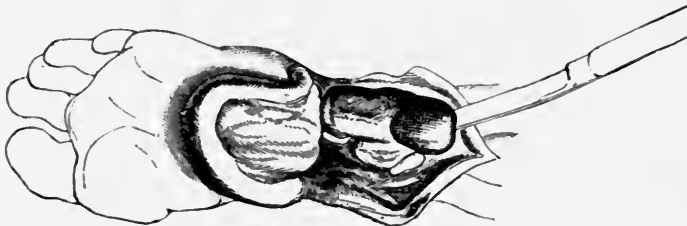

FIG. 424.—Excision of os calcis.

resulting flaps are dissected off close to the bone, the articulation between the calcaneum and the astragalus is opened posteriorly, the ligamentous connections are severed, together with those between the calcaneum and the

other contiguous bones, the os calcis is taken away, and any additional diseased bone removed.

Since the preceding incision is greater than is required to remove the bone, *Forabeuf* advised that the incision cease at a point about an inch and a half to the inner side of the median line of the foot and be met at the outer side by a vertical one two inches long located in front of and parallel with the tendo Achillis (Fig. 425, c). The vertical incision is carried down

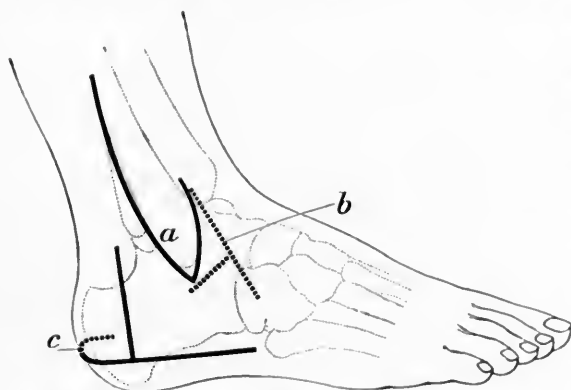


FIG. 425.—a. Excision of ankle joint (outer incision). b. Excision of astragalus (outer incision). c. Excision of os calcis.

to the bone, and the periosteum along with the superimposed soft parts and tendinous insertions carefully separated in the usual manner. After exposure of the under surface, the bone is grasped at the anterior part with bone forceps, depressed, denuded of ligaments all around, and removed carefully, avoiding injury of the peronei tendons.

The Remarks.—The direct relation which this bone bears to the posterior

portion of the arch of the foot, and the attachment which it affords to important ligaments concerned in the maintenance of the arch, invests the bone with great importance in walking.

The Results.—About sixty-five per cent of these cases recover with useful limbs; about one in twenty die from operation, with asepsis much less.

Excision of the Astragalus.—Removal of the astragalus can be accomplished through incisions of various forms, as the *oval*, *single*, *double*, *vertical*, etc.

The Anatomical Points.—The relation of the tuberosity of the scaphoid bone to the head of the astragalus must be carefully observed, as it is a certain guide to the articulation just behind it, a matter of obvious importance. The interosseous ligament and its characteristics should be carefully noted before operation.

The operation by the oval incision is the oldest method, and is objectionable because of the great degree of disturbance it causes to the tendons on the dorsum of the foot. In this incision the tendons are either drawn aside or divided. If the latter, the ends are united after completion of the operation. The oval flap extends between the malleoli on the dorsum of the foot with the convexity downward. The tendons of the extensor muscles are carefully pushed aside, the ligamentous connections of the bone with the tibia, fibula, and os calcis are severed, and finally those with the scaphoid as well. The foot is then extended, the bone removed from its site, and the calcaneum placed in the resulting gap between the malleoli.

The Operation by the Double Incision (Outer and Inner).—The outer incision begins in front of the external malleolus, on a line with the articular cartilage of the tibia, and extends downward and forward parallel with the outer border of the tendon of the peroneus tertius two and a half inches. A second is made at a right angle to the preceding, passing from the center of the same downward and backward, and terminating a little below the tip of the malleolus (Fig. 425, b). The inner incision begins just below the tip of the inner malleolus and is carried in a curved manner upward in front of the anterior margin of the malleolus (Fig. 428, c). Through the outer incisions the ligamentous connections of the astragalus with the fibula, tibia, scaphoid, and os calcis are carefully divided, and through the inner one the remaining ligamentous attachments of the bone are severed. The astragalus is removed through the anterior incision with lion-jaw forceps. The flaps are united, the wound is drained, and the foot confined at right angles with the leg by a fenestrated plaster-of-Paris splint. The operation by a single incision at either side can not be advised on account of the limited room and the resulting increase in the injury of the tissues.

The Results.—About seventy-five per cent of these cases recover with useful limbs.

Excision of the Ankle Joint.—Excision of the ankle joint is now less frequently performed than formerly. The uncertainty of the result of the operation and of the final usefulness of the limb, together with the established utility of prosthetic appliances after ankle-joint amputation, have almost eliminated the operation from the practice of many, especially for the removal of diseased bone. In the instances of complicated fracture and of compound dislocation, the outlook is more promising, particularly when practiced with antiseptic care. The ankle joint is a hinge joint and has no lateral movement except when the foot is well extended, which even then is very limited. The relation of the epiphyseal centers to the long bones, their periods of union, the arrangement of the ligaments of the ankle

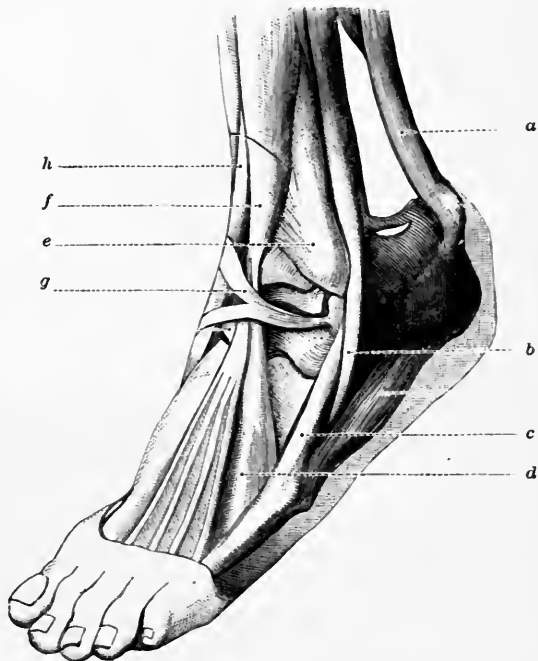


FIG. 426.—Outer side of ankle. *a.* Tendo Achillis. *b.* Peroneus longus. *c.* Peroneus brevis. *d.* Peroneus tertius. *e.* External malleolus. *f.* Extensor longus digitorum. *g.* Crucial ligament. *h.* Extensor longus pollicis.

especially for the removal of diseased bone. In the instances of complicated fracture and of compound dislocation, the outlook is more promising, particularly when practiced with antiseptic care. The ankle joint is a hinge joint and has no lateral movement except when the foot is well extended, which even then is very limited. The relation of the epiphyseal centers to the long bones, their periods of union, the arrangement of the ligaments of the ankle

joint and its synovial membranes, are matters of special importance in excision. The landmarks of the joint are stated under the consideration of amputations at the ankle (page 509 *et seq.*). The indications calling for the operation are numerous and should be well considered before it is attempted. As in all of these operations, those incisions which best preserve the tendons, vessels, nerves, and periosteum should be practiced, consequently longitudinal incisions are the ones that should be employed.

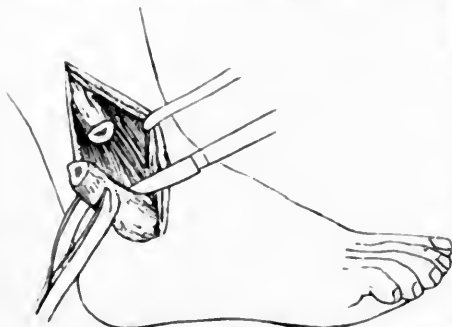


FIG. 427.—Removing lower end of fibula.

The Operation of Subperiosteal Excision of the Ankle Joint (Langenbeck).—Make an incision about three inches in length along the posterior border of the lower extremity of the fibula down to the bone (Fig. 425, *a*), carrying it forward in a hooked shape around the lower end and then upward along the anterior border about an inch. The periosteum is reflected from the bone together with the tissues in contact with it, thereby exposing the lower extremity of the fibula without opening the tendinous grooves of the peronei muscles (Fig. 426). The fibula is then divided at the upper end of the incision with a narrow saw, the lower fragment is pulled outward, its ligamentous attachments are severed (Fig. 427), and the bone is removed. A semicircular incision is then made about an inch and a half in length down to the bone, around the lower end of the inner malleolus (Fig. 428, *a*). A third and vertical one is next made about two inches in length down to the bone through the center of the internal malleolus, connecting below with the semicircular one.

The triangular flaps, including the periosteum, are turned aside with the elevator, using care to raise the sheaths of all associated tendons from their grooves and push them aside; the tibia is then divided at the upper end of the cut with a saw, the fragment is pulled outward with the forceps, freed from the interosseous membrane, and removed (Fig. 429). If it is necessary to remove a part or the whole of the astragalus it can be done through either incision; the better, however, through the internal one on account of the greater amount of room.

The tibia is then divided at the upper end of the cut with a saw, the fragment is pulled outward with the forceps, freed from the interosseous membrane, and removed (Fig. 429). If it is necessary to remove a part or the whole of the astragalus it can be done through either incision; the better, however, through the internal one on account of the greater amount of room.

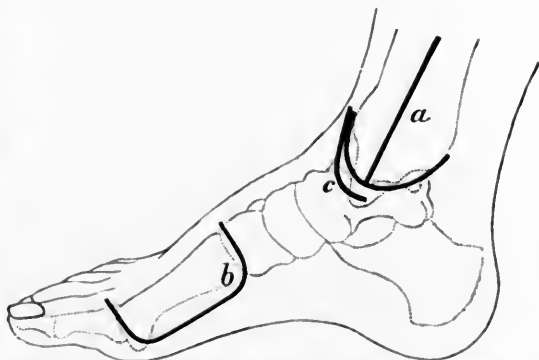


FIG. 428.—*a.* Excision of ankle joint (inner incision). *b.* Excision of metatarsal bone of great toe. *c.* Excision of astragalus (inner incision).

If it is necessary to remove a part or the whole of the astragalus it can be done through either incision; the better, however, through the internal one on account of the greater amount of room.

Vogt recommends, when excision is performed for chronic disease of the ankle and the contiguous joints, with the view of getting a more extended insight into the diseased portions, that an incision be made anteriorly, midway between the tibia and fibula, beginning about two inches above the articulation of the ankle and extending downward on the dorsal surface of the foot to the medio-tarsal joint. The long extensor tendons are carefully drawn to the inner side, the tendons of the short extensor are divided and drawn to the outer side, the blood vessels carefully tied between two ligatures and divided, and the capsule of the joint is opened by a vertical incision; the anterior ligament is then detached and the head and neck of the astragalus is exposed. If the superior astragalo-scaphoid ligament be divided, the anterior and inner surfaces of this bone will be the better exposed. A transverse incision is now made at right angles to the primary one, extending outward to the tip of the external malleolus, leaving the

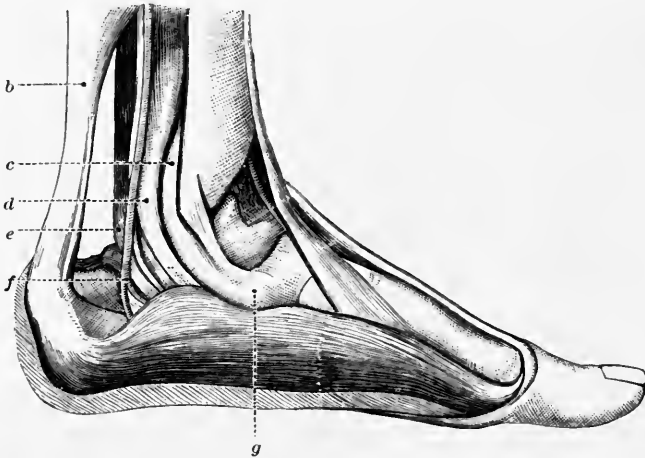


FIG. 429.—Inner side of ankle joint. *a.* Tibialis anticus muscle. *b.* Tendo Achillis. *c.* Tibialis posticus muscle. *d.* Flexor longus digitorum. *e.* Flexor longus pollicis. *f.* Posterior tibial artery. *g.* Tuberosity of scaphoid bone.

tendons intact: Divide the three fasciculi of the external lateral ligament close to the malleolus, and cut the interosseous and internal calcaneo-astragaloid ligaments; force the articular surface of the astragalus outward; seize the bone with lion-jaw forceps, separate its remaining connections, and remove it. All diseased portions can now be easily examined and removed with a minimum degree of disturbance of the healthy tissues.

*The Operation of Non-subperiosteal Excision of the Ankle Joint (Busch).—*An incision is made down to the bone, from one malleolus to the other, across the sole of the foot. The sides of the joint are exposed by drawing the tissues forward. The os calcis is sawed through from below upward and forward to the anterior margin of the calcaneo-astragaloid articulation and pulled backward after the division of the opposing ligamentous structures. The entire astragalus can now be removed through the opening and also the lower extremities of the tibia and fibula.

After the removal of the dead bone and the establishment of good drainage the fragments of the os calcis are placed in position and held there by silver wire. The wound should be dressed antiseptically and no weight allowed upon the foot until the tissues are firmly united.

The Comments.—This method is a very ingenious one, as it permits removal of the diseased joint without impairing the tendons or their sheaths. It is open to the objection, however, of weakening the arch of the foot on account of the division of the long calcaneo-cuboid ligament and the plantar fascia. The fact remains therefore that the method of subperiosteal excision is especially adapted to the anatomical construction of this joint on account of the subcutaneous location of the lower ends of the tibia and fibula; and the excellent results that sometimes follow are dependent also on the greater security of the tendons and ligaments in this method.

The after-treatment for excision of the ankle joint consists in applying an immovable dressing around the joint under antiseptic precautions. This

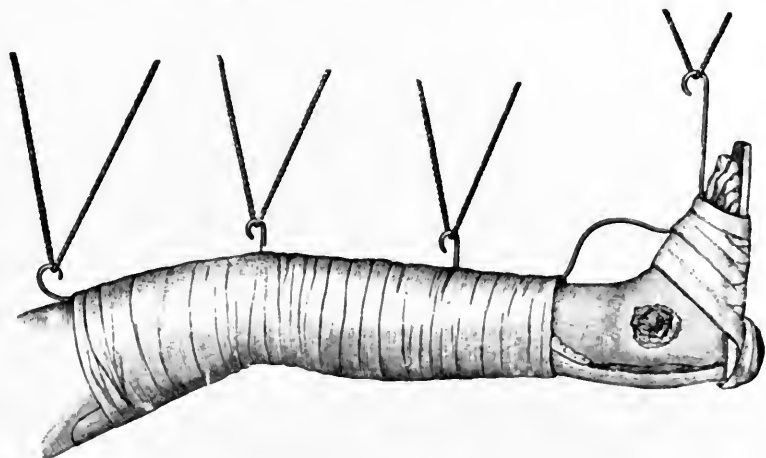


FIG. 430.—Bracketed suspended plaster-of-Paris splint for excision of ankle joint.

dressing may be of plaster of Paris, suspended or not as seems desirable. The indications of cleanliness, extension, and preservation of the foot in the proper axis of the limb and the securing of sound ankylosis should be kept in constant view by the surgeon. Not infrequently after subperiosteal operations a satisfactory degree of motion at the ankle joint is secured. The mobility of healthy contiguous joints contributes much to this satisfactory outcome. Later the ingenuity of the maker of orthopaedic appliances may add much to the serviceableness of the limb.

The Results.—Excisions of the ankle joint done before asepsis resulted as follows: Of 459 cases done for disease, 15.8 per cent died, and of 87 cases done for gunshot wounds, the mortality was 26.6 per cent. Of 114 cases done under asepsis for all causes, 2.5 per cent died.

The prognosis for life is most favorable between one and fifteen years of age; most unfavorable between thirty and forty years. A large proportion

of the recoveries from this operation results in a more or less serviceable limb; about nine per cent are useless.

Osteoplastic Resection of the Tarsus (Wladimirow-Mikulicz).—This operation is sometimes practiced instead of amputation for relief from extensive disease and injury of the tarsal bones and for paralytic talipes.

The Operation.—Beginning about half an inch behind the tuberosity of the fifth metatarsal bone, make a transverse incision down to the bone across the sole of the foot to a point immediately in front of the tuberosity of the scaphoid. Make an incision down to the bone at either side of the foot from each end of the transverse one upward and backward to the posterior borders of the respective malleoli. Unite the upper ends of these incisions by a posterior transverse one and divide the tendo Achillis; flex the foot sharply; open the ankle joint from behind; sever the lateral ligaments; enucleate and remove the astragalus and os calcis; saw thin disks

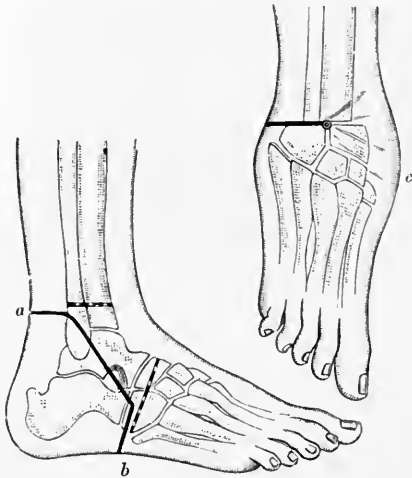


FIG. 431.—Wladimirow-Mikulicz's osteoplastic resection of the tarsus. *a.* Incision through the soft parts. *b.* Division of the bone. *c.* Position of the foot after the operation.

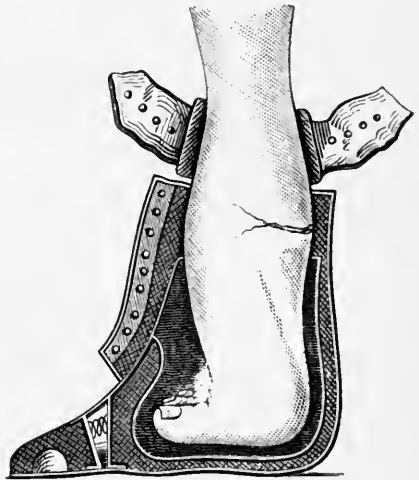


FIG. 432.—Result after osteoplastic resection.

of bone from the exposed extremities of the tibia and fibula, and from the exposed surfaces of the scaphoid and cuboid bones; divide subcutaneously the flexor tendons of the toes so that the latter may be extended to a right angle with the dorsum of the foot; bring in contact and fasten together the sawed bony surfaces with sutures, and close the wound of the soft parts (Fig. 431, *c*). The extremity is then dressed and confined by means of a plaster-of-Paris splint until healing is completed, after which it is fitted with a suitably constructed shoe (Fig. 432).

The Comments.—*Berger*, in order to preserve the integrity of the posterior tibial artery and nerve, approached the ankle joint through a T-shaped incision made at the outer side. The present high degree of usefulness and comfort secured by prosthetic appliances lessens decidedly the utility of such methods of practice.

The Results.—In nineteen operations, of which thirteen were for tubercular caries, two died of general tuberculosis eight months afterward; twelve made a good recovery, and walked with more or less ease; in five, failure followed, three of which required amputation.

Excision of the Bones of the Leg.—If it be desired to remove by excision or otherwise portions of either of the bones of the leg, the location and extent of the incision is governed by the situation and extent of the injury or disease of the bone. The bone should, however, be reached by the shortest practicable course, which usually is *between* the individual muscles rather than through their structures. After removal of the bone, which should always be subperiosteal, the limb is confined so as to permit the new structure when completed to fulfill the functions of its predecessor. Therefore the patient must not be permitted to bear weight on the limb till the new bone becomes firm, else distortion or fracture will occur.

The Precautions.—Careful avoidance of involvement of the knee joint and of injury to the anterior tibial and musculo-cutaneous nerves and the tendon of the biceps should be observed in dealing with the head of the fibula.

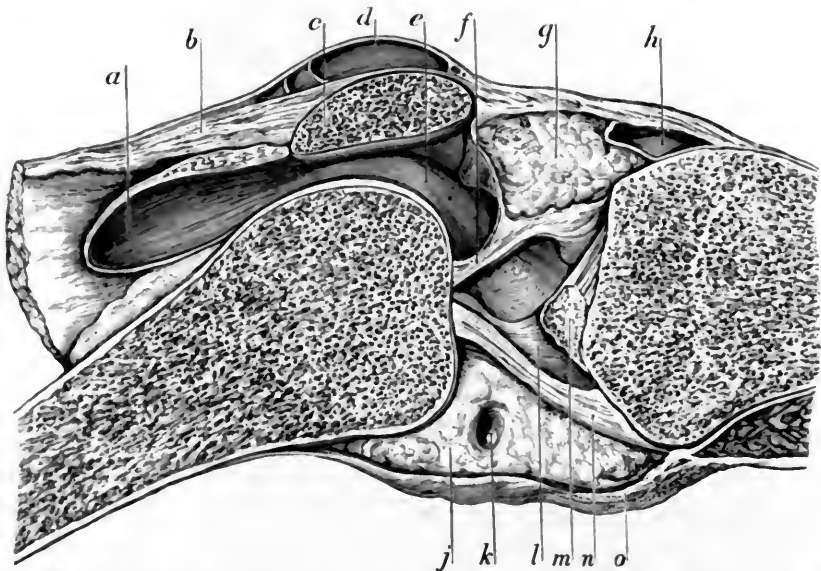


FIG. 433.—Longitudinal section of the knee joint. *a.* Upper extremity of synovial sac. *b.* Tendon of the quadriceps extensors. *c.* Patella. *d.* Pre-patellar bursa. *e.* Inner condyle of femur. *f.* Ligamentum inuicosum. *g.* Fatty tissue between ligamentum patellae and synovial sac. *h.* Bursa beneath ligamentum patella. *j.* Fatty tissue. *k.* Opening in synovial membrane behind crucial ligament leading into inner half of joint. *l.* Synovial membrane reflected from crucial ligaments. *m.* End of anterior crucial ligament. *n.* Posterior crucial ligament. *o.* Ligamentum posticum Winslowii.

Excision of the Knee Joint.—The knee joint can be excised with comparative safety to the patient and with a fair prospect of recovery with a useful limb. As in the preceding, the nature of the cause demanding the operation exercises a marked influence on the result.

The Anatomical Points.—Much is said regarding these points in connection with amputations. Still, it will not be amiss to remind the reader that the popliteal artery is closely associated with the ligamentum posticum Winslowii which separates that vessel from the joint cavity (Fig. 196, f). If ordinary care be exercised there is but little danger indeed of injury to this vessel unless there be extensive disease and

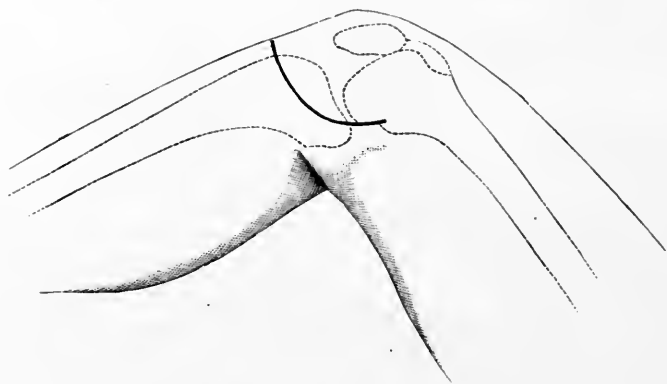


FIG. 434.—Mackenzie's anterior curved incision.

deformity of the ligament, when the vessel may be nicked in the removal of the diseased tissue in spite of great caution, as has once happened in the practice of the author. When it is necessary to remove diseased tissue at this situation the presence of pulsation of the popliteal artery will be of inestimable aid, and therefore the circulation of the vessel should be unhindered at that time. The articular arteries should be avoided if possible, for their division causes free hæmorrhage. The superior ones pass above the respective condyles of the femur; the inferior internal pass below the inner tuberosity of the tibia and *beneath* the internal lateral ligament; the external just above the head of the fibula and *beneath* the external lateral ligament. The synovial membrane of this joint is extensive and replete with small pockets, which may interfere with proper drainage and the removal of diseased processes. The bursa of the popliteus muscle communicates with the joint and not infrequently with the superior tibio-fibular articulation at the same time, therefore an unguarded interference with this articulation exposes the general cavity to the danger of inflammatory involvement. The synovial elongation upward beneath the tendon of the quadriceps is well exhibited in the illustration (Fig. 433). The relation of this extension to a similar and subsidiary bursa above is explained sufficiently in connection with amputation at the knee joint (page 524). With the leg extended this elongation ascends beneath the quadriceps to its highest point, but when the leg is completely flexed it reaches scarcely above the anterior limit of the articular cartilage of the femur. Therefore the leg should be flexed to avoid opening the joint in incisions made at the lower and anterior aspect of the thigh. The lines of epiphyseal junction of the femur and tibia at the knee should be located carefully in the young before excision, so that, if possible, they may

be left undisturbed and contribute still further to the growth of the bone. In a child of eight years of age, no more than two fifths of an inch can be

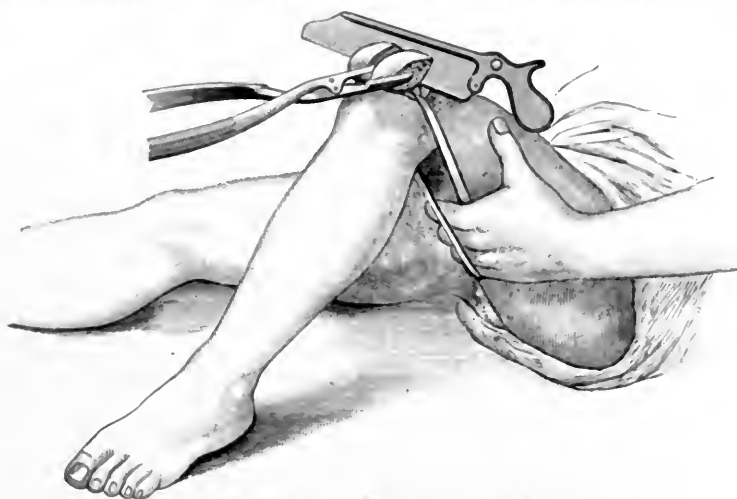


FIG. 435.—Sawing off lower end of femur.

removed from the tibia, nor more than three fifths from the femur, without invading the epiphyseal cartilage. At puberty three fifths of an inch can be removed from each. Very often, indeed, disease of the epiphyseal structure modifies or destroys the power of subsequent development, and inevitable deformity follows. If the leg be slightly flexed, or the joint cavity distended, the apex of the patella corresponds to the articular line of the joint.

There are *two well-known methods of excision* of this joint: 1, the non-subperiosteal, or ordinary; and 2, the subperiosteal method. The former is employed only when the tissues are too extensively destroyed or diseased to admit of the saving of the periosteum.

*The Operation of Non-subperiosteal Excision of the Knee Joint (Mackenzie).—*Flex the leg to a right angle and make a curved incision from the posterior border and upper portion of the inner condyle around to a corresponding point on the outer, with the convexity downward and extending to the insertion of the ligamentum patellæ (Fig. 434). This incision divides the tissues down to and opens the anterior portion of the capsular ligament. The limb should now be still more strongly flexed, the flap turned upward, and the lateral and crucial ligaments divided. A retractor is then passed between the ligamentum posticum Winslowii and the posterior surface of the condyles of

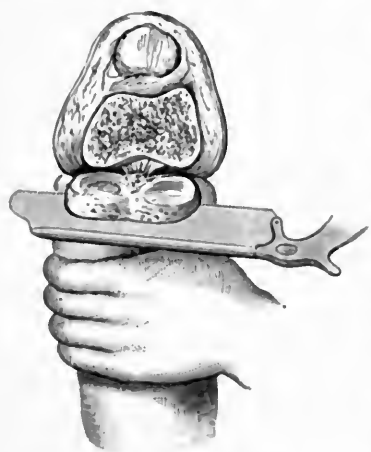

FIG. 434.—Sawing off upper end of tibia.

the femur, the lower end of the femur bone pushed forward and cut off on a

plane at right angles with the long axis of the bone (Fig. 435) and parallel with that of the distal surface of the condyle, provided the extent of the disease will admit. The head of the tibia is then exposed, pushed forward,

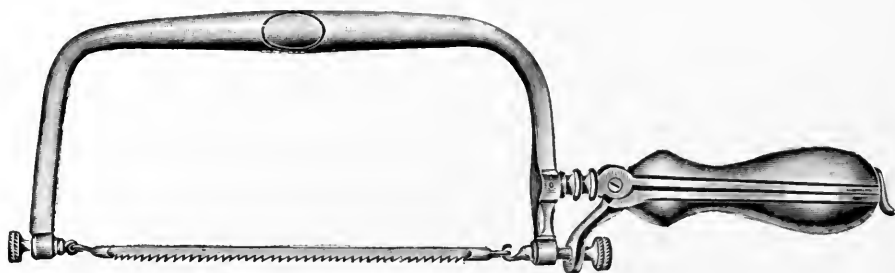


FIG. 437.—Szymanowski's saw.

and sawed in the same manner with similar care, being careful to avoid the articulation of the fibula (Fig. 436). The peculiarity of the saw devised by Szymanowski (Fig. 437 and page 364) makes it useful in sawing these and other bones of large size.

In this operation it is better to remove the patella, since its means of attachment (the ligamentum patellæ) has been severed. All inflamed or degenerated synovial membrane should be dissected away; sinus tissues, too, should be thoroughly removed.

The wound is then wiped or flushed with a hot aseptic solution, and drainage established from side to side behind the bones, the divided ends of the bone are wired or pegged together, the soft parts sutured, the whole limb is enveloped in antiseptic dressing, and immovably fixed in properly suspended bracketed plaster or a wire cradle splint.

The Operation of Excision by a Transverse Incision (Bird).—Ascertain the line of junction of the articulation with the limb extended, if the condition of the joint will permit; make a transverse incision from one condyle directly across to the other, passing over the middle of the patella or its apex (Fig. 438); if the former, saw the patella through in the line of the incision, remove the fragments, after which the

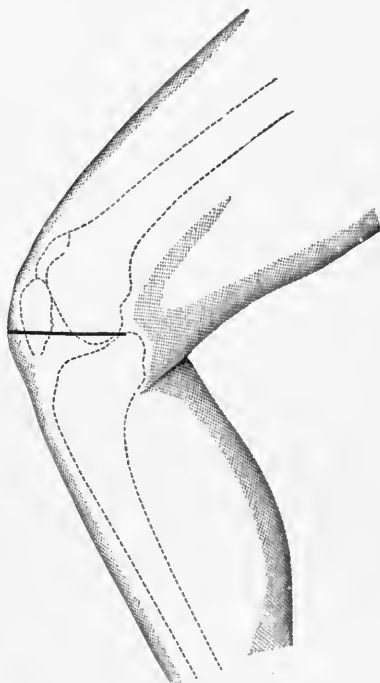


FIG. 438.—Incision and excision of the knee.

joint surfaces are exposed and removed as in the preceding operations. This incision affords the opportunity to establish good drainage, and exposes the joint with a minimum injury of the soft parts.

The Operation of Subperiosteal Excision of the Knee Joint (Langenbeck).—Extend the limb and make a curved incision five or six inches in length on the inner side, commencing at the inner border of the rectus femoris and terminating below at the crest of the tibia. The convexity of this incision turned backward corresponds to the posterior borders of the condyle and tuberosity, and its center to the line of the articulation (Fig. 439). If the flap be now raised, the vastus internus muscle and the tendons of the adductor magnus and sartorius will be seen (Fig. 440), and should be carefully avoided. Divide the internal lateral ligament on a line with the articulation; with the periosteal elevator separate the capsular ligament together with the internal semilunar cartilage and the periosteum from the anterior and posterior surfaces of the inner condyle of the femur and the tibia out-

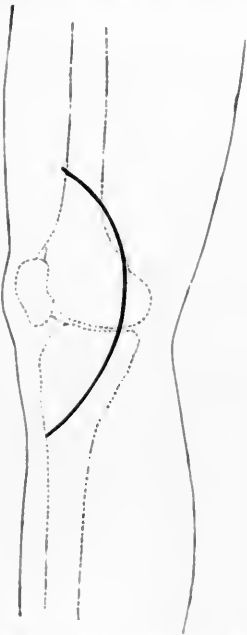


FIG. 439.—Langenbeck's incision.

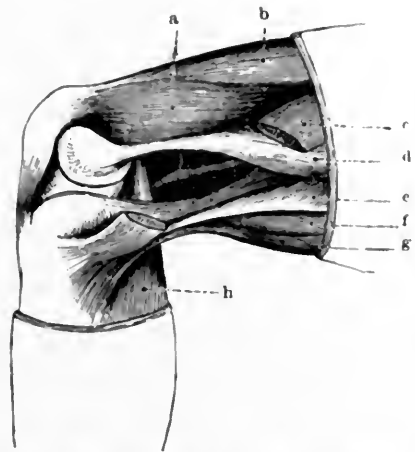


FIG. 440.—Tendons at inner side of knee joint. *a.* Vastus internus muscle. *b.* Rectus femoris muscle. *c.* Sartorius muscle. *d.* Adductor magnus muscle. *e.* Gracilis muscle. *f.* Semimembranosus muscle. *g.* Semitendinosus muscle. *h.* Gastrocnemius muscle.

ward to the median line of the bones; flex the leg, then extend it slowly, and at the same time dislocate the patella outward with the thumb applied to its inner border; divide the crucial ligaments; also divide by a semilunar incision carried a few lines below the tip of the external condyle; divide the external lateral and the adjacent portion of the capsular ligament; remove the periosteum and its associated tissues from the outer aspect of the tibia and femur, the same as at the inner side; divide the posterior portion of the capsule and force the extremities of the femur and tibia in turn through the wound, and saw them as before. The patella remains unmolested, except it be diseased, when the diseased portion is removed with a gouge, or the bone can be enucleated from the periosteal surroundings by the elevator and scalpel. A small opening should now be made at the outer

and one at the inner side of the wound posteriorly, for the purpose of establishing thorough drainage. A drainage tube can be passed through the upper synovial pouch, or firm compression can be made thereon to prevent the collection of inflammatory products within it. The surfaces are then cleansed, all hæmorrhage is arrested, the flaps are united, and the limb, surrounded by antiseptic dressing, is immovably fixed till future dressings become necessary.

The Operation of Subperiosteal Excision of the Knee Joint (Ollier).—Make an incision through the soft parts, commencing two inches above and to the outer side of the patella, carry it down to the upper and outer angle of the patella, along the outer border toward the apex and thence along to the outer side of the ligamentum patellæ as far as to its insertion (Fig. 441); denude the outer condyle of the femur of its periosteum together with the lateral and capsular ligaments and the outer head of the gastrocnemius; denude the anterior and internal surfaces of the femur; cut the crucial ligaments; displace the patella inward over the inner condyle; flex and carry the leg inward, causing the femur to protrude, when the end is isolated and sawed off. The upper end of the tibia is then denuded of its periosteum from above downward, pushed through the opening and likewise divided. If the patella be diseased, remove it, leaving its periosteum behind.

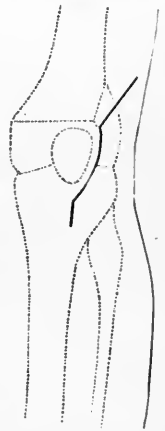

FIG. 441.—Ollier's incision.

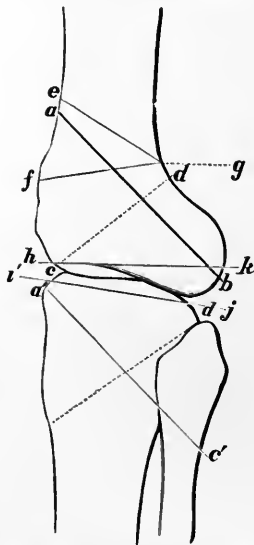


FIG. 442.—Saw lines in excision of the knee joint.

The Remarks.—In sawing through the exposed extremity of either bone, the line of incision may be made to include the whole of the diseased osseous tissue. If, however, carious bone or an abscess cavity extend in an isolated manner into the sawed extremity of the femur or tibia, it can be scooped out, and the resulting cavity drained by making an opening with a bone drill through the bottom and continuing it to the external surface, thereby saving the surrounding healthy bone tissue and thus contributing to the length of the limb. Deeply congested cancellous bone tissue should be preserved, especially if its removal will impair the epiphyseal cartilage (Fig. 443). Such diseased bone makes a good recovery, and contributes to the preservation of the growth of the femur. The lines of section of the sawed surfaces of the bones must be parallel with each other with the leg in the straight position (Fig. 442, *a b, a' c'*), otherwise their union will cause an angular deformity. This fact applies more particularly to those cases where anky-

losis in the straight position is sought. If for any reason it be thought better to ankylose the limb with slight flexion, then the thicker portions should be taken from the posterior parts of the bones (*h k, i j*).

The limb should be firmly fixed, with the bone surfaces suitably in contact with each other, before the wounds of the soft parts are closed. If any diseased tissue remains it may produce a general infection of the wound, and, even if not causing a fatal issue, its non-removal would be followed by delayed and unsatis-

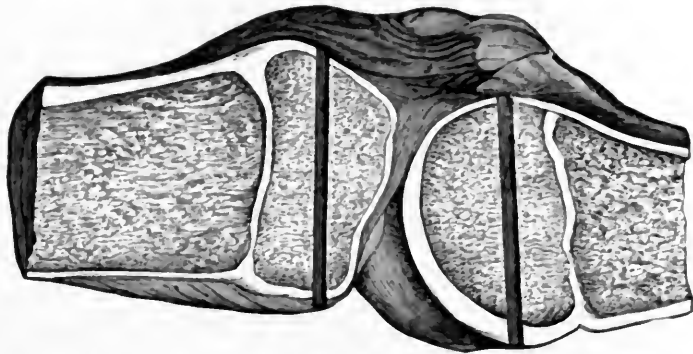


FIG. 443.—Epiphyseal cartilage and line of section in excision of knee joint.

factory recovery. Therefore, the synovial pouches and sawed surfaces should be carefully inspected for the presence of objectionable morbid products.

If the limb be ankylosed in a flexed position, it should be corrected as much as possible by Buck's extension before operation, to lessen the otherwise needless sacrifice of bone, and obviate undue stretching of the popliteal tissues incident to correction at the time of operation, and the common sequel in such cases—backward displacement of the head of the tibia. The use of the elastic bandage in excision of this joint enables one to distinguish the presence of disease of the synovial and osseous structures better than without it, and to complete the dressing of the part without the presence of bleeding, if such a course be advisable. Certainly the latter procedure should not be practiced unless competent surgical skill be at immediate call. It is far better and more secure to arrest all bleeding before closing and dressing the wound. Since diseased synovial membrane should be carefully dissected away before the wound is closed, the anterior pouch should be cautiously explored for this reason. In all forms of excision of this joint, care must be taken to prevent the soft parts posterior to the bones from being caught between their sawed surfaces, since this occurrence will hinder union by preventing a proper contact of the surfaces. If the two wire sutures be carried from in front through to the posterior borders of the bones, and united at the anterior surface, this accident can not occur, neither will it happen if the surfaces be placed in contact and confined there by muscular contraction or a closely fitting splint. The fixation of the bones by metallic sutures and needles, bone pegs, etc., is open to the objection that it may be necessary later to remove them for relief of the irritation which their presence provokes. Pegs driven from without through the integument and bone in opposite directions, so as to hold firmly together the sawed surfaces, as practiced by Barker, Wyeth and others, are efficient in many cases. However, if the apposed surfaces can be firmly held in

position with apparatus, the use of these devices can be properly omitted. If the patella be permitted to remain, its severed ligament may be united by suturing, or, if the bone have been sawed across, the bony fragments may be united by strong catgut or silver wire. It is thought, in cases of imperfect union of the tibia and femur, that the presence of the patella gives greater stability to the limb (Fig. 444).

The idea of confining the sawed surfaces (König) to each other by nailing the attached portion of the bisected patella to properly sawed surfaces of the femur and tibia is certainly ingenious, and in favorable cases can be employed. If successful, it will offer a strong obstacle to backward displacement of the tibia. In fifteen cases of excision the wire was employed by the author, and in five nothing but the splint was used for this purpose; the results, so far as union was concerned, were equally satisfactory. The wire caused trouble in only three instances; in one, a necrosis along its course, in the remaining two a local irritation due to pressure, which was promptly relieved by removal of the wires.

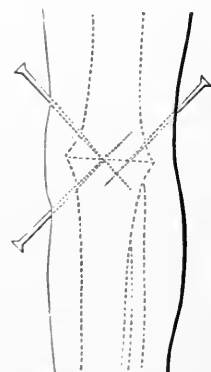


FIG. 444.—The arrangement of nails in resection of knee joint.

After-treatment.—The wire cradle splint and the fenestrated plaster-of-Paris splint confining the entire extremity, and properly swung with elastic bandages, were employed consecutively or singly in each of the author's cases (Fig. 445). After the soft parts are united the application of a plaster-of-Paris spica, as in fracture of the thigh, and out-of-door exercise on crutches are very important measures of treatment. That strict antisepsis and good drainage are essential needs no remark.

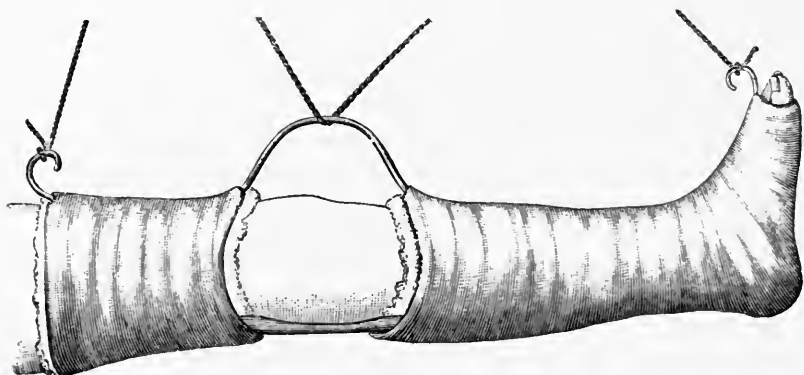


FIG. 445.—Suspended bracketed plaster-of-Paris splint.

The Results.—Of 1,063 cases of excision of the knee joint for all causes, performed during the preaseptic period, the mortality was 22 per cent; of 580 cases done for disease, and under antiseptic precautions, 8.24 per cent died. In the author's 24 adult cases for disease, 2 died (8.3 per cent), one expectedly, the remainder recovered with serviceable limbs.

The age of the patient is a consideration not to be underestimated; the results are best from five to ten years of age, whether the operation is for injury or disease.

When done for disease, fourteen per cent of the results were perfect, forty-two were useful, and the remaining useless; of which latter eighteen per cent required amputation.

For injuries, about eighteen per cent were perfect, about sixty-five per cent useful, and in about twelve per cent amputation was performed.

When for gunshot injuries, about sixty per cent were useful and twenty-four per cent required amputation, the remaining not accounted for.

When done for deformity, nineteen and a half per cent of the results were perfect, and about sixty-eight per cent of the patients had useful limbs; the remainder not reported.

It appears that the degree of usefulness does not depend upon the amount of bone removed.

The removal of the patella seemed to increase the degree of usefulness of the limb. In excision of the knee joint for all causes, before the growth of the patient is completed, great care should be taken to preserve intact, if possible, the epiphyseal cartilages, especially that of the lower end of the femur (Fig. 444). This precaution markedly lessens thereafter the liability to failure of development of the length of the femur upon the diseased side, because this epiphyseal junction provides normally for much more than its proportionate share of the growth in length of the bone.

Arthrectomy.—Arthrectomy, sometimes called *erosion*, is a conservative operation employed to remedy disease of a joint—usually the knee—in lieu of the more formidable procedure of excision. It is applicable especially to cases in which the disease of the joint structures is not extensive, nor of a tuberculous or suppurative nature, and displacement is not yet present. The conservatism of this method is shown in the young, since the epiphyseal structure need not be impaired by the measure. Such instruments as curved scissors, mouse-tooth forceps, surgical spoons and gouges, are required here in addition to the commoner implements of operation.

The Operation of Arthrectomy.—The preparation and position of the patient, the extent of the incision, and the exposure of the joint cavity, are similar to the steps in excision. All diseased serous, ligamentous, cartilaginous and bony tissues are removed with scissors, scoop, and gouge, being careful to preserve especially the crucial and posterior ligaments. A careful exploration of the synovial elongations and pouches is necessary, in order to detect and remove the disease products. Isolated areas of diseased bone or cartilage should be cautiously removed by scraping and gouging. Arrest hæmorrhage, flush the joint with a solution of aseptic fluid, drain the cavity at dependent points, unite the flaps with silkworm gut, surround the part liberally with antiseptic dressing, firmly bind in place, and confine the joint immovably as in excision.

The Results.—If successful, a firm, stiff limb of normal length is produced. At all events, the danger incurred is less than in excision, which

can, if advisable, be resorted to later on. Painstaking efforts should be made to secure a stiff limb.

Arthroctomy of the Ankle Joint (Brüns).—Make two incisions downward, one at either side of the anterior aspect of the limb, from about an inch and a half above the line of articulation to the medio-tarsal joint; separate the borders of the incisions and remove the diseased tissues from the anterior portion of the joint by the same means as at the knee. The posterior portion of the joint is then freed of diseased tissue through two vertical incisions made one at either side of the tendo Achillis. The part is then treated as after excision of the joint.

The Excision of the Patella.—Excision of the patella, independently of the tibia and femur, may be necessary on account of necrosis or injury. In such cases the deep incisions must exactly correspond in extent to the diseased bone, for if they be greater, the synovial cavity may be opened. The periosteum should be raised, and the dead bone carefully removed, if possible without entering the joint. When the joint is not involved, recovery will be speedy and satisfactory if the limb be confined in the extended position till sufficient repair has taken place to warrant flexion without fracture of the new bone.

The Precautions.—With the limb straight, the apex of the patella in a healthy joint is *just below* the joint line, but with the limb slightly flexed, or with the joint distended, a puncture at the apex readily enters the joint.

The results in eleven cases, of which eight were complete, and three partial, excisions, were two deaths and nine recoveries.

Excision of the Great Trochanter.—Excision of the great trochanter is occasionally required on account of caries of that structure. A longitudinal or posteriorly curved incision is made down upon the bone, and the diseased portion removed with the usual instruments. The branches of the circumflex vessels and the capsular ligaments are to be avoided. The periosteum should be saved when possible.

Excision of the Hip Joint.—It is well before attempting this operation to give a brief survey of the important ligamentous and muscular attachments that are to be respected. The extent of this book is too limited to describe them in detail, and even to do so would hardly be in keeping with the scope of the work, therefore a standard work on anatomy should be consulted.

The Anatomical Points.—The ilio-femoral, capsular, cotyloid, and even the teres ligaments, should be carefully considered in connection with their origins and insertions, so that their attachments to the involucrum and periosteum may be maintained. When practicable those muscles which are connected with the trochanters major and minor should likewise be preserved intact, in order that their association with the new bone growth may give to the new joint, so far as possible, the normal functions of the old. It is important to note the fact that the upper border of the trochanter major is on a level with the center of the hip joint, also that the epiphyses of the upper end of the femur contribute but comparatively little to

the growth of the bone in length, which is the result almost entirely of those of the lower end.

The hip joint may be excised by two quite distinct methods of procedure: 1. *The radical method*, when no effort is made to save the periosteum, and the muscular and ligamentous attachments about the joint are freely divided. This method is applicable to malignant disease of the bone, and to injuries causing extensive comminution and laceration. 2. *The conservative method*, in which scrupulous care is exercised in the peeling off of the periosteal tissue and muscular attachments worthy of preservation. Under all circumstances the acetabulum should be closely scrutinized for the presence of dead bone, which should be removed cautiously to avoid injury to the pelvic contents by the manipulation.

The Radical Operation of Excision of the Hip Joint (White).—This operation is performed by placing the patient on the healthy side, and making a deep curved incision with a strong knife (Fig. 446), commencing at a point midway

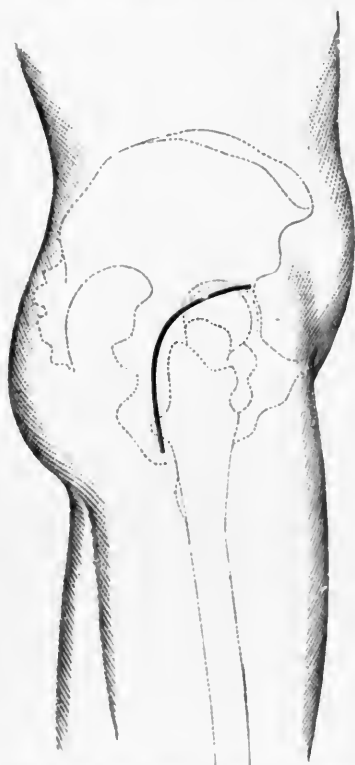

FIG. 446.—White's posterior curved incision.

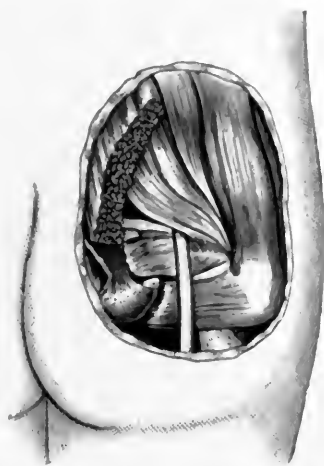


FIG. 447.—Sciatic nerve and external rotator muscles.

between the anterior superior spinous process of the ilium and the trochanter major, and passing backward around the top of the trochanter major, down its posterior border about three or four inches; then dividing the insertions of the muscles connected to the great trochanter (Fig. 447), drawing them aside with a spatula, and exposing the posterior surface of the neck of the femur and the acetabulum. The exposure will be still more complete if the femur be rotated strongly inward. If the cotyloid and capsular ligaments be now divided, and the thigh be flexed, adducted, and rotated outward, the head of the bone will be raised from the acetabulum sufficiently to admit of the

division of the ligamentum teres, when the complete escape of the head of the femur will take place. The soft parts are then protected by a spatula, and the bone, exposed to the required extent, is sawed off (Fig. 448).

A Conservative Method of Subperiosteal Excision of the Hip Joint (Langenbeck).—Place the patient on the sound side with the thigh flexed to

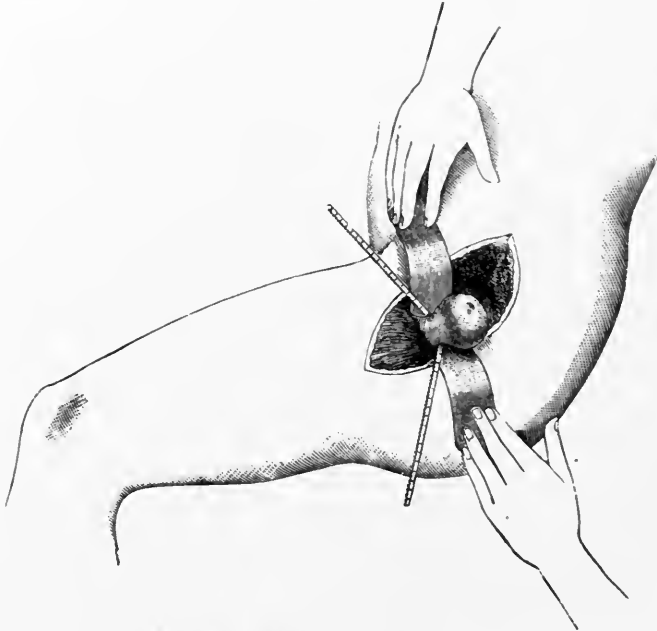


FIG. 448.—Sawing off head of femur.

an angle of 45° , and rotated slightly inward; make a straight incision five or six inches in length in the long axis of the great trochanter (Fig. 449), upward and backward toward the posterior superior spine of the ilium, passing through the fascia lata, fibers of the gluteus maximus, and periosteum of the trochanter; separate the surfaces of the wound with retractors, and with the elevator and knife raise the periosteum and the attachments of the muscles inserted into the trochanter major and the contiguous surfaces, being careful to preserve their connections with each other; next make a longitudinal incision along the neck of the femur, through the capsular ligament and the periosteum. The periosteum of the neck is then separated in connection with the attachments of the capsular ligament and the obturator externus in a careful manner. If an incision be now made through the cotyloid ligament, and the thigh be rotated outward and adducted, the head of the bone will be elevated from the floor of the acetabulum sufficiently to admit of the division of the ligamentum teres, if present, after which the head of the bone can be pushed through the opening and sawed off. All diseased products are now removed from the acetabulum with scoops, gouges, chisel and mallet, etc., and from elsewhere about the joint with proper means. After the control of hæmorrhage, the joint is flushed freely with an antiseptic solution

and drained, and the borders of the wound are united with silkworm-gut sutures.

Farabeuf, after making the initial incision, located with the finger between the pyriformis and the gluteus medius muscles, drew the muscles apart and divided the periosteum between their insertions, also the capsular ligament, and the periosteum of the neck of the bone, all in the line of the primary incision. He then exposed the trochanter major and neck by reflecting the periosteal flaps and the muscular attachments on either side backward and forward respectively; divided the periosteum of the neck of the bone at the line of the articular cartilage; and then so manipulated the thigh as to expose and clear successively the remaining aspects of the neck and trochanter, after which the bone was dislocated, and the requisite

amount removed with the saw. In other important regards *Farabeuf* adhered to the preceding method of action.

A Conservative Method of Excision of the Hip Joint (Barker).

—With the thigh fully extended make an incision at the front, beginning an inch below the anterior superior spinous process of the ilium and going downward and a little inward for three inches, so as to separate the tensor vaginae femoris and glutei muscles at the one side from the sartorius and rectus at the other, down to the neck of the bone. Divide the neck with a narrow saw in the direction of the wound; lift out the head of the bone, search for additional disease and remove it if present with the flushing gonge devised by *Barker* himself.

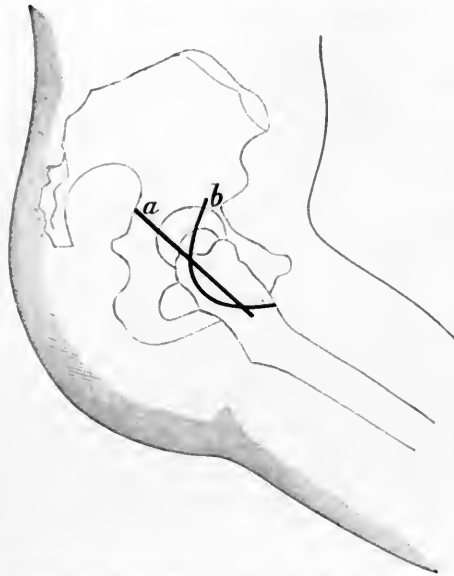


FIG. 449.—Excision of hip joint. *a.* Langenbeck's incision. *b.* Sayre's incision.

After any such disease is removed, flush and dry the cavity, place the sutures for closure of the wound, fill the wound with iodoform emulsion, and then tie the sutures, at the same time pressing out what may come of the iodoform emulsion. Drain, if essential, dust the surface with iodoform, apply antiseptic dressings with firm pressure, and confine the limb with a spica bandage so as to force the remainder of the neck of the bone into the acetabulum, where it is retained to serve the important purpose of support. During the entire removal of diseased products, the wound is flushed with hot sterilized water (110°) through the agency of the gouge, which serves the double purpose of separating the diseased tissue and washing it away simultaneously (Fig. 370, *d*). Although the natural opportunity for drainage of the wound is indeed inadequate, yet, if drainage be urgent, it can be easily provided by separation of the deep dependent structures.

In this operation the short route and the minimum degree of damage to the soft parts, and of hæmorrhage, certainly bespeak a favorable outcome in proper cases.

A Conservative Method of Excision of the Hip Joint (Sayre).—The following method of excision is that of the late Professor Lewis A. Sayre. It is subperiosteal in all essential particulars, and possesses an advantage over the one just described in that the primary incision is better suited for drainage. The following is substantially the description given by Professor Sayre. Place the patient on the sound side, with the thigh flexed, and make an incision with a strong knife down to the bone, commencing at a point midway between the anterior superior spinous process of the ilium and top of the trochanter major; carry it in a curved course upon the bone to the top of the great trochanter midway between its posterior border and center; complete it by carrying the knife forward and inward, making the length of the incision from four to six or eight inches, depending upon the size of the thigh (Fig. 449, *b*). If it be not certain that the periosteum of the trochanter have been divided by the first incision, the knife should be carried along the same line a second, and even a third time if need be. The soft parts are now drawn asunder, exposing the great trochanter, when, with a narrow, strong knife, a second incision is made through the periosteum only, at a right angle with the first, about an inch or an inch and a half below the top of the trochanter. At the junction of the periosteal incisions introduce the blade of the elevator, and carefully peel the periosteum from either side as far as possible, together with the ligamentous attachments, until the digital fossa is reached. The insertions of the rotators into the trochanter major and digital fossa are so firm that it will be impossible to peel them off; they must therefore be carefully separated by short, parallel cuts, so directed as to remove as well the periosteum with which they are blended. After the separation of the tendinous insertions, continue the elevation of the periosteum upon either side of the neck, using great care not to rupture it. Having separated the periosteum as far as can be done safely, adduct the thigh carefully, raise the head of the bone from the acetabulum, and detach the remaining portion. Adduct and depress the femur slightly, being careful not to tear the periosteum, and lift the head of the bone out far enough to admit of a division just above the trochanter minor. Care should be taken not to expose a greater surface of bone than is necessary, since necrosis would follow and hinder recovery. It is better to remove the trochanter major, even though it be not diseased, since its presence will impede the escape of discharges, and is not essential to obtaining a useful limb in cases where its periosteal covering and muscular attachments are preserved. In all cases after the operation, the wound should be well irrigated with a strong solution of carbolic acid.

The General Remarks.—The period between five and fifteen years of age is regarded as the proper one for excision. Not a little conflict of opinion exists regarding the stage of the disease best suited for operation. At the present time, however, the consensus of opinion favors the later rather than the earlier operative attacks. Whether or not the trochanter major

should be left entire or removed wholly or in part is not agreed upon by experienced authorities. When the leaving of it intact would interfere with drainage, expose to recurrent disease, or become a source of irritation thereafter, as is apt to be the case, it should be removed wholly or in part at the time of operation. When the points of insertion of muscles and ligaments are cartilaginous, a thin layer of the cartilage may be removed, leaving the attachments undisturbed. The preservation of the integrity of the periosteum is regarded as important in the prevention of infiltration into the surrounding tissues, to provide attachments for serviceable ligaments and muscles, and to furnish a basis for the reproduction of the bone, which it is hoped will take place, each of which factors will exercise an important influence in the establishment of a useful joint. However, much of the foregoing will prove fanciful when addressed to excision in adults for relief from the effects of traumatic violence, since then the separation of the periosteum will be exceedingly difficult and perhaps hazardously slow, and too often attended with a degree of mutilation that will destroy so much of the membrane as not only to defeat the purposes for which it is saved, but also to hinder subsequent repair. The saving of the periosteum in the instance of infective disease is of questionable utility, because incompleteness of removal of the infective process may be followed by a prompt return of the primary infliction. In all instances of excision as prompt healing as practicable should be sought for. Therefore, after securing suitable drainage, quite firm pressure on the surface should be made by carefully applied sponges and soft antiseptic dressings, which are fixed securely in place with bandages.

The After-treatment.—Extension, cleanliness, and nutritious food are essential. Extension in bed should be as limited as possible, on account of the evil influences of confinement in these cases. However, extension with the wire breeches (Sayre) or the Thomas splint will enable the patient to leave the bed at an early period, affording also an opportunity for dressing the wound and providing the extension necessary, to prevent the end of the bone from pressing upward against the acetabulum.

The Results.—When done for gunshot injuries before asepsis, about ninety-two and a half per cent die from the primary, about ninety-one per cent from the intermediary, and ninety and a half from the secondary operation. When done for disease, the mortality in 1,700 cases done before asepsis was 33 per cent; of 644 like cases done under aseptic precautions, the mortality was 7.14 per cent. The most favorable age is between five and ten years, and the best results are said to occur when the disease has existed several months. The rate is about three per cent greater from complete than from partial excisions. The rate of mortality is a little improved by the removal of the trochanter major and the upper portion of the shaft; it is diminished, however, in proportion to the amount of diseased bone removed from the head of the femur downward, and is increased in proportion to the extent of the disease of the ilium. About ninety-four per cent secure useful limbs when excised for disease. Complete excision is followed by a more useful limb than partial ex-

cision. The advent of strict asepsis and improved technique with judicious selection of cases has led to the startling results of only three (Wright) to five per cent mortality. The usefulness of the limb will depend very much on the amount of bone removed—the less the better—other things being equal. However, the majority secure serviceable limbs and walk unaided.

The Operation of Arthrotomy for Old Unreduced and Irreducible Dislocations of the Hip.—Inasmuch as the causes of irreducibility are various, and relate to the interference of the capsule, of tendon or of muscle, and, perhaps, of a fragment of bone, also, in no small degree to the restraining influences of the tissue changes incident to nature's conservative efforts, to say nothing of the obstacles also incident to the abnormal relations of the hard and soft parts with each other, it becomes difficult, if not impossible, to indicate a systematized mode of procedure that will meet the technical requirements of even a limited number of these cases.

The primary incision should be of ample size to promote clear observation and rapid, intelligent effort, therefore, when practicable, make it so as to expose the dislocated end of the bone, the cotyloid cavity and the established restraining influences—i. e., the capsule, the muscles inserted into the trochanter major, and nature's contributions to repair, now exercising obstinate restraint. *Barker's* anterior incision (page 428) affords prompt, easy, and free exposure of the anterior aspects of the joint, and may answer admirably in early and simple cases and in the old dislocations with limited structural changes and comparatively free movement, and those with limited dorsal or with anterior displacement. In instances of immobility with the head of the bone well back on the dorsum or in the sciatic notch, especially when of long standing and attended with marked secondary changes, the extreme straight or curved incisions will likely afford a better opportunity of observing the object. However, in any instance the head of the bone must be freely exposed and isolated, the route to the acetabulum made clear, and when, on manipulation to secure return, obstacles are met, they should be overcome by division of capsule, tendon and ligament, by periosteal separation of muscular insertions, and by the removal of new products; patient and painstaking efforts of a thoroughly aseptic character are essential to primary success and to security of the patient, and to the usefulness of limb.

Strong, straight and curved scissors, scalpels, periostotomes, rugines, strong hooks (Fig. 375), and tapes to raise the bone in place are required; when restored, the sound tissues should be repaired by sewing fast in place the muscular insertions and providing temporary drainage. The patient should be confined in bed, and the limb immobilized until healing is effected, when the use of crutches with employment of passive motion are instituted.

If the head cannot be restored, then excision or osteotomy should be done, and the patient treated accordingly. Usually excision has been practiced. It may be deemed wiser to take no active measure whatever.

The Results.—This method has been practiced 30 times, of which

number 11 were reduced. Of the 19 failures, in 18 excision was performed, and in one osteotomy. Of the 11 successfully reduced, 8 were functionally good, 1 died of sepsis, 1 was followed by necrosis of the head, and 1 by return.

Excision of the coccyx is oftentimes done, though sometimes ineffectually, for the relief of coccygodynia. The operation exposes the patient to no danger and can but remove a comparatively useless appendage.

The Operation.—Place the patient on the side and expose the bone by a straight incision in the middle of its long axis; isolate the bone carefully and remove it with bone forceps.

OSTEOTOMY.

In the liberal acceptance of the term, osteotomy may be defined as a section of bone.




FIG. 450—Instruments employed in osteotomy. *a.* Scalpel. *b, c, d.* Chisels. *e.* Mallet. *f, g, h.* Osteotomes. *i, k.* Retractors. *l, m.* Sponges wet with a solution of carbolic acid to hold over incisions.

In a limited sense, however, it is applied to the divisions of bone that are made for the relief of deformities dependent on ankylosis, rickets, badly

united fractures, etc. The bone may be divided either through a *free* or an *abridged* incision of the soft parts. In the former, a liberal incision of the soft parts is made down upon the bone, and it is therefore called the *open method*. If the opening in the soft parts be of only sufficient size to admit

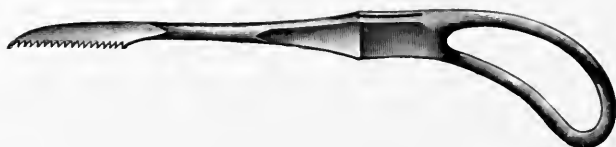

FIG. 451.—Langenbeck's saw.

the entrance of the instrument, thereby preventing observation of the act, it is denominated the *abridged* or *subcutaneous method*. If the bone be divided directly through, in either an oblique or transverse direction, at one situation only, the act is denominated *linear osteotomy*, and is usually of the abridged or subcutaneous variety. When, however, a wedge-shaped piece

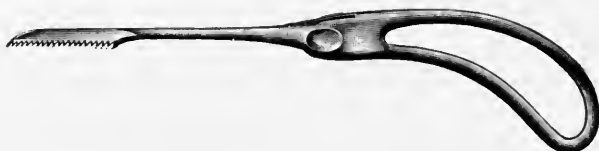

FIG. 452.—Adams's saw.

is removed, the procedure is called *cuneiform osteotomy*, and is practiced through a free incision.

The instruments employed in osteotomy consist of especially designed saws, chisels, osteotomes, mallets, blunt hooks, and sand pillows (Fig. 450).

Variouly formed saws are employed, named usually for the one who designed them, as Langenbeck's (Fig. 451) and Adams's saws (Fig. 452).

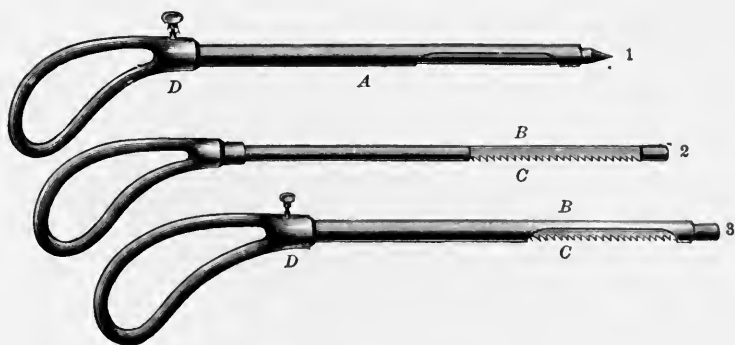


FIG. 453.—Shrady's bone saw.

The blades are short and strong, a quarter of an inch in width and an inch and a half in length, connected to the handle by a strong shank three inches long. The deviations from these varieties are to meet special indications rather than to limit the use of the instruments.

The objections to the use of the saw not only relate to the danger of lacerating the contiguous tissue, but more forcibly to the retention in the wound of the bone dust which, failing to be absorbed, is apt to be followed by suppuration; therefore the osteotome and chisel are better than the saw. The saw devised by Dr. George F. Shrady, of this city, is a good instrument, and is described by himself as follows:

“(Fig. 453.) The instrument consists of a staff with a handle and blunt extremity. A portion of this shaft at a short distance from the extremity is flattened, one edge (*B*) being made into a knife blade, and the other (*C*) being provided with saw teeth. When in position (3) either the saw (*C*) or the knife edge of the shaft, according to the way the latter is turned, corresponds with the opening of the cannula. The saw or knife can then be worked to and fro within the cannula by a pistonlike movement, the cannula being steadied by grasping the flange or handle (*D*) (Fig. 454) at its base. If it be necessary to work the instrument as an ordinary blunt-pointed sheathed saw or knife, the shaft can be fixed in the cannula and made into one piece by a thumbscrew in the handle. The portion of the cannula at the back of the opening is made extra strong, and is of the same thickness as the blade,

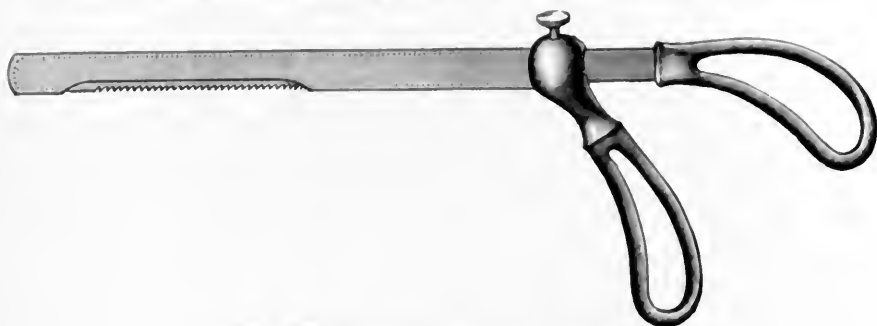


FIG. 454.—Shrady's improved bone saw.

so that in sawing there is no stoppage of the passage of the instrument through any thickness of the bone. The soft parts are protected from injury, no matter which way the instrument may be worked. The saw blade is blunt at its extremity, and is guarded on all sides except in its limited cutting surface. The same may be said of the knife. The working of the saw to and fro in the cannula is sufficient in sweep to insure the division of any bone having a diameter less than the cutting edge. Still, as this process is much slower than when the saw is used in the ordinary way, it is perhaps better to restrict its employment to operations on the smaller bones, to cramped localities, and to situations where there is special danger of wounding some neighboring vessels. All that is necessary in using this saw is to thrust the trocar and cannula into the limb, the fenestrum of the cannula being alongside of the bone upon which the operation is to be performed. The trocar is then withdrawn, the staff introduced in its place and worked as already described.”

The *chisel* resembles the carpenter's chisel in form, but differs from it in quality; it has two parallel margins extending to its cutting edge, which is

beveled on one side. The base of the bevel should be an eighth of an inch in thickness; if thicker than this it may splinter the bone. The width varies according to the size of the bone to be divided—half an inch being suitable in the majority of cases. For narrow bones, a quarter of an inch in width is better (Fig. 450, *b, c, d*). The width should be less than that of the bone to be operated upon.

The temper given to the tools of the hardwood or ivory turner is best suited for the purpose of this instrument, and its efficacy should be tested upon the thigh bone of an ox or a like animal before being used for its special purpose.

The chisel should be sharp, and leave a smoothly cut surface. This instrument is employed only to remove a wedge-shaped piece from the bone, since the shape of its cutting extremity will, like that of the carpenter's chisel, cause it to go awry if a straight section be attempted.

The Osteotome.—The osteotome is beveled at the end on both sides, resembling, therefore, a slender wedge, with the handle and the blade continuous and of the same material. One border of the blade should be delicately marked in inches or otherwise, to determine the depth of the wound. The edge should be sharp enough to cut a finger nail, and the temper of a character to withstand the strain required. The strength of this instrument can be tested the same as in the preceding instance. Osteotomes vary in thickness in order that a section begun by one of a given thickness may be continued on its withdrawal by the substitution of another of a lesser thickness. The tops of the osteotome and chisel should each have a round head against which the thumb is pressed to steady the instrument (Fig. 450, *f, g, h*).

The mallet is made of hard wood, or rawhide constructed for the purpose; or an extemporized one may be employed (Fig. 450, *e*).

The scalpel is a long one with a sharp point suitable for penetrating at once to the bone (Fig. 450, *a*). *Blunt hooks* are employed to draw the edges of the incision apart without force (*i, k*).

The Sand Pillow.—The dimensions of the sand pillow are usually about twelve inches by eighteen, made of stout cloth, and filled with sufficient fine sand to permit the contents to be moved from one part of the bag to another without leaving any portion empty. It should be dampened before use, covered with a carbolized cloth, and the limb laid upon or rather imbedded in it. It forms an efficient support, and prevents the impulse of the blow from causing injury to the soft parts.

The Comments.—The opening in the soft parts leading down to the point of proposed section should be limited in extent and so located as to avoid the division of important structures or injury to a joint. It should be made when practicable in the long axis of the fibers of the muscle through which it passes down to, but not through, the periosteum. The blade of the scalpel should remain in the incision till muscular contraction ceases, and then the chisel, osteotome, or saw is passed into the wound by the side of the blade acting as a guide, after which the knife is withdrawn.

It is better that the wound be large enough to admit the finger, or even

to permit inspection of the bone, than that the tissues around a small incision be treated with violence in introducing the chisel or osteotome.

If chips of bone are to be removed, a larger incision is required than if a simple section be intended. The patient should in all instances be anesthetized, and if advisable the limb rendered bloodless by the elastic bandage. However, the wound should not be finally closed until the surgeon is assured that no significant degree of hæmorrhage is liable to take place. In all respects the operation must be performed with antiseptic care.

When the blow is delivered, the osteotome or chisel should be firmly grasped and steadied by the lower border of the hand placed in contact with the soft parts (Fig. 455). If either instrument be held loosely, or be applied to the bone indifferently, the blow of the mallet will be both futile and dangerous. The edge of the osteotome should not be so pointed or placed as to endanger important structures by a direct or deflected curve in the course of the instrument. The first blows should be lighter than the succeeding ones so that the edge of the instrument may be first safely fixed in the bone. If the osteotome be removed, it should be replaced in the original track for obvious reasons. If the instrument be fixed in the bone, it should be loosened by careful rocking in the direction of the long axis of the cutting edge, and not the short, as by the latter movement the edge is liable to be nicked and broken. The greater liability of the laceration of the soft parts, and of the entrance of air into the wound and the deposit of bone dust in it, are valid objections to the use of the saw as compared with that of the osteotome.

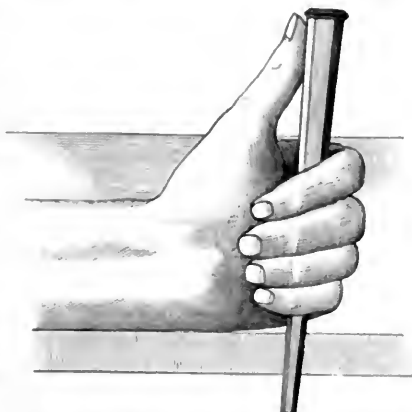


FIG. 455.—Method of holding osteotome.

Subcutaneous Division of the Neck of the Femur.—Subcutaneous division of the anatomical neck of the femur is practiced to remedy faulty position of the thigh incident to ankylosis following hip disease, etc. The division can be made with the saw or osteotome.

The Division with the Saw (Adams).—Place the patient upon the sound side, with the bone to be treated uppermost. Locate the upper border of the trochanter with the finger. Introduce about an inch above the top of the center of the great trochanter, on the flat and at a right angle with the neck, a long scalpel or tenotome straight down to the neck of the femur; divide the muscles and open the capsule freely on the anterior and upper surface so as to permit the easy entrance of the saw, which is passed by the side and along the track of the knife down to the anterior surface of the neck, which is then sawed transversely through (Fig. 456) from before backward sufficiently to be easily broken. The limb is then placed in the proper position, the wound irrigated to render it aseptic and to wash out the bone dust; hæmorrhage is checked, a small drainage tube introduced, the remain-

ing portion of the incision closed, the whole area enveloped in antiseptic dressings, and the limb placed in an immovable apparatus. The tendinous contractions that may prevent the limb from being properly corrected should be divided subcutaneously.

The Remarks.—This method of practice is best suited to those cases in which the neck of the femur has undergone no especial change. If this portion of the bone have been shortened, thickened, or eburnated, or be surrounded with indurated tissue, or the head of the bone be displaced, the use of the saw is contraindicated, and the osteotome should be employed instead. Aside from these facts, the deposit in the wound of bone dust and the probable bruising of the tissues with the end of the saw are regarded as objectionable features.

The Results.—This operation has been successful in thirty-one out of thirty-four cases.

The Division with the Osteotome.—Place the patient on the sound side, expose the upper border of the neck of the femur to the osteotome through an incision extending upward from the upper border of the great trochanter three quarters of an inch. Introduce the osteotome before removal of the knife; turn it so as to divide the neck in the direction of the short diameter. A few sharp blows with the mallet will permit restoration of the limb with fracture of the undivided portion of bone.

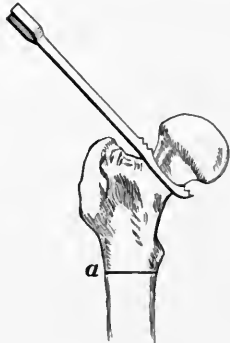


FIG. 456.—Sawing neck of femur.

The Remarks.—Special care must be exercised in the use of the osteotome, and in the handling of the limb during the use, so as not to cause fragments of bone to be loosened or pushed into the soft tissues by the advancing end of the instrument or by incautious movement of the fragments. The instrument should be so held and the blow so directed as to limit the effect to the bone alone.

Maunder, Billroth, and others have used the chisel for forcible fracture with good results.

Division of the Neck of the Femur; Formation of False Joint (Volkman).—While false joints are often fickle, and in many instances afford no great advantages over those gained by an increased compensatory movement of the spine, still by this operation good results are reported to have been so common as to merit a more frequent trial of the method.

The Operation.—Make an incision along the posterior border of the great trochanter four or five lines in length down to the bone. The femur is then cut through about an inch below the great trochanter with a chisel, the wall of the cervix femoris broken, and the upper portion of the bone removed. The thigh is then adducted to make the upper end of the distal fragment of the femur more accessible, then the latter is cut across and rounded off to fit the new socket made by chiseling out the head of the femur and increasing the area of the acetabulum by the same process, being careful not to open into the pelvic cavity. The upper end of the femur is placed in

the newly formed cavity, and extension is applied to the limb to keep the cut surfaces sufficiently separated to prevent bony union. Early passive motion should be made.

The Results.—Volkman has performed this operation several times, obtaining useful limbs in each instance.

The Division by Inter-trochanteric Osteotomy (Sayre's modification of Barton).—This operation consists in exposing the anterior, outer, and posterior surfaces of the femur through an incision about six inches in length, beginning just above the tip of the trochanter major, and carried longitudinally through the center of its outer surface. A short, transverse incision is then joined to the center of the posterior lip of the first; the respective surfaces of the bone are then exposed with an elevator, until the trochanter minor can be felt, when a chain saw is passed around the bone immediately above this process. *The first or curved section* (Fig. 457) is made by first sawing upward and outward, until the bone is half severed, then changing the direction to downward and outward, and completing the section.

The second or straight section is made by sawing directly through the upper end of the lower fragment in its transverse axis so as to excise a piece of bone an eighth of an inch thick at the outer and inner borders, and three quarters of an inch at its central part.

The upper end of the lower fragment is then rounded to fit the concavity above. The limb is straightened and the wound treated like a compound fracture.

The Results.—The removal of a disk of bone in this situation has been quite frequently practiced, but with indifferent success. Out of the seventeen cases reported, seven died.

Volkman's Modification.—The modification introduced by Volkman in 1873 consists in making an incision along the posterior border of the great trochanter and upper portion of the shaft of the femur about three inches in length, and removing the periosteum from two thirds of its circumference at the lower part of the incision, when with chisels and gonges a wedge-shaped piece is taken from just below the great trochanter (Fig. 458), and the bone broken, straightened, and placed in proper position until union takes place.

The Results.—Of the twelve operations thus performed, all recovered.

The Division of the Shaft below both Trochanters (Gant).—This method of procedure is performed in the following manner:

The Operation.—Make a longitudinal incision down to the bone on the outer aspect of the femur corresponding to the situation of the lesser

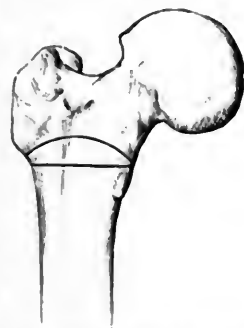


FIG. 457.—Sayre's lines of section.

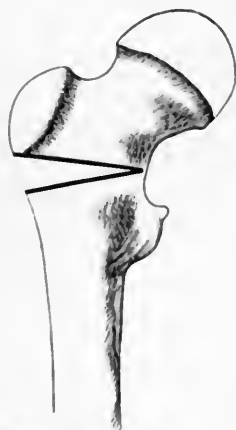


FIG. 458.—Volkman's section.

trochanter. Through this opening introduce the osteotome down to the bone and divide the bone transversely just below the lesser trochanter (Fig. 456, *a*).

The Remarks.—The ease of approach to the bone, the comparative simplicity of the division, and the uniformly favorable outcome thus far secured, bespeak the adoption of this method when practicable, instead of either of the more complicated and less favorable ones already stated.

After-treatment.—In all instances of division of the neck of the femur thorough drainage and aseptic cleanliness should be practiced. If a false joint be the desideratum, extension and passive motion should be made to prevent bony union. The latter is begun as soon as the wound is well healed, and the former is continued while the patient is in bed, and even later if need be, by special apparatus. If bony union be unobjectionable, the limb is treated by immobilization apparatus, the same as for fracture. The choice of operation will be governed largely, indeed, by the nature of the desired outcome—mobility or immobility at the seat of division.

Congenital Displacement at the Hip (Hoffa's operation).—Place the patient on the sound side; flex the thigh to an angle of forty-five degrees, make an incision three or four inches in length in the long axis of the great trochanter, upward and backward toward the posterior superior spinous process of the ilium through the tissues, down to the bone. Remove the periosteum and muscular attachments from the great trochanter with a periosteotome; cut away the capsular ligament if it oppose reduction; enlarge the acetabulum with bone scoops; reduce the displacement by manipulation, stretching or dividing muscular structure opposing reduction; drain the wound, dress antiseptically, abduct and extend the thigh, and confine the limb with a plaster-of-Paris spica until the wound is healed.

The Remarks.—In children under six years of age the muscles can usually be stretched sufficiently to bring the limb into proper position for confinement during healing. In those of six and upward stretching rarely avails, and subcutaneous division of the muscles attached to the tuber ischii and of the adductor muscles is practiced, together with open division of the fascia lata and of the soft parts attached to the anterior superior spine of the ilium, as the need for such divisions is demonstrated by putting the tissues successively on the stretch. The ligamentum teres, the cartilages, the fatty and a good portion of the cancellous tissue of the acetabulum should be removed, disturbing as little as possible the margins of the cavity.

The After-treatment.—If the acetabulum be shallow, the head of the bone should be held in place with extension or by means of a padded strap buckled around the pelvis and over the trochanters. If the acetabulum be deep enough the head will remain in position without mechanical aid.

Hoffa advises that the limb be at first moderately inverted, abducted and extended, then after a few weeks brought into the normal position. The first fixation dressing is retained in place three or four weeks if practicable. For weeks and perhaps months afterward the patient should not stand or walk without the support of an apparatus directed to maintaining the length of the limb while permitting motion at the hip joint.

The Results.—Hoffa reports 112 operations on 82 patients. Ankylosis of the hip followed in 9 and return of the displacement in 11 cases. Death followed in 3 cases: in 2 from the effects of shock; in 1 from iodoform poisoning.

Lorenz's Modification of Hoffa's Operation.—Place the patient on the back, with the limb abducted and rotated outward. Make an incision from a point two inches beneath the anterior superior spinous process of the ilium, going obliquely downward and outward through the tensor vaginae femoris muscle and the anterior fibers of the gluteus medius muscle and the fascia lata, crossing the trochanter at about the middle of the external surface and extending to a point just below the long axis of the femur; draw apart with broad, strong retractors the borders of the tensor vaginae femoris and gluteus medius muscles, find the rectus femoris muscle and locate its reflected tendon at the point of insertion into the bone just above the acetabulum; uncover the capsular ligament and incise it longitudinally so as to expose the head and neck of the bone; cause the assistant to flex the thigh to a right angle with the body, and free the insertions of the capsular ligament from the anterior and posterior surfaces of the bone so that the finger can be passed completely around its neck; throw the head of the bone outward; divide the ligamentum teres if present, and turn the bone aside, thus exposing to view the underlying capsule and the acetabulum; deepen the acetabulum with a curette, preserving as much as practicable its bony rim.

The Remarks.—If the head of the bone be conical, a portion should be removed, preserving, however, as much as is possible of its articular cartilage to obviate the ankylosis that is liable to follow the removal of cartilage in deepening the acetabulum. The finding of the socket is sometimes difficult, on account of the presence of fibrous tissue and of the overlying adherent portion of the capsule. Portions of tissue that prevent reduction of the head and of its retention in place with the limb abducted or in a straight position should be severed. A short neck of the bone, contraction of the adductor muscles, or a narrow acetabulum may further prevent reduction or proper retention in place. When reduction attends adduction of the limb, forcible abduction may be employed to stretch the tissues hindering the proper placement of the limb in the normal position. *Bradford* in some instances divided the Y-ligament to effect a proper reduction. After satisfactory reduction the divided tissues may be united with buried catgut sutures, and the wound carefully drained, or it may be packed with gauze at the outset, as circumstances demand. Prior to operation in any method the restraining tissues should be stretched for some time with the limbs in an abducted position by weight and pulley. Objectionable internal or external rotation of the limb after recovery can be remedied by division of the femur below the trochanter, followed by rectification of the deformity and the application of the plaster-of-Paris spica until union ensues. *Lorenz* himself no longer practices this method.

The Results.—*Lorenz* reports excellent results in a series of 100 cases. Two cases were followed by slight fibrous ankylosis, and one by suppuration and complete ankylosis. *Schauz* reports 135 cases operated on by twenty-one

different operators. Death occurred from operation in 7 and from complications in 4 cases. Eight were not satisfactory, 6 perfectly so, and 109 were excellent results. If a rudimentary acetabulum be not present, *Ogston* advised that an opening be chiseled through the ilium and the head of the bone adjusted to it.

The results in these operations appear to be excellent when measured by the depth of the inherent difficulties to which they are addressed. The nature of the infliction necessarily renders infrequent perfect cure. *Lorenz's* method may be regarded as the simplest and least dangerous of the effective operative procedures.

Bony Anchylosis of the Knee Joint.—Bony ankylosis of the knee joint may be associated with flexion, or with internal or external deflection of the leg. In either instance the deformity can be practically overcome, and the usefulness of the limb enhanced by supracondyloid osteotomy of either the linear or cuneiform variety. The anatomical points bearing on the operation are in all respects similar to those relating to correction of genu valgum. And, too, the methods of procedure in cases of deflexion present no substantial differences from those employed in the operation for that deformity.

The Operation by Linear Osteotomy.—When performed from the outer aspect, make a longitudinal incision down upon the bone at the outer border of the rectus tendon, one finger's breadth above the upper portion of the outer condyle, sufficient to admit the osteotome. The osteotome is introduced and turned so that its cutting surface corresponds to the transverse axis of the bone at the point to be divided; with the limb resting upon the sand bag the anterior two thirds of the femur is divided and the posterior third broken or bent. If performed from the inner aspect, the incision is made half an inch in front of and parallel with the anterior border of the tendon of the adductor magnus, beginning one inch above its insertion. The remaining steps of the operation are similar to the preceding. It may be necessary to supplement the section of the femur with that of the tibia, in order to sufficiently correct the deformity. This is done by making an incision through the skin over the tibial crest, just below the tuberosity. Through this opening, the subcutaneous and posterior surfaces of the tibia are divided sufficiently to permit of a fracture of the bone and the consequent correction of the deformity. The fibula, owing to its mobile association with the tibia, does not require division at this situation. It is often necessary, however, to cut the hamstring tendons before the deformity can be properly corrected.

The Operation by Cuneiform Osteotomy.—Although this variety of osteotomy may be applied to deflected curves, the linear is much the better, and the cuneiform method should be rather employed in instances of ankylosis of the knee with marked flexion of the leg. It can be employed above (*Barton*) or through the joint. The latter is much the better plan. The size of the piece to be removed can readily be estimated by noting the course of two imaginary lines dropped perpendicularly to the long axes of the tibia and femur respectively (*Fig. 459*). If these lines be so dropped as to join at the angle of the deformity, they will indicate the minimum amount of bone that should be removed. A still greater saving of bone can be made

if the cuneiform section ceases at the posterior third of the transverse diameter, which part is then overcome by fracture as the limb is straightened. In all instances the lines of division of the two bones *must* be made so as to be *parallel* with each other when the leg is brought into the correct position, otherwise a new deformity will be created—deflection of the leg. If the degree of flexion be a minor one, linear osteotomy will suffice for the rectification.

The General Remarks.—Care must be observed that the osteotome does not invade the popliteal space as the vessels and nerves may be directly injured thereby, or from the resulting sharp fragments of bone.

In the case of fibrous ankylosis the use of the weight and pulley should be employed to overcome as much as possible the deformity, and also to stretch to the fullest extent the opposing soft parts before osteotomy is done. In no instance, either before or after operation, should these tissues be so stretched as to imperil their integrity, benumb the limb, or interfere materially with the circulation. Cuneiform division is practiced here with the saw, especially when done through the joint.

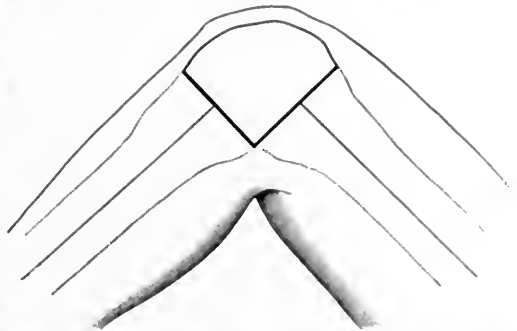


FIG. 459.—Cuneiform incision for bony ankylosis of knee joint.

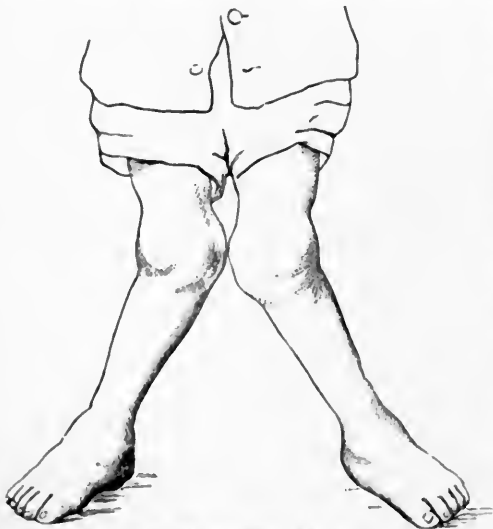


FIG. 460.—Genu valgum.

Genu Valgum.—The operations for the relief of genu valgum can be practiced with comparative impunity in the presence of antiseptic measures and anatomical knowledge (Fig. 460). Care should be taken to avoid the popliteal vessels, especially the anastomotica magna and superior internal articular arteries.

The Anatomical Points.—The limit of the epiphyseal junction is on a line with the tubercle of the adductor magnus. The preponderance of the bony structure here corresponds to the external surface (Fig. 461). The synovial membrane of the knee joint extends upward above the articular surface for an inch or more with the limb extended.

tends upward above the articular surface for an inch or more with the limb extended.

The Operation of Osteotomy of Genu Valgum, Supracondyloid (Macewen).—Flex the leg on the thigh to draw down the synovial pouch; place the limb on a sand pillow; make an incision down to the bone through the soft parts at the inner side of the limb, beginning a finger's breadth above the

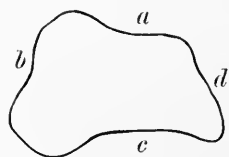


FIG. 461. — Transverse section near epiphyseal junction at lower end of femur.
a. Anterior surface.
b. External surface.
c. Posterior surface.
d. Internal surface.

insertion of the tendon of the adductor magnus into the spine at the upper portion of the internal condyle and half an inch in front of the tendon, and carry it upward sufficiently to admit the osteotome; or, the lowest limit is made to correspond to a line drawn transversely across the limb in front, beginning an inch above the external condyle, which will, if the internal condyle be much elongated, prevent the osteotome from being driven into the external condyle instead of above it. The course of the incision (Fig. 462, *a*) avoids as far as possible any interference with the anastomotica magna and the articular branches. The osteotome may be applied to the bone transversely at the site indicated by the transverse dotted line (*b*), and so directed that its course will correspond to a line extending across the posterior aspect of the femur to a point one finger's breadth above the external condyle. The extent of the osseous incision will depend upon the density of the bone; if the subject be young, the bone can be cut through two thirds of its diameter, and then be bent or broken; if it be dense, it will be necessary to carry the incision to the outer wall. The posterior and inner surfaces of the bone are first cut, when, if necessary, a thinner chisel is employed to complete the operation. When the bone is sufficiently divided, the limb is straightened, all hæmorrhage arrested, and the part treated as indicated.

Fig. 463 shows the long internal condyle of genu valgum; Fig. 464 represents a section of about three fifths of the diameter; Fig. 465 illustrates the appearance of the bone with the line of section closed, showing the curvature as rectified. The prognosis of this operation, with reference to usefulness of the limb, cure of the deformity, and danger to life, is most flattering.

The Results.—In about six hundred and fifty supracondyloid osteotomies but three fatal cases are reported that can be attributed to the operation: one each from septicæmia, hæmorrhage, and carbolic-acid poisoning. All the patients were benefited, and many were enabled to take an active part in affairs from which they had been debarred.

The Operation of Osteo-arthritis for Genu Valgum (Ogston).—The operation of osteo-arthritis consists in dividing the elongated condyle of the femur *by sawing* (Ogston), or *by cutting* (Reeves), sufficiently to admit of the rectification of the deformity (Figs. 466 and 467).

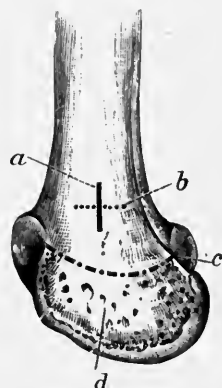
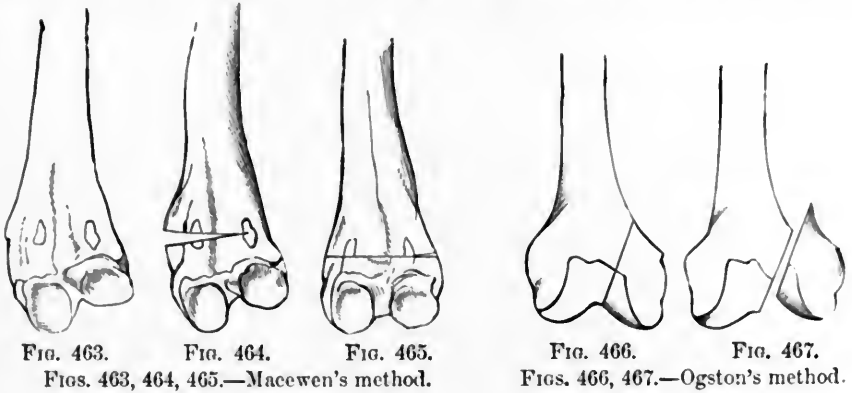


FIG. 462. — Supracondyloid osteotomy. *a.* Direction of incision of soft parts. *b.* Line of bone section. *c.* Epiphyseal junction. *d.* Epiphysis.

The Operation by Sawing.—Place the patient in the dorsal position; flex the leg upon the thigh fully. At a point two or three inches above the tip of the inner condyle introduce a tenotome upon the flat, carry it downward, forward, and outward until its point can be felt anteriorly in the inter-



condyloid space. The cutting edge is then turned downward, and the tissues divided down to the bone as it is withdrawn. A small Adams's saw is then introduced along the course of the incision, and the condyle is sawed, from above downward, and before backward, through about three quarters of its thickness. If the limb be now straightened, the remaining portion is fractured and the deformity is rectified.

The Results.—In forty-six operations two patients have died of septicæmia. Neither of these methods can be advised.

The Operation by Cutting.—By this method the elongated condyle is divided or loosened with a chisel or osteotome, the intention being to divide the condyle to the greatest depth without opening into the joint. Even though the cut be made to meet this indication, the joint is no doubt involved (except possibly in the very young) by the displacement upward of the fragment necessary to correct the deformity.

Chiene's Method of Osteo-arthrotomy.—

Mr. Chiene, instead of sawing or cutting off the condyle, corrected the deformity by the removal of an oblique transverse wedge of bone from the body of the condyle, which, when pressed upward by straightening the limb, remained attached by its apex to the shaft (Fig. 468). Not infrequently, however, the condyle is detached by this manipulation and the joint opened. The details

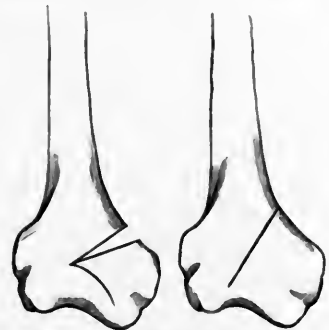

FIG. 468.—Chiene's method.

attending this method are omitted, since it can not be compared favorably with the much simpler and equally efficient one—supracondyloid osteotomy.

Genu Varum.—This deformity, too, is relieved by osteotomy. In osteotomy in these instances the operative proceedings are directed to the outer instead

of the inner side of the bones of the leg and thigh. The procedure, precautions, and treatment are like those for genu valgum. The division of the bone through a small external opening can be made almost indiscriminately in such as present this deformity, always remembering that thorough and complete antiseptic precautions should be taken.

The results are most flattering and commend this operation to the consideration and practice of the profession.

Genu Varum (Fig. 469) or Bowlegs may depend on an outward curvature of the bones of the leg, wholly or in part. In either instance the deformity of the leg can be corrected by *osteotomy* of the tibia. The tibia and fibula can be divided at any part of their course by either the linear or cuneiform methods; the linear for

the lesser, and the cuneiform for the greater, degrees of deformity, is the rule. If the patient be young enough, a green-stick fracture of the fibula will obviate the necessity for its division.

The Operation by the Linear Method.—Cleanse the part thoroughly, apply the elastic bandage, place the limb on the sandbag, and at the point of the

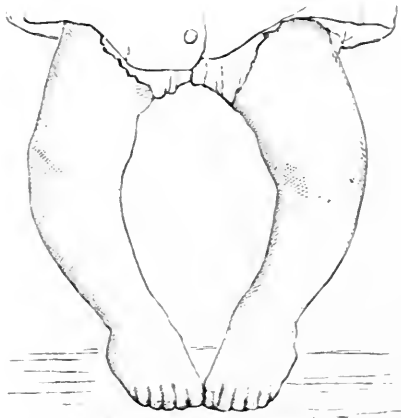


FIG. 469.—Genu varum.

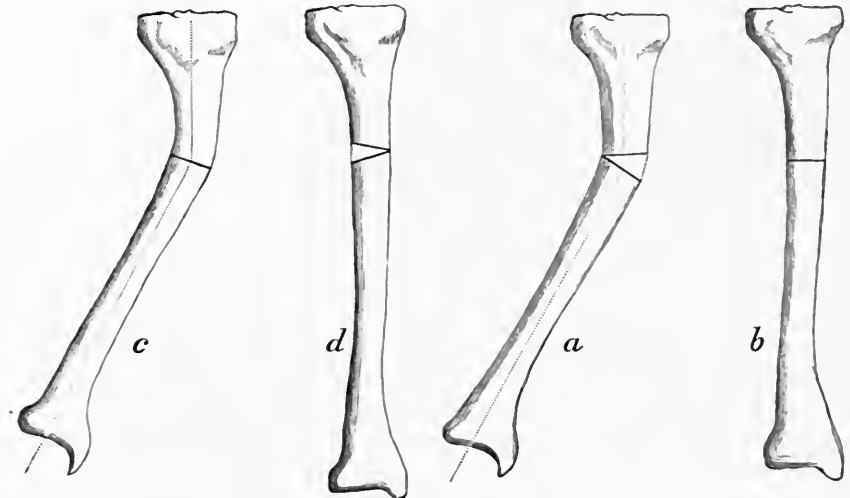


FIG. 470.—Linear osteotomy: *c*. Bone divided. *d*. Deformity corrected. Cuneiform osteotomy: *a*. Cuneiform piece removed. *b*. Deformity corrected.

greatest curvature make a longitudinal incision down to the periosteum, midway between the borders of the subcutaneous surface of the tibia at the

point of proposed division and of ample length to admit the osteotome, which is then turned so as to divide the bone transversely sufficiently to admit of its being fractured (Fig. 470, *c, d*). Cut or bend the fibula, correct the deformity, close the wound in the soft parts with catgut, dress antiseptically, and confine the limb in a temporary dressing until all danger of hæmorrhage, inflammation, etc., has subsided, when it may be placed in an immovable plaster-of-Paris dressing and retained until union has taken place. If a double section is to be made at different points, an antiseptic sponge (Fig. 450, *l, m*) should be bound over the incision in the soft parts of the first while the second operation is being made. This affords an opportunity to determine the severity of the hæmorrhage and the ease with which it can be controlled. If it be necessary to divide one bone in two situations to correct a deformity, the second division should be deferred until the former has healed, when it should be done at the remaining point of greatest convexity.

The Operation by the Cuneiform Method.—If the bones be much curved, it may become necessary, in order that the deformity be properly corrected,

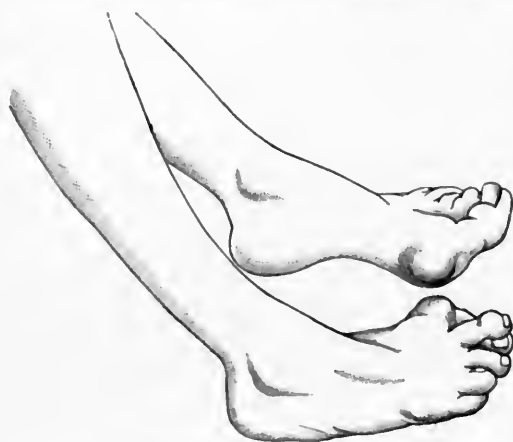

FIG. 471.—Hallux valgus.

to remove a wedge-shaped piece (Fig. 470, *a, b*), which is best accomplished with the chisel. The base of the cuneiform section corresponds to the crest of the tibia and the apex to the posterior surface, or as much farther in front of it as the surgeon's idea of fracture *versus* section may suggest. The rule for the formation of the proper sized section is indicated in the consideration of the treatment of ankylosis of the knee.

The After-treatment and

Results.—All osteotomies should be performed under strict antiseptic precautions, and the incision of the soft parts closed with a catgut suture. The limb must be immovably fixed and the patient kept quiet; in fact, the measures applicable to a compound fracture are in order, since osteotomy resembles that condition more nearly than any other.

The Results.—The results of all osteotomies performed with antiseptic precautions are extremely satisfactory. As yet, I have no personal knowledge of a death from the operation, and of fourteen hundred osteotomies but about one per cent only are reported to have died in consequence of it.

Hallux Valgus.—Hallux valgus is practically limited to the great toe, and is usually caused by improperly fitted boots and shoes. Fig. 471 (Tubby) represents the condition more graphically than words can. In this condition the first phalanx (anatomical) articulates with the outer portion of the distal extremity of its metatarsal bone and is rotated inward on its long

axis. The principal portion of the head of the metatarsal bone projects inward, and its extremity is surmounted by a sensitive bunion. The indication is to place the toe in its normal axis and retain it in that position. In pronounced cases this can not be accomplished without division at the least of restraining fibrous tissues. If the deformity be great, little else than an operation on the bone will be of any practical value. *Two methods of operation* can be recommended:

1. The removal of the head of the metatarsal bone, together with enough of the shaft to permit the great toe to be easily replaced and held in its normal axis (Fig. 422, *a*). Under strict antiseptic precautions this operation results in quick recoveries and useful toes.

2. The deformity can be corrected by removing a V-shaped piece (cuneiform osteotomy) from the inner portion of the distal extremity of the metatarsal bone, as near the head as possible without involving the joint cavity. This, too, must be done under strict antiseptic precautions, and is accomplished through an incision made along the inner side of the metatarsal bone. The soft parts are retracted, and the V-shaped piece of the bone is removed without dividing more than three quarters the diameter of the shaft. The thickness of the base of the triangular piece to be removed is estimated by the degree of deflection of the toe from its normal position, in the manner practiced for cuneiform osteotomy.

The bone wedge can be removed by means of a saw or chisel and the toe brought into position, causing fracture of any undivided portion of the bone. Horsehair drainage and immobility under antiseptic dressings will be followed by speedy union and a satisfactory recovery. If the deformity be less marked, then a simple linear osteotomy, followed by a rectification and confinement, will secure a satisfactory outcome. The author has on three occasions operated on both toes simultaneously, employing excision of the head of the bone and cuneiform osteotomy in proportionate instances. They all healed promptly, each resulting in a serviceable limb with no appreciable difference except that the cases treated by osteotomy were followed by freer movement.

Osteotomy for Talipes.—The operation methods devised for remedying the deformities of talipes are quite numerous, and often as fanciful as those directed to amputation at the shoulder joint. The following only will be considered as representative of the series.

Cuneiform Osteotomy of the Tarsus for Talipes Equino-varus (Tarsectomy, Davies-Colly). *The Operation.*—After careful antiseptic preparation and application of the elastic bandage, place the foot on a sand bag, with the outer border uppermost; make a straight incision down to the bone along this border from the middle point of the os calcis to the base of the fifth metatarsal bone; make a second incision through the superficial tissues from the dorsum of the foot to the center of and at right angles with the first an inch in length. Reflect the flaps, draw aside the tendons and vessels upon the dorsal and plantar surfaces, raise the periosteum, and remove with saw or chisel a wedge-shaped piece, composed of adjoining portions of the os calcis and cuboid, and, if the case be severe, the entire cuboid and even the

base of the fifth metatarsal bone. After removal of the bone, arrest hæmorrhage, rectify the deformity, unite the borders of the wound, dress antiseptically, and confine the part in an immovable position with a plaster-of-Paris, or other suitable splint.

The Comments.—It is thought better that the second incision pass into the sole of the foot rather than onto the dorsum (Tubby). The primary incision should be extended downward sufficiently to meet the operative requirements of the deformity. Since the cause of the deformity exists at the inner aspect of the foot, and the effect at the outer, the removal of the bone at the latter situation can not be regarded as rational except as a final expedient.

The Results.—In about ten per cent of the cases suppuration has occurred, followed by death in one instance. The operation should not be practiced, except as a final resort, and then with certain antiseptic technique.

The Operation of Linear Osteotomy of the Neck of the Astragalus for Talipes Equino-varus (Bradford).—This operation is not attempted until after the beneficial effects of division of contracted tissues and manipulation have failed to correct the deformity.

The Operation.—After strict antiseptic preparation and application of the elastic bandage, make an incision through the soft parts from the top of the inner malleolus to the inner border of the head of the first metatarsal bone; draw apart the borders of the opening, adduct the foot strongly, and expose the scaphoid bone and the head and neck of the astragalus; introduce and place an osteotome across the inner aspect of the neck of the astragalus and sever it with a few sharp blows of the mallet. If the bone be incompletely severed, the rectification of the deformity will cause fracture of the remaining portion. Correct the malposition of the foot, unite the borders of the wound, dress antiseptically, and confine the part in position until union occurs.

The Remarks.—The line of section of the neck should be in a plane such that when the deformity is corrected the gap at the site of section will be of the smallest possible size. Although simple in practice this plan often proves inefficient.

Phelps's Open Incision Method.—The free open incision method is practiced when the integument at the seat of the deformity is too short to permit of rectification after a free subcutaneous division of the constricted tissues.

The Operation.—After the employment of thorough antiseptic precautions and the application of the elastic bandage, make an incision beginning directly in front of the inner malleolus and passing downward to the inner side of the neck of the astragalus. Through this incision divide respectively such of the following structures as offer resistance to the rectification of the deformity: the tendon of the tibialis posterior muscle, the abductor pollicis muscle, flexor brevis digitorum muscle, tendons of long flexor muscles, the elongations of the deltoid ligament and of the plantar fascia, and the calcaneo-scaphoid ligament, avoiding if possible the internal plantar nerve and artery. The wound should be dressed to secure organization of blood clot (page 358) if possible, or treated in the usual manner of open

wounds. At once or a few days later the raw surface may be covered with skin grafts. *Phelps* advises that if the elastic constriction be employed the dressing be applied before its removal, and that the extremity be slung in a perpendicular position for from four to six hours thereafter. The deformity must be corrected before application of the dressing, and be immovably confined in the rectified position by plaster of Paris or other acceptable means.

The Results. — *Phelps* reports one hundred and sixty-one operations, of which ten cases were found to have relapsed one year after, due, it is claimed, to neglect. The cases heal promptly with but few exceptions, and serviceable limbs are secured (Fig. 472).

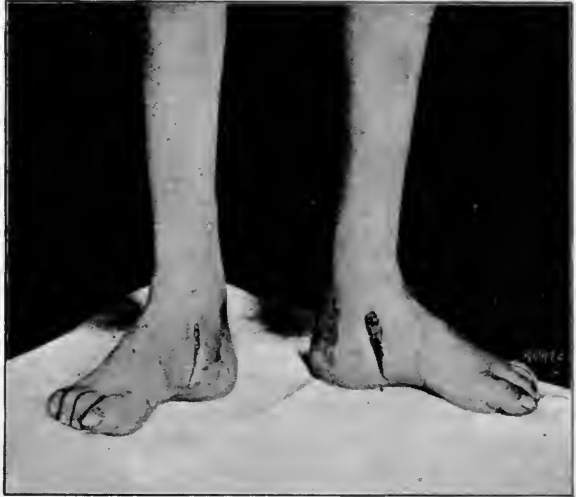

FIG. 472.—*Phelps's* operation, four weeks after.

The Enucleation of the Astragalus (*Lund*).—This procedure is practiced, and with much success, in inveterate cases of clubfoot. As the method of excision has been described already (page 410) nothing further need be added at this time, except that the foot be confined immovably at right angles with the leg until healing is complete.

The Results.—In twenty-one cases all did well. In two suppuration occurred.

Other operative methods are employed for the relief of talipes, as, for instance, through an incision extending from the front of the lower end of the internal malleolus to the internal cuneiform bone, a wedge-shaped piece of bone can be taken from the inner border of the foot formed of the scaphoid alone or including the head of the astragalus (*Bird*), or the astragalo-scaphoid joint may be excised or erosion practiced upon it in such a manner as to form a wedge-shaped space (*Ogston*). Recently the removal of the astragalus has been practiced successfully (*Vogt*). Each of the foregoing methods has been employed with varying success for the relief of flat foot. In either instance, after operation the foot is corrected and held properly in place with pegs, wire, etc., or, what is still better, a properly moulded plaster-of-Paris splint. The removal of a wedge-shaped piece of bone from the inner side of the head and neck of the astragalus (*Stokes*), followed by correction and the usual treatment of these operations, is a useful expedient for the relief of talipes valgus. The treatment applicable to compound fractures should, furthermore, be addressed to each of these operations.

Osteoplasty.—Osteoplasty or transplantation of bone has not yet gained the prominence as a general surgical expedient that the knowledge of the laws governing the growth of bone seemed likely to secure for it.

Bone along with its periosteal and fibrous connections has been pushed to one side—transverse displacement—as in the case of the operation on the hard palate for the closure of a fissure. The closure of the spaces between fragments and borders of bone, by filling such spaces with freshly sawed sections from the main structure with bone chips, or decalcified bone fragments, is in many instances wisely and successfully practiced. The conditions necessary for a successful issue are numerous and exacting, the chief one of which is a most rigid adherence to the antiseptic methods.

In the employment of bone chips, whether decalcified or not, the intervention and organization of blood clot is essential to success. The technique of this procedure is the following:

The Preparation of the Bone.—Saw into longitudinal strips about an eighth of an inch in thickness the compact tissue of the tibia or femur of the ox, entirely stripped of periosteal and marrow tissue; immerse the bone strips in a ten- to fifteen-per-cent solution of hydrochloric acid and water, which is changed daily for from one to two weeks; then wash the strips in a weak alkaline solution; cut into small pieces, and immerse them for forty-eight hours in a 1-to-1,000 bichloride solution, after which store them finally in a saturated solution of iodoform and ether.

The Preparation of the Cavity.—Cleanse the cavity by thorough and repeated curetting and flushing with a 1-to-2,000 bichloride solution supplemented by scouring with aseptic gauze and dusting with iodoform. If the cavity be filled with olive oil and the oil be raised to a boiling point by the introduction of a thermo-cautery, the cavity is made aseptic.

The Filling of the Cavity with the Chips.—Place a capillary drain at the most dependent point of the cavity; carefully fill the latter with the bone chips and unite the soft parts over them with buried and subcuticular sutures and dress antiseptically. Before using, the bone chips of proper size to fit the cavity should be selected, wrapped in aseptic gauze, and immersed in alcohol to remove the ether and iodoform. Just before using, they are washed in a 1-to-1,000 bichloride solution, and cautiously wiped with iodoform gauze. If employed in cranial openings, they should be freely perforated to hasten drainage. If the soft parts be too scanty to cover the grafts, aseptic rubber tissue should be employed to remedy the defect.

The feasibility of bone transplantation *en masse* is not yet sufficiently established to warrant its being considered a matter of great practical utility.

CHAPTER IX.

AMPUTATIONS.—GENERAL CONSIDERATIONS.

AMPUTATION consists in the cutting off of a limb in the continuity of the bone structure or at an articulation ; the latter is often termed disarticulation. The aims sought for in amputation are : 1. The saving of the life of the patient. 2. The securing of a serviceable stump. If the prospects of recovery be annulled by the presence of a badly diseased or a mangled limb, it is no opprobrium to the art of surgery to remove the limb. If a limb be so badly injured or diseased as to require removal, it is wise that the mechanical ability of the designer of compensative appliances be considered, so that the patient may reap the combined benefit of the art of the surgeon and the ingenuity of the mechanic.

A stump, to be serviceable, should be sound, unirritable, with good circulation and abundant leverage. The first three qualities depend very largely upon the length, shape, vascular supply, and sensibility of the flaps ; the last one depends entirely upon the length of the bone. The flaps at the extremity of the stump after healing is completed should be freely movable—except at the seat of the cicatrix—over the subjacent tissues, not tightly drawn and smooth like a baseball cover. Flaps that are tightly drawn at the initial dressing soon become more tense, on account of tissue retraction and inflammatory action. The increased tension causes pain, early and rapid ulceration at the seat of the sutures, followed by separation of the flaps, union by granulation with a broad scar, and finally a troublesome stump ; or the normal shrinkage of the integument draws the flaps against the end of the bone, to which they, together with the cicatrix, become immovably united, causing similar difficulties. Integument normally exposed to pressure—as that of the palm of the hand and sole of the foot—makes the best covering. *The proper length of flaps*, therefore, becomes an important point in estimating the prospective usefulness of the limb and the comfort of the patient. As a general proposition, in flap amputation both flaps should be made the same length, each equaling not less than one fourth the circumference of the limb at the point where the bone is to be divided. If one flap only is employed it should equal in length the two flaps. Any decrease in the length of one flap should be accompanied by a proportionate increase in the length of the other. The lengths of the flaps control largely the site of the cicatrix. *It is advisable that the cicatrix be so placed*, when practicable, as not to be subjected to undue pressure or friction. If, however, the flaps be made of sufficient length to admit of the formation of a non-adherent

or movable cicatrix, its location is a matter of secondary importance. The length and situation of the flaps largely influence their circulation. If they are too long, the circulation will be enfeebled; if, on the contrary, they are too short, it will be impeded by the tension, causing in either instance a blue, cold, and shiny surface sensitive to the slightest injury. While the general rules just stated are a fair guide in establishing the proper length of flaps, still it is necessary not to lose sight of the fact that certain natural and acquired characteristics of the structure of a stump so modify its usefulness as to compromise the result of amputation unless these characteristics be given due recognition at the time of operation. The contractility of the integument and subcutaneous tissue is lessened by infiltration of inflammatory products, overdistention, old age, and atrophy. Integument thickened by friction, or naturally dense, contracts but little. On the other hand, if the integument be thin, or have scanty subcutaneous tissue, or be disconnected from bony or abnormal subjacent structure, the contraction is well marked. It is a matter of common observation that muscles contract when severed. The amount of their shortening is influenced by the length, size, vigor, and freedom of the muscle. Short, small, weak, or atrophied muscles, and those of limited movement, contract comparatively little. The degree and duration of primary and secondary muscular retraction often modify the final aspects of a stump, as will appear hereafter in the consideration of special amputations. *The nutritive integrity of a flap* and the freedom of the circulation are enhanced by attention to the proper degree of arterial supply and care in the preservation of the vessels. A too great compression with bandages, a vigorous bending or the undue traction of a flap to bring it into position, contribute fatally often to the integrity of the structure. *The severed ends of tendons* should not extend below the division of the remaining soft parts, nor should they be cut so short as to cause the empty sheaths to harbor deleterious products. *The nerves should be severed* high enough to prevent their ends entering directly into the cicatricial and reparative tissue at the end of the stump. *The periosteum should be neither bruised nor lacerated*, but cut neatly through at the point of bone section. *The bone itself should be sawed carefully and squarely* and not denuded of periosteum, otherwise circumscribed necrosis will occur. The removal of the cicatrix from direct pressure irritation suggests that those of the lower extremity have a lateral, and those of the upper a central location. However, it should not be forgotten that, notwithstanding the exercise of the greatest care in each of the foregoing respects, an untidy stump, or one belonging to a dissipated person, is very liable indeed to become the cause of great annoyance, if not of physical incapacity. The circulation even in a normal limb, or a portion of it, may be such as to predispose to a small and sluggish blood supply and thus impair flaps constructed from it.

The flaps are classified, according to the kind of tissues entering into them, as the *cutaneous or integumentary or skin flaps*, *musculo-cutaneous*, and *periosteal*, either variety of which may be single or double. The integumentary variety is commonly employed in this country. The outlines and structure of flaps have been changed so often, and yet so slightly on the whole, that

it is difficult indeed to assign rational reasons for the multiplication of terms and methods born of these alterations. Which makes the better flap, the skin and subcutaneous tissue alone or when combined with muscular tissue, is not yet definitely settled. It is fair to say, however, that the flaps of skin are less vital than when fortified with subjacent muscular structure. However, this fact is not of great significance except in the enfeebled circulation of the old, or in the presence of the necessity for an inordinately long flap. While it is true that the muscular tissue of a flap soon atrophies, yet it can not be denied that the fibrous residue of the muscle exercises a serviceable influence at the end of the stump. At all events, the integumentary portion should be considerably longer than the muscular part. Surely there can be but little doubt of the fact that the dangers incident to infection are less pronounced in integumentary than in muscular flaps.

Flaps are fashioned by, 1, transfixion, 2, by free deep cutting from without, and, 3, by superficial division and separation of their tissues. The

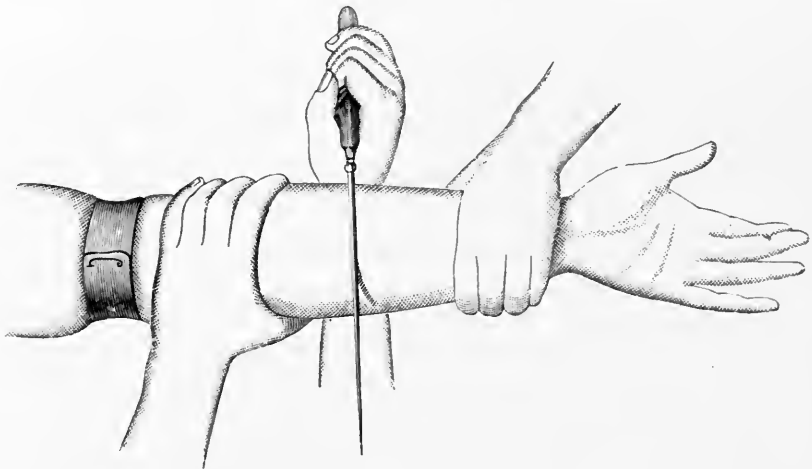


FIG. 473.—Circular method.

first two methods provide musculo-cutaneous flaps, the last one integumentary. The novice in surgery and the conceited surgeon regard it as derogatory to their attainments to trim or shape a flap after its division. It is far wiser, however, to make flaps of excessive length and suitably trim them thereafter, than to make them too short at the expense of the comfort and usefulness of the limb. The great danger is that flaps will be made too short rather than too long.

The methods of amputation are classified, according to the outlines of the incisions, into *circular, modified circular, elliptical* (page 460), *oval or racket, and common and special flap methods*. The flaps of these methods may be composed of integument alone, or combined with muscular tissue, and even with periosteum.

The Circular Method.—The circular method gives an admirable stump. It is easily and consequently frequently made, and is recommended especially

in the field operations of military surgery, since the lightness of the flaps permits transportation of the wounded with the minimum degree of disturbance at the seat of the amputation. It is performed by making an incision around the limb (Fig. 473) through the integument and subcutaneous tissue

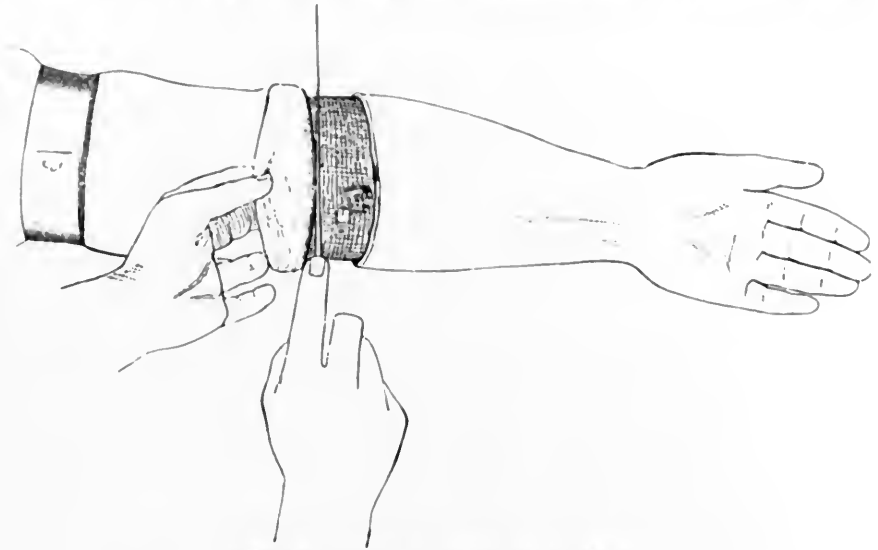


FIG. 474.—How to dissect up the flap.

down to the fascia of the muscles, at a distance not less than one fourth the circumference of the limb at the point of proposed division of the bone, and so directed that after contraction of the integument a circular flap will remain. The flap is then separated from the muscles with an ordinary scalpel, the edge being directed toward the muscles (Fig. 474) rather than parallel with them (Fig. 475), so that the capillary connection between the integument and the deeper tissues will not be injured un-

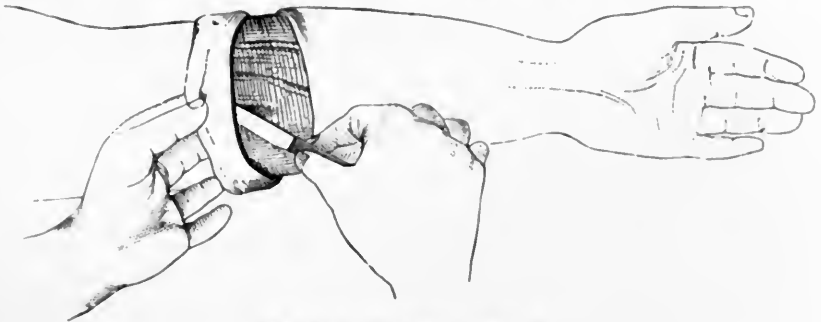


FIG. 475.—How not to do it.

necessarily. The separation should be done by circular sweeps of the scalpel and upward traction of the skin with the hand, rather than by mincing cuts, which hack the tissues and hinder union.

If the limb be of a conical shape, much difficulty will be experienced in turning over the sleeve of integument, which can, however, be obviated by a longitudinal division of the flap made usually at its most dependent por-

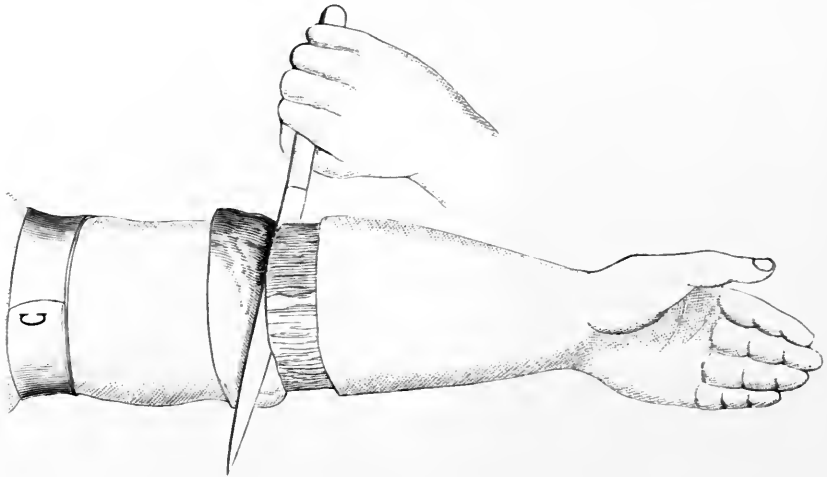


FIG. 476.—Division of the muscles close to reflection of flap.

tion. The flap should be turned upward to the point where the bone is to be divided; then, with a suitable knife, make a circular division of the muscles down to the bone, beginning far enough below the reflection of the flap to allow for the retraction of the divided muscles. While no definite law can be assigned as a guide to this part of an amputation, still, as already stated, muscles retract according to their size, length, degree of irritability, etc. The points of section of special muscles will be stated in the description of the amputations requiring it. Not infrequently the muscles are cut just below the reflection of the flap, as in Fig. 476; this plan is not, however, as good as that in which a lower division is practiced, since sensitive stumps are more liable to result therefrom (Fig. 477). A conical stump is a not infrequent sequel of this method of amputation, and is the result of an equal division of unequally retractile tissues. In those parts where the bone is located centrally—in the arm and thigh—the superimposed muscular structure should be divided by repeated circular cuts, so as to create a funnel-shaped stump with the end of the bone at the summit (Fig. 634). A stump thus fashioned affords good drainage, and reduces the liability of protrusion of the bone to a minimum. The bone should be sawed at its highest point of exposure.

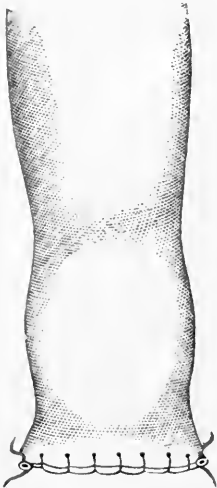


FIG. 477.—Stump after circular amputation.

The Modified Circular Method.—The circular method may be modified by making one or more longitudinal incisions through the integumentary structure down to the circular cut. A posterior longitudinal incision (trans-

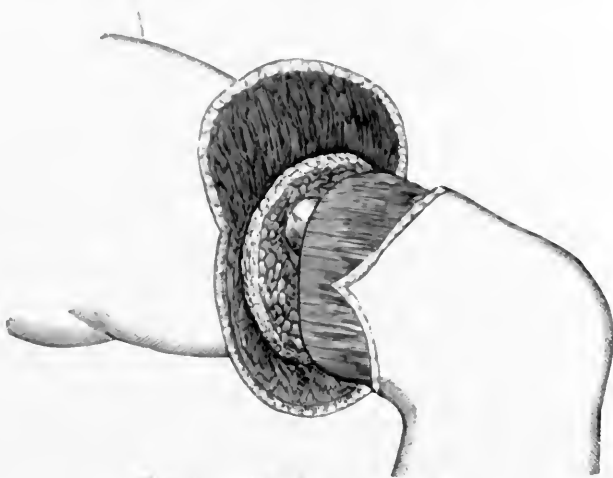


FIG. 478.—Modified circular flap.

verse racket flap) facilitates the turning up of the flap, and offers an admirable opportunity for drainage. An anterior longitudinal incision is not to be commended. One made at either side of the limb down to the circular cut forms square antero-posterior flaps which possess no advantage over the lateral variety.

The following plan was suggested by Mr. Liston. He made semilunar flaps, which were dissected up to their points of junction with each other, at which level the muscles and bone were divided, as in the circular method. Liston's method was afterward modified by Mr. Syme, who dissected a short distance above the points of juncture of the flaps, and divided the muscle and bone as before (Fig. 478). In either instance, however, it amounts substantially to slitting up the cuff of a circular flap on opposite sides and trimming off the angles caused thereby.

The Oval or Racket Method.—The oval or racket method is in reality a modified circular amputation, the flap being slit up at one side and the angles trimmed off (Fig. 479). This flap is employed principally in disarticulations, and will be described in connection with those operations. Oval-shaped flaps may be either unilateral, bilateral, anterior, or posterior.

The Single-flap Method.—The single flap is suited to those cases where the tissues of one side of a limb only are available for the purposes of a flap, as in the case of unilateral lacerations, ulcera-

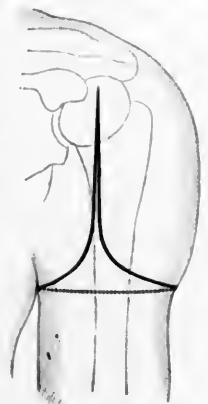


FIG. 479.—Racket flap at shoulder.

tions, etc. This flap may be composed of the muscular tissues and integument, or of integument alone (Fig. 616), and can be made either by transfixion or division from without. If possible, a short convex flap is made on the opposite surface of the limb.

The *double-flap method* is performed by transfixion, and includes the muscles down to the bone on either aspect of the limb (Figs. 480 and 481). The tissues to be transfixed are raised slightly by the left hand of the operator, who then enters the point of the knife at the side nearest himself, pushing it through slowly in close contact with the anterior surface of the bone, slightly raising the handle as it passes in front of the bone, thereby causing its point to emerge at the opposite side of the limb at a point exactly opposite to that of entrance; the flap is then made by cutting with a sawing motion obliquely upward and forward. This flap is pulled backward by an assistant, and the knife is reinserted at the original point of entrance, carried behind the bone, handle depressed to cause the

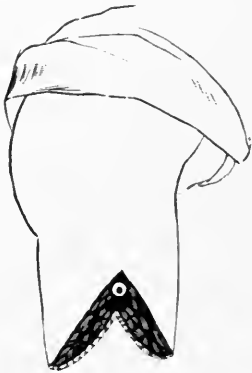

FIG. 480.—Flaps by transfixion.

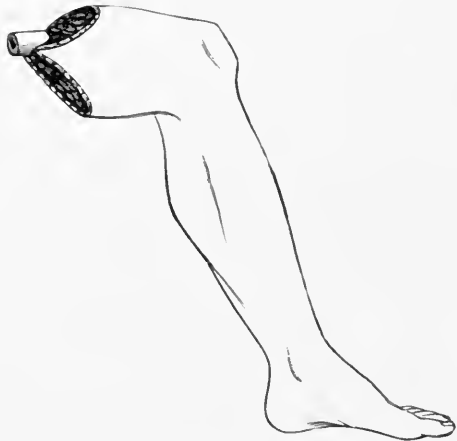

FIG. 481.—Removal by transfixion.

point to emerge at the same situation as at the anterior transfixion, and the posterior flap made by cutting obliquely upward and backward. Each flap should correspond in length to at least one half the diameter of the limb. The retractor is then applied, the soft tissues are drawn well upward, the remaining fibers in contact with the bone are severed by a circular sweep of the knife, and the bone is carefully sawed through. When lateral flaps are made, the flap containing the large vessels should be constructed last.

The *mixed double flap* is a modification of the preceding, and sometimes called Sédillot's method. The flaps are made by transfixion, as before, but are more superficial, the knife not being brought in contact with the bone. The remaining muscles and vessels are divided by a circular incision, and the amputation completed as before described. In this instance the flaps are thinner and shorter than in the preceding.

Langenbeck's Method.—Langenbeck's method differs from the last one only in the manner of obtaining the result, the flaps being cut from the surface toward the center of the limb, thus affording a better opportunity to shape them. Another modification of this method consists in cutting the

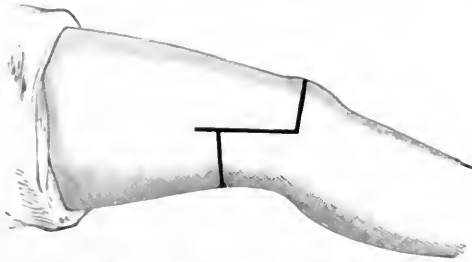


FIG. 482.—Teale's method.

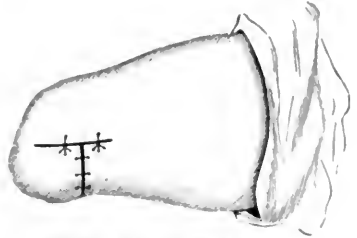


FIG. 483.—Teale's stump.

anterior flap from the surface, and making the posterior flap afterward by transfixion.

The Rectangular Flap (Teale's Method) (Figs. 482 and 483).—In Teale's method two rectangular flaps are employed, one being four times longer than the other; both flaps include the structures down to the bones. The longer flap is taken from the surface of the limb where the bone is the most superficial. The shorter contains the important vessels. The length and

breadth of the long flap each equals half the circumference of the limb at the point of proposed amputation. The width of the short flap is a half, and its length an eighth, of the circumference of the limb at the point of bone section. Both flaps should be carefully marked out before beginning the operation. This method makes an admirable stump, but sacrifices fulcrumage, and therefore can be employed only at special parts of the body, and when the tissues at one aspect of the limb only are healthy and suitable for flaps. *Mr. Lister* recommends that the longer flap be made a third and the shorter flap a sixth of the circumference of the limb in length, thus bringing the cicatrix at the edge of the stump; also that the posterior flap shall consist of the integument and subcutaneous tissues alone. *Lister's*, like *Teale's*, method may be employed when the loss of tissue is greater upon one side of a limb than upon the other.

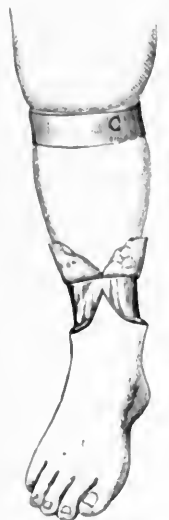

FIG. 484.—Bilateral-flap method.

The Hood Flap.—The hood flap resembles very closely indeed the racket flap (Fig. 617). There is therefore no substantial difference in the plan of construction of this and that of the circular flap, if the latter be slit up at the most dependent part and the resulting corners rounded off. This

method meets the indications requisite for a good stump as well as any variety of flap.

The Equilateral Flaps (Fig. 484).—Equilateral flaps are formed of skin and are oval in outline, the posterior angle being located somewhat farther

up the limb than the anterior, to improve the drainage. The muscles are cut by a circular sweep at a suitable distance below the point of reflection of the integumentary flaps, and the bone is exposed and sawed somewhat above the anterior point of junction of the flaps.

The Periosteal Flap.—A periosteal flap is properly made by raising the periosteum, in conjunction with the tissues which rest upon or are attached to it (Fig. 638), so as to cover the end of the divided bone, after which it is allowed to fall into place. If a periosteal flap be raised independently of superimposed tissues, it is very liable to waste away or slough outright (Fig. 485, a). This variety of flap is adapted best to those bones subcutaneously located, like the tibia, and will be again referred to in connection with amputations of the leg.

A periosteal flap will, if it become adherent to the end of the bone, preserve it from atrophy, and lessen the danger of the formation of a conical stump; it likewise prevents the adhesion of the scar to the bone, thereby forming the basis for a movable cicatrix.

If the patient be young, new bone may be developed from the periosteal flap, which will add much to the usefulness of the stump. It is claimed by some that bony spiculæ often shoot into the soft tissues at the end of the stump, and require a second operation for their removal. It is our opinion, however, that if the periosteum be removed entire and remain connected with the superimposed tissues, and be so placed that the force of gravity will aid in holding its bone-producing surface in contact with the divided end of the bone, this danger will be obviated.

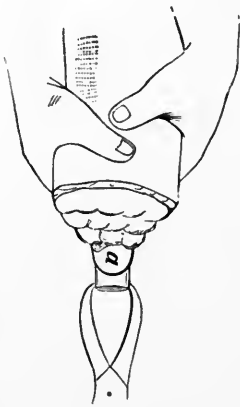


FIG. 485.—Improperly made periosteal flap.

The Comparative Merits of Different Forms of Flaps.—The principal aims sought in making flaps are: 1. To secure good drainage. 2. To make the flaps of suitable length, that the circulation and movement of the integumentary cushion at the end may be unrestrained. 3. To place the cicatrix beyond the point of friction, and prevent its adhesion to the end of the bone. 4. To guard against any danger of undue sensibility, by making the flaps of proper length, and by drawing down and cutting off the cutaneous and other nerves of larger size that may exist in them.

With these aims in view, it will be seen that the old-fashioned circular flap affords equal advantages, in proper sites, to the others, and is commendable for its simplicity and rapidity of execution. It is true that in this method the scar will fall on the end of the stump, but with proper precautions as to the length of the flaps and suitable surgical attentions, any danger from this source is reduced to a minimum. As Treves very justly says, "It is difficult to claim an unreserved superiority for any one method." While in one situation the circular amputation is undoubtedly the best, in

another it is with equal certainty the least efficient method of procedure. The same may be said of any one method of performing amputation by the cutting of flaps.

The main commendatory points in the selection of a method of amputation are the following: 1. The method should be one attended with the

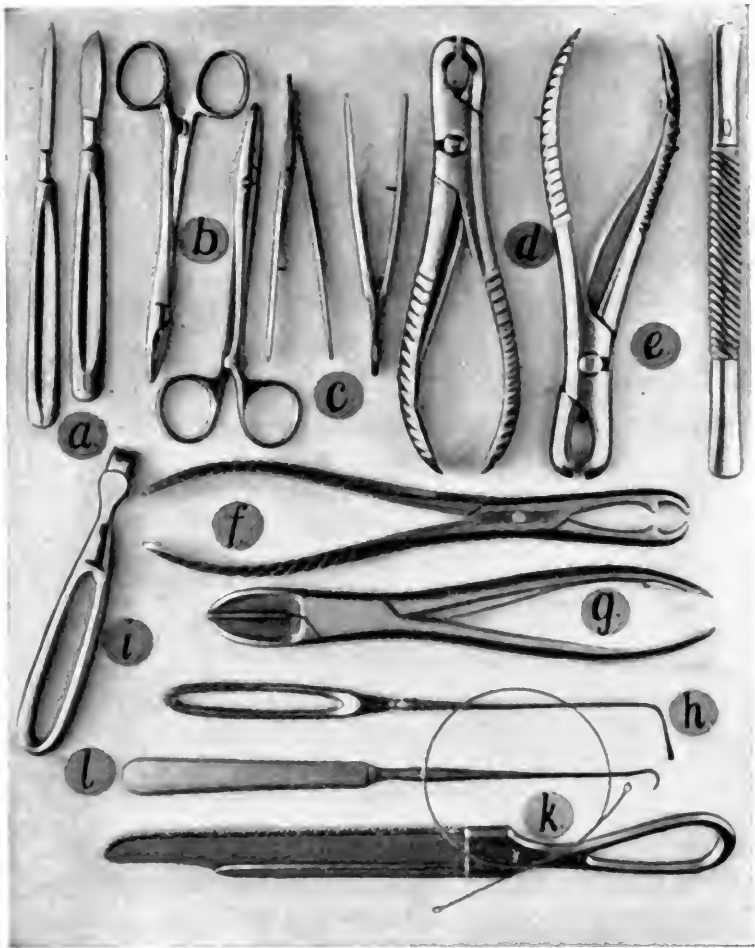


FIG. 486.—Instruments employed in amputation.

- a.* Scalpels. *b.* Forcepressure. *c.* Thumb forceps. *d.* Curved and straight rongeurs. *e.* Periosteotome. *f.* Lion-jaw forceps. *g.* Liston's bone-cutting forceps. *h.* Aneurism needle. *i.* Ruginé. *j.* Tenaculum. *k.* Lifting-back and Gigli-Haertel's saws. Retractors (page 50), needle-holders (page 100), needles, sutures, drainage, etc., are required.

least sacrifice of the healthy tissues of the limb, while providing a good and permanent covering for the bone. 2. One causing as small a wound area as is consistent with its proper performance. 3. One securing a good blood supply to the flaps and tissues which form the stump. 4. One followed by a well-adjusted and painless cicatrix. Therefore the line of coop-

tation should be so placed as not to interfere with the healing process, while securing at the same time efficient drainage, and removing the cicatrix from pressure as far as possible when the stump is healed. 5. One providing easy exposure of the bone at the saw line, and having simplicity of method.

6. One permitting of the cutting of the main vessels transversely, and allowing of rapidity in the operation.

Since many of the preceding forms of flaps are but modifications of the circular variety, they inherit the advantages of their distinguished progenitor. However, the circular method is not the best if the soft parts near the injury, disease, or distortion be unequally involved, as then a sacrifice of the healthy tissue of the opposite side of the limb is required. It is clearly obvious that an irregular flap method is suited for these cases.

The agents required for amputation are those for arresting hæmorrhage, for the division and trimming of the soft parts and the bone, and those for uniting and dressing the wound. The preparation of the surgeon (page 113 *et seq.*) and patient for the operation, the agents for controlling and arresting hæmorrhage (page 65 *et seq.*), together with the various methods of securing and maintaining the coaptation of the cut surfaces (page 96 *et seq.*), drainage, and various forms of dressing, antiseptic and otherwise, have been heretofore considered, therefore, there remain to be enumerated under this heading only those instruments especially adapted to the requirements of amputation.

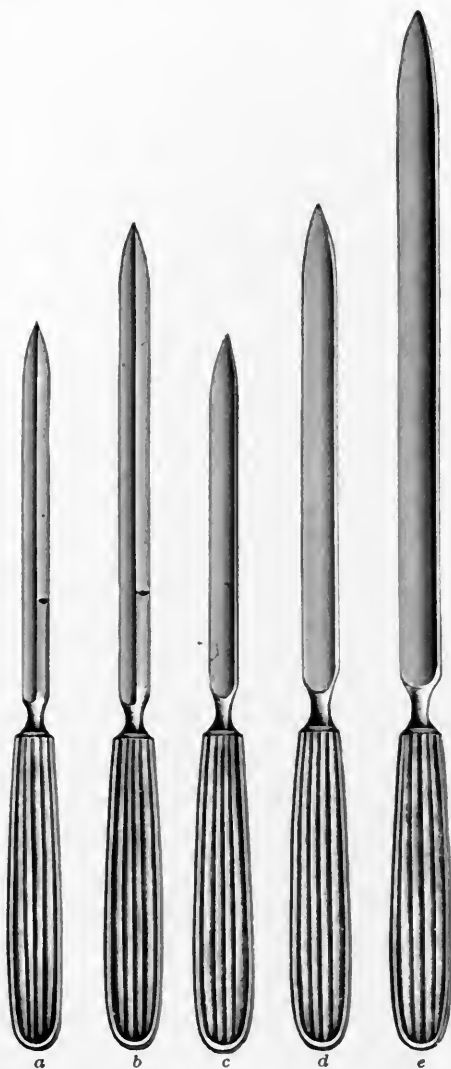


FIG. 487.—Amputating knives.

The instruments (Fig. 486) are amputating knives, scalpels, saws, lion-jaw forceps, periosteal elevator, special metal retractor, tenaculum, and a support for the stump.

The Amputating Knives (Fig. 487).—The modern amputating knives can be used for making circular flaps, or for transfixion. Some are single-

edged, others may be double-edged (*a, b*) entirely (Catlin), or only for an inch or two from the point. The length of the knife selected will depend upon the size of the limb to be operated upon, and should be about one and a half times the diameter of the limb. While it may be inconsistent with good taste, it is entirely consistent with good judgment and economy to amputate an arm or forearm with the knife intended for use at the thigh, and the result will be equally satisfactory. On the other hand, the absence of the stereotyped amputation knife constitutes no good reason for the deferment of operation in the presence of the wisdom of prompt action and the possession of one or more scalpels.

The manner of grasping the amputating knife, prior to and during the division of the soft parts, may add much to the general effect of the procedure and to the comfort of the operator. The knife should be grasped lightly at first with the edge looking forward, near enough to the extremity of the shank to permit the upper end of the handle to play between the heads of the metacarpal bones of the thumb and index finger when swung backward and forward (Fig. 488). *Two methods are employed* of carrying the knife entirely around the limb: 1. Stand with the left side toward the patient, seize the limb above the point of intended operation with the left hand, an assistant holding its distal extremity; place the left foot forward, slightly bend the right knee, and with the knife held by the right hand, as before described (Fig. 489),

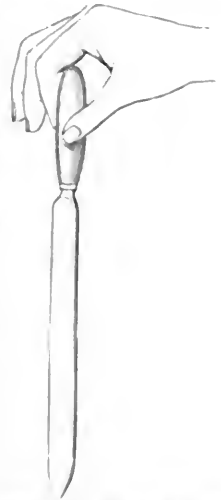


FIG. 488.—How to grasp amputating knife.

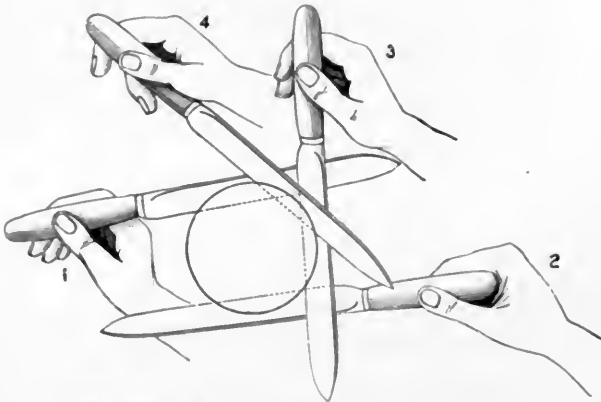


FIG. 489.—How to carry knife around limb.

stoop downward and forward sufficiently to carry first the knife and forearm *under*, and then the knife over the limb, placing its heel as near to the upper surface of the limb as is convenient, when, with a sawing motion, the knife is drawn toward the operator beneath the limb, then upward

between it and the operator, and so on around until it joins the beginning of the cut, making a complete circular division. If the knife be properly grasped, the handle will pass readily between the thumb and forefinger as the hand passes around the limb, enabling the surgeon to

ease, and without the least man-
make the section with perfect
ifestation of stiffness. 2. The
method may be reversed by
first passing the hand and knife
over instead of under the limb
(Fig. 490); otherwise the ma-
nipulations are the same. The
latter plan, however, is less nat-
ural, besides which it exposes
the arm of the operator, and the
integument to be divided last,
to the flow of blood. If the
handle of the knife be grasped
firmly between the thumb and
two fingers, and carried around
the limb with a deliberate long
sawing motion, accompanied
with firm application of the
edge to the tissue, the cutting
depth can be easily regulated.
If the operator be not acquaint-
ed with the technique of this
method he

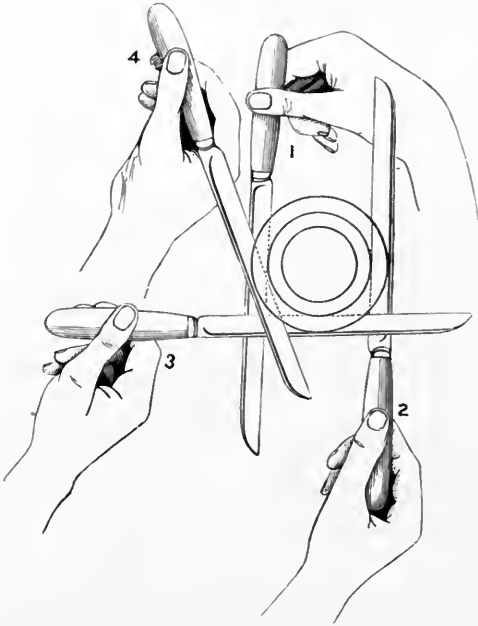


FIG. 490.—Another method.

can soon familiarize himself with it by passing the knife around the limb as described with the *back* of the blade against the surface. The method commonly employed and figured in text-books (Fig. 491) is stiff and awkward at the outset, and as the knife advances in its course the operator's posture and expression become both unnatural and labored.

The Catlin (Fig. 487, a, b).—The Catlin is employed chiefly to divide the tissues in the interosseous space in amputations of the leg and forearm. It can be readily supplanted for this purpose by the single-edged narrow knife, provided the latter be withdrawn to complete the division of the interosseous tissues instead of changing the direction of the cutting edge while the blade yet remains between the bones. The latter act will bruise and tear the interosseous tissues.

The Scalpels.—Two or three ordinary scalpels should be at hand for use in separating the flaps (Fig. 486, a).

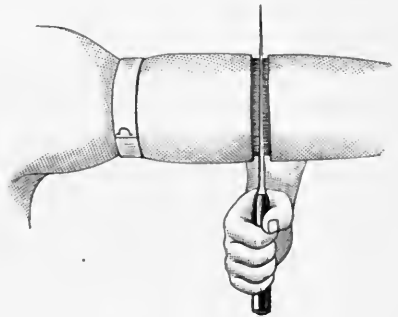


FIG. 491.—A common method.

A knife with a long narrow blade is the better for amputating at the phalangeal articulations.

The Saws.—The ordinary broad-bladed saw (Fig. 492) and the bow-backed (Fig. 493) are in common use. The first meets all requirements



FIG. 492.—Broad-bladed saw.

except in certain excisions, when either the chain saw (Fig. 376) or Butcher's saw (Fig. 494) must be employed. The Gigli-Haertel, and the narrow, lifting-back saws (Fig. 486, *k*), are of use in severing small bones and spiculæ.

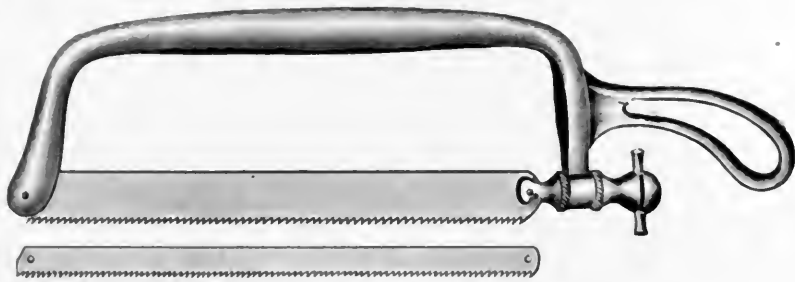


FIG. 493.—Common bone saw.

The proper method of using a saw should be given some attention (Fig. 495). After the division of the soft parts the surgeon grasps the saw firmly, places its heel on the bone close to the border of the retracted muscles in a

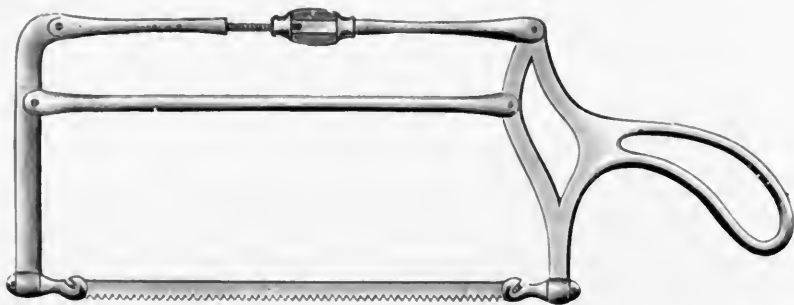


FIG. 494.—Butcher's bone saw.

line made through the periosteum by the knife, and, while guided by the thumb nail applied at the saw-point, slowly and carefully draws it backward along the first four or five inches of its edge, then raises it from the track, and places it as before, repeating the operation until a track of sufficient

depth is made to retain the saw in place during to-and-fro movements; these should be made by quick, sharp, but not rapid strokes, until the bone is nearly severed, when care must be taken, or the saw will be clamped and the remaining portion of bone broken off. If the handle of the saw be raised and the remaining portion be divided at a different angle with the bone, the danger of the breaking is lessened. When two bones are to be sawed off, the saw should be started in the less movable bone and then turned so as to include both for a time, when either may be sawed independently of the other. If the movable bone clamp the saw, cut off the solid one

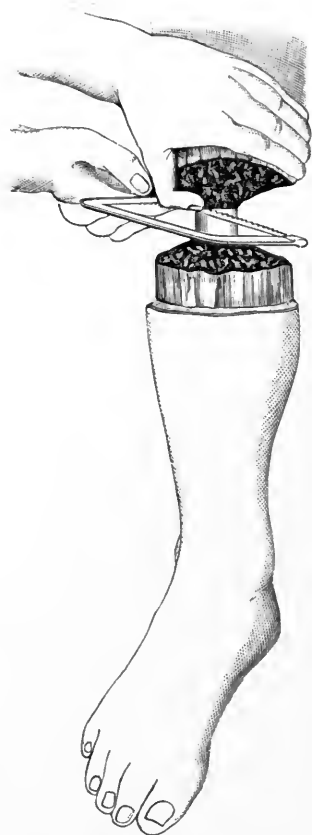


FIG. 495.—Sawing the bone.




FIG. 496.—Retractor for two bones.

first; this course gives better final command of the movable bone. The proximal and distal portions of the limb should be firmly supported during the division of the bone, care being taken not to hold the limb in such a manner as to clamp the instrument during the final act of the sawing.

The Bone Forceps.—Liston's cutting forceps are used for trimming off rough bony prominences. Fergusson's lion-jawed and Farabeuf's forceps (Figs. 375 and 378) are excellent instruments for grasping the bone to steady the part, and are also used for removing bone by twisting, when great force is required.

The Periosteal Elevator and Rugine (Fig. 486, *c, i*).—Although these instruments are convenient for the purpose of raising periosteum for flaps, yet they are not necessary, as the same can be accomplished with the end of the metal handle of a scalpel.

The Cloth Retractor.—The cloth retractor is made of linen or ordinary muslin, fashioned, by tearing, according to the size and anatomical arrangement of the limb to which it is applied. If for two bones, one extremity of the retractor should be torn into three strips (Fig. 496), the middle one for use between the bones (Fig. 497), the remaining ones to be carried around them. If but one bone be present the retractor is torn partially through the middle (Fig. 498), and applied as shown in Fig. 499.

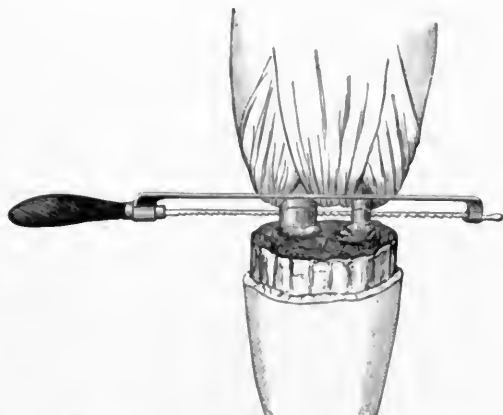


FIG. 497.—Three-tailed retractor applied.




FIG. 498.—Retractor for one bone.

A *special metal retractor*, devised for use at the thigh and arm, is worthy of employment. It consists of two thin slotted plates of metal so fashioned that they will simultaneously grasp the bone and retract the flaps when properly joined and firmly held by the rings (Fig. 500). After the soft parts are divided down to the bone, the bone is grasped at that point by the opposing slots of the respective plates, which are then drawn upward by the rings against the muscular tissue (Fig. 501). This retractor protects the muscles during division of the bone, is an admirable guide for the saw, and enables the assistant to firmly hold the proximal portion of the limb while the bone is being severed.

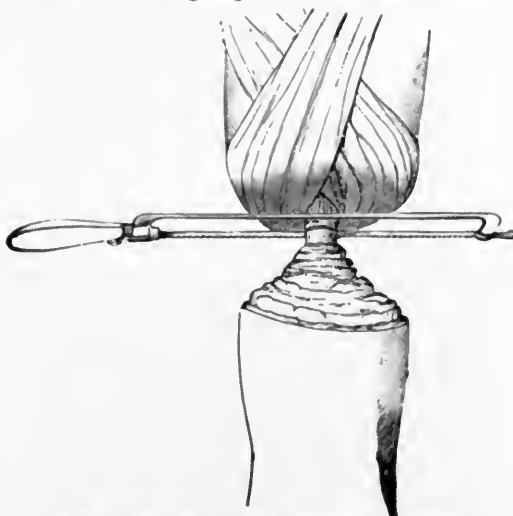


FIG. 499.—Two-tailed retractor applied.

A *tenaculum* should be at hand for the purpose of picking up small bleeding points of severed vessels for the purpose of ligature when necessary.

The Aneurismal Needle (Figs. 175, 177, and 178).—Not infrequently this implement is needed to aid the surgeon in tying collateral branches

which arise so close to the ligature as to imperil the formation of a proper clot. In diseased vessels this precaution is of greater significance than in healthy.

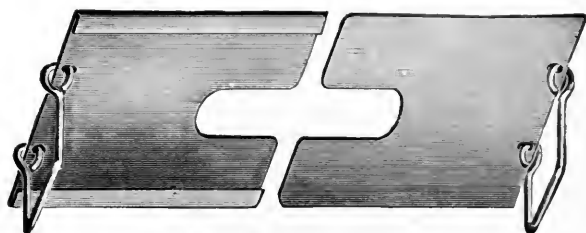


FIG. 500.—Metal retractor, open.

wood, or pads of special device, or an ordinary pillow, should be provided and confined to the limb with rollers. This support steadies the limb and at the same time affords a ready means of handling the stump. In lieu of this the limb may be swung from a cradle by elastic or inelastic suspension, which, although it adds to ease of movement and comfort, does not always control properly muscular contraction.

The Comments.—Before beginning an amputation the operator should rehearse, in his mind at least, the entire operation, as he contemplates it; by doing this he will be quite certain to anticipate the details and complications of the procedure. The surgeon should plan his work with careful precision, even to marking out on the limb the outlines of the flaps, and such other incisions as may be required. We are aware that this is seldom practiced, even by the most experienced surgeons; but, within our own observation, had it been done better results might have been secured. The young surgeon, too, often fancies that to do this proclaims himself as ignorant and inexperienced; such, however, is not always the case; it rather serves to emphasize his cautious and painstaking qualities. An amputation should be done without haste, when the safety of the patient will permit, remembering that it is done quickly when it is done well.

The operator should stand in such relation to the patient that the left hand can readily control any undue hæmorrhage by compression or otherwise.

The primary incision should be located, if possible, so that the escaping blood will not obscure the course of the incisions subsequently made.




FIG. 501.—Metal retractor, closed.

The division of important vessels should be made last, when possible.

The tissues should not be retracted until after complete division, if practicable.

In flaps made by transfixion the tissues constituting them are raised or

depressed, according to the aspect of the limb from which the flaps are made. Those in front of the bone are raised, those behind depressed.

After the limb is removed, the open mouths of the vessel should be caught by forepressure, forceps, etc., after which the control of the circu-

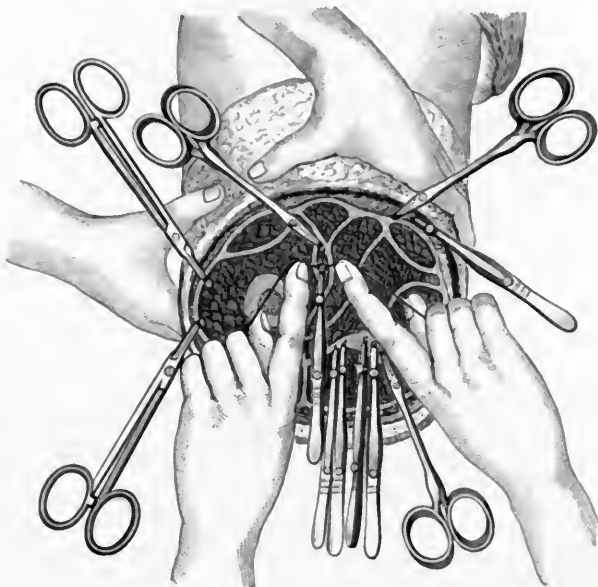


FIG. 502.—Catching and tying bleeding points.

lation is slowly relaxed, and all bleeding points arrested as they appear by suitable means (Fig. 502). The surgeon can then proceed deliberately to ligature the vessels thus secured. *The open ends of tendinous sheaths should be closed by suturing to exclude infection.*

AMPUTATIONS AT UPPER EXTREMITY.

The General Remarks.—In amputations at the carpus and digits it is important to remember that usefulness and symmetry are the ends to be attained. If strength and usefulness be the desiderata, the insertions of the muscles and ligaments that endow the part with important functions should be preserved (Fig. 503).

It is therefore imperative that the surgeon carefully study the functions of the important muscles associated with the hand, and preserve if possible their points of insertion. The surface markings of the palm and of the digits (Fig. 504) and the relation of the web of the fingers to the heads of the metacarpal bones and to the vessels are important. It is a well-established principle that every portion of the hand of a laboring man which possesses motion and can become of service to him should be saved. In the case of one whose circumstances or vocation will permit, the sacrifice of usefulness to symmetry may, with the concurrence of the patient, be made.

Amputation at the Phalangeal Articulations (*Disarticulation*). *The Anatomical Points.*—The first row of surgical phalanges is flexed by the terminal insertions of the flexor profundus digitorum; the second, by those of the flexor sublimis digitorum; the third, by the flexor sublimis, through the *vincula accessoria tendinum*, by dense fibrous bands connecting the tendons of the flexor sublimis with the distal extremity of that row (Fig. 505), also by the secondary action of the lumbrical muscles and interossei on the extremities of the bones of this row.

The terminal phalanx is amputated by seizing and flexing it to a right angle with the second (Fig. 506); an incision which opens the joint is then made on its dorsal surface, on a line corresponding to the transverse diameter of the second phalanx. Divide the lateral ligaments with the point of the knife; separate the articular surfaces, and pass the blade between them; cut along the under surface of the phalanx to be removed, close to the bone

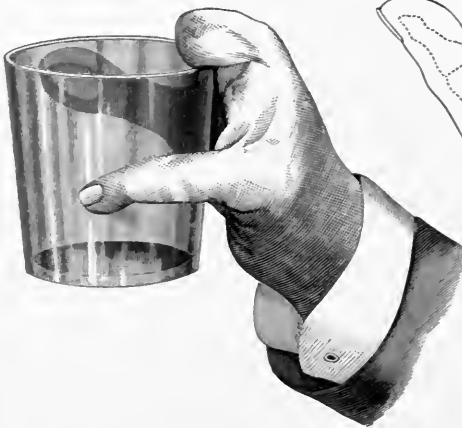

FIG. 503.—Conservatism illustrated. Thumb, stump of index finger, and the little finger remaining.

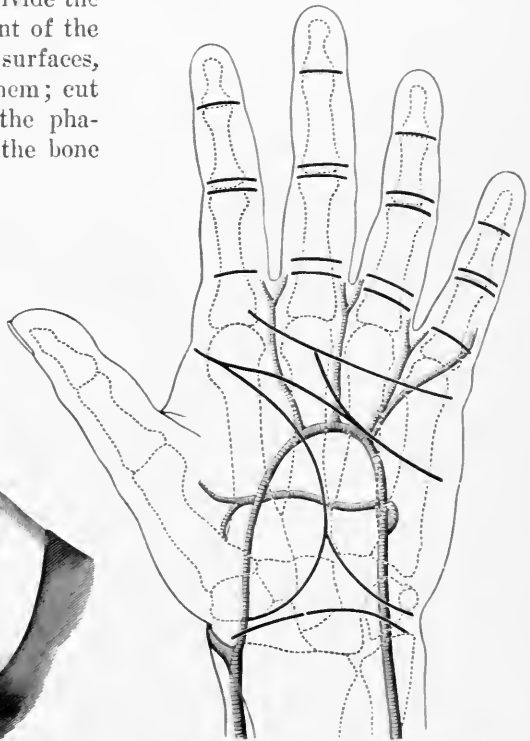


FIG. 504.—Surface markings of the palm of the hand.

(Fig. 507), far enough to make a palmar flap of sufficient length to easily cover the end of the stump (Fig. 508). The application of the rule previously given regarding the length of flaps will enable the operator to meet this requirement. If the base of the flap be first formed by dividing the tissues at each side of the phalanx, for three or four lines down to the bone, the knife will then hug the under surface of the bone in making the flap without cutting the base of the flap too narrow, which otherwise would occur on account of the proximal extremities of the phalanges being thicker

than their bodies. Remove the flexor tendon from the flap, tie the vessels, close the open end of the tendinous sheath with a suture, confine the flap in position with two or three fine sutures, and dress antiseptically.

The amputations at the second row can be performed in precisely the same manner as the first; or, with the finger extended, transfix the soft

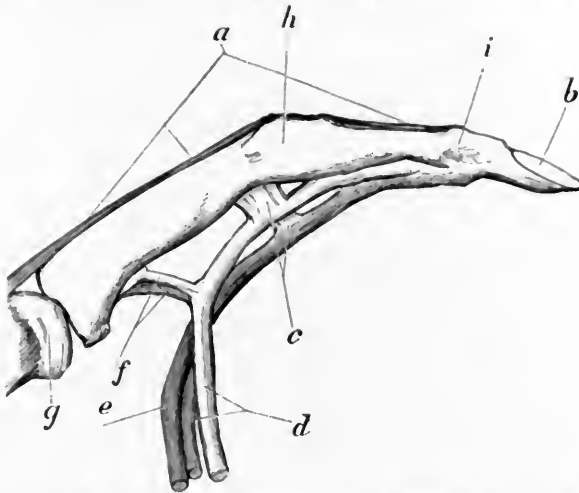


FIG. 505.—Attachments of tendons to phalanges. *a.* Extensor communis digitorum. *b.* First surgical phalanx. *c.* Fibrous bands between common flexor tendons and distal extremity of the third surgical phalanx. *d.* Tendons or flexor sublimis digitorum. *e.* Tendon of flexor profundus digitorum. *f.* Vincula accessoria tendinum. *g.* Head of metacarpal bone. *h.* Joint between second and third surgical phalanges. *i.* Joint between first and second surgical phalanges.

parts on the palmar surface opposite the joint, and cut downward until a well-rounded flap of proper length is formed (Fig. 509). Then carry the knife upward between the articular surfaces and through the soft parts on the dorsum. The transfixion method is objectionable, because the vessels may be split or the flap be imperfectly formed (Fig. 510).

The Remarks.—Either of the phalanges may be amputated at the center by a short dorsal and a long palmar flap. If a third surgical (first anatomic)



FIG. 506.—Flexed phalanx. FIG. 507.—Making flap. FIG. 508.—Flap completed.

cal) phalanx be amputated at the center, the power of flexion is limited to the lumbrical and interossei muscles and the vincular tendons connecting the base of the phalanx with the flexor sublimis digitorum. These connections can be supplemented wisely by stitching the divided tendons to the contigu-

ous theca. The division at this situation is regarded by many as objectionable practice, disarticulation being preferable. These anatomical facts have led the writer to amputate frequently in the continuity of this phalanx, and always with entirely satisfactory results. If symmetry be a primary consideration, this method of amputation can not be commended. In the case of the thumb, the index and little fingers, whatever adds usefully to the length of the digits should be saved, as the range of motion of the thumb and little finger is more extensive than that of the others, and the presence of the index finger or its stump greatly aids a crippled thumb in the performance of its functions. However, it should not be forgotten that it is not wise to make unnecessary sacrifice of a portion of any phalanx, as this portion may be of great prehensile service in conjunction with a crippled thumb—at all events of more use than the most ingenious artificial device. The phalanges are amputated frequently by flaps fashioned according to the demands of the case. Unequal flaps at both surfaces of the finger, and those of single or lateral pattern, can be employed when required. It is better at all times to subordinate symmetry to the attainment of prehensile advantage. It is better that transfixion in making flaps from the

digits be not practiced, because when thus made they are often ill fashioned and may contain tendinous tissue. The Gigli-Haertel saw is the best agent for dividing the bone; bone-cutting forceps often crush and splinter it. The free communication of the synovial tendinous structures of the little finger and

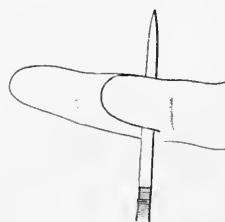


FIG. 509.—Flap by transfixion.

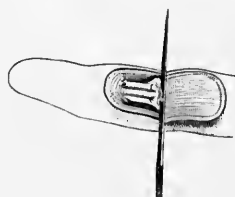


FIG. 510.—Opening joint.

the thumb with those of the carpus (Fig. 369) explains the occasional extensive inflammation which follows injury of these digits. It suggests also closing their open ends with a suture, or by sewing the divided tendons to them. The open ends of the sheaths of the remaining tendons should be treated in like manner, although they terminate in blind, noncommunicating extremities at the lower part of the palm.

Amputation at the Metacarpo-phalangeal Articulations.—It is recommended by some that this operation be practiced in lieu of amputation at the middle of the third phalanges (surgical) of the second and third fingers, or even disarticulation between the second and third phalanges.

We are satisfied, however, that the hand will be far stronger if the stump be allowed to remain, since it is soon easily flexed and extended, and the continuance of these motions serves to stimulate and nourish the common muscles engaged in performing them, and thereby strengthens the power of the remaining fingers.

Amputation of the Second or Third Fingers.—Amputation of these fingers at the metacarpo-phalangeal articulation is done by the oval-flap method, and the flap should be marked out before the operation is com-

menced (Fig. 511). The flaps must be taken from the finger to be removed, and should be of generous dimensions. The limit of the incision above corresponds to the head of the metacarpal bone, the lower limit to the transverse line of the palm joining the fingers to the web. Separating widely the contiguous fingers, seize the condemned finger, extend it well, and carry the incision transversely along the line beneath, then in a curved direction upward along the side of the finger to the head of the metacarpal bone. This incision is repeated on the opposite side, the tissue carefully divided, and the finger removed (Fig. 512). The transverse palmar incision can be made (Fig. 514, c), and many prefer that variation. Better drainage will be secured if the flap be reversed by forming its retiring angle on the palmar instead of the dorsal surface of the hand (Figs. 513 and 514).

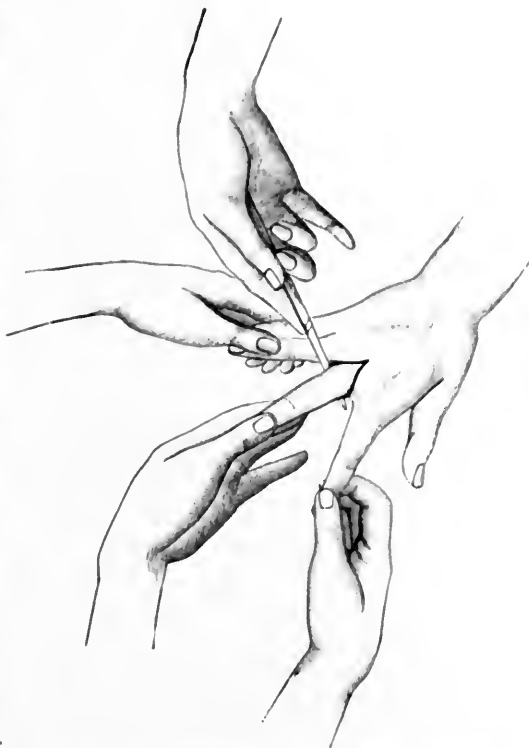

FIG. 511.—Amputating second finger, oval flap.

The Lateral-flap Operation.—The lateral-flap operation is best adapted to the thumb, index, and little fingers (Fig. 513); it can, however, be employed at the ring and middle fingers. The limit of the dorsal incision is the same as in the preceding. The lower limit, after crossing the transverse line of the web, extends toward the palm about a third of an inch. The flaps are taken from the sides of the finger to be removed.

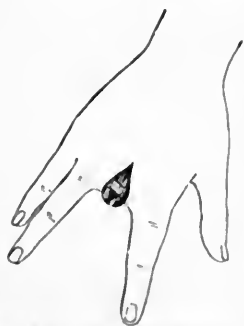

FIG. 512.—Finger removed.

In the case of the middle and ring fingers the flaps should be equilateral (Fig. 514, d). For the thumb, index, and little finger, that portion of each digit against which pressure is most constantly brought should be covered by the longer flap, which is taken respectively from the outer surface of the index finger, the inner surface of the little finger, and from the palmar aspect of the thumb, the base of the flap being on a level with the joint (Fig. 514, a, b, e). The longer one is dissected off,

after which the smaller one is made. Divide the ligaments and tendons and remove the digit.

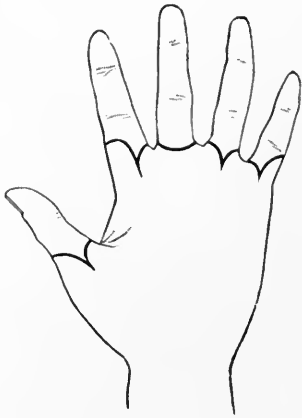

FIG. 513.—Appearance of flap at palmar surface.

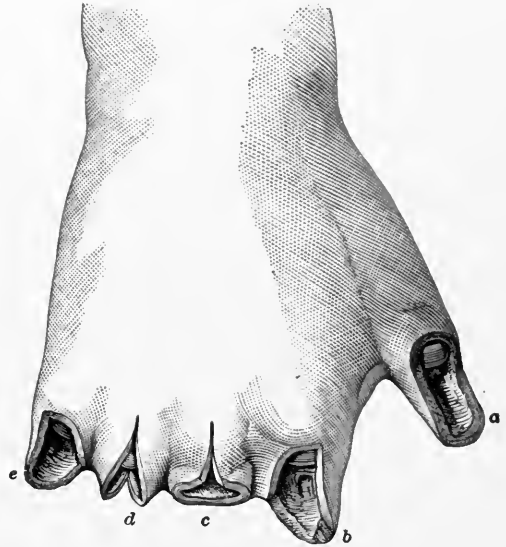


FIG. 514.—Flaps in disarticulation of fingers. *a.* Long palmar flap. *b.* Long external flap. *c.* Circular method, dorsal incision. *d.* Lateral flaps. *e.* Long outer flap.

Amputation of the Thumb, Little, and Index Fingers at the Carpo-metacarpal Articulation. *The Oval Method.*—The oval method can be employed equally well with the thumb, index, and little fingers. The limit of the dorsal incision in either instance is the proximal extremity of the metacarpal

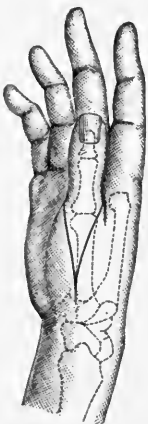


FIG. 515.—Oval method.

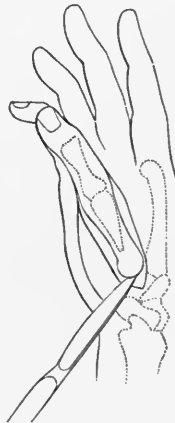

FIG. 516.—Opening the joint.

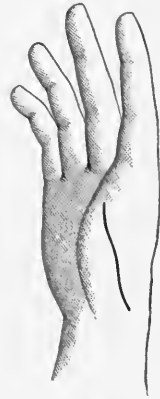

FIG. 517.—Wound united, linear cicatrix.

bone to be removed. The upper or palmar limit is the transverse line at the junction of the finger with the palm. On removing the thumb by this

method begin the first incision at the base of the metacarpal bone of the thumb (Fig. 515), carrying it along in a slightly curved direction to the outer side of the metacarpo-phalangeal articulation, then inward through the line of the web. The second one joins the first near the base of the metacarpal bone, and takes a corre-

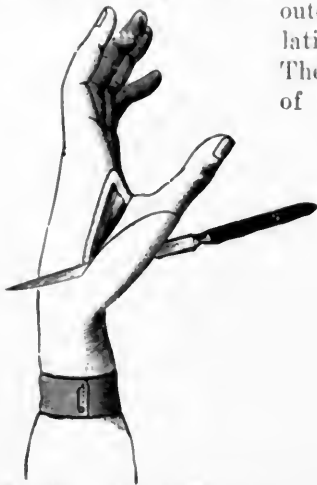

FIG. 518.—Lateral-flap method.

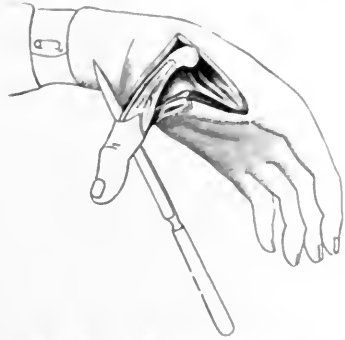


FIG. 519.—Making outer flap.

sponding course along the inner side, meeting the former at the inner extremity of the transverse line of the web. The flaps are dissected off,

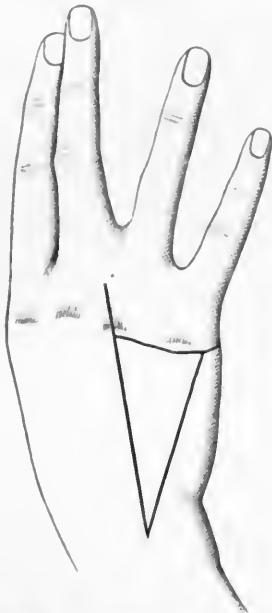


FIG. 520.—Amputation through fourth and fifth metacarpal bones.

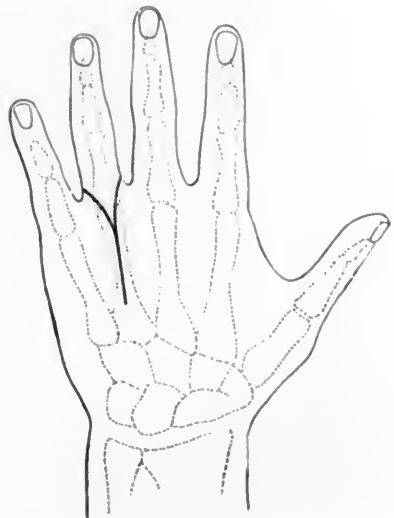

FIG. 521.—Amputation through one metacarpal bone.

and the articulation between the metacarpal bone and the trapezium is opened from the ulnar side, to avoid injuring contiguous joints (Fig. 516). The union of the flaps leaves a linear cicatrix (Fig. 517).

The Lateral-flap Method (Fig. 518).—The lateral-flap method can be more quickly and easily performed than the former, but leaves the cicatrix in a less advantageous situation. Abduct the thumb and enter the knife between the first and second metacarpal bones, carry it up between them with a sawing motion, till the head of the first is reached. Cautiously disarticulate the digit from within outward, increase the abduction, and carry the blade through the joint and along the outer side of the metacarpal bone, thus making the outer flap, which should terminate opposite the web of the thumb (Fig. 519).

Amputation through the Metacarpal Bones.—In amputation through two or more of these bones the principal flap should be taken from the palmar surface, although it may be taken from the border of the hand and palm as well (Fig. 520). If but one metacarpal bone be attacked, the incisions are the same as those for amputation at the metacarpo-phalangeal articulation by the oval method, the only difference being that their upper limit will correspond to the point of proposed section of the bone (Fig. 521). The bone is exposed by reflection of the soft parts up to the point of proposed division, after which it is sawed through with a chain, Gigli-Haertel, or metacarpal saw, separated carefully from its palmar connections, and removed with the finger attached. If a saw be not convenient, the bone-cutting forceps (Liston) can be used, although with some risk of splintering the bone. This operation is often performed in preference to disarticulation at its head, in order to give symmetry to the hand (Fig. 522).

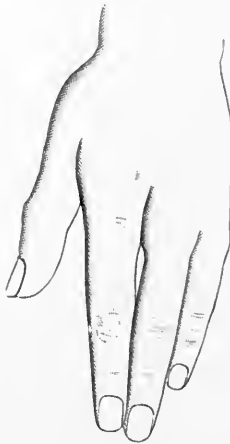

FIG. 522.—Appearance of hand after amputation through third metacarpal bone.

The Remarks.—The division of the transverse ligament, which extends between the heads of the metacarpal bones, lessens the strength of the grip. This operation is therefore not to be recommended except in those of sedentary habits, and even in these instances the subsequent atrophy of the soft

parts and the separation of the metacarpal bones at the seat of the operation do much to lessen the cosmetic effect originally gained by the amputation. If possible, the divided ends of the palmar transverse ligament should be sewed together, which will serve to lessen the tendency to the latter element of deformity.

Amputation of the Last Four Metacarpal Bones (*Disarticulation*).—Make a semilunar flap from the tissue of the palm by a curved incision, beginning at the web of the thumb and terminating at the ulnar border of the fifth metacarpal bone (Fig. 523). This flap can be made by transfixion if desired (Fig. 524). The dorsal incision (Fig. 525) begins at the same point of the web of the thumb, and is carried to the upper third of the metacarpal bone of the index finger, and from there transversely across until it meets the ulnar extremity of the first incision. The flaps are reflected up to the carpo-metacarpal joints, the hand is strongly abducted, and the carpo-meta-

carpal joint opened from the ulnar side, using great caution not to injure the articulation of the trapezium and the metacarpal bone of the thumb. Without the thumb this operation would be of little avail in securing a use-

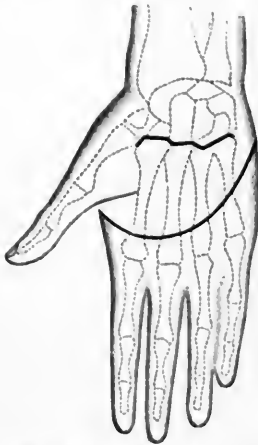


FIG. 523.—Line of palmar incision.

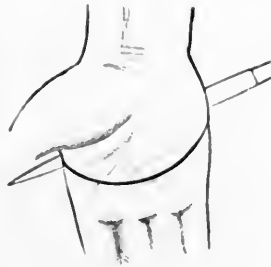


FIG. 524.—Making by transfixion.

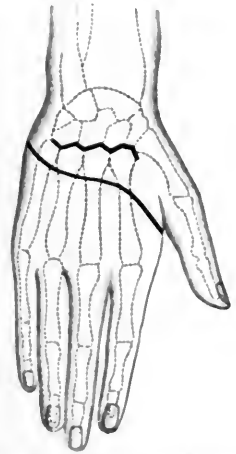


FIG. 525.—Line of dorsal incision.

ful stump. Unite the flaps with interrupted sutures, introduce at either angle of the wound drainage when needed (Fig. 526), and treat antiseptically.

Amputation of the Inner Three Metacarpal Bones.—Begin the palmar incision at a little distance below the base of the fifth metacarpal bone, carry it downward and outward across the palm below and parallel with the transverse palmar fissure for about an inch and a half, then toward the base of the middle finger, finally dividing the web of the hand at the outer side of that digit. A like flap is then made on the dorsal surface, the bones are removed, and the flaps united and dressed in the usual manner.

The principles embodied in the last two amputations are applicable to amputation of the metacarpal bones of the last two fingers.

Amputation of the Four Metacarpal Bones with the Fingers requires a long convex palmar flap and a short concave dorsal one. The bases of the metacarpal bones are saved as they afford attachment to important flexors and extensors of the carpus.

The Remarks.—Amputation of the fingers and of the metacarpal bones exposes the synovial sacs of the carpal bones and tendons (Fig. 413) to the dangers of inflammation. It is fortunate for this reason that these sacs are not common to their respective tissues. The relations of the surface markings of the palm (Fig. 504) to the bones and vessels of the carpus are of much significance in amputation and exsision.

After-treatment.—The wounds of these amputations should be closed with silkworm gut or horsehair, and simple drainage should be employed

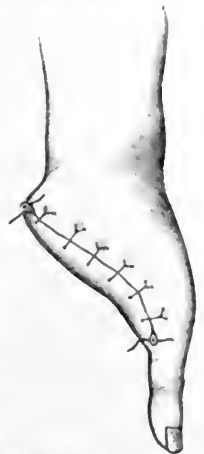


FIG. 526.—Appearance of stump.

for the first two or three days. If the tissues have been bruised or lacerated, freer drainage is advisable. The hand should be kept in an elevated position, and the wrist joint confined with a splint.

The results of amputations of the thumb and fingers are favorable. Only three to six per cent, and even less, with antiseptic precautions, die.

Amputation at the Wrist. (Disarticulation.)—The bones entering directly into this articulation are the radius, scaphoid, and semilunar.

The Anatomical Points.—The location of the joint can be determined, 1, by forcibly bending the carpus backward, when the angle on the dorsal surface formed by the hand and forearm indicates the radio-carpal joint; 2, by drawing a line transversely from one styloid process to the other the joint is about one fourth of an inch above this line. The tip of the styloid process of the ulna is nearly opposite the joint at that situation. The lowest transverse fold of skin on the anterior surface of the wrist is about three fourths of an inch below the joint; this fold indicates the upper border of the annular ligament. The integument on the back of the wrist is thinner or more lax than is that on the front, therefore it retracts more than does the latter—a fact to be considered in the construction of flaps. The relations of the tendons, bones, and synovial sheaths with each other are well illustrated elsewhere (Fig. 416). Amputation can be done by either *the circular, single palmar, radial-flap, or the double-flap method.*

The Circular-flap Method.—To establish the length of the flap ascertain one fourth of the circumference of the wrist at the articulation, and add

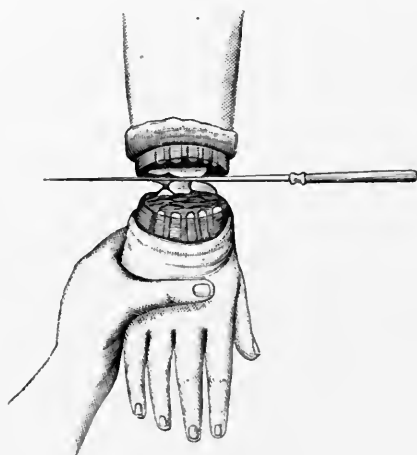


FIG. 527.—Circular method.



FIG. 528.—Flaps united.

posteriorly to it about an inch to compensate for the retraction which characterizes the integument on the posterior surface of the carpus.

Measure downward from the articulation this distance and divide the soft tissues by an oblique incision which becomes circular by retraction; dissect up the sleeve of integument until opposite the joint; pronate and forcibly flex the carpus, and open the wrist joint on the dorsal surface by

an incision extending between the styloid processes; divide the lateral ligaments, pass the blade through the articulation, and sever the remaining structures (Fig. 527). Join the flaps in the long axis of the joint, introduce drainage and sutures, and dress antiseptically (Fig. 528). If for any reason the flap be made too short, the defect can be remedied by sawing off obliquely the styloid processes.

The Single Palmar Flap.—The single palmar-flap method is easily performed, and makes a serviceable stump. Mark out on the palmar surface with a strong scalpel a semilunar flap about three inches and a half in length going down to the flexor tendons, the base being located just below the apices of the styloid processes (Fig. 529); reflect it upward; divide the remaining tissues in front of the articulation; open the articulation, pass the knife through it, and make a short dorsal flap. The dorsal flap can be made first, the joint opened from behind, and the long anterior flap cut from the joint outward. The former is the better plan, however, as thus a more symmetrical flap is made.

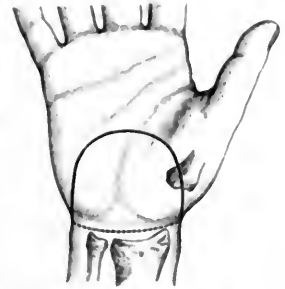


FIG. 529.—Single palmar flap.

The Double-flap Method (Ruysch).—Mark out the distal limits of the flaps as in the circular method; flex and pronate the hand; carry a semilunar incision over its dorsum, beginning at the styloid process of the ulna, extending to the circular line indicating the dorsal extent of the flap, and terminating at the radial styloid process (Fig. 530). Dissect up the flap,

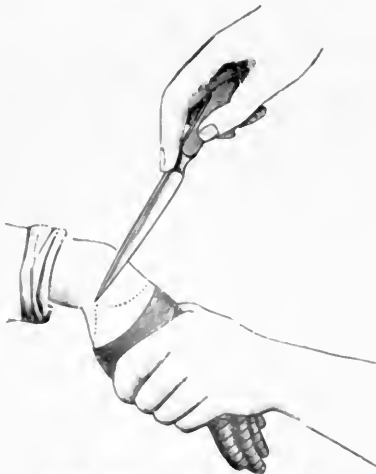

FIG. 530.—Making dorsal flap.

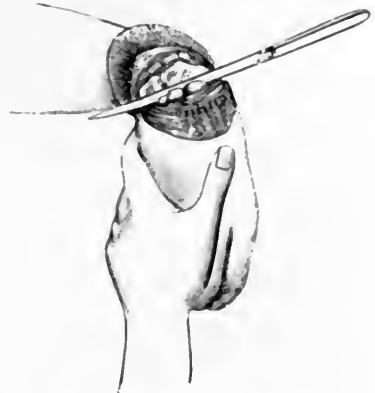


FIG. 531.—Making anterior flap.

allowing the tendons to remain; flex the carpus firmly, and open the articulation, as in the circular method; carry the blade of the knife through the articulation (Fig. 531) and make the anterior flap by cutting downward and outward.

The Radial Flap (Dubrueil).—Make a flap beginning on the dorsal surface at a point just above the articulation and at the junction of the outer third with the inner two thirds of that surface, and extending downward toward the thumb, crossing the middle of the metacarpal bone of that digit toward the palm, then curving upward and inward through the thenar eminence and terminating at a point on the palmar surface of the wrist directly

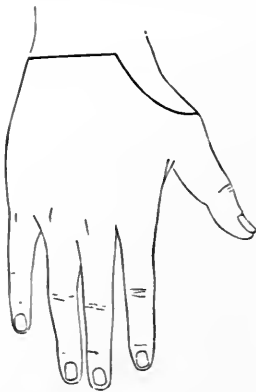

FIG. 532.—Dubrueil's method. Radial flap.

opposite the site of beginning (Fig. 532). Separate the thumb flap, connect the sides of its base by an incision carried transversely around the ulnar side of the hand, draw the skin upward, open the joint as before, remove the carpus, and properly adjust the flaps (Fig. 533).

The Remarks.—The pisiform bone is frequently removed from the flaps. If the tissues are not impaired by diseased or acute inflammatory processes, the sheaths of the tendons should be closed with sutures, even including the ends of the tendons, if not too much retracted, after which the flaps are united, suitable drainage provided, antiseptic dressings applied, and the limb placed on a retaining palmar splint to control the movements. If the tissues be infected, the wound should be

packed lightly with gauze, dressed, kept clean, and when granulations appear the surfaces should be united in a suitable manner.

The Results.—A total number of 256 cases of amputation at wrist joint done for various causes shows the following: Of 189 cases done before asepsis, 26.31 per cent died. Of 67 cases done under asepsis, 1.8 per cent terminated fatally. In civil practice the rate is less than 12 per cent.

It follows therefore that amputation at the wrist joint can not be recommended on the ground of safety to the patient. There are other objections of less importance, which, with the one just stated, places the operation in disfavor. It makes a stump which, owing to the feebleness of the circulation of the flaps, often becomes cold and even chilblained, and the bulbous extremity often interferes with the application of the properly fitted socket of an artificial appliance. However, supination and pronation of the forearm are more nearly complete than in amputations of the forearm, for obvious reasons.

Amputation of the Forearm.—The forearm can be amputated by either of the following methods: *The circular skin-flap, the equilateral skin-flap, or the antero-posterior musculo-cutaneous flap.*

The Anatomical Points.—The insertions of the supinator muscles should be saved when possible, to preserve their function. During division of the interosseous structures the forearm should be supinated to afford as much room as possible for that purpose.

The Circular Skin-flap Method.—Although this method can be employed at all parts of the arm, yet it is best suited for the lower third. It

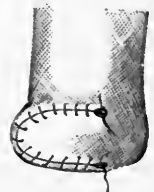

FIG. 533.—Appearance of stump.

is performed by first carefully laying out the length of the flap equal to a little more than one fourth the circumference of the limb at the point of bone section. Then with a long knife divide the tissues by a circular incision down to the fascia surrounding the muscles, and dissect up the integumentary cuff by repeated incisions directed toward the muscles (Fig. 474).

If the integumentary cuff be too small to be turned up readily it is slit up at the most dependent part. After the flap is reflected sufficiently, the muscles are divided half an inch or so below the line of its reflection by a circular sweep of the knife made down to the bone. The undivided tissues lying between the bones on both aspects of the limb are severed with a scalpel. It is wise that the interosseous membrane and its vessels should be divided a short distance below the point of proposed bone section, and its borders separated from those of the contiguous bones up to the point of section with the scalpel. And, too, the blade should be withdrawn with each section of the membrane; for to turn it while between the bones lacerates and unnecessarily injures the soft structures. This course avoids the risk of cutting the vessels too short, as occurs when they are divided at a level with the bones, which procedure permits them to retract above the point of easy access. The muscles are then drawn upward with the three-tailed retractor (Fig. 497), and the bones sawed at the highest point of exposure, the radius being divided first. Having secured the radial, ulnar, anterior and posterior interosseous arteries, the wound is then properly united (Fig. 534), drained, and dressed.

The Equilateral Skin-flap Method.—With the forearm midway between supination and pronation the flaps are raised either from the radial and ulnar borders or the dorsal and palmar surfaces of the forearm, the latter course being most frequently adopted. The length of the flaps is determined in the same manner as for the circular, plus an inch for special retraction; in fact, if the incision be made first, and the angles of the cuff trimmed off down to near the site of muscular section, the flaps will thus be formed. It is better, however, to mark them out before incision, since to make each with the same curve and same breadth of base is not an easy task without this precaution. The remaining steps of the amputation are similar to those of the circular method. *Jacobson* advises that the posterior flap be made an inch longer than its fellow to provide for the greater retraction of the integument of that aspect of the part.

The Musculo-cutaneous-flap Method.—The musculo-cutaneous flap is made by transfixion and cutting outward, or cutting from without, the former plan being commonly employed. Either plan of action is best fitted for the upper half of the forearm, on account of the large muscular development at that situation (Fig. 224). Owing to the great degree of muscular retraction here, the making of the flaps should be carefully planned and executed.

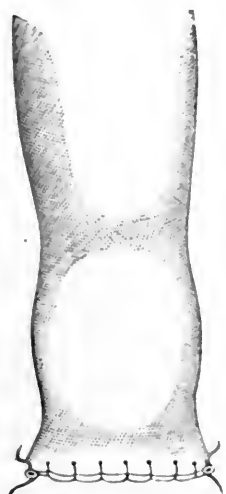

FIG. 534.—Stump after circular operation.

The width of the base and the length of each should equal one half the circumference of the limb at the point of proposed amputation. It will not be amiss, in cases of large muscular development, to increase the length somewhat, on account of the unusual contraction incident to this class of cases. The remaining steps differ in no essential degree from those of other methods of procedure.

The Comments.—The placing of the cicatrix at the end of the stump in the arm, even when followed by its adhesion to the underlying tissues, is less objectionable than at the end of a weight-bearing stump, for apparent reasons. The circular method is not advisable at the upper two thirds of the arm because of the large amount of muscular structure there.

The Results.—Of 2,933 cases of amputation of the forearm during the preaseptic period, 16.34 per cent died; of 478 operations under asepsis, only 3.09 per cent terminated fatally.

Amputation at the Elbow Joint (Disarticulation).—*The elliptical-flap, the circular, and the anterior single-flap methods are commonly employed.*

The Anatomical Points.—Before operation carefully define the location of the most prominent portions of the condyles of the humerus. The internal condyle is about one inch and the external about three fourths of an inch above the articulation. Just below the outer condyle is felt the movable head of the radius; about an inch below the inner condyle the ulna joins the humerus; the articulation is therefore oblique, the inner portion being about half an inch the lower, owing to the inner condyle being that much longer than the outer. The anterior crease of the integument is just above the joint. The integument on the anterior and radial sides of the joint retracts freely, while that on the posterior has little tendency to retract, and is well inured to pressure by previous use.

The Elliptical-flap Method.—The elliptical method can be practiced by making the ellipse either on the anterior or posterior surface of the limb.

The Anterior Ellipse.—In this method the olecranon process marks the highest point of the ellipse behind; the anterior point of the ellipse is just above the middle of the forearm in front (Fig. 535). The flap is outlined by an incision made through the skin only, extending from the olecranon around in front and back to the point of starting. The forearm is then slightly flexed, the flesh pinched up and transfixed down to the bone close to the joint through the beginning of the preceding incision, and the knife carried downward and forward along the same line to the completion of the flap. The flap is then drawn upward and disarticulation is performed the same as before. The union of the borders of the wound results in a posterior cicatrix.

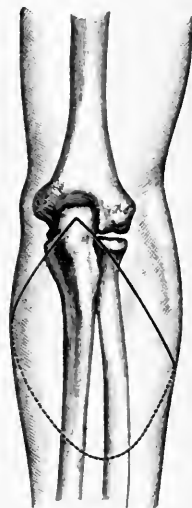

FIG. 535.—The elliptical-flap method.

The Posterior Ellipse.—In this method the points of the ellipse are reversed, the flap being taken from the posterior surface. There is nothing

to commend this plan in the place of the former. In this amputation a drainage tube should be employed for the first few days of the treatment.

The Circular Method.—Lay out the flaps obliquely, measuring from the condyles—four inches below the outer and two and a half inches below the inner condyle. Divide the superficial tissues obliquely down to the fascia

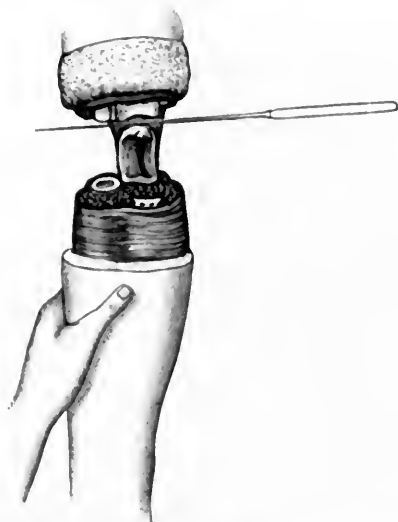

FIG. 536.—Circular amputation at elbow joint.

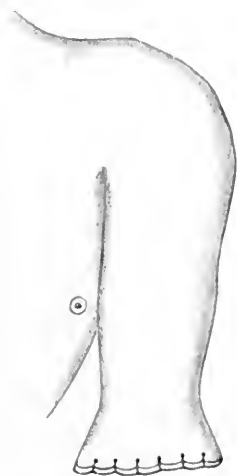


FIG. 537.—Stump in circular amputation at elbow.

surrounding the muscles; dissect the flap upward to a level with the joint, the bony landmarks to which should again be carefully determined. Forcibly extend the arm and make an oblique incision in front on the line of the articulation into the joint; sever the internal and external lateral ligaments, and press the arm still farther backward; draw the olecranon process forward into the wound, and sever its connection with the triceps (Fig. 536). Unite the borders of the flap as indicated in the figure (Fig. 537). The flaps can also be united from before backward, which causes the cicatrix to fall between the condyles, and likewise increases the drainage facilities—two very important indications.

The Anterior Single-flap Method.—The single flap can be made either of integument and subcutaneous tissue alone or it may be musculo-cutaneous, and formed by transfixion. In either instance it should be taken from the anterior surface of the forearm. *If made by transfixion* (Fig. 538), supinate and flex the forearm slightly, raise the soft parts in front of the joint and enter the knife an inch below the inner condyle, pass it in front of the bones obliquely outward, causing it to escape about two inches below the outer condyle. Cut the anterior flap downward and outward, making it about four inches and a half in length, the radial side being the longer, because of greater retraction there; dissect and draw the flap up to a level with the joint in front. Make the posterior flap by connecting the extremities of the first incision by a slightly convex one of the skin alone, or including the

muscular tissues (Fig. 539); dissect this up, after which the joint is opened in front, the lateral ligaments are divided, the olecranon process is displaced forward, and the triceps cut off.

The Comments.—In amputations at the elbow the variety and location of the flap must be regulated largely by the state of the tissues. Imperfect soft parts at one aspect necessitate a proportionate increase of the flap of the opposite surface. Therefore, it should be remembered to seek flaps wherever they may be found, rather than impair the usefulness of the stump by sacrifice of bone.

It is advisable, when possible, to saw off the olecranon, allowing it to remain with the triceps attached. If it be possible to sever the ulna below the insertion of the brachialis anticus, allowing the fragment to remain along with its muscular attachments, the stump will be more serviceable. In amputations near the elbow, the tubercle of the radius, together with the biceps tendon inserted into it, should be carefully preserved when possible.

The anterior elliptical and the anterior single-flap method each provides an ample and well-nourished flap, good drainage, and suitably locates the

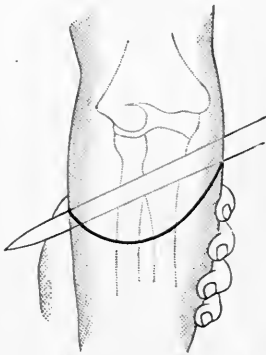


FIG. 538.—Anterior flap by transfixion.



FIG. 539.—Making posterior flap.

cicatrix. Of the two, the former is somewhat the better plan; each is the antithesis of the posterior elliptical in these respects. The circular method although causing a limited loss of the soft parts covers less satisfactorily the end of the stump and places the cicatrix there.

The Results.—Of 332 amputations in this situation for various causes, done before asepsis, 14.15 per cent died; in 252 cases done under asepsis the mortality was 3.57 per cent.

Amputation of the Arm.—The arm can be amputated by *the circular-flap method, the irregular double flap, the antero-posterior flap, the single circular incision of Celsus* (Fig. 637), and by *Teale's method*. The circular-flap methods are applicable especially to the lower portion of the arm; the remaining methods are better adapted to the upper portion, and each can be employed as circumstances require.

The Circular-flap Method.—The circular-flap method can be practiced in either of two ways: *First*, the length of the flap is made to conform to one fourth of the circumference of the limb, plus an additional inch to pro-

vide for retraction. Divide the superficial tissues down to the muscular fascia and turn the flap up as elsewhere (Figs. 474 and 475); then divide the muscles about an inch below the reflection of the flaps down to the bone. Apply the two-tailed retractor (Fig. 499), saw through the bone opposite the point of reflection of the flap, and unite the flaps in the direction best calculated to provide dependent drainage. *Second*, divide the integument the same as before, free it at the border from the intermuscular septa, draw the flap upward gently and with a long knife make a circular sweep around but not entirely through the muscles, draw up the divided muscular fibers and repeat the circular sweep, going this time down to the bone. This manœuvre makes the cone-shaped arrangement of the end (Fig. 634). In other respects the operations are similar.

The Irregular Double-flap Method.—If skin alone be employed, the unequal flaps should be carefully mapped out upon the integument of the arm. Dissect these up, and an inch below the flap reflection make a circular section of the muscles down to the bone; unite the flaps and dress the stump.

The Remarks.—The irregular-flap method is advantageous in the saving of bone, when irregular injury or disease of the surface of a limb requires either this kind of flap or else a sacrifice of leverage to secure uniform ones. The base of each flap should equal one half the circumference of the limb. If the condition of the soft parts will permit, the length of the anterior flap is made equal to the circumference of the limb, the posterior to half that distance.

The Antero-posterior flap Method.—The antero-posterior flaps can be made of skin alone or combined with muscle. In the former instance they are fashioned and raised as is already elsewhere indicated.

If musculo-cutaneous flaps (Langenbeck) be desired, they can be made by transfixion and cutting from within outward with a long knife, or from without inward with a scalpel. The latter plan secures better uniformity of outline of the flap. If made by cutting from without, outline them carefully (Fig. 540), and when dissected up the desired distance, finish the operation by a complete division of the muscles.

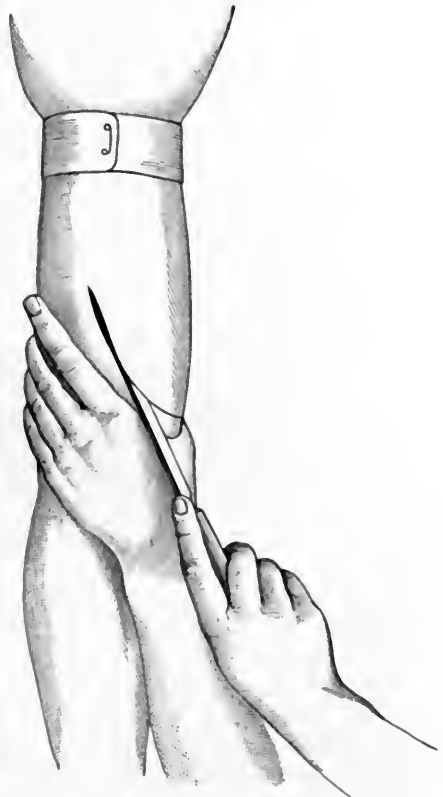

FIG. 540.—Langenbeck's method.

The large anterior and small posterior skin-flap method is sometimes performed (Fig. 541), also one with a large anterior flap and a posterior circular incision (Fig. 542). These flaps possess the advantage of good drainage and of placing the cicatrix where it is well removed from irritation. The dimensions of the flaps can be easily estimated on the basis of reciprocal length—viz., if one be increased in length, the other should be proportionately shortened.

Teale's Method.—Teale's method when employed should be done at the lower portion of the arm, the long flap being taken from the antero-external surface, in order that the short one shall contain the nerves and the brachial artery.

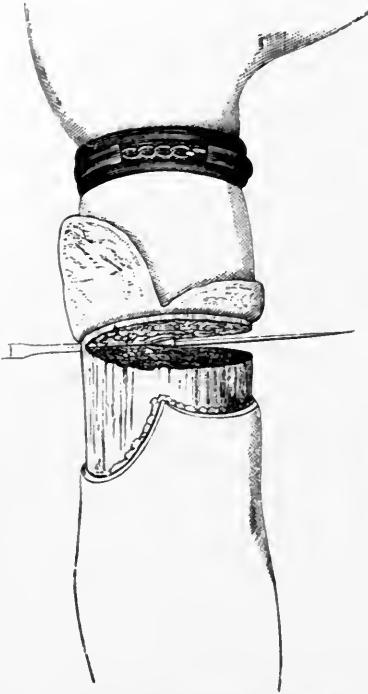


FIG. 541.—Unequal skin flaps.

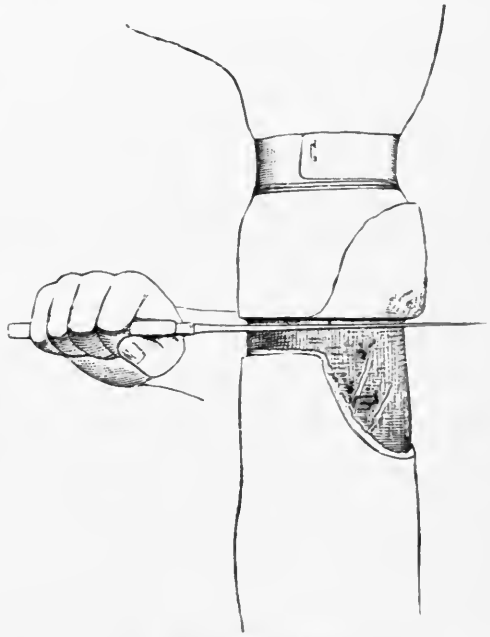


FIG. 542.—Large anterior flap.

Amputation at the Surgical Neck of the Humerus.—*Two methods* of amputation are practiced, in either of which the bone is divided just above the insertions of the tendons of the pectoralis major and the latissimus dorsi muscles. This amputation is characterized by *special considerations*, such as the avoidance of the line of epiphyseal junction, of the bursa of the subscapular tendon on account of its frequent communication with the shoulder joint, and of the vessels and nerves associated with the surgical neck of the bone. The operation can be employed for uncomplicated cases in those over eighteen years of age.

The Anatomical Points.—The integument over the deltoid is thicker, more adherent, and less retractile than is that over the pectoral muscle and inner surface of the arm. With the arm hanging at the side and the hand supine, the bicipital groove looks forward, and the articular surfaces of the

head in the same direction as the inner condyle. The circumflex artery and nerve cross the humerus horizontally about three quarters of an inch above the vertical center of the deltoid muscle—an important fact, especially in excision (page 387).

The Oval Method (Guthrie).—Arrest the circulation of the subclavian by direct or elastic pressure, raise the arm from the side of the body, begin the cutaneous incision two fingers' breadth beneath the acromion process, carry it to the inner side of the arm just below the border of the pectoralis major muscle, then beneath the arm to the outside, where it is joined by a second incision carried backward from the beginning of the preceding one. The integument is retracted and the muscles of the flap are severed, the bone is exposed up to the great tuberosity, the circumflex vessels and nerves are drawn upward with a hook, and the bone is sawed through. The large nerves are cut short. If the circumflex vessels can not be withdrawn from danger they should be tied and divided.

The Single External-flap Method (Farabeuf).—An integumentary U-shaped flap with the base equal in width to one half the circumference and the length to the diameter of the extremity is made with the base two inches below the surgical neck. The muscular tissue is divided by transfixion, and cutting outward in the line of the integumentary incision. The tissues at the inner aspect of the limb are divided singly and with care as follows: Expose the bone below the bicapital groove; divide the periosteum at that point and detach it upward along the groove with an elevator, including the insertion of the greater part of the pectoral muscle; divide the tendon of the long head of the biceps low down, avoiding injury of the synovial sheath and also of the bursa of the subscapularis tendon. Expose and tie the main vessels before their division, cut short the nerves and sever the tendinous insertions close to the bone. The flaps are united and dressed in the usual manner. Amputations at this situation are regarded as less fatal than disarticulation at the shoulder joint, and, moreover, the rotundity of the joint is better preserved, and the stump offers a better opportunity for the attachment of an artificial limb.

The Remarks.—The circular method is better adapted to the lower and the flap method to the upper half of the arm. In amputations of the humerus during childhood the disproportion of the growth in the bone and soft parts is liable to result in a conical stump. It happens not infrequently in these cases that repeated exsection of the distal end of the elongating bone is required to relieve pain and discomfort at the end of the stump.

The Results.—In 8,050 amputations of the arm for all causes, of 7,457 done before antisepsis, 29.5 per cent died; of 593 with asepsis, 12.4 per cent died—about eighteen per cent when done in the upper third, sixteen per cent at the middle third, and about twenty-six per cent at the lower third—the greater per cent in this situation being due, no doubt, to the greater degree of the injury calling for amputation at this point.

Amputation at the Shoulder Joint (*Disarticulation*).—There are various methods recommended for amputation at this joint. It is hardly necessary

to enter into the details of more than those which are commonly recognized and employed. The remainder, while ingenious in many instances, do not present sufficient practical differences to entitle them to introduction into other than cyclopædic treatises of operative surgery.

Four methods of amputation will be described: The external- and internal flap-method, the circular method, the racket methods of Larrey and Spence.

The special considerations incident to disarticulation at this joint may be briefly stated as follows: 1, The control of hæmorrhage; 2, the maintenance of the symmetry of the shoulder; 3, the transverse division of the axillary vessels and high division of the nerves; 4, the prevention of entry of air into the veins; 5, the establishment of good drainage; 6, the least possible division of tissue; 7, the easy disarticulation; 8, the formation of a serviceable stump.

Hæmorrhage may be prevented by direct pressure of the subclavian on the first rib by the thumb, a padded key, or the padded extremity of a short crutch, or the artery may be ligatured here for the purpose. Which expedient is the best, depends very much indeed on the quietude and condition of the part; for, if the shoulder be pushed upward during the operation,

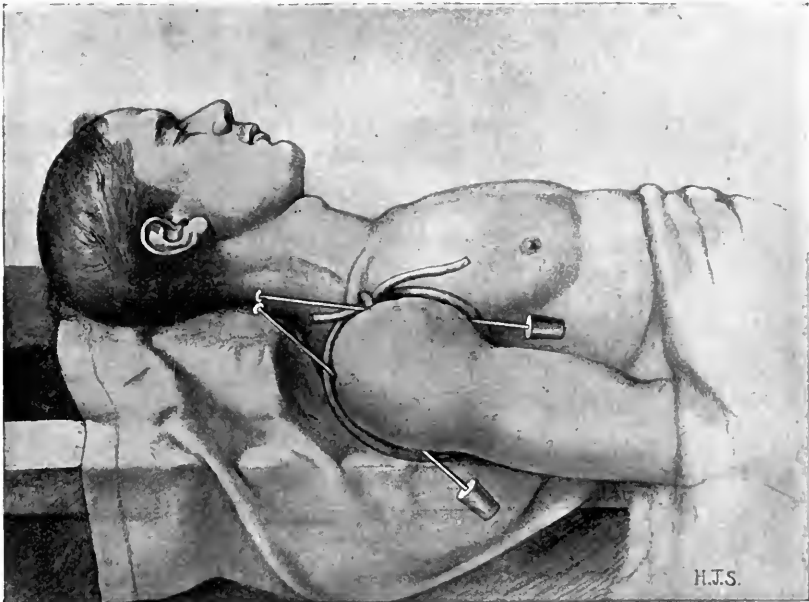


FIG. 543.—Shoulder-joint amputation. Pins and rubber-tube tourniquet in position. The Esmarch bandage is removed from arm.

the compressing agent may be displaced by movements of the clavicle, if the tissues be thickened by disease, or otherwise, direct pressure may be inefficient for the purpose. The employment of elastic constriction, as figured (Fig. 545), or with the aid of Wyeth's needles (Figs. 543 and 544), may answer well throughout unless the vessel be compressed against the head of

the humerus. When thus compressed, hæmorrhage will probably occur when the bone is removed. Before division of the vessels, however, the tissues containing them can be firmly grasped by the hand above the point of section, and thus the bleeding will be prevented in any instance. *Symmetry is maintained* to the fullest extent by the preservation of the deltoid, the

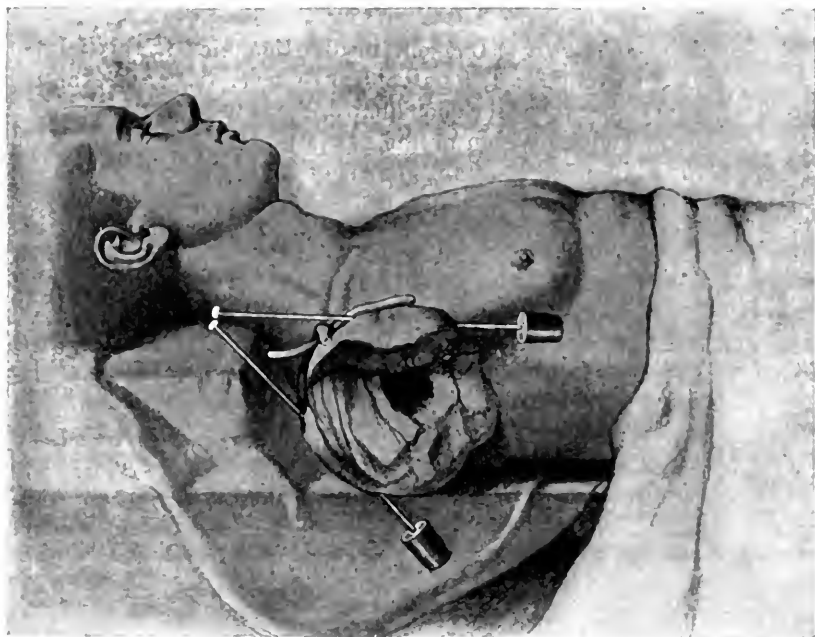


FIG. 544.—Appearance after disarticulation and ligation of the vessels.

acromion process, and the circumflex nerves and arteries; division of these nerves and arteries—the former especially—leads to muscular atrophy. *Transverse division of the vessels* is easily made by cutting the tissue containing them at right angles while taut. *High division of the nerves* is easily performed by pulling down upon them before section. *The entrance of air* is prevented by prompt closure of the open mouths of the veins (page 122). The remaining four special considerations will be recalled in connection with their exemplification by operative method.

The External- and Internal-flap Method (Dupuytren).—Place the patient at the edge of the table, and turned toward the healthy side, with the body raised; make an external oval flap by an incision extending from the coracoid process downward and outward to the insertion of the deltoid, then upward and backward, terminating at the junction of the acromion process with the spine of the scapula (Fig. 545). Raise the flap, including the deltoid muscle, as far as the acromion, expose the capsule of the joint, push upward the head of the humerus, and divide the capsule above; rotate the arm outward, sever the subscapularis; then inward, and divide rapidly the external rotators attached to the greater tuberosity. While the arm is

rotated internally, divide the capsule still further, together with the tendon of the long head of the biceps; tilt the head of the humerus outward, pass the blade of the knife beneath it (Fig. 546); seize the head of the bone and draw it outward, carry the knife along its inner surface until within about



FIG. 545.—Disarticulation of shoulder joint, making outer flap; elastic circular compression.

four inches below the axillary fold, then turn the edge inward and complete the flap. The last sweep of the knife severs the principal vessels. This flap should be seized by an assistant and tightly grasped before it is divided. The appearance of the wound after the operation is represented in Fig. 547.

The Circular-incision Method.—Control the circulation as before. Abduct the arm and make a circular incision entirely around it severing all the tissues, down to the bone, at a level corresponding to the insertion of the deltoid. Ligate the vessels and saw off the bone. Make a second incision longitudinally from the anterior border of the acromion the whole length of the stump down to the bone. The bone is first held firmly and the soft parts are separated from it (Fig. 548), then it is rotated outward and inward, to admit of the division of the muscular and fibrous attachments to its head, after which it is removed.

The Remarks.—This operation is a good one, well calculated to provide

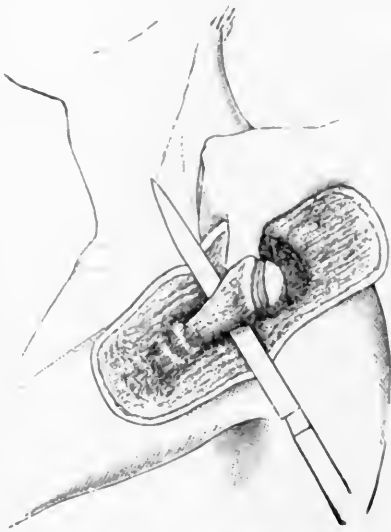


FIG. 546.—Making inner flap.

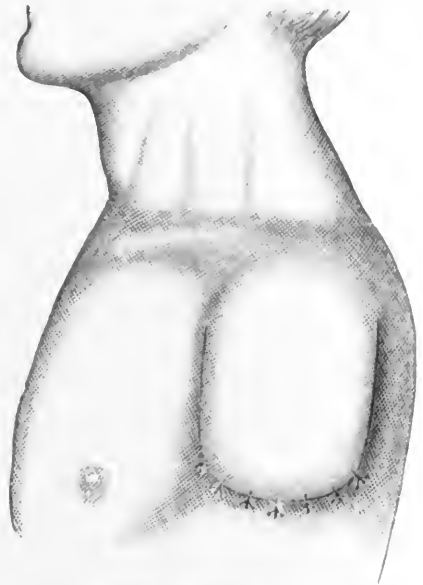


FIG. 547.—Appearance of the stump.

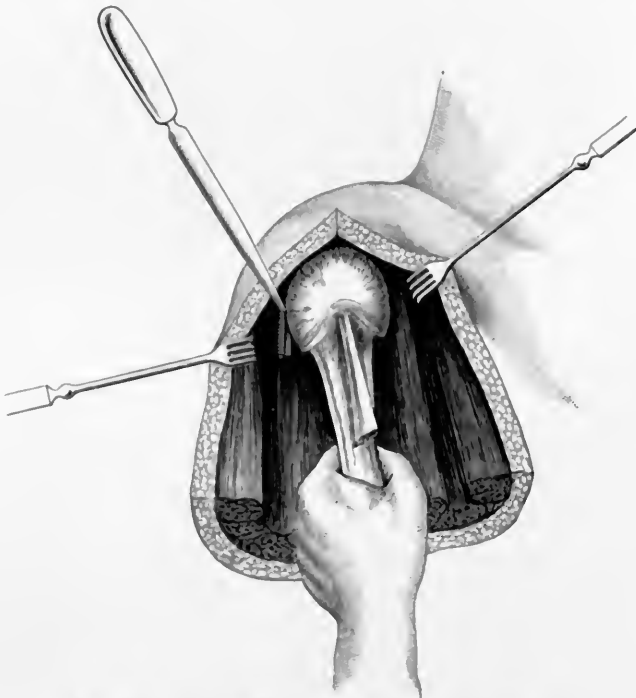


FIG. 548.—Circular incision method, removing bone.

favorable drainage (Fig. 549), and is done with a minimum amount of injury to the soft parts. If the periosteum be separated from the bone without disturbing the surrounding soft parts there will be less danger of the extension of inflammatory action beyond the line of the longitudinal incision; moreover, a greater degree of firmness will be given the stump even though new bone be not produced.

The Oval-flap Method (Larrey).—The oval method is well regarded, and is performed by making a vertical incision from just below the extremity of the acromion process, with the arm extended, about three inches in length, down to the bone; this incision should terminate about two inches below the head of the humerus. Two oblique incisions are then made, each beginning near the middle of the vertical cut, one on the anterior and the other on the posterior aspect of the limb, and are carried through the lower borders of the structures comprising the anterior and posterior walls of the axilla, at the points where these borders

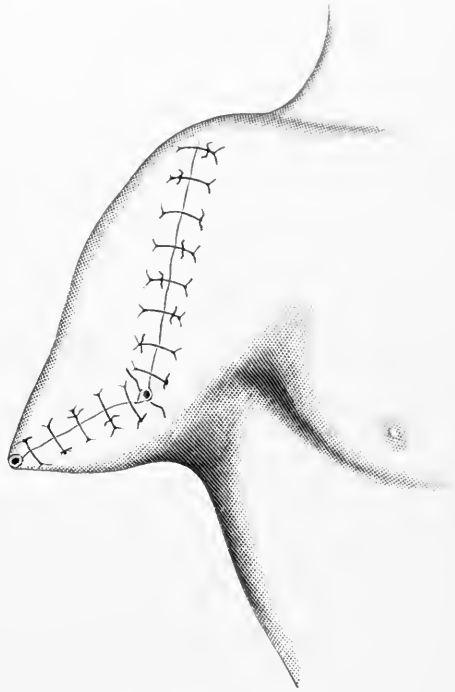


FIG. 549.—Flaps united, drainage introduced.

connect with the arm, thus severing their attachments to the humerus (Fig. 550). The soft parts at the inner aspect of the humerus still remain undivided. The borders of the wound are now drawn apart, the joint is exposed and opened above, the bone is drawn downward to separate the joint surfaces, the blade of the knife passed behind the luxated bone, and the operation is completed by cutting the tissues remaining at the inner side of the humerus (Fig. 551).

The Racket-flap Method (Spence).—The racket-flap method has attracted considerable attention, and is certainly entitled to great consideration. The operation is performed in the following manner: Abduct the arm slightly, rotate the humerus outward, cut down upon the head of the bone, beginning immediately external to the coracoid process, thence directly downward through the fibers of the deltoid and pectoralis major to the lower border of the latter, which is divided; carry the incision with a gentle curve outward across and through the lower fibers of the deltoid, to, but not through, the posterior border of the axilla (Fig. 552). Begin the inner incision at the lower extremity of the vertical one, carry it around the inner side of the arm, through the skin and fat only, to meet the one made at the outer side. If

the fibers of the deltoid have been thoroughly divided, the flap, together with the posterior circumflex artery, can be easily separated by the finger from the bone and joint, and drawn upward and backward until the head of the bone

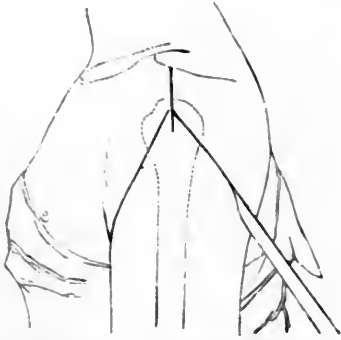


FIG. 550.—Larrey's method.

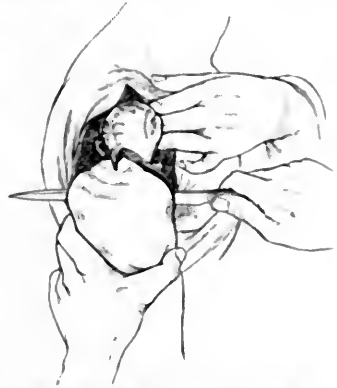

FIG. 551.—Forming inner flap.

is exposed; then the ligaments and muscular attachments are divided, disarticulation is accomplished, and the limb removed by dividing the remaining soft parts at the axillary aspect.

The Remarks.—Spence's method is valuable because it admits of a choice between excision and amputation. In very muscular subjects a redundancy of muscular tissue in the flap can be avoided by dissecting the integument and subcutaneous tissues a short distance upward over the deltoid, and dividing its fibers high up.

It will be noted that the external- and internal-flap method (Fig. 545) meets very many, indeed, of the considerations regarded as wise in amputation at the shoulder joint. The oval method damages the deltoid muscle considerably. The circular and Spence's methods are not much removed from each other in operative advantages. However, the latter is the more artistic, and is the more commonly employed of the two.

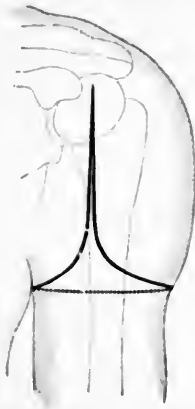


FIG. 552.—Spence's method; racket flap.

The Results.—Of 1,629 disarticulations at the shoulder joint, performed for all causes, 1,387 were done before asepsis, with a mortality of 37.7 per cent; of 242 cases done under asepsis, 7.7 per cent died.

Amputation above the Shoulder Joint.—It may become necessary, on account of malignant growths and severe injuries, to amputate the scapula together with a portion or the whole of the clavicle.

The operation is often tedious and attended with great loss of blood. Inasmuch as the situation of the disease or injury calling for operation will modify the location and direction of the incisions, no definite plan can be prescribed. The aim should always be to save enough healthy integument to cover the wound and to avoid hæmorrhage.

However, in view of the fact that the necessity for the amputation is often urgent, it is deemed wise to describe as briefly as possible the method presented by Berger in 1887. According to Treves, Berger divided the amputation into four stages: "1. The clavicle is exposed and divided at the junction of the middle with the outer third. The middle third of the bone is excised. The subclavian vessels are exposed and secured by double ligatures and divided. 2. The antero-inferior flap is fashioned and the brachial plexus severed. 3. The postero-superior flaps are fashioned. 4. The extremity is removed by dividing the tissues still connecting the scapula with the trunk."

The Operation.—The patient is placed on the back close to the edge of the operating table, with the shoulders elevated upon a hard cushion. The clavicular incision begins on the clavicle at the outer border of the sternomastoid muscle, and is carried outward down to the bone to just beyond the acromio-clavicular articulation (Fig. 553). The periosteum is separated from

the underlying surface of the bone with a periosteal elevator. The clavicle is then drawn forward and steadied by a blunt hook passed beneath it while it is sawed through at the junction of the inner and middle thirds with a keyhole, Gigli-Haertel, or fine chain saw. The inner end of the outer fragment is then seized with the forceps and drawn forward, the remaining periosteum removed from the middle third, and the middle third removed by sawing at its junction with the outer third. The subclavian

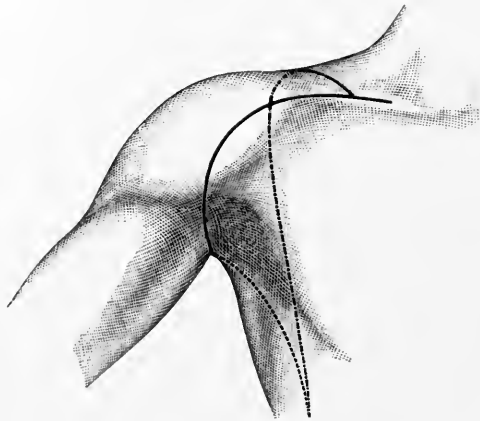


FIG. 553.—Anterior and posterior (dotted) lines of incision in amputation above the shoulder.

muscle is isolated and divided opposite to the inner section of the bone. It is then dissected up, the intervening fascia divided, and the deep vessels are thus exposed. The artery is tied with two ligatures at the outer border of the first rib, and divided between the ligatures. The vein is treated in a similar manner.

The entire scapular region should now be freed from the table, the limb carried away from the body, and the head drawn in the opposite direction. An incision is then made, beginning at the center of the clavicular one, and curved downward and outward just outside the coracoid process, thence along parallel with the anterior border of the deltoid muscle to where the anterior fold of the axilla joins the arm, then across the lower margin of the pectoralis major transversely through the skin upon the inner surface of the arm to the lower margin of the tendons of the latissimus dorsi and teres major muscles. The arm is then raised and the incision completed by carrying the knife downward and inward along the groove formed by the axillary border of the

scapula and the muscular mass formed by the teres major and the latissimus dorsi muscles, to the posterior surface of the inferior angle of the scapula. The flap is dissected forward, the pectoralis major divided at the tendinous part, the pectoralis minor close to the coracoid process, the brachial plexus

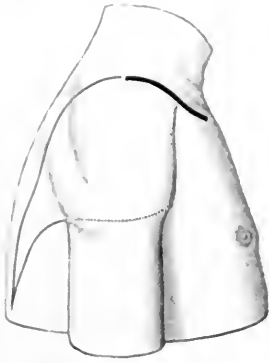


FIG. 554.—Amputation above the shoulder joint. Side view.

is exposed and the nerves are divided in a line with the main vessels. The latissimus dorsi is severed on the line of incision, and the shoulder falls outward from the body. The arm is now carried across the chest so as to expose the scapular region. An incision is then made, beginning at the upper portion of the preceding one near the acromio-clavicular articulation, and is carried backward behind the shoulder and downward by the shortest route over the spine of the scapula to join the termination of the anterior incision at the inferior angle of the scapula. This flap is laid back so as to expose the trapezius muscle

which is then divided close to its attachments to the clavicle and scapula. The flaps are now held aside and the superior and vertebral borders of the scapula are rapidly freed from their muscular attachments by large scissors applied close to the bone and the part is removed. The flaps are united with sutures, and dressings are firmly applied so as to obliterate all dead spaces (Fig. 554).

The Comments.—During the giving of the anæsthetic an Esmarch's bandage may be applied to the arm when the nature of the case approves. The flaps should be modified in shape to conform to the requirements of the case. The external anterior thoracic nerve is a good guide to the vessel, since it passes upward between the vein and the artery. Pulsation is the better guide, unless neutralized by shock. All ligatures should be placed before being tightened, and the artery should be tied first. The suprascapular vessels should be secured also. The manipulations of veins, both large and small, should be conducted with great care, to avoid rupture and the entrance of air, which appears to be an especial danger at this situation. The branches of the brachial plexus should be severed on the same plane as the large vessels. The primary incision may pass at once down to the clavicle, and the periosteum corresponding thereto should be divided and pushed back. The vessels may be controlled by pressure on the sub-clavian.

The Precautions.—In the instance of displacement of the vessels by large tumors, etc., insecure control of hæmorrhage may happen. Beware of shock, and be prepared to meet it in all of its degrees (page 121).

Entrance of air is comparatively so common in this operation as to constitute an active danger; therefore the veins should be tied as soon as practicable. The surgeon for this reason ought to be both alert and prepared not only to obviate but promptly treat this complication (page 122). Little danger attends from septicæmia.

The Results.—Of 74 cases of this amputation, 8 died, 6 of which occurred before 1880, and were due either to hæmorrhage or to infection. Ultimate recoveries, related of course to malignant disease, are for one year and more 46 per cent (Russell Fowler).*

* *Annals of Surgery*, January and February, 1900.

CHAPTER X.

AMPUTATIONS AT THE LOWER EXTREMITY.

No better or more comprehensive statement can be made bearing on the duty of the surgeon in amputations of the lower extremity, than that "Under all circumstances, except where poverty, advanced age, and confirmed dissolute habits so combine in the individual as to render it certain that mechanical appliances would be of little service, the patient should be given the stump best adapted to the most useful artificial limbs. In all amputations of the lower extremity, the surgeon should be governed in the selection of the point of operation and the method to be adopted by the mortality of the operation in question; by the adaptability of the stump to the most serviceable artificial limb for locomotion."*

Amputation of the Phalanges of the Toes.—Amputation is practiced in the continuity of the bone (Fig. 555, *a*), or through the articulations (disarticulation), and is done in the same manner as amputation of the fingers (page 469 *et seq.*), and therefore need not be considered here. In the case of the toes, however, it is often difficult to open the joints on account of the changes induced in them, and in the contour of the bones, by the pernicious influence of ill-fitting boots and shoes. The flaps are usually made from the plantar surface.

In amputation at the metatarso-phalangeal articulations, it must be remembered that the web of the toes is about an inch below the joints in question. The tendinous sheaths, the tendons, and the flap, are treated here as in amputation of the phalanges of the fingers.

On account of the vast importance of the great toe in connection with the power of serviceable and symmetrical locomotion, the amputations of this member are given a detailed attention. The remaining toes play a subsidiary part, indeed, in comparison with the great. Owing to the importance of the latter, a stump as long and as serviceable as possible should be constructed.

Amputation of the First Phalanx of the Great Toe.—Flex the phalanx to a right angle with its fellow, as in amputation at the fingers make a transverse incision with a narrow-bladed knife in the dorsum of the toe on a line with the center of the long axis of the second phalanx; this will open the joint. Sever the lateral ligaments separately with the point of the knife, then pass the blade through the articulation, and carry it

* From report of Drs. Valentine Mott, Gurdon Buck, John Watson, A. C. Post, Willard Parker, Ernst Krackowizer, W. H. Van Buren, and Stephen Smith.

forward, making a long plantar flap. If short incisions be made down to the bone at each side of the first phalanx, the flap can then be formed without the danger of too great narrowing of the base.

Another Method.—With the phalanx extended make an incision down to the bone across the dorsal surface of the first phalanx, then forward along the outer side, nearer to the dorsal surface, to the distal extremity and around this extremity to the inner side, then backward in a similar manner to the inner end of the transverse incision. This incision is made down to the bone throughout the entire course. Hyperextend the phalanx, dissect off the flap, open the joint from beneath, and sever the remaining structures by passing the blade upward through the articular surfaces.

Amputation through the last phalanx of the great toe should be practiced when possible, in order to preserve the proximal fragment for the purposes of leverage, and the points of insertion of the flexor and extensor tendons. The racket incision is best suited for this amputation. The handle of the racket begins at the head of the metatarsal bone and terminates near the middle of the phalanx on the dorsal surface in lateral incisions at each side, which meet on the plantar surface near the distal extremity of the phalanx (Fig. 555, *b*).

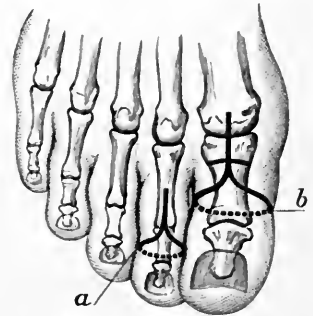


FIG. 555.—Amputation through last phalanx, great toe, and second of the adjoining (racket methods).

The phalanges of the remaining toes can be removed in a similar manner.

Amputation of Single Toes (*Disarticulation*).—Single toes can be removed by the oval or by the lateral-flap method (Figs. 556 and 557). The former is the better, and is done as follows: The operator grasps the condemned toe, while the assistant pulls aside its fellows. Commence the incision on the dorsum over the metatarso-phalangeal joint, carry it downward along the side of the phalanx to be removed, beneath the toe, through the transverse line of the web on the sole of the foot. A second incision is then made of a similar extent and outline on the opposite side of the toe. The tendons are severed, the plantar and lateral ligaments divided, and the bone removed by cutting from below. If the extremities of the divided tendons remain exposed they are cut off on a level with the divided border of the soft parts.

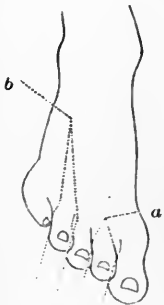


FIG. 556.—*a*. Removal of single toe, oval flap. *b*. Removal of toe with metatarsal bone.

The removal of either the *second, third, or fourth toes* can be well effected at this situation by making a transverse incision on the dorsum over the joint, and passing the knife through it and along the under surface of the bone a sufficient distance to make the necessary plantar flap, which is then turned upward and united. However, the preceding methods are preferable.

Amputation of the Great and Little Toes (*Disarticulation*).—Either of these toes can be promptly and suitably amputated by a single lateral-flap method. The amputation is performed by abducting the toe and entering the knife vertically between it and the contiguous toe, and cutting upward

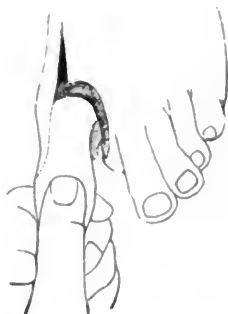

FIG. 557.—Lateral-flap method.

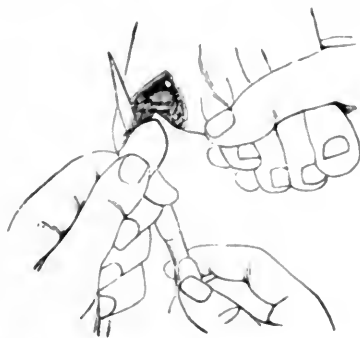


FIG. 558.—Completion of operation, lateral flap, little toe.

through the web till the line of the articulation is reached, when the knife is turned from the median line of the foot, the joint opened, the blade passed through it, and the lateral flap made of sufficient length by cutting along the opposite side of the toe (Figs. 557 and 558) to be removed. The importance of the great toe as a lever in propelling the body requires that even a part of a phalanx shall be saved when practicable. With the remaining toes, however, it is not a matter of so much importance.

The prominent head of the metatarsal bone of the great toe, which remains after disarticulation, has so frequently become the seat of painful bunions that many surgeons advise that the bone be amputated behind the head by making either a transverse or oblique section of the metatarsal bone. Of one fact there can be no doubt: the boot or shoe should be kept from contact with the stump in these cases, otherwise great annoyance and needless crippling will result.

The Square-flap Method.—The great toe can be amputated by a large square internal flap (Fig. 559). Begin the longitudinal incision at the outer side of the extensor tendon a little below the joint; carry it through the tissues down to the first phalanx (surgical); make a transverse incision from the termination of this one around the inner side of the toe to a point opposite, on the plantar surface; extend the toe and make another incision from the termination of the last toward the foot along the outer side of the tendon of

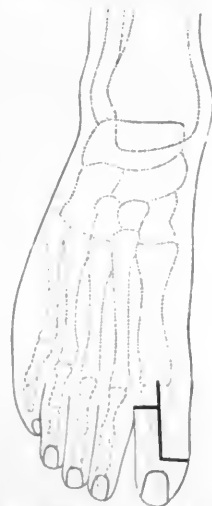

FIG. 559.—Square-flap method.

the flexor longus pollicis to the web; connect this incision with the center of the dorsal one by a transverse cut carried around the outer side of the base

of the toe; dissect off the flaps and divide the ligaments and remaining soft parts from within outward.

The Oval-flap Method.—In the oval-flap method the incision is commenced just above the joint on the dorsal aspect in the median line, and is carried down to the center of the proximal phalanx and around it, avoiding the web, up to the point of beginning (Fig. 560). The joint is opened from below. The cicatrix is vertical and at the end of the bone.

The Internal Plantar-flap Method (Farabeuf).—Make an incision, beginning at the head of the metatarsal bone at the line of junction of the internal and dorsal surfaces of the toe, downward parallel with the extensor pollicis tendon for about one inch; thence over the inner surface and across the plantar aspect of the toe to the web between it and the contiguous toe; then between the toes by the shortest route to the point of starting. The flap is dissected back, the joint opened from below, the extremity removed, leaving the sesamoid bones behind. This method provides a most admirable flap of inured tissues, and places the cicatrix quite without the range of irritation (Figs. 561 and 562).

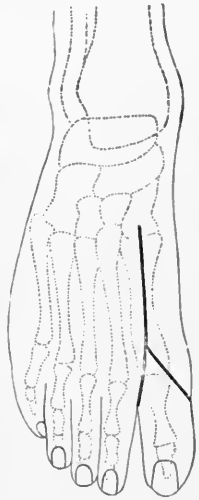


FIG. 560.—Oval-flap method.

Amputation of Two Adjoining Toes.—Begin the dorsal incision between the metatarsal bones of the toes to be removed just below the metatarso-phalangeal joints; carry it to the farther side of one of the toes, making a good-sized flap from it, thence through the digito-plantar fold to the opposite side of the other toe back to the point of starting. Remove each toe separately in the usual manner and close the wound.

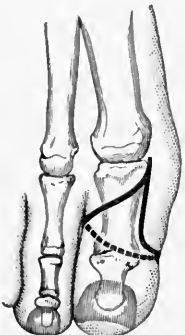


FIG. 561.—Incision for plantar flap.

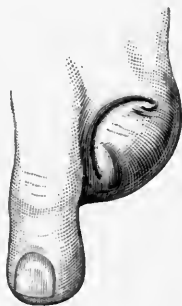

FIG. 562.—Stump of internal plantar flap.

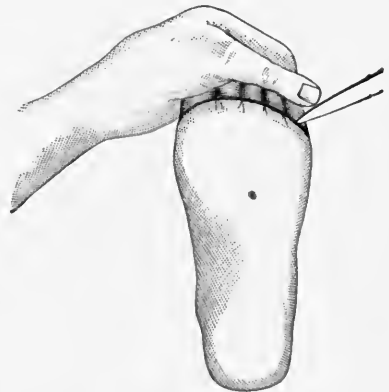


FIG. 563.—Amputation of all the toes, plantar incision.

Amputation of all the Toes at the Metatarso-phalangeal Joints (*Disarticulation*).—Forcefully extend the toes with the left hand and make a curved incision on the plantar surface from the inner side of the articulation of the great toe to the outer side of the corresponding joint of the little toe, carrying it through the groove between the sole of the foot and the bases of the

toes (Fig. 562). Flex the toes and join the extremities of the first incision by a similar one carried across the dorsum (Fig. 564). Dissect up the flaps, expose the joints, and remove each toe separately, allowing the sesamoid bones of the great toe to remain. If the flaps be too short, the heads of



FIG. 564.—Amputation of all the toes, dorsal incision.

the metatarsal bones should be cut off sufficiently to permit proper adjustment, and uniting of the divided surfaces of the stump (Fig. 565).

The Comments.—Since the head of the metatarsal bone of the great toe is the one most difficult to cover, the flap at that situation should be extended downward along the inner side of the toe to the center of the proximal phalanx, and thence transversely outward across the plantar surface so as to utilize a suitable portion of the plantar tissue of the great toe for the purposes of the main flap. The sheaths of the flexor tendons should be closed in the manner already advised (page 471). The flaps

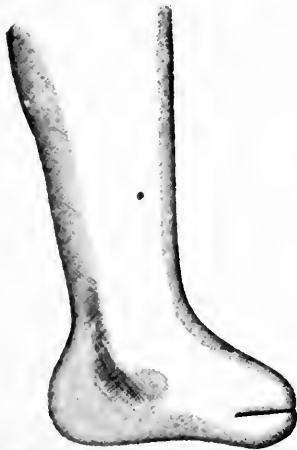

FIG. 565.—Appearance of stump.

should be united with silkworm-gut sutures, the stump loosely dressed, the limb elevated somewhat and required to rest upon the side to facilitate drainage, which may be encouraged for the first three days by the use of wisps of horsehair or silkworm-gut introduced at either extremity of the wound. Irregular flaps may be employed and thus avoid sacrifice of bone for leverage purposes. Careful scrutiny from time to time is advisable to detect the first indication of inflammatory extension along the sheaths of the tendons into the foot. Evidences of such extension call for prompt release of the flaps and cleansing and drainage of these channels.

The Results.—The general rate of mortality in amputation of toes is about six per cent.

Amputation through the Metatarsal Bones.—*Amputation through all of these bones* is best accomplished by a short dorsal and a long plantar flap. Make the plantar flap first by dissecting the tissues down to the bones backward from the junction of the toes with the sole to the point of amputation.

A short dorsal flap (Fig. 566) is then made with the convexity downward, its extremities being united to those of the preceding. Divide the interosseous tissues with a sharp, narrow-bladed knife; employ an antiseptic six-tailed retractor; draw the soft parts upward, and divide the bones with a fine saw, turn the plantar flap upward, and unite it with the dorsal flap in the usual manner.

Amputation of the Great Toe with the Metatarsal Bone.—This amputation is best done by the oval or racket method (Fig. 567), similar to that for removal of the thumb. In this instance the incision is begun on the dorsal aspect of the metatarsal bone at the base, and carried downward along the bone at the inner side of the tendon of the extensor proprius hallucis to near the lower end of the bone, thence around the outer side of the toe to the web, and across the plantar aspect in the groove between the toe and the sole, finally curved upward across the inner surface of the toe to meet the dorsal incision at the center of the metatarsal bone. The flaps are laid off, and the extensor tendons divided at the upper limit of the incision. The flexor tendons are then severed, the base of the bone is exposed, the peroneus longus cut, the bone still further exposed, the remaining tendinous attachments are divided, the tarso-metatarsal joint is opened, and the extremity taken away. It is recommended, in order to gain room, on account of the width of the base of the metatarsal bone of the toe, to make a short transverse incision across it at the tarso-metatarsal joint.

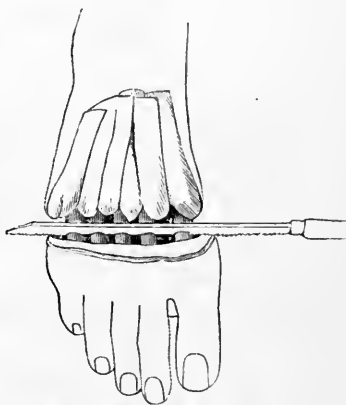


FIG. 566.—Sawing the bones.

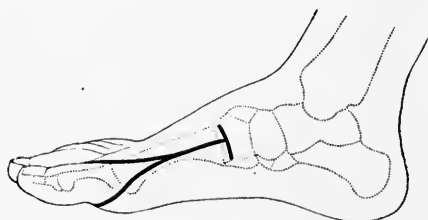


FIG. 567.—Amputation of great toe with the metatarsal bone (oval method).



FIG. 568.—Amputation of little toe with metatarsal bone (lateral-flap method).

Amputation of the Little Toe with the Metatarsal Bone.—Amputation can be done by either the oval- or the lateral-flap method; the steps of the former method are in all respects similar to those for the removal of the great toe with its metatarsal bone.

The lateral-flap method is performed by separating the fifth from the fourth toe, at the same time carrying a narrow-bladed knife upward from the web between the fourth and fifth metatarsal bones until it is arrested,

when the knife is withdrawn, and the incision prolonged upward on the dorsal and plantar surfaces on a straight line about one inch. Strongly

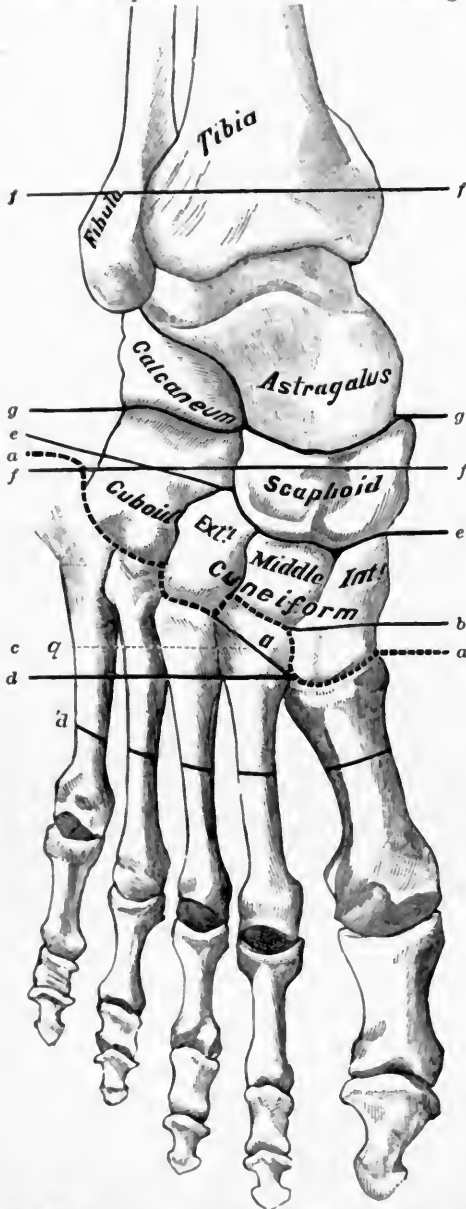


FIG. 569.—*a, a*. Line of Lisfranc's amputation. *b*. Line of Hey's modification of Lisfranc's amputation. *c*. Line of Skey's modification of Lisfranc's amputation. *d*. Line of Baudens's modification of Lisfranc's amputation. *d*. Amputation through metatarsal bones. *e, e*. Line of Forbes's amputation. *f, f*: *f, f*. Lines of Mikulicz's amputation. *g, g*. Lines of Chopart's amputation.

abduct the metatarsal bone to be removed, separating it from its fellow and from the cuboid; carry the knife around the base to the outer side, and, keeping close to the bone, downward to the metatarso-phalangeal articulation (Fig. 568); remove the bone, and the tongue-shaped flap will fit the intermetatarsal incision.

Amputation of the whole or part of a metatarsal bone of either the second, third (Fig. 556, *b*), or fourth toes can be readily accomplished by extending the stem of the racket or oval incision employed for the removal of the toe upward on the dorsal surface of the metatarsal bone to the point at which the bone is to be divided for removal. Caution is essential here to avoid injury to the underlying soft tissues during removal. Therefore the manipulative procedures should be directed especially toward the bone itself.

The Comments.—In amputation through all of the metatarsal bones dorsal and plantar flaps of equal length can be made. A single dorsal flap is not advisable, because of its thinness and the unfavorable site of the scar. A flap taken from the inner and also one from the outer margin of the foot may be serviceable in this emergency.

Amputation at the Tarsometatarsal Joints (Lisfranc's).—It will very much expedite matters, save considerable an-

noyance to the operator, and preserve the edge of his knife, if the relations of the bones entering into the joints be fully noted before attempting disarticulation (Fig. 569). The articulation between the cuboid and the fifth metatarsal is seen to be to the inner side of the tuberosity of the metatarsal bone. The articulation of the internal cuneiform and the metatarsal bone of the great toe is about an inch and a half in front of the tuberosity of the scaphoid, and the base of the second metatarsal bone is seen lodged between the three cuneiform bones. In every instance these joints must be carefully located.

The Operation.—Flex the foot and mark out on the plantar surface a large semilunar flap, the base of which shall correspond to the distance between the tarso-metatarsal joints, first and fifth, as just indicated, and its distal extremity to the heads of the metatarsal bones.

Extend the foot, and draw a short dorsal flap with the convexity forward, its base connecting with and corresponding to that of the plantar flap (Fig. 570). Divide and draw the small dorsal flap upward, and commence the disarticulation at the outer side of the tarsus just behind tuberosity of fifth metatarsal. Strongly extend and adduct the bones, which will better mark the lines of the articulation; separate the fifth, fourth, and

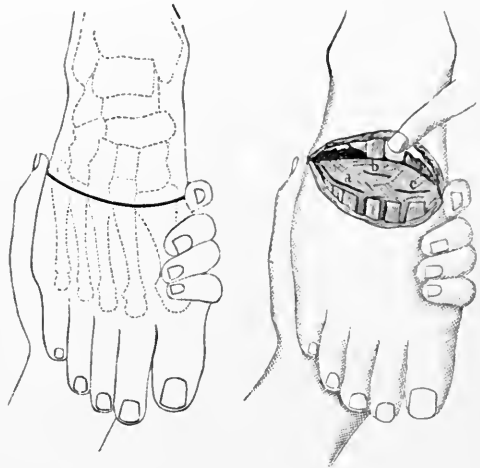


FIG. 570.—Dorsal flap. FIG. 571.—Articulation of second metatarsal.




FIG. 572.—Separating the second metatarsal.

FIG. 573.—Making plantar flap.

third articulations; skip the second and open the first. The articulation of the second with the cuneiform bones is peculiar in that it is about two fifths of an inch higher than the first and third (Figs. 571. *b*, and 572). However, with the bones depressed, a short transverse incision liberates its dorsal con-

nections with the middle cuneiform, after which it is disconnected from the internal and external cuneiform bones, as well as its contiguous metatarsal, by cutting upward (Fig. 572). Open all the joints well, divide the ligaments at the sides and plantar surface, carry the knife along the sole, and make the plantar flap as previously laid out (Fig. 573). If the flap contains all of the muscular tissues of the sole it will be too bulky; therefore a part should be omitted, more especially that portion at the hollow of the foot.

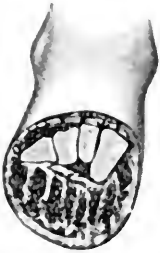

FIG. 574.—Appearance of flap (Lisfranc's amputation).

The plantar flap may be made by transfixion before the articulations are opened; this method can not be recommended, however, as the flap thus formed must await the completion of the operation without facilitating it. Moreover, if the plantar flap be made by transfixion before disarticulation, the transverse arch of the foot will be intact, causing the center of the flap to be made thin, since the knife can not come sufficiently close to other

than the first and fifth metatarsal bones to properly form the flap. After the removal of the part, the flap appears as seen in Fig. 574.

The Remarks.—This method has been variously modified, the modifications in some instances becoming confused with the original method. *Hey* sawed off the projecting portion of the internal cuneiform (Fig. 569. *b*); this, however, is not expedient, as it lessens the attachment of the tibialis anticus and shortens the leverage of the foot.

Skay sawed off the base of the second metatarsal, leaving it in the mortise (Fig. 569, *c*). This adds nothing to the usefulness of the stump, and exposes the remaining fragment to the danger of necrosis.

Baudens (Fig. 569, *d*) proposed that the first metatarsal bone only should be disarticulated, and the remaining ones sawed off transversely on a level with the internal cuneiform.

Smith (*R. W.*) practiced a modification of the operation which required the removal of the four lesser metatarsal bones close to the proximal articulations through an oblique incision extending from a point three fourths of an inch in front of the base of the fifth metatarsal bone to the metatarso-phalangeal articulation of the great toe. The plan adds to the leverage of the stump and preserves the inner and outer supports of the transverse arch of the foot better than any of the preceding modifications.

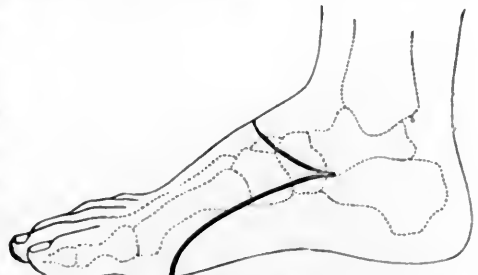


FIG. 575.—Chopart's amputation, inner incision.

Amputation through the Mediotarsal Joint (Chopart's).—

The mediotarsal joint is formed by the astragalus and os calcis behind and the scaphoid and cuboid bones in front (Fig. 569, *g g*).

This compound articulation can be readily located by drawing a trans-

verse line across the dorsum of the foot, the inner extremity beginning just behind the tuberosity of the scaphoid, the outer extremity terminating about an inch behind the tuberosity of the fifth metatarsal bone.

The Operation.—The foot is raised and a curved incision is carried around the sole, extending from the articulation of the scaphoid with the astragalus (Fig. 575) forward to within a thumb's breadth of the heads of the metatarsal bones (Fig. 576), then across the sole and backward along the fifth metatarsal bone to the outer extremity of the articulation of the cuboid and os calcis (Fig. 577).

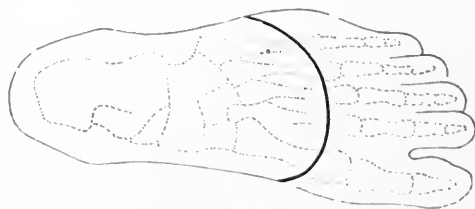


FIG. 576.—Plantar incision.

Forcefully extend the foot and

make a slightly curved incision, through the skin only, the convexity downward, across the dorsum, connecting the extremities of the plantar incision (Fig. 578). Turn the dorsal flap upward, open the joint on the dorsal surface, beginning from within, depressing the metatarsal bones toward the heel, and severing the ligamentous connections thus made tense. Finally, pass the knife through the articulation to the plantar surface, turn the edge toward the toes and complete the plantar flap by cutting downward (Fig. 579). Fig. 580 represents the stump after the flaps are united.

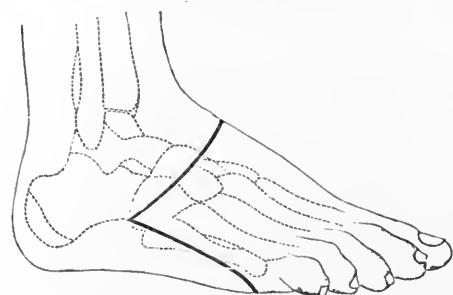

FIG. 577.—Outer incision.

extended, causing the patient to walk on the cicatrix at the anterior extremity. The division of the tendo Achillis during or subsequent to the operation is practiced to counteract this tendency, but frequently without permanent success. If the stump be confined in a flexed position during the healing, and for a time afterward, there is less danger of this annoying sequel. The suturing together over the end of the flexor and exterior tendons may correct this vice. The operation can not be recommended as a substitute for those that are to follow in point of comfort and usefulness. Better service is secured with an artificial appliance after the Syme amputation than after Chopart's.

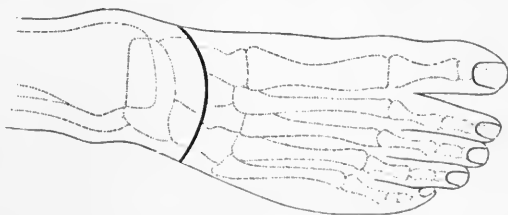


FIG. 578.—Dorsal incision.

The Results.—The mortality is about eight per cent.

Forbes's Modification.—While this modification is accomplished through

substantially the same incisions as Chopart's operation, still it is, in point of fact, a different method rather than a modification. In this the scaphoid and cuneiform bones are separated, and the cuboid is sawed through on the line of their articulation (Fig. 569, *e e*). Inasmuch as the stump by this operation is given no additional power of flexion, but retains much of the power of extension of the tibialis posterior muscle, and all the disadvantages of Chopart's operation, this method can not be commended.

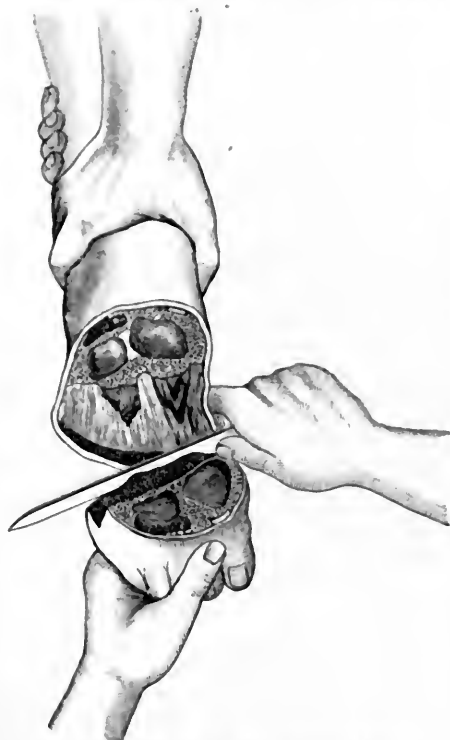

FIG. 579.—Severing the posterior flap.

Irregular Tarsal Amputations (Mollière).—In view of the great advantages to be gained by strict use of antiseptic measures in promoting union by first intention, limiting suppuration, and lessening the danger of necrosis, it is suggested that amputations across the bones of the foot be made irrespective of the articulations; in other words, that the foot be treated as if it contained but one bone. Heretofore such measures have been followed frequently by

necrosis of the fractional portions of the tarsal bones remaining in the stump.

Sub-astragaloid Disarticulation.—The sub-astragaloid amputation leaves



FIG. 580.—Appearance of stump.

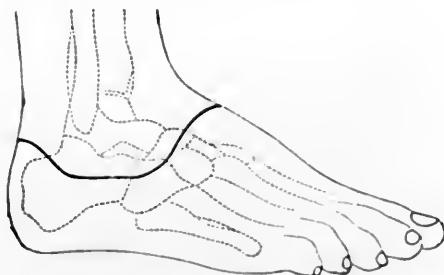

FIG. 581.—De Lignerolles's amputation, external incision.

behind the astragalus only, which forms the end of the stump. Several methods of procedure are practiced.

Lignerolles's Amputation.—Make two lateral flaps by an incision beginning immediately above the tuberosity of the os calcis on the inner side, which divides the tendo Achillis and is carried along the outer side of the os calcis in a curved direction, convexity downward, about an inch below the external malleolus; thence extending obliquely upward across the middle of the cuboid to the dorsum of the foot (Fig. 581); then vertically downward across the inner border of the scaphoid (Fig. 582) till it reaches the center of the sole of the foot; it is then turned directly backward at a right angle with the preceding cut, and joins the beginning of the incision at the inner border of the tendo Achillis (Fig. 583).

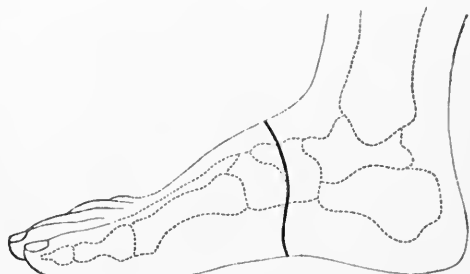


FIG. 582.—Internal incision.

Dissect up both flaps till the lateral surfaces of the os calcis and the astragalo-scaphoid joint are exposed, being careful not to injure the tibio-tarsal joint; remove the bones in front of the medio-tarsal junction; seize the anterior extremity of the os calcis with bone forceps, depress and turn it inward, and divide the external lateral ligaments with a narrow knife about a third of an inch below the tip of the malleolus; then divide the interosseous ligament between the os calcis and astragalus; finally, the talo-calcanean ligament is divided an inch below the internal malleolus (Fig. 584). The

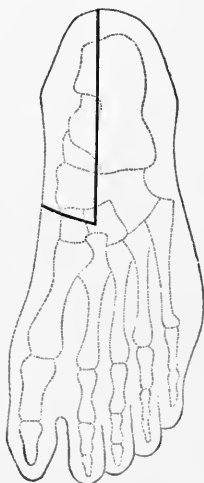


FIG. 583.—Plantar incision.

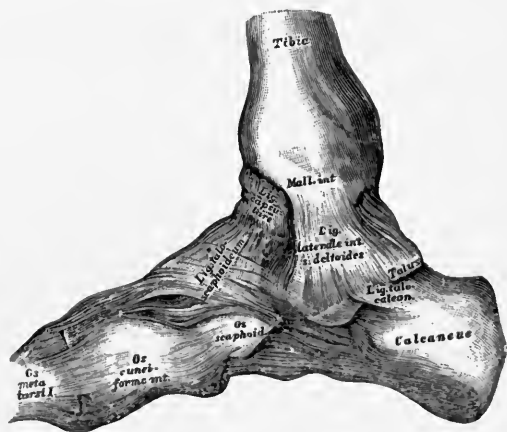


FIG. 584.—Internal ligaments.

os calcis is then removed (Fig. 585) and the flaps are united in proper position. Fig. 586 shows the appearance of the stump after union of the flaps.

The Results.—Over twelve per cent are reported to have died from the operation alone.

Verneuil's Method.—In Verneuil's operation the incision is begun at the outer tuberosity of the os calcis about an inch below the external malleolus and carried forward to within three fourths of an inch of the base of the fifth metatarsal bone; then over the dorsum to the middle of the internal cuneiform; thence obliquely across the sole by the shortest route to the commencement of the incision. The flap is raised and disarticulation accomplished in the usual manner. If the head of the astragalus be too prominent it should be sawed off.

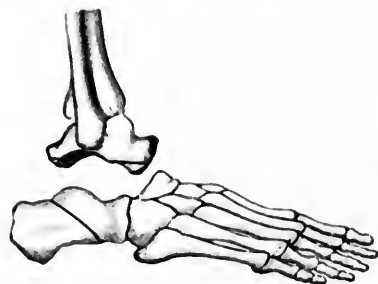

FIG. 585.—Bones separated (De Lignerolles). Bones sawed (Hancock).

The Heel-flap Method.—In the heel-flap operation begin the plantar incision half an inch below the external malleolus, carry it transversely across the sole to within an inch of the internal malleolus. The dorsal incision is begun at one end of the plantar incision and is carried downward and forward in a curved manner to the astragalo-scapoid joint; thence backward and downward, still curved, terminating at the opposite end of the plantar incision. The heel flap is dissected back to the insertion of the tendo Achillis, the dorsal flap is raised to the astragalo-scapoid articulation, which is then opened, and the blade passed backward through the calcaneo-astragaloid joint and laterally so as to separate the soft parts from the os calcis down to the tendo Achillis, which is then divided. As before, the head of the astragalus should be removed if necessary.

Hancock's Operation.—Hancock's method of procedure may be considered as a combination of the sub-astragaloid and Pirogoff methods. The operation can be made through incisions similar to those of the latter; the flaps, however, should be somewhat longer. The os calcis is sawed as in Pirogoff's method. A horizontal section of the astragalus is made (Fig. 585) and the detached fragment removed, together with the associated part of the os calcis, after which the sawed surface of the remaining portion of the os calcis is placed in contact with the under surface of the articulated portion of the astragalus.

Tripier's Operation.—By this method of practice it is thought possible to prevent the retraction of the flap and extension of the stump by the powerful muscles attached to the heel, as happens after Chopart's operation. The os calcis is divided on a level with the sustentaculum tali and at a right angle with the long axis of the tibia, which makes the cut surface of the bone parallel with the ground.

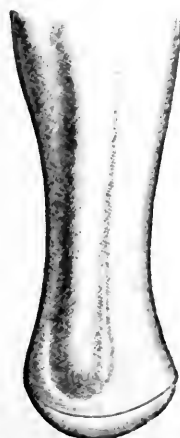

FIG. 586.—De Lignerolles's method, appearance of the stump.

The Operation.—Begin the incision of the soft parts at the outer border of the tendo Achillis, on a level with the outer malleolus, carry it along the outer border of the foot to the base of the metatarsal bone of the little toe, thence directly across the dorsum of the foot to the base of the metatarsal bone of the great toe; from this point it passes across the sole of the foot, forming there a convex flap at least one inch longer than the dorsal one, finally joining the outer incision at an oblique angle. The flaps are dissected up sufficiently to admit of the disarticulation of the medio-tarsal joint and of a horizontal section of the os calcis just below the sustentaculum tali. If the bone be divided from without inward, the posterior tibial artery is less likely to be injured. The wound is drained, the flaps are united, and the stump is dressed antiseptically.

After-treatment.—The wounded part should be kept raised, well ventilated, and lying on the side. It is better that drainage agents be limited to the openings than that they should extend through from side to side. Heel flaps may be punctured longitudinally for drainage.

The Results.—An analysis of 880 cases of tarsal amputations, including the methods of Lisfranc, Chopart, and the modifications, shows that of 628 cases done before asepsis, 22.9 per cent died, and of 252 operations performed under asepsis, 8.7 per cent died.

Amputation at the Ankle Joint—Removal of the Entire Foot (Syme's Method).—Syme's amputation may be considered one of the most practical

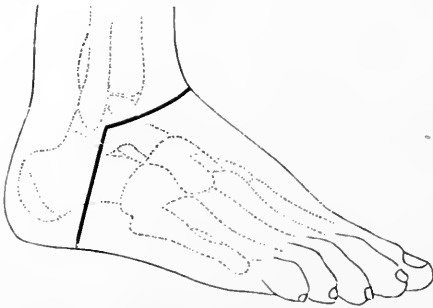


FIG. 587.—Syme's method, outer incision.

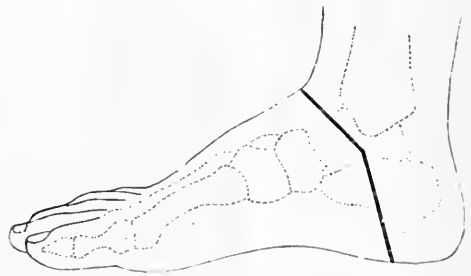

FIG. 588.—Inner incision.

of the operations on the foot and ankle. It is followed not only by a low rate of mortality, but also by a most serviceable stump, either with or without an artificial appliance. The patient is placed upon a table with the leg overhanging it, the thigh raised by an assistant, who at the same time flexes the condemned foot upon the leg by seizing and pulling upward on its anterior portion. The outlines of the respective flaps should now be carefully drawn before the incisions are commenced. The line indicating the proper course of the plantar incision begins at the apex of the external malleolus, and with a slight backward inclination passes around the foot (Fig. 587) to a point opposite to its beginning, which is about a finger's breadth below the apex of the internal malleolus (Fig. 588).

The second or dorsal line is drawn directly across the instep, and connects the extremities of the plantar incision.

The Operation.—The surgeon selects a large scalpel with a strong shank, and inserts the point at the commencement of the incision down to the bone at a right angle to its outer surface, with the edge undermost; carries it along the guiding line in contact with the bone to its inner

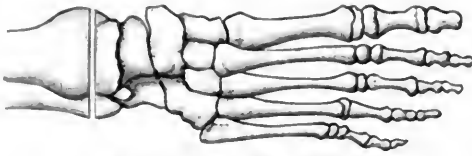


FIG. 589.—Bones of leg sawn through.

extremity; places the fingers on the heel and the thumb within the cut, and draws firmly backward on the heel flap, at the same time liberating it from the outer surface and sides of the os calcis, back to near the insertion of the tendo Achillis. An incision is

now made down to the bone on the anterior line; the joint is opened in front; the foot is well extended, lateral ligaments are divided, and the foot is removed by liberating the remaining tissues attached to the posterior surface of the os calcis, including the tendo Achillis; always remembering to closely hug the bone, else the flap may be perforated and its integrity impaired. After the removal of the foot, dissect up the soft parts around the malleoli a sufficient distance to permit the articular ends of the bones to be sawed off (Figs. 589 and 590); cut off the extremities of the tendons even with the cut

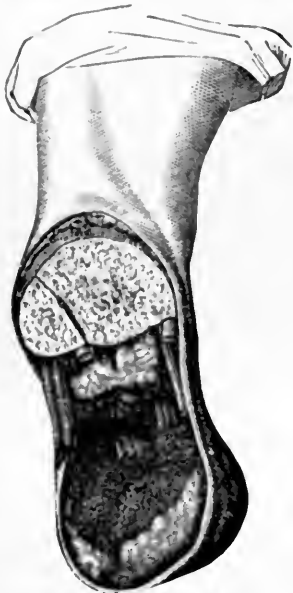

FIG. 590.—Heel flap.

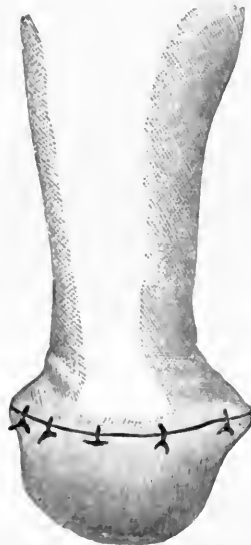

FIG. 591.—Flaps united.

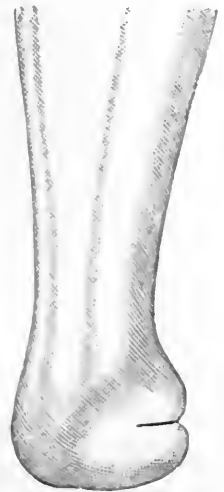

FIG. 592.—Side view of stump.

surfaces of the soft parts, bring the flap into position, unite it in front (Figs. 591 and 592), and dress with care.

The Modifications.—Sawing the malleoli obliquely with a transverse section of the posterior lip of the tibia (Fig. 593) instead of removing them, together with a thin transverse section that includes the entire articular

surface of the tibia as recommended by Mr. Syme, is a modification which has been long and somewhat extensively practiced. It is believed to give a better-shaped stump, and to be attended with less danger to life than if the bony canals of the tibia be freely opened, as in the case of complete transverse section.

Wyeth carries the inner part of the plantar incision as far forward as practicable to add to the nutritive safety of the flap.

Many surgeons, after making the plantar incision, open the joint in front, as before described, disarticulate, and then dissect the heel flap from behind forward.

This course affords more room and leverage to aid in the removal of this flap, but increases the danger of cutting it, and also permits the blood to flow downward and interfere with the final separation of the heel flap. The removal of the periosteum from the sides and the posterior surface of the os calcis, including the insertion of the tendo Achillis, has been practiced. If this can be done without too much laceration of its structure, it is a commendable modification. Before puberty the epiphysis of the tuberosity of the os calcis may be detached and allowed to remain connected to the heel flap.

The articular cartilage remaining on the extremity of the tibia is scraped off by some operators; this procedure is thought to hasten the healing process. Many methods, adapted to various forms of injury to the soft parts, have been devised to modify the construction of the flaps so as to cover the end of the stump. When the formation of the heel flap is impossible, tissues can be taken from all or either of the three remaining aspects of the foot, being ever cautious to avoid injuring the posterior tibial artery where it lies below the inner malleolus.

The Fallacies.—The incision across the instep lies below the line of articulation between the astragalus and the tibia; therefore, unless care be taken to locate the joint, the operator will cut down upon the neck of the astragalus, and, not finding the joint, will become much confused; or he may even open the articulation between the scaphoid and astragalus. If the plantar flap be made too long, it will be impossible to carry it back over the point of the heel; therefore, if it be necessary to make a long heel flap, the joint should be opened at once from before backward, and the heel flap dissected off from above downward. If the dorsal flap be lengthened for any reason the heel flap must be decreased correspondingly. The saw line for removal of the articular surface of the tibia should be made close to the

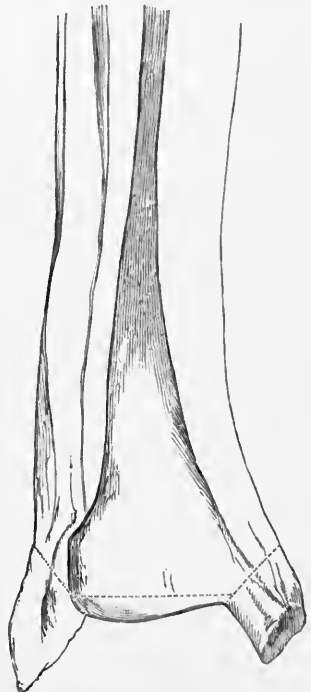

FIG. 593.—Oblique division of malleoli and removal of posterior lip.

dome of the articulation, thus avoiding needless sacrifice of bone in the adult or involvement of the epiphyseal cartilage in the young.

The Results.—The rate of mortality from Syme's operation is from five to nine per cent; the functional results are admirable.

Roux's Method.—Begin the incision at the outer side, a little above the insertion of the tendo Achillis; carry it straight forward beneath the outer

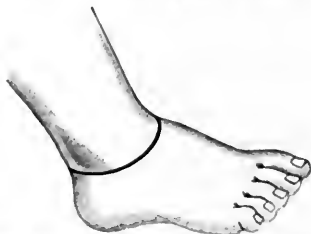


FIG. 594.—Roux's method. Outer incision.

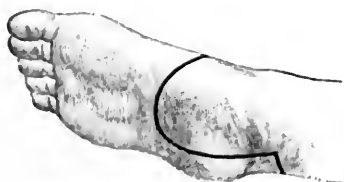

FIG. 595.—Inner incision.

malleolus (Fig. 594); then in a curved line across the instep an inch in front of the articular edge of the tibia, passing backward and downward on the inner side of the foot between the inner malleolus and the tuberosity of the scaphoid to the sole (Fig. 595); thence

obliquely backward to a point about an inch behind the tuberosity of the fifth metatarsal bone; and finally backward and upward over the outer surface of the heel to the point of beginning. Dissect up the external flap, open the joint at the outer side, and complete the internal flap after disarticulation of the foot. The bones of the leg should then be divided as in Syme's method, flaps united, and the wound dressed antiseptically.



FIG. 596.—Pirogoff's amputation. Lines of section of os calcis.

The Remarks.—This operation, while more difficult and less satisfactory than Syme's, can be wisely employed when for any reason the latter is of doubtful utility.

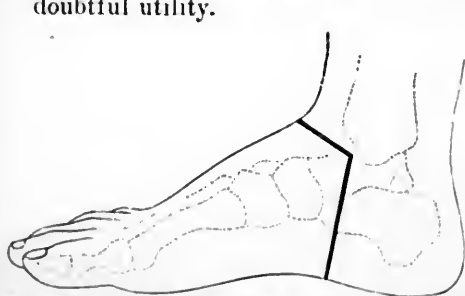


FIG. 597.—Pirogoff's amputation. Inner incision.

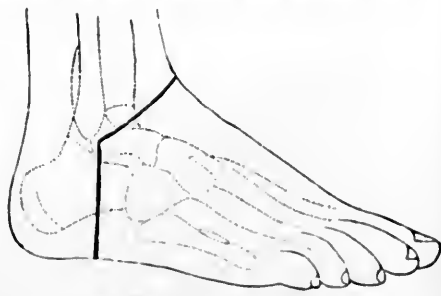


FIG. 598.—Outer incision.

Pirogoff's Amputation.—Pirogoff's operation is osteoplastic in character, and consists in the application of the sawed surface of the posterior portion of the os calcis (Fig. 596) to the sawed surfaces of the bones of the leg. The

length of the limb is well preserved, and, without the use of an artificial appliance, the stump is often superior to that of Syme's operation.

The Operation.—Flex the foot at a right angle with the leg; make an incision from the tip of the internal malleolus across the sole a little in front of the long axis of the tibia (Fig. 597), to a point in front of the apex of the external malleolus down upon the bone (Fig. 598), and dissect the flap backward from the os calcis for about a quarter of an inch.

Connect the extremities of this incision by another carried down to the bone half an inch in front of the lower extremity of the tibia. Open the joint in front, divide the lateral ligaments (Fig. 599), expose the upper surface of the os calcis, draw back the detached portion of the heel flap, and with a narrow saw divide this bone obliquely downward and forward parallel with and a little posterior to the line of the plantar incision. Raise the anterior flap, dissect up the tissues around the lower ends of the bones, and saw through the lower extremities of the tibia and fibula, from just above their articular surfaces in front to a point half an inch above the articular surface of the tibia posteriorly. Cut off the divided tendons on a level with the wound.

The cut surface of the os calcis is then brought forward and placed in contact with that of the tibia, the wound united and dressed antiseptically.

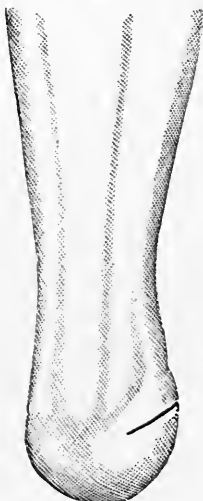


FIG. 600.—Appearance of stump.

The Remarks.—If the posterior border of the os calcis be cut too thick, the divided bone surfaces can not be properly apposed without force, which will cause the fragment to tilt backward. The tilting can be remedied by removing more bone from the posterior border or by dividing the tendo Achillis. Whenever this tendon inclines to tilt the bone, it should be divided. The bone fragment can be united to the tibia by silver wire, thus retaining the sawed surfaces firmly in apposition. The os calcis is sawed at different angles by different operators (Fig. 596), but the one just considered has given the most satisfactory results. Fig. 600 shows the appearance of the stump after Pirogoff's operation.

The bone in the flap may become displaced by the muscles of the calf, may necrose, or fail to unite. The latter contingencies are referable especially to elderly subjects.

The Results.—The death rate from this operation is about ten per cent by old methods.

The Modifications of Pirogoff's Operation.—These modifications are not a few and are of fanciful utility in some instances.

Fergusson's Modification.—This modification consists in retaining the

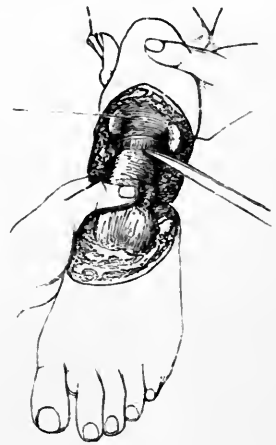


FIG. 599.—Separating articular surfaces.

malleoli, unless diseased, and placing the sawed end of the os calcis between them after having divided the tendo Achillis. *Turnipseed* and others practiced this modification and advised it. We are not disposed to commend it.

Le Fort's Modification.—In *Le Fort's* modification the incisions for the flaps are quite similar to those of *Syme's* amputation. The ankle joint is exposed by raising the dorsal flap, keeping close to the bone so as not to injure the anterior tibial artery. Divide the external lateral ligament and the ligaments between the astragalus and os calcis. Turn the foot inward, and remove the anterior portion of the foot at the medio-tarsal joint. Seize the as-

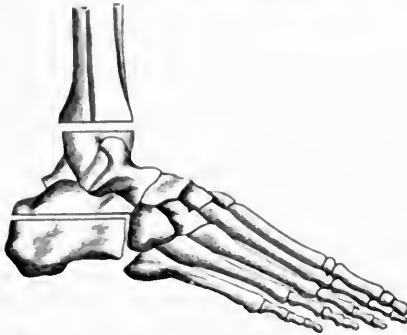


FIG. 601.—Sawn bones in *Le Fort's* modification.



FIG. 602.—Appearance of stump.

tragalus with strong forceps, make tense and cut the ligaments connecting it with the bones above, and then remove it. Push down the os calcis, and with a narrow saw remove its upper third horizontally from behind forward, beginning just above the insertion of the tendo Achillis. Saw off the malleoli

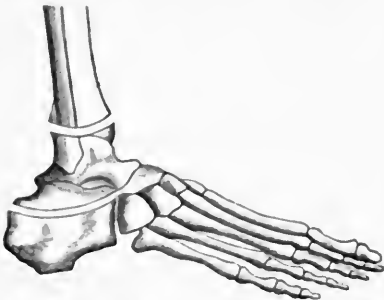


FIG. 603.—Sawn bones in *Brun's* modification.

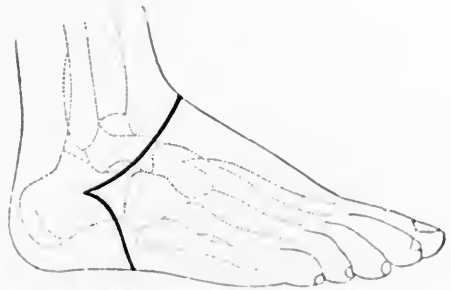


FIG. 604.—*Esmarch's* modification. Outer incision.

and the articular surface of the tibia also horizontally (Fig. 601); place the sawed surfaces in apposition, and dress in the usual manner. This modification permits the preserved fragment of the os calcis, when placed in position, to maintain the same axis relative to the end of the stump that it held in the foot; consequently, the direct pressure is received upon integumentary

covering already adapted to that purpose (Fig. 602). It also provides a broader support, and for these reasons is regarded by some as superior to the Pirogoff method.

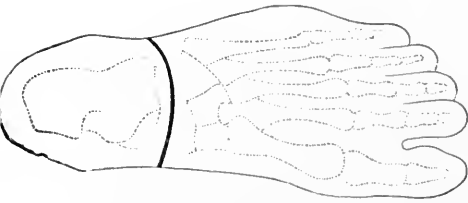


FIG. 605.—Plantar incision.

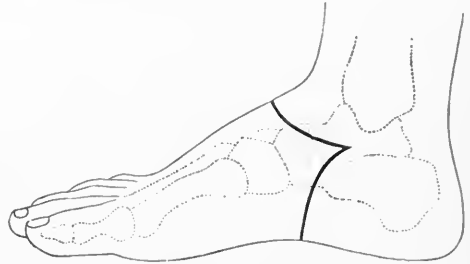

FIG. 606.—Inner incision.

Bruns recommended that the sawed surface of the os calcis be made concave and that of the tibia convex (Fig. 603).

Esmarch's modification of Le Fort's operation consists of making two incisions: one across the sole, the other across the dorsum of the foot. The former commences about four fifths of an inch below the tip of the external malleolus, and passing forward (Fig. 604), runs under the cuboid and scaphoid bones (Fig. 605), ending at the inner side, one inch below and just in front of the internal malleolus (Fig. 606). The curved dorsal incision (Fig. 607), with its convexity forward to the tuberosity of the scaphoid, connects the extremes of the plantar one. Dissect up the dorsal flap to the tibio-tarsal joint, open the joint, depress the foot, expose the upper surface of the os calcis sufficiently to apply a small saw behind the upper margin of its posterior surface, and saw the bone as before described.

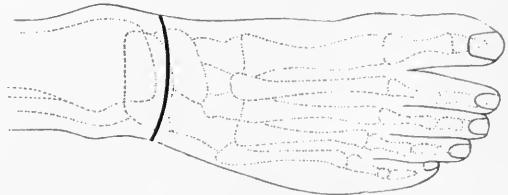


FIG. 607.—Dorsal incision.

The Results.—Grouping the methods of Syme, Pirogoff, and the modifications, 544 amputations at this situation shows: 340 cases before asepsis, with a mortality of eighteen per cent; 204 done aseptically, with 2.95 per cent fatality.

AMPUTATIONS AT THE LEG.

Amputation at the leg is of great importance, as it directly involves the comfort and usefulness of the patient. The unequal arrangement of tissues and the necessity of providing a bearing surface suitable to meet the demands of the burdens and pleasures of life, add emphasis to the importance of considering the occupation of the individual in amputation here. However, the local arrangement of tissues has not all to do with the outcome of amputation, for while a badly constructed stump is a serious affliction, yet if to this be added the local effects of intemperance and of inattention to the part, the full measure of physical disaster in this regard is realized.

Amputation of the Leg at the Lower Third.—At this situation the crest of the tibia and the interosseous space are reduced to a minimum, and tendons predominate throughout nearly the entire location. The following methods of amputation will be considered:

Guyon's method, Duval's method, the Author's method, Teale's method, the large posterior-flap method, the bilateral-flap method, and the hood-flap method.

The Amputation by Guyon's Method (supramalleolar).—In Guyon's amputation two incisions are made, one at either side of the foot, each beginning in front at the center of the ankle joint, and passing downward and backward in a curved direction just anterior to the respective malleoli and terminating at the summit of the curve of the heel (Fig. 608, *a*). The heel flap is dissected upward, carefully avoiding the posterior tibial vessels, the tendo Achillis severed, and the bones of the leg are exposed for two inches above the tips of the malleoli (*a'*), and then sawed horizontally at that situation. This method properly locates the cicatrix and provides good tissue for the flap. Drainage, however, is faulty unless a small slit be made in the flap posteriorly, or the limb be so placed as to facilitate the escape of the discharges.

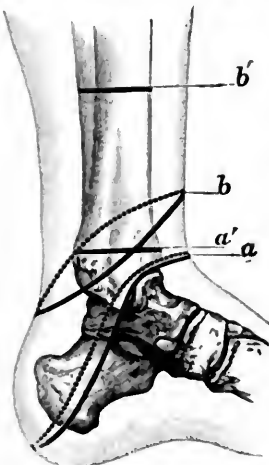


FIG. 608.—*a*. Guyon's supramalleolar amputation. *a'*. Saw line of same. *b*. Duval's supramalleolar amputation. *b'*. Saw line of same.

The Amputation by Duval's Method (supramalleolar).—In Duval's amputation the place at which the bones are to be sawed is higher than in the preceding; the point of amputation is first determined in order to estimate properly the outline of an elliptical incision in forming the flap to cover the end of the stump. The posterior extremity of the ellipse is located at a point below the place of sawing, a distance equal to one and a half times the antero-posterior diameter of the limb at the site of proposed section (*b'*), and the anterior extremity of the ellipse, at a point below the same place, a distance equal to three fourths of the same diameter. This incision crosses the leg laterally at an angle of about 45° (Fig. 608, *b*). The skin is reflected upward carefully to just above the line of proposed bone division, the bones are sawed horizontally, and the borders of the ellipse united antero-posteriorly with sutures. The tendo Achillis is cut near its insertion. It is advised by some that its extremity be united by deep sutures to the extremities of the tendons in front. This operation places the cicatrix nearer the end of the stump and provides a flap less inclined to friction than does the former method.

Amputation by the Author's Method.—This method comprises the making of a circular integumentary flap provided anteriorly with an attached periosteal lining. If the site of operation can be chosen it should be about three or three and a half inches above the lower extremity of the tibia, or, more definitely speaking, just below the point where the tapering of the limb

ceases. The length of the flap should exceed by one inch a fourth of the circumference of the limb at the proposed point of bone section.

The Operation.—Lay out the flap as just indicated; make a circular incision through the integument and subcutaneous tissue down to the fascia of the muscles and the subcutaneous surface of the tibia. Dissect the sleeve upward for about an inch, then divide the periosteum at the subcutaneous surface of the tibia by a transverse incision at the level of reflection of the flap; also divide it longitudinally at the outer and inner borders of the subcutaneous surface of the tibia a sufficient distance—half an inch—to allow the periosteum to be reflected upward while attached to the inner surface of the flap. These longitudinal incisions are increased as often as it becomes necessary to detach the periosteum to keep pace with the turning up of the remaining part of the flap—that is, instead of turning up from the subcutaneous surface of the tibia an integumentary flap only, the periosteum of this surface is detached from a proper area of the bone up to the

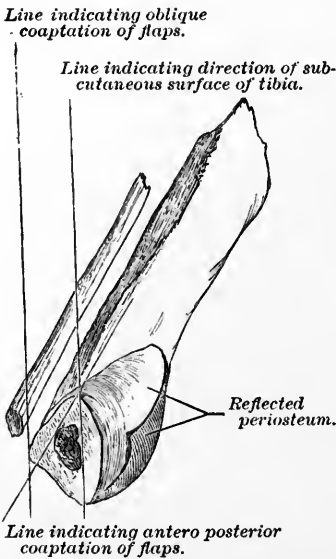


FIG. 609.—Reflection of the periosteum.

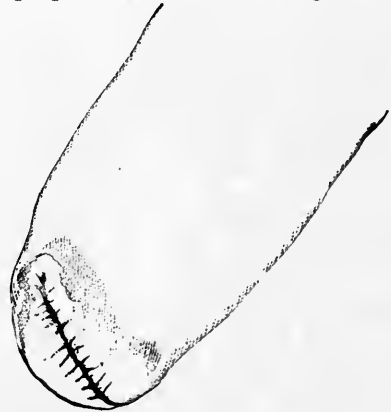

FIG. 610.—Oblique coaptation scar.

saw line, being raised along with, and not separated from, the integument which overlies it, thus forming a limited lining of the flap. Fig. 609 shows the extent of the reflection of the periosteum from the tibia, the other soft parts having been removed. After circular division of the muscles half an inch below the reflection of the flap, the tibia is sawed through at the highest point of periosteal reflection, the fibula is exposed one fourth of an inch higher up and divided by sawing toward the tibia. The flaps are united obliquely, parallel with the margin of the subcutaneous surface of the tibia, so that the line of union falls between the bones, and the periosteal lining of the flap falls and lies smoothly across the extremity of the tibia (Fig. 610). It will be necessary in order to reflect the sleeve flap that it be divided longitudinally at a point that will be lowermost when the flaps are obliquely joined.

The Remarks.—The limb should be dressed carefully, cautiously maintaining the oblique direction of the flaps till the healing process is complete. The periosteal flap grows to the end of the tibia, lessening the liability of

atrophy of the bone and likewise obviating the adhesion of the cicatrix to the end of the tibia. Fig. 611 shows a vertical section through the flap made three months after operation by the writer.

The Results.—Of the fifteen cases performed by the writer all but one have resulted in exceptionally serviceable stumps. In no instance has bony spiculæ appeared.

The Amputation by Teale's Method.—Teale's amputation has not been practiced to any extent in this country. The details of the method are comparatively intricate, and the high division of the bones often cause an unwise sacrifice of leverage, especially important in connection with modern prosthetic appliance. However, if the method be employed, the lower third of the leg affords the best site, as there the long flap can be extended well downward. The flaps are rectangular, and should be carefully marked

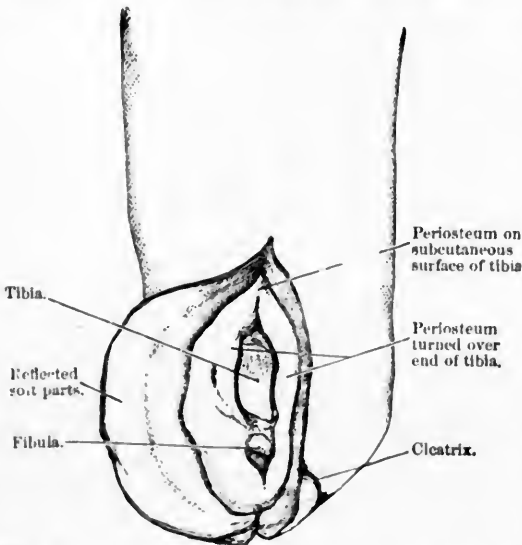


FIG. 611.—Dissected specimen showing the relation of parts.

out before the incisions are made. The length of the anterior flap is one half the circumference of the limb at the point of amputation, and the posterior one eighth. The anterior flap is made by two lateral incisions going down to the bone, supplemented by a short transverse one at the lower margin of the flap. The posterior flap is made by a vigorous cut down to the bone. The anterior includes all of the tissues in front, and the posterior all of those behind the bones. The bones are sawed through in the usual manner, and the stump is carefully dressed. Although a

good cushion is provided at the end of the stump and the cicatrix is removed from direct pressure, still, the stump is not a more serviceable one than can be secured by more conservative methods.

The Amputation by the Large Posterior-flap Method.—In this method the length of the posterior flap is made to exceed one half the circumference of the limb at the proposed point of bone section, and the anterior is a little more than one eighth of the same circumference. The posterior flap is limited by an outer and an inner incision carried through the integument and fascia from the saw line to near the insertion of the tendo Achillis (Fig. 612, a). The inner one passes in front of the inner border of the tibia; the outer passes behind the fibula; they join together in a curved manner near the insertion of the tendo Achillis. The muscles at the outer and posterior surfaces of the tibia are then disconnected from that bone, by

cutting and blunt dissection for a distance of two inches. The soft parts at the back of the limb are now grasped by thrusting the thumb and finger into the gaps caused by the separation, and the posterior flap is completed by cutting from without inward (Fig. 613). During the division of the muscles the foot should be somewhat flexed. The anterior flap is now made down to the bone and dissected up, the interosseous membrane is divided, retractors are adjusted, bones sawed, and the posterior tibial nerve is divided to above the point of bone section. The muscular structures of the respective surfaces of the limb can be joined with deep sutures.

The Amputation by the Bilateral-flap Method.

—The bilateral-flap method (Fig. 617, a) consists of equilateral flaps constructed from the integument and subcutaneous tissue at the outer

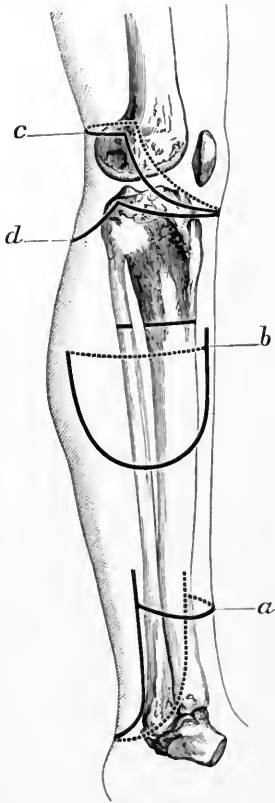


FIG. 612.

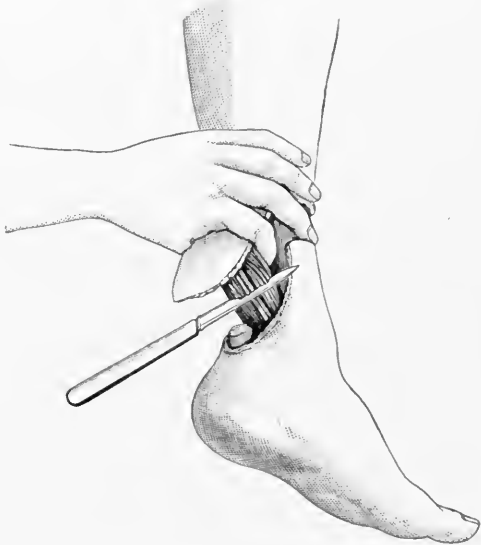

FIG. 613.

FIG. 612.—a. Amputation, lower third, large posterior flap. b. Amputation, upper third, large external flap. c. Carden's amputation. d. Lister's modification.

FIG. 613.—Making large posterior flap.

and inner surfaces of the limb. The operation may be performed in this method with or without the periosteal lining. The circular method, with oblique coaptation, is far the better if the periosteum be raised, since in antero-posterior coaptation the periosteal flap is tilted, and is more liable to eversion and the production of bony spicular growths.

The length of the bilateral flaps is estimated in the usual manner. Therefore, the width of each flap at the base is equal to half, and the length is in excess of one fourth the circumference. Each one is nearly semicircular, and the points of junction should be at the center of the limb, anteriorly

and posteriorly, thus bringing the anterior point of union to the inner side of the crest of the tibia; it should also be well below the point of the proposed section of the tibia. The posterior point of junction is considerably above that of the anterior, to provide for suitable drainage. After having been properly outlined, each flap is dissected upward to near the point of bone division; the muscles are divided by a circular incision, then pushed upward above the anterior point of union of the flaps, and the tibia is sawed off on a line corresponding to the junction of the flaps posteriorly. The fibula is sawed a fourth of an inch the shorter. If there be an undue amount of muscular tissue behind, it can be trimmed off until it admits of the ready union of the borders of the flaps. Suitable drainage, antero-posterior coaptation, and an antiseptic dressing comprise the immediate attentions in the case.

The amputation by the hood-flap method is a modification of the circular, the skin cuff being slit up posteriorly to the point at which the bone is to be divided, and the corners trimmed off to resemble the outlines of the lower portions of the bilateral flaps. This flap is then reflected upward, and the muscles and bones divided as before. The line of coaptation is antero-posterior (Fig. 617, a).

The advantages claimed for this method are: perfect drainage; the location of the cicatrix on the posterior surface of the stump; and the falling of the integument over the end of the bone, thus obviating the presence of a cicatrix at that point. Like the bilateral, it can be employed in connection with the periosteal flap; still, as it is joined to form an antero-posterior line of union, it is open to the same objections as the bilateral with reference to the proper application to the bone of the periosteum.

The Results.—Of 2,343 cases of amputation at the lower third of the leg, 1,909 were done before sepsis, with a mortality of 24.6 per cent, and 434 were done under asepsis, of which 11.6 per cent died.

Amputation of the Leg at the Middle Third.—The limb can be amputated at this part by the methods employed at the lower third, and the principles applicable to the lower third have an equal force at this situation. The presence of the calf offers an additional difficulty in obtaining the oblique coaptation, but does not interpose an insurmountable obstacle to it. Care in dressing the stump will maintain the obliquity of the line of coaptation in the periosteal-flap method. The bilateral- (Fig. 617) and hood-flap methods, either with or without the periosteal lining, present to the surgeon the means of making a serviceable stump. Amputation here can also be performed by either the large posterior- or the large external-flap method.

The Amputation by the Large Posterior-flap Method (Hey).—In this method first ascertain the circumference of the limb at the point of proposed amputation; then mark off two U-shaped flaps, posterior and anterior, the base and length of the former equaling one half the circumference of the limb, and the length of the latter one sixth. The leg is flexed on the thigh, and the skin and subcutaneous tissues are divided with a scalpel along the line of the posterior flap as indicated. Flex the foot and divide

the gastrocnemius in the line of the incision; separate the remaining soft parts at this situation from the posterior surfaces of the bones, grasp them with the thumb and fingers and sever them from within outward with a sharp transverse cut; separate further the soft structures from the bones up to the saw line; make the anterior flap by dividing first the integument and subcutaneous tissue, and then severing the muscles down to the bone and displacing them upward to the saw line in front; divide the interosseous membrane; apply the three-tailed retractor and saw the bones transversely. The triangular projection of the crest of the tibia is then removed to prevent its impingement on the anterior flap.

Lee practiced amputation at this part of the limb after the method of *Teale*, except the long flap was placed posteriorly, and only the muscles of the calf were included in it. Both flaps were reflected upward to the point of bone section, the remaining soft parts were divided transversely, the retractor was adjusted, and bones sawed through as before. Both methods provide serviceable stumps; the latter is more easily performed, but requires higher division of the bones than the former method. In neither method is good drainage provided.

The long external-flap method, having a semicircular incision on the inner side, offers good drainage, and carries the cicatrix beyond the point of pressure. These flaps may be either integumentary or muscular; the latter are made by transfixion or the reverse; the former by external incision with the ordinary scalpel, and circular section of the muscles with the long knife. The principles controlling the length of the flaps are the same as previously stated for single flaps. The long flap should be made from the outer side of the leg, having a base equal to one half the circumference of the limb. The inner or short flap is semicircular in outline (Fig. 614). The bones are sawed off just above the anterior point of junction of the flaps, united, and the wound is dressed as before.

The Results.—Of 1,967 cases, 1,751 before asepsis had a mortality of 27.8 per cent; of 217 under asepsis, 11.2 per cent died.

Amputation of the Leg at the Upper Third.

—Amputation at the upper third involves much more tissue than at either of the preceding parts of the limb. Either variety of flap employed at the middle third can be utilized at the upper, but modifications of procedure are advisable on account of the difference in the bulk and relation of the tissues at the upper third.

The Amputation by a Large External Flap (*Farabeuf*).—The flap is U-shaped, and the length is equal to one third the circumference of the limb at the point of bone section. It is marked out carefully before division, beginning in front at the level of the proposed bone section, and passing downward the proper distance along the inner border of the crest

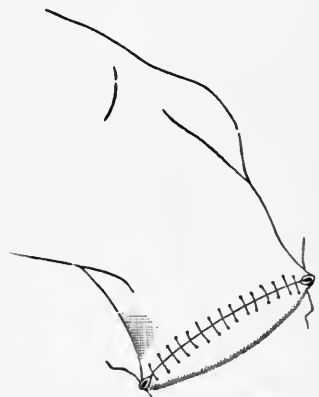


FIG. 614.—Long external-flap method.

of the tibia, is carried in a curved direction across the outer aspect of the limb, and then upward in a line diametrically opposite the anterior incision to a point about an inch and a half below the level of the primary point of departure (Fig. 617. *b*). Flex the leg and divide the skin and subcutaneous

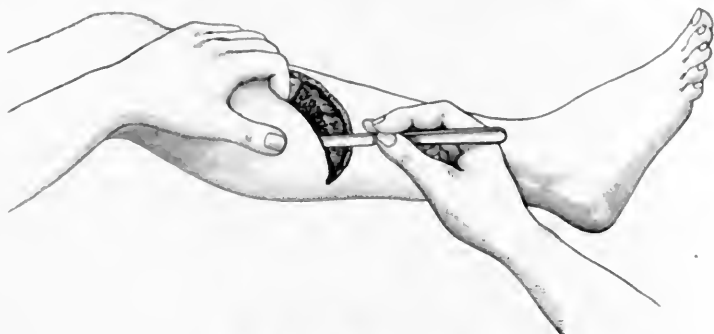

FIG. 615.—Making the flap.

tissue throughout the entire course of the flap with a scalpel. Then divide the muscles obliquely from above downward and outward down to the bone and interosseous membrane (Fig. 615); separate them upward carefully to the point of bone section, cautiously avoiding injury of the anterior tibial artery as it appears in front of the interosseous membrane. The tissues at the inner side are divided transversely down to the bone by transfixion or otherwise, and separated from the bone up to the line of section. The

periosteum of the tibia is divided an inch below the line of proposed section by a circular incision, then at each side of the bone by a short vertical one; the anterior and posterior flaps thus formed are pushed upward by the elevator to above the saw line; the interosseous membrane is divided, the retractor adjusted, and the bones are sawed in the following manner: Divide the fibula obliquely from above downward and inward, about a quarter of an inch shorter than the tibia; saw the tibia across and remove the sharp projection at the anterior border with a mallet and chisel (Fig. 616); adjust the periosteal flaps, sew them in place with catgut, and unite the flaps in the usual manner. It is much better to strip off the periosteum without disturbing the superimposed tissue, as thus its vitality is better

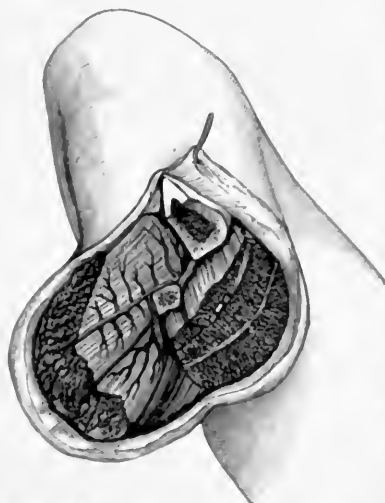

FIG. 616.—Flap formed and crest of tibia sawed.

preserved. Treves regards this method with great favor.

The Amputation by the Circular-flap Method.—In the circular method

the length of the cuff is made nearly one half the circumference of the limb at the point of bone section.

The flap is made by a circular sweep of the knife. As the posterior part retracts considerably, the anterior is dissected up until it retracts an equal amount, after which the gastrocnemius is seized and cut off on a line with the reflection of the integument. The integumentary cuff is carried up (the gastrocnemius accompanying the posterior part) nearly to the line of bone section. The remaining soft parts are divided transversely down to the bone a little below the saw line, the retractor is applied, and the bones are sawed as in the preceding method. The periosteum and the projection of the bony crest are also treated as in the preceding instance. Direct pressure is not well borne at the end of this stump, but when flexed it is very serviceable.

The Amputation by the Bilateral-flap Method (Fig. 617, *b*).—This method has been described already in amputation of the lower third of the leg. At the upper third the flaps should each equal in length one third of the circumference of the limb at the seat of amputation. In other respects no substantial difference in the procedure obtains. The bilateral-flap method

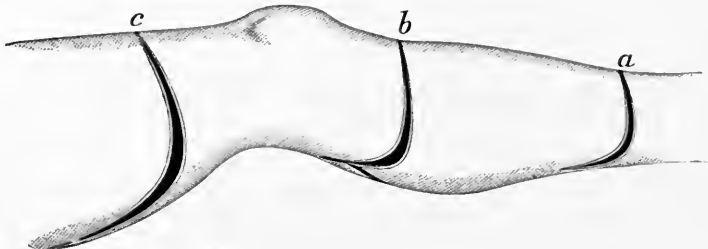


FIG. 617.—Bilateral-flap method, sometimes called hood-flap method.

is regarded by many surgeons as one of the most useful that can be employed. It is called sometimes the hood-flap method.

The after-treatment in amputations of the leg is substantially similar in each instance: the flap should be well supported without undue pressure, the stump slightly elevated and comfortably placed on a pillow; drainage agents should not extend into the wound needlessly, and care is required to maintain the flaps suitably after removal of the sutures.

The Results.—Of 920 amputations at this situation, 614 before asepsis, 69.8 per cent died; 306 under asepsis, 39.8 per cent died.

Amputation at the Knee Joint (*Disarticulation*).—The dangerous sequels that formerly rendered amputation at this joint a much-dreaded procedure are now eliminated, or so modified by modern antiseptic technique as to place it high in the list of amputations near to this point, as a conservative measure of undoubted good repute. Not only is the rate of mortality comparatively low, but its worth as a serviceable pressure-bearing stump is of the highest order. The makers of prosthetic appliances are unreserved in their expressions of approval of the latter fact. The condyles of the femur not only offer a broad bearing surface, but also serve an important purpose

in retaining the artificial appliance in good position, because of the excellent grasp they furnish the instrument at the thigh.

In this operation the joint surface is not disturbed; the semilunar cartilages are left attached to the femur, thus reducing to a minimum the retraction of the synovial pouch and the surrounding tissues. The patella is not removed unless it be diseased, and therefore provides continued attachment for the quadriceps muscle. The patella presents no local obstacle to use of the limb, for it finally rests out of the way just above and on a level with the condyles. The ligaments should be cut short, and the popliteal artery tied only after sufficient isolation is practiced to secure ample space for proper occlusion of the vessel.

The Anatomical Points.—The inner condyle of the femur is larger and more prominent than the outer, therefore the inner flap should be made correspondingly longer. The apex of the patella is on a line with the margin of the upper extremity of the tibia. The synovial membrane proper of the joint extends about an inch above the patella, and above this limit a synovial bursa is found beneath the tendon of the quadriceps and the lower portions of the vasti muscles. The bursa communicates with the joint in about eighty per cent of the cases by an opening of varying size, and is an important factor in the after-treatment, since, when connected with the joint, it may collect and retain for a time the discharges (page 417).

Amputation at the knee joint may be performed by the following methods:

Amputation by the bilateral-flap method, the elliptical incision method, the circular-incision method, and by the long anterior-flap method.

The Amputation by the Bilateral-flap Method (Stephen Smith).—This method is properly a hood-flap method, and is, without doubt, superior to any yet devised. It provides two well-nourished flaps, which, when united, locate the cicatrix between the condyles posteriorly, also affording admirable drainage.

The Operation.—With the thigh elevated and the leg extended, begin the anterior incision of each flap one inch below the tuberosity of the tibia, cutting through the skin and subcutaneous and muscular tissues. Carry the incision of one side downward and forward below the curve of the leg, thence inward and backward to the middle of the under surface of the leg, then directly upward to the middle of the popliteal space (Figs. 617, *b*, and 633, *a*). The opposite flap is made in a similar manner, remembering, however, that the flap at the inner side must be made the longer, on account of the greater length and size

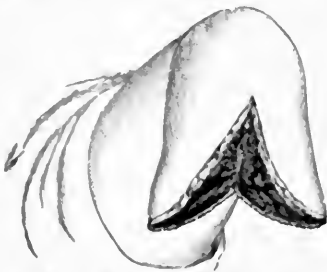

FIG. 618.—Appearance of the flaps.

of the inner condyle. Raise the flaps until the apex of the patella and the articulation are reached; divide the ligamentum patellæ; open the joint in front; divide the crucial ligaments; draw the head of the tibia forward, and pass a long knife behind it; extend the leg somewhat and cut the

remaining tissues directly across. After removal of the leg the flaps present the appearance shown in Fig. 618. The flaps are then united and suitable drainage is provided. When healed the stump presents the appearance shown in Figs. 619 and 620.

The Precautions.—Before severing the posterior tissues be careful to ascertain if perfect control be had of the femoral artery. A perplexing sequel to this operation, in rare instances, is the formation of an abscess beneath the quadriceps extensor, due to the collection of pus at the upper synovial pouch when connected with the joint, the elevation of the stump causing the discharges to gravitate to that point. This complication can be avoided by the division of the lateral synovial bands commanding the entrance to the pouch and the introduction of a drainage tube to the uppermost portion, or by carrying the tube through the uppermost extremity to the anterior surface of the thigh. Sometimes compression firmly and continuously applied over the pouch will answer the purpose of prevention. If care be not taken in the application of the dressings, undue pressure

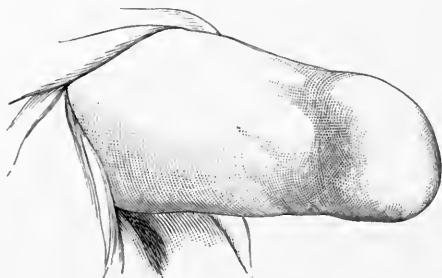


FIG. 619.—Side view of stump.

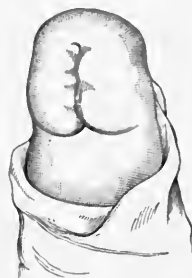


FIG. 620.—Posterior view of stump.

will be made on the tissues covering the condyles of the femur, causing ulceration and even sloughing of the flaps at these situations.

The Fallacies.—The operation has, however, this fallacy, which has been the cause of much chagrin to surgeons on rare occasions, the danger of making the flaps too short, followed by the necessity of removing the patella, or sawing off the condyles before the flaps can be properly united. If the semilunar fibro-cartilages be permitted to remain connected with the femur they lessen the degree of retraction of the soft parts; but they not infrequently slough and come away.

Amputation at the Knee Joint for Gangrene of the Toes and Foot due to an Atheromatous Condition of the Arteries (Stephen Smith).—In relation to the procedure, Dr. Smith says: "This operation was devised for the purpose of securing well-nourished flaps in knee-joint amputation in cases of gangrene of the toes and foot due to an atheromatous condition of the arteries of the limb. This result is obtained by two incisions, viz.: First, a perpendicular incision on the anterior aspect of the knee, by which only the terminal part of the arteries of the soft tissues of the joint is divided; and, second, a circular incision below the origins of the articular arteries, to

avoid dividing their trunks. The several steps of the operation are as follows :

“ Compress the artery at the groin with the four fingers on a soft pad to avoid breaking the brittle structure; then make a straight incision commencing two inches above the upper border of the patella, downward over the center of that bone to the lower border of the tuberosity of the tibia; from the lower extremity of this incision make two incisions, an external and an internal one, both curved downward, one to the external and the other to the internal border of the limb; now join these two incisions by a straight incision across the posterior surface of the leg. Dissect these flaps from the bone upward to the joint, then disarticulate and finish by removing the patella.

“ *The precautions* to be taken are to make the lateral incisions with a sufficiently large curve to insure the covering of the long internal condyle of the femur and to include as much as possible of the recurrent tibial artery. The hæmorrhage is so slight, owing to the division of only the extremities of the arteries, that ligatures are rarely required except for the popliteal artery and the proximal end of the recurrent tibial artery.”

The Amputation by the Elliptical-incision Method (Baudens).—In this method an elliptical incision is made around the upper portion of the leg at an angle of 30° with its long axis. The anterior and lower end of the ellipse is located on the tibia at a point below the apex of the patella equal to the antero-posterior diameter of the limb, and the upper and posterior extremity of the ellipse is placed at half this distance below the level of the apex of the patella. The integument is reflected up on a line with the apex of the patella, leg flexed, ligamentum patellæ divided, the blade passed between the head of the tibia and the semilunar cartilages, the soft parts at the back of the joint are cut across, and the limb is removed.

The Amputation by the Circular-flap Method.—Extend the leg and make a circular incision around it, about four inches below the patella, through



FIG. 621.—Amputation by circular method.

the integument and subcutaneous tissues. Dissect up the flap to a line corresponding to the apex of the patella; flex the leg and divide the ligamentum patellæ at the apex of the bone; open the joint in front, and divide the lateral ligaments close to the tibia so that the semilunar car-

ligaments will remain connected with the femur. Flex the leg and cut the crucial ligaments. Pass a long knife between the bones, extend the leg,

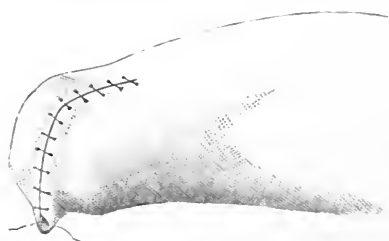

FIG. 622.—Antero-posterior coaptation.

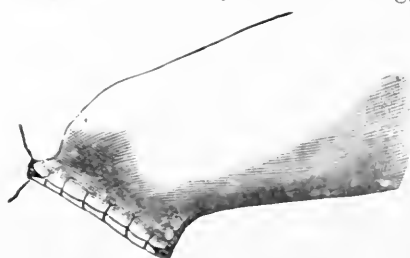


FIG. 623.—Transverse coaptation.

and sever the posterior connections as before (Fig. 621). The flaps can be united from before backward (Fig. 622), or transversely (Fig. 623), the former being the better method, for obvious reasons. If difficulty be experienced in dissecting up the flap, a slit of accommodation may be made at the side (Fig. 621).

The Amputation by the Long Anterior- and Short Posterior-flap Method (Pollock).—Flex the leg and make a long semicircular-shaped flap, beginning a little below the center of the inner surface of the internal condyle, extending downward to five inches below the patella, then around in front and upward to a point on the external condyle similar to that of starting (Fig. 624). Dissect the flap upward to the patella, open the joint as before; divide the lateral and

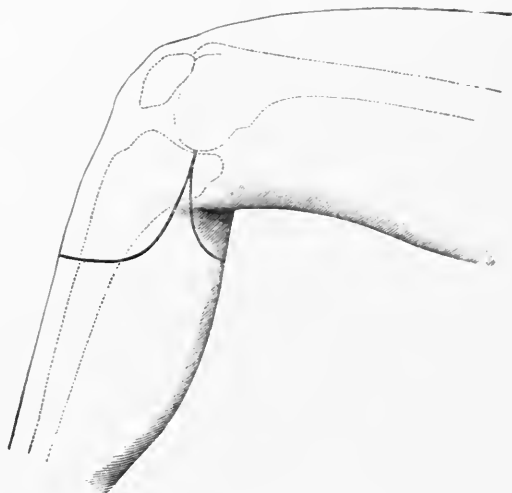


FIG. 624.—Outlines of flaps.

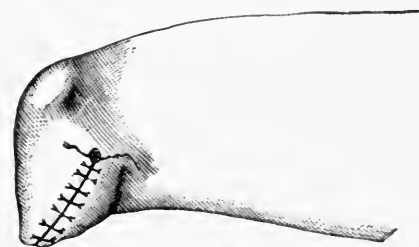

FIG. 625.—Appearance of stump.

crucial ligaments; draw the head of the tibia forward and pass a long knife behind it, making a short posterior flap from above downward, beginning the incision at the upper limits of the anterior flap. When united the cicatrix is well protected and good drainage afforded (Fig. 625).

The Results.—A careful examination shows the fact that of 690 cases

of disarticulation at the knee joint for all causes, 421 were done before a sepsis, with a mortality of 32.8 per cent, and 269 under a sepsis, 14.6 per cent

died. Amputation through the knee joint offers, as a rule, a better chance for life than through the upper third of the leg. The long anterior flap covers the condyles less suitably, and is prone to slough. The long posterior flap has nothing to commend it when either of the preceding methods is available.

Amputation of the Thigh through the Condyles.—Amputation through the condyles offers no mechanical advantage over that made through the articulation. The rate of mortality is, according to some authorities, somewhat greater in the former, being reported at about forty-eight per cent, although this would, without doubt, be much lessened by the employment of rigid antiseptic measures. The usefulness of the stump is decidedly in favor of the latter method. However, as conditions sometimes arise rendering the disarticulation or excision impracticable, amputation through the condyles becomes a valuable expedient.

The Amputation by Carden's Method.—Extend the leg, seize the joint with the left hand, the ends of the thumb and index finger resting as nearly as possible over the centers of the condyles. With a stout scalpel make an anterior semilunar flap, commencing at the point indicated by the end of the index finger, and passing around in front about two inches below the patella to the tip of the thumb on the opposite side. If the question of amputation or excision be undecided, reflect the anterior flap first; then, if the condition of the parts requires amputation, connect the extremities of the anterior flap by a short posterior incision carried directly down to the bone (Fig. 626). Reflect both flaps upward to the base of the condyles; flex the leg to draw down the patella, and divide the remaining tissues surrounding the condyles down to the bone; then saw off the condyles at the base, secure the vessels as before described, and unite the divided parts. The lower epiphysis joins the shaft of the femur at about twenty years of age, therefore in young subjects the saw line should be made as far as possible below the line of epiphyseal junction, which is marked by the adductor tubercle on the inner condyle.

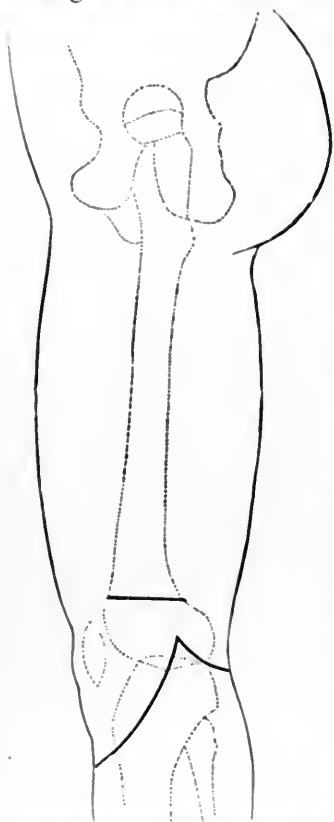

FIG. 626.—Outlines of Carden's method.

The Results.—The rate of mortality as reported by Carden was about seventeen per cent by old methods.

Lister and Farabeuf have each modified Carden's method. *Lister* made an anterior flap by a transverse incision between the tuberosities of the tibia on a line with the tubercle of that bone, and a posterior flap at an angle

of 45° with the long axis of the leg, which included the integument and fat. He elevated the limb, dissected up the posterior flap, divided the hamstring tendons as soon as exposed, raised the remaining flap tissue in the usual manner to a point that exposed the upper border of the patella when the leg was flexed, divided the quadriceps tendon, exposed the anterior surface of the femur immediately above the cartilage, and sawing the bone transversely at that point, removed the limb.

Farabeuf's modification differs from Lister's only in the construction of the outlines of the flaps. The anterior flap exceeds in length by an inch the antero-posterior diameter of the limb at the point of bone section. The length of the posterior flap equals about half the diameter of the limb at that point. The base of each flap corresponds to the line of the articulation, that of the anterior flap being limited internally by a point two inches behind the inner edge of the head of the tibia, externally by the fibula, thus exceeding in width more than half the circumference of the limb.

The Amputation by Gritti's Method.—Gritti's method (Fig. 627, *a*) of procedure is *osteoplastic*, and although it bristles with surgical ingenuity, still, the results of the method do not sufficiently emphasize its practical utility to establish for it a fixed place in amputations in this situation. The special technique of the method requires that the patella be bisected in a plane passing vertically through its transverse diameter, and that the attached portion of the bone be fixed to the sawed end of the femur by silver-wire or kangaroo-tendon sutures. A lion-jaw forceps to hold, a fine keyhole saw to divide, and a slender bone drill to pierce the patella, are the special implements required for the operation.

An anterior rectangular incision is made reaching downward from the centers of the condyles of the femur to the tubercle of the tibia; the integument on the posterior surface is divided by an incision directed transversely or slightly downward, and connecting the upper extremities of the rectangular one; the ligamentum patellæ is severed at the insertion, the flap containing it dissected up, the synovial membrane removed from its attachment to the femur in front, the bone sawed just above the articular cartilages, and the remaining soft parts are divided with a long knife carried directly through them. The articular surface of the patella is then sawed off, and the remaining part placed in contact with the lower end of the femur, to which it is confined by silver-wire or kangaroo-tendon sutures.

The Fallacies.—The sawing of the patella is always difficult, and is often attended with injury of the soft parts unless great care be exercised. The rongeur can be substituted for the saw with good results. Owing to contraction of the quadriceps muscle it may be difficult to place the fragment of the patella in proper position, and also to retain it there. If a tendency to displacement from this cause be apparent, the division of the quadriceps tendon at the base of the patella or the removal of an additional section of bone should be practiced.

Stokes's modification of Gritti's method consists in making an anterior oval instead of a rectangular flap, the posterior flap being made one third the length of the anterior. The femur is sawed off an inch above the condyles

(Fig. 627, *b*) instead of through their base. The cartilaginous surface of the patella is scraped off, and the bone itself is then united to the extremity of the femur by strong catgut or kangaroo tendons passed through the soft tissues attached to the patella and those immediately behind the thigh bone.

Stokes's modification (Fig. 627, *b*) disturbs the soft parts but little, and permits the divided surfaces of the bones to lie easily in contact. The practical results of this modification are superior to those of the original method.

The Results.—Of 130 cases of amputation by Gritti's operation and Stokes's modification done under asepsis, 16 cases, or 12.3 per cent, died.

Osteoplastic flaps, when applied to the ends of divided bones, appear in many instances to serve important purposes. However, if greater care were taken in the making of the ordinary simple flaps, there would be less occasion to prompt the making of the complex ones. The osteoplastic variety, like the periosteal, exercises an influence in closing and protecting the medullary canal, in increasing the stability of the end of the bone, and correspondingly the usefulness of the stump, by aiding nutrition and providing for it a freely movable integumentary covering.

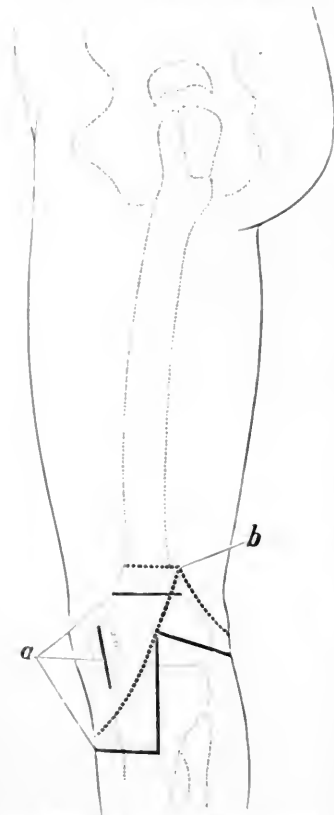


FIG. 627.—*a*. Gritti's amputation.
b. Stokes's incisions.

this proposition at the upper third of the leg in the following manner: Outline an antero-internal cutaneous flap whose base equals half of the circumference of the leg, and whose length equals its diameter. Dissect upward the flap thus formed; incise transversely at the apex of the flap, the periosteum on the subcutaneous surface of the tibia, and also longitudinally upward from this part along the borders of the tibia to a sufficient length to form the flap (Fig. 628). The flap should be shorter for the tibia than for both bones; remove from the anterior surface of the tibia by means of a Gigli-Haertel saw a bone flap, leaving attached the superimposed periosteum; fracture the bone flap at the base and turn it upward, the periosteum forming a hinge (Fig. 629); unite posteriorly by a semicircular incision the upper ends of the primary flap; amputate the limb in the usual manner, finally bringing down and applying to the end of one or both bones, as the case may be, the periosteal flap (Fig. 630), which is then fastened to the divided end or ends by chromicized catgut; bring down into place the upper flap and close the wound in the usual manner, dress-

ing the stump quite firmly to hasten union of the complex flap, with overlying simple flap. Bier, in order to increase the supporting power at the lower end of the leg, removed a wedge-shaped piece (Fig. 631) from just

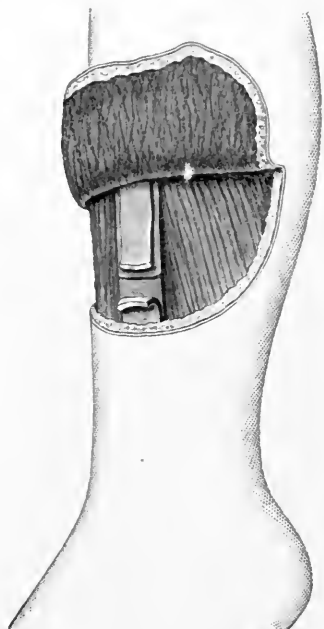


FIG. 628.—Osteoplastic flap. Method of Bier and Eiselsberg.

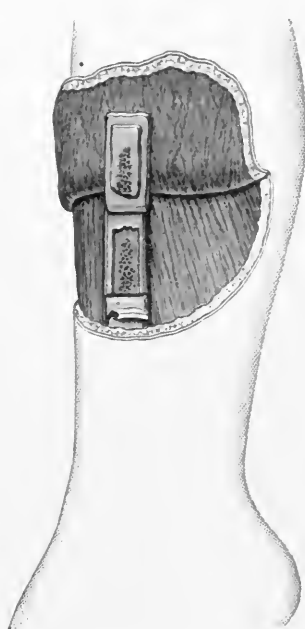


FIG. 629.—Osteoplastic flap turned up. Method of Bier and Eiselsberg.

above the end of the bone, turned the lower fragment upward and united it in position, thus closing the medullary opening, and changing the relations of the scar to the end of the stump. In this connection we are disposed to say: that if greater care were taken in making simple amputations

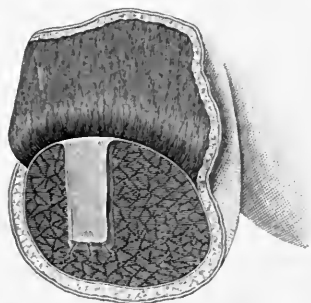


FIG. 630.—Osteoplastic flap turned down. Method of Bier and Eiselsberg.

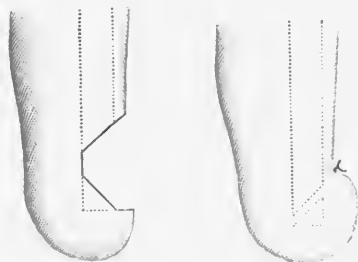


FIG. 631.—Amputation of leg. Bier's method.

at this point, little if any need would arise for the above modifications. In the hands of the author the amputation described on page 517 *et seq.* has secured excellent results.

Sabanejeff's Method.—Make a longitudinal incision at either side of the leg from the head of the fibula and from the internal lateral ligament respectively downward to near the junction of the middle and upper thirds of the limb; connect these incisions in front by a transverse one located two fingers' breadths below the tubercle of the tibia and behind by a similar incision made somewhat higher; reflect a posterior skin flap up to the knee and tibio-fibular joints; open these joints from behind and sever the crucial and lateral ligaments; turn the leg forward against the anterior surface of the thigh; saw off the lower end of the femur (Fig. 632, *a*), and so form a bone flap from the upper and anterior aspect of the tibia as to include the insertion of the ligamentum patellæ, and place this flap in contact with the sawed surface of the femur, where it should remain without restraint (Fig. 632, *b*).

Amputation of the Thigh.—The muscles surrounding the thigh are of large size, and many of them of great length. Those on the posterior and internal, and one on the anterior surface, extend from the pelvis to the leg.

The Special Considerations.—The greater the length of a muscle from its origin to the point of division the more marked will be its retraction, other things being equal. It therefore happens in amputation of the thigh, unless care be exercised in division of the muscles, that the bone protrudes or presses too strongly against the flap, giving it an undue conicity, or otherwise distorting the stump. The position in which the limb rests during the healing process also has an influence on the muscular retraction. For instance, if the limb be extended during the division of the muscles, the posterior and internal ones, on account of their greater length and tension, retract the most, and if to this be added the additional retraction due to placing the stump in a semiflexed position on a pillow, or to swinging during healing, the tendency to cause tender, painful, and otherwise troublesome stumps is increased. To avoid this sequel, the limb should be held as nearly as possible at the same angle with the body, when the muscles are being divided, as that at which it will be placed when the dressing is completed and during the process of recovery. However, at the middle and upper thirds the bone is quite near the center of the muscular mass, and the muscles contract proportionately less here than at the lower third.

In order to obviate the occurrence of the danger of undue shortening of the muscles after division and during treatment, it will not be amiss in the instances of low amputations of the thigh to divide the tendons of the hamstring muscles at once through the primary incision, limited to the lower border of the flap. This act will promptly permit of free contraction, and thereafter these same muscles can be again divided higher up with the others if they are not already found to be of a suitable length. It should not be overlooked at first that apparently too long flaps often prove (especially here)

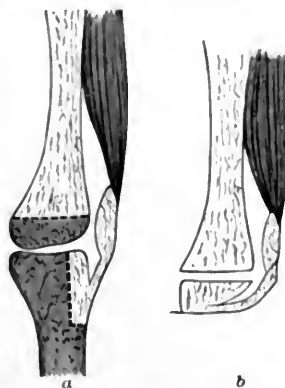


FIG. 632.—Sabanejeff's amputation.

to have been the proper length. When, during the course of repair, apprehensions arise regarding the fitness of the final outcome in instances of suspected short flaps, much may be gained by applying to the stump traction by means of adhesive plaster, pulley and weight. Such treatment of receding coverings may save the surgeon the annoyance and chagrin of having to remove the advancing end of the bone in order to receive a satisfactory result. Greater care and vigilance are requisite in securing serviceable weight-bearing stumps than those not required to meet such exacting demands, and the greater the weight required the greater is the duty imposed upon all concerned. However, if the periosteum and deep muscular tissues be sewed firmly over the end of the bone at the outset (Figs. 461, 462, 463) and are held firmly in position until repair has taken place, little doubt need be entertained that a suitable stump will result.

The following are common methods practiced in amputation of the thigh: *The equilateral-flap method; the bilateral-flap method; the antero-posterior musculo-integumentary-flap method; the circular integumentary-flap method; the high circular-incision method; the long anterior-flap method; the long anterior- and posterior-flap method.*

The Amputation by the Equilateral-flap Method (Vermale).—The flaps in this method, made by transfixion, are musculo-cutaneous and U-shaped, and the length of each is equal to the diameter of the limb at the point of amputation. Great care should be taken that the transfixion does not impale the femoral vessels; if the inner flap be made the broader this danger will be obviated. In this method of operation the surgeon grasps the soft parts at one side of the thigh with the thumb and fingers, draws them vigorously away from the bone, then passes the blade of a long catlin from above downward close to the bone, and cuts the flap downward and outward from the bone of the indicated length; the second flap is made at the opposite side in a similar manner (Fig. 633, *b*). Both flaps are then drawn forcibly upward, and the bone is exposed an inch above the point of transfixion and divided with the saw. The flaps are united, drained, and the wound is dressed as before. If amputation be performed close to the band of a tourniquet or the elastic bandage of Esmarch, the muscles will be held too firmly to permit natural retraction until after the bone is sawed and they are liberated; this is a fault which must be recognized and corrected by cutting the muscles lower than would otherwise be done.

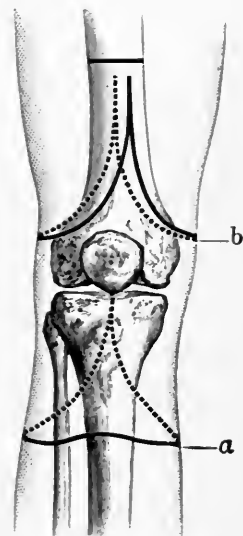


FIG. 633.—*b*. Equilateral-flap method. *a*. Bilateral-flap method.

The Amputation by the Bilateral-flap Method (Fig. 617, *a*, *c*).—The bilateral-flap method is admirably adapted to amputation at the middle and lower thirds of the thigh.

The flaps are integumentary and their outlines are formed the same as in amputation of the leg by this method. They are dissected up from the

muscles three inches, or about half their length. The muscles are then divided by a single or repeated circular sweeps of the knife, and the bone is exposed and, after the formation of a periosteal flap, sawed off three inches higher up. *In circular division of the muscles*, in connection with any kind of flap, it is advisable that the first sweep of the knife should divide only the superficial layer, which will then retract, or can be drawn upward when the second layer is severed at a higher point, thus causing the open stump to present a conical-shaped cavity, the sawed bone corresponding to the apex (Figs. 634 and 635).

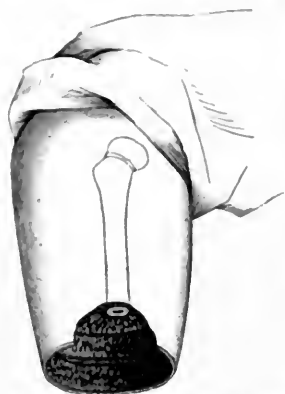

FIG. 634.—Conical-shaped cavity from repeated circular incisions of muscles in circular-flap amputation.

The Amputation by the Antero-posterior Musculo-integumentary-flap Method (Figs. 480 and 481).—These flaps include all of the tissues down to the bone, and are usually made by transfixion, although the anterior one may be made by cutting from without and the posterior by transfixion at the upper limit of the former. The length of each should be about one third the circumference of the limb. When both flaps are made by transfixion the tissues should be raised somewhat by the left hand of the operator, who then enters the point of the knife at the side nearest himself and pushes it through in close contact with the anterior surface of the bone, depressing the handle a little as the point reaches the bone and raising it a little after the point has passed, thus causing the knife to emerge on the inner side of the limb exactly opposite its point of entrance (Fig. 636, *b*).

The flap is then formed by cutting obliquely upward and forward with a sawing motion the proper distance, and when completed the flap is pulled backward by an assistant assigned for that purpose. The knife is reinserted at the original point of entrance and carried behind the bone, the point elevated so as to emerge at the same situation as before, and the posterior flap is made by cutting obliquely upward and backward. The remaining muscular fibers are cut by a circular sweep of the knife, retractors applied, and the bone is divided at a point a little below the level of the point of transfixion. The end is then seized by strong forceps, the soft parts on its posterior surface and sides are pushed up, and with a small, sharp-pointed knife an oval- or rectangular-shaped flap of periosteum is marked out and pushed upward from the anterior surface of the bone, together with the soft parts resting upon it (Fig. 638). The base of the periosteal flap should correspond to the point of secondary



FIG. 635.—Amputated portion with terraced surface.

division of the bone, which will be about two inches above the primary section. The bone is sawed again and removed. The portion of the flap having the periosteum is allowed to fall into its proper position across the end of the divided femur, the edges are united, and the stump is dressed as desired. In flaps of this structure the skin retracts more than the muscles, causing the lower ends of the latter to be exposed. To avoid this exposure, *Agnew* recommends that the flaps be formed first from the integument, reflected up an inch and a half, and that the muscles be divided by transfixion, the point of the knife being pushed through at the junction of the reflected integumentary flaps.

The amputation by the circular integumentary-flap method can be employed at the thigh, with admirable results; but owing to the greater contraction of the muscles at the posterior and inner aspect of the thigh, the incision should be made obliquely, the anterior and outer limit of the flap being located about two and a half inches nearer the line of proposed bone division than is the posterior and inner limit (Fig. 636, *a*).

First carefully mark the outline of the flap, then with a long knife or a large scalpel fashion the flap in the course of the line, going down to the muscles; free the integument equally for a short distance all around, retract it, and divide the superficial muscles at the inner and posterior aspects of the limb promptly; retract these, then with a circular sweep of the long knife sever the remaining muscles parallel with the integumentary incision, at the highest point practicable; expose the bone, adjust the retractor, and use the saw as before. The angular projection of the *linea aspera* is removed with a rongeur or bone forceps. This amputation is best employed at the lower third of the thigh. However, when practiced at either of the other thirds, the obliquity of the incision is lessened, it being the least oblique at the upper third.

Syme's modification of this method is easier of performance than the original, and consists in making two equal, short, antero-posterior flaps of integument by means of short, lateral incisions at either aspect of the thigh, carried upward from a circular incision of the integumentary tissues of the

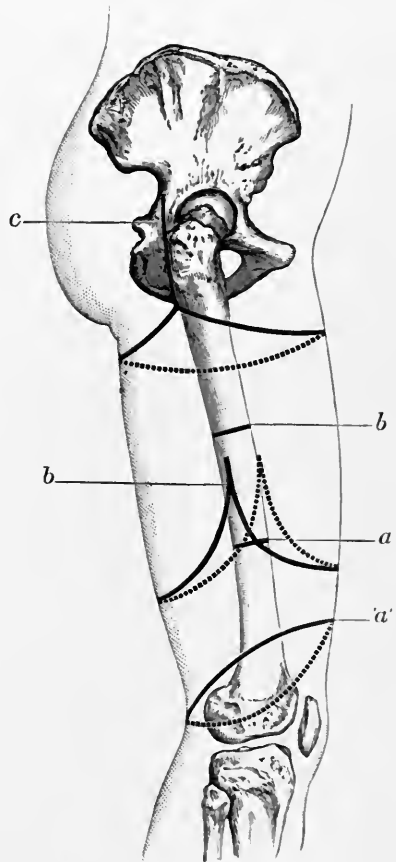


FIG. 636.—*a'*. Circular amputation. *a*. Saw line. *b*. Antero-posterior method. *b'*. Saw line. *c*. External racket method, disarticulation.

limb. The flaps, and two inches additional of integument above them, are dissected up, and the exposed muscles are divided in front at the highest and behind at the lowest point of exposure, down to the bone. The retractor is adjusted, and the bone sawed about two inches above the line of division of the anterior muscles.

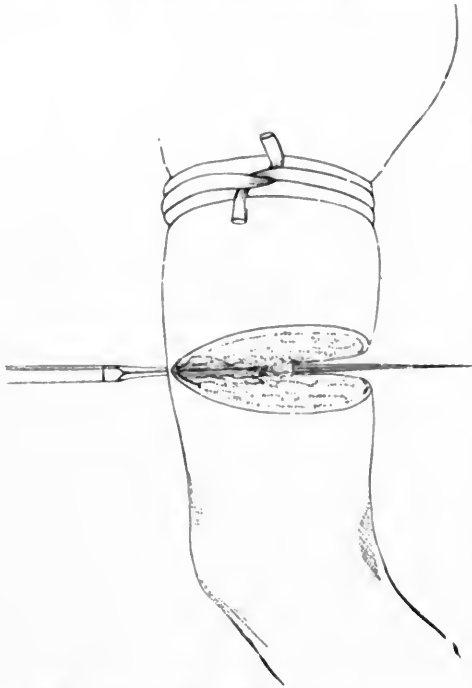


FIG. 637.—Celsus's single circular incision.

*The Amputation by the Single Circular-incision Method (Celsus).—*With a long knife divide all the soft parts by a circular sweep down to the bone (Fig. 637), which is then sawed off.

The end of the divided bone is now seized by strong forceps, and the surrounding soft parts are drawn upward, when, if desirable, a periosteal flap can be made, its base corresponding to the site of secondary section of the bone (Fig. 638). Saw the bone a second time close to the periosteal flap, and allow the parts to fall into position. The amount of bone to be removed

at the second division is estimated the same as is the length of the flap in other amputations. The divided borders can be united transversely (Fig. 639) or the reverse; the former union holds the periosteal flap in position the better.

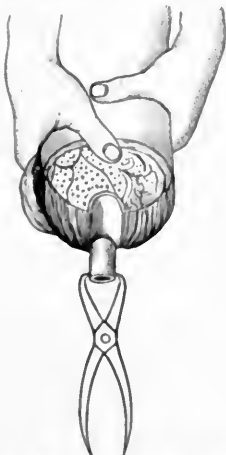


FIG. 638.—Periosteal flap.

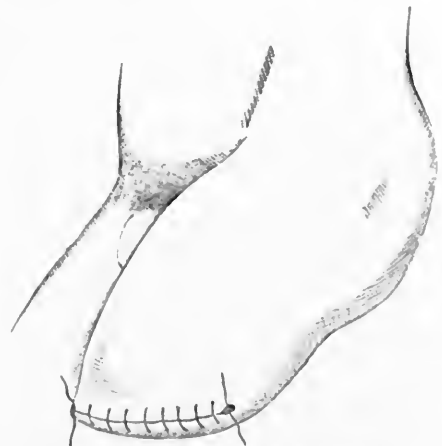


FIG. 639.—Appearance of stump.

The Remarks.—This method is of interest on account of its antiquity, and also from the fact that in a thigh clothed with scantily developed and flexible muscles it forms a serviceable stump with a minimum area of exposed surface of the soft parts. But if the muscles be indurated this method ought not to be attempted. If the periosteum be pushed up all around and remain attached to the surrounding soft parts, the injury to the muscles is still further lessened.

The Amputation by the Long Anterior-flap Method (Sédillot).—The long anterior-flap method can be employed at any portion of the thigh. Mark out on the anterior surface of the limb a flap, the length of which is equal to the diameter of the limb and its base to half of the circumference at the saw line. Divide the tissues obliquely, upward and backward, not making the flap too thick. The tissues on the posterior portion of the limb are divided transversely down to the bone, which is then exposed about two inches higher and sawed off. If the length of the anterior flap be increased by about a quarter of the diameter of the limb, the usefulness of the stump will be improved.

The Amputation by the Long Anterior- and Short Posterior-flap Method (Farabeuf) (Fig. 640, a).—This method is well adapted to amputation at the middle of the thigh. The flaps are U-shaped, the anterior having a base a little broader than half the circumference of the limb and a length equal to one and a half diameters of the limb at the point of amputation. The posterior flap equals in length one half the diameter of the limb. The integumentary structure of both flaps is first divided with a large scalpel. Then the tissues of the anterior flap are pinched up with the thumb and fingers and divided obliquely downward and upward to the bone with a long knife. The muscles of the posterior flap can be divided from without, as in the preceding flap, or by transfixion and oblique downward division. The flaps are then retracted, and the bone is exposed and sawed as usual.

The General Remarks.—In amputation at the thigh the periosteal portion of the flaps should be formed to correspond as nearly as practicable with the outlines of the major parts of the flaps, so that when the borders of the former are united together (Fig. 643) the end of the bone will be suitably covered.

The suturing over the end of the bone of a recent stump, by chromicized catgut, of a periosteal flap (Figs. 641, 643), along with its immediate mus-

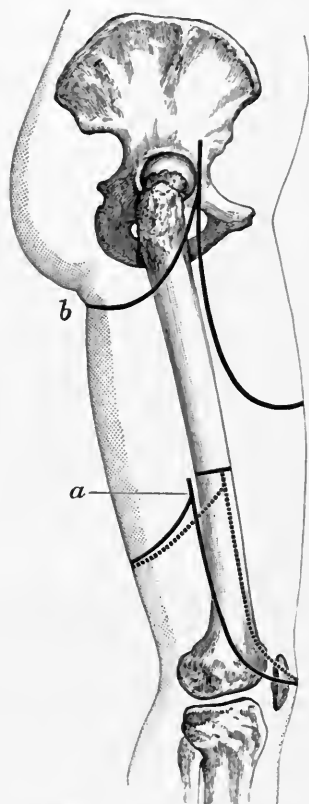


FIG. 640.—*a* Long anterior- and short posterior-flap method. *b*. Antero-posterior flap (disarticulation).

cular tissue connections (Fig. 641), exercise an important preservative influence on the nutrition of the end of the bone, and in obviating abnormal deviations of growth (bony spines), and also in limiting undue retraction of the deep soft tissues at that situation. When this measure is supplemented by buried suture apposition of the overhanging muscular flaps (Fig. 642), especially in the instances of thigh and arm amputation, great benefit follows, because muscular retraction of the entire stump is inhibited, thereby promoting prompter and better union and the making of a better stump. In the absence of these measures, undue muscular retraction encouraged by a fixed position of the stump (especially of the thigh) leads much too frequently to an unserviceable caused by a tender protruding bone.

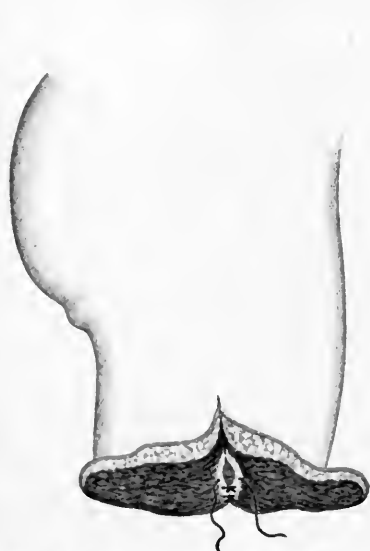


FIG. 641.—Amputation of thigh. Periosteum sewed over end of bone.

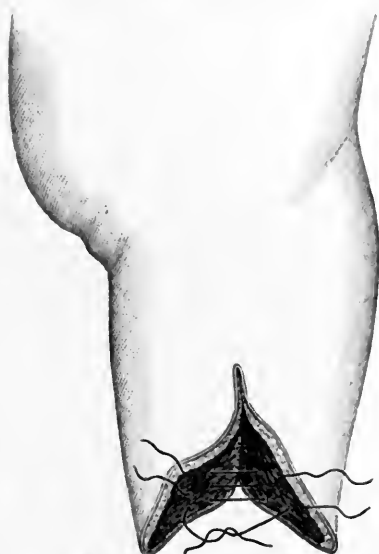


FIG. 642.—Amputation of thigh. Periosteal flap covered in and muscles united deeply with sutures.

The divided ends of the deep and of the superficial layers of muscular tissue may be joined together respectively, thus opposing retraction and thereby lessening dead spaces and covering more effectively the end of the bone (Fig. 644). The unheeded effect on the stump of the unusual length of the muscles of the thigh and of their strong retractile tendencies frequently beget conical stumps and distorted scars, especially at the lower half of the limb.

Although the antero-posterior musculo-cutaneous-flap method is the best all-round plan of practice, still the circular, when performed with due consideration of the necessity of dividing the muscles according to their degree of retraction, hence in an elliptical manner (Fig. 636, *a*), provides an excellent stump. It should not be forgotten that the transfixion methods sever muscles of unequal lengths and different degrees of contractility, therefore, unevenness of the flap is a natural consequence.

The After-treatment.—Not a little of the success in amputation of the thigh depends on the after-treatment of the stump. It should be carefully surrounded with antiseptic gauze bound in place with sufficient firmness to support the soft parts, eliminate dead spaces, and equalize the circulation of the stump. The dressing should be carried around the pelvis, to prevent displacement and needless exposure of surfaces contiguous to the wound

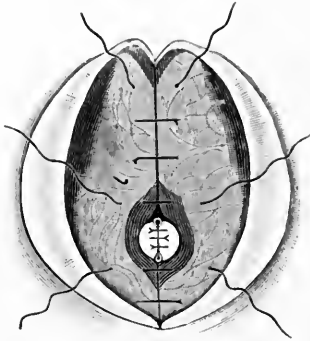


FIG. 643.—Periosteum covering end of bone. Ends of deep muscles approximated with sutures.

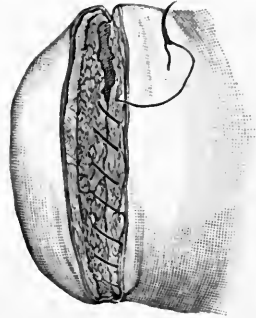


FIG. 644.—Ends of superficial muscular structures approximated.

(Fig. 645). The stump should be slightly raised, and placed on a firm pillow to which it is loosely attached. Drainage should be provided at the most dependent portion by a small rubber tube extending only into the wound cavity, or by wisps of horsehair or catgut. If lateral flaps have been made they should be carefully supported or their weight will cause undue tension at their upper junction. In fact, the sutures should be

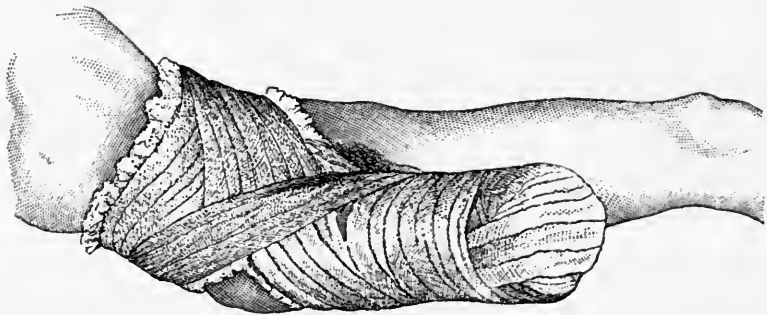


FIG. 645.—Stump dressed with antiseptic gauze.

permitted to remain longer here than elsewhere in the line of coaptation, for the reason that there is greater danger of traction at this point. If the patient be restless or delirious and move the stump frequently the danger of conicity is thus increased. In such cases it is our practice to apply continuous extension to the soft parts of the stump by means of a rubber band fastened to them at one end with adhesive straps and the other passed over

the distal end of a perineal crutch, thus keeping up continuous extension even if the stump be moved by the patient.

The Results.—The rate of mortality in amputation at the lower third of the thigh for gunshot injuries is fifty-five per cent, at the middle third sixty-five per cent, and at the upper third seventy-eight per cent. About thirteen per cent more recover with expectant treatment, in gunshot injuries, than after amputation. The rate of mortality after primary amputations is twenty-one per cent greater than after secondary. The results are much more favorable when done in private practice, or with antiseptic precautions irrespective of the cause.

Later Results.—Of 7,360 amputations of the thigh for all causes, 6,245 were done during the pre-aseptic period with a mortality of 43.66 per cent, and 1,115 under asepsis, of which 21.0 per cent terminated fatally.

Amputation through the trochanters is safer than disarticulation at the hip-joint and may be practiced instead of the latter in instances of injury, and of tumors of the femur when the bone is not involved at the seat of amputation, and when good judgment favors the former.

Amputation at the Hip (*Disarticulation*).—The causes of death from this amputation are loss of blood, shock, and septicæmia. Various plans to limit the loss of blood have been suggested, such as compression of the abdominal aorta by the fingers of an assistant with the hand introduced into the rectum, combined with digital pressure upon the femoral as it crosses the pubis. In all instances when abdominal



FIG. 646.—Pancoast's tourniquet.

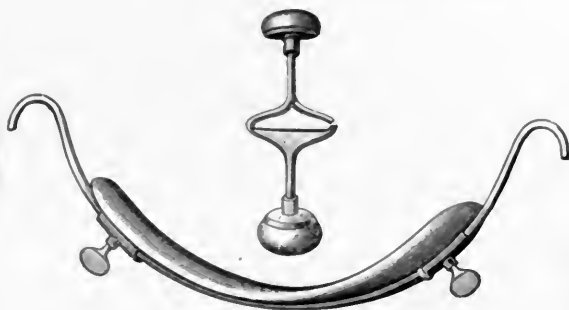

FIG. 647.—Esmarch's tourniquet.

pressure is to be applied the intestines should have been previously evacuated. The application of the pressure to the part of the median line of the abdomen at which the pulsation of the vessel is the best determined should be considered, although not necessarily adopted. In patients with unusual adipose development the measure is of no use, and its employment may be positively harmful. For another purpose in patients with unusually sensitive abdominal tissues the pressure is illy borne and may be positively unendurable without anæsthesia. Various forms of tourniquets have been designed

for the purpose, as Pancoast's (Fig. 646), Esmarch's (Fig. 647), and Lister's (Fig. 648). Fig. 649 shows Esmarch's elastic tourniquet in position.

If a tourniquet be not at hand, a pad may be substituted made by winding a linen bandage about three inches wide and twenty-five feet in length

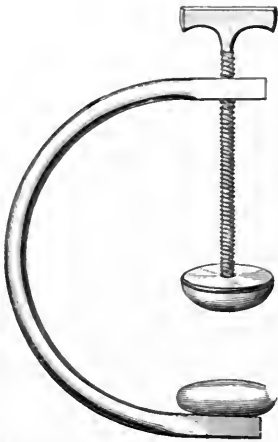


FIG. 648.—Lister's tourniquet.

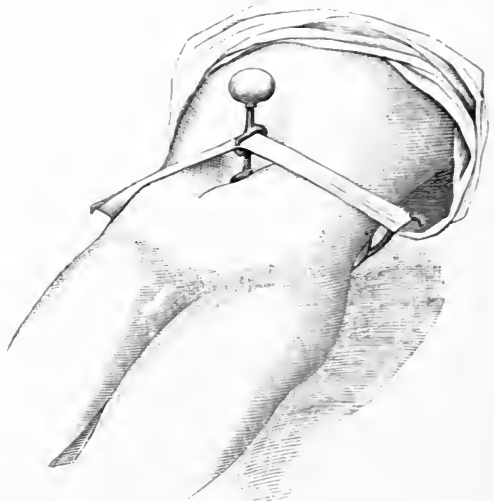


FIG. 649.—Esmarch's tourniquet applied.

around a stout rod or stick one inch or so in diameter and twelve inches long, which is placed immediately below the umbilicus and held in position by an assistant.

It can be held in position, and the pressure still further increased, by several turns of a rubber bandage carried over it and around the body (Fig. 650).

If the elastic traction around the body be objectionable, a longer stick

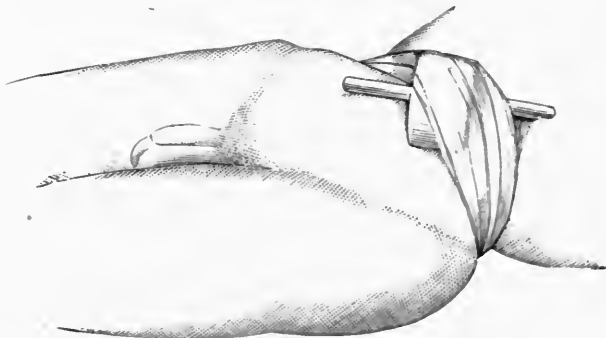


FIG. 650.—Compressed pad and elastic band.

can be substituted, and the compress secured in position by rubber bands carried over the ends of the stick and under the table (Fig. 651).

Davy's lever (Fig. 91) is a useful agent to control hæmorrhage at this situation. The lever is open to the objection of being easily disturbed by

the struggles of the patient, and the danger of injuring the intestines, especially when carried to the right side of the body.

Trendelenburg's rod (Fig. 92) has been mentioned, and is of unquestionable utility. It is a steel rod fifteen or sixteen inches long, about one fourth of an inch broad, biconvex on transverse section, and a twelfth of an inch thick at the center, with blunt edges, but provided with a movable, lance-shaped point two inches in length. The rod is passed through the soft parts in front of the joint, entering an inch and a half below the anterior superior spinous process of the ilium, passing across the femur behind the femoral artery, and emerging at the posterior scroto-femoral junction. The point is removed, and a strong elastic tube or band is wound firmly, like the figure 8, around its ends, passing in front of the thigh. A long knife is then inserted in the course of the rod about half an inch below it, and the anterior flap made in the usual manner and the vessels ligated. The rod is then withdrawn, the hip joint disarticulated, and the posterior flap is made. The late Dr. Varick, of Jersey City, N. J., who first employed

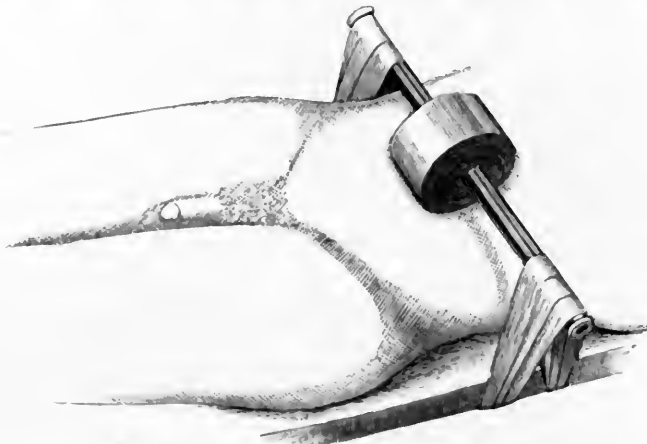


FIG. 651.—Brandis's method of compression.

the rod in this country, did not disarticulate until he had transfixed a second time behind the neck of the femur, including as much of the soft parts on the posterior surface as possible; compression with the rod was then applied as before, and the tissues were divided by a posterior semicircular incision down to the bone. The amount of blood lost was trifling, and the patient made a speedy recovery. The rod can be employed in the various forms of flaps, but it has not as yet been enough used to be esteemed more than a rational expedient.

Wyeth's modification of the application of the principles of the Trendelenburg method is a decided improvement on the original. Wyeth employs two instead of one fixation agent, and constricts the entire limb above these agents, instead of a portion of the limb against the single agent.

The following is a description of this modification as applied to the hip joint: If the condition of the limb will permit, draw the hip well over the edge of the table, and apply an Esmarch bandage to the entire extremity and

up as closely to the perineum as practicable. The point of a steel mattress needle, three sixteenths of an inch in diameter at the base and one foot long, is inserted one fourth of an inch below and slightly to the inner side of the anterior superior spinous process of the ilium, and carried superficially through the tissues at the outer side of the hip, emerging on a level with the point of entrance. A second needle is then inserted internally through the adductor longus half an inch below the perineum, emerging an inch below the tuber ischii of the same side. After covering the needle points with corks, a long piece of half-inch rubber tubing is passed while on the stretch five or six times tightly around the thigh above the needles and fastened with a clamp or by tying, after which the Esmarch bandage is removed. A circular musculo-cutaneous flap is then made, beginning five

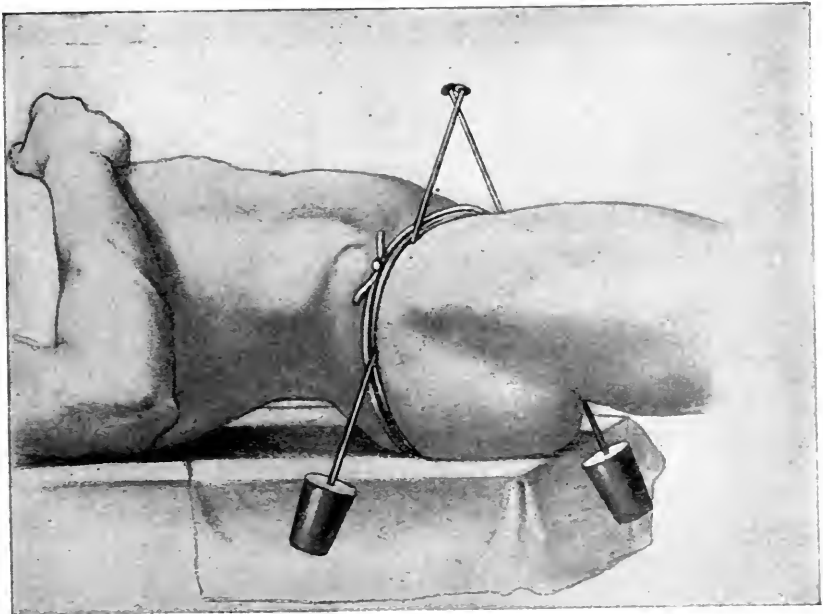


FIG. 652.—Hip-joint amputation. Pins and rubber-tube tourniquet in position. The Esmarch bandage has been removed.

inches below the rubber cord and extending up to the trochanter minor; if necessary to proper action, this flap can be incised behind and also in front in the long axis of the limb (Fig. 652).

The muscles are then divided at the upper limit of the flap by a circular sweep of a long knife. The bone is sawed through at this or at a lower point (Fig. 653); if at the latter, better fulcrumage is gained in aid of a subsequent step of the operation—dislocation of the head of the bone (Fig. 654). The visible ends of all divided vessels are secured, and the rubber cord is loosened carefully and slowly and finally removed, the bleeding points being caught as soon as they appear. The remaining portion of the femur is freed from its muscular attachments; the capsule and cotyloid ligament are divided posteriorly by the sharp point of the knife, and

the lower extremity of the bone is carried forcibly upward and inward until luxation occurs; the round ligament and the capsule are divided and the

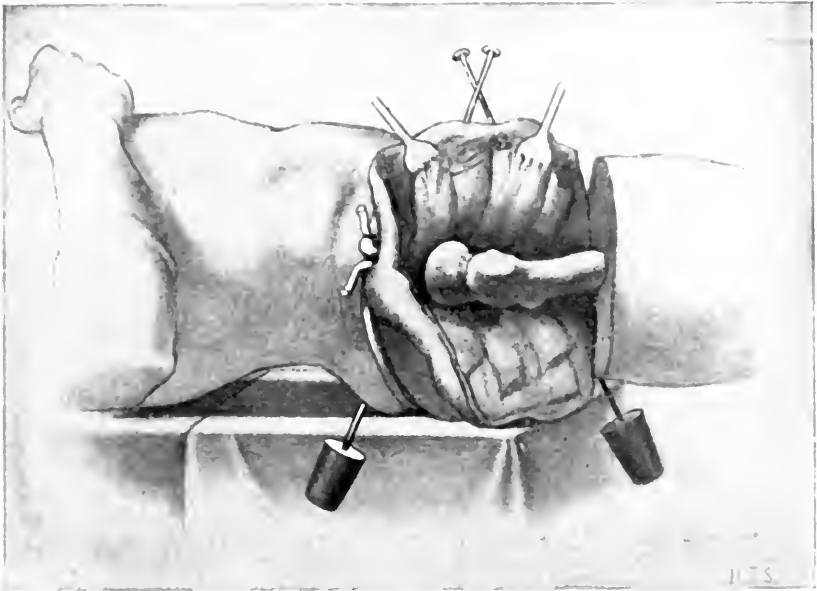

FIG. 653.—The same, showing the soft parts dissected from the bone and the capsule exposed.

bone is removed. The flaps are united antero-posteriorly and the wound drained (Fig. 655).

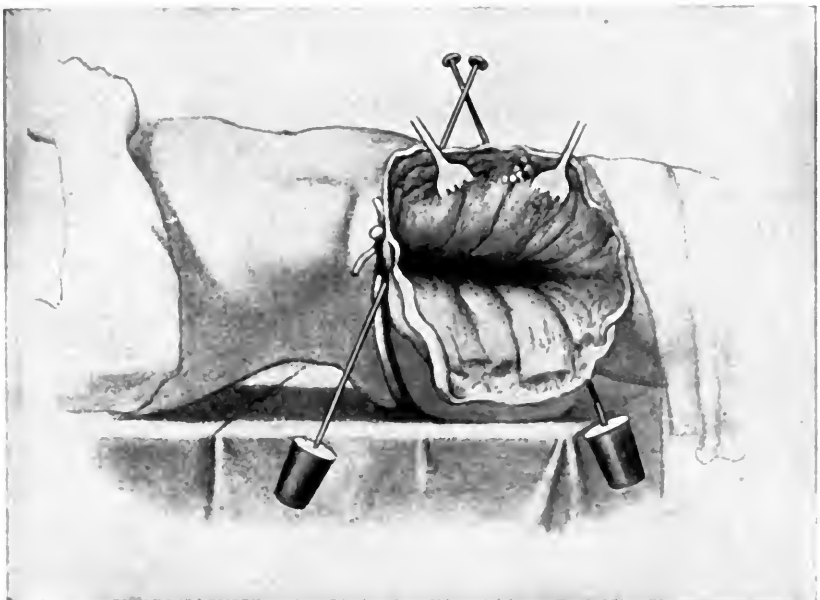


FIG. 654.—The same, with the disarticulation complete. Constrictor still in position.

An admirable method of controlling hæmorrhage in amputation at the hip joint has recently been described (Lloyd) :

“A strip of black india-rubber bandage two yards long is to be doubled and passed between the thighs, its center lying between the tuber ischium of the side to be operated on and the anus. A common calico thigh roller must next be laid lengthwise over the external iliac artery. The ends of the rubber are now to be firmly and steadily drawn in a direction upward and outward, one in front and one behind, to a point above the center of the iliac crest of the same side. They must be pulled tightly enough to check pulsation in the femoral artery. The front part of the band, passing across the compress, occludes the external iliac artery, and runs parallel to and a little above Poupart’s ligament. The back half of the band runs across the

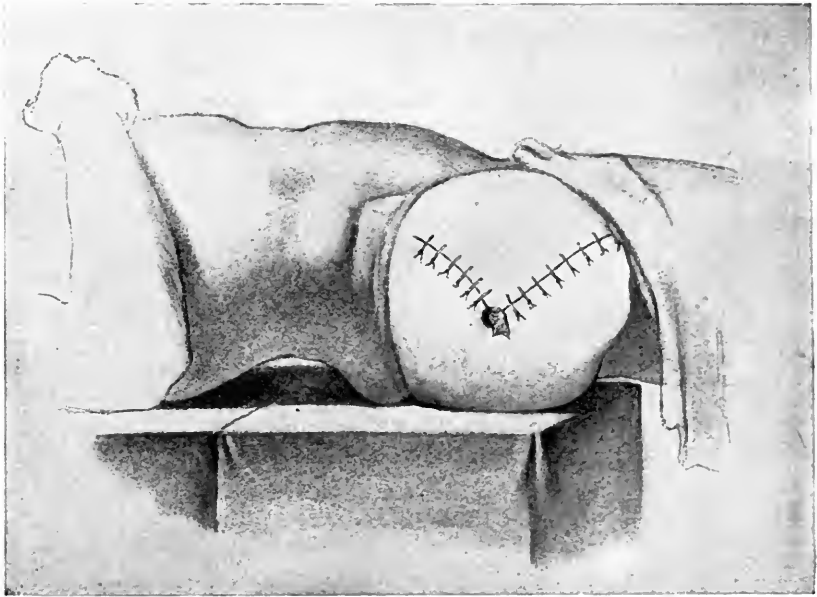


FIG. 655.—The operation completed.

great sacro-sciatic notch, and, by compressing the vessels, prevents bleeding from the branches of the internal iliac artery which pass through it. The ends of the elastic band can be held by the hands of an assistant, or bandages may be tied to its extremities and passed across the opposite shoulder and tied; care should be taken to prevent the compression rollers from slipping. This device has been employed on several occasions with entire satisfaction.”

McBurney has advised and practiced a most valuable suggestion, especially for those cases in which disease of the upper end of the thigh interferes with the circular constriction method. The finger of an assistant is introduced into the abdomen through the “gridiron” incision for appendicitis (Vol. II), carried over the psoas muscle, placed on the common iliac artery, flexed and drawn outward so as to press the artery against the inner border of the muscle, thus easily and effectually controlling the hæmorrhage. Of

course, strict asepsis must be practiced, or an element of great danger will be added to the operation.

Tilden Brown devised a clamp to control the circulation of the femoral during amputation.

The plans of *Wyeth* and *McBurney* appear to the writer to meet the demands of the operation better than any yet devised.

Shock is certain to happen in amputation of the thigh, and the occurrence should be anticipated in order that it may be treated successfully. Not only should the patient be prepared for the occurrence of shock, but also the surgeon should have at command the recognized agents of relief (page 121 *et seq.*). The body should be warmly enveloped with flannel at the outset, and, too, bottles of hot water may be applied at the time of the operation.

The Results.—Of 267 cases done by this method for all causes, 53, or 19.8 per cent, died; 137 were for malignant disease, 14.10 per cent died; 94 for infection, mortality 16.7 per cent, and 36 for injury, of which 63.9 per cent died. (*Wyeth.*)

Senn's bloodless amputation at the hip-joint: Make (according to *Senn*)

“A straight incision (beginning about three inches above the upper border of the great trochanter) of about eight inches in length directly

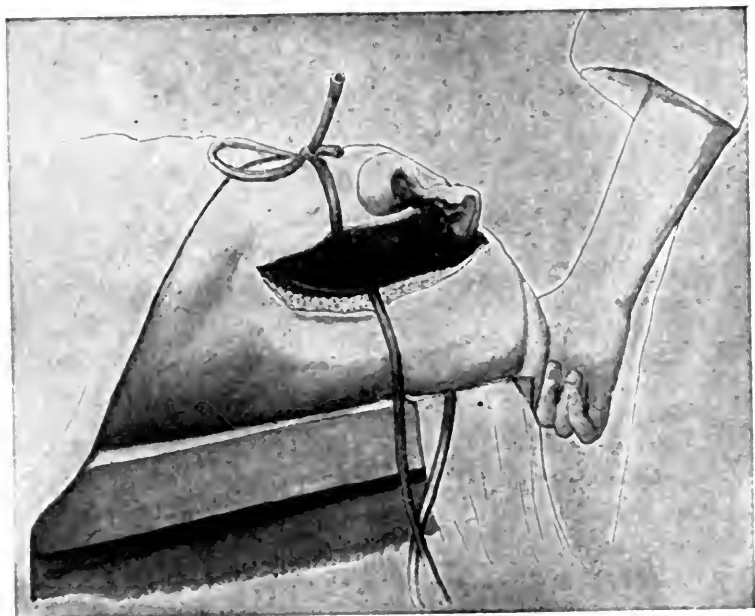


FIG. 656.—*Senn's bloodless amputation at the hip-joint.* Head of femur dislocated through incision. Elastic constrictors in place, anterior one tied.

over the center of the great trochanter and parallel to the long axis of the limb. When the knife reaches the great trochanter, its point should be kept in contact with the bone the whole length of the remaining part of the incision. The margins of the wound are now retracted, and any spurting

vessels, such as the circumflex arteries, secured by applying pressure forceps. During this and the remaining steps of the operation the body is drawn down so that the pelvis rests upon the lower edge of the table, in order that the thigh can be manipulated freely by the assistant who is entrusted with this work (Fig. 656). The trochanteric muscular attachments are now severed close to the bone with a stout scalpel. The clearing of the digital fossa and the division of the tendon of the obturator externus require special care. The thigh is now flexed, strongly adducted,

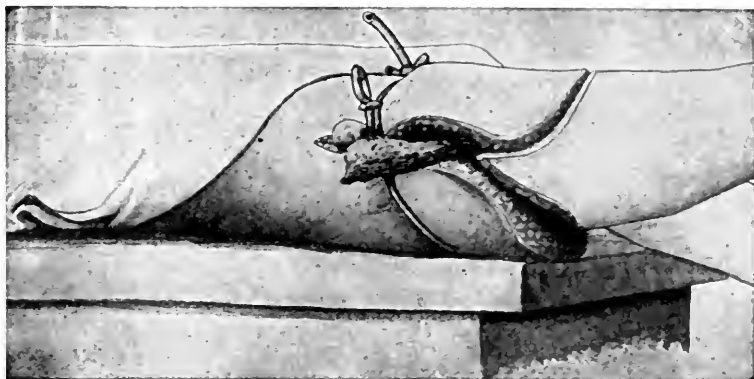


Fig. 657.—Senn's bloodless amputation at the hip-joint. Elastic constriction completed. Antero-posterior flaps formed of all tissues down to muscles.

rotated inward, when the capsular ligament is divided transversely at its upper and posterior aspect. The remaining portion of the capsular ligament is severed, while the thigh is brought back to a position of slight flexion, after which it is rotated outward, and, if possible, the ligamentum teres is cut. If this can not be done, the head of the bone is forcibly dislocated upon the dorsum of the ilium by flexion, adduction, and rotation inward of the thigh. After dislocation has been effected, the trochanter minor and the upper part of the shaft of the femur are cleared by using scalpel and periosteal elevator alternately. At the completion of this part of the operation the femur is in a position of extreme adduction, and the upper portion projects some distance from the surface of the wound.

During the operation, if the surgeon has kept in close contact with the bone, and has used the knife sparingly and the periosteal elevator freely, the hæmorrhage has been slight, much more so than if this part of the operation had been reserved for the last, as is done in von Esmarch's and Wyeth's methods. Elastic constriction is now applied in the following manner: The limb is brought down in a straight line with the body, the thigh is slightly flexed so as to push the upper free end of the femur forward into and beyond the wound, when a long, stout hæmostatic forceps is inserted into the wound behind the femur and on a level with the trochanter minor when in a normal position. The instrument is then pushed inward and downward two inches below the ramus of the ischium and just behind the adductor muscles. As soon as the point can be felt under the

skin in this location, an incision is made through the skin, about two inches in length, through which the instrument is made to emerge. After enlarging the tunnel made in the soft tissues by dilating the branches of the forceps, a piece of aseptic rubber tubing three quarters of an inch in diameter and about three or four feet in length is grasped with the forceps in the middle and is drawn along the tunnel as the forceps are withdrawn, whereupon the rubber tube is cut in two at the point where it was held by the forceps. With one half of the tube the anterior segment of the thigh is constricted sufficiently firmly to intercept both the arterial and venous circulations completely. Before the constrictor is tied the limb should be held in the vertical position for a sufficient length of time to render it practically bloodless. The elastic constrictor is either tied, or, still better, after having secured the necessary degree of constriction, it is held with a pair of forceps at the point of crossing. The posterior segment of the thigh is constricted by the remaining half of the tube, which is drawn sufficiently tight behind, when the ends of the tube are made to cross each other and are brought forward and made to include the anterior segment, when they are again firmly drawn and tied, or otherwise fastened, above the



FIG. 658.—Senn's bloodless amputation at the hip-joint. Amputation completed. Vessels handy for ligature.

first constrictor (Fig. 657). As the anterior segment of the thigh contains the principal blood-vessels, this method of applying the posterior constrictor furnishes an additional security against hæmorrhage from the large vessels when cut during the amputation (Fig. 658). After the principal blood-vessels have been tied, the posterior constrictor is removed and additional bleeding points are secured before the anterior constrictor is removed. Sur-

face compression with a compress wrung out of a hot normal salt solution is a valuable aid in minimizing the hæmorrhage after the removal of the constrictors. As this method of controlling hæmorrhage does not require the presence of a skilled assistant, it will prove of special value in emergency cases (Fig. 659). The operation can be performed with the instruments

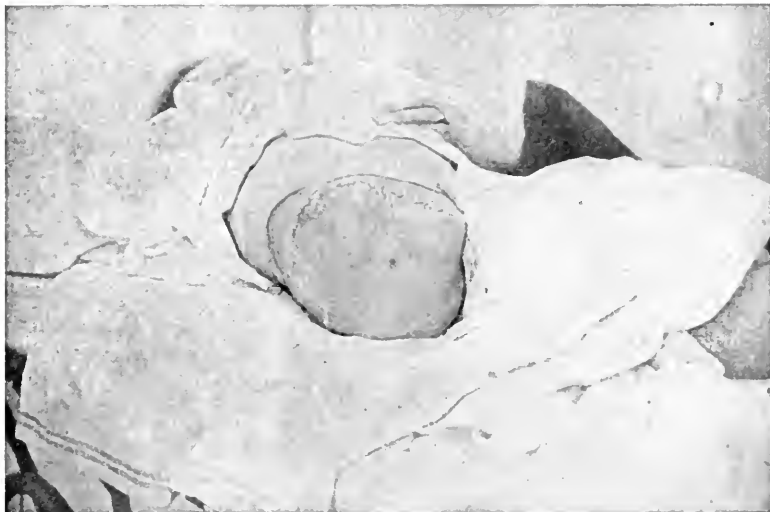

FIG. 659.—Senn's bloodless amputation at the hip-joint. Stump from a long posterior cutaneous flap.

contained in every pocket case. Should an elastic tube not be at hand, the constriction can be made in a satisfactory manner by substituting for it a cord made of sterile gauze, tightened with a lever of some kind, as is done in applying the ordinary Spanish windlass."

Amputation at the hip-joint may be done by any of the following methods: *By the external-racket method; by the anterior-racket method; by the long anterior- and short posterior-flap method (Mance); by the circular-flap method (Dieffenbach); by the Furneaux-Jordan method; by the antero-posterior-flap method (Guthrie); and by the single-flap method (Malgaigne's).*

The Amputation by the External-racket Method (Disarticulation).—After complete control of the circulation is attained, adduct, flex somewhat, and rotate the thigh inward; make an incision from a point two inches above the end of the great trochanter downward along the posterior border of the same, seven inches in length (Fig. 636, c); connect internally the lower end of this incision with crescent-shaped incisions of equal length at either surface of the limb which join each other at a lower point than that of the beginning. These incisions are made through the integument and subcutaneous tissue only. The flap embracing the limb is dissected up for two inches; the vertical incision deepened to the bone; the muscular attachments to the great trochanter are severed; the portion of the femur corresponding to the vertical incision is cleared; then adduct the limb strongly

and divide the capsule at the upper and posterior part; sever the remaining portion of the capsule; dislocate the head of the bone; divide the round ligament; free the upper part of the femur and cut the muscles at the remaining aspects of the limb on a level with the reflected flap with a vigorous sweep of the knife.

Lister made the vertical incision eight inches in length, and divided the muscles by a circular sweep before exposure of the upper end of the bone, disarticulation being the final step of the procedure.

The external-racket incision and its modifications are admirably adapted for amputation here, as they reduce the loss of blood to a minimum, afford good drainage, locate the scar in an advantageous position, and remove the incision from the prejudicial influences of anal proximity.

Amputation by the Anterior-racket Method.—An incision of the skin and subcutaneous tissue is begun at the center of Poupart's ligament and carried downward along the course of the vessels for three inches, then inward over the inner aspect of the limb four inches below the genito-crural junction, thence over the posterior aspect to the outer surface of the limb, just below the great trochanter, then upward obliquely across the anterior surface of the thigh, meeting the primary incision two inches below

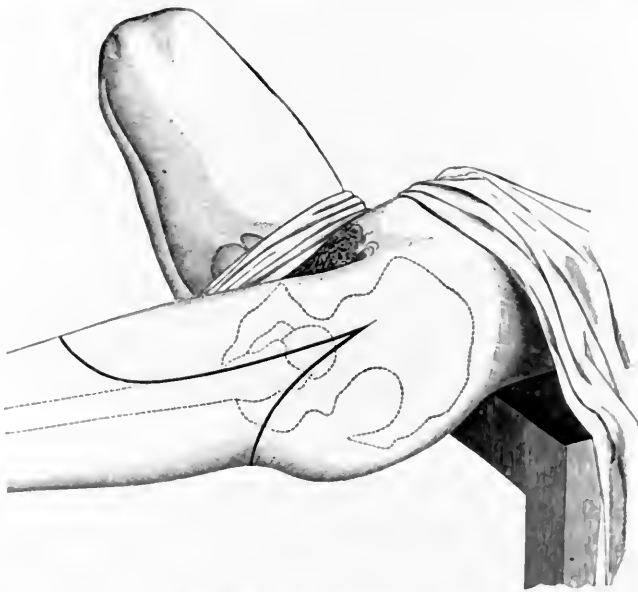


FIG. 660.—Manec's method.

the commencement. Expose the femoral sheath at the uppermost incision, bare the vessels, tie each one independently with two ligatures and sever the portions between them; liberate and retract the skin along the border of the entire flap; divide the superficial muscles at the outer aspect with a scalpel; divide the circumflex artery thus exposed between two ligatures; rotate the limb inward and divide the insertion of the gluteus

maximus, then outward, and sever the psoas; expose, secure, and divide the internal circumflex as in the preceding instance; employ retractors and cut the superficial muscles at the inner aspect of the limb on a level with the retracted skin; adduct and rotate the thigh inward and free the trochanter from muscular insertions; rotate it outward and cut the capsule transversely; steady the pelvis and bear down on the limb, thus dislocating the bone; divide the round ligament, draw the head of the bone forward and carry a knife behind it, and with a downward and outward sweep sever the remaining tissues on a level with the retracted skin, thereby removing the limb.

The anterior-racket incision offers prompt control of hæmorrhage and easy disarticulation, in addition to other common advantages. However, the technique of the procedure is not as simple as that of the external-racket method.

*Amputation by a Long Anterior- and Short Posterior-flap (Mance).—*Place the patient on the table so that half the pelvis, on the side to be operated upon, projects beyond the edge; draw the scrotum to the opposite side by a towel (Fig. 660). Exsanguinate the limb by the elastic bandage; after which control the hæmorrhage from above by the form of arterial compression selected, and remove the elastic bandage. The limb to be amputated is held by one assistant, and another is instructed to control the circulation in the femoral artery as it crosses the pubes, and to catch the anterior flap and compress it before it shall have been completely severed below.

The operator then introduces the point of a long knife midway between the anterior superior spinous process of the ilium and the trochanter major, pushing it down to the bone parallel with Poupart's ligament; draws it back a little and lowers the handle and carries it upward (Fig. 661), at which time the assistant flexes the thigh slightly; the operator then passes the point of the knife through the anterior portion of the capsular ligament; thence downward, inward, and out at the inner side of the thigh, an inch or so below the perineum, and as far posteriorly as can be easily done (Fig. 661). The knife is then carried downward, in contact with the bone, with long, sawing strokes, forming an anterior flap six to eight inches in length. The flap is caught by an assistant, who at the same time compresses the main vessel within it with the fingers and raises the flap upward. The knife is then carried posteriorly between the thighs (Fig. 662), thence outward in a curved direction, passing below the gluteal fold, and going down to the bone, thus forming the posterior flap. The bone is disarticulated by dividing the capsular

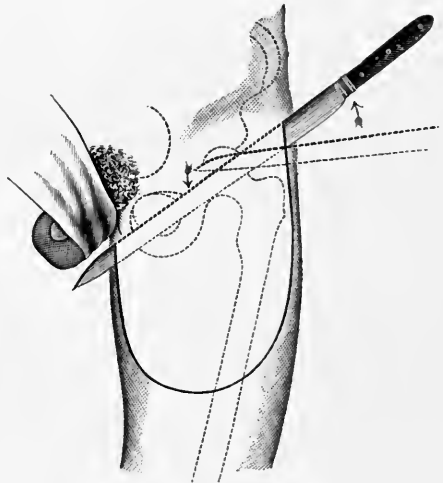


FIG. 661.—Transfixing.

ligament and the muscular attachments to the greater and lesser trochanters, and the limb removed.

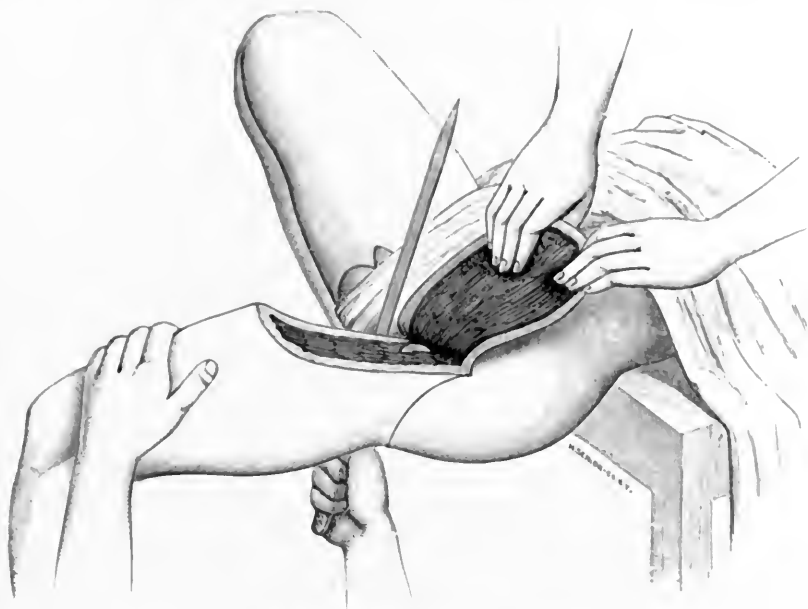

FIG. 662.—Making posterior flap.

Bring the flaps into position, unite them with sutures, and insert a long, large drainage tube into the acetabulum, allowing it to protrude at the centre of the line of union (Fig. 663).

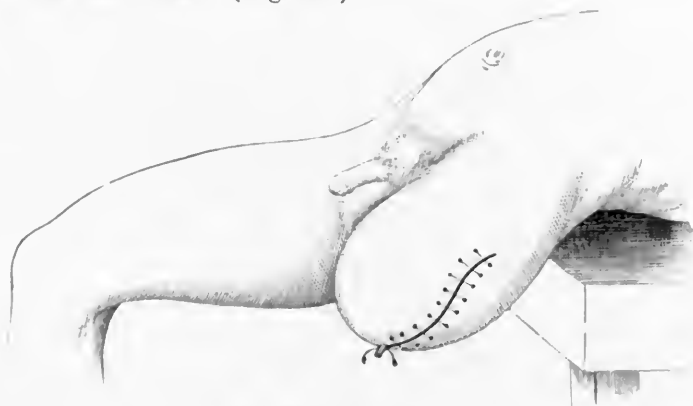


FIG. 663.—Flaps united.

Amputation by the Circular-flap Method (Dieffenbach).—Control the hæmorrhage as before, or by means of the elastic ligature (Fig. 664), and with a long knife make a circular incision down to the bone, which is then sawed through (Fig. 665). Tie all vessels, veins included. Remove the

elastic ligature, secure all bleeding points, and inserting a knife two inches above the great trochanter, at its outer side, carry it down to the bone, over the middle of the trochanter, as in Fig. 668, and along the outer surface of the femur to the circular incision. Then seize the bone with a

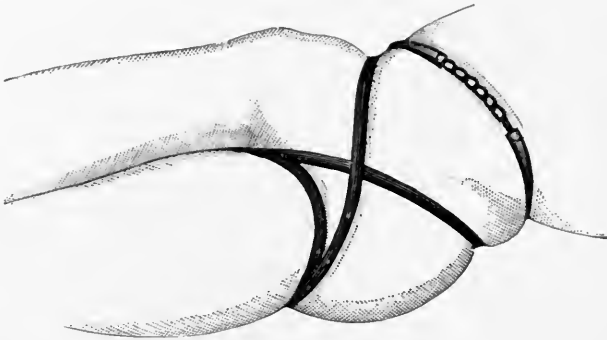


FIG. 664.—Elastic ligature.

strong forceps, separate the edges of the vertical incision, and remove the periosteum with a suitable instrument down to the points of muscular insertion. These must be separated with a knife, the edge directed toward the bone. Remove the periosteum in this manner up to the capsule (Fig.

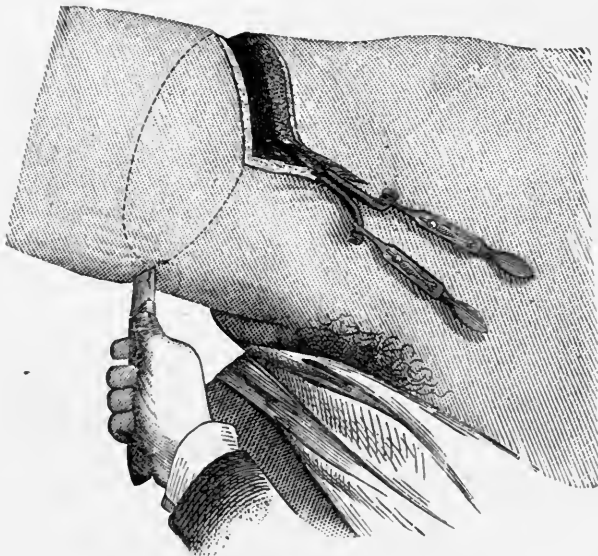


FIG. 665.—Dieffenbach's circular method.

666), which is opened and the head dislocated. The last step of the operation is attended with but slight loss of blood. Fig. 667 shows the appearance of the parts after their coaptation. An additional drainage tube is inserted at the lower extremity of the wound. If it be impossible to employ the bloodless method, the femoral vessels should be secured in two situations by

forceps or ligatures at the base of Scarpa's triangle, and divided between them (Fig. 665).

Dieffenbach's plan can be rapidly executed, and the lessened disturbance of the soft parts attendant on removal of the periosteum is a desideratum.

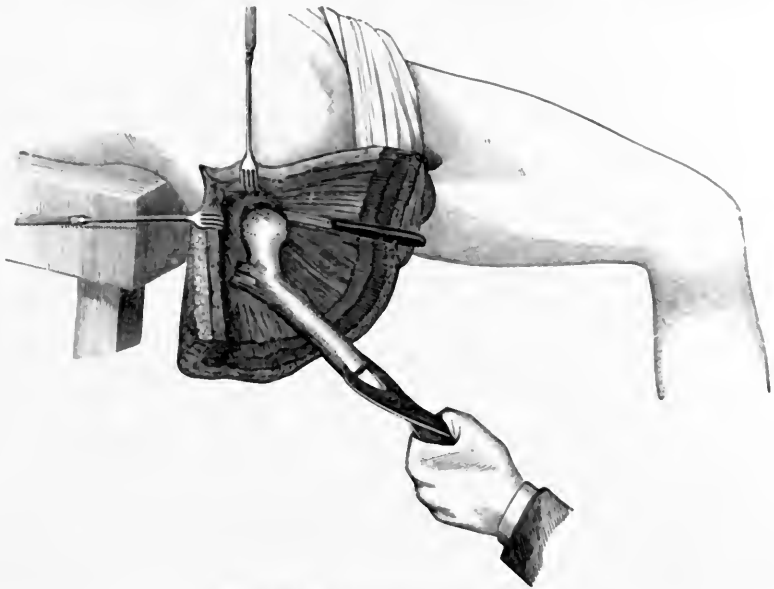


FIG. 666.—Removing the bone.

Amputation by the Furneaux Jordan Method.—This method contemplates low division of the soft parts, thus obviating the increased danger from shock attendant on high division of those structures, also the attainment of the purpose with a minimum loss of blood.

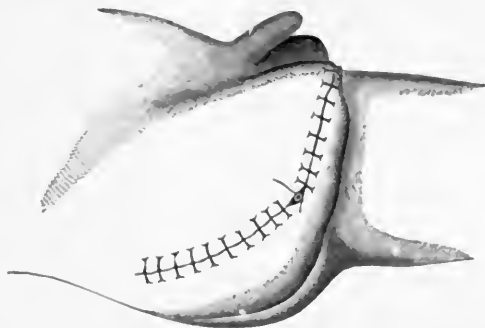


FIG. 667.—Wound closed.

The Operation.—Make a straight incision down to the bone from a point just above the trochanter major downward along the outer surface of the thigh to the point of proposed circular division of the soft parts (Fig. 668); free the trochanter and the upper part

of the shaft from the muscular attachments; open the capsule of the hip-joint and dislocate the head of the femur; separate the tissues from the bone down to the point of intended division and sever them there by a circular sweep of the knife. Saw off the bone, seize the end with forceps, complete its separation from the soft parts and remove it. The sawing of the bone

is a matter of convenience, since it lightens the burden by removal of the limb.

Amputation by the Antero-posterior-flap Method (Guthrie).—The posterior flap is laid out first, by an incision commenced at a point a little above the great trochanter and carried downward and inward in a curved

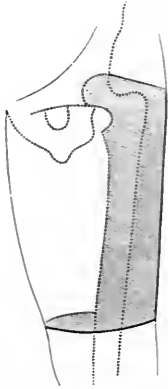


FIG. 668.—Vertical and circular incisions (Furneaux Jordan).

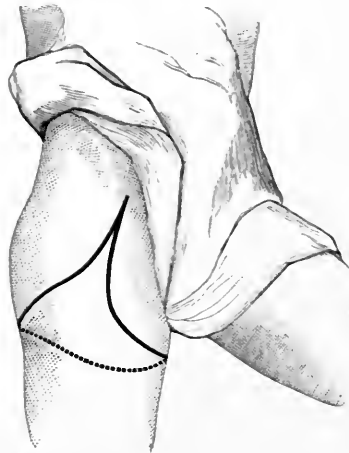


FIG. 669.—Antero-posterior flap (Guthrie).

direction across the posterior surface of the thigh, then upward and inward in a similar manner to a point in front of the tuber ischii (Fig. 669). The anterior flap is made at the anterior surface of the thigh by a corresponding incision beginning and terminating at the same points as the preceding. Each flap is made not less than five inches in length, and the first incisions are limited to the division of the integument and subcutaneous tissues. After retraction of these flaps the muscular structures are divided in the same order as the preceding ones, from below upward in an oblique manner until the joint is reached, after which disarticulation is effected in the usual way.

This method provides an excellent stump with a small and well-located cicatrix.

Amputation by the Single-flap Method (Malgaigne).—The method of Malgaigne admits of rapid execution, and, were it not for the available anæsthetic, would be the proper operation to select, in view of the additional shock caused by the more methodical and lengthy procedures advocated elsewhere.

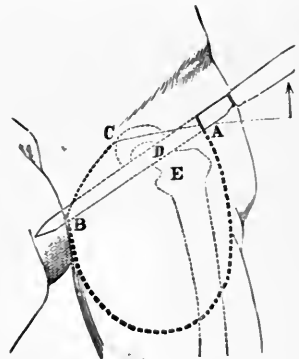


FIG. 670.—Malgaigne's method. A. Point of entrance of knife. B. Point of exit of knife. C. Poupart's ligament. D. Knife passing through capsule. E. Trochanter major.

Having controlled the circulation, place the patient on the table, with the hip overhanging the edge. The surgeon, standing at the outer side of the limb, which is slightly flexed and separated from its fellow, introduces

the point of a long knife midway between the anterior superior spinous process of the ilium and the top of the trochanter major (Fig. 661), directing it in the course of Poupart's ligament down to the bones, when it

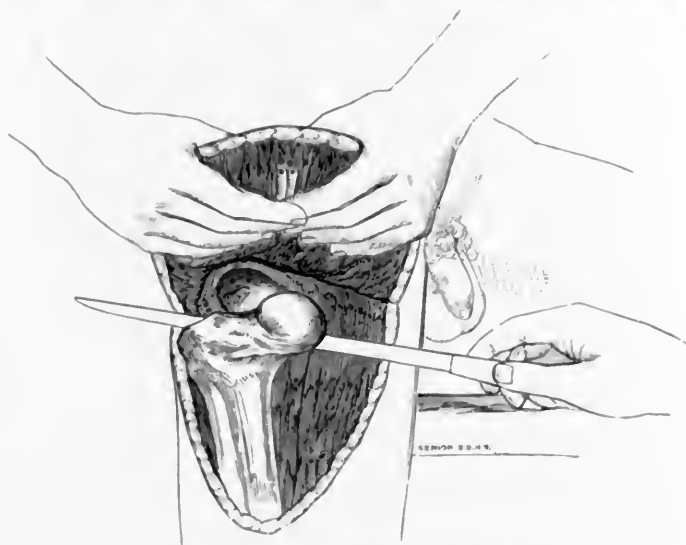


FIG. 671.—Assistant compressing vessels.

is carefully withdrawn a little way, and the handle is depressed sufficiently to permit the easy passage of the point of the knife across the neck of the femur and through the anterior portion of the capsule. If the handle be depressed before the point is withdrawn, the point may be broken. The

handle is then raised and the knife pushed onward until the point emerges an inch below and in front of the tuberosity of the ischium (Fig. 670).

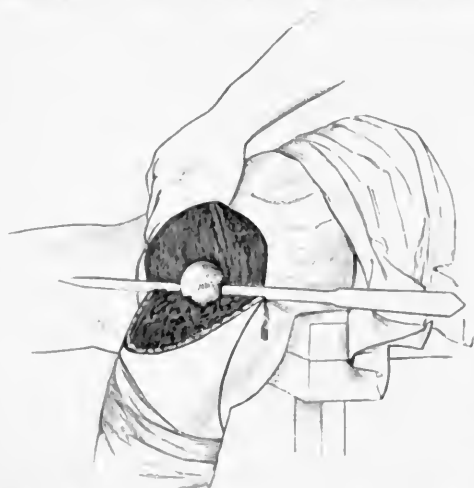

FIG. 672.—Passing blade behind head of bone.

The flap is then made by carrying the blade downward six to eight inches along the anterior surface of the bone, parallel with its line of entrance, when it is brought directly to the surface. Before the vessels are divided an assistant seizes the flap by inserting the fingers into either side of the incision above the knife, compresses the vessels, and, when these latter are

severed, carries the flap upward on to the abdomen (Fig. 671), while the surgeon at the same time divides the remaining anterior portion

of the capsule with the point of the knife; another assistant then rotates the thigh inward, and the attachments to the great trochanter are severed. The limb is then quickly and forcibly rotated outward and abducted, causing the head of the bone to escape sufficiently to expose the ligamentum teres, which is divided with the point of the knife, and, as the head of the femur slips from its cavity the blade is passed behind the bone (Figs. 670, 672), which is seized with the left hand of the operator, who quickly severs the posterior tissues by a downward and inward stroke of the knife.

The After-treatment.—The combating of shock, the maintenance of cleanliness and good drainage, the proper support of the flap during healing, and the prevention of bedsores, are the chief requirements of this treatment.

The Results.—The rate of mortality is governed by the nature of the cause calling for the operation. In immediate amputations in military practice, ninety-three per cent die. In civil practice, the mortality after the primary amputations reaches eighty per cent. Secondary amputations offer better results; sixty per cent recover in the civil and military combined.

The results are more favorable in non-traumatic cases, the mortality being less than forty-one per cent. Taking both traumatic and non-traumatic together, the rate is a little over sixty per cent, being a trifle more than for amputation in the continuity of the thigh, which is about sixty-three and a half per cent. But in civil practice, with antisepsis and the modern methods for the control of hæmorrhage, the death rate is only about sixteen per cent. The transfixion methods of practice are much inferior to the ratchet methods, and can not be commended except when, for some special reason, the latter are unsuited for the purpose.

The Later Results.—Of 754 cases of disarticulation at the hip-joint, for all causes, 646 were done before asepsis, with a mortality of 82.45 per cent; and 108 done under asepsis, of which 36.19 per cent died.

CHAPTER XI.

DEFORMITIES.

DEFORMITIES may be either congenital or acquired, and they affect, individually or conjointly, the soft or hard parts.

The acquired deformities usually depend on ankylosed joints, distorted shafts and extremities of bone, irregular or unequal muscular contraction, etc. To overcome the deformities dependent upon ankylosis, we resort to forcible movement, if it be fibrous; and the division of the bone and to excision or division of the joint structure, if it be bony.

The forcible movement of an ankylosed joint, while not an operation in the accepted sense of the term, is nevertheless often associated with consequent complications, which entitle it to a greater degree of prominence than that of many accepted operative procedures.

Brisement Forcé, as it is sometimes called, is a forcible breaking up of an ankylosed joint, and should be preceded by subcutaneous section of all the tendons, muscles, and fascia upon which "point pressure" causes reflex action (Sayre).

The incisions having healed, place the patient upon a hard table, administer an anæsthetic, and, while the portion of the limb between the ankylosed joint and the body of the patient is held firmly by assistants, the surgeon seizes the distal portion of the limb and flexes it by the employment of steady and persistent force. As soon as moderate movement follows flexion, the limb is then extended, and by repeated flexion and extension the range of motion of the joint is cautiously increased.

If the *knee-joint* be the one in question, the patella must be loosened before movement is attempted. After the manipulation, strap the toes and bandage the limb from the toes to the knee firmly, having first applied adhesive plaster to the leg for the purpose of extension. Pad the popliteal space with cotton, and surround the knee-joint with strips of adhesive plaster firmly and symmetrically applied. Continue the roller over the knee and up the thigh, applying pressure to the femoral artery by means of a small piece of moist sponge applied over its course and held in position by the ascending bandage (Sayre).

The Remarks.—If the ankylosis be bony, the deformity can be relieved by osteotomy above the condyles, and, if necessary, below the head of the tibia at the same time; by excision of the joint; or by the removal of a wedge-shaped piece of bone from the joint, as described in Fig. 459. The plan advised by Barton can be practiced (Fig. 673).

For severance of the ankylosis, boring the joint and other expedients have been resorted to. The safest of all, however, is supra-condyloid osteotomy (page 444). In all joints, ankylosis is amenable to one or more of these procedures.

In ankylosis of the knee-joint of long standing, attended with contraction of the heads of the gastrocnemius with or without subluxation of the head of the tibia, forcible extension of the leg frequently causes rupture of the attachments of the muscle to the condyles of the femur, often followed by a degree of hæmorrhage that suggests rupture of the popliteal vessels. If the tendo Achillis be divided, or the foot be forcibly extended before extension of the leg is attempted, the resisting influence of the gastrocnemius will be reduced to a minimum. At all events, the foot must not be *flexed* during the manipulation for reasons that should be obvious.

During the act of correction the opposing bands of tissue are severed subcutaneously as their resisting tension brings them to notice. And it should not be forgotten that the contiguous tense nerve trunks and vessels, especially the popliteal in rectification of the knee, may be mistaken for the simpler structures and divided. If the ankylosis be of long standing, and especially if associated with subluxation, proper rectification of the deformity may be impracticable or unsafe, and even impossible. Impracticable, because of the pain, numbness, and loss of power following undue stretching of the nerve trunks; unsafe, on account of the danger of rupture of important vessels, and impossible, for the reason of the pronounced relative changes of the hard and soft structures of the joint. Therefore a proper consideration for the safety of the patient and the security of the limb may promptly demand the substitution of operation for manipulative rectification.

Deformities caused by distortion of the long bones can be best corrected by osteotomy (page 443 *et seq.*).

The After-treatment.—Place the patient in bed, employ extension of the limb with the foot of the bed elevated; apply ice-bags to the knee and keep the limb immovably confined. At the end of five or six days the dressings are removed, and, after slight motion is made, replaced, the sponge being omitted.

The Results.—Loss of life and of limb from rupture of vessels, from severe inflammatory reaction, and from fat embolism may follow incautious or too vigorous attempts at rectification, especially of large joints. If marked chronic arthritic changes be present in the joint, correction with complete ankylosis or perhaps limited motion is all that need be expected from even repeated attempts at cure. The attainment of perfect motion need not be expected, and often complete relapse follows more or less promptly the best-directed efforts for relief.

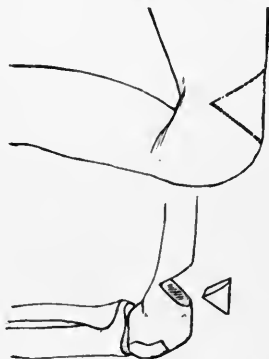


FIG. 673.—Barton's operation.

Curvature of the Spine.—“A common method of treatment at the present time is the application of the plaster-of-Paris dressing. The body of the patient is surrounded first by a closely fitting knitted jacket, between which and the region of the stomach is introduced a wedge-shaped ‘dinner pad,’ with the point downward, composed of a folded towel, or several thicknesses of cloth, or cotton wadding surrounded by cloth. All sensitive parts and projecting points should be relieved from direct pressure by spongio-piline, cotton, felt, or other similar

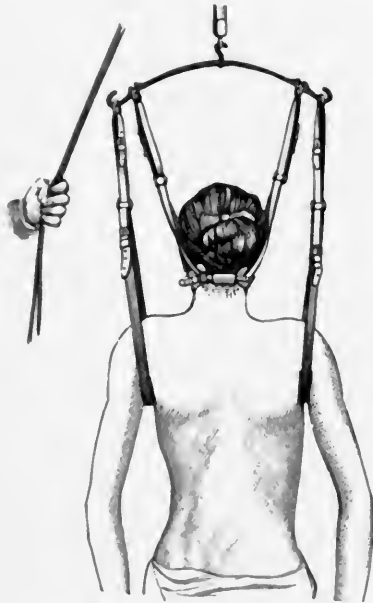

FIG. 674.—Apparatus applied.



FIG. 675.—Body extended.

material. The iliac spines, the adjoining portions of the iliac crests, and the mammary glands in the female should also be protected:

“Suitable space for the latter should be provided by the introduction of properly shaped pads.

“Tie the shirt over the shoulders and fasten it between the legs. Then the patient is drawn up by the extending apparatus (Fig. 674), gently and slowly until he feels perfectly comfortable, *and never beyond that point* (Fig. 675). A prepared, saturated plaster-of-Paris roller having been gently squeezed, so that all surplus water is removed, is now applied around the smallest part of the body, and is carried round and round the trunk, downward to the crest of the ilium, and a little beyond it; afterward in a spiral direction from below upward, until the entire trunk from the pelvis to the axillæ has been incased.

“The bandage should be placed smoothly round the body, and must not be drawn tight; it should be simply unrolled with one hand while the other

follows and brings it into smooth, close contact with all irregularities of the trunk.

“After one or two thicknesses of bandage have been placed around the body in the manner described, narrow strips of roughened or perforated tin can be placed parallel with each other on either side of the spine, or, if the case requires it, at intervals of two or three inches in sufficient number to surround the body. Over these another plaster bandage is applied. In a very short time the plaster sets with sufficient firmness, so that the patient can be removed from the suspending apparatus, and laid upon the face or back on a hair mattress, or, what is preferable, especially when there is much projection of the spinous processes or sternum, an air bed. Before the plaster has completely set, the ‘dinner pad’ is removed, and the plaster gently pressed in with the hand, in front of each anterior iliac spinous process, for the purpose of molding the case over the bony projections.

“While the jacket is drying it is necessary sometimes to wet it with a little water and dust it with more plaster. The surgeon often leaves some weak spots that need strengthening in this manner.

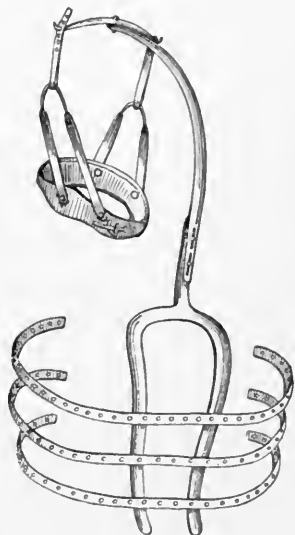


FIG. 676.—Sayre's jury-mast head-swing.

“If the deformity be located in the upper dorsal or in the cervical regions, the splint will be inadequate for the purpose, and the ‘jury-mast’ (Fig. 676) should be incorporated with it, and thereafter so attached to the head and regulated as to relieve the spine of its burden (Fig. 677).”

The preceding is a description as recorded by Dr. Sayre, to whom the profession is indebted for the prominence which has been given this method.

The Deformities dependent upon Perverse Muscular Action are, in an operative sense, relieved by subcutaneous division, called myotomy and tenotomy; the latter has been already considered (Chapter IV).

Torticollis (Wryneck).—The operative treatment of congenital wryneck is directed to subcutaneous or open division of the sterno-mastoid muscle and restraining fascial bands. The former method of procedure has already been described (page 338). *The open method* is practiced under strict antiseptic precautions, and consists of dividing the sterno-mastoid, near its lower extremity, from without inward, while on the stretch. Restraining bands of fascia are divided at the same

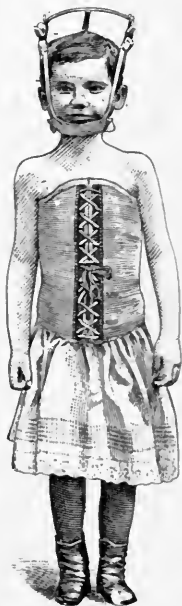


FIG. 677.—Jury-mast apparatus applied.

time. After the arrest of hæmorrhage the incision is closed, the deformity rectified, and the head held in an overcorrected position by a plaster-of-Paris bandage or other suitable means until cure is effected.

The Remarks.—The open method gives good results, but has limited application. The care needed to avoid injury of the underlying important structures is apparent. Other cervical muscles preventing rectification can be divided, if not too deeply located; then their opposition can be overcome by forcible restitution under anæsthesia.

Spasmodic wryneck is treated by resection of the spinal accessory nerve (page 319), and of the posterior divisions of the cervical nerves (page 320). The latter are divided in instances of post-cervical muscular spasm and after failure from division of the spinal accessory.

The Remarks.—The results from section of the spinal accessory are quite flattering. Of twenty-six cases thus treated by Petit, thirteen were a “perfect success,” seven much improved, two but slightly benefited, three temporarily benefited. This operation is not so highly regarded as formerly.

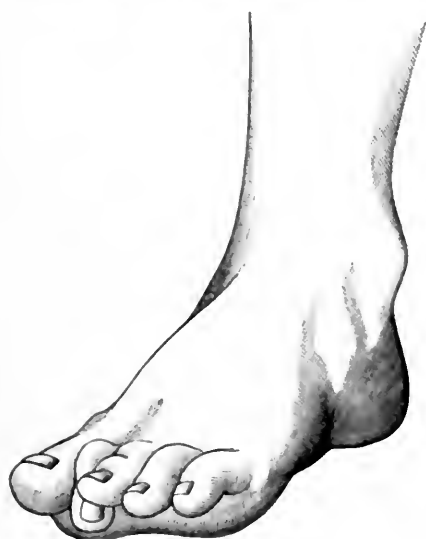

FIG. 678.—Hammer-toe.

perfect success,” seven much improved, two but slightly benefited, three temporarily benefited. This operation is not so highly regarded as formerly.

Hammer-toe (Fig. 678).—The deformity is indicated with sufficient accuracy by the illustration. In the majority of instances the second toe is affected, and when surmounted with a painful corn is exceedingly annoying. Two or three methods of treatment are practiced, depending on the obstinacy of the case: 1. Forcible reposition with the fingers, aided, if necessary, by a V-shaped division of the shortened skin. 2. Subcutaneous division of the lateral and glenoid ligaments, and even the flexor tendons when required.

The division is accomplished by means of a narrow-pointed strong-backed knife (Fig. 368), the point being entered at the center of the under surface opposite to the first interphalangeal joint and carried upward beneath the skin, avoiding the digital arteries and nerves (Fig. 227). Sever the lateral and the glenoid ligaments, and divide the long tendon without removal of the knife, if required. Now, complete restoration can usually be accomplished with but little effort. A failure in the attempt is followed by the employment of other means in turn, such as division of the extensor tendon, excision of the head of the bone, and even of the entire joint. Amputation need not be considered if the foregoing expedients can be carried into effect properly.

Mallet-finger (Fig. 679).—This deformity results from a blow upon the end of the finger, and is a sequel of changes in the joint and contiguous tissues due to gout. In the former instance the points of attachment of

the extensor tendon to the phalanx are partially or completely torn asunder, or stretched, or thinned by separation. In the latter, stretching is the principal element of the cause of the deformity. Repair can be effected by exposure of the extensor tendon at the dorsum of the distal phalanx through a longitudinal incision about three quarters of an inch in length. The tendon is raised, divided transversely at its thinnest portion, shortened, and the proximal end, advanced so as to overcome the deformity, is stitched to the under surface of the skin near to the root of the nail. The wound is closed and the finger confined until repair has taken place. The end of the tendon becomes fixed to the skin and also to the underlying periosteum; if moderate overcorrection be secured at the outset the final result will be correspondingly improved.

Snap-finger.—This expression refers to an interrupted extension of a finger, often requiring aid, and attended with an evident snap or jerk of the finger when the obstruction is overcome. After passive motion fails to cure this infirmity, any abnormality associated with the tendons or with their synovial structures contributing to the trouble, should be approached and treated through a free incision, and under strict antisepsis.

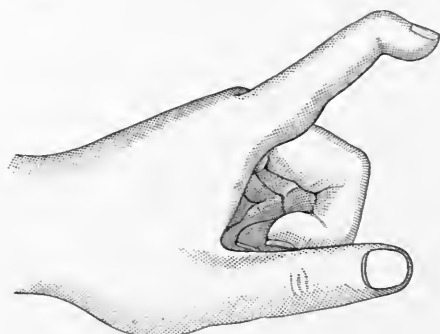


FIG. 679.—Mallet-finger.

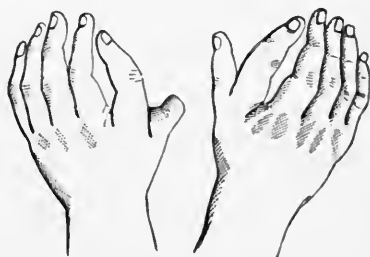


FIG. 680.—Supernumerary digits.

Deformities due to Fusion of the parts and supernumerary attachments, like webbed fingers and toes, and supernumerary digits, although not common, are nevertheless entitled to consideration.

Polydactylism (Supernumerary Finger).—One meets occasionally with a case bearing an extra finger, usually located at the radial side of the thumb or the ulnar side of the little finger (Fig. 680). Bone is usually, although not necessarily, present in these abnormalities. They should be removed early, and with strict antisepsis, because not infrequently the synovial cavities of the normal are intimately associated with those of the attached extremities of the abnormal digits. Supernumerary toes are similarly treated.

Syndactylism (Webbed Fingers).—The operative treatment for the relief of this deformity will depend very much indeed on the extent as well as the thickness of the attachments; whether the connections be limited to the soft parts alone, or the bones be fused. Digits that are united by their extremities only can be separated easily by the division of the tissues which connect them. If they be united the entire length, even then an incision in

the median line of their attachments, down to the line of the normal web, may be sufficient to effect a cure, if the tissues connecting them be not too thick; if such be the case, great difficulty is often experienced in healing the divided surfaces, owing to the tendency to reunion at the point of junction. To obviate this, various expedients have been recommended, one of which (Rudtloff) is to introduce a rubber seton at the base of the malformation on a line with the normal web of the hand, and allow it to remain until the opening becomes permanent (Fig. 681), when the remaining portion is divided and the borders united by sutures. The employment of a lead, silver, or gold button has been practiced with a similar outcome. Another plan (Dec) is to make a short triangular flap of the entire thickness of the web at its posterior portion, the base corresponding in shape and size to the space between the knuckles, and the apex directed to the free edge of the abnormal attachment. The flap is raised and turned aside, the fingers kept widely separated, until the cicatrization of the flap is followed by

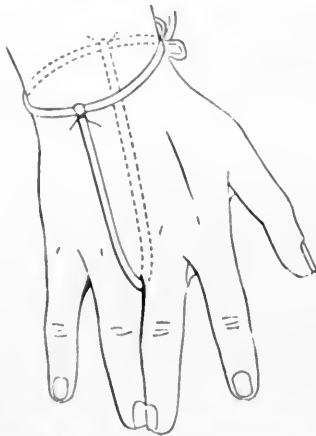


FIG. 681.—Webbed fingers.

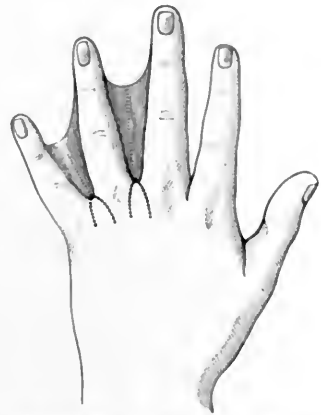

FIG. 682.—Norton's operation.

retraction and formation of a new commissure. The remaining portion of the web is then divided and the borders of the wound are closed by sutures as in other instances. This method is well suited for the treatment of wide-webbed cases.

Norton suggested the making of two well-nourished flaps at the base of the phalanges—one on the palmar and one on the dorsal aspect—followed by severance of the webbed tissue between them up to the base of the flaps (Fig. 682). The flaps are then united with each other by fine sutures, and the fingers are kept well apart during healing.

Another very effectual and ingenious method, devised by *Diday* (Fig. 683), is thus described by *M. Nélaton*: “A longitudinal incision is made in the center of the phalanx of one finger on the dorsal aspect for the posterior flap (*a b*); on the palmar aspect of the other for the dorsal flap (*c d*); the length of the incision will correspond with the depth of the web. From either extremity of the longitudinal incision, a small transverse one is to be

made toward the phalanx of the connected finger (Fig. 683). The lower transverse incision will correspond to the free edges of the web; the upper one will cross the flap between the fingers. Each flap is now to be dissected back toward the contiguous fingers. In doing this the two folds of the

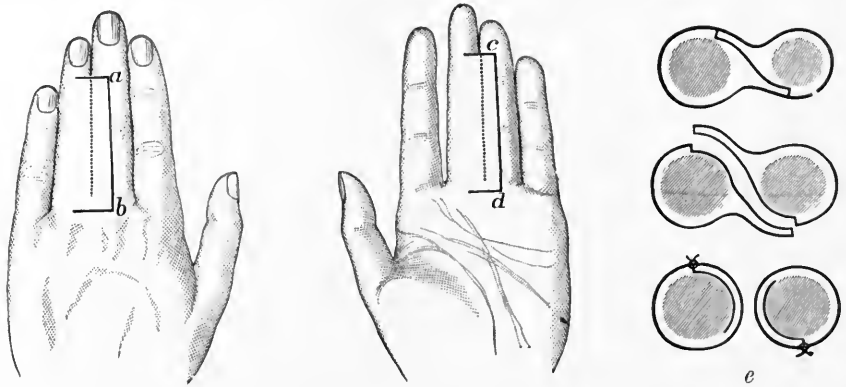


FIG. 683.—Diday's operation.

web will be separated from each other, one entering into the formation of the posterior flap, the other into the formation of the anterior. Each flap will now be found to be attached by one edge only, and is to be wrapped around the denuded surface of the finger to which it is attached (*e*). The flaps are to be adjusted by strips of adhesive plaster and by sutures."

Annandale says: "The principal objection to this ingenious operation appears to me to be that it necessitates cutting into the palmar and dorsal aspects of the fingers in order to get a flap to cover their sides." If the web or fold of the skin be loose, he deems it preferable "to make the longitudinal

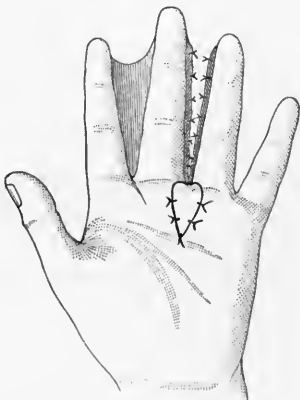


FIG. 684.—Agnew's operation.

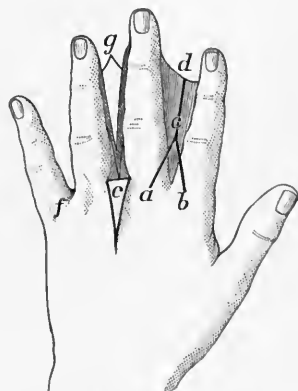


FIG. 685.—Zeller's operation.

incision along the sides of each finger instead of along the center of the dorsal and palmar aspects." Diday's method is objected to also on the ground that the web may be too thin to admit of splitting without danger of sloughing, and that, in spite of every care, the granulating process may

involve the cleft and cause renewal of the deformity; also that flexion and extension of the fingers may be crippled if the flaps be ill-fitting. If Diday's operation be performed, care must be taken in uniting the flaps or sloughing will ensue.

Agnew's Method (Fig. 684).—Raise from the dorsal surface of the base of the web a triangular-shaped flap, with the apex forward, comprising half the thickness of the web; divide the remaining portion of the web longitudinally; carry the flap through the cleft at the base of the fingers; stitch its apex and its borders to the wound of the palm and the sides of the fingers respectively; separate and immobilize the fingers while healing takes place.

Zeller's Method (Fig. 685).—Make two incisions on the dorsal aspect of the web and fingers, beginning respectively at the metacarpo-phalangeal joints ($a b$) and ending at a common point in the middle of the web (c), opposite the second (surgical) interphalangeal joints; reflect the triangular flap thus formed and divide the remainder of the web ($c d$); separate the fingers widely and carry the flap (e) between them, and join it with the borders of the cleft and the wound of the palm. Keep the raw surfaces widely separated during healing.

Fowler advocates an original proposition (Fig. 686) for the relief of severe and intractable cases in the following words: "Dissect up two narrow flaps from the back of the hand ($b^2 b^3$) and pass them through a button-holelike slot previously made in the line of the natural web ($a^1 a^2$), and well up between the heads of the metacarpal bones. If for a single web,

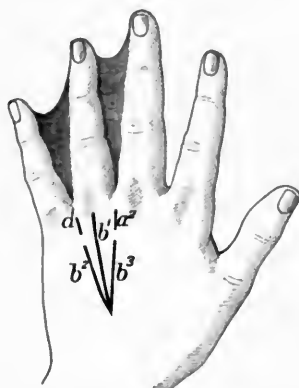

FIG. 686.—Fowler's operation. Formation of flaps and buttonholes.

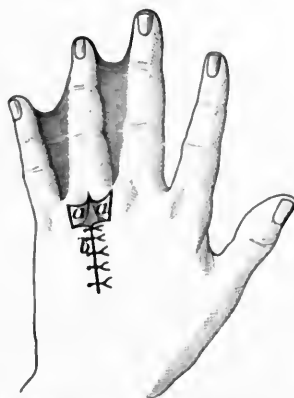

FIG. 687.—Fowler's operation. Flaps passed through buttonholes.

'place the flaps with the skin surfaces facing each other, rotate each flap slightly,' and pass them through the buttonhole so as to project a quarter of an inch or more on the palmar surface. The extremity is pinned to the palm as no sutures are needed. At the end of a week divide the web, and a 'healthy integumentary tissue' will be found to occupy the cleft. If a double web be present, each flap can be thrust through the slit corresponding to it. The wound on the dorsum (Fig. 687) is closed at once and

dressed; the bases of the flaps are divided when the web is severed. The wound is treated aseptically throughout."

The Remarks.—When the joints of the digits are fused, it is not wise, as a rule, to attempt their separation, since, though it may be accomplished, the digits when separated may have their function greatly impaired; however, this course of action is not so objectionable since the advent of asepsis. If a supernumerary digit possesses an independent articulation, it can be removed without any great danger to its associate.

Ingrown Toe Nail.—Ingrown toe nail is quite a common affliction, to the relief of which various palliative measures have been directed (Fig. 688). As a rule, however, they have been found inadequate to effect a cure. This condition is induced largely by improperly fitting boots and shoes, although in some persons there exist additional causes. Going barefooted will in a majority of cases effect a cure, but, since this is rarely practicable, operative measures are often necessary.

The Operation.—When the affliction is fully established, administer an anæsthetic, and with a sharp-pointed scalpel divide the nail at the side its entire length on a line parallel with its ingrown border (+), which latter can then be quickly and easily removed by a thin-bladed forceps or a narrow spatula passed beneath it. If the other border be affected, it, too, should be removed in a similar manner. Cauterize the exposed matrix back to the limit of the root, and apply a hot aseptic anodyne poultice at once. The patient must keep quiet until the tenderness has in a measure subsided. In no instance ought the entire nail to be removed unless it be diseased.

The method just described is somewhat old-fashioned, and although satisfactory as far as final relief is concerned, still the cure is protracted, and the final outcome less gratifying than with the modern and more scientific methods of procedure.

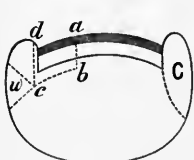


FIG. 689. — Transverse section showing *a b c d* tissue removed at matrix. *w*. Wedge-shaped removal. *C*. Cotting's operation.

Anger's Method.—Inject into the diseased site twenty or thirty drops of a two-per-cent solution of cocaine, having previously encircled the toe with rubber tubing to limit the action of the cocaine and control hæmorrhage. Beginning above the upper limit of the matrix (dotted line), split the nail longitudinally, close to the diseased margin (+) with a sharp knife; remove the fragment of nail with forceps; dissect away the diseased parts (*A*), including the exposed matrix (Fig. 688), even scraping the periosteum from the bone at that situation (Dowd); bring the borders of the wound together (Fig.

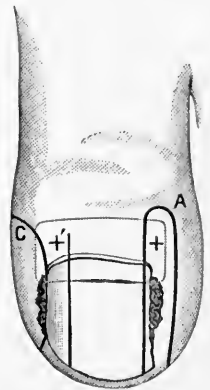


FIG. 688.—*A*. Anger's operation. *C*. Cotting's operation. +'. Earlier method. Dotted line, the limits of matrix. +. Tissues removed in Anger's operation.

690) with horsehair; dress antiseptically, and keep the limb quiet for two or three days. Or the diseased soft parts can be removed with a knife, transfixing vertically at the posterior limit of the exposed matrix all of the

tissues, followed by their complete anterior division along the side of the phalanx. The diseased portion of the flap thus formed and the exposed matrix (*a b c d*) are carefully dissected away and the wound closed and treated as before.

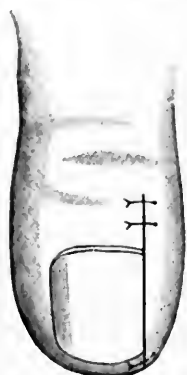


FIG. 690.—Anger's operation completed.

The Remarks.—The chief aim of this method is the complete removal of the matrix, to obviate the disfigurement and annoyance that might follow the development of horny growths. The removal of a thin portion of the underlying bone is sometimes practiced to insure success in this regard.*

The Results.—Dowd reports twenty-three cases that were under his observation for periods of twelve days to twelve months, and in all but one the result was entirely satisfactory. Dr. Dowd's subsequent experience equals in number and conforms in results to the preceding, so far as he can now determine.

Cotting sliced off together the healthy and affected tissues down to the margin of the nail, and allowed the wound to heal by granulation (Fig. 688, *c*).

Cases in which the anterior portion of the nail only is at fault can be treated by the removal of a wedge-shaped piece (Fig. 689, *w*) of the soft parts from the side of the toe and the closure of the wound with sutures, thus drawing the inflamed tissue away from the border of the nail. In this method special care must be taken to avoid infection of the fresh wound.

Bunion.—A bunion is accompanied in a large proportion of cases by malposition of the great toe (Fig. 691), and increase in the size of the normal bursa, or the development of an adventitious one. The simpler operative means for relief consist either in the excision of the bursa or its subcutaneous division with a narrow tenotome. If these means fail, a sufficient amount of bone should be excised to allow the return of the toe to its normal position. The operation described on page 408 can be performed in such cases, after which the toe is confined in place until recovery is established.

The Remarks.—Since free communication between the bursa and the joint cavity is often present, the former should be invaded only with strict antiseptic precautions. It is sometimes necessary to sever the attachments of the bone at the fibular side of the second (surgical) phalanx before proper rectification can be satisfactorily maintained, even after quite free excision.

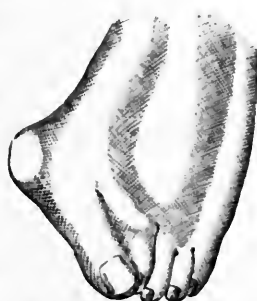

FIG. 691.—Bunion with hallux valgus.

* If bleeding happen, Horsley's wax may be applied. Horsley's wax is composed of seven parts of bee's wax and one each of sweet oil and salicylic acid. It should be kept in a wide-mouthed jar under a solution of carbolic acid. It is pinched off and kneaded for use when required.

CHAPTER XII.

PLASTIC SURGERY.

PLASTIC surgery relates to the means adopted to overcome or alleviate the deformities of aspect and function resulting from congenital defects, disease, or accident, by the utilization of living tissue.

Inasmuch as the successful issue of these operations depends far more on the careful attention to the details and small matters connected with them than anything else, it is well for the operator to understand at once that there is no precaution so trifling as to be treated with indifference.

The Preparation of the Patient.—The patient ought to be in a vigorous physical condition, the appetite and functions normal, and the surroundings of such a character as to combine quietude of mind with close and gentle attention. No association can be allowed with putrefactive processes, or diseases known to engender changes derogatory to union and repair. Prior to the operation, the part should be purified by well-recognized aseptic measures.

The Size of the Flap.—The shape and size of the flap must be ascertained by careful measurement. A pattern of the deformity to be repaired is carefully cut out and used to outline the flap employed in filling the gap. The contraction of the normal tissues, when loosened from their underlying attachments, may be sufficient to require undue force to secure proper coaptation of the divided borders. Therefore, reparative flaps should always be made large enough to admit of at least four lines of shrinkage for each inch in width of their surface.

The flap should be formed of sound, healthy skin, and under no consideration should cicatricial tissue of a pale, glossy surface be employed, for when its subcutaneous connections are severed, it is almost certain to slough, especially when the result of a burn. The relation which cicatricial tissue bears to a flap is all-important. If it exists at the base, sloughing is quite likely to occur. Cicatricial tissue at the border of a flap is quite certain to die, and its presence there must not be estimated in computing the area of the new flap. When the flap is to be joined on three sides with cicatricial formation, the base must be made large, be highly vascular, and but little twisted, as the vascular supply at the sides will be very little added to by the new association. The thickness of the flap should be sufficient to include all the vessels that normally afford it nourishment. The long axis of the flap should correspond to the course of its vascular supply,

and the base must be located as nearly as possible to these vessels. Hemorrhage must be checked before the flaps are united, since an intervening thin clot of blood may prevent union. The direction of the flap should be such that it can be properly placed with the least twisting of the pedicle. The edges of flaps may be beveled; this increases the width of the opposed surfaces, and, when combined with undercutting of the borders, increases the chances of union. Silk-worm gut and horseshair make efficient sutures, and should not



FIG. 692.—Paper-protective.

be drawn tightly. Carbolized cotton yarn (Buck), in connection with the plastic pins, offers a soft and otherwise admirable retaining agent when frequently changed. To avoid any danger of ulceration at the pressure points small squares of aseptic carbolized unglazed bibulous paper, of a diameter of half an inch or so (Fig. 692), with a small hole through the center of each, may be used beneath the knots (Fig. 693).

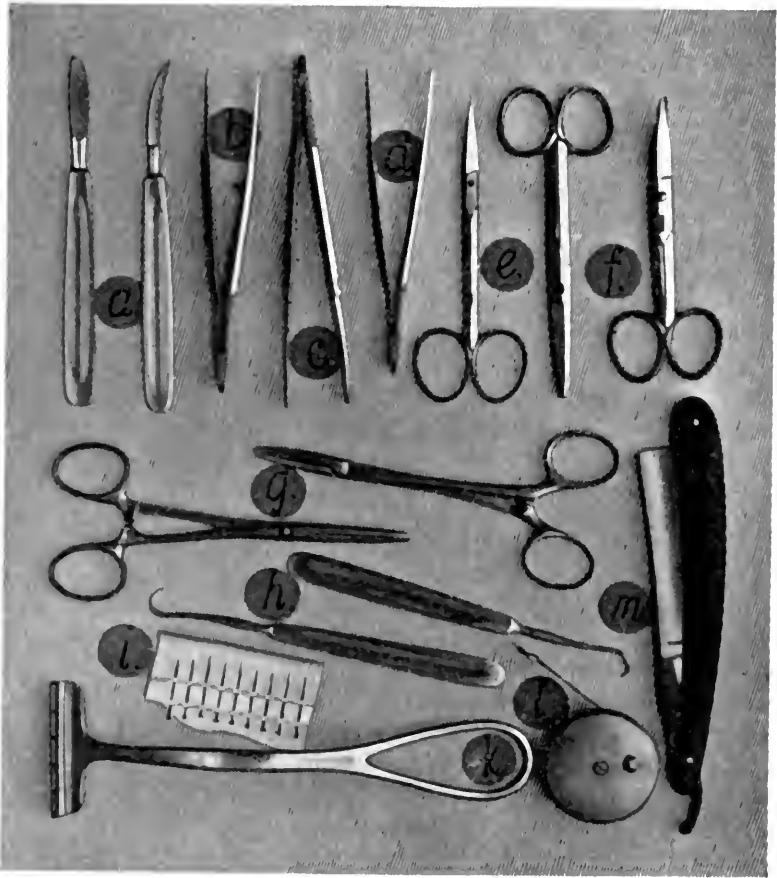

FIG. 693.—Instruments employed in plastic surgery.

- a.* Small scalpel and bistoury. *b.* Thumb forceps. *c.* Thiersch's forceps. *d.* Mouse-tooth forceps. *e.* Curved sharp-pointed scissors. *f.* Curved and straight blunt-pointed scissors. *g.* Forepressure. *h.* Tenacula. *i.* Black pins. *k.* A McBurney traction hook. *l.* Tape measure. *m.* Razor for cutting skin grafts.

If small black pins (*i*) be inserted to indicate the extent of the flaps, the incisions will be formed more accurately than if they be measured by the aid of the eye alone. Flaps can be applied at once to the gap or allowed to remain *in situ*, surrounded with proper dressing, until the vitality is tested by the capacity of the base to properly nourish them. *Migratory flaps* are sometimes necessary to meet the demands of scanty contiguous integumentary supply. A migratory flap is one transferred to a prepared site located nearer to the final one than is the seat of removal. As soon as the flap is properly united at this place, the position is again changed to another still nearer the site of final lodgment, and maintained either through the preservation of the primary pedicle or the formation of a new one, depending on the requirements of the case.

The Methods of Transfer.—The methods of transfer may be classified into six general forms, with their subdivisions: 1. Sliding in a direct line. 2. Sliding in a curved line. 3. Jumping. 4. Inversion, or eversion. 5. The Taliacotian. 6. Grafting.

Sliding in a Direct Line.—Four varieties characterize this method of transfer. *The first and simplest variety* consists in uniting the lips of an ordinary incision made for the purpose of repair of adventitious openings in the skin, and of the simplest forms of harelip, and is sometimes called “simple approximation of divided surfaces.”

The second variety is called “undercutting,” and consists in cutting under the edges of an incision at each side before drawing them together. This method is employed in the adjustment of the borders when undue traction attends their union.

The third variety consists in sliding in a direct line by aid of parallel incisions made at both sides of the primary one, which is finally closed. The

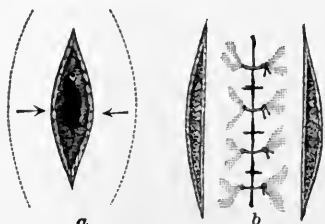


FIG. 694.—*a*. The defect, parallel incision. *b*. Closure, sliding in direct line.




FIG. 695.—Transverse liberating incision.

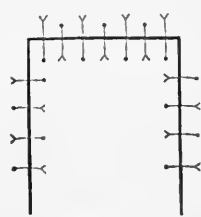


FIG. 696.—Opening closed.

outside incisions are allowed to heal by granulation (Fig. 694). Undercutting at the primary incision lessens the tendency to separation of the parallel ones.

In the fourth variety the liberating incisions are made transversely—that is, at right angles to the extremities of the defect, or in the long axis of it, and undercutting is employed freely (Fig. 695) to permit closure of this opening (Fig. 696). The uppermost curve is undercut, and the lowermost is liberated by a combination of undercutting and sliding aided by transverse incisions. The defect *a b c d* is repaired by making incisions at

either end of the defect in the line of its long axis, and raising and bringing together at *a b* and *c d* the flaps *e a c f* and *e' b d f'*. After further sewing the wound appears as in the illustration. The employment of two

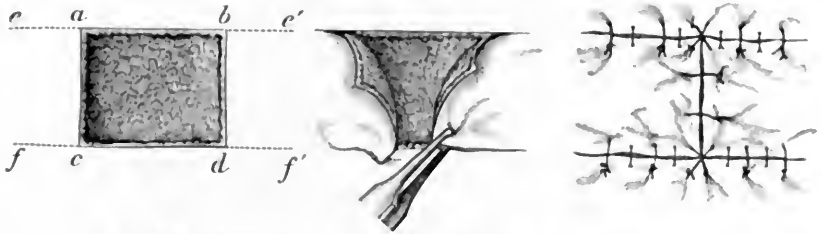


FIG. 697.—Repair by incisions in the long axis of the defect.

flaps for a definite purpose lessens correspondingly the demands that would be made on a single flap for a similar intent.

Sliding in a Curved Line.—Sliding in a curved line can be done with flaps having either curved or angular borders. In the former instance, the

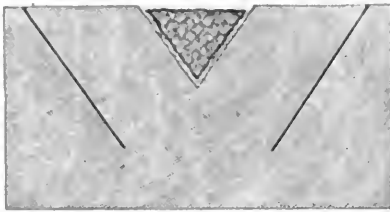


FIG. 698.—Dieffenbach's bilateral-flap method.




FIG. 699.—Dieffenbach's bilateral-flap method, defect closed.

space from which the flap is taken is filled by undercutting and drawing together the borders. In the latter, the space is usually allowed to close by granulation. This method of repair is directed especially to the closure of triangular, quadrilateral, and elliptical openings in the integument. The

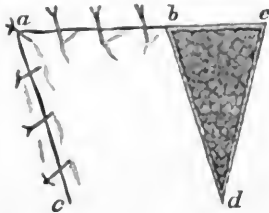


FIG. 700.—Dieffenbach's unilateral-flap method.

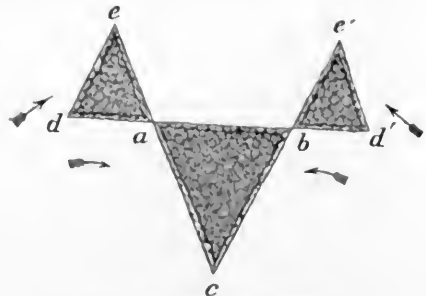


FIG. 701.—Burow's method.

triangular openings are readily closed by Dieffenbach's, Burow's, or Jaesche's method. *Dieffenbach* practiced two methods of closure, one a bilateral (Figs. 698 and 699), and the other a unilateral (Fig. 700) incision and

sliding method, in both of which the resulting triangular spaces were allowed to heal by granulation. The technique of these methods is plain enough without special comment. The flap $a b c d$ is dissected from the sides $e d$ and $b c$, slid across and united with the side $a c$, leaving the triangular space $b e d$ to heal by granulation.

Burrow's method of closure of a large triangular opening is ingenious (Fig. 701). It consists in making lateral incisions $d a$ and $b d'$, each equal in length to at least two thirds of the width of the portion of the triangle to

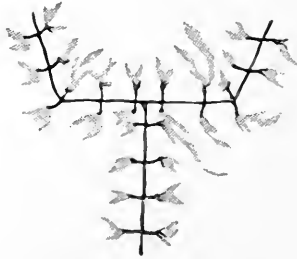


FIG. 702.—Burrow's method, flaps united.

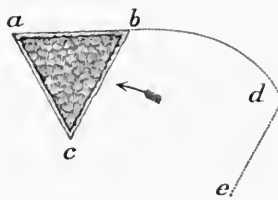


FIG. 703.—Jaesche-Dieffenbach method.

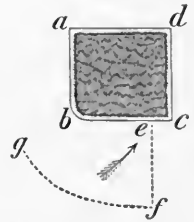


FIG. 704.—Littenneur's method.

which they correspond. The flaps $d a c$ and $c b d'$ are dissected up freely and united with each other ($a c$ to $b c$). This union causes great relaxation of tissue at either side ($a d e$ and $b e' d'$), which tissue is removed and the borders properly joined with sutures forming the outlines of Fig. 702.

Jaesche-Dieffenbach Method (Fig. 703).—The figure of this method explains fully the manner of its application. If the incision $b d$ (Jaesche) be carried downward and to the right $b e$, parallel with the border $b c$ (Dieffenbach), thereby forming flap $c b d e$, and the flap be dissected up and slid to join $a b c$, the gap will be readily closed.

Littenneur's method of closure of quadrilateral spaces by the curved sliding process is as follows (Fig. 704): The flap $b e f g$ is raised and slid so that the borders $e f$ and $a d$ are united with each other.

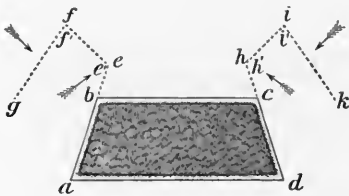


FIG. 705.—Brüns's method.

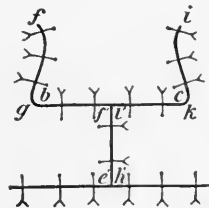


FIG. 706.—Brüns's method, flaps united

Brüns's method of closure with two lateral flaps is more complex (Fig. 705). In this the flaps $a e f g$ and $d h i k$ are raised, carried downward, and caused to fill the gap $a b c d$ by uniting the borders $h i$ and $e f$ with each other (Fig. 706).

Elliptical openings of large size can be closed by either of the following plans of procedure (Figs. 707 and 708). In the former the flaps $a c d e$ and $b c d f$ are raised, displaced upward, and united so as to close the open-

ing. In the latter (Weber's method) the flap *a c d* is raised and carried upward so that the point *c* can be united with the angle *b*. The second flap is utilized to close the remaining space (Fig. 708).

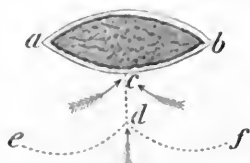


FIG. 707.—A method of closing elliptical opening.

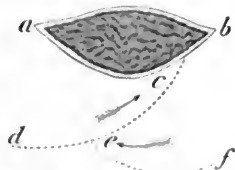


FIG. 708.—Weber's method of closing elliptical opening.

Jumping.—Jumping, as the name implies, consists in “jumping a flap connected by a pedicle over intervening undetached tissues.” It can be done with or without the pedicle being twisted (Fig. 709).

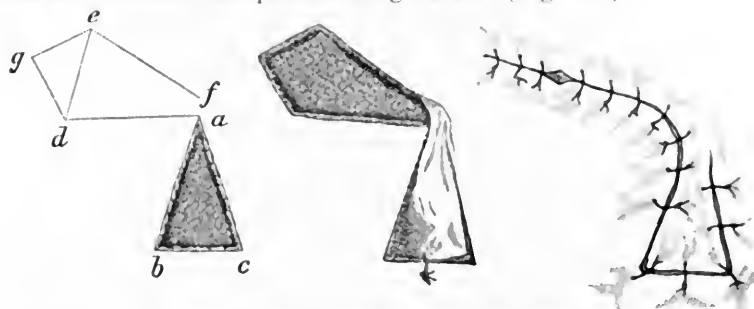


FIG. 709.—Jumping, pedicle not twisted.

If the flap be not moved more than a quarter of a circle, twisting of the pedicle is not necessary. Undercutting is employed in this operation when needed to adjust the parts properly.

In Fig. 709 the opening *a b c* is closed by a flap jumped a quarter of a circle and united. When the flap is moved more than a quarter of a circle the pedicle will be twisted, and the degree of twisting will depend on the distance the flap is moved. Fig. 710 illustrates a twisted pedicle improperly employed in the repair of the lower lip.

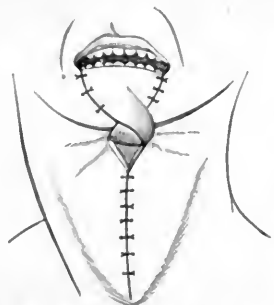


FIG. 710.—Jumping, pedicle much twisted.

If the pedicle be too much twisted, the circulation of the flap will be impeded, and sloughing will ensue.

Inversion and Eversion.—These methods relate to the employment of integument in the repair of mucous membrane, or *vice versa*. Tubular formations may be constructed by either of these methods, as in the formation of new canals, like the urethra, vagina, and the

closure of an extroverted bladder.

The Tagliacotian Operation.—The tagliacotian operation is familiarly known as the dissection of a flap from another and distant portion of the

body, and after granulation its final application to the part to be repaired, as may be done in the operation for the construction of a new nose (Fig. 711).

Grafting.—Grafting by the entire removal of a thick skin flap to the locality to be repaired is no longer practiced. The assured success of the newer methods has supplanted almost entirely all attempts with this, the older one. However, severed portions of the nose, ear, and tips of the fingers are sometimes rescued, when not infected or badly bruised, by immediate restoration to their former sites. In such instances the fragments should be carefully sewed in place with fine sutures, and dressed so as to keep them warm and with a minimum impairment of the circulation. A skin flap having only a pedicle of subcutaneous tissue is sufficiently well nourished for plastic repair of mucous membrane when turned into the defect without twisting. The mucous membranes of the urethra, cheek, etc., can often be repaired by the transplantation of this membrane from man and animals. The loss of bone tissue is occasionally remedied by the transplantation of large pieces with and without their periosteum, and frequently by small ones taken from near the joints of the young, whose bone growth is active, and from elsewhere, and employed successfully with (page 450) and without (page 235) decalcification. Pieces of ivory, sponge, and even bone ash have been utilized as a framework in the efforts at repair by the development of new bone. As the result of these various efforts, curious and highly important ends have been accomplished which justify the efforts and emphasize the wisdom of a continuance, and the belief that important practical benefits may arise from the labor.

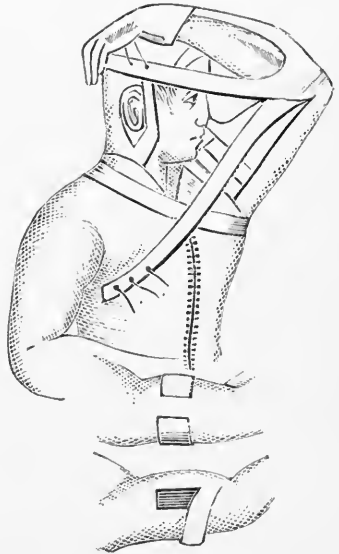


FIG. 711.—Italian method.

Skin-grafting is practiced for the purpose of causing the healing of fresh and granulating surfaces of larger or smaller size. It is essential to success that the granulations be healthy and that aseptic care be exercised in the performance of the grafting. Three methods of procedure are now well recognized: one, the oldest, Reverdin's method, the others and the more modern, Thiersch's and Krause's methods.

Reverdin's method is performed by *first* making small punctures in healthy granulating surface with the sharp end of a common pocket probe, half an inch or so apart; and, *second*, by placing over the open mouths of these shallow punctures small pieces of integument, a line or two square, with the fresh surface downward. They are then pushed into the openings of the punctures by the same probe, in such a manner as to cause a close contact between the raw surfaces of the small "grafts" and those of the

punctures in the granulating surface. Small pieces of sterilized lint are placed over each graft, and confined in position by narrow strips of adhesive plaster. The part should be carefully redressed at the end of three or four days. At this time small flocculent appearing spots will be noticed corresponding to the seat of the grafts, if it have been successfully placed. The bits of skin employed are taken from the healthy surface of the donor by means of a fine thumb forceps and small curved scissors and include the rete Malpighii.

Thiersch's Method.—In Thiersch's method the raw surfaces of strips of the epidermal layer of the integument are placed in contact with the shaven or curetted base of an ulcer, and with fresh surfaces of recent wounds. A sharp razor, saline solution, rubber tissue strips, aseptic gauze, aseptic cotton, and gauze bandages are required for the operation. Neither antiseptic solutions nor gauze should be brought in contact with the grafts, as the contact will impair their vitality. The tension hooks of McBurney (Fig. 693, *k*) are handy and serviceable, although not essential, as the skin of the thigh or arm—from which grafts are usually taken—can be made sufficiently tense for the purpose by opposing manual traction of the operator and the assistant (Fig. 713). *Schleich's No. 3* (page 39) renders removal painless.

The Operation.—Make tense the skin at the outer surface of the thigh or arm (Fig. 712); lay the razor flatwise on the surface and with a slow to-and-fro movement split the integument in the long axis of traction, making the strips of such length and width as is necessary or convenient (Fig. 713, *a*).

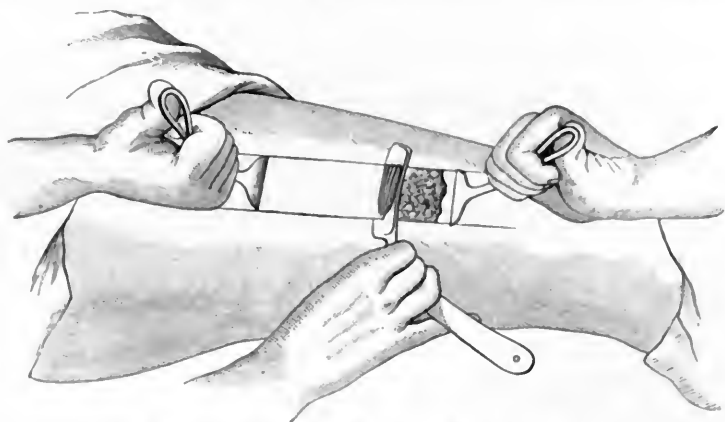


FIG. 712.—Cutting grafts; traction hooks.

The graft is retained on the upper surface of the blade as fast as formed, and when of proper length is divided at the base with scissors or by the razor alone. The razor with the graft is instantly dipped in the saline solution and the graft placed in position by a reverse motion of the razor, while the base of the graft is held in proper place with the finger or probe (Fig. 713, *b*). The presence beneath the graft of air, blood, foreign bodies, etc., hinders union and may prevent it altogether. After the integumentary grafts are suitably placed, the wound is covered with strips of aseptic rubber tissue wet

with the saline solution, and arranged as in ordinary strapping. Aseptic gauze and sterilized absorbent cotton follow, held in place with a gauze bandage lightly applied. The part is redressed on the fourth or fifth day. The occasional moistening of the superimposed dressings with the saline solution is not practiced so much now as formerly, and there is good reason to believe that undue importance has been attached to this practice in the past.

Krause's Method.—The preparations for grafting require that the integument to be used for the purpose shall be bathed with a bichloride

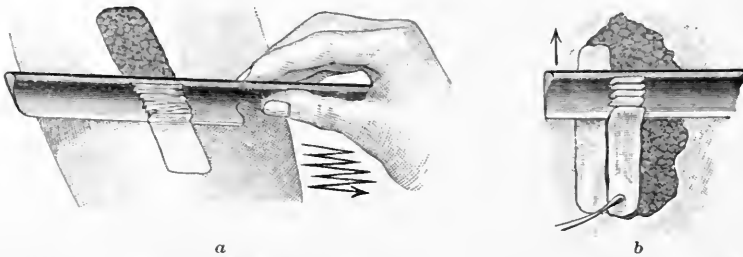


FIG. 713.—*a.* Cutting grafts without traction hooks. *b.* Placing graft in position.

solution, rinsed with the saline, and wiped dry with and surrounded by sterilized gauze. The seat of repair should be fresh, all granulation tissue being removed down to the normal structures with a knife, and the surface thoroughly cleansed with the aforementioned solutions, the bleeding arrested, and surface pressed dry with sterilized gauze. The grafts should be oval or spindle-shaped, include the skin only, and be outlined before raising; they should be promptly and aseptically dissected up with forceps and scalpel, placed in position without moistening, and gently pressed into close contact with the surface, and carefully confined there with sterilized or iodoformized gauze supplemented by additional gauze closely confined in place with bandages.

The Remarks.—The part to be repaired should be made anæmic when possible by elastic pressure, and the grafts applied and the part dressed before the elastic bandage is removed, thus hastening the procedure and facilitating union. For it is stated (Fischer) that grafts removed from and applied to parts made anæmic by such pressure unite more promptly than when otherwise treated. The subcutaneous fat should be entirely removed from the flap. These flaps thrive when applied to muscle, fascia, bone, etc., and with nearly equal vigor. The fact that they appear discolored and swollen in a few days need not excite apprehension, as they frequently thus appear in successful cases. The dressings directly in contact with the wound should not be removed until they are thoroughly loosened by saturation with warm saline or boric-acid solutions, to prevent disturbing the grafts.

Lusk's (Z. J.) Method.—In cases in which for any reason the preceding methods are objectionable, this method can be employed with satisfactory results. Its application is attended with comparatively little annoyance, and consists in utilizing for the purpose the epithelium covering blistered surfaces. This epithelium is cut away while attached to overlying sterilized

gauze, treated for a few minutes with a warm solution of boric acid, divided into pieces a line or so square, each of which is carefully pressed at a suitable distance from its fellow upon the granulating surface already treated with weak sublimated and saline solutions respectively. Lusk advises that a layer of sterilized gauze saturated with a solution of balsam of Peru (one drachm) and castor oil (one ounce) be applied to the grafted surface. Two or three layers of sterilized cotton in addition, held in place with a roller bandage, complete the dressing. After three or four days the superficial dressing should be changed, but the deep dressing, whether of gauze or rubber tissue, may remain undisturbed for ten or twelve days.

The Remarks.—If sterilized gauze or rubber tissue be placed upon the cuticle and attached to it before the cutting, the cuticle can be readily handled, raised up, or cut into pieces along with the supporting structure, and applied and held in place by the overlying strip.

Croft's Operation for Cicatricial Contraction.—Croft's method consists in jumping a prepared flap into a gap resulting from a free incision of a band of cicatricial tissue of greater or lesser width. The operation can be practiced in any part of the body where a proper area of unaffected tissue can be utilized for the purpose. The rationale of the procedure is illustrated best in connection with cicatricial contraction at the arm (Fig. 714). Make the integumentary bridge as long as practicable, in healthy tissue, and as thick as possible, especially at the center; approximate the sides of the wound with sutures, carefully avoiding interference with the bases of the

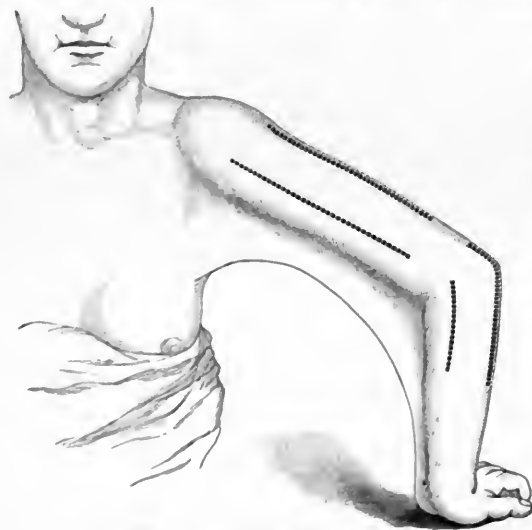

FIG. 714.—Croft's operation.

flap; separate the bridge of skin from the tissues beneath by a layer of oiled silk dipped in carbolyzed oil, being careful to make the separation complete at the bases, to avoid shortening of the flap by granulation of contiguous borders; cover the entire area lightly with antiseptic dressing and fix the part in an immovable position. At the end of two or three weeks cut through the cicatricial tissue down to healthful fascia and muscle; arrest hæmorrhage; divide the integumentary bridge; freshen the borders of the

flap and lodge the extremity in the cicatricial gap, being careful that they conform with each other as nearly as possible in shape and extent, and also that the free end of the flap be properly united to the opposite border of the gap. The parts are held in place by careful dressing, and the flap—especially the distal end—is cautiously treated to avoid sloughing. Much

time is required to secure the degree of union that bespeaks a successful issue of the attempt; six or eight months are often necessary for cure.

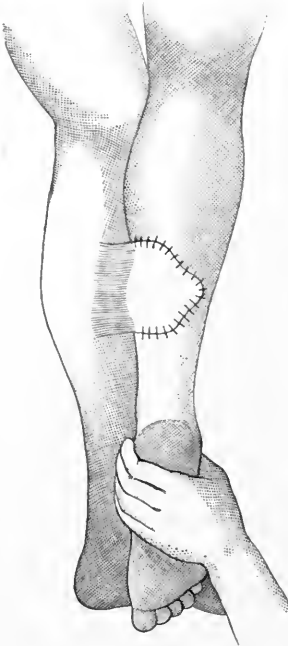

FIG. 715.—Flap with single pedicle.

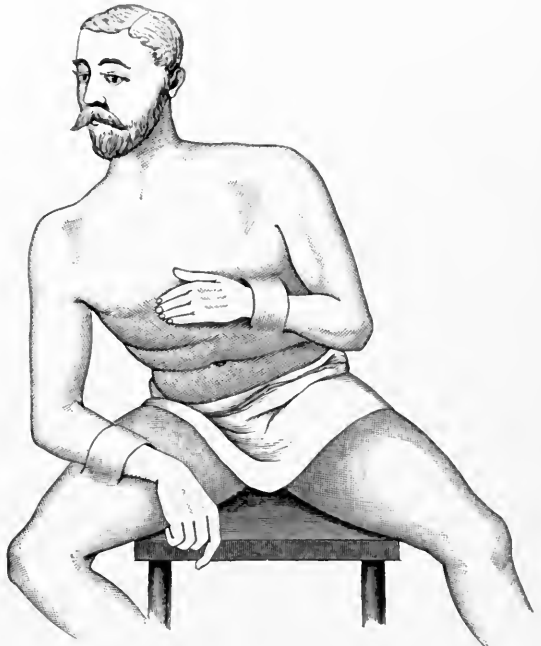

FIG. 716.—Flaps with double pedicle.

Examples of repair of a similar nature, in which pedunculated flaps are raised from another than the afflicted portion, and placed in contact with the granulated or freshened surfaces of it, are practiced (Figs. 715 and 716).

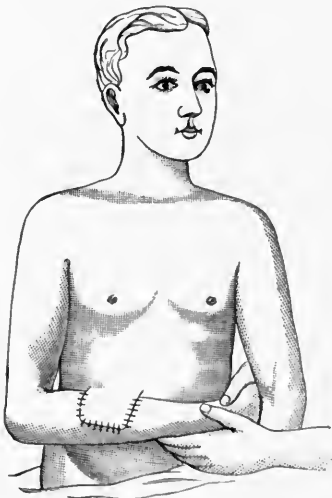


FIG. 717.—Single pedicle, forearm.

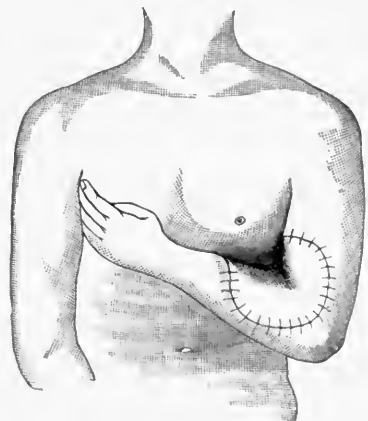


FIG. 718.—Single pedicle, author's case.

These flaps include the subcutaneous tissues, and their dimensions are estimated on the lines of recognized tissue contraction, as stated (page 569). The borders of the flaps are united with sutures to one or both of those of the defect, and thus maintained until proper union is assured. Ordinarily, in the instance of a double pedicle (Fig. 716), one pedicle may be divided after ten or twelve days, the other a week or so later. If only a single pedicle be present (Figs. 717 and 718), the division is delayed two weeks or more, according to its size, the condition of the circulation of the flap, and the state of the patient. It is wise to remember that a few days of delay is better than to precipitate action in the division by even one day.

The Remarks.—In these instances the raw surfaces due to raising the flap should be closed at once, if practicable, by sutures, or covered then or later by skin grafting. The interposition of rubber tissue or oiled silk at the bases of the pedicles, to prevent their shortening by healing, and also between the limb and body to obviate union of any apposed raw surfaces, is advisable. Thorough antiseptic practice should characterize throughout the operative and post-operative treatment.

Rhinoplasty.—Rhinoplasty consists in the reproduction of a part or the whole of the nasal organ. The present ability of the surgeon to arrest the diseases causing deformities of the nose has lessened the frequency of this operation. *Ingenious contrivances of ivory, rubber, etc.*, have been made to fit the deformity, and to thus supply a substitute for the lost parts. These contrivances, when tinted to conform to the complexion of the wearer, often prove quite deceptive to the observer; but, being unaffected by the various contingencies of the weather and the emotions, they are apt at times to cause the wearer to present a ludicrous appearance.

In operating on the nose for deformity, save all that is possible of its cartilaginous and bony tissues, for they will each afford important supports for the new structure. The cartilages of the alæ should, when possible, constitute the free border of the new structure.

The deformities of this organ may be due: 1, to a loss of the superficial soft parts, which may vary in extent and degree; 2, to a loss of the bony or cartilaginous septum, with or without loss of the nasal bones; or, 3, to a loss of both combined. The soft parts may be restored by utilization of one of the methods before named. The extent of the deformity and its situation will determine the choice of a method. When the loss of the integument is small and does not involve the alæ and the deeper structures, the defect may be remedied by the direct approximation of its borders, aided, of course, by a free undercutting with or without parallel incisions. The French method, by transverse incisions combined with undercutting, can be employed (Fig. 719) when the former is deemed inadequate.

The author some time ago fashioned a quadrilateral-shaped flap from either cheek with the pedicles downward and supplied with blood from the vessels of the upper lip, carried them inward, with the raw surfaces underneath, and united them with each other at the median line of the nose, and to the freshened border at the bridge, for the purpose of closing a large defect resulting from the removal of all of the soft parts of the nose, except

the septum and columna, and of the interorbital space, on account of a luxuriant epithelial cancer. The flaps united promptly and afforded a symmetrical and complete covering of the gap. However, the retractile forces of the tissue of the cheeks soon caused undue flattening of the nose, which deformity remained undisturbed, as the patient expressed a high degree of satisfaction with the result, not fully shared by the author. As evidenced by the presence of cicatricial tissue at the root of the nose, and emphasized by the knowledge of the obliteration of the angular arteries by the previous operation, this procedure appears here to have afforded the best solution of the problem. The gaps in the cheeks were closed with sutures and quickly healed. The nostrils were supported with pieces of drainage tube (Fig. 721) covered with iodoform gauze, and the whole lightly covered with aseptic dressing. The extended application of this method is particularly useful in those cases in which the upper part of the nose is intact.



FIG. 719.—Closure by transverse incision.

However, the tissue of the cheek is not so well adapted to nasal repair as is that of the forehead, owing to a lesser degree of direct vascularity and greater contractile tendencies. In still another instance two quadrilateral-shaped flaps—one from either cheek—were turned over and united at the median line of the nose and the raw upper surface was grafted by Thiersch's method. For some time the appearance of the organ was entirely satisfactory; later, however, contraction caused it to assume a saddle shape. It was then proposed to rectify the deformity with another flap, but the patient did not return to the hospital.

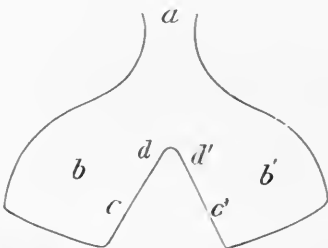


FIG. 720.—Syme's operation, bilobar flap.

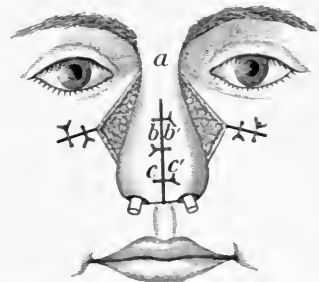


FIG. 721.—Syme's operation, flaps in place.

Syme's Operation.—Syme's operation is a fair illustration of the extended method of procedure. A symmetrical bilobar flap (Fig. 720) is formed from the cheeks, the pedicle (*a*) being located at the root of the nose; the area and

borders of the gap are freshened; the flap is placed in position, and the lobar portions are united with each other in the median line and with the freshened borders of the gap at the sides (Fig. 721). The nostrils are supported by rubber tubes, the gaps on the face closed with sutures, and the entire wound is covered lightly with aseptic dressing.

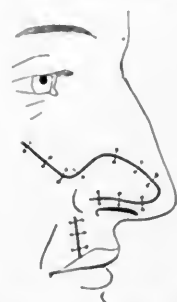

FIG. 722.—Repair by jumping.

The Remarks.—The cicatrization of the triangular-shaped places at the sides of the nose apparently increases the height of the organ. If a septum be present the transfixion of the entire structure at the outer and lower borders of the flaps with a fine needle will provide satisfactory support during the healing process.

If the extremity of the nose or the alæ be involved, sliding in a curved line, the flap having either curved or angular borders, is recommended. Figs. 722 and 723 represent

the restoration of the alæ by a flap taken from the cheek and upper lip. The flap must be of sufficient size to allow at least one fourth for its contraction, otherwise when united in position it will displace the axis of the nose, thereby substituting one deformity for another. *Langenbeck* repaired a similar deformity by taking a flap from the opposite side of the nose (Fig. 724). As in the preceding method, the dissection must be carefully made down to the cartilaginous framework. The border of the new alæ, although freshly cut, heals in a satisfactory manner. Fig. 725 shows the line of incision employed to repair the deformity with a flap possessing an already cicatrized border. The vascular supply of this flap is not active, and every precaution should, therefore, be taken to provide against the danger of sloughing.

The incision is begun at the sound side, near the tip of the nose, and ex-



FIG. 723.—Ellis's method, from lip and cheek.

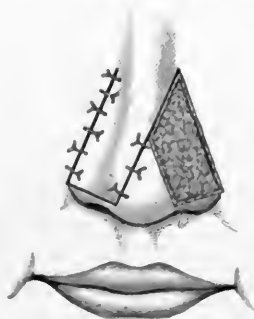


FIG. 724.—Langenbeck's method.

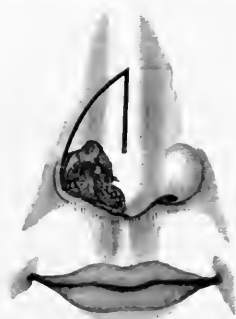

FIG. 725.—Denonvillier's method.

tended upward close to the root of the nose, thence obliquely downward and outward, terminating at the upper and outer angle of the defect. The lower part of the flap should contain a portion of cartilage, for obvious reasons.

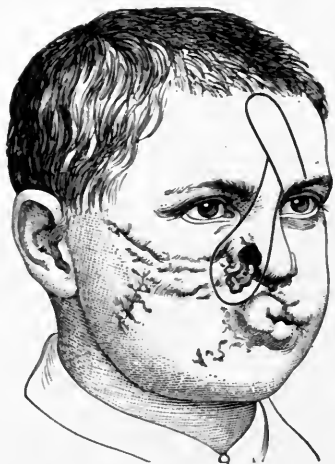


FIG. 726.—Buck's method.

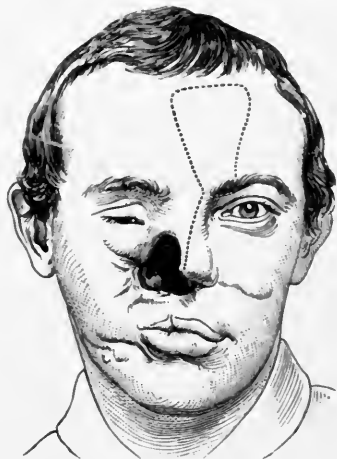

FIG. 727.—Buck's method.

After the edges of the defect are freshened, the flap is slid carefully into the gap and united there with horsehair sutures.

Weber cured a defective ala with a flap taken from the upper lip, the pedicle being continuous with the columna. The flap was oval, included a portion of the thickness of the lip only, and was slid into the gap and united with its freshened borders by horsehair sutures. At the end of four weeks the pedicle was divided and turned upward to improve the symmetry of the nose. If either ala be absent, and the resulting gap be large, the material for its repair can be taken from the forehead, as will be understood by consulting Figs. 726 and 727. It will be seen that the pedicles are admirably located to receive ample nourishment. The loss of the end of the nose may be repaired also from the tissue of the upper lip or the cheek.

If the columna be absent, it may be replaced by structures taken from the upper lip (Fig. 728). In this operation it is better to include the whole thickness of the lip (*b c, b' c'*), tipping the flap directly upward into place, than to make an integumentary flap the adjustment of which will require a sharp twisting of the pedicle. In the former instance the cuticle is dissected off and the raw surface carried directly into its position. The mucous surface of the flap soon assumes integumentary characteristics. If the lip be deficient, a flap can be taken instead from beneath either ala or from the dorsum of the nose (*a*) (Heuter) and carried into place.

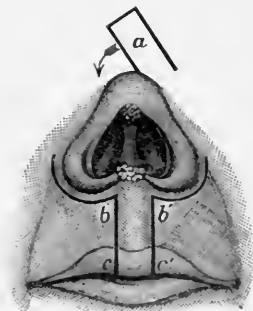


FIG. 728.—Repair of columna.

Loss of the Bony or Cartilaginous Septum, with or without Loss of the Nasal Bones.—The loss of the cartilaginous portion of the septum, the other tissues remaining intact, causes a flattening at the end of the nose or a depression at the lower end of the nasal bones. The operation of sliding the tissues may temporarily relieve the deformity, but subsequent retraction of the tissues is apt soon to reproduce it.

If the nasal bones be intact, the loss of the bony septum is not manifested by any external deviation of the organ. If the septum and nasal bones be gone, it then becomes necessary, in order to relieve the deformity, to elevate and maintain in position the tissues composing the soft parts of the nose. To accomplish this purpose it requires an internal support of some sort, although much may be gained by dissecting up the soft parts at each side of the nose and raising them in the line of the bridge, by approximating their bases by means of pins passed through, and then confining them in position until union of the flaps takes place.

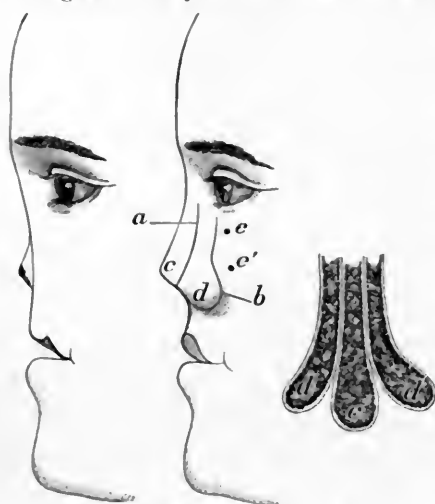


FIG. 729.—Dieffenbach's method.

Dieffenbach's Method.—In 1829 Dieffenbach published a method of operation by which he overcame the deformity resulting from the loss of the nasal bones and the septum (Fig 729). An incision was made with a narrow-bladed knife along the outer side of the sunken border of each nostril (*a*), the intervening strip (*c*) being three times broader at its connection with the upper lip than where it joined the forehead above. At the outer side of each of these incisions another (*d*) was made down to the bone, which began a few lines below, and to the outer side of the upper extremity of the first, and was carried obliquely downward,

parallel with the primary one and external to the side of the nose, around into the nostril, thereby separating the ala. The columna was elongated by short, parallel incisions in the upper lip, and the cheeks were dissected up from their bony attachments, through the lateral cuts, sufficiently to render them freely movable. The flaps (*c d d'*) were then raised, and their lower borders having been pared obliquely, were reunited, fastened with pins and sutures, and retained in position by drawing the detached portions of the cheeks toward the median line of the nose, in which position they were fixed by two long pins passed through their borders (*e e'*) under the nose. The pins were passed through two narrow strips of leather, which equalized the force and prevented the production, by the pins, of premature ulceration. A quill surrounded by oiled lint was then introduced into each nostril with the idea of holding the nostrils open without irritation during healing.

Superimposed superficial flaps were successfully employed by *Verneuil*. In this case the alæ and tip of the nose were uninjured, but were tipped upward and the bridge of the nose was flattened.

The Operation.—Make an incision in the median line of the nose, down upon the hard structures from the root of the organ to a little below the upper border of the cartilage (Fig. 730, *a*). Make a transverse incision across the upper and lower ends of the vertical one (the upper ones being downward and outward) down to the bone; raise two lateral flaps composed of the soft parts and periosteum if possible, also any fragment of a nasal bone that is present (Fig. 730, *b*); separate the cartilaginous portions of

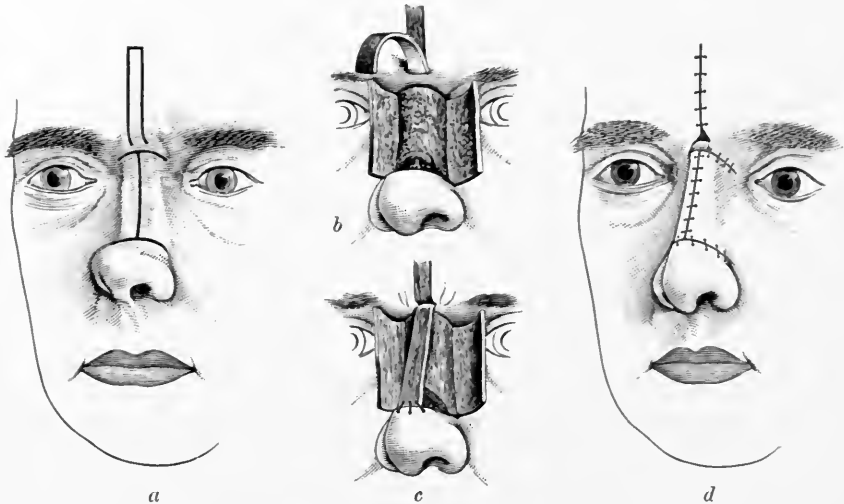


FIG. 730.—Verneuil's method of operation.

- a.* The lines of incision for the flaps. *b.* The flaps reflected, tip of nose freed and in position. *c.* The flap from forehead sutured in place. *d.* The lateral flaps united over forehead flap; gap at root of nose closed by sutures, later by stump of forehead flap.

the nose from the bony by a transverse incision opening into the nasal cavity, thence sufficiently through the cartilaginous septum to permit of the tip of the nose being properly adjusted. Raise a vertical flap from the forehead, of suitable length and about a quarter of an inch in width, composed of the soft parts and external table of bone, in the following manner: Make a vertical incision at either side of the median line of the forehead, about a quarter of an inch apart from a point half an inch above the root of the nose, upward to a distance ample to furnish a suitable bridge, with the tip of the organ properly adjusted (Fig. 730, *c*). Shave off the cuticle of the lower end of the flap, so as to correspond with the freshened surface on the dorsum of the nose, leaving untouched the cuticle corresponding to the opening into the nasal cavity. Cut through the external table corresponding to the vertical incisions with a thin sharp chisel, then introduce a chisel of about the width of the flap through the transverse incision at the upper end and direct the instrument downward, so as to remove with the skin flap the external table of the frontal bone; break off the flap at the

lower end, turn it downward; push the tip of the nose into place and adjust the flap to the nose and tip so as to hold the latter in proper position; stitch the extremity of the reflexed flap to the freshened cartilaginous border (Fig. 730, *c*), adjusting its cutaneous surface so as to conform with the opening into the nose; liberate the lateral flaps freely in order to permit of their being raised and united in the median line over the reflected flap; close the wound of the forehead with sutures, leaving the pedicle of the flap free from constriction for obvious reasons; divide the pedicle of the reflected flap after three weeks, and turn upward, and fit the remnant into the gap of the frontal wound (Fig. 730, *d*).

The Remarks.—The vertical flap ought not to contain hair follicles. The long portion of the reflected flap may become absorbed, followed by marked depression of the bridge. At the time of operation a piece of suitably shaped celluloid of sufficient length to hold the end of the nose properly adjusted may be covered in by the reflected flap. It is better, however, to introduce the supplementary agents—i. e., celluloid, paraffin, chicken bone, etc.—after sound healing has taken place, as then a better estimate can be made of the degree of deformity to be corrected, and the difficulties arising from infection are reduced to a minimum.

In this connection we are prompted to impress on the attention of the operator the great need of securing and preserving a substantial flap. Care in handling and in subsequent protection from extremes of all kinds are highly requisite. At the best, more or less disappointment on the part of the patient is probable, and it ought always to be tempered by a discreet prognosis.

The Indian Method (Fig. 731).—The Indian method was at one time the prevailing method of operation when the septum and a large portion of the

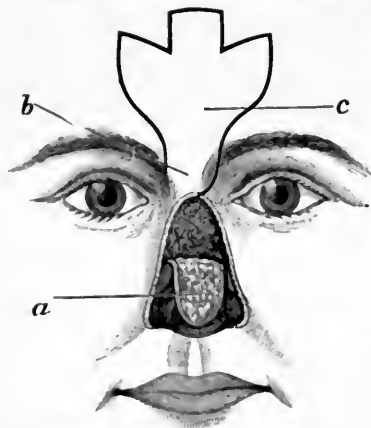


FIG. 731.—The Indian method.

soft parts of the nose were absent, and was employed even when the lower extremities of the nasal bones had sustained a loss. The tendency to atrophy and sliding down of the flap after union had taken place, accompanied by closure of the nostrils and danger to the life of the patient from the operation, bid fair for a time to cause the substitution for it of more satisfactory measures. However, modern modifications have placed it again in the list of wise operative procedures. Before active measures are begun, a false nose, conforming to the cosmetic requirements of the face, should be fashioned from gutta-percha, plaster, or other suitable material,

and placed in position. Then the superficies of the artificial appliance should be carefully estimated by measurement, and a pattern corresponding to the same, including the ala, columnna, etc., should be formed of some flexible though inelastic substance. This pattern is an exact measure of

the prepared flap plus an increase in size of one third in all directions, to provide for subsequent shrinkage.

The Operation.—Freshen the borders of the defect thoroughly and evenly; reflect downward a small quadrilateral-shaped flap from the skin at the root of the nose (*a*) when possible, leaving the base attached and the raw surface uppermost. This flap adds to the compactness of the nose and serves also to anchor the main flap more firmly in position, thus preventing the downward sliding that formerly characterized this plan of procedure. Place the pattern of the large flap obliquely on the forehead and mark its outline with the pedicle located at one side of the root of the nose (*c*). The pedicle (*b*) should be about half an inch in width and include the supratrochlear artery of the side on which it is situated. The integument corresponding to the side opposite to the proposed pedicle should be divided in a curved direction down to the freshened gap, thus laying off one side of the pedicle, which is permitted thereby to be more readily and safely turned when the flap is placed in proper position. The flap is now made by dividing the tissues freely down to the periosteum, in the course of the indicating line, the bleeding being controlled by sponge and digital pressure. Serre-fine clamps (Fig. 103) are admirable for the arrest of hæmorrhage at the borders of the wound at this time. The flap is raised—leaving the periosteum behind—turned, and placed in the required position, and the borders carefully united with those of the freshened gap with sparsely placed and carefully tied sutures of horsehair or silkworm gut. The alæ and columna are then secured in a similar manner. The columna may be formed either by inserting the elongation connected with the flap into a slit made at the upper border of the median portion of the lip, or, if this be not present, by turning upward a narrow strip from the upper lip and fastening it in position. The nostrils are supported and the formation of the nasal

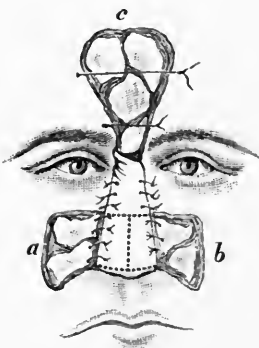


FIG. 732.—Thiersch's rhinoplasty.

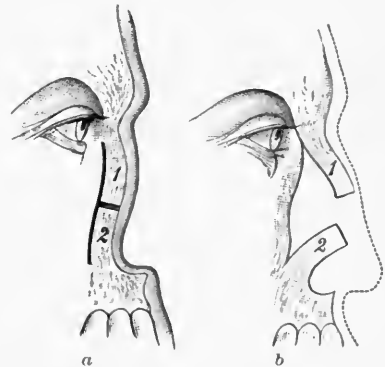


FIG. 733.—Formation of a bony framework for the nose. (Langenbeck and Ollier.)

openings assured by the introduction of pieces of suitable sized drainage tubes (Fig. 721) or quills covered with iodoform gauze, for a considerable length of time. The wound of the forehead is closed as best it may be by harelip pins or sutures properly placed. The unclosed part can be treated

at once by skin grafting, or be allowed to heal by granulation. A light antiseptic covering held loosely in place completes the primary dressing.

The after-treatment is controlled entirely by subsequent requirements of the cases. Whatever operative steps are essential to secure usefulness and symmetry of the organ are employed as the indications arise.

Various mechanical expedients are employed to prevent depression and flattening of the amended organ, such as gold and platinum bridges, levers,

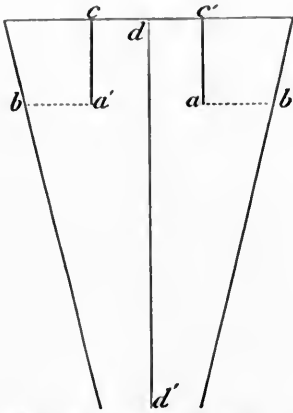


FIG. 734.—The triangular flap. $c a'$, $a' c'$. Short vertical incisions. $a b'$, $b a'$. Lines of bending. $d d'$. Median line. d . Columnna.

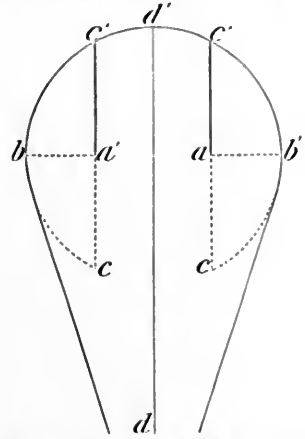


FIG. 735.—Dieffenbach's flap. $d d'$. Median line. $c' a'$, $c' a$. Short vertical incisions. $b a' c$, $b' a c$. Lines of bending.

etc. However, it is quite rare that they afford a degree of satisfaction that is at all commensurate with the annoyance which they cause. Vitalized support is often obtained through the agency of two small longitudinal skin flaps ($a b$) turned inward from the borders of the gap and placed with the raw surfaces outward, thus affording support to the main flap (c) (Fig. 732) (Thiersch). Pieces of bone taken from each side of the osseous aperture with a fine saw and raised upward so as to form a supporting arch for the soft parts was advised by *Langenbeck* (Fig. 733, 1, 2, a and b). The pedicle is divided usually at the end of the fourth week, and the attached portion is utilized to lessen disfigurement, if practicable.

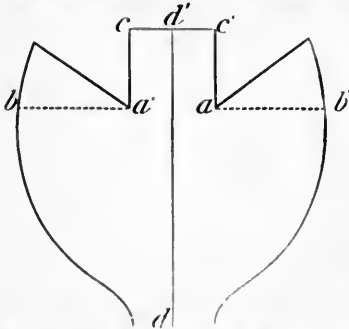


FIG. 736.—Langenbeck's flap. $d d'$. Median line. $a' c$, $c' a$. Columnna. $b a'$, $a b'$. Lines of bending.

The outlines in the main flap differ somewhat, four important varieties being recognized:

The outlines in the main flap differ somewhat, four important varieties being recognized:

1. The triangular form (Fig. 734). In this variety quadrilateral flaps are formed at either side of the base by short, vertical incisions ($c' a$, $c a'$). The middle part is utilized for the columna (d), and the lateral parts, when properly fashioned, and bent on lines $b a'$, $a b'$, form the alæ.

2. The pyriform flap of Dieffenbach (Fig. 735) differs only in shape from the preceding. The vertical incisions ($c' a$, $c' a'$) are cut as before, and the resulting flaps are utilized by bending for similar purposes.

3. Langenbeck's flap (Fig. 736) is shaped something like the ace of spades. The central segment ($c a'$, $c' a$) forms the columna and the lateral ones ($a b'$ and $b a'$) the alæ.

4. *Keegan's Operation.*—Surgeon-major Keegan has devised and carried into effect on repeated occasions and with eminent success, an ingenious reparative measure for nasal deformity deeply involving the end of the nose.

The Operation.—From points slightly external to the alæ nasi carry upward two converging incisions to points at either side of the bridge of the nose about three quarters of an inch apart, corresponding to the place at which spectacles are commonly adjusted ($a c$, $f h$) (Fig. 737, *b*). Connect these points by a transverse incision ($a f$); bisect the transverse one with a perpendicular incision ($b d$) carried downward along the bridge of the nose to nearly the free borders of the nasal bones; dissect these flaps ($a b c d$, $e f g h$) downward almost to the free margin of the bones, which part is left

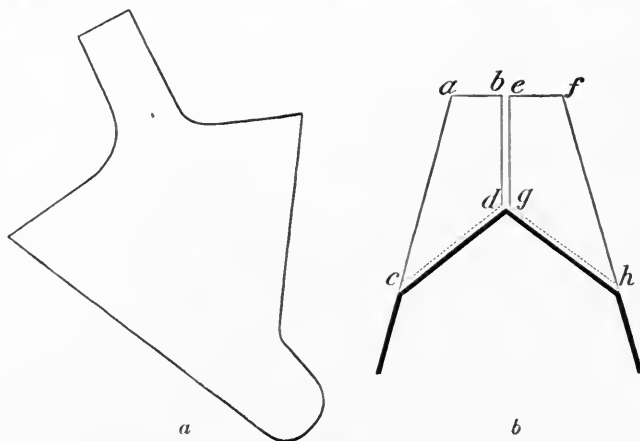


FIG. 737.—Keegan's operation.

undisturbed. An obliquely placed flap of proper size and corresponding to the one depicted in the cut (Fig. 737, *a*), with the pedicle at the inner angle of the eye, is now raised from the forehead. The nasal flaps already described are turned downward at the bases ($c d$ and $g h$) and properly fitted by the cutting off of the overlapping portions, thus leaving their raw surfaces uppermost. The main flap (*a*) is now turned downward and placed in position. The free margins of the frontal and nasal flaps are united with horsehair sutures, the columnar segment is properly joined below, and the lateral nasal incisions are suitably fitted to accurately meet the main flap, to which they are joined carefully with horsehair sutures. The wound of the forehead, the newly formed nostrils, and the final dressings are managed in all substantial respects as in the preceding instance. The pedicle is divided at the end of two weeks. The tendency of the flap to slide downward has been combated in various ways—such as connecting the pedicle

with a longitudinal incision at the side of the nose, the attachment of its whole length to a newly formed raw surface at its base, and grafting the sharpened pedicle into the integument at its base.

In these operations, after the columna and alæ are fashioned and sutured in place, the end of the nose presents from below a quite natural appearance (Fig. 738).

The Italian Method.—The Italian method, although an old one, has many virtues, and, were it not for the great difficulty of keeping the parts in position, would be much more employed than now. The flap is taken from over the biceps, with its apex toward the shoulder. It is first dissected up, and its extremities allowed to remain attached until suppuration is established, when the proximal end is separated and the dressing continued until the flap is well shrunken and the under surface cicatrized. It is then applied to the gap after the borders have been freshened (Fig. 711). When union is completed the pedicle is cut, and the flap is fashioned so as to relieve the deformity in the best possible manner.

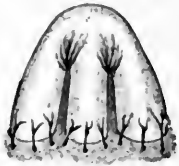

FIG. 738.—View of the new nose from below after being sutured into the defect.

The tedious associations of this operation do not commend its employment except in those cases in which the necessary material for repair can not be suitably secured by other methods. The cosmetic qualities of the integument of the arm are not as well suited to the repair of facial deformities as are those of the integument of the face itself. However, the facial disfigurement incident to transplantation of integument in the former instances is avoided by this latter procedure, a fact, that will largely compensate for its irksomeness. One who contemplates the performance of this method should consult the experience of Sir William MacCormac, as set forth in the Transactions of the Clinical Society for 1887, vol. xli, p. 181.

Osteoplastic Rhinoplasty.—The periosteum has been removed frequently from a part of the frontal bone in connection with the flap, and consigned to the gap with the hope that the formation of new bone might occur, so as to give solidity as well as prominence to the new nose. The removal of the periosteum from the frontal bone is not by any means devoid of danger. Osteomyelitis has arisen therefrom, followed by pyæmia and death. The periosteum may be used to form a portion of the flap first applied in the double-flap method illustrated in Fig. 730. It is true that the relation of its surfaces will be reversed, but this can not change its bone-producing value; moreover, if bone be formed, it can be easily shaped by manipulation to suit the proposed outline of the organ.

Ollier's Method.—An operation was performed some time since by Ollier for a deformity caused by the loss of the alæ, columna, cartilage, lobe, and a portion of the septum, due to lupus. The nose was not more than an inch long, due to the arrest of development of the ossa nasi, to which was attached a strip of cartilage. The integument of the lip and cheeks had been involved, and could not therefore be depended upon for flaps.

Ollier commenced two diverging incisions in the median line of the

forehead two inches above the eyebrows, and carried them downward to a fourth of an inch from the outer sides of the nasal orifices (Fig. 739). The upper portion of the triangular flap included the corresponding portion of periosteum down to the upper ends of the nasal bones. The dissection was continued along the right nasal bone, omitting the periosteum, down to its lower end, from which the cartilage was separated, though remaining attached to the flap. The left nasal bone was separated from its bony connections with a chisel, leaving it attached to the flap by its anterior surface; the cartilaginous septum was then divided from before backward and downward with scissors, and left attached by its base to the cutaneous cartilage, that a central support might be provided for the new structure. The whole flap was then drawn downward until the upper border of the loosened nasal bone (left) came opposite to the lower border of the right one, when they



FIG. 739.—Ollier's method.

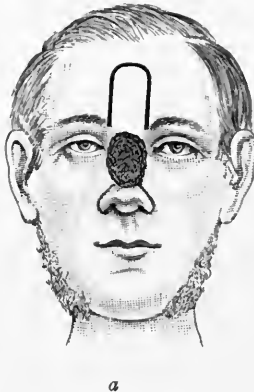

FIG. 740.—König's method.

were fastened together with a metallic suture. The sides of the flap were then united to the cheek and the frontal incision closed above its apex.

In this case, the space remaining after the removal of the left nasal bone was filled by bone developed from the periosteum that had been slid down from the forehead.

König's method (Fig. 740) of treatment consists in separating the cartilaginous from the bony portions of the nose by a transverse incision, and turning the end downward sufficiently to remedy the outline of the defect, then filling in the gap by an osteoplastic flap taken from the forehead and placed with the bony surface upward. A second flap is then raised from the forehead and turned downward on the former with the cuticular surface upward, thus bringing the raw surfaces in contact with each other. Each flap is united separately with the borders of the gap. After firm union is established, the pedicles are cut and the part is so fashioned as to make an acceptably formed member.

Israel modified this operation by closing the wound in the forehead at once and permitting the bone flap to granulate and heal by cicatrization, when the contraction following healing so drew forward the skin of the under surface of the bone flap as to cover two thirds of the circumference

of the upper surface of the newly formed dorsum. Quadrilateral-shaped flaps were then dissected from the outer surfaces of the deformed nose, also from the healed upper surface of the newly formed dorsum, and turned outward. The latter flaps, with the raw surfaces upward, supported, and were covered in by, the former, which were united at the median line with each other. If later the bridge of the frontal flap be severed, and the end inserted lower down, and the flap itself have only a ridge of bone at the center of its long axis, the remaining upper surface being periosteal, the cosmetic effect would be improved.

This variety of deformity has also been relieved by attaching a finger to the sides of the nasal chasm. The nail was first removed, and the palmar surface of the finger denuded, by the formation of lateral flaps, down to the distal third of the first phalanx. The finger was then fastened in position upon the freshened borders of the deformity by means of sutures passed through the lateral flaps, and, when union was sufficient to sustain the nutrition of the part, the finger was amputated at the juncture of the middle and distal thirds of the third surgical phalanx, and the distal end of the latter turned downward, to form the end of the nose and its columna.

The detail essential to the proper description of this operation, which was done with success by the late Prof. T. T. Sabine, is too extensive to be considered here. A full account of this very interesting case can be found in the April number of the *Illustrated Quarterly of Medicine and Surgery*, 1882.

Pancoast's Subcutaneous Method.—The subcutaneous method consists in the subcutaneous division of the depressed tissues, so that they are separated from their bony connections, as was done by Professor Pancoast in 1842. The operation can be best described in his own language:

“A long, narrow-bladed tenotomy knife was introduced on either side by a puncture through the skin over the edge of the nasal process of the upper maxillary bone. The knife was pushed up under the skin to the top of the nasal cavity, and then brought down, shaving the inner side of the bony wall so as to detach the adherent and inverted nose upon either side. The point of the nose could now be brought out. The nose still remained adherent to the top of the nasal chasm. The knife was a third time introduced under the skin, in a direction corresponding nearly to the long diameter of the orbit of the eyes, and the adhesions separated from the nasal spine and the internal angular processes of the os frontis. The soft parts and the cheeks were loosened, by sweeping the knife outward along the surface of the bone, so far as to divide the infra-orbital nerve and artery on each side down toward the median line, and held together with sutures passed through the cavity of the nose.”

The saddle-back and angular deformities of the nose are of not infrequent occurrence, and are either of acquired or congenital origin.

These defects can be rectified by König's method (Fig. 740), and by the use of various mechanical expedients. Martin's platinum support (Fig. 741), as employed by Weir and others, is representative of this class of mechanism.

The Operation.—A flap composed of the upper lip and of the nose, up to the transverse center of the nasal bones, is raised by free division of the mucous membrane at the gingival fold, and separation of the soft parts of the nose from the bony borders of the meatus with a small scalpel. A platinum support so constructed as to meet the cosmetic requirements is anchored in position beneath the flap by inserting the ends of the legs (*c b*) into small openings made into the bone at the outer borders of the meatus with a fine awl. The nasal flap is then properly adjusted to the support (*a*), the borders of the gingival fold are united with fine sutures, and moderate pressure is applied to the upper lip to secure prompt union. Within a week or so the post-operative irritation disappears, and the patient will be relieved of the deformity for a variable period without material personal discomfort.

The introduction beneath the integument at the seat of deformity of a *properly shaped piece of celluloid* is easy and comparatively satisfactory in the experience of the author. The incision is made in the median line of the nose down to the periosteum, the soft parts are turned aside sufficiently to permit of the introduction into the depression of a celluloid bridge so shaped as to remedy the defect. The flaps are closed with horsehair sutures and the patient kept quiet till union occurs.

Properly shaped pieces of gold, silver, platinum, rubber, etc., placed on the bridge of the nose, or supported by artificial septa, are occasionally employed as described.

The Comments.—The consideration of these expedients is introduced with the full knowledge of the fact that, as yet, but temporary success from their use can be assured. However, even this may be of great value in certain cases, and it is not impossible that the improved technique of extensive practice may greatly increase the benefits. The dangers attending these procedures when offset by aseptic precautions are of little moment. I can not refrain from expressing the belief that in many of the instances of non-traumatic, so-called nasal deformities, the outline of the nose is in accordance with the demands of the architecture of the face and therefore should not be condemned for contributing its share to the “best that can be done under the circumstances.” In such cases as these the morbid imaginings of the patient and the complaisant co-operation of the enterprising surgeon may make an agreeable face grotesque by the fashioning of an incongruous nose.

Paraffin injection for the purpose of correcting nasal deformities, especially saddle-nose, appears to be an established procedure. It ought to be realized at once that the practice is not as simple as it may seem at first.

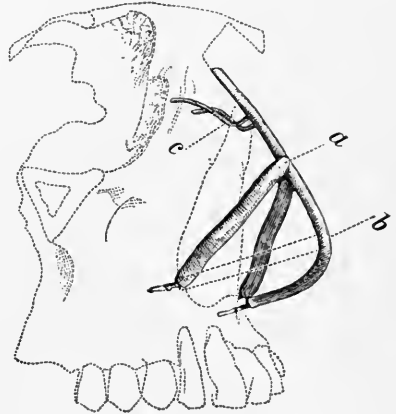


FIG. 741.—Martin's nasal support.

However, when properly conducted the outcome is in most instances highly satisfactory. In each case a thorough aseptic technique should be practiced in all respects. Both hard and soft paraffin are employed for the purpose, the latter certainly appearing to be the safer for reasons that will hereafter appear. The degree of the melting point of the paraffin used has much to do with the security of the procedure, 110° F. being the most trustworthy. A degree much higher than this exposes the patient to the dangers of pulmonary embolism, because of the diffusibility of the paraffin, and to impaired integrity of the skin because of the undue temperature. If lower than 110° F., its hardness may plug the needle, interfere with the proper molding, etc. The material suitable to melt at this degree (110° F.) can now be secured

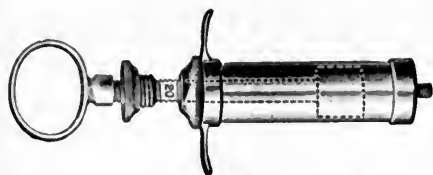


FIG. 742.—Smith's paraffin injection syringe.

in shops, for immediate use, in sealed sterile tubes. The injection can be made with the antitoxine syringe or with one designed for the purpose (Fig. 742), and in either case the needle should be stout, sharp, and with a sufficient lumen to permit the ingredients

to "emerge from the needle in a thread-like string," "easily molded and quite capable of forming an embolus" (Smith), when properly cooled.

The Operation.—Secure anæsthesia at the seat of prepared puncture with a drop or two of a two-per-cent solution of cocaine if required; intro-

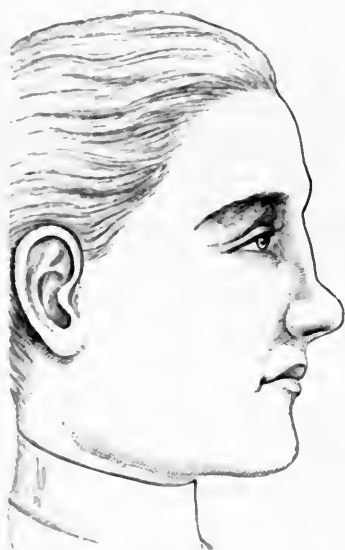

FIG. 743.—Deformity of nose.

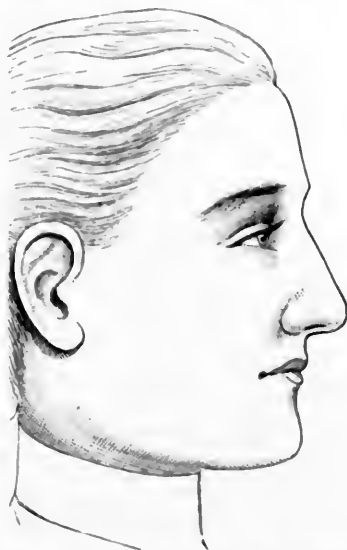


FIG. 744.—Deformity of nose rectified by paraffin injection.

duce the needle at the selected point into the subcutaneous tissue just beneath the skin, slightly beyond the deformity (Fig. 743); begin the injection slowly, continuing it with frequent interruptions to permit the proper

molding of the drug, withdrawing the needle gradually as the injection proceeds; finally, when a sufficient amount is introduced, withdraw the needle entirely, closing the point of puncture with collodion. When proper molding is assured (Fig. 744), hasten the hardening by ice-water applications or by a mild use of the ether spray.

The Dangers.—With the exercise of care in the preparation, introduction, and control of the agent little fear of unfavorable outcome need be felt; but indifference, carelessness, or ignorance in the use may be followed by either toxic absorption, excessive inflammatory action, loss of tissue from infection, abscess and overheating of the drug, pressure necrosis, air or paraffin embolism, deformity from too little or too great amount of the injection and from its going astray; its absorption, its interference with muscular action of the ala, and the effects of an improper melting point.

The Remarks.—The proper temperature can be secured by dropping the loaded syringe into water of the requisite warmth, remembering that the needle cools sooner than the barrel of the instrument. Special syringes kept at suitable temperature by electricity or hot water are devised; also syringes are covered with gutta percha for a similar reason. If the needle only be dipped in hot water for a few seconds before use, hardening of the drug *en route* will be obviated. If the fingers be pressed along the ridge of the nose to limit the spread, no danger of invading the ala or orbital region will occur. If blood can be drawn into the needle after injecting cocaine, the paraffin should not be introduced at that situation.

The Results.—Paget * reports forty-three cases done for deformed noses with no accident, and a great majority with a satisfactory outcome.

The deformity of twisted nose (Fig. 744 *a*) is corrected (Fig. 744 *b*) by cutting upward subcutaneously with a fine sharp thin chisel and

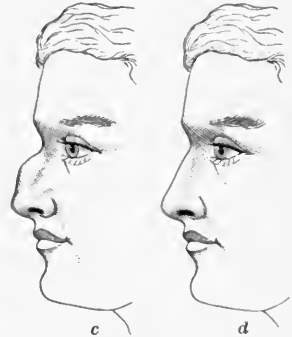

FIG. 744 *c*.—An angular nasal deformity.

FIG. 744 *d*.—The deformity corrected.

FIG. 744 *a*.—A twisted nasal deformity.

FIG. 744 *b*.—The twisted nasal deformity corrected.

mallet the bony connections between the nasal bones at either side and the nasal process of the superior maxilla and adjusting the parts.

The angular nose can be made shapely often by the removal of the super-

* Lancet, May 16, 1903.

abundant tissue at the seat of deformity with a sharp chisel or knife (Figs. 744 *c* and *d*). The incision for this purpose is located in the median line of the deformity, and is of proper dimensions to permit exposure of the enlargement without undue injury of the contiguous soft parts. After removal, the incision is closed in the usual manner.

Disfigurement of the nose dependent on morbid growths frequently requires treatment. So long as the bony and cartilaginous framework of the nose remains intact, the removal of the disfigurement and the grafting of the raw surface resulting therefrom can, in the great majority of cases, be carried to a satisfactory issue, as in the following case:

This patient came under the observation of the writer while suffering from a large and highly vascular angioma involving nearly all of the superficial structures of the nose and the columna (Fig. 745). The growth began in infancy as a "mother's mark" and had increased rapidly in size during the last three or four years. Repeated severe hæmorrhages had occurred from an ulcerating point on the surface, which greatly weakened the patient. The following plan of treatment was carried into effect. The circulation was controlled at either side of the nose by long-bladed forceps so applied as to compress the upper lip and cheek; that of the frontal vessels was controlled by direct external pressure. The growth was split in the median line down to the bony and cartilaginous framework the entire length with a scalpel, and the respective halves were turned aside with a blunt instrument carried along the bony and cartilaginous tissues to the outer limits of the growth, where they were ligatured with the cobbler's stitch and cut away with cautery. The *alæ* were not involved sufficiently to require removal. After the cutting away of the ligatures the granulating surface was covered with skin grafts, and quickly healed (Fig. 746). The remaining points of angiomatous structure were treated with galvano-puncture.

Harelip.—The deformity of harelip constitutes a large proportion of the congenital defects calling for operations upon the face.

The operations for its relief can be practiced at any age, but the best time is as soon after birth as the infant becomes sufficiently well educated to take its food and enabled to bear the loss of blood. If the infant be plump and robust operation can be practiced earlier than if weak and puny. The exceptions are rare when operation is not admissible at four months of age. *The complete control of the patient* during the operation is important.

For this purpose an anæsthetic should be given, chloroform being usually selected. The arms of the patient are placed at the sides and held in position by a napkin surrounding the body and pinned sufficiently tight to prevent their withdrawal, being careful, however, not to constrict the chest during anæsthesia. One assistant takes the child in his lap, another stands behind him and holds the infant's body. The head of the patient is held by the hands of the first assistant, so as to enable him to control the movements of the head, and likewise the circulation in the facial arteries with the fingers, and at the same time to bend the head forward, that blood may escape from the mouth. He can, if necessary, also administer the anæsthetic with a small sponge held between the index fingers. The success of the operation will depend in a very large degree upon the entire absence of tension of the parts when placed in position. To prevent tension, it is often necessary to separate the lip and cheeks to a considerable extent from their bony con-

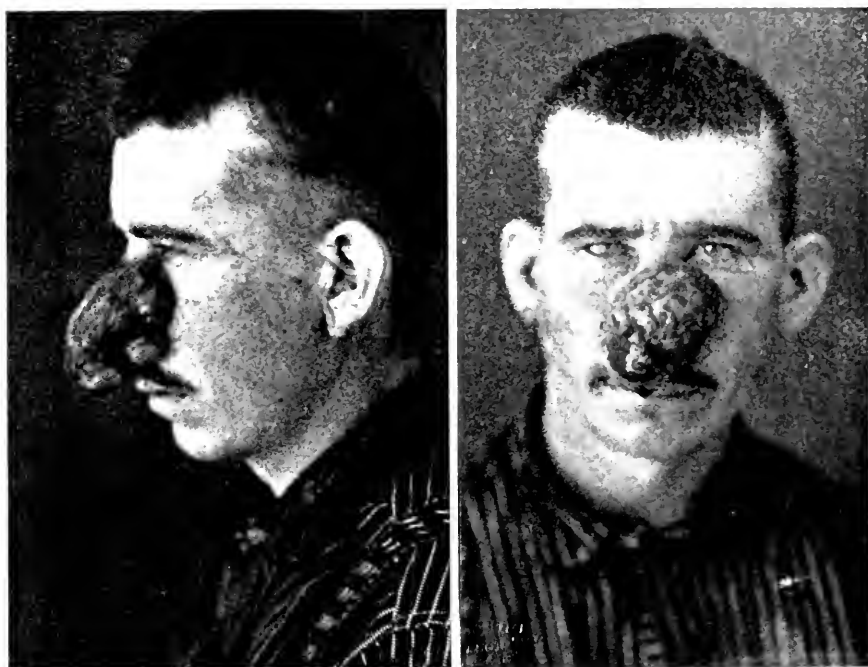


FIG. 745.—Before operation ($\frac{1}{8}$ size).

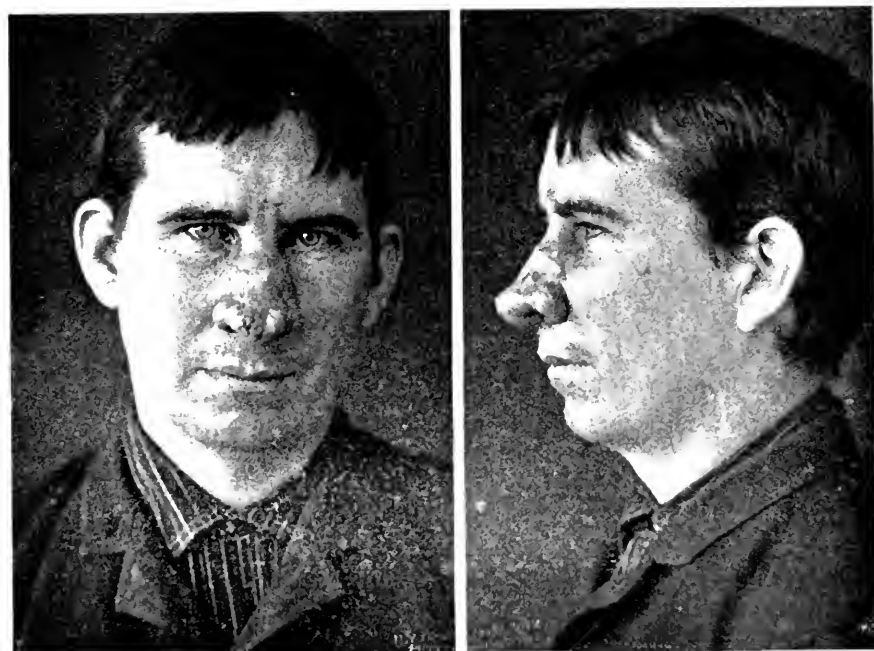


FIG. 746.—After operation ($\frac{1}{8}$ size).

nections. In some instances, owing to the difficulties of the case, the loss of blood will be considerable, unless every precaution be taken. The coronary vessels usually supply the bleeding points, but they can be easily controlled by grasping the lip at both sides of the incision between the thumbs and fingers. By this procedure, the same force that puts the part upon the stretch also checks the flow of blood. As the fingers of the assistant often hinder the operator, especially if the cleft be large, their action can readily be supplemented by passing through the lip, at each side of the proposed cut, a strong silk ligature, which, when looped, makes it possible to keep the parts on the stretch without inconvenience, and which can be so placed that when made tense the coronary vessels will be compressed. Either Milne's artery compression forceps or Langenbeck's *serre-fines* (Fig. 103) will control the hemorrhage admirably if fixed at the angle of the mouth on each side. If the blades of the ordinary dressing forceps be sur-



FIG. 747.—Instruments employed in operation on harelip. *a.* Double-edged and blunt-pointed knives. *b.* Thumb- and mouse-toothed forceps. *c.* Sharp-pointed curved, and blunt-pointed straight scissors. *d.* Harelip pins (not frequently used now). *e.* Langenbeck's *serre-fines*. *f.* Forceps.

rounded by adhesive plaster and closed upon the lip by rubber bands passed around the handles, a useful substitute will be had for the instruments just mentioned (Fig. 747). The borders may be pared with a sharp-pointed scalpel, strong scissors, or the triangular cataract knife; the latter is very useful for this purpose. It is not permissible to sacrifice certain of the parings taken from the free borders of the cleft, except in cases with but little deformity; they therefore should remain attached and be utilized in filling in the gap, this being the only satisfactory manner of avoiding the occurrence of the objectionable notch often seen after operations for harelip. The pins and sutures should perforate the flaps at least a third or fourth of an inch from the borders of the wound, and even farther, if there be any degree of tension. One or two of either will be sufficient in the majority of cases. Neither pins nor sutures are carried entirely through the flaps, but are passed near to their under surface. The sutures may be inserted nearer to

the edges of the wound than the pins, and in sufficient number to properly connect the lips. The pins are removed within two or three days, the sutures remain longer. If ulceration around the pins be threatened, they should be removed after others have been inserted at new points to receive any strain that may be present.

The operation for all forms of harelip can be divided properly into three steps.

The First Step.—In the first step the possibility of the occurrence of tension with union of the borders of the defect, is combated by freely separating the lip and perhaps also the cheek backward and upward from the bone at either side with scissors or scalpel. A restraining ala should be separated from its bony connections in a similar manner. Unusual bony projection should be remedied by instrumental or manual force at this time.

The Second Step.—The second step consists in making the borders of the cleft tense with mouse-tooth forceps and cutting them of equal thickness with a small, sharp-pointed scalpel, or with scissors, in accordance with the plan of the operation. When possible, the preparatory cutting should be planned so as to utilize the parings in the final closure, thus lessening tension and obviating a notched vermilion border. The performance of this step is attended with more or less hæmorrhage, which can be easily controlled by pressure at either side of the lip with the fingers, by Langenbeck's *serre-fines*, or properly adjusted traction sutures.

The Third Step.—The third step relates to the approximation of the divided borders. The borders are apposed by forward pressure directed from the cheeks by the assistant. A single, long harelip pin is then carried through the flaps at the center of the lip at considerable distance from the borders, and its influence supplemented with a figure-of-eight aseptic cotton-yarn suture applied moderately tight. The vermilion borders of the flaps are now carefully adjusted and united with silkworm-gut sutures; the upper border is similarly treated. The pin is then withdrawn and the intervening space suitably joined with similar sutures. Two or three sutures of fine catgut or silk are next applied to the vermilion border and mucous membrane. If tension be marked, the pin or needle employed in the primary adjustment of the borders can again be used, and its influence supplemented with the cotton-yarn suture, until danger of ulceration at the points of perforation is feared. If still further restraint be needed, the pin may be reapplied at a different site.

The wound is then dressed with iodoform or acetanilid and still further supported if necessary with adhesive strips which are applied far back on either cheek, drawn forward, crossed, and attached to the opposite sides simultaneously. If there be a cleft in the hard palate also, the application of iodoformized collodion to the surface of the wound will prevent the food and buccal discharges from soiling its borders. The wound is redressed at the end of the second or third day. The sutures are removed successively from the fifth day on, the lip being fortified by adhesive-plaster restraint over the site of removal if advisable. When union fails in part or entirely, the borders ought still to be held as nearly together as possible, during such

a degree of repair as may take place. An attempt to remedy a secondary defect of this sort by operation should not be made until some time has elapsed, in order that the borders shall again become well healed, and the condition of the patient improved. In all instances, carefully avoid closure of the nostrils unless the patient is able to breathe easily through the mouth when they are obstructed.

Single Harelip.—Single harelip can be treated by superficial or deep paring with direct union of the borders of the cleft either by the single- or

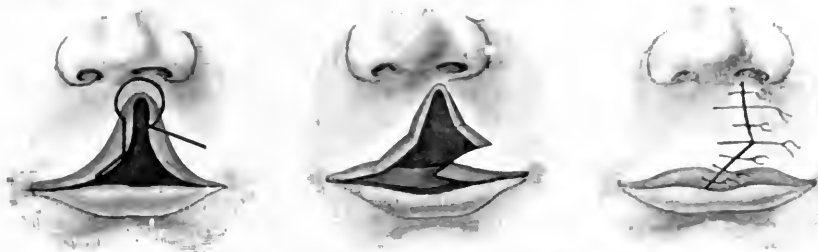


FIG. 748.—Mirault's method of freshening and suture.

double-flap methods. The simplest method consists in paring with a knife the borders of the cleft, loosening freely the labial connections to the bones, and bringing the edges directly into contact with each other. Unless the operation is carefully performed this method is often followed by a notch at the border of the lip where the flaps are joined.

The Single-flap Method (Mirault) (Fig. 748).—Draw down both borders of the cleft and freely sever their connections with the bone; pare the border of the longer portion, and make the flap from the shorter; turn down the flap, and approximate and unite the borders as before described.

The Double-flap Method (Malgaigne).—Pass a silk ligature through each angle of the fissure; divide the sublial connections; make one side



FIG. 749.—Malgaigne's method of freshening and suture.

tense; transfix it near the border of the fissure, and cut upward to and over the apex of the same; repeat the operation on the opposite side of the fissure; draw both flaps thus formed downward, bringing their cut surfaces in contact with each other (Fig. 749); close the cleft with a pin or suture passed near to the vermilion border, and with another above if necessary; unite the everted flaps by a fine silken thread or horsehair; cut off their extremities obliquely, leaving enough tissue to form a prominent projection

at the margin of the lip in order to obviate the formation of a notch. If the cleft be shallow the flaps should remain connected above and be turned downward and united as before.



FIG. 750.—Hagedorn's method of freshening and suture.

Hagedorn's Method (Fig. 750).—Loosen the lip and fix the borders of the cleft with traction sutures; make a curved incision on either side by transfixion from above downward along the outer limit of the convex mucó-



FIG. 751.—Simon's method.

cutaneous borders of the cleft to near the vermilion border of the lip, the incision in the major border of the cleft being slightly the longer; from near to the lower end of the shorter incision and from the lower end of the longer one, two short incisions are made, the one passing horizontally outward, and the other obliquely upward and outward. Short incisions are then made outward from the free borders of the cleft to the long ones.

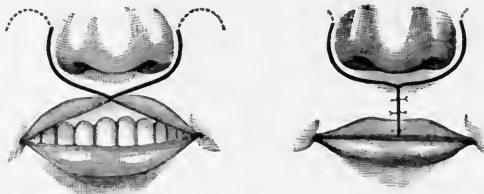


FIG. 752.—Dieffenbach's method, liberating incisions.

The upper extremities of the primary incisions are united by short transverse incisions, and the marginal tissue is removed. The borders are brought in contact and united with silk-worm gut.

Simon's Method (Fig. 751).—Simon made an L-shaped incision in the border opposite the median one, and a recumbent \leftarrow -shaped incision at the median border (A); the tissues were removed, the upper limits of the freshened borders were united first, and the remaining portions subsequently, in the usual manner.

Dieffenbach's Method.—In cases with wide and complete clefts, liberating incisions passing around the alæ (Fig. 752) and outward for a short distance into the cheeks, or made transversely directly below the nose, are of much service in securing ready and proper coaptation of the borders of the cleft. These incisions enable the surgeon to make more readily the needed detachment of the lip from the jaw.

König's Method.—König removes the borders of the cleft entirely, and then forms a flap at either side by means of incisions directed downward and outward from near the middle points of the vertical ones (Fig. 753).

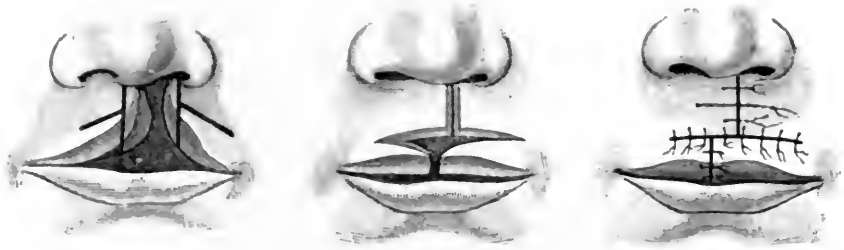

FIG. 753.—König's method of freshening and suture.

The incision at the outer side of the cleft is somewhat the longer. The flaps are tilted downward in sewing, thus obviating the liability of a notch in the vermilion border.

Giraldès's Method.—Giraldès's method is principally employed when the deformity extends into the nasal cavity, and the flaps are constructed so as to provide a floor to its entrance (Fig. 754). When the flap (1) is carried upward to repair the floor of the nostril, the angle of this flap is then brought in contact with the angle at the upper extremity of the



FIG. 754.—Giraldès's method of freshening and suture.

border (3), the cut surfaces thus brought into apposition being of a similar length (3, 4). The freshened border (5) then comes in contact with (2) the point of the flap resting upon the undermost cut, in which position the margins are united. The cuticular border of the end of the inner flap (1) is partially removed so that a freshened wedge of tissue is inserted at the horizontal incision of the flap. This is an admirable operation, and can be employed on all occasions where extensive deformity exists.

Double Harelip (Simple).—Pare the central portion (Fig. 755) on both sides; make lateral flaps with their attachments below at the outer borders (*a b*); liberate the labial connections, and approximate the raw surfaces by the aid of silkworm-gut sutures.

Complicated Harelip.—Harelip is often complicated by a fissure through the alveolar process, which sometimes extends to the hard palate, and even beyond, and through, the soft parts. For a time before the operation, it is

well for the parents or nurse to make gradual pressure upon the more prominent bony portion, combined with outward traction on the depressed side, endeavoring thereby to cause the alveolar arch to assume as nearly as possible a normal outline. A reasonable degree of patience in making these painless manipulations will, in time, effect a more satisfactory result than the application of sudden force by means of forceps. The practice of forcing the alveolar extremities into position, paring and wiring them, is pernicious, since to do so still further shortens the outline of the arch of the superior maxilla, and does not result in a bony union of the extremities. The gentle but constant traction exerted by the united lip will in time as certainly reduce the projecting bone to the proper place as the more vigorous measures.

It is better to allow the deformity of the hard parts to remain unmolested until the teeth appear, when the outline of the biting surface of the upper may be compared with that of the lower jaw, and made to meet it by rectifying the upper, and introducing, if necessary, additional teeth upon a plate to fill any gap in the biting surface. Giraldès's method (Fig. 754) offers the best means of closing the fissure in the lip in these cases.

The fissure may be double, and involve both the hard and soft parts, back to and through the soft palate. The intermaxillary bone in these cases may project freely, and even be adherent to the soft parts covering the end of the nose (Fig. 756). If such be the case, division of the vomer may be practiced, after which the projecting portion is forcibly pressed into position, and the soft parts are united, as in the simpler forms; except, perhaps, it may not be prudent to unite both sides simultaneously for fear of causing too great traction.

The Management of a Projecting Intermaxillary Bone.—Many plans to remedy an excessive projection of this bone have been devised. *Blandin* advised the free removal of a properly estimated triangular-shaped piece from the vomer (Fig. 757). But attendant hæmorrhage and failure of union caused many surgeons to advise rather its subperiosteal resection. The subperiosteal method is readily accomplished by raising the periosteum

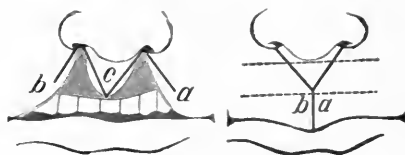

FIG. 755.—Double harelip.

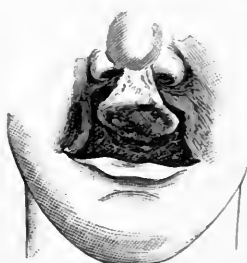

FIG. 756.—Complicated harelip.

and superimposed mucous membrane simultaneously with a delicate periosteotome through incisions made along either side of the edge of the vomer. After a proper extent of denudation, the elevated tissues are

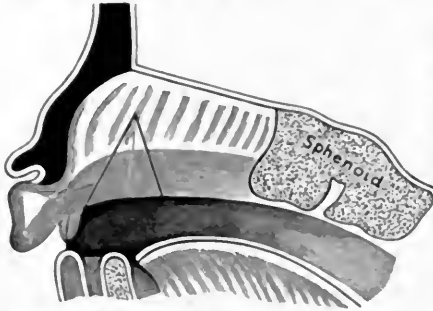


FIG. 757.—Projecting intermaxillary bone. Blandin's operation, triangular incision. Rose's operation, dotted line.

drawn aside by retractors, and the triangular section is made with strong scissors; the projecting portion is forced into place, and the soft parts are properly retained by suitably arranged intra-nasal and supra-labial restraint. *Rose* advised that a single vertical incision be made through the bone after denudation.

When the protruding portion is connected to the nose, it should be separated with care or the columna will be impaired.

Bardleben divided the bone after denudation for about three quarters of an inch and then reduced the deformity with but trivial bleeding. The reduction of the deformity then causes an overlapping of the borders of the vomer, which is followed by union of the apposed surfaces.

The Operation for Double Harelip (Complicated).—After proper reduction of the intermaxillary bone, the central strip of integument is pared at the margins so as to form a quadrilateral-shaped flap. After this is accomplished the outer borders of the cleft are pared, the lower portions of which are provided with flaps similar to those in *Malgaigne's* operation. The borders of the upper portions are removed entirely. The attached flaps are turned downward, trimmed, and properly united with each other, coincident with the proper adjustment of the remaining corresponding borders of the wound (Fig. 758). The author in two cases of this character has



FIG. 758.—Operation for double harelip.

turned outward the parings of the vertical borders of the central segment, and inserted the distal ends respectively into transverse incisions made one beneath either ala, as in *Giraldès's* method. This plan provides a good floor to the entrance of the nostrils.

Hagedorn's Method (Fig. 759).—*Hagedorn's* method, although not so simple as the preceding one, requires no special description to explain it. The teatlike projection at the median line of the upper lip is longer than necessary.

Owen's Method.—In this operation the prolabium and the incisive bone are removed and thick flaps are cut as follows: On the right the incision *c d e* (Fig. 760, *a*) is made and the fragments removed. On the

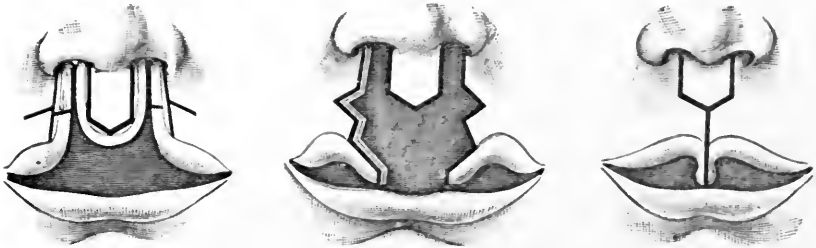


FIG. 759.—Hagedorn's operation for double harelip.

left the incision *f b* is made and the respective borders united so as to bring *a* to *e* (Fig. 761), *b* to *d* and *f* to *c*, when the sutures are introduced and tied.

The After-treatment.—In such cases as these care must be taken not to obstruct the nasal openings, hence cumbersome dressings should be avoided, and the wound treated with iodoformized collodion supplemented with a scanty gauze covering. The mouth and the nostrils, especially the latter, should be kept well cleansed and free from all discharges, food, etc. In other respects the treatment is similar to that of the preceding cases.

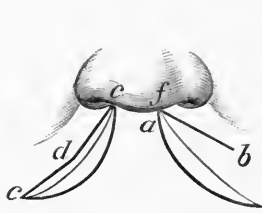


FIG. 760.—Owen's operation. Making flaps.

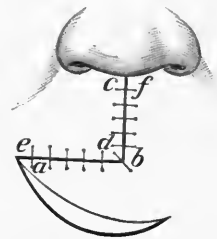


FIG. 761.—Owen's operation. Flaps united.

The Results.—The rate of mortality depends on the severity of the operation, age, condition, and environment of the patient, etc. About five per cent die in the first two weeks after operation, and about forty to fifty per cent during the first year. However, the operation can not alone be blamed for this high rate.

Cheiloplasty is an operation directed to the cure of deformities of the lips dependent on disease or congenital defects. The general technique of cheiloplasty differs but little from that of harelip. The former operation is addressed mainly to the defects of adults and those amenable to discipline. Therefore, the requirements of cleanliness are better observed, and the final results are correspondingly improved.

Deformity of Lower Lip. *The V Incision.*—The V incision is employed for the removal of epitheliomata or other morbid growths that do not require the elimination of more than one third of the lip. The whole thickness of the lip is divided, the length of the arms of the V being increased proportionately to the width of its base. The usual liberating incisions may

be required. The cut surfaces are united by the same means, and cared for in the same manner, as in operations for harelip (Fig. 762).

Grant's Method.—This incision can be employed in place of the V-shaped incision, especially when the gap following the latter is too wide

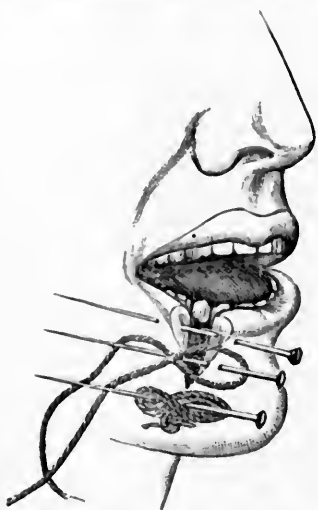


FIG. 762.—V incision; union with harelip pins.

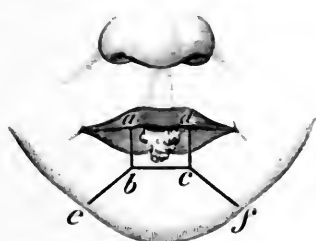


FIG. 763.—Grant's operation. Flap formed.

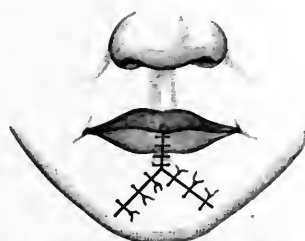


FIG. 764.—Grant's operation. Flap united.

for the purposes of ready adjustment with satisfactory cosmetic effect; also the oblique incisions *b e* and *c f* (Fig. 763) can be extended beneath the chin, affording opportunity to remove diseased lymphatics (Fig. 763).

Blasius's Method.—In this method the growth involves more or less of the lower lip. After removal of the growth, the semilunar incisions (Fig. 765) are made, their length being regulated by the freedom of the subsequent adjustment of the flaps. If the morbid process will permit (Fig. 765), sufficient mucous membrane may be saved or separated and transferred

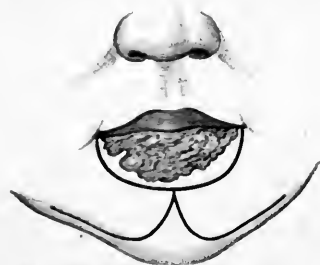

FIG. 765.—Blasius's method for removal of lower lip.

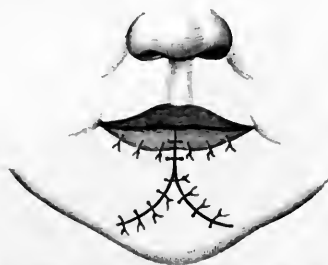

FIG. 766.—Blasius's method for removal of lower lip. Flaps united.

by sliding from the inner surface so as to cover the oral margin, thus providing a suitable vermilion border when sutured to the integumentary edge.

The Horizontal Incision.—When the morbid process does not involve the free border of the lip, it can be removed by an oval incision horizontally

situated, and the gap closed in the usual manner (Fig. 767). If the space be too large to admit of closure, it can be left to heal by granulation, or be remedied by the sliding process, either with or without parallel or transverse incisions.



FIG. 767.—A method of removal of superficial epithelioma of lip.

Celsus's Method.—When the morbid growth involves the whole or half of the lip, the broad-based V incision is supplemented by transverse ones extending outward from each angle of the mouth a sufficient distance to admit the easy joining of the V borders after the tissues have been freely liberated from their bony attachments (Figs. 768 and 769). If difficulty be expe-



FIG. 768.—Celsus's method. Flap formed.

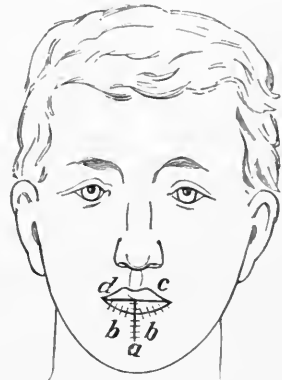

FIG. 769.—Celsus's method. Flap united.

rienced in sliding the flaps, it may be overcome by making short vertical incisions through the cheek at the outer extremities of the horizontal ones (*e, e*). The most ingenious feature of this method consists in dividing the buccal mucous membrane at least a fourth of an inch above the incision made through the cheek and parallel with it, so that when the outward cuts are completed, and the parts joined in the median line to form the lip, the raw border of the latter can be covered by turning the processes of mucous membrane over it, thereby forming an excellent vermilion border.

The angles of the mouth are also to be formed by stitching the membrane and buccal cuts to each other.

Estlander's Method.—Estlander's method is efficient when the loss of lip is partial, located at one side, and encroaches on the skin over the chin (Fig. 770). A triangular flap, having the coronary artery in the pedicle, is turned downward from the

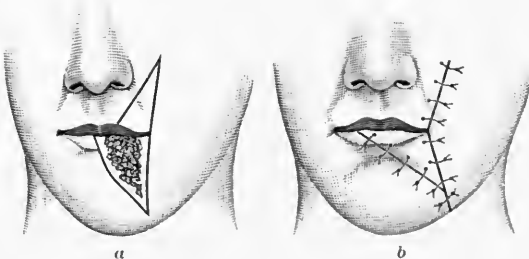


FIG. 770.—Partial cheiloplasty (Estlander).

side, and encroaches on the skin over the chin (Fig. 770). A triangular flap, having the coronary artery in the pedicle, is turned downward from the

cheek and fitted to the gap below prepared for its reception. This method provides a vermilion border and results in a prompt and satisfactory cure.

Langenbeck's Method (Circular).—Langenbeck's method is addressed to a defect limited to any part of the lower lip not exceeding half its length (Fig. 771), and involving the movable portion only. The incision passes along the inferior limit of the defect, and is extended outward at either side around the angles of the mouth and into the upper lip to a distance conforming to the width of the gap to be closed. The separated portions of the lip are loosened and so adjusted as to fill the gap when united by

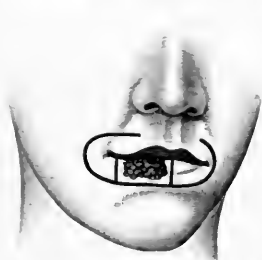
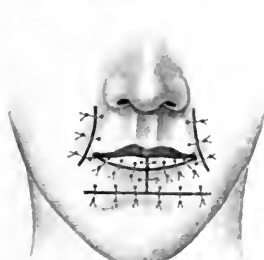


FIG. 771.—Cheiloplasty with displacement of the border of the lip (Langenbeck).

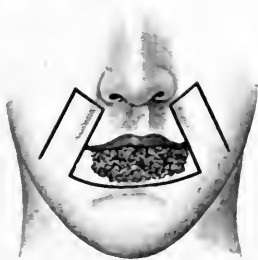

FIG. 772.—Cheiloplasty with the formation of two flaps from the cheeks (Bruns).



sutures below. The remaining portion of the gap is closed with sutures, always remembering to begin the suturing opposite the angles of the newly formed mouth, that the oval outline may be maintained.

Bruns's Method.—Bruns's method is applicable to the restoration of the entire lower lip (Fig. 772). After the gap is properly fashioned, two quadrilateral flaps, comprising the thickness of the cheek, are formed, one at either side of the mouth. These flaps are loosened and turn downward into the gap, to the borders of which they are carefully united with sutures. If the buccal mucous membrane be divided on a line a quarter of

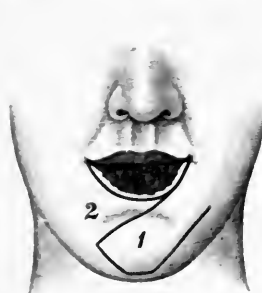

FIG. 773.—Cheiloplasty with the formation of a flap from the chin. After suture (Langenbeck).

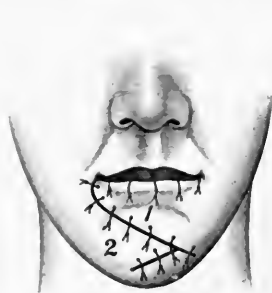


FIG. 774.—Cheiloplasty (Syme-Buchanan).

an inch or so posterior to the division of the cheek, a vermilion border may be formed by sewing the membrane to the integument after the flaps are properly placed and united. The resulting wounds of the cheeks are closed with sutures.

Langenbeck's Method.—Langenbeck devised this method to meet those cases in which the tissues of the chin only are available for use (Fig. 773). The flap may be made single or double, according to the demands of the case. In the single-flap method the oblique margin of the defect is made to correspond to the proximate part of the new lip. The oblique incision is then prolonged downward, and in other requisite directions, sufficiently to construct a flap of suitable dimensions to fill the gap. It will be noticed that minor disfigurement follows the union of the borders. It is an obvious fact, however, that it is impossible to construct a complete vermilion border in this instance.

The Syme-Buchanan Method.—This method is adapted to restoration of the lip when the loss of tissue is sustained mainly by the central part, and at the lower border. Two quadrilateral flaps are made at either side of the V-shaped incision employed for the removal of the defect, each corresponding to half the length of the lip, by carrying downward at either side an incision continuous with the border of the gap (Fig. 774). The width of the flaps should correspond after shrinkage to the width of the lip. The flaps are loosened, carried upward, and united at the median line, thus effecting the restoration.

Syme's Method.—In Syme's method the operation is performed by continuing the sides of the V-shaped incision (Fig. 774) downward and outward along the lower portion of the cheek in a curvilinear direction for about two inches, dissecting up the flaps in the usual manner, raising them up to form the lip, uniting them in the median line, and allowing the remaining portion to heal by granulation. The mucous membrane should be stitched to the integument to provide a suitable border. Buchanan's method differed from Syme's in making the extremities of the flaps straight. In other respects no radical difference between these methods exists.

Buck's Method.—Buck first removed the morbid growth by the V-shaped incision, and united the parts in the usual manner. After union had taken place, the short lower lip was overhung by the upper, giving to the patient a sucker-mouthed appearance (Fig. 775). The steps taken to relieve this deformity can best be described in Dr. Buck's own language: "In order to insure precision in making the requisite incisions, their course should first be designated by pins temporarily inserted erect in the skin at certain points, as shown by Fig. 776. The letters *a a* represent two pins inserted at one finger's breadth below the under-lip border, one at either side of the chin, a little to the outside of the angle of the mouth, and both equidistant from the median line; *b b* are also two pins inserted, one on either side, into the upper lip, at the margin of the vermilion border, both equidistant

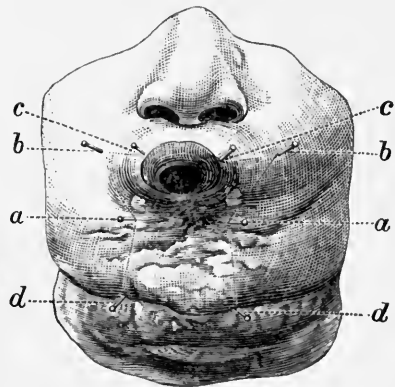


FIG. 775.—Operation for contracted lower lip.

from the median line and at such a distance apart as to include between them sufficient length of lip border with which to form a new upper lip. The steps of the operation are, then, the following: with the forefinger of the left hand placed on the inside of the mouth, the cheek is held moderately on the stretch, while with a sharp-pointed knife it is transected at the point *a*, as marked by the lower pin in the side of the chin. An incision is then

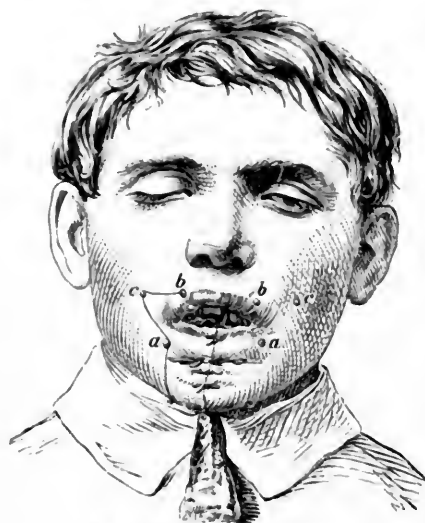

FIG. 776.—Buck's incision.

carried through the entire thickness of the cheek upward and a little outward, a distance of one inch and a half to a point *c*, near the middle of the cheek. The upper lip should next be transected at the point *b*, marked by a pin on the vermilion border, and the incision carried through the lip and cheek outward and a little upward to join the first incision at its terminus *c* in the middle of the cheek. A triangular patch, *b c a*, will thus be formed which will include the entire thickness of the cheek, with its apex free and disconnected while its base remains attached toward the mouth. The next step is to transfer the patch from the cheek to the side of the chin. For this purpose an incision should be made on the side of the chin from the

starting-point of the first incision *a*, vertically downward to the edge of the jaw and to the depth of the periosteum. The edges of this incision, retracting wide apart, afford a V-shaped space for the lodgment of the triangular patch, which is now to be brought around edgewise and adjusted by sutures in the new location. By this transfer, the portion of the upper-lip border that formed a part of the base of the patch is brought into a transverse line continuous with the lower lip, and forms an extension of it. The space upon the cheek, from which the triangular patch was taken, is closed by bringing its edges together and securing them by sutures. By this adjustment a new and naturally shaped angle is formed for the mouth at the point *b*, where the lip was transected in commencing the second incision of the cheek. The incisions must be made with the utmost precision, and special care taken that the mucous membrane is divided exactly to the same extent as the skin. The same procedure may be applied to the other side of the mouth and executed at the same operation."

Malgaigne's Method (Fig. 777).—In Malgaigne's method the growth is removed by means of one horizontal and two vertical incisions. The vertical incisions begin at the angles of the mouth, the horizontal one is located between the angles and below the disease. Two additional horizontal incisions are subsequently made on each side to permit the closure of the gap by the sliding method. The flaps are freely separated, brought forward, united in

the median line, and the mucous membrane of their upper borders is stitched to the integument. The mucous membrane can in this instance be taken with the cheek flap to form the vermillion border, as in Celsus's method.

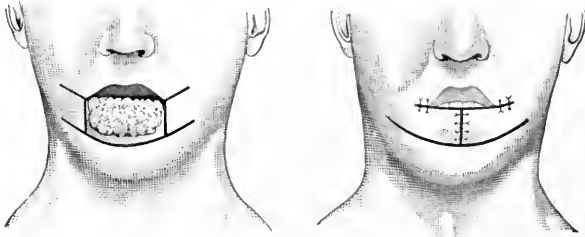


FIG. 777.—Malgaigne's method.

Sédillot's Method (Fig. 778).—The diseased portion is removed as in the preceding method, after which the vertical incisions are extended to the lower border of the jaw, then backward far enough to make flaps of sufficient

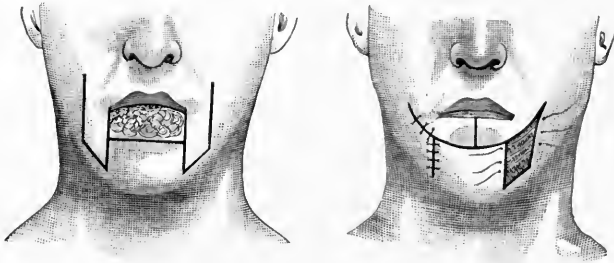


FIG. 778.—Sédillot's method.

width to fill the gap; thence directly upward to a point opposite the angle of the mouth. These flaps are dissected up and united in the median line by the usual means.

Dowd's Method.—This method exposes the submaxillary spaces for removal of diseased lymph nodes, also affords better adjustment of the flaps than does the preceding method.

The Operation.—Remove the primary growth as indicated (Fig. 779) half to three fourths of an inch from its margin; make then two deep diverging incisions, one at either side, and located so as to permit of exposition of the submaxillary contents; make two horizontal incisions, one at either side, each beginning at the angle of the mouth and extending backward two inches or more, as may be required, down to the buccal mucous membrane; expose upward from these incisions for a third of an inch the mucous membrane, dividing it at this the upper limit from before backward at either side, sufficiently to constitute ample tissue for a complete vermillion border of the new lip; remove carefully from each submaxillary space the lymph

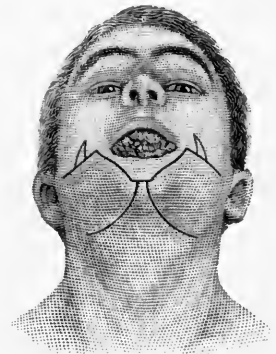


FIG. 779.—Dowd's method.

nodes whether enlarged or not; liberate, approximate and unite the flaps in the median line, without undue tension; stitch the flap of mucous membrane to the tegumentary border of the new lip, thus forming the vermilion covering; take away at each angle of the mouth the integumentary redundancy, by removing triangular wedges of skin, as shown in the illustration, closing the gaps with sutures; dress the wound lightly, and keep the dressing clean.

The Remarks.—As much undisturbed tissue as possible should be left on the prominence of the chin. The facial vessels are usually severed by the submaxillary incisions. The submaxillary salivary glands are seldom cancerous, except from contact with contiguous infected nodes.

Deformities of the Upper Lip.—If the deformity here be slight, it can be remedied by the simple means employed upon the lower lip.

Buck's Method—Intero-lateral Flap.—

Buck practiced this method to restore one half of the upper lip and the adjacent portion of the cheek (Fig. 780). He divided the under lip, where it joins the

cheek, by a vertical incision, *a b*, one inch in length, at right angles to its border. He made a second incision, *b c*, one inch and a half in length, beginning at the lower end of the first, *a b*, and running forward parallel with the border of the lower lip. An oblique incision, *c d*, about half an inch in length, was then made upward and forward from the end of the horizontal one, leaving the flap with a good attachment at the point of finishing. He pared the edges of the deformity and the adjoining end of the half lip above, and separated the latter from its bony attachments by free section of the underlying tissues directed upward toward the orbit. The under-lip flap was then tipped endwise, and its upper extremity connected by sutures with the freshened end of the half upper lip. The remaining space between the flap and cheek was closed by sutures.

Bruns, in order to utilize the healthy portion of the mucous membrane, reflected from the inner surface of a diseased lower lip in making a vermilion border for the newly constructed labrum, circumscribed the morbid growth (Fig. 780 *a*) by carrying inward beneath and below it from the angle of the mouth an incision which, meeting another including the lip at

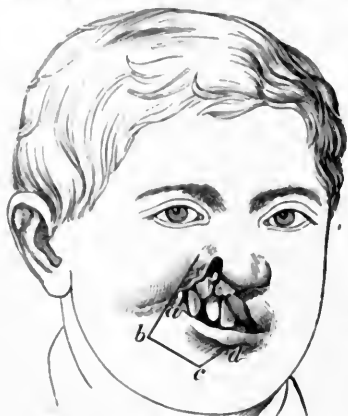

FIG. 780.—Buck's method.
Intero-lateral flap.

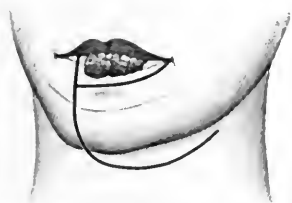

FIG. 780 a.—Bruns's method.
Vermilion border plan.

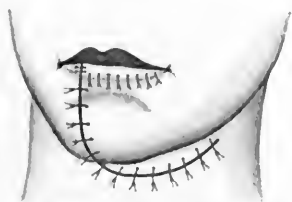

FIG. 780 b.—Bruns's method.
Vermilion border made.

the opposite side, passed downward and outward beneath the jaw in a manner permitting of the examination and removal of the submaxillary lymph nodes (Fig. 780 *a*). The removal of the growth, the sliding up into place of the flap and the covering of the new upper border with the remnant of mucous membrane belonging to the inner surface of the lip, is shown in Fig. 780 *b*. The submaxillary glands of the opposite side should not escape attention.

Entire Loss of the Upper Lip.—This deformity may be repaired by semicircular vertical flaps or by the lateral-flap method.

Buck's Semicircular Vertical-flap Method (Fig. 781).—Commence an incision at the median line on a level with the floor of the nasal cavity; carry it outward and downward in a semicircular direction around one side of the mouth to a point below the lower lip corresponding to the junction of its outer and middle thirds, *a b*; make a similar incision, *a c*, around the other side of the mouth. These incisions are carried through the entire thickness of the cheeks and lips at a uniform distance of an inch and a quarter from the border of the opening. Dissect the remaining portions of the cheeks freely from their attachments beneath, that they may be easily brought forward.

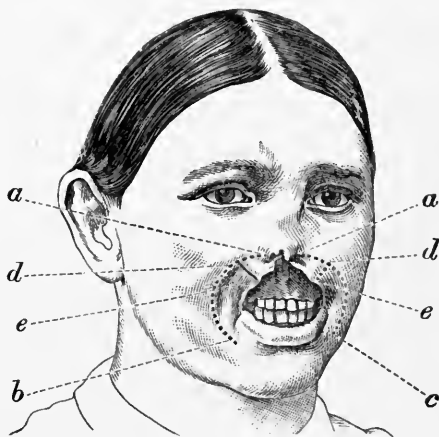


FIG. 781.—Semicircular-flap method.

The upper extremities of the semicircular flaps are trimmed off at a proper angle, *e d*, after which they are united in the median line by the usual means. The interval between the cheeks and the newly constructed mouth is closed by sutures.

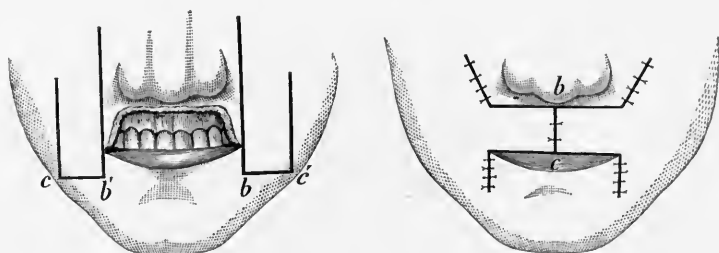


FIG. 782.—Sédillot's vertical-flap method.

Sédillot's Vertical-flap Method (Fig. 782).—The bases of the flaps in this method may be made either upward or downward, the former being the better plan. They should comprise the entire thickness of the cheeks, their length and width corresponding to the dimensions of the proposed new lip, plus an allowance of one fourth for shrinkage. They are carried

into position and united in the median line. The gaps in the cheek may be closed by sutures or allowed to heal by granulation.

Dieffenbach's S-shaped-flap Method.—Freshen the lower border of the remaining portion of the original lip, then raise two S-shaped flaps, one at each side of the nose, extending down to the angle of the mouth, turn them across the space in front of the alveolar process, unite them to each other and also to the freshened border beneath the nose (Fig. 783).

Dieffenbach's Curved-flap Method (Fig. 752).—This method of Dieffenbach is employed where the central part of the lip is gone and the gap

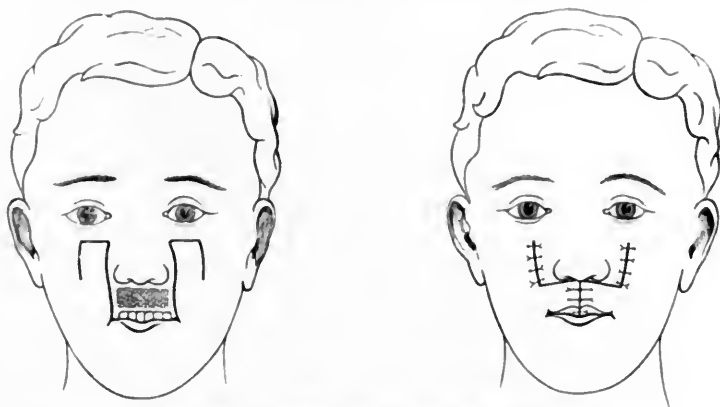


FIG. 783.—Dieffenbach's S-shaped method.

is covered with mucous membrane. Two flaps are formed by curved incisions, each beginning at the apex of the defect and carried one at either side of the alæ of the nose. The mucous membrane of the gap is partially detached from above and turned downward. The flaps are liberated, brought together in the median line, united, and so joined with the reflected mucous membrane as to provide for the new lip a vermillion border.

Szymanowski's Method.—In this method a lateral flap the width of the lip is cut from the cheek at either side (Fig. 784). The outer extrem-



FIG. 784.—Szymanowski's method.

ities are curved downward so as to lessen the tension. The flaps are liberated the entire length, brought forward into position, and united at the median line. If the buccal mucous membrane be divided a quarter of an inch below the inferior incisions in the cheeks, it can be utilized for the formation of a vermillion border after the flaps are properly united.

Ledran-Mackenzie Method (Fig. 785).—The ingenious method of repair of the loss of a large portion of the lips of one side and of the corresponding cheek by flaps taken from the chin and neck, and united to the extremities of the upper (*a'* to *a*) and the lower (*b'* to *b*) lips respectively, is easily com-

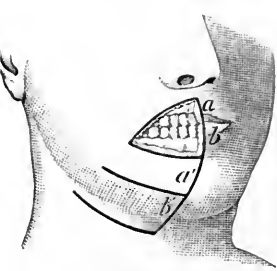


FIG. 785.—Ledran-Mackenzie method.

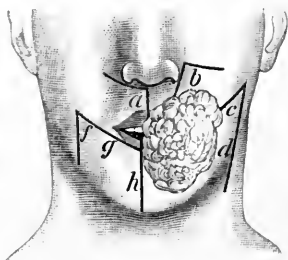
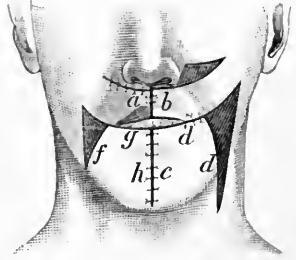


FIG. 786.—Repair of chin, cheek, and lips. (Vanzette.)



prehended. *Another* and quite complicated method of practice for repair of the chin, cheek, and lips is presented (Fig. 786). This demonstrates the cosmetic result that may be attained when the use of highly vitalized tissues is supplemented by ingenious surgical planning.

Stomatoplasty.—The operation of stomatoplasty is employed to increase the size of a narrowed mouth, or to regulate a mouth that is abnormally shaped, from deformities either incident to disease or resulting from previous operative procedure.

The deformity can be corrected by an operation already described when the lower lip is the contracted portion. In any instance the angles of the new mouth may be formed by means of transverse incisions made at the proper situations. Whenever these incisions are made the mucous membrane must be stitched over the raw surfaces to prevent them from becoming united.

Buck's Method.—The method described by Buck for restoring the angles of the mouth is simple and effective (Fig. 787). A curved incision is made with great exactness along the line of the vermilion border, circumscribing one lateral half of the mouth, and extending to an equal distance along the upper and lower lips, *a* to *b*. This incision should only divide the skin and not involve the mucous membrane. A sharp-pointed, double-edged knife is inserted at the middle of this curved incision, and directed toward the cheek, flatwise, between the skin and mucous membrane, so as to separate them from each other as far outward as the new angle of the mouth is required to be placed.

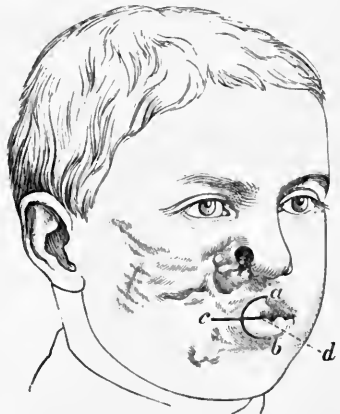

FIG. 787.—Stomatoplasty.

The skin alone is next divided outward on a line with the commissure of the mouth, *d* to *c*. The underlying mucous membrane is then divided in

the same line, but not so far outward. The angles at the outer ends of these two latter incisions are accurately united by a single-thread or fine silk-worm-gut suture. The freshly cut edges of skin and mucous membrane, above and below, that are to form the new lip borders, are to be shaped by paring first the skin and then the mucous membrane in such a manner that the latter shall overlap the former after they have been secured together by fine sutures at short intervals.

Serre's Method.—Serre's method is practiced for the restoration of the angle of the mouth (Fig. 788). Three incisions are made, a superior, external, and inferior. The first is placed horizontally in a line with the upper border of the mouth; the second, beginning at the outer extremity

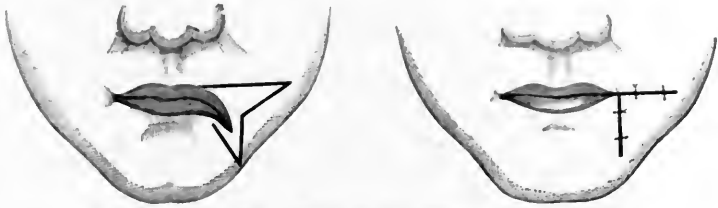

FIG. 788.—Serre's method.

of the first, passes downward and inward near to the angle of the deformity, and then directly downward for a short distance; the third passes from the border of the lower lip just within the deformity, downward and outward to join the lower end of the second, thus forming a smaller triangle below with its base opposed to that of a larger one above. The circumscribed tissues are removed, the bases of the triangles caused to meet at the angle of the mouth, and the borders are joined with sutures.

Meloplasty.—Meloplasty relates to the restoration of defects of the cheek dependent on cicatricial changes caused by noma, etc. The rules of action in this operation are substantially similar to those employed in plastic repairs of other parts. The utilization

of skin from the neck and of that adjacent to the eyelids and the lips for flaps is objectionable, because of the disfigurement incident to contraction, and when thus employed the probable need of a supplementary procedure should be well understood. In the instance of locked jaw from cicatricial tissue, the tissue must be dissected away freely and sound structures alone employed in repair. Two flaps, the upper taken from the cheek and

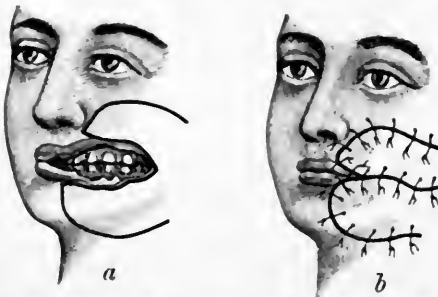


FIG. 789.—*a.* Meloplasty by the use of two pedunculated flaps from the cheek and chin. *b.* Condition after suture.

the lower from the cheek, neck, and chin, are employed sometimes to cure a crippling defect (Fig. 789).

Gussenbauer's Method.—This method is commended for those cases of locked jaw dependent on contraction caused by extensive ulcerations and sloughing of the mucous membrane of the cheeks. It is of no avail, however, in those cases in which the integumentary structures of the cheek are involved.

The Operation.—Fashion from the cheek and reflect backward to the anterior border of the masseter a skin flap about an inch and a quarter broad in front and two inches and a half broad behind; remove the subcutaneous soft parts of the cheek and the scars back to the anterior border of the masseter; so turn into the defect the superficial flap that its anterior border and the sides can be united with those of the divided mucous membrane lying beneath and in front of the masseter, thus bringing the epithelial surface innermost; divide the pedicle of the flap at the end of the fourth week and turn the superficial part of the flap forward; unite it to the borders of the remaining part of the defect, thus closing the defect entirely; cover the outer surface of the flap with a rectangular-shaped one slid into place from the lower jaw (Fig. 790).



FIG. 790.—Restoration of the cheek and mouth. (Gussenbauer.)

Trendelenburg advises the application of one or two flaps, as the case may be, taken from the cheek, temple, lower jaw, or chin, to defects due to removal of cicatricial tissue involving the entire structure of the cheek. The cuticular surfaces are turned innermost, and the outer or raw surface is skin-grafted, or instead covered with an independent flap slid into place from a contiguous surface.

Israel closed a defect of the skin and mucous membrane of the cheeks by means of a single long flap raised from the side of the neck and supra-

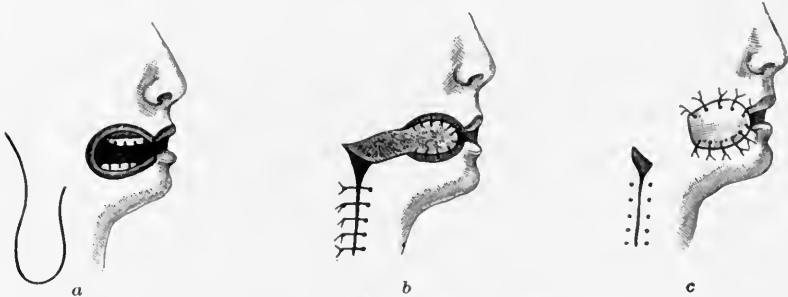


FIG. 791.—Meloplasty. (Israel.)

scapular region down to the clavicle, with the pedicle just below the angle of the jaw (Fig. 791). The flap was turned into the defect and sutured in place and the wound closed. After seventeen days the pedicle was divided and the raw surface of the posterior portion was applied to that of the anterior by doubling the flap, thus providing a cuticular outer surface to the

cheek. The remaining border of the flap and those of the defect were closely adjusted with sutures and an extended mucous border provided from the mucous membrane of the lips. *Hahn* closed a like defect in a similar manner by a long flap taken from the chest. *Czerny* raised a very long large flap from the cheek and neck with the pedicle corresponding to the zygoma. The flap included the platysma and was carried upward and so folded on itself as to permit the apex to be sutured to the posterior part of the defect, with the cuticular surface innermost. The borders of the flap were united to those of the defect and the wound closed with sutures. Later the pedicle was divided and the operation completed.

Gersuny used a flap for a similar purpose having a pedicle of subcutaneous tissue only. Flaps with these pedicles are admirable and can be turned directly into place or indirectly through a slit made in the skin.

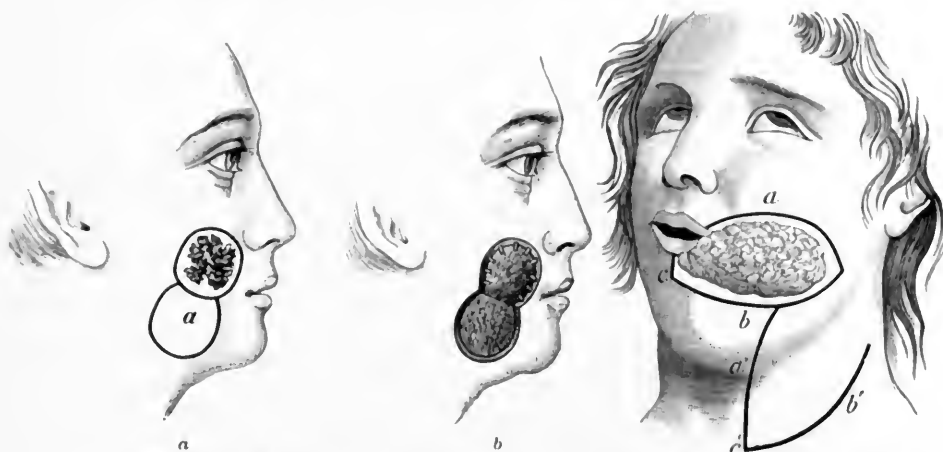

FIG. 792.—Meloplasty. (Kraske.)

FIG. 793.—Lallemánd's method, without inversion of the flap.

Kraske closed a defect in the cheek by a flap taken from the immediate locality (Fig. 792). The flap was turned over and stitched in place with the integumentary surface innermost, and the raw surfaces covered at once with Thiersch's skin grafts.

Lallemánd carried a flap from the neck into a defect of the cheek and lips resulting from removal of a neoplasm, joining a' to a , b' to b , c' to c , therefrom without inversion of the cuticular surface (Fig. 793). However, inversion with prompt grafting of the raw surface is the better when practicable.

The Remarks.—In those cases in which plastic measures afford no relief, either extraction of the teeth, excision of the jaw from the corner of the mouth to the articulation, and possibly excision of the zygoma, may be required.

Operations upon the Palate.—The operations employed to relieve the deformities of the hard and soft palate are denominated *staphylorrhaphy*, *uranoplasty* and *staphyloplasty* (Fig. 794). The armamentarium usually

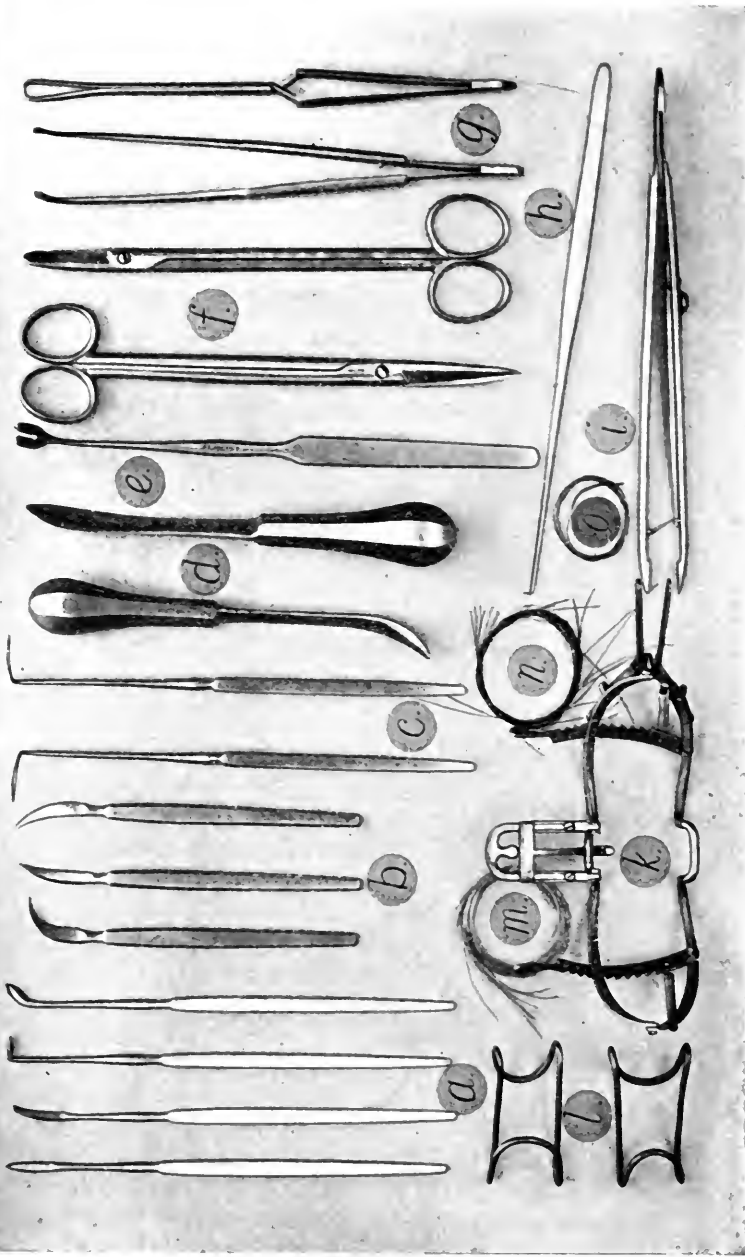


FIG. 794.—Instruments employed in operations on the palate.

a. Goodwillie's knives, *b.* Langenbeck's knives, *c.* Curved needles with eye at the end, *d.* Periosteal elevators slightly and much curved, *e.* Suture adjuster, *f.* Curved, sharp, and blunt-pointed scissors, *g.* Curved, toothed and hooked forceps, *h.* Tenaculum, *i.* Suture twisting forceps, *k.* Whitehead's mouth gag, *l.* Cheek retractors minus connecting elastic (Fig. 799), *m.* Silkworm gut, *n.* Horseshair, *o.* Fine silver wire, Forceps, sponge holders, sponges, ligatures, etc., are also required. Any suitable mouth gag can be used (Fig. 4).

assigned to these operations is quite elaborate, and in many respects needless. Ordinary tenotomes and knives meet the indications quite well indeed.

Staphylorrhaphy.—Staphylorrhaphy consists in closing an abnormal opening in the soft palate by bringing its freshened borders in contact with each other. These openings vary in extent from a simple cleft of the uvula to a complete fissure of all the soft parts (Fig. 795).

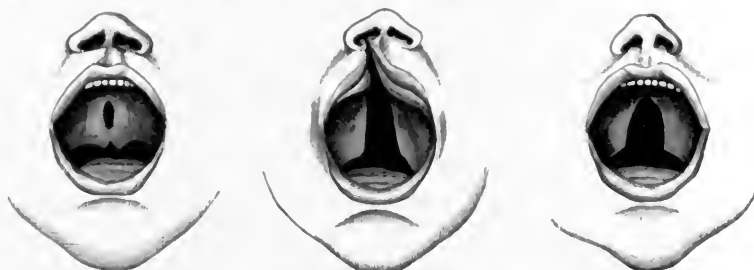

FIG. 795.—Degrees of deformity.

The Comments.—The length of the cleft is of less significance than the width, as narrow clefts are more easily closed than wide ones. However, the condition of the tissues of the soft palate is of importance in either case, for if they be contracted or atrophied the difficulties are increased, especially in connection with the wider clefts. Spoiled children, and those with bad tempers and of indifferent health, are ill suited for the operation. According to *Mr. Thomas Smith*, simple clefts of the velum may be closed at the third year of life in proper cases. If a limited involvement of the hard palate

be present, the operation should be deferred for three or four years longer. The simultaneous closure of both hard and soft parts is regarded as the better practice. While strong solutions of cocaine may be sufficiently potent for closure of short, narrow fissures, without pain, in older children or adults, still, except perhaps in the simplest cases, it is wiser to employ an anæsthetic in all sensitive patients. Horsehair sutures for relaxed tissues, and silkworm gut and fine silver wire for tense ones, are sufficient. *The position of the patient* during operation is a matter for the comfort and expediency of the operator, and often of safety to the patient. The patient should be

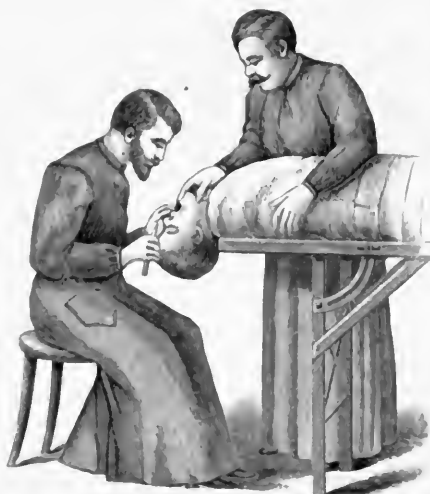

FIG. 796.—Rose's position.

placed on a narrow table of suitable height, with the head raised and thrown back. *Rose* advises that the head be thrown far backward (Fig. 796), so that the blood will collect in the upper part of the pharynx rather than enter the

trachea. Inasmuch as in this position the manipulations of the surgeon are hindered, and the cranial circulation of the patient is somewhat obstructed, a reasonable doubt as to the wisdom of the posture can be entertained. Some time prior to the operation, the patient should be instructed by manipulation to control properly the fauces, so that the surgeon may handle the parts without causing involuntary movements of them.

If the cleft extends through the whole of the soft palate, or even encroaches somewhat upon the hard portion, it may be necessary, especially if the gap be wide and the muscles controlling it be active, to overcome the muscular influence before attempting to unite the cleft. The tensor- and levator-palati muscles, together with the palato-glossi and palato-pharyngei, are the ones that exercise contractile influence on the part, and if they be properly severed the velum will remain motionless and flaccid. The accompanying illustration shows their relations to the important contiguous tissues (Fig. 797).

The *palato-pharyngei* muscles can be cut with a pair of blunt-pointed scissors, by dividing the posterior pillars of the fauces, of which they form the principal part. The *palato-glossi* muscles, comprising the anterior pillars, may be cut in a similar manner. The remaining muscles, after first passing a silken thread through the velum on each side of the cleft at points corresponding to the origin of the uvula, looping the extremities of the threads and making the velum tense with a tenaculum (Fig. 794, *h*), are divided.

The *Tensor Palati*.—Recognize the hamular process around which

the tendon of the tensor palati runs; it is located a little behind and internal to the upper posterior molar tooth. Make tense that segment of the velum by the traction suture just introduced, and enter the point of a narrow-bladed knife (Fig. 794, *a* and *b*) a little below and at the inner side of the process with the edge upward; carry it upward, backward, and inward, until the point is seen through the gap; this divides almost the entire width of the velum, with the main, if not the entire, portion of the tendon of the tensor palati.

The *Levator Palati*.—Many of the lowermost fibers of this muscle will be cut in the division of the preceding one. If a greater section be required, depress the handle of the knife and carry it outward, so as to make an oblique incision on the posterior surface of the velum as it is withdrawn.

The *Remarks*.—It is well to allow two or three days to elapse after division of the muscles before attempting the union of the cleft, so as to

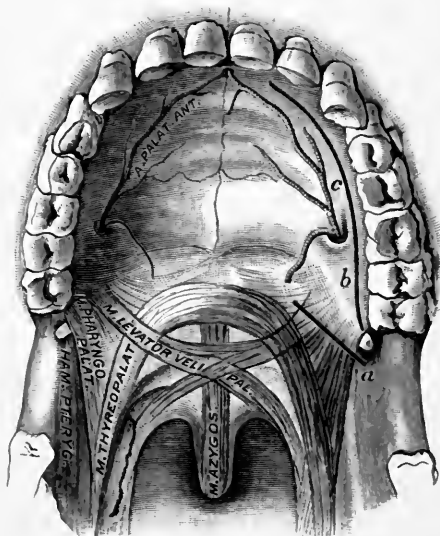


FIG. 797.—Muscles of the soft palate. *a*. Line of division of muscles. *b*. Line of incision. *c*. Palatine vessels.

permit hæmorrhage and inflammatory action to subside, and to determine more clearly whether further section will be required. The levator muscle, if it be made tense by drawing the velum toward the incisor teeth by means of the silken thread, may be cut with blunt scissors under direct observation, especially if the cleft be deep.

The Operation of Staphylorrhaphy.—There are *three steps* to the operation of staphylorrhaphy: 1. Freshening the edges of the cleft. 2. Passing the sutures. 3. Coaptating the divided borders and tying the sutures. First apply a solution of cocaine to the palate, if advisable, and then, placing the patient in a chair or on a table which will permit the head to be thrown well back so as to expose the parts to a strong light, insert the gag and draw the cheeks aside (Fig. 798). The lower point of one border of the cleft is then seized with the forceps, made tense, and the border freshened from below upward (Fig. 799), or the reverse if desired. Treat the opposite side in a similar manner.

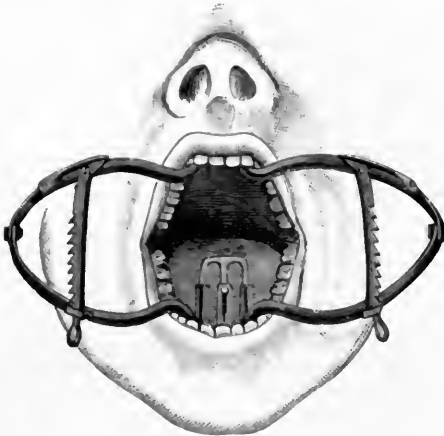

FIG. 798.

FIG. 798.—Whitehead's mouth gag.



FIG. 799.

FIG. 799.—Freshening the borders of the cleft. Cheeks drawn aside by elastic traction. Sutures supported by hooks on band around head.

If an anæsthetic has not been employed, the patient is allowed to rest after the completion of the first step, until the hæmorrhage ceases and self-control is regained. The sutures should be half a yard in length, doubled before passing, and thoroughly aseptic. Either horsehair, silkworm-gut, or metallic sutures can be employed. Three or four are usually sufficient. The first should be introduced at the middle, the second at the lower extremity, of the gap, while the remaining ones close the spaces between. They can be passed from before backward on one side, and from behind forward on the other, by means of the needle holder and the ordinary short-curved needle (Fig. 800), or in the following manner by means of a curved needle with the eye near the point (Fig. 794, c). Seize the left side of the cleft with forceps, and carry the needle through it at the point selected, from

before backward; draw one end of the suture through between the borders of the cleft; withdraw the needle, arm it with another suture, and pass it on the opposite side in the same manner; catch the thread and withdraw the needle, leaving the looped suture in the border of the cleft (Fig. 801); then pass the end of the ligature first inserted through the loop, which is forthwith drawn out, carrying the single thread through the right side.

The remaining sutures are passed in a similar manner. Each one is tied somewhat loosely, to allow for the swelling, with a reef knot, or, what is better, the slip knot held in place by a second knot tied over it. The suture last passed should be always left uncut so that the borders can be steadied by traction upon it during the passage of the next succeeding one. Perforated shot may be passed over the sutures and held in position by compressing them, or by the ordinary knot. If silver wire be used, it must be very fine and flexible, and applied with an adjuster. The sponging during the operation must not be done with any form of antiseptic fluid of a poisonous nature, since the patient may swallow a certain portion of it with an objectionable result, and, too, sponging should be done sparingly, as it excites movements of the parts and hinders operation. The sutures are left sufficiently long to admit of their easy removal, which is done at the end of a week. The diet should be plain, and all conversation interdicted.



FIG. 800.—Gross's needle forceps.

The Results.—The prospect of union of the parts is very favorable, scarcely more than five per cent of the operations being failures. The time necessary to acquire a distinct voice is variable, and often this is not attainable. The death rate in cleft-palate operations before the fourth month is about fifty per cent. The unfavorable condition of the patient adds much to this result.

Uranoplasty.—Uranoplasty is performed to close a fissure in the hard palate. It is divided into two stages: 1, the formation of the flaps; 2, the arrest of hæmorrhage and the adjustment and uniting of the flaps.

The patient is anæsthetized, and so placed in a chair or on a table as to permit of a good light, and the gag is introduced.

Langenbeck's Method—the First Step.—If there be sufficient tissue, pare the mucous edges of the cleft, otherwise omit the paring and proceed at once to raise the muco-periosteal flaps from the bone. This is done by first making an incision down upon the bone (Fig. 802) with a scalpel at the margin of the alveolar border of sufficient length to admit a slightly curved elevator (Fig. 794, *d*). The instrument is thrust through the incision inward on the bone to the cleft, causing a limited separation of the muco-periosteal flap at that situa-

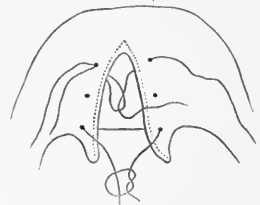


FIG. 801.—Looped suture and slip knot.

tion. It is then withdrawn and another with a greater curve is inserted into the opening at the border, and with this the flap is separated from the bone by to-and-fro movements the entire length of the cleft. The soft palate is drawn forward and its connection with the bone divided the entire width of the flap with scissors. Repeat the operation on the opposite side. Arrest hæmorrhage and renew the anæsthetic preparatory to the next step of the operation.

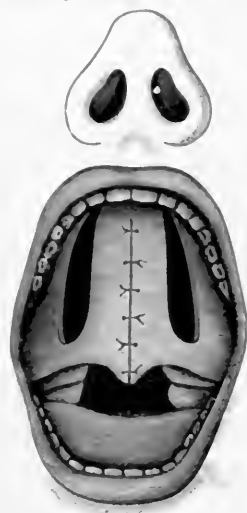

FIG. 802.—Langenbeck's method. Flaps raised, adjusted, and united.

The Second Step.—Freshen the adjoining borders of the flaps and unite them with fine silver-wire or silkworm-gut sutures. If tension of the flaps be noted, the external incisions for primary introduction of the elevator should be extended backward even into the tissue of the soft palate itself, to secure easy adjustment of the borders of the flaps. The separation of the flaps can, however, be made by an extension of the primary incisions at the outset, instead of as before described (Fig. 802). Hæmorrhage is more easily controlled and the blood directed away from the fissure by the latter plan.

The Comments.—If the fissure be very broad and one that can not be covered with the flaps already described, then flaps are made by beginning the incision at the posterior border of the last molar tooth, or, practically, in front of the hamular process, and carrying it through the periosteum, forward along the inner margin of the alveolar process to the interval between the lateral and middle incisors (Figs. 803, 797, *b*). If the curvilinear incision were made along the base of the alveolar process, or were carried forward to the central incisors, the posterior and

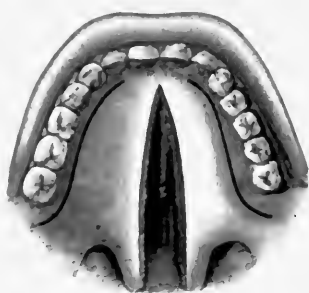


FIG. 803.—Curvilinear incision and cleft with borders freshened.

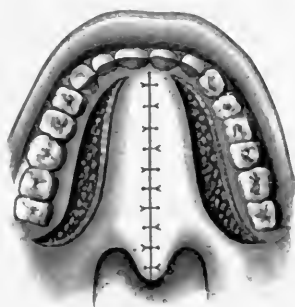


FIG. 804.—Borders of cleft united.

anterior palatine vessels would be divided. These flaps are now to be carefully detached by a periosteotome, from without inward and from before backward until the edges of the fissure are reached; they are then carried toward the median line, and, if no degree of traction be noticed, united throughout to each other by silkworm-gut or silver-wire sutures (Fig. 804). The displaced

periosteum fills in the gap and often develops sufficient bone to produce an admirable degree of firmness. The sutures are allowed to remain in position ten days or so; the patient is fed on liquid food; any cough is relieved by anodynes, and the parts are kept clean.

The Dieffenbach-Fergusson Method (Fig. 805).

—Pare the edges of the cleft; make an incision on one side through the soft parts down to the bone, parallel to the cleft and midway between it and the alveolus (*a*); divide the bone along the line of incision with a chisel (*e e*) and displace it

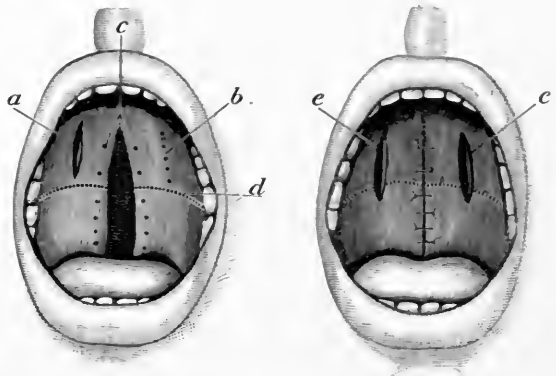


FIG. 805.—Dieffenbach-Fergusson method. *a*. Incision over hard palate. *b*. Punctures for chisel. *c*. Suture holes in palate. *d*. Margin of hard palate. *ee*. Incision through hard palate.

to the median line of the cleft; treat the opposite side in a similar manner, bringing the pared borders of the soft parts in contact with each other (*c*) and uniting them with sutures. These sutures can be fortified by others passed entirely around the displaced portions. The lateral openings are lightly packed with antiseptic gauze. If the cleft be located only at one side of the vomer, the osteoplastic or muco-periosteal flap is taken from the side of the defect. In these instances the passing of sutures is greatly hindered. If several openings be made through the hard palate in the line of incision (*b*) with a bradawl, the use of the chisel is facilitated.

The Remarks.—Differences of opinion exist among competent authorities regarding the wisdom of this plan of practice, it being claimed that hæmorrhage, sloughing, necrosis, and septicæmia are quite prominent factors in its history, especially in children of lessened vigor.

Mears uses Adams's saw after drilling an opening for its entrance, and claims less injury is thus done to the bone than by any other means. The hæmorrhage is quite severe during the separation of the muco-periosteal flaps, but it is readily controlled by pressure and cold. When the osteoplastic flaps are made the bleeding is usually still greater.

Lannelongue's Method.—In unilateral cases Lannelongue constructed a quadrilateral-shaped flap proportionate to the dimensions of the gap from the mucous membrane of the contiguous surface of the nasal septum. A long horizontal and two short perpendicular incisions outline the flap, which is then detached with a thin periosteotome and reflected downward, its base remaining attached below to the septum. The free border of this flap is then joined to the freshened outer border of the cleft with sutures. While this ingenious measure can be wisely employed as a *dernier ressort*, still, it may be also useful as a supplementary step in the other methods of closure.

The Davies-Colley Method.—In this method a triangular-shaped flap (*a b c*), including the whole of the soft parts, is cut from the wider portion of the hard palate (Fig. 807). The apex of the flap is located just behind the insertion of the incisor teeth; the base (*a c*) extends from the border of the alveolus of the last molar tooth inward and backward to near the border of the cleft of the soft palate close to its attachment to the bone. A somewhat similarly shaped flap is formed at the other side of the cleft, the inner border of which (*d e*) remains continuous with the soft parts at the border of the defect. The flap last formed is raised from the bone with an elevator and turned over across the cleft while remaining attached at its inner border by a hinge of muco-periosteal tissue (*d e*). This flap is now joined to the freshened opposite border of the defect with two or three catgut sutures. The first flap (*a b c*) is now raised in a similar manner and jumped across to the

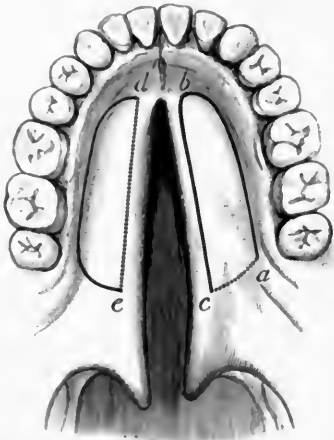


FIG. 806.—Davies-Colley method.
Flaps marked out.

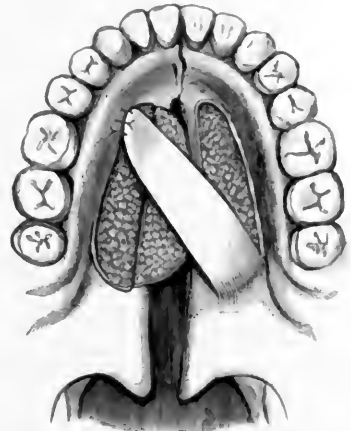


FIG. 807.—Davies-Colley method.
Flaps in position.

opposite side and its apex joined with the outer margin of the opposite gap by two or three silver-wire or silkworm-gut sutures.

The Remarks.—This operation is much less severe than the preceding, and therefore can be employed at an earlier date. Less hæmorrhage attends it and the dangers of necrosis and septicæmia are not so distinct. The pressure of the tongue against the roof of the mouth is less harmful.

Fergusson's Method.—The child is wrapped in a sterile sheet, the arms extended at the sides, and an antiseptic towel or a rubber cap is placed upon the head. The mucous surfaces concerned in the operation are cleansed with alcohol and water. The mouth gag is employed and the head thrown back.

The Operation.—"1. With a slender, slightly curved, narrow-bladed knife, cut through the mucous membrane of the mouth about one sixteenth of an inch from the edge of each segment, and divide all the soft structures to the mucous membrane on the nasal aspect of the palate, but not through it (Fig. 808).

“2. With a small, round, fully curved needle, not larger than one half inch between the eye and the point, held in a suitable needle-holder, and threaded with fine silk, closely insert interrupted sutures by passing the

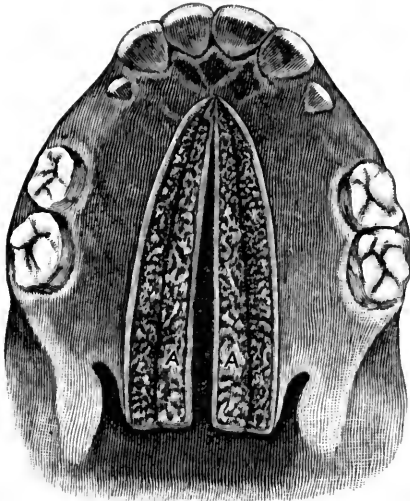


FIG. 808.—Fergusson's method. Forming flaps, A, A.

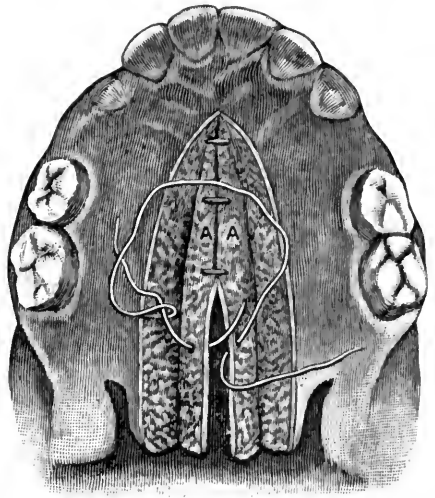


FIG. 809.—Fergusson's method. Uniting superior flaps.

needle through the free borders of the flaps from the mucous surface to the raw, and from the raw to the mucous surface, and tie them as you proceed from before backward, all the knots being situated on the nasal side (Fig. 809).

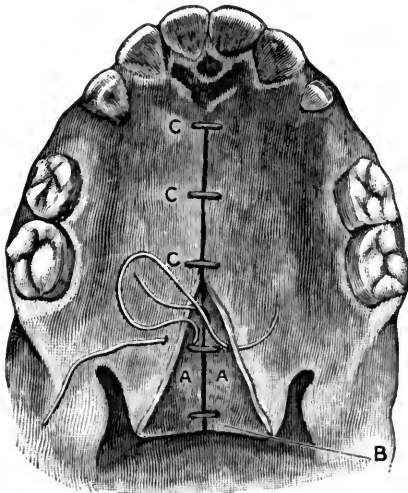


FIG. 810.—Fergusson's method. Uniting inferior flap. C, C, C. Final step (Fig. 811) precedes complete closure.

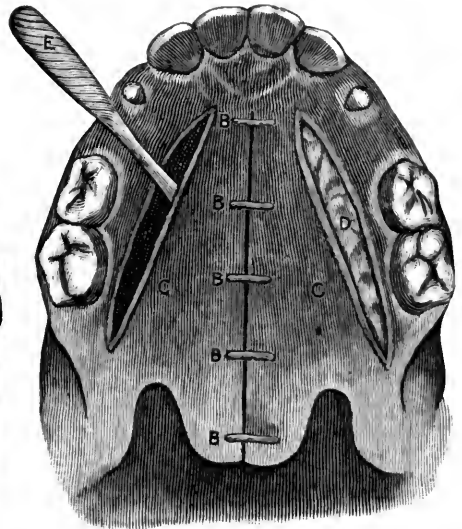


FIG. 811.—Fergusson's method. Final step; formation of periosteal flaps.

“3. Take the same needle and needle-holder and complete a row of interrupted stitches of horsehair on the buccal surface of the palate from the tip of the uvula forward, and tie them where apposition is possible without tension. The soft structures of the hard palate can not be brought together until the next step of the operation is taken (Fig. 810).

“4. Place the forefinger of the left hand on the hamular process; take a short, strong, slightly curved, narrow-bladed knife, and make a curvilinear incision on one side, beginning just behind the hamular process, cutting down to the bone and extending forward along the alveolar process, as far as desired; prevent hæmorrhage by pressure with the finger and gauze; rapidly raise the mucoperiosteal flap with a strong periosteal elevator, from the segments of the hard palate, and immediately pack the wound firmly with iodoform gauze. Repeat this performance on the opposite side, and tie the horsehair stitches not already secured (Fig. 811). The soft structures of the hard and soft palate are beautifully held in apposition without tension on the stitches.

The Remarks.—“In packing the iodoform gauze in the wounds, fixation points are obtained by forcing some of it into the bone, and also between the teeth and under the mucous membrane. If this is properly carried out, the gauze will remain in place for a week, and sometimes longer. It is removed when it becomes loosened, by which time it has generally fulfilled its usefulness. A second and occasionally a third packing may have to be inserted.

“It will be observed that this is not a flap-splitting but a flap-formation operation, the flaps carrying with them two narrow strips of the firm, strong, buccal mucous membrane of the palate, which holds sutures securely, and when they are turned upward and held in coaptation by means of the first row of sutures they form an ideal protecting roof to the raw surfaces beneath them, and afford twice the width of denuded tissues for apposition, and the nasal mucopurulent discharge is shed off to either side.”

Regarding *after-treatment*, Fergusson says that every two or three hours the mouth should be washed with boric-acid solution, and after the child has taken nourishment it should be given a little whisky and water to wash the liquid food off the area operated upon. It is usually necessary to give nutritive enemata. The stitches are not taken out earlier than the twelfth day. If the child cries much it will be necessary to give an opiate.

The following cases, he regards, are suitable for this operation:

1. When the cleft in the hard palate is not wider than half an inch. If it is wider than half an inch, it will be necessary first to perform a preparatory crowding operation (page 625).

2. The mucous membrane covering the inner edge of each bone segment should be thick, and well nourished. If it is not, the crowding operation must be first performed.

3. The operation is adapted for all clefts of the soft palate alone.

Fergusson maintains that the results of this method are vastly better than are obtained by any other. The turning of the mucous surface flaps upward lessens considerably the danger of sepsis.

The General Comments.—The palatine vessels running along the base (see Fig. 797, *c*) of the alveolar process will be divided unless great care be exercised. Since these vessels run between the periosteum and mucous membrane they are much less likely to be injured in the formation of muco-periosteal than mucous flaps. However, the bleeding can be readily controlled by pressure and ligature. In order that the undermost flap may be easily and smoothly swung into place, it may be necessary to loosen its base quite freely from the underlying tissues. The opposed raw surfaces promptly unite, since the pressure of the tongue holds them firmly in contact with each other. Any remaining defects can be closed at another time. This method is adapted especially to young subjects—one and two years old—and those with broad defects, and in failure by other methods.

The length of the cleft in the hard palate has less to do with the cure than has the width of the palatine arch. If the latter be naturally narrow, or be narrowed on account of the width of the fissure, the difficulty of closure is correspondingly increased. The more arched is the palate the easier the closure; the flatter it is the more difficult the closure because of the lack of tissue for substantial flaps. A fissure with a pointed extremity is more readily closed than one with a rounded extremity. Fissures extending to the incisor teeth are difficult of closure at that point because of the limited supply of soft parts and the difficulty of separating the periosteum at times. A rectangular knife is sometimes used for the purpose. The suitable age is about six years, provided the health of the patient be satisfactory. Operation at two or three years of age is not advisable, since interference at this time may forestall Nature's efforts at closure, and therefore prove harmful. It can be completed at one or more sittings, depending on the obstacles to be overcome.

If the deformity in the hard palate be complicated with a complete cleft of the soft palate, each defect may be treated separately. If, however, the cleft of the soft palate be partial, both can then be closed at the same sitting. The soft portion should be united first, in the manner before described, to prevent it from being obscured by the blood associated with the operation on the hard palate.

Operations for closure of a fissure of the hard palate, forcing direct apposition of the borders of the fissure, often so markedly modify the symmetry of the face and the biting line of the teeth, that imperfect mastication and a striking facial disfigurement are substituted for an oral deformity that can be easily closed by mechanical device.

The After-treatment.—Anodynes to relieve pain and secure quiet may be needed; ice-water for the first four or five hours, followed by iced milk and barley water for the first day or two, supplemented by nutrient enemata, are commended. The mouth should be thoroughly rinsed with a mild, innocent, antiseptic fluid after eating, and talking should be interdicted. Great pains should be taken by the parents to educate the child in speaking, otherwise the chief aim of the operation will fail of realization. In those instances in which the united borders of the cleft render the velum so tense as to prevent it from touching the posterior wall of the pharynx, and those in which, on

account of the great width of the fissure, such a result can be foreseen, an artificial appliance should be employed at once.

The Results.—Closure of the cleft does not cure the defect in articulation. However, closure aids much in the attainment of better speech, and often contributes greatly to the benefits of time and effort in this regard. Prolonged vomiting and unskillful pulling or bruising of the borders contribute actively to failure of operations.

Mechanical means are employed, not infrequently, to fill the opening in both the hard and soft parts, and to provide even an artificial uvula. The apparatus is made of vulcanized rubber, and is held in position by being attached to a plate fitted to the roof of the mouth. Defects in the biting line can be remedied by regulation of the teeth, and by the introduction into the gap of false teeth attached to the plate closing the fissure. An expert dental surgeon must be consulted, since he is, as yet, the only one fully competent to treat cases by this method. The ability to speak and to otherwise control the action of the throat and pharynx with this contrivance is very satisfactory, in the majority of instances equaling, if not exceeding, the best results from an operation.

Staphyloplasty.—Staphyloplasty consists in filling in the gap of the soft palate, and as much as possible of the hard, by a flap taken from the posterior wall of the pharynx.

Schönborn's Operation.—Anæsthetize the patient, perform a preliminary tracheotomy, and introduce the tampon cannula into the trachea. The flap from the posterior wall of the pharynx is made with the base downward, and

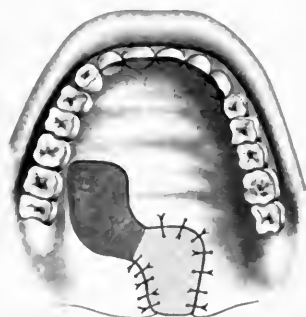


FIG. 812.—Lane's method. Reflected flap in place.

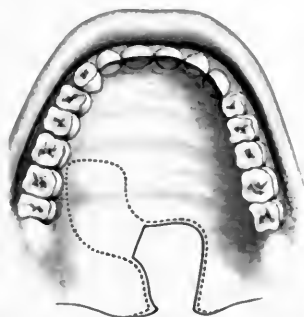


FIG. 813.—Lane's method of repair of soft palate.

the apex is carried as far upward as possible to permit of its introduction into the cleft without tension. The width and shape of the flap must be determined by the size and outline of the deformity, allowance being made for its normal shrinkage. It should consist of the mucous lining of the pharynx along with the subjacent muscular tissue. The fibro-mucous coverings of the hard palate are dissected up until its tissues and those of the velum are freely movable. The borders of the cleft are freshened, and the flap is brought in place and united by several sutures. The tampon cannula can be removed as soon as hæmorrhage has ceased, or, at the farthest, on the

day following the operation. The parts should be cleansed frequently and carefully with a mild antiseptic fluid, to wash away the abundant secretions. The sutures should be removed on the sixth or seventh day following the operation.

The Results.—The inconveniences in breathing, and the interference with hearing and smelling following a successful operation do not commend its adoption.

Lane closed a residual cleft in the soft palate by means of a flap taken from the mucous membrane at a suitable point, contiguous to the gap; turned this flap upon a properly formed pedicle and united its borders to those of the defects (Figs. 812 and 813).

Elongated Uvula.—An elongated uvula is easily shortened by seizing the end of the uvula with the forceps, and removing the required amount with scissors, after the patient has withdrawn the tongue by the aid of a dry towel. The little pain that may be caused by the operation can be relieved by the application to the part of a solution of cocaine.

CHAPTER XIII.

OPERATIONS ON THE MOUTH, PHARYNX, NOSE, ŒSOPHAGUS, AND NECK.

Salivary Fistula.—In salivary fistula the saliva is discharged on the external surface of the cheek instead of into the mouth. The object of an operation is to establish an internal communication with the duct so that the external opening can heal.

Agnew's Method.—Agnew's method consists in passing a good-sized thread of silk into the mouth, through the fistula, from without inward, and leaving it there, removing the needle, and attaching to it the end of the thread remaining outside, and carrying it through the tissues into the mouth in the same direction as the former, but not exactly in the same track, thus including a small portion of buccal tissue. The needle is then re-

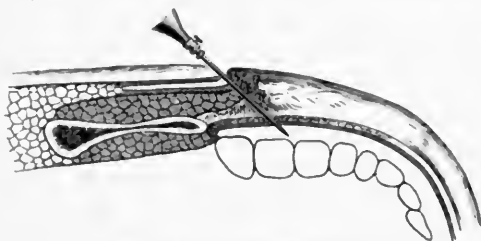


FIG. 814.—Desault's method.

removed, and the extremities of the thread are firmly tied within the mouth or round the inclosed tissue. A fine rubber ligature can be substituted for the silk. The loop cuts its way through the tissues grasped, forming an internal opening, which permits the healing of the external one.

Desault's Method.—Desault carried a small trocar from the fistulous opening forward and inward, entering the mouth opposite to the second molar tooth (Fig. 814). A seton was drawn into the channel made by the instrument and retained until a patent canal was formed through which the saliva flowed, followed by healing of the external opening.

Van Buren's Method.—Van Buren cured an obstinate case by turning the end of the duct into the mouth in the following manner: A small probe was introduced into the duct from without to steady it during dissection and indicate its situation so as to prevent cutting it. The distal end of the duct was exposed for a short distance by careful dissection, and was then passed into the mouth through a small incision made through the

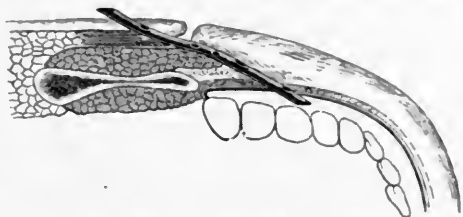

FIG. 815.—Richelot's method.

buccal mucous membrane and confined there with horsehair sutures. The external opening was refreshed and closed at once.

Richelot's Method.—Richelot inserted into the fistula a small rubber tube so as to cause one end to project slightly into the mouth, while the other end was cut off obliquely and so placed that the saliva could flow directly into the tube (Fig. 815). Thereafter the external wound healed promptly.

Deguisse's Method.—Deguisse made a puncture through the fistula, opening obliquely backward and inward to the inner surface of the cheek, and passed through it one end of a leaden wire (Fig. 816). A second puncture was then made through the same external opening, but directed obliquely forward to the inner surface, through which the other end of the wire was passed into the mouth and united snugly with its fellow by twisting. The parotid secretion promptly followed the leaden guides into the mouth, and the external opening quickly healed.

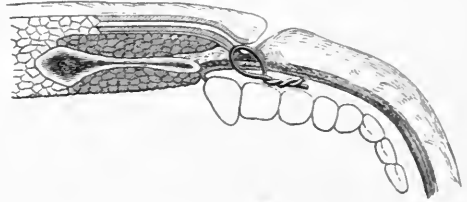


FIG. 816.—Deguisse's method.

Excision of the Tonsil.—The excision of the tonsil can be done with an ordinary bistoury or with curved scissors, aided by a tenaculum. The various forms of tonsillotomes, while they simplify the operation by giving the operator a perfect control over the cutting edge, are not necessary to its execution.

The Removal of the Tonsil with the Knife or Scissors.—If the patient be young or unable to exercise self-control, give an anæsthetic, or apply to the tonsil a strong solution of cocaine. Cause a bright light to shine into the open mouth; depress the tongue; seize the tonsil with the tenaculum or forceps, draw it inward from between the pillars of the fauces, and with scissors curved on the flat, or with the probe-pointed bistoury, or an ordinary bistoury with the point guarded by adhesive plaster, sever the tonsil from below upward. It is not necessary at first to remove the entire tonsil, since a curative influence is often established by an incomplete removal. Among the tonsillotomes in common use are Mathieu's and Mackenzie's. In using the instrument the patient is placed as before stated, and the ring of the instrument is adjusted around the tonsil with the aid of the index finger; the tonsil is elevated by a tenaculum, or by a special hook of the instrument, and severed by pressing the blade against it.

While removal of the tonsil is ordinarily a matter of but little significance, yet the not infrequent instances of severe and even fatal hæmorrhage that follow this act invite thoughtful attention and care in any case before the measure is carried into effect. Severe bleeding from constitutional causes (from abnormal vascular association, from uncommon free blood supply, from obstructed venous return, are conditions that cause perplexing complications at the bowels and often fatal results when they are incautiously invited. Aneurism of the carotid underlying the tonsil or of the

tonsil itself are conditions not new to the surgeon of extensive observation. The outcome following incision in any such cases as those is too obvious to be open to doubt. We recall an instance of aneurism of the tonsil having appearances that might readily invite the instrumental activity of an incautious practitioner.

The Results.—Any undue hæmorrhage can be controlled by ice, pressure, and astringents; actual cautery is rarely needed. In four instances the internal carotid artery has been wounded by recklessness in cutting the tonsils. Bleeding may be controlled by interrupted suture or adrenalin.

Abscess of the Tonsil.—In opening abscesses of the tonsil and of the fauces great care should be exercised not to invade the tissue too deeply and endanger the internal carotid. Therefore, attention to the anatomy of the tonsil and its environments is important (page 644). The blade of a scalpel, well guarded, except at the point, with adhesive plaster or with sterilized gauze, is often employed for making the incision (Fig. 817, *g*).

OPERATIONS ON THE TONGUE.

It is often necessary to remove the tongue in part or entirely on account of hypertrophy and malignant or other growths of its structure. The elements of danger in removal of the tongue relate to hæmorrhage, which is increased by the difficulty in catching the bleeding points, and to the danger of blood entering the larynx, both of which are emphasized by loss of command of the patient. The arteries supplying the organ are the dorsalis linguæ, ranine, and branches from the ascending pharyngeal. The ranine, the principal branch, runs along the under surface of the tongue from the base to the apex. The facial and sublingual arteries are not endangered unless the floor of the mouth is operated on in conjunction with the tongue. It should be remembered that the vessels on either side of the organ do not often communicate freely with each other, and consequently ligaturing of the lingual artery of one side will permit of free incision on that side with but trifling hæmorrhage. The buccal, sublingual, and submaxillary glands are closely associated with this organ in a surgical sense.

The principal danger from bleeding arises from division of the lingual arteries. The situation of the hæmorrhage is much more disturbing than the amount. Similar sized vessels divided elsewhere in the body would scarcely cause the least apprehension. Bleeding, however, can be prevented by ligature of these vessels in the neck (Fig. 230), or controlled for the time being by firm pressure upward on the floor of the mouth by the thumbs of an assistant, together with drawing the base of the tongue forward by means of the finger hooked over it. Not only do these manipulations control hæmorrhage, but also fix the floor of the mouth so that the bleeding points can be better seen and more quickly caught.

A method has been recommended by Langenbeck to control the hæmorrhage when but half or two thirds of the anterior portion of the tongue is to be removed by cutting.

A long, well-curved needle, armed with a strong ligature, is entered at the left of the median line of the tongue, behind the portion to be removed,

and passed through to the right side and under surface of the organ, so as to carry the ligature beneath the branches of the lingual artery at this situation. The ligature is then carried through the right border of the tongue and firmly tied. A similar procedure is repeated on the opposite side of the tongue. These ligatures can be used also to draw the tongue forward during operation. *The introduction through each nostril into the pharynx* below the base of the tongue of a rubber tube suitable for the purposes of anæsthesia, and the packing with gauze of the space above the lower extremities of the tubes, will prevent the admission of blood into the larynx (Fig. 825).

The danger of blood entering the air passages can be obviated by turning the head forward and to one side. In fact, when the head is thus placed, and the mouth widely opened, the arterial jets will escape through the latter, and thus reduce the active bleeding in the mouth to a minimum. The important desiderata are having the patient and the tongue under complete control, the dangers from hæmorrhage are then insignificant.

Preliminary Laryngotomy.—Preliminary opening of the larynx or trachea, together with tamponing of the pharynx, are wise measures in those instances in which careful, deliberate, and unobscured division of the tissues is needed for the purpose of suitable removal of the disease. In extended removal of the tongue and in operation on the floor of the mouth these measures find their greatest use. If there be no fear of infection at the seat of the operation, the tube may be removed as soon as the procedure is completed. Otherwise it should remain until healthy repair is established. In tamponing the pharynx with a sponge, or by other means, to prevent the entrance of blood, the tongue should be drawn well forward at the time of introduction so as to permit complete closure of the pharynx without interfering with the necessary manipulation of the organ for the arrest of hæmorrhage, etc.

Before operation, the mouth, the growth, and the teeth of the patient should be repeatedly and thoroughly cleaned by the frequent and free use of an antiseptic solution. Irregular and loosened teeth and dental asperities should be removed at the time of operation, and every care should be taken to provide for the operation field aseptic cleanliness.

Excision of the Tongue.—The tongue may be removed with the *knife, scissors, galvanic cautery, écraseur, or ligature*. The last method and the galvanic cautery method should be excluded, as the greater length of time required and the greater pain caused by the latter, and the greater dangers from hæmorrhage and from sepsis of the former, unfit them for use. If the diseased portion be small, it may be taken away by the incision best calculated to accomplish the object, since it is a bad plan to secure symmetry at the expense of future safety. *If hypertrophy involve the apex, or if a tumor be located at this situation*, either condition can be treated by removing a V-shaped piece in the following manner:

The Operation. V-shaped Incision.—Anæsthetize the patient; place him in a suitable position in a strong light with the mouth well opened by a special gag, or any proper instrument, forced, with a string attached, between the posterior molars. If the patient be in the recumbent posture turn the head to one side, so as to collect the blood in the hollow of the cheek; pass

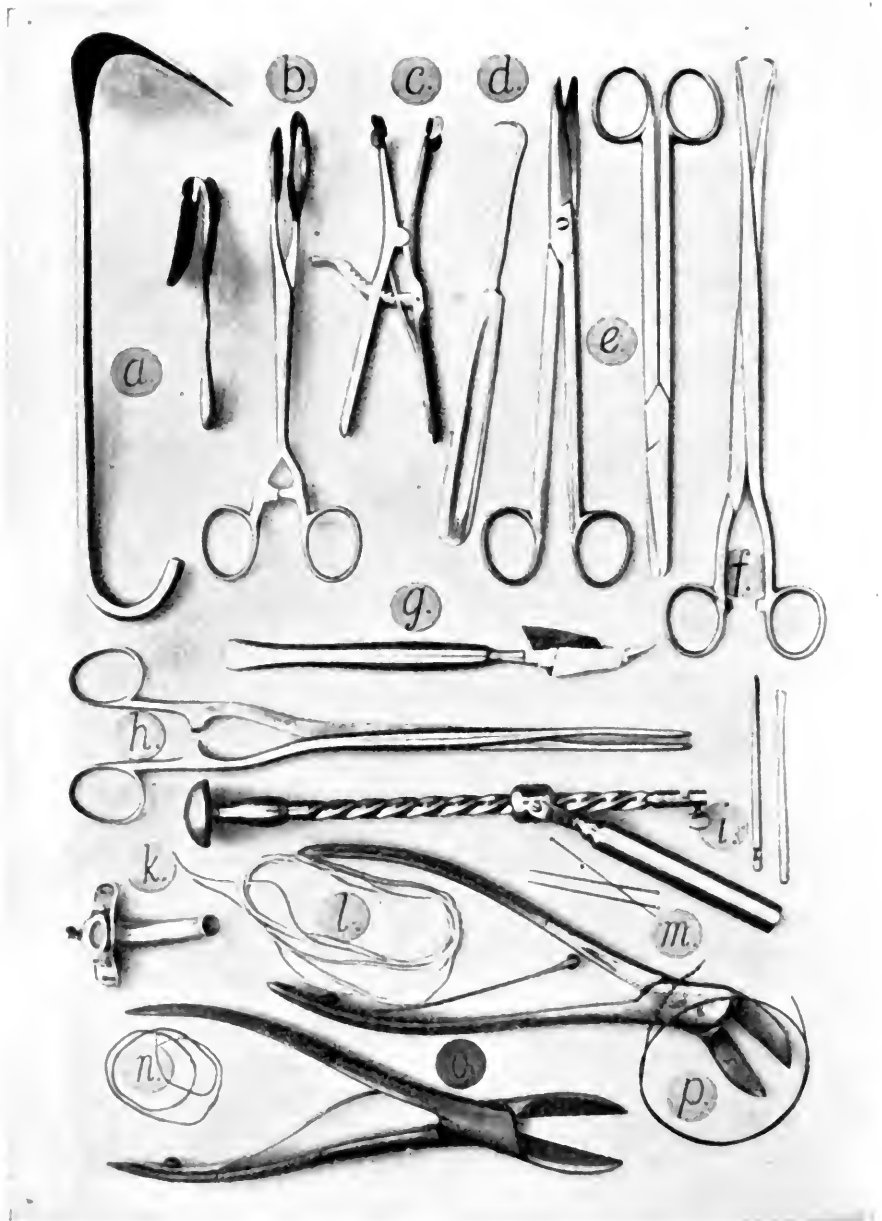


FIG. 817.—Instruments employed in operations on the tongue, tonsil, and pillars of the fauces.

- a.* For retraction of cheek. *b.* Tongue forceps. *c.* Mouth gag. *d.* Tenaculum. *e.* Curved and blunt-pointed scissors. *f.* Volsella. *g.* Bistoury guarded with adhesive plaster. *h.* Sponge forceps. *i.* Bone drill. *k.* Trachea tube. *l.* Traction loops. *m.* Hare-lip pins. *n.* Stout wire. *o* and *p.* Curved and straight bone-cutting forceps. Scalpels, forceps, pressure, ligatures, wipers, etc., should be had in abundance.

a stout ligature through each side of the tongue, just outside of the intended site of the apex of the V incision; then loop the ligatures and give each to an assistant with instructions to pull the tongue forward; seize the tip of the tongue with a forceps, or with the thumb and finger, and with a sharp-pointed, narrow-bladed knife transfix the organ posteriorly from below upward in the median line, thus locating the point of the V, and cut outward

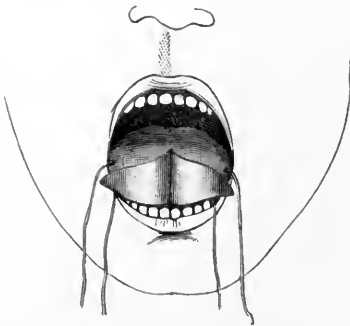


FIG. 818.—Removal of V-shaped piece.

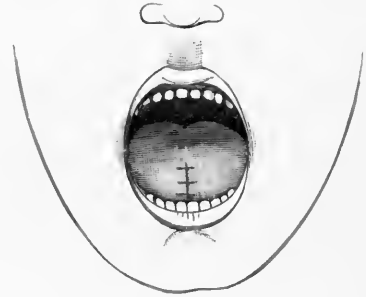

FIG. 819.—Flaps united.

and forward through one border of the tongue. Check the points of severe hæmorrhage with forceps; make the division on the opposite side in a reverse direction from the border—backward—to join the site of commencement of the first incision (Fig. 818). Ligature the bleeding points and unite the flaps by sutures in the usual manner (Fig. 819).

Hypertrophy of the Tongue (Fig. 820).—Hypertrophy of the tongue involving its entire structure, can be treated by the removal of a V-shaped piece in the manner just described, thus shortening the transverse diameter and diminishing the length. The flaps are then united, and, after union has taken place, the thickness of the tongue can be diminished in the following manner: A strong ligature is passed laterally through the organ near to the base, by which the tongue is drawn forward and held, while a wedge-shaped piece is removed by lateral transfixion in a longitudinal direction, begun midway between the upper and lower surfaces of the organ as far back as possible. The under flap is made by cutting downward, outward, and forward through the under surface of the tongue; the upper by division of the tissue above the last incision. The bleeding points should be ligatured and the flaps united with sutures.



FIG. 820.—Hypertrophy of the tongue.

Half of the organ can be removed through the mouth by first ligaturing the lingual artery corresponding to the side of operation, after which two

long, stout ligatures are passed through the tongue near the tip, one on each side of the median line, by means of which the tongue is drawn forward and upward; the frenum and the mucous membrane beneath the tongue are cut with scissors back to the base of the organ; the tongue is then divided in half from before backward with a knife or scissors; its deeper tissues are separated by tearing with the finger or the handle of the knife, and the portion to be removed is finally severed with scissors. The remaining half can be removed in a similar manner.

The Comments.—The contention on the part of some surgeons that the entire tongue should be excised when removal of half of the organ appears needful, has many strong and, it seems to me, wise objections offered to the practice. Half of the tongue, although deformed by healing, still has remaining, in a crippled state, the functions that characterize the organ in health, such as speaking, swallowing, tasting, etc. The moral effect on the patient of a proposition to remove the entire organ at the outset will too often lead to a rejection of the operation, thereby causing delay which may render unserviceable any operative procedure. Finally, if removal of but half of the organ affords only temporary respite, the remainder can then be taken away with no greater danger than that attending the removal of the whole in the first instance. *Hueter* suggests that, in excision of the anterior portion of one side of the tongue, the gap be closed at once by using as a flap for that purpose the apex of the remaining portion. The advantages that may follow this practice are measured by the comparative differences resulting from prompt union with a shortened organ and those of one crippled by the cicatricial influences of prolonged healing. *Hueter's* suggestion in this regard is not often followed.

The Removal of the Entire Tongue.—The removal of the entire tongue can be done through the mouth, beneath the inferior maxilla, by division at the lower jaw either at the symphysis or at one side of it, or through the cheek. It can be removed through the mouth by means of the *knife*, the *scissors*, the *galvano-cautery*, and the *écraseur*.

The Operation through the Mouth.—Put the patient thoroughly under the influence of an anæsthetic at the outset, as afterward only partial insensibility is desired; gag the mouth, and support the head so that the blood will escape externally rather than into the pharynx. Pass a stout thread through the tongue at the juncture of the middle and anterior thirds; draw the organ forward and upward with the thread, and detach it with scissors from its connections with the jaw and anterior pillars of the fauces; divide the muscles of the tongue with strong, straight, blunt-ended scissors back to near the larynx, as closely to the under surface as the disease will permit. The glosso-epiglottidean folds are now brought under control by passing a long ligature through each fold. These ligatures are allowed to remain *in situ* in order that the floor of the mouth may be drawn forward by them in the event of secondary hæmorrhage or difficult respiration. The excision is then completed and all bleeding points are checked.

The Comments.—The frænum linguæ and the anterior pillars of the fauces should be completely and promptly divided so as to permit a free withdrawal

of the tongue from the mouth. *Whitehead* advises that the muscles of the tongue be rapidly and boldly cut, irrespective of other than arterial hæmorrhage, as the oozing will be promptly checked by control of the various arteries. With previous study and present caution these arteries can be caught and tied or twisted before being severed, after which the operation is promptly completed without further troublesome hæmorrhage. A preliminary tracheotomy is advisable in those cases in which extensive wound surfaces and troublesome hæmorrhage are anticipated. Infective pneumonia is obviated in the former, and the entrance of blood to the pharynx is prevented in the latter instance.

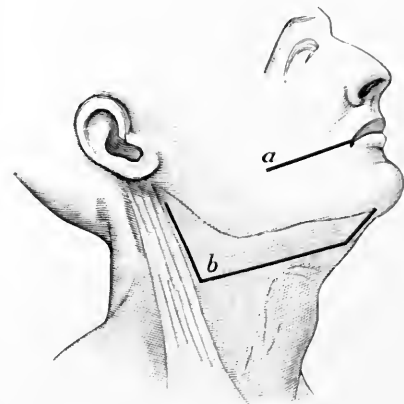


FIG. 821.—*a.* Jaeger's incision. *b.* Kocher's incision.

The ligaturing of the lingual arteries beneath the hyoglossus muscles before the employment of the scissors for removal of the tongue simplifies the operation exceedingly, as then the dangers and annoyance of present or prospective hæmorrhage are largely obviated. Now and then a dorsal lingual branch requires attention. The author has, however, noted but one instance of this kind in his own practice. Nor is this all, for the ligature of these ves-

sels affords opportunity for the removal of the lymph glands associated directly with the affected part of the tongue, whether they are diseased or not, a measure of far greater importance in our opinion than that of ligature of the vessels. In fact it is our practice, and we believe that it should be made the first step of operative endeavor, to remove these glands, tying the lingual or not as may then seem wise.

The After-treatment.—Wash the floor of the mouth cautiously with a solution of biniodide of mercury (1 to 1,000), dry it, and, if desirable, paint the raw surface with the antiseptic varnish of *Whitehead*, which is compounded by substituting for the rectified spirits in the compound tincture of benzoin a mixture of nine parts of ether and one of turpentine saturated with iodoform. Before using the ether add one part of turpentine to ten of that fluid. The mixture dries quickly and remains as a firm coating for twenty-four hours. Gauze packings are regarded as objectionable by some, as they become quickly saturated with saliva. *Treves* makes "no applications of any kind" other than antiseptic solutions.

Kocher's Method.—*Kocher* recommends the following plan if the floor of the mouth and contiguous glands, and even the pharynx be involved along with the tongue: After a preliminary laryngo-tracheotomy and thorough cleansing of the parts, a triangular flap is made, with the base upward, its lower boundaries corresponding to the course of the digastric muscle, and its apex being at the point of connection of this muscle with the hyoid bone (Fig. 821, *b*). The posterior incision may also be made from the apex

directly to the anterior border of the sterno-mastoid muscle, thence upward along this border to the angle of the jaw, thus affording a greater space than is secured by the former line of incision. This flap covers the region of the jaw and neck occupied by the facial artery and the submaxillary glands posteriorly, and the lingual artery and the sublingual glands anteriorly. The flap is dissected up, the arteries are tied, and the glands are removed. This exposes the side of the base of the tongue and the back part of the floor of the mouth to easy inspection and manipulation. The larynx and pharynx are then protected from the entrance of blood by a large sponge, to which a string should be attached, and the myo-hyoid muscle is divided close to the jaw, exposing the tongue and mouth freely. The organ is now drawn through the opening, split, and the half of it on the side corresponding to the flap is removed, including, if necessary, the floor of the mouth, pillars of the fauces, and pharynx, down to the hyoid bone. The remaining portion can be removed in a similar manner through a triangular opening on the opposite side or through the primary opening, if the extent of the disease will permit. As before remarked, the operation which involves the bone and soft parts around it results less favorably than when the tongue is removed through the mouth by the methods described.

The Comments.—The lingual artery at either side may be tied before the flaps are turned up, or they may be ligatured afterward, as suits the desire of the surgeon. If the entire tongue be removed at one side, the lingual artery of the opposite side should be tied before the removal.

The After-treatment consists in keeping the mouth well cleansed, while to the raw surfaces iodoform and iodoform gauze or other suitable antiseptic dressings are applied. The tracheotomy tube should not be removed until all dangers from inflammation and from infective pneumonia due to the discharges are ended.

The Removal of the Tongue with Division of the Jaw does not offer the chances of success secured by the preceding method.

Sédillot's Method.—Beginning at the median line of the lower lip, divide the soft parts vertically downward to the hyoid bone (Fig. 822, *a*); extract a central incisor tooth and drill a small hole through the body of the lower jaw at either side, a quarter of an inch from the median line; divide the jaw in the median line vertically or irregularly—the latter affords opportunity for a

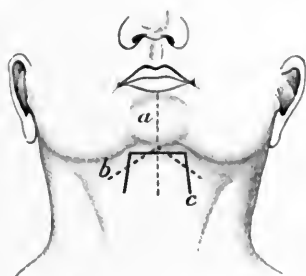


FIG. 822.—*a*. Incision of Sédillot, Roux, Syme. *b*. Regnoli's incision. *c*. Billroth's incision.

more substantial subsequent coaptation; pass a strong ligature through the tongue and separate the bony fragments, thus exposing to view the floor of the mouth. Divide the mucous membrane at its connection with the jaw, also the genio-hyoid and genio-hyoglossi muscles; draw the tongue forward and sever the remaining attachments carefully with scissors, securing the ranine vessels before their division. The tongue may be either removed entire or split and each half removed separately, as before described. Unite

the jaw with silver wire; drain the wound from the lower angle; fortify the line of junction of the jaw with an interdental splint (Fig. 826); unite the stump of the tongue to the sides of the mouth and maintain thorough cleanliness by the frequent employment of antiseptic solutions.

Jaeger's Method.—Jaeger divided the cheek, from the angle of the mouth back to the anterior border of the masseter muscle (Fig. 821, *a*), and approached the diseased tongue in this manner. This measure is serviceable in instances in which the disease is located far back on the tongue, and in which the anterior pillar of the fauces is invaded, also in the event of inefficient light, severe hæmorrhage, an uncontrollable patient, or a limited separation of jaws. If scarring be of special significance, other means of attainment of the objects should be considered.

The employment of the écraseur, as practiced by Mr. Baker, is a satisfactory means of removing the tongue.

Baker's Method (écraseur).—Pass through each side of the tongue, one inch from the extremity and half an inch from the median line, a strong silk ligature, which is firmly tied and looped; the operator, holding one loop while the assistant holds the other, causes the tongue to be drawn forward, and then with a blunt-pointed scalpel, aided by the fingers, splits the tongue in the median line back to a point one inch behind the cancerous growth; arrest hæmorrhage, draw the diseased half still farther forward, sever the muscular and mucous connections at the symphysis, and with sharp-pointed scissors divide the mucous membrane backward along the lower jaw to one inch behind the site of the growth. Free the diseased portion of the organ from its attachments so as to readily permit the application of the écraseur and the division of the segment at a point as far as possible from the growth; pass two strong, blunt-pointed curved needles through the tongue far behind the seat of the disease, and adjust the loop of the écraseur around the segment behind and below them, so as to cause it to pass wide of the disease at the line of severance. Baker employed a whipcord loop (Fig. 823) with a moderate-sized instrument, curved somewhat on the flat at the lower end. Vessels which may remain unsevered after tightening the loop are ligatured and divided, and the nerves are severed close to the stump. If necessary, the remaining half of the tongue is treated in a similar manner. The instrument can be applied to the tongue through an opening made behind the symphysis. The loop can be introduced here so as to command half or all the tongue.

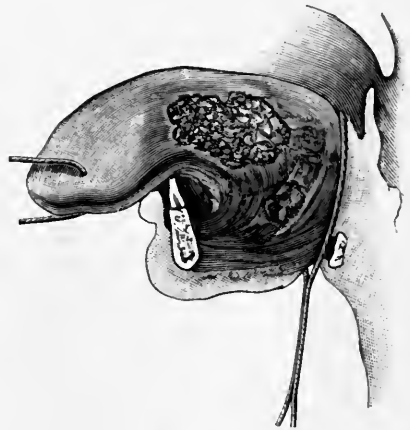


FIG. 823.—Whipcord loop applied.

The Precautions.—As the loop is tightened around the tongue, care must be observed to prevent it from slipping forward nearer to the seat of

the disease, which is liable to happen notwithstanding the restraining influences of the transfusion needles and of the shallow grooves made in the soft parts for the lodgment of the loop. Since the nerve and the vessels often escape the effect of the loop, the loop should be withdrawn carefully, the nerve cut, and the artery caught and tied to avoid embarrassing hæmorrhage.

Regnoli's Method.—The operation devised by Regnoli affords easy access to all portions of the tongue, except its base, and also furnishes good drainage, but creates a large and somewhat dangerous wound.

The Operation.—An angular or crescent-shaped incision is carried along the base of the lower jaw (Fig. 822, *b*) extending between the anterior borders of the masseter muscles, avoiding the facial arteries. A vertical incision is then made from the center of this to the median line of the hyoid bone. The flaps are reflected, the mucous membrane, the attachments of the lingual, hyoid, and digastric muscles divided from the inner surface of the lower jaw, and the tongue is freed laterally from the anterior pillars as in other methods. The tongue is then drawn through the opening and severed by the knife or scissors, the bleeding points being secured as fast as they appear. The flaps are united, the wound is drained, and the remaining raw surfaces are allowed to heal by granulation.

Billroth made a somewhat curved submental incision (Fig. 822, *c*) only, and extended it at either side so as to permit ligature of the lingual arteries and removal of the infected glands before extirpation of the tongue (Fig. 824).

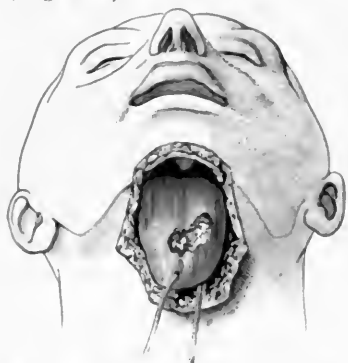

FIG. 824.—Tongue exposed through Billroth's submental incision.

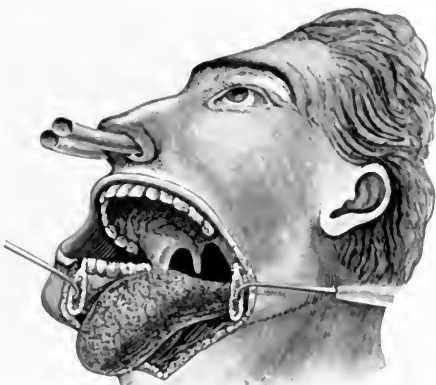

FIG. 825.—Langenbeck's incision, floor of mouth involved. Tubes entering pharynx through nose for anæsthetic purposes (page 635).

If the floor of the mouth were involved in addition to the tongue, *Billroth* made an incision about one inch below the border of the lower lip, from one facial artery to the other; at either end of this incision he made a vertical one extending downward to a point about four fifths of an inch below the lower border of the inferior maxilla; at the sites of juncture of these vertical incisions with the jaw he divided the bone and turned it downward along with the soft parts, thereby affording ample room to reach the diseased parts within. After extirpation of the disease, he wired the fragments in position and closed the wound. *Langenbeck* (Fig. 825) divided the

jaw on the side of the greatest amount of disease, drew apart the fragments, excised the tongue, floor of the mouth, etc. The jaw was united as in the preceding instance. If the portion to be removed be extensive and the danger from hæmorrhage great, a preliminary tracheotomy is advisable. This measure not alone prevents the blood from obstructing respiration, but lessens the dyspnœa frequently caused by a wide separation of the jaws.

The Choice of Method.—In the choice of method Treves wisely presents the following propositions:

“1. The organ should be removed by cutting either with scissors or with the bistoury.

“2. The removal should, as a general rule, be effected through the mouth. (Simple removal in 202 cases, of whole or part of organ, 14 died (Butlin).)

“3. Every means should be taken to reduce the hæmorrhage to a minimum.

“4. When the floor of the mouth is involved, or the glands are extensively diseased, the excision should be carried out through the neck.”

The General Remarks.—Cancer of the tongue causes infection of lymph glands speedily, and prompt action should be counseled in all instances. Therefore, an accurate knowledge of the nature of a morbid growth of the tongue should be quickly gained, and, too, before the employment of irritating applications. When the disease is located at the frænum it is difficult of removal and of proper estimation of the extent without first extracting two or three of the lower incisor teeth. A suitable vulcanite interdental splint constructed to fit the jaw before its division is the best agent for the retention in place of the fragments after operation (Fig. 826). It should not be overlooked that in hopeless cases the removal of the disease from the buccal cavity, even though it returns promptly elsewhere, rescues the patient from the pitiless suffering attendant on its presence in the mouth.

The After-treatment.—Thorough asepsis and a liberal nutritious diet are the elements of prime significance in the treatment. Rectal alimentation for the first two days, followed by the use of the stomach tube, if necessary, is very important. Abundant fresh air and cleanliness of the mouth should be secured.

The Results.—The rate of mortality from removal of the tongue by all of the methods described is considerable, fifty-six out of two hundred and forty-four cases having died. In one hundred and sixty-three cases of removal through the mouth attended with preliminary ligature of the linguals only, the death-rate was 12.8 per cent. In fifty-eight cases operated on by Kocher, the death-rate was about 10.5 per cent. In twelve cases done by Kocher after his own method the death-rate was 8.3 per cent. In removal requiring excision of the jaw or extensive dissections, the rate is increased five and ten per cent. In two hundred and forty cases ten per cent

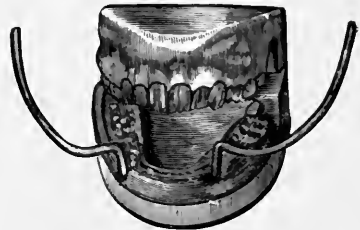


FIG. 826. — Kingsley's interdental splint of vulcanized rubber.

reached the three-year and 6.6 per cent the four-year limit. In severe cases, when thoroughly done, the life limit is encouraging, as is shown by the fact that half of Kocher's long-lived ones were of this character. Whitehead reports 129 cases, in which, so far as could be known, 8 lived from 3 to 10 years, 17 succumbing before the three-year period (Curtis). Treves reports 34 cases of his own attended with primary ligature of the linguals, in which 3 died. Baker reports, as the result of his method, 40 cases with 5 deaths, 1 from diphtheria. Many of Whitehead's cases are early ones. The rate in removal of glands and part or whole of tongue below jaw is 5 per cent better than with division of jaw. Unoperated cases live scarcely more than a year.

Tongue-tie.—Tongue-tie depends on an undue extension forward, either with or without an abnormal shortening of the frænum linguæ. If the condition be severe enough to call for treatment, the end of the tongue is pressed upward by passing the first two fingers beneath it, palm downward, bringing the tense frænum between them, which can be divided with a blunt-

pointed scissors at a little distance from, but parallel with the palmar surface, care being taken not to sever the ranine artery.

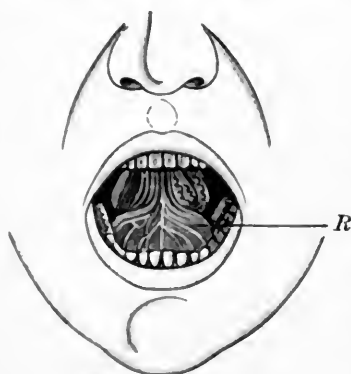


FIG. 827.—Ranula.

Ranula (Fig. 827).—The closure of the ducts of the sublingual and other glands in this situation causes a cystic distention of them, and even of the glands themselves. If it is not possible to find and probe the duct openings, it will be necessary to evacuate the contents at the floor of the mouth below the tongue, or, if the tumor be of large size, this must be done in the median line externally, close to the hyoid bone. In either instance it may be necessary to pack the cavity with lint and liquor ferri sulphatis, or cauterize

the sac with nitrate of silver or carbolic acid, and even to dissect it partially or entirely away. The use of stimulating injections, the introduction of a seton of silk medicated with an astringent or stimulant, or the division and stitching outward of a portion of the wall of the cyst, may be practiced if simpler means fail. Secondary sacs should be opened to permit cure.

Removal of Tumor of Tonsil and Pillar of Fauces.—This operation is practiced for the purpose of removal of malignant disease of the tonsil, with or without involvement of contiguous tissues. In the simpler forms the disease can be removed through the mouth. But if the disease be extensive, and evidences of deep tissue and lymphatic involvement be noted, the approach should be made from the neck (pharyngotomy). In either instance a careful study of the important nervous and vascular relations to the diseased structure should be made.

The Anatomical Points.—The tonsil in health corresponds to the angle of the lower jaw. It is a vascular structure receiving branches from the facial, internal maxillary, lingual, and ascending pharyngeal arteries. The internal carotid lies at the outer and posterior aspect of the tonsil, at a distance of

about three fourths of an inch, separated from it by the muscular and fibrous structures of the pharynx, the styloglossus, and stylopharyngeus muscles. The glosso-pharyngeal nerve has a substantially similar association. The removal of the tonsil for malignant disease can be carried on through the mouth or through an incision in the neck. The former route is advisable when the growth is limited to the tonsil, and even extends to the base of the tongue, and is not attended with glandular involvement. In some instances either tracheotomy with pharyngeal plugging, or splitting of the cheek, and ligature of the external carotid, may be practiced, especially the latter, if for no other reason than that of lessening, for a time, at least, the blood supply of the diseased part.

The Operation.—Fix the mouth widely open with the gag and raise the shoulders so as to expose the parts to a good light; seize the diseased tonsil with forceps or tenaculum, and draw it well into the mouth, then with long, blunt-pointed scissors divide the tissues cautiously and as far away from the growth as advisable, arresting hæmorrhage with sponge pressure, torsion, etc., as it appears. If the disease has extended beyond the tonsil to the pillars of the fauces, divide the soft palate near to the median line, thence outward with scissors, and finally remove the pillars of the fauces and the tonsil by means of blunt dissection carried on with the scissors, fingers, or an instrument devised for the purpose. If it so happens that the large size of the growth interferes with the visual or manipulative opportunities of the surgeon, the growth may be reduced in size by the galvano-cautery knife at a dull red heat. Forepressure and sponge pressure usually meet the hæmostatic requirements.

Pharyngotomy (Cheever's method, Fig. 828).—Make an incision through the integument, platysma, and fascia along the anterior border of the sternomastoid muscle from the level of the lobe of the ear to below the level of the tumor; make a second one extending from the first along the body of the lower jaw; dissect and draw aside the flaps; avoid, if possible, the lower branches of the facial nerve; divide the stylo-hyoid, styloglossus, stylo-pharyngeus, and the digastric muscles, if need be; ligature and divide the facial artery and vein; draw the submaxillary gland forward, and the internal jugular vein and carotid arteries outward, exposing the pharyngeal wall. Introduce the forefinger into the mouth and outline the extent of the disease, aided by conjoined manipulation from without. Open the pharynx in front of the disease from without with a galvano-cautery knife or with scissors, thence passing upward, backward, and downward, circumscribing the diseasewidely and removing it along with the contiguous portion of the wall of the pharynx, leaving no lymphatic glands behind.

The Remarks.—The author, in a recent severe case requiring excision of the ascending ramus of the jaw, carried the first (*a b*) incision along the lower



FIG. 828.—*a b c*. Cheever's incision. *a c*. Mikulicz's incision. ----. Author's secondary incision to *a b*.

border of the horizontal ramus of the jaw instead of in the course described above. The second incision (dotted line) was made backward and downward from near to the center of the first, and the flaps were reflected in the usual manner. On closing the external wound, the lower end of the second incision was situated admirably for the purposes of dependent drainage.

Czerny's Method.—Introduce a tracheotomy tube, and tampon the pharynx; make an incision from the angle of the mouth downward and outward to the anterior border of the masseter, thence downward to the level of the hyoid bone; expose and divide the lower jaw just in front of the last molar tooth; draw the fragments apart and divide the buccinator, digastric, styloglossus, stylo-hyoid, and stylopharyngeus muscles; secure the facial and lingual vessels; avoid the salivary glands, and the lingual, hypoglossal, and glosso-pharyngeal nerves. After removal of the growth the jaw is united with silver wire, and the wound is closed and dressed.

Mikulicz's Method.—Tracheotomy and pharyngeal tampon are employed the same as before. Make an incision from the tip of the mastoid process along the anterior border of the sterno-mastoid muscle to the greater cornu of the hyoid bone. Expose both surfaces of the ascending ramus of the lower jaw with the rugine, carefully avoiding the parotid gland, facial vessels, and external carotid artery; exsect the ramus, draw aside with strong hooks the body of the jaw, the masseter, internal pterygoid, digastric, and stylo-hyoid muscles, thus exposing the lateral wall of the pharynx at the situation corresponding to the tonsil. The pharynx is opened and the disease is removed as in the first instance. If the tissues connected with the ramus of the jaw are involved, this portion of the bone should be removed along with the diseased structures connected with it. The elevation of the periosteum at the inner surface in such cases as these is obviously as unnecessary as it is unwise.

The General Remarks.—*Treves* advises the passing of a soft catgut ligature beneath the common carotid, so that hæmorrhage can be arrested promptly in case of need, by traction on the ligature, not, however, by tying it. After operation the ligature is removed and the wound closed. If hæmorrhage be not feared, preliminary ligature of the external carotid is advisable, since this measure not only controls hæmorrhage, but likewise arrests the freedom of the circulation of the part for some time to come, and, moreover, offers no impediment to cerebral circulation. In those cases in which the external carotid is tied and the operation completed at once, infection of the wound from the pharynx may lead to cellulitis of the neck, and to secondary hæmorrhage from the external carotid at the seat of the ligature. Therefore, in our last case of this kind, the wound was packed with iodoform gauze for three days before the disease was removed. During this time reparative closure of the interstices of the entire wound had taken place, and but a very limited suppuration followed. A longer time than this can be taken in many instances. It is essential for final cure that the lymphatic glands be removed irrespective of the appearance in them of infection, as it is a well-established fact that

these glands may be infected without causing an appreciable increase in size. The glands and the associated connective tissue should be dissected away together, thus securing the removal of infected glandular and other lymphatic structures. Two wires should be introduced through the fragments of the jaw at some distance apart, especially in the posterior division of the bone, to prevent rotation of the posterior fragment, which is quite sure to happen if but one be employed. The interdental splint (Fig. 826) finds in these cases a most satisfactory use.

The After-treatment.—Free drainage, thorough cleanliness, and ample nutrition by means of the stomach tube are essential. The opening in the wall of the pharynx should be closed at once as far as possible with chromicized catgut. The external wound is closed; drainage and moderate pressure are applied to the surface. If an opening remain in the pharynx, it should be plugged lightly from within with antiseptic gauze to prevent infection of the wound. The patient should be got out of bed and in the fresh air as soon as practicable. He should be caused to lie on the well side during healing, to prevent contact with the raw surfaces of the buccal discharges.

The Results.—Late detection of the disease, with consequent involvement of the glands, renders the final outcome very unsatisfactory indeed. However, sufficiently favorable results have followed bold and extended action on the part of many surgeons to warrant the attempt of extirpation, provided proper co-operation can be secured. Bosworth reports but one cure—two and a half years—in 118 cases. *Butlin* reports 54 cases, with 14 deaths from operation; 21, alive or dead, with recurrence; 3 died from cancer elsewhere; 9 were free for more than three and 8 from one to three years. *Butlin* does not favor preliminary tracheotomy.

Low Lateral Pharyngotomy (*author's case*).—The operation of low lateral pharyngotomy for the purpose of reaching the lower part of the pharynx, the upper part of the cesophagus and the posterior aspect of the larynx, is not a novel procedure except in so far as may relate to tumor of the larynx itself.

In the instance in question, the patient, forty-five years of age, had suffered for many months with a tumor located apparently at the lower part of the pharynx, so low, in fact, that it could be seen only with the aid of a laryngoscope and could be felt only with much difficulty at its upper aspect with the index finger introduced through the mouth. The distance from the upper incisor teeth to the tumor was five and a half inches. The growth appeared to fill the entire pharynx at that situation, although the finger could be swept around the upper part very easily. However, at a distance of six inches from the incisor teeth the end of the finger, when thus swept, came in contact at the right border of the pharynx with an apparent attachment of the tumor to that aspect of the pharyngeal wall. The patient could breathe readily except when in the recumbent position and during sound slumber, then the presence of obstruction, characterized by obstructive stertor and difficult breathing, were prominent.

Inasmuch as local treatment had in no manner been followed by benefit,

it was determined that only direct removal would suffice, and low lateral pharyngotomy at the right was selected as the best means of approach to the growth. It was deemed wise to direct the lower portion of the incision so as to correspond to the site of the supposed attachment of the morbid growth to the lateral wall of the pharynx, thus enabling one to clearly define the important characteristics of the tumor and the best means of removing it, i. e., by enucleation, the hot loop, or by ligature or division of the pedicle.

With the head and shoulders well elevated to facilitate respiration, the patient was anæsthetized with chloroform. The approach of profound anæsthesia was promptly attended with such a degree of respiratory obstruction as to require the employment of a trachea tube, which was introduced into the larynx in order to limit as much as possible the capacity of the space above the tube, thus minimizing the amount of blood that might enter the larynx in spite of packing should much bleeding attend the removal of the growth.

The Operation.—After the introduction of the trachea tube the head was turned strongly to the opposite side and an incision made from a point about an inch below the body of the jaw, in a line corresponding to the posterior border of the thyroid cartilage, through the integument superficial fasciæ and platysma, to a point a little below the cricoid cartilage. The borders of the incision were drawn apart and held by means of traction loops, and the left greater cornu of the hyoid bone was firmly pressed to the right, thus bringing into prominence the right greater cornu, which was then seized with a tenaculum and drawn firmly upward and held, thereby increasing the space below it and immobilizing the cornu, thus placing on the stretch and making prominent the part of the inferior constrictor at the floor of the incision, the thyro-hyoid muscle at the outer border and also the portion of the thyro-hyoid membrane immediately below the greater cornu, as well as the contiguous borders of adjacent muscles. It is proper to note at this time that the external and internal branches of the superior laryngeal nerve are the only nerve structures of special significance that are reasonably exposed to danger from proper operative advance through this incision. The external branch is intimately associated with the part of the inferior constrictor muscle most concerned in the operation, lying upon, sometimes piercing, its lower part, perhaps passing quite transversely across, then again nearly vertically downward upon it. However, inasmuch as this nerve can be easily seen in the great majority of instances, it can be readily avoided. The internal branch passes beneath the thyro-hyoid muscle with the superior laryngeal artery, between the greater cornu and the thyroid cartilage, and pierces the thyro-hyoid membrane, going to its distribution. Often the superior thyroid vein, and sometimes the middle, lies in the way. In this instance a careful examination of the floor of the operation field disclosed the external laryngeal nerve lying quite vertically along the inferior constrictor, with the superior thyroid vein lying transversely somewhat higher up. The former was raised, pulled aside and held, the latter tied between two ligatures and pushed aside. A half-inch incision was then made through

the thyro-hyoid membrane, just below the great cornu, avoiding the internal branch of the laryngeal nerve and the attendant artery, into the pharynx.

Through this opening the index finger was carefully introduced and the tumor lying in front was closely examined. It extended from side to side, encroaching more pronouncedly upon the right, was quite immovable and appeared to be located immediately posteriorly to the larynx and firmly attached to it. It was at once evident that it could not be entirely removed by cold or hot snaring, and therefore removal by enucleation was next considered. The incision into the pharynx was extended downward to opposite the point of supposed contact of the growth to the wall of the pharynx, thus exposing the right side of the tumor with the mucous membrane reflected above it. Through this opening the index finger was introduced between the tumor and the reflected membrane, and with patient though somewhat rigorous caution the tumor was completely enucleated, leaving intact the entire membranous envelope, a fact quickly proven by introducing into the sac fluid from which none escaped, except at the point of its entrance.

The Remarks.—The enucleation showed that the growth began at the right side of the posterior surface of the cricoid cartilage and increasing gradually in size had remained covered with the expanding overlying mucous membrane of its inception, becoming attached as it increased to the posterior surfaces of the arytenoid cartilages and the intervening structures. The right half of the growth was so firmly held in position by the right ala of the thyroid cartilage that it was necessary to divide with scissors the ala at a point just internal to the junction of its cornu before the growth could be raised from its bed.

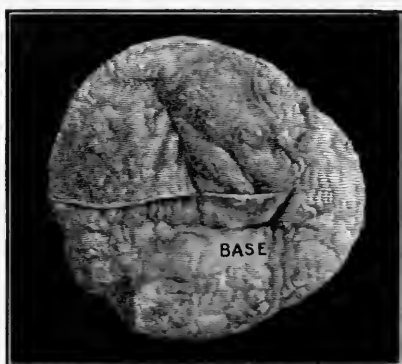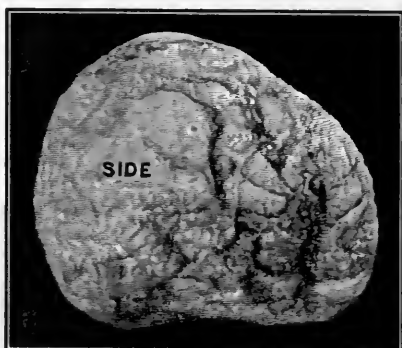
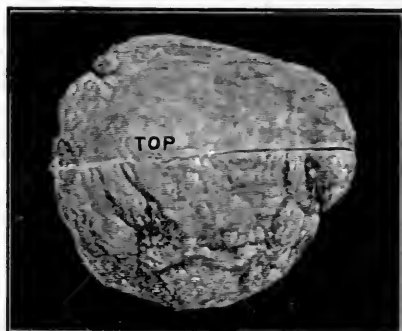


FIG. 829.—Growth removed from posterior aspect of larynx by low subhyoid lateral pharyngotomy. Weight, 425 gr.; diameters, $1\frac{1}{4} \times 1\frac{1}{4} \times 1\frac{1}{2}$ inches. Photograph taken after preservation in formalin. Top and base show lines of section.

The opening into the pharynx was closed with fine interrupted chromicized catgut sutures; the superimposed structures by buried catgut and superficial silkworm-gut sutures. A textile fabric drainage agent was introduced into the sac after removal of the tumor, and the remaining portion of the external wound was lightly packed with gauze. The borders of the divided cartilage were closely united with a chromicized catgut suture. The direct pharyngeal portion of the wound healed promptly. At the end of the third day a limited portion of fluid injected into the sac entered the pharynx through a small opening at the lower part, caused, no doubt, by sloughing, since the foul odor of the breath suggested this process. On the fifth day fluid injected into the sac likewise entered the larynx, causing evidences of strangling. No doubt limited sloughing of the anterior wall of the sac happened about this time. However, care in washing prevented unpleasant results from this cause. The entire wound substantially closed at the end of nineteen days, the patient returning home.

According to Haubold, the first authentic case of low lateral pharyngotomy was by Cocks in 1856, for removal of a false-tooth plate. The next was by Wheeler in 1875 for the removal of a needle from the pharynx. This operation involved only the making of a small opening into the pharynx. Justi in 1882 made a low lateral pharyngotomy for removal of a plum pit from the pharynx. In 1884 Wheeler removed successfully a spindle-celled sarcoma the size of a small egg from the pyriform sinus of the pharynx by means of a low lateral pharyngotomy. In 1886 Wheeler excised a diverticulum of the pharynx by an incision for low lateral pharyngotomy and the patient recovered. In five previous cases all recovered.

This case appears to be the first of removal of a tumor from the posterior surface of the larynx by the means of low lateral pharyngotomy.

OPERATIONS ON THE NOSE

Plugging of the Posterior Nares (Fig. 830).—Plugging of the posterior nares is practiced for the arrest of obstinate epistaxis. The tampon or plug can be made of sponge, lint, or of suitable cloth, and should be of a proper size to closely fit the posterior naris of one side, which in the adult is about three quarters of an inch long and half an inch wide. The plug is made by tying a strong ligature around the middle of the selected aseptic material suitably arranged for the purpose, the ligature including within its grasp at opposite sides of the plug the loops of two other strong ligatures, which are in turn tied firmly to the primary one; the ends of the latter after tying are cut short. A plug of simpler construction than this is often employed (Fig. 830). The cannula of Belloeq (Figs. 830 and 831, *c*), with the spring withdrawn, is then carried along the floor of the nostril to the posterior wall of the pharynx, when the movable rod is projected forward into the mouth. The extremities of the loop at one side of the tampon are passed through the eye of the instrument, with which they are drawn through the meatus by first returning the central rod and then withdrawing the instrument itself. The tampon is now carried into position by pulling on the strings which have their exit through the nose, aided by the finger carried behind the soft

palate. Sufficient traction is made to forcibly close the posterior nares; the strings in front are then tied around another plug similar to that already used, by which means the anterior opening is closed as well. The plug should be well carbolized before introduction, and, if need be, can be wet with an astringent solution. The plug is removed at the end of forty-eight hours by pulling downward on the strings remaining in the mouth supplemented with backward pressure by an instrument introduced along the floor of the nostril. If the cannula of Bellocq be not available, a long, flexible probe, an ordinary gum catheter (Fig. 831, *c*), or even a common wire, may be utilized in its stead (Fig. 831, *c*). Sometimes the string is carried preferably through the nostril and out of the mouth by means of the cannula, etc., or other instrument, and then attached to the plug, instead of being tied to it before the cannula is introduced.

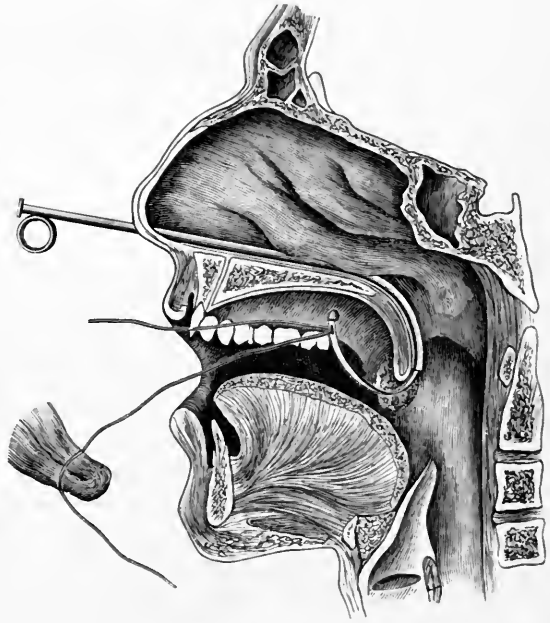


FIG. 830.—Plugging posterior nares.

The Remarks.—If the plug be introduced too tightly, sloughing of the mucous membrane may ensue, followed even by necrosis of the bones; also, the removal may cause quite severe bleeding. If hæmorrhage recur after removal of the plug, the nares should be thoroughly cleansed before another is introduced, to obviate the danger of sepsis, a risk that is proportionate to the length of time that the plug is allowed to remain in place unchanged.

The Removal of Nasal Polypi (Forceps or Snare).—If the polypus or the pedicle be small, the growth can be quite readily removed by the forceps or the snare.

If the forceps be employed, the patient should sit in a chair exposed to a bright light, with the head supported by an assistant, and, after spraying the nares with a strong solution of cocaine, the point of attachment of the growth is seized and twisted off by turning the instrument repeatedly on its long axis. *If the growth be attached to the turbinated bone*, it may be necessary to twist and pull away the bone structure before the tumor can be removed. In such a case as this, the patient should be placed in the recumbent position and with the head so turned as to cause the blood to flow from the nose instead of into the pharynx. An anæsthetic should be em-

ployed. One blade of the forceps is passed carefully beneath the turbinated bone, the other at the opposite side, and when closed firmly the bone is twisted away along with the large, and often with numerous small growths. If the growth be situated far back or hang down into the fauces, it may be detached by the finger passed behind the soft palate. If this plan fail, the tumor may be snared. In snaring, the wire loop (Fig. 831, *c*), without or with the cannula (Fig. 833), is passed along the floor of the nose and over

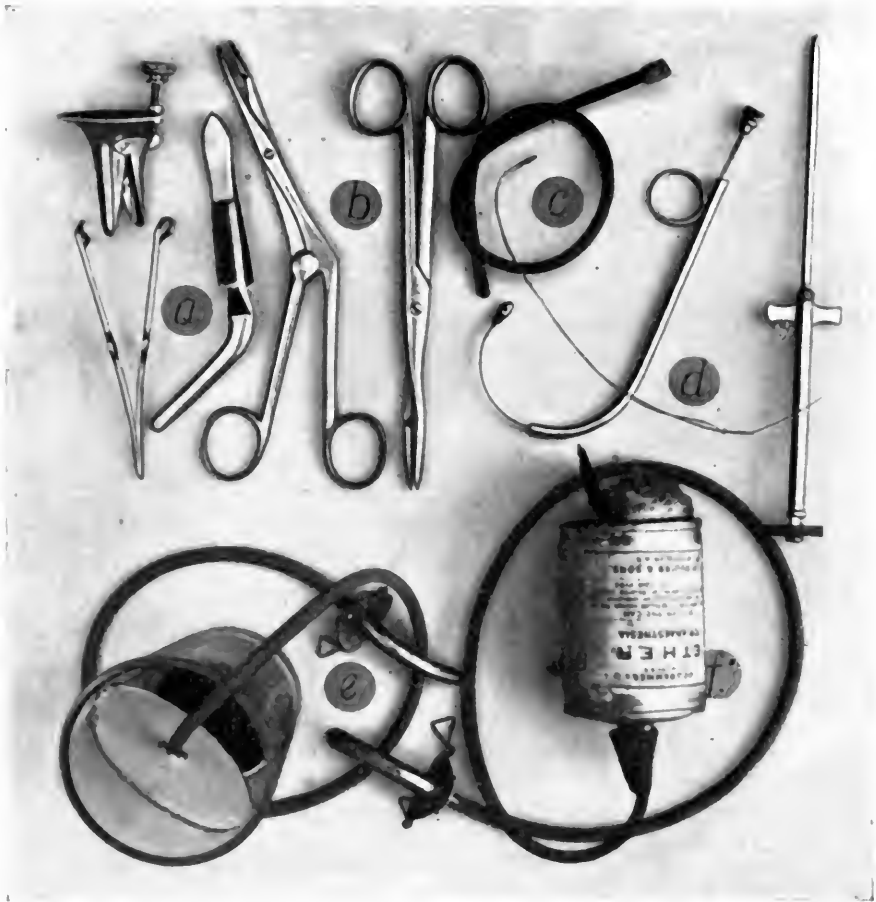

FIG. 831.—Implements employed in plugging nares and in removal of nasal growths, etc.

a. Nasal specula. *b*. Straight and curved polypus forceps. *c*. Gum catheter, Bellocq's cannula, and wire loop for plugging. *d*. Polypus snare. *e* and *f*. Extemporized tracheal anesthetizing apparatus.

the tumor by aid of the finger. The loop is tightened and the growth severed. The growth may be strangulated by means of intertwined loops placed around the pedicle as indicated in Fig. 834. The greater length of time required and the offensive odors that often attend the removal do not commend the method.

The Removal of some Nasal and Naso-pharyngeal Polypi.—In addition to instruments employed in removal of nasal growths (Fig. 831) there may be also required instruments for ligature of vessels (Fig. 175); for excision of the jaw (Fig. 378); chisels and mallet (Fig. 450), and for tracheotomy and tracheal anæsthesia (pages 682 and 652). An abundance of forcipressure, ligatures, antiseptic wipers (Fig. 73), and gauze, should

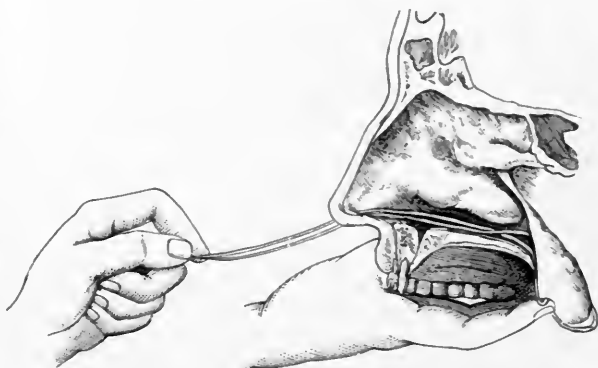


FIG. 832.—Loop guided over polypus with finger.

be provided. If the growth be fibrous and not amenable to treatment by the previous methods, or be of naso-pharyngeal origin, it can then be exposed either by way of the nasal palatine or maxillary routes. *The nasal route* is best suited to the removal of growths limited to the nasal cavity. They may be reached by *turning the cartilaginous part of the nose aside* (Desprez).

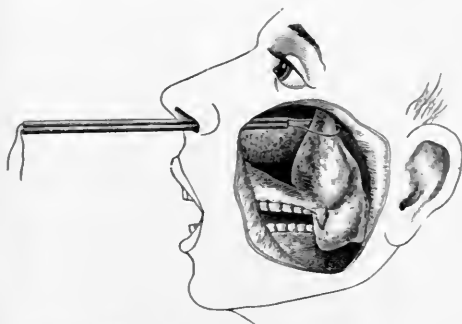


FIG. 833.—Double cannula in position.

junction of the cheek and nostril, and thence cut downward, ending in the nasal orifice of the opposite side; separate the cartilaginous from the bony part of the nose by means of scissors, and the inferior attachment of the septum for the proper distance by the same means. The end of the nose is freed and turned to the opposite side, and, if additional space be required, the turbinated bones are removed. After removal of the growth, the end of the nose is replaced and united with sutures to the divided borders.

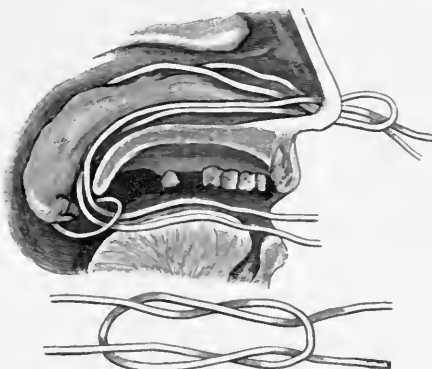


FIG. 834.—Application of loops for tying pedicle.

Chassaignac's Method.—Chassaignac carried an incision from near the inner canthus of one eye directly across the root of the nose to a point corresponding to that of starting, thence downward along the outer side of the nose through the alar groove across close beneath the end of the nose to the



FIG. 835.—Chassaignac's method.
The incision.

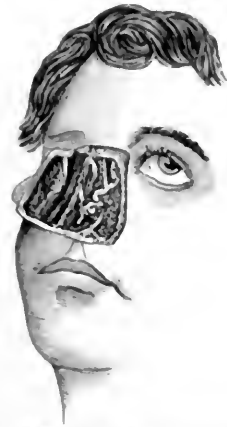

FIG. 836.—Chassaignac's method.
Flap turned aside.

opposite ala (Fig. 835). He divided the bones in a line corresponding with the incision of the soft parts, also the septum, and turned the nose to the opposite side, thus exposing freely the nasal cavity (Fig. 836).

After the removal of the growths the parts are restored to their normal position and the edges of the wound united. *If this method be not deemed advisable, the nose can be turned downward by making a U-shaped incision down to the bone, the convex portion of which shall cross the root of the nose between the eyes, while the arms extend downward at each side of the nose to the outer borders of the alæ (Ollier) (Fig. 837, a).*

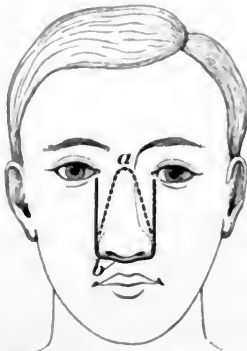


FIG. 837.—a. Ollier's method.
b. Lawrence's method.

The bones are then sawed through in the line of the incision, the septum liberated at their under surface, and the nose turned downward, so as to expose the interior of the nasal cavity to observation and manipulation. If the growth be a large one and greater space be necessary, the incision can be modified (Fig. 842, a), as shown by the dotted line, and the bones lying in its course sawed through, as before described, care being taken to avoid the roots of the teeth. After the removal of the growth the parts are replaced and confined in position by sutures, dressings, etc. Naso-pharyngeal polypi can sometimes be removed by this method.

In 1873 Rouge described the following method applicable to the removal of diseased bone, obstinate polypi, and even small naso-pharyngeal growths when located well in front:

Rouge's Method.—With the patient's head turned to one side and the upper lip drawn forcibly upward by an assistant, the surgeon carries a curved scissors close to the bone through the space lying between the bicuspid teeth of the respective sides, severing the soft parts up to and opposite the nasal bones. At the same time the cartilaginous septum is detached from the nasal spine, thus permitting the end of the nose to be turned upward toward the forehead, thereby exposing the anterior nares to free examination (Fig. 838). After removal of the growth, the parts are restored to their normal place and held there by careful bandaging.

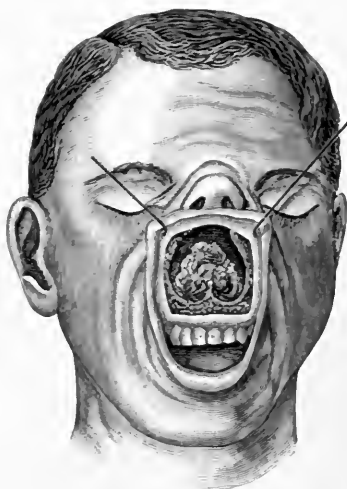

FIG. 838.—Rouge's method.

Langenbeck's Method (Fig. 839, a).—Make an incision from near to the center of the root of the nose obliquely downward and outward on the outer side of the nose and cheek to a point external to the ala nasi. Separate the upper border of the flap a short distance, leaving the periosteum; sever the alar cartilage from the nasal bone, and with bone nippers sever the nasal bone from its fellow. Also in the same manner divide the nasal process of the superior maxilla at its base through to the margin of the orbit (Fig. 840). The entire upper part of the nasal cavity can then be exposed by raising upward the quadrilateral piece of bone thus formed of both the nasal bone and process

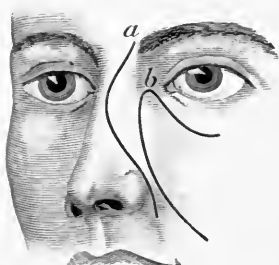


FIG. 839.—a. Langenbeck's method.
b. Boeckel's method.

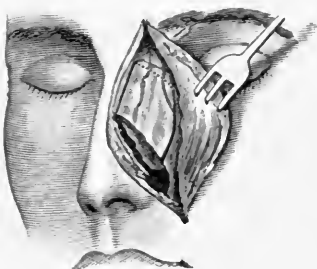

FIG. 840.—Langenbeck's method.
Flap turned aside.

together. After the tumor is removed the bone flap can be returned and fastened in its proper position.

Lawrence's Method (Fig. 837, b).—From a point just internal to the lachrymal sac, make an incision along each side of the nose to the junction of the ala with the lip. Sever the nasal bones and the nasal processes of the superior maxillæ with bone forceps, thus opening into the nasal cavity. Divide the septum and turn the nose upward.

The Comments.—Rouge's method leaves no scar and the parts are readily adjusted without sutures. The nose, however, should be supported in

proper shape until union takes place. The amount of room provided by these operations is limited, therefore a careful determination of the connections of the growth must be made before operation, to avoid unwise or needless mutilation.

The palatine route is suited for the treatment of more difficult cases than is the nasal one. Naso-pharyngeal as well as nasal growths are approachable through this channel of procedure.

Nélaton's Method (Fig. 841, a).—Make an incision in the median line through the uvula and soft palate down to the bone (a); continue it forward along the posterior half of the hard palate; two other incisions, one on either side, are now carried obliquely outward from the anterior extremity

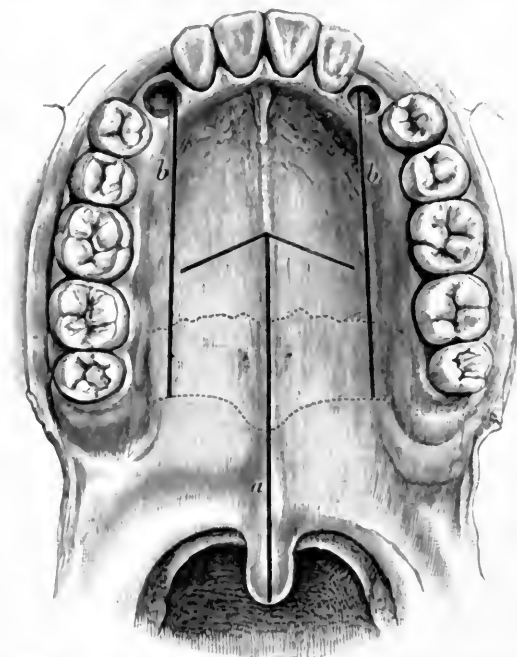


FIG. 841.—a. Nélaton's method. b. Chalot's method.

of the first to the respective alveolar processes; these flaps, including the periosteum, are reflected outward with a rugine; the hard palate is perforated and cut away; the periosteum and mucous membrane of the floor of the nose are turned aside, the septum is removed if necessary, the tumor exposed to view and excised. The periosteal flap of the hard palate should be returned to the normal position and stitched in the usual manner. The cut through the soft palate can be joined then or subsequently, accordingly as the operator desires. If the growth be a small one, but one side of the hard palate need be attacked.

Chalot's Method.—Divide the gingivo-labial fold and separate the upper lip from the bone at a point corresponding to the anterior nasal spine, thus opening into the nasal fossæ in front. Draw the canine teeth, open the mouth widely, and make an incision down upon the under surface of the hard palate at either side close to the alveolus, beginning at the empty socket of the canine tooth, and terminating at the posterior border of the bone (Fig. 841, b, b); divide the alveolus and hard palate at either side in the line of incision with chisel and mallet; separate the bony flap thus formed from its connections with the vomer and nasal mucous membrane; displace it downward and backward into the mouth, the velum acting as a hinge; remove the growth; restore and fasten the bone flap in place with wire sutures. This procedure is ingenious and effective except when the growths are large and

located at the vault of the pharynx. The degree of hæmorrhage in this operation is an important item, and suggests the advisability of tracheotomy and a pharyngeal tampon as wise preliminary measures, especially as the presence of the bone flap will impede the manipulations of the surgeon.

Annandale's Method.—Expose the anterior nares as advised by Rouge (page 655); divide the bony septum at its connections with the maxillæ; open the mouth widely and make an incision in the median line of the hard palate down to the bone; remove a middle incisor if need be, and divide the alveolus and hard palate in the median line with a small saw introduced through the nose. The soft palate is not disturbed unless the size or position of the morbid growth calls for it. The maxillæ are pried apart or drawn asunder with hooks, if required, carefully avoiding displacement of the nasal bones by severing their connections with the nasal processes of the superior maxillæ, if called for, the tumor is exposed and removed with forceps, scissors, scoops, etc. Thorough disinfection, and packing with antiseptic gauze follows the removal, succeeded by restoration and wiring of the bones in the proper position. The soft palate should be closed at the same time if the condition of the patient does not contra-indicate it. This operation offers the most room of any by this route, with no loss of structure or resulting deformity.

The maxillary route is selected when the size and nature of the growth render the preceding ones dangerous on account of the hindrance due to the limited space available for operation. A preliminary tracheotomy is advisable if the tumor be large, of broad origin, or unusually vascular.

Boeckel's Method.—Make an incision down to the bone from near the root of the nose along its side to the groove of the nostril and cheek, thence in a curved direction outward and backward on the cheek to a point vertically below the middle of the orbit (Fig. 839, *b*). A second incision, beginning at the upper end of the first, is carried outward along the lower margin of the orbit down to the bone; raise the flap with the periosteum from the bone with a rugine or periosteotome, exposing the lower portion of the nasal bone and the entire width of the nasal process of the superior maxilla, carefully avoiding the lachrymal sac and the infra-orbital nerve; define the bone flap (Fig. 385, *D*) with chisel and mallet, commencing at the inner border of the infra-orbital canal and going vertically downward to opposite the floor of the naris, thence inward to the naris itself; then divide the bone in front of the lachrymal sac, the nasal process its entire width, and finally cut downward and inward through the lower portion of the nasal bone by similar means, the chisel going into the nose throughout the entire course of the bony incision. Remove the bone section, thus exposing the nasal cavity, which exposure can be still further increased by removal of the turbinated bones. After removal of the growth the opening is closed by returning and suturing in place the periosteal flap.

Langenbeck's Operation.—Make a slightly curved incision with the convexity downward, extending from the ala of the nose to the malar bone, and thence as far backward as the middle of the zygoma. A second incision is made, beginning near the center of the root of the nose, and, passing along

the inferior margin of the orbit, to join the former near the middle of the malar bone (Fig. 842, *c*). These incisions should extend down to the bone; the soft parts, however, are not to be raised, with the exception of the periosteum of the floor of the orbit, which should be raised if the orbital plate is to be removed. Separate the masseter muscle from the malar bone; divide the buccal fascia; depress the inferior maxilla and pass a pointed elevator, or the finger if possible, into the posterior nares, carrying it by way of the lateral opening through the pterygo-maxillary fissure into the sphenomaxillary fossa, thence through the sphenopalatine foramen, all of which passages may have been distended by the morbid growth. A small keyhole saw is passed by the same route, and the superior maxilla divided from behind forward in the line of the lower skin incision (Fig. 385, F, F). The extremity of the saw is covered by the end of the index finger carried into the pharynx through the mouth, to protect the tissues from being injured by it. The zygomatic process of the temporal, frontal process of the malar, and orbital plate of the superior maxilla are then sawed through from behind forward to the lachrymal bone, the saw here being made to pass in its course through the sphenomaxillary fissure. Or the superior maxilla can be divided in the

line of the superior incision of the soft parts, thus leaving the orbital plate intact. The osteo-cutaneous flap is now raised by an elevator carried beneath the malar bone and slowly lifted upward and inward toward the nose, the bones and soft parts of which form a hinge to the flap at that side. If the saw can not be passed into the posterior nasal cavity even by the aid of a grooved director, the lips of the incision of the soft parts may be drawn asunder, and the bone sawed from without inward and before backward.

The Comments.—The operation is usually attended by quite severe hæmorrhage, which, however, can be controlled readily by pressure and an occasional ligature. After the removal of the growth, the parts are adjusted and confined in position by sutures, etc. If the growth to be removed be a large and vascular one, a preliminary tracheotomy should

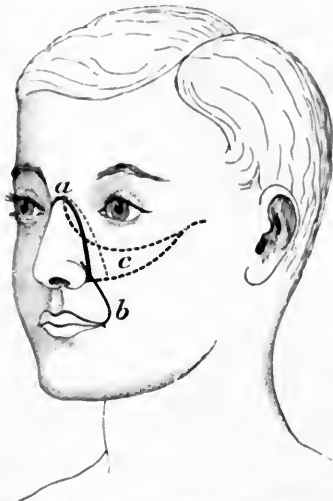


FIG. 842.—*a*. Ollier's incision. *b*. Guérin's incisions. *c*. Langenbeck's incision.

be done. If it be malignant or very vascular, and have a large attachment, we deem it a wise precaution to tie both external carotids prior to removal. The dangers from hæmorrhage will be lessened by this measure, and, moreover, the diminished vascularity of the parts will hinder the redevelopment of the growth. *Dawbarn* practices the removal of these vessels and for similar reasons.

The division of the bones can be readily and advantageously done with an osteotome and mallet (Fig. 450), especially when the spaces at the back of the jaw are not sufficiently distended by the growth to permit a wise use

of the saw. The difficulty of raising the flap and of returning and properly adjusting it, thereby incurring the dangers of necrosis, with consequent sepsis and non-union, are objectionable features of the measure.

The Results.—The rate of mortality from this method is less than twenty-five per cent, and depends more on the dangers arising from the removal of the growth than those the result of the steps necessary to reach it. The mortality is greater when the operation is done through the hard palate than when performed by means of the displacement of the upper jaw.

Guérin's Method.—Make an incision along the facial line from the ala of the nose to the angle of the mouth; dissect up the soft parts, opening the nostril, and bare the malar process of the superior maxilla; introduce a saw or chisel into the nose and divide entirely the maxilla horizontally backward below the infraorbital canal; separate, through the mouth, the soft from the hard palate with a scalpel; remove a middle incisor tooth and divide the hard palate in the median line with a saw or chisel. The fragment is then taken away with lion-jaw forceps.

The Remarks.—This operation is an excellent one so far as deformity is concerned, and can be practiced even without division of the lip. The employment of an artificial appliance to the roof of the mouth will remedy the resulting defect in speech (page 373).

Kocher's Method.—Place the patient in Rose's position and divide the upper lip from above downward; sever transversely down to the bone the reflection of the mucous membrane above the alveolar process; with a chisel cut through obliquely on a level with the nasal process the superior maxillary bones (Fig. 843); divide the alveolar process and the hard palate in the median line and draw the bones apart with hooks; incise the mucous membrane of the floor of the nasal fossa close to the septum, and push the vomer to the opposite side, thus exposing freely to observation the naso-pharyngeal space. After removal of the tumor, restore and fasten the parts in position with wire or an interdental splint.

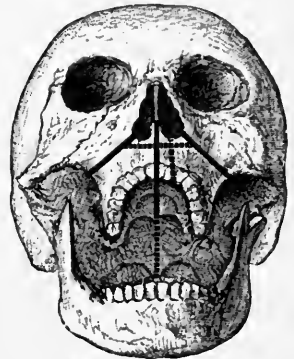


FIG. 843.—Kocher's method.

Cheever's Method.—In Cheever's case both superior maxillæ were removed, owing to the large size and central situation of the growth. Cheever made an incision from near the inner canthus on each side of the nose, downward along the natural furrow, around the alæ to the median line of the lip, which he divided. These flaps were reflected upward and outward as far as the malar prominences, and the body of each superior maxilla was sawed from behind forward to the middle meatus of the nose; the septum and vomer were cut with scissors; the jaws were then depressed and the tumor removed, after which the bones were replaced and wired in position. The loss of blood was not great, but the patient died on the fifth day from exhaustion.

The General Comments.—The excision of the entire upper jaw may be practiced for the removal of neoplasms, or only the portion below the line

of the orbital floor may be removed. The superior maxilla can be raised and turned outward on a hinge formed by the zygomatic process of the malar bone and the contiguous soft parts by dividing the bone in the line of Ferguson-Webber's incision (Fig. 380, *b*, *b'*), the upper portion of which, for this purpose, should be extended to the malar bone. The maxillæ are separated by sawing through the hard palate and alveolar process, and the nasal bone is disconnected from the superior maxilla by severing its connections with bone forceps. The osteocutaneous flap can then be raised and swung outward. If necessary, the soft palate may be divided. After the removal of the growth, the parts, including the soft palate, are adjusted and joined by sutures.

With the view of avoiding as far as possible the division of the terminal filaments of the superior dental nerve, and obviating the loss of function incident thereto, Langenbeck recommended that a curved incision be made, crossing the cheek about midway between the angle of the mouth and the lower border of the orbit, beginning near the lower end of the nasal bone and extending downward and outward and then upward, so as to avoid Steno's duct. The flaps are dissected from the superior maxilla, which is removed through the opening made in the soft parts. If the whole bone is to be excised, the integrity of the superior maxillary nerve can be still further preserved by removing it in advance from the infra-orbital groove by the aid of a fine, sharp chisel.

The removal of a growth of any great size from the posterior nares or pharynx, especially the latter, will be attended, if its attachment be extensive, by the entrance of a large amount of blood into the pharynx and trachea; it is therefore wise to do a preliminary tracheotomy, so that the lower extremity of the pharynx may be closed by sponges or otherwise tamponed. If the shoulders be elevated and the head allowed to fall far backward, the blood can be removed from the dependent portion of the pharynx as fast as it collects; this position, however, impedes respiration by overextending the muscles that act on the os hyoides. If a preliminary tracheotomy be done, the anæsthetic must be administered through the tube. The apparatus devised for this purpose by Trendelenburg (Fig. 877) may be used entire, or only the inhaling portion attached to the ordinary tracheotomy tube can be employed; the latter plan is generally to be preferred, since the rubber tampon attached to this tube often causes bronchial irritation when inflated; moreover, if it become ruptured during the course of an operation, or be imperfectly distended, blood may enter the trachea unawares.

Extemporized substitutes for this purpose can be provided if a rubber tube of suitable size and length be attached by one extremity to the tracheotomy tube, and the other be inserted loosely into the bottom of an empty quarter-pound ether can and fastened there, and a sponge be introduced into the can and kept moistened with ether (Fig. 831, *f*). The anæsthesia thus produced will be eminently satisfactory and the outlay nominal. In the absence of the ether can, pass the end of the rubber tube through a tightly fitting opening in the center of a pasteboard diaphragm properly

adjusted to a glass tumbler in the bottom of which rests a sponge moistened with ether (Fig. 831, *e*).

The choice of operation is regulated largely indeed by the size, situation, attachments, vascularity, and nature of the growth. If the growth be comparatively small, with a well-defined pedicle, and accessible through the nose, this channel may be adopted. Annandale's, Boeckel's, and Guérin's methods are suited to the treatment of large naso-pharyngeal growths. Langenbeck's method is quite commonly practiced, and is an admirable one, especially when the naso-pharynx is much distended by the growth. The removal entirely or the swinging outward or inward of the superior maxilla, after free incision, affords a fine exposure of the naso-pharynx, especially the removal of the bone. In one instance the author practiced removal with great operative satisfaction, and followed with but slight cosmetic defect.

The after-treatment is essentially that for removal of the jaw (page 372).

The Results.—About twenty-five or thirty per cent die from the operation. Here, as in excision of the jaw for other reasons, septicæmia, etc., claim a share of the victims. According to Lincoln, twenty per cent die from the operation, and in about thirty-six per cent the disease returns within twelve months after the operation. We are disposed to regard the latter figures as having a decidedly optimistic expression.

Deviation of the Septum Nasi.—It not infrequently occurs that both the bony and cartilaginous portions of the septum are deflected to such an extent as to seriously interfere with breathing through the nose during attacks of coryza, and likewise to impart a distinct nasal twang to the voice. This deformity may or may not be associated with external modifications of the nasal symmetry. In either case the indications remain the same: to overcome the deformity and to maintain the corrected relations of the parts until recovery takes place.

The Operation.—The deformity can be overcome by grasping the abnormal septum between the blades of a forceps especially designed for the purpose (Fig. 845, *f*), which are thrust into the anterior nares and closed upon the deformed septum and held for a few moments with sufficient firmness to press its irregularities into a normal position. This resistance is still further overcome by cautiously turning the forceps from side to side on its long axis. The pressure exerts a crushing and compressing influence on the septum, permitting of its being pressed into a normal position. The retentive apparatus is a specially constructed clamp (Fig. 844), which is screwed into position while grasping the septum. This instrument retains the part thus rectified until the reparative processes necessary to permanency shall have taken place. The clamp may remain in position two or three days, not tightly screwed, for this would cause ulceration, but closely enough to exert a gradual controlling influence on the structure. This indication can likewise be well met by introducing into each nostril rubber tubes of proper size and length, sur-

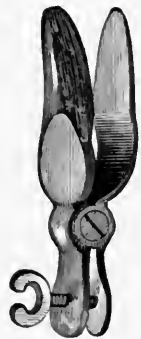

FIG. 844.
Adams's clamp.

rounded by oiled lint. After three or four days either of the preceding appliances should be replaced by splints (Fig. 845, *e, h, d*), which are pushed into each nostril and worn at night only. This treatment is annoying and even attended by positive discomfort, but the good result will amply repay the patient for the infliction incurred. Other operations are recommended, such as the removal of the inferior turbinated bone on the side of the deflection; or punching the septum to establish a communication between the closed and the unclosed nostrils. Neither of these acts rectify the deformity, and both are open to objections, the former of a physiological, the latter of a mechanical nature. The removal of the projecting portion of the cartilage and its mucous membrane is likewise commended. The taking away of the deformed septum, together with a portion of the superior maxilla

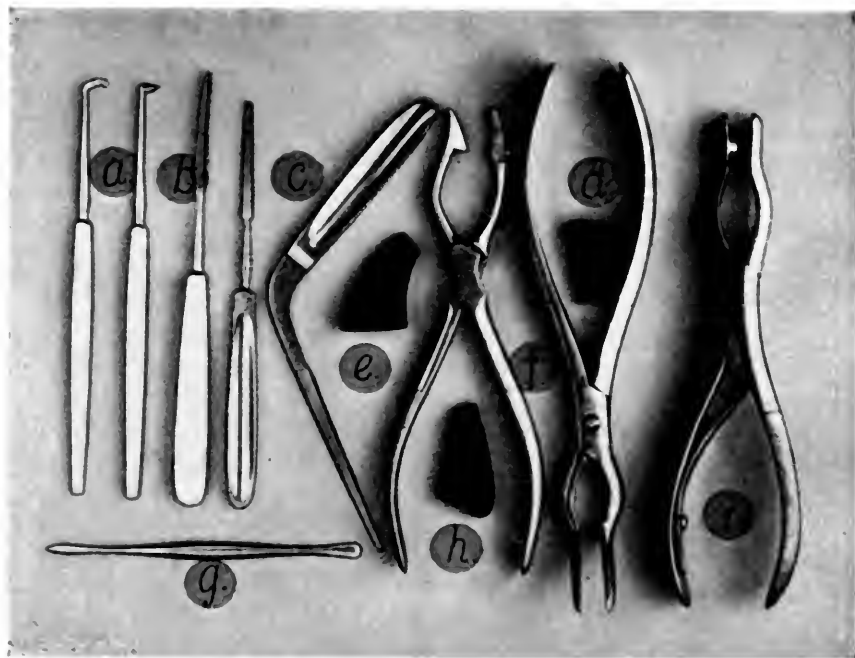

FIG. 845.—Instruments employed in treatment of deviation of the nasal septum. *a.* Douglass's knives. *b.* Mial's and Curtis's saws. *c.* Bosworth's saw. *e, h, d.* Asch's, McKernon's, and Douglass's nasal splints. *f.* Asch's scissors and septum compressor. *i.* Douglass's perforator. *g.* Elevator.

(Post), accomplished by separating the side of the nose from the cheek, and turning the nose over, thus gaining access to the obstruction, constitutes an operation whose severity is out of proportion to that of the primary difficulty, and may be followed by an unsightly scar. It is recommended also that the meatus be burred out (Wagner) by means of the dental engine. The reported results certainly give strong testimony in favor of this proposition. The deformed portion of the septum may be sawed off on a plane conforming to that of the remaining portion by first applying a strong solution of cocaine to it, then removing the deformity

with a narrow, fine saw (Fig. 845, *c*) constructed especially for the purpose. This plan is practiced by Bosworth, and it appears to be preferable to burring or punching the septum.

THE OPERATIONS ON THE ŒSOPHAGUS.

The nature of the functions and the important intimate anatomical environments of the œsophagus contribute greatly, indeed, to the difficulty of treatment of this passage, and also favor the development in it of obstructive changes of grave import. The anatomical relations of this tube should be carefully considered, and the possibilities of a cure cautiously weighed, before active interference is begun. Otherwise, what appears to be a simple matter and quickly curable may by illogical effort become suddenly of the greatest import and of irremediable nature.

The Anatomical Points.—The œsophagus begins at the cricoid cartilage on a level with the sixth cervical vertebra. It lies in the median line at the beginning, but bears off half an inch toward the left in the cervical region; then returns to the median line at the fifth dorsal vertebra and again tends slightly toward the left as it passes through the diaphragm, terminating opposite the ninth dorsal spine behind, which corresponds to the left seventh chondro-sternal junction in front. In a sagittal direction the œsophagus corresponds to the curves of the portions of the spinal column with which it is associated. The average diameter is about four fifths of an inch; the smallest—a little more than half an inch—is wisely placed at the beginning of the tube; the second narrowing is opposite the fourth dorsal vertebræ, the third at the diaphragm. The narrowest parts can be dilated to three fourths of an inch and the remainder to an inch and a half in the dead subject. The transverse diameter exceeds the antero-posterior. Since these measurements are based on post-mortem experiments, they can be regarded only as indicating rather than establishing the limits of dilatation, a fact which is emphasized frequently in the living by the ready passage along the œsophagus into the stomach of articles of much greater dimensions than are those assigned to the passage itself. *Ogstan* considers that food traverses the normal œsophagus in about four seconds. *Cannon* and *Moser* determined that fluids “are propelled deep into the œsophagus” at the rate of seven feet per second. With the finger on the larynx and the ear at the back, swallowing time may be told.

The consultation of a text-book on anatomy will promptly suggest those important relations which, in the presence of disease or invasion, invite disaster if unwisely disturbed. The trachea, carotid vessels, aorta, pericardium, left bronchus and mediastinum, are of special importance in this regard.

Foreign Bodies in the Œsophagus.—The nature, shape, and size of the foreign body, together with the situation and time of impaction and the symptoms, must be ascertained with deliberation if the condition of the patient will permit. Foreign bodies are arrested commonly at the narrowest part of the œsophagus, therefore, usually at the beginning. At this situation the foreign body can be easily touched with a probang and often with the index finger, although not without causing the patient distress if con-

sciousness be present. Careful examination of the left side of the neck, behind the cricoid cartilage, will often disclose the presence of the obstruction. When situated lower down, the probang and bougie will establish the fact (Fig. 846). After failure of the simpler means of removal—i. e., external

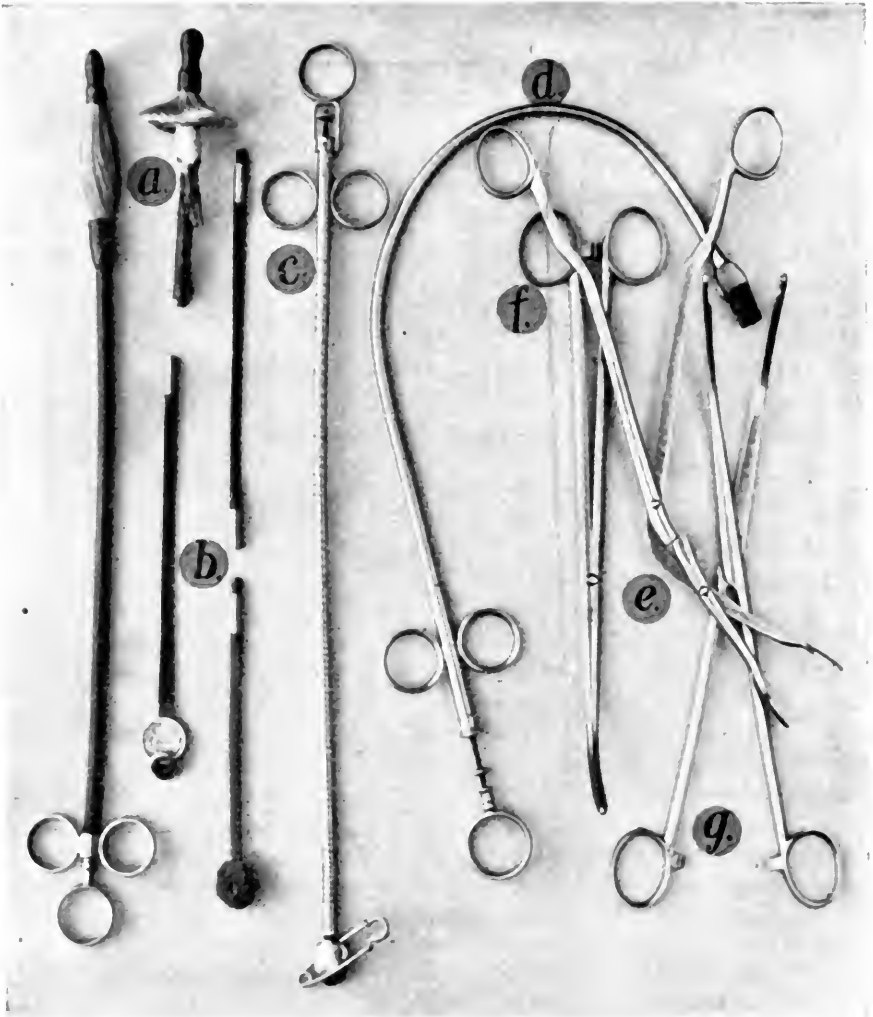


FIG. 846.—Instruments employed in removal of foreign bodies from œsophagus. *a*, Bristle probang, opened and closed. *b*, Coin catcher and sponge probang, whalebone. *c*, Roe's flexible coin catcher. *d*, Tiemann's flexible cork-catching forceps. *e*, Cusco's throat forceps. *f* and *g*, Curved throat forceps. Curved forceps of different patterns may be employed.

manipulation, emesis, etc.—the obstruction is usually removed at the higher situation with throat forceps designed for the purpose (Fig. 846, *e*), or by the bucket probang (*b*), or by a loop of wire, or other simple devices of this character. However, if the obstruction have been lodged here for some time,

consequent swelling of the soft parts, or irregularities of the foreign body, may render removal by way of the mouth impossible. The same may be said also of foreign bodies located elsewhere in the tube. The bristle and the sponge probang (Fig. 846, *a, b*) are the common implements for removal under these circumstances. The X-ray is very useful in these cases.

The Remarks.—It is seldom indeed that a foreign body causes complete occlusion of the œsophagus. Those too large to enter it encroach not infrequently on the larynx and cause death from suffocation. The lodgment of an article near the cardia is specially dangerous because of the proximity of the heart, great vessels, and pleura. While all bodies, irrespective of their physical characteristics, lodge most frequently at the established narrowings of the œsophagus, irregular and sharp ones may lodge between these points, but round and flat ones do not. External manipulation for removal is applicable only to the obstructions located in the cervical portion, and should not be practiced in the event of firm impaction or when marked asperities characterize the obstructing agent.

The Introduction into the Œsophagus of Instruments.—The introduction of an instrument into the œsophagus is usually a simple procedure.

A Method of Introduction of a Stomach Tube.—Place the patient in a good light while in a chair or sitting up in bed; tip the head backward and

give it in charge of an assistant; gag the mouth; seize the tongue (guarded from slipping with a dry cloth) with the thumb and fingers and draw it forward, thus advancing the larynx; grasp the previously warmed and oil-smearred instrument lightly in the right hand; carry the end downward and backward to the posterior wall of the pharynx; push it along as the patient gags, and cause him to swallow as the advancing extremity engages in the lower part of the pharynx; advance the instrument with gentleness, heeding the presence of spasm or other obstruction, until finally the instrument passes readily along the œsophagus into the stomach.

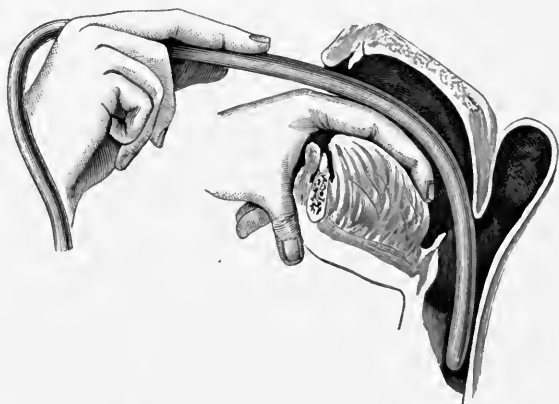


FIG. 847.—Introducing tube into œsophagus.

Other Methods of Introduction.—Instead of grasping the tongue the index finger can be introduced as a guide to the advancing instrument, as is commonly practiced in the introduction of an œsophageal bougie, conducting it safely over the larynx to the posterior aspect of the pharynx (Fig. 847). *Solis-Cohen* recommends the drawing of the larynx forward with the thumb and fingers applied without. The accomplishment by this method requires the employment of a firm and somewhat painful pressure (except perhaps in the presence of anæsthesia) that is out of proportion to the demands of the

case. The location of the obstruction can be estimated by recalling the fact that in the average-sized adult the distance from the diaphragmatic narrowing of the œsophagus to the upper incisor teeth is about fourteen inches and a half, and from the aorta and from the upper end of the œsophagus to the same teeth is nine and five and a half inches respectively. These facts are of immense importance as bearing on the relation of the obstructing agent to important organs and the liability of serious complications from the passage and from the effects of the means employed for relief.

The Precautions.—The introduction into and passage along the œsophagus of a probang, bougie, etc., and the manipulation of the foreign body should be conducted with great care and a minimum expenditure of force, otherwise perforation will ensue, and especially is this true in those cases characterized by the structural changes incident to disease and ulceration of the walls of the tube. Avoid entering the larynx with the instrument. Coughing and continued spasm of the larynx with the advance of the instrument indicate laryngeal invasion. The escape of air through a hollow instrument under these circumstances is diagnostic of entry to the larynx. Observe that the end of the advancing instrument be not curved forward, but instead that it lies in contact with the posterior wall of the pharynx. A cautious advance in the presence of spasm or other source of obstruction must always be observed. Relaxed and pouched states of the pharyngeal wall, notably at its junction with the œsophagus, oppose the progress of the bougie not infrequently, especially when the head is not well extended. Deflections and pouches of the œsophagus may interfere with the descent of the bougie, and this interference should not be opposed with vigor, for fear of causing perforation of the tube. The partial withdrawal of the instrument and the changing of its course should be practiced promptly in this instance. While cautious attempts made to dislodge an impacted body are always admissible, still in the instance of sharp and irregular impacted agents the manipulations should be much more guarded in time and method than when such bodies are regular and smooth. It is much safer to resort at once to the operative methods for extraction of the obstacle than to prolong and aggravate the case by renewed efforts of removal or by permitting the impacted body to remain, especially when it is contiguous to important structures. Sometimes the instrument becomes immovably engaged to a fixed obstruction, requiring operative procedure for the liberation and extraction of both, and the situation will decide whether gastrotomy or œsophagotomy shall be performed.

The Remarks.—The preparation of the walls of the pharynx for invasion with instruments, by a weak solution of cocaine, by titillation, the use of cold, etc., to arrest the spasm, can be practiced with discretion. If the presence of a foreign body be not noted with the downward passage of the bougie, the latter should be withdrawn to the upper end of the tube and the attempt repeated, unless disclosure attends the withdrawal. It should not be forgotten that the presence of the foreign body may escape detection, and that it may cause death from perforation of the large vessels, heart, or pleura, without the occurrence of any significant premonitory symptoms.

In children it is wise to employ an anæsthetic, as better control of them is thus maintained; in adults some assistance may be rendered by the sufferer, if not anæsthetized. Generally speaking, bristle probangs and coin catchers are used for the extraction of smaller, less fixed, and more distant bodies than those treated with the forceps.

Many ingenious plans of action for the removal of special obstructions have been devised and operated with success. Those for the removal of fish hooks and of pronged bodies swallowed with string attachments will suffice as examples of successful attempt, and are fertile with suggestion for future action. The line attached to the hook is passed through either a bullet or some other solid substance, or through a long, hollow bougie. In the former instance the weight of the bullet and the force of the effort at swallow-

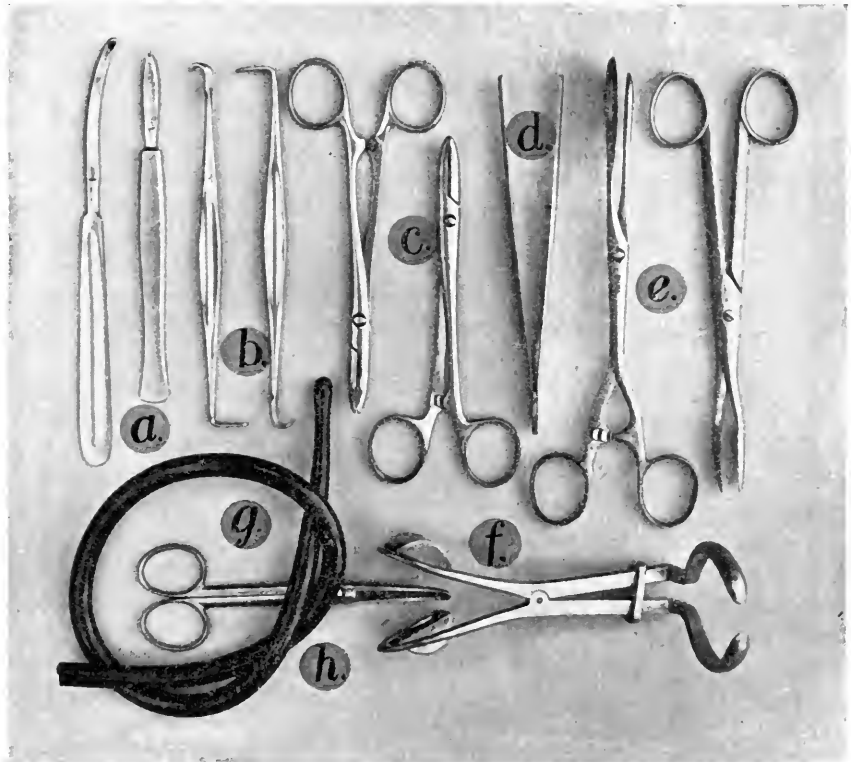


FIG. 848.—Instruments employed in œsophagotomy.

a. Scalpels. *b.* Retractors. *c.* Forceps. *d.* Mouse-tooth forceps. *e.* Tongue forceps and forceps for extraction of foreign body. *f.* Goodwillie's mouth gag. *g.* Curved scissors. *h.* Oesophageal bougie. Drainage tube, wipers, ligatures, traction loops, etc., are essential.

ing dislodge the hook; in the latter, when the lower end of the bougie reaches the hook, it disengages it by direct downward pressure (Mackenzie).

The swallowing of a sticky bolus containing strong thread with a string attached, and the entangling of the foreign body thereby and its withdrawal

along with the thread, often affords a happy solution of the difficulty (Créquy). A single thread may be swallowed with fluid (Dunham).

If a foreign body be immovably lodged in the œsophagus it must soon be taken away through an external incision, or a fatal result will ensue, due to ulceration or extravasation, or perhaps to starvation alone.

The œsophagus can be entered for this purpose from without through the neck, the thorax, or the stomach, depending on the situation of the obstruction.

Œsophagotomy.—The operation of œsophagotomy is practiced for the removal of obstructions in the cervical and upper dorsal portions of the œsophagus, commonly caused by the lodgment of foreign bodies.

The situation of the foreign body in the cervical region is usually determined by the presence of a prominence at the left side below the cricoid cartilage; or, if this be not manifest, the exact site of lodgment in the canal can be determined by the introduction into it, through the pharynx, of a good-sized bulbous or other form of bougie (Fig. 848, *h*).

The important surgical relations of the œsophagus in the cervical region are: In front, with the trachea above and with the thoracic duct and the thyroid gland below; *behind,* with the vertebral column and longus-collis muscles; *at the sides,* especially the left, with the common carotid and inferior thyroid arteries and thyroid lobes. The recurrent laryngeal nerves lie between the œsophagus and the trachea on the respective sides.

The Operation of Cervical Œsophagotomy.—After thorough aseptic measures employ an anæsthetic; place the patient on the back, with the chest and shoulders elevated and the head turned to the opposite side; feel for the foreign body, and, if it can be located, make the incision directly at that point.

If the foreign body be not discernible by touch, make an incision about four inches in length on the left side, between the sterno-mastoid muscle and the trachea, beginning at the upper border of the thyroid cartilage (Fig. 849). The platysma and fascia are divided on a director; the borders of the wound are separated, the omo-hyoid is drawn outward, and the sterno- and thyro-hyoid muscles inward; this exposes the sheath of the carotid, which vessel is drawn outward and retained; the lobe of the thyroid gland is raised and drawn inward; the larynx is carefully outlined, drawn forward, and held while the

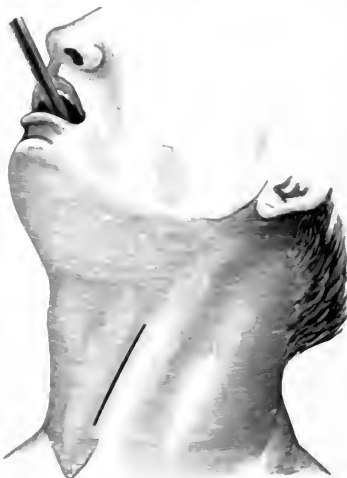

FIG. 849.—Œsophagotomy, primary incision.

location of the foreign body is sought for; if the latter be not distinguishable a bougie is introduced to mark the outline of the tube; then raise the wall with mouse-tooth forceps or a tenaculum, and open it longitudinally (Fig. 850) sufficiently to admit a good-sized probe, care being

taken to avoid the recurrent laryngeal nerve. The site of the obstruction is located by the probe and the obstruction is removed with suitable forceps, aided by manipulation from without, and facilitated by lengthening the œsophageal incision if necessary. The opening in the œsophagus may be closed with two rows of fine catgut sutures, the inner being applied to the mucous membrane only, if the borders of the incision have not been injured by manipulation or impaired by the lodgment of the foreign body; if, however, either of these conditions be present, closure should not be attempted. In no instance is it wise to close entirely the external incision, although it may be narrowed by suturing the upper portion. Antiseptic gauze is packed lightly in and over the wound, and confined in place loosely with a gauze bandage. The aim must be to keep the wound clean and prevent extravasation through and inflammation of the cervical tissues.

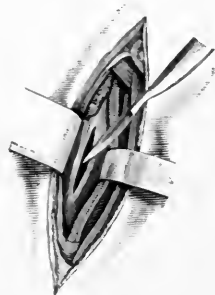


FIG. 850.—(Esophagotomy, final incision.

The Fallacies.—The foreign body may be mistaken for an enlarged gland on external examination. The œsophagus may be confounded with the longus-colli muscle at first; however, a moment's examination will serve to dispel the doubt. The respiratory movements of the œsophagus, distending and collapsing alternately, are important aids in determining its identity. It must not be forgotten that the swelling, pain, and tenderness elicited by external examination of the neck are not necessarily at the exact site of the agent causing them, and, too, that exploratory agents do not always indicate the presence of a foreign body. The efforts at upward removal of a foreign body that has as yet caused no significant damage in its downward course are often repulsed by œsophageal peristalsis to a degree that renders removal upward unwise and perhaps impossible, especially if the object be bulky and of irregular outline.

The Remarks.—If the foreign body be not located near the opening in the œsophagus, the canal should be explored upward and downward for its detection. If below, it may be at the narrow part of the œsophagus located opposite the fourth dorsal vertebra, from which point it may be removed with the use of properly constructed forceps. During the operation all bleeding points should be controlled promptly. The situation of the inferior thyroid artery, the anterior jugular vein, and the recurrent laryngeal nerve should be clearly understood, and needless injury of them avoided. With this object in view and to avoid the nerve, the incision into the œsophagus should be made as far posteriorly as practicable. The opening in the œsophagus may be dilated by the introduction of the blades of curved dressing forceps or the lips pulled apart by traction loops introduced through the borders of the œsophageal wound. If the obstructing agent be accessible and fixed in place by its irregularities and projections, these, or the object itself, can be divided with bone forceps and afterward easy removal accomplished. *Richardson* has determined that the index finger, when introduced into the œsophagus through a low cervical incision

(low cervical œsophagotomy), can reach the arch of the aorta and in some instances pass beneath it, also readily appose an index finger introduced from below through the stomach. The utilization of this method of manipulation serves an important purpose in the dislodgment of impacted bodies and in the dilatation of strictures. Not infrequently prompt union of the borders of the wound has resulted in immediate healing; but this course of action is not to be regarded as wise except in special instances, and then under close surveillance. The insertion into the bottom of the wound of a small drainage tube is desirable in cases in which too free separation of the tissue has occurred, and where free discharges are anticipated. If the tissues at the seat of the obstruction are already inflamed, emphysematous, etc., œsophagotomy should be practiced at once and the wound left open, thoroughly drained from the bottom, and lightly dressed with antiseptic materials. When the nutrient enemata are not retained or are insufficient for proper nutrition, a feeding tube should be introduced through the mouth or nose into the stomach, and be kept in place or passed at intervals for a time, as circumstances may demand. When illy borne at these situations, the introduction through the wound is advisable. Ordinarily the operation of cervical œsophagotomy is not a perplexing procedure; but when the neck is short or fat, the vessels and thyroid gland enlarged, the detection and removal of the foreign body difficult, or the patient is exhausted, the operation often taxes the patience and fortitude of the surgeon.

The After-treatment.—Keep the patient in bed with the head and shoulders raised, and the head so confined that the movements will not disturb the relations of the tissues of the wound. For the first day or so nourish the patient by the bowel, after this by means of the stomach tube, until the œsophageal wound is healed. In the case of a six-year-old patient operated on by the author, fluid food was given by the mouth after forty-eight hours, and the escape from the wound, during the act of swallowing, was reduced to a minimum by gentle pressure upon it, made with a good-sized pledget of aseptic cotton batting.

The Results.—Eighty-two cases are reported, of which nineteen died, but from causes independent of the operation in many instances. The rate can be placed at about twenty-two per cent, which will surely be lessened in the future, if the operation be done as early as it should be. Promptness of operative action lessens the rate of mortality, as a death-rate of 19.5 per cent follows operations made during the first three days, and 32.1 per cent after that time.

Silver reports one hundred and sixty-five instances of cervical œsophagotomy for the removal of foreign bodies since 1870, in which one hundred and twenty-seven recovered and twenty-eight died.

Foreign bodies in the intrathoracic portion of the œsophagus can be located with ease by a probang. If situated at the upper portion, the removal may be accomplished through a low cervical œsophagotomy and with the use of long curved forceps. Inasmuch as the œsophagus is quite narrow opposite the body of the fourth dorsal vertebra, it is fair to assume that the lodgment will be at this point. However, if below this place, the difficulty

of removal through a cervical incision will be greatly increased, if not made impossible. But inasmuch as comparatively safe relief through thoracotomy is as yet quite improbable, prompt, cautious, and intelligent efforts should be first employed at upward removal, not sufficiently prolonged, however, to impair the chances of more rigorous methods. Failing in these attempts, removal may yet be attained through the *performance of thoracotomy or gastrotomy*. The former method of relief is fully described on page 1260 *et seq.*

Gastrotomy.—*The employment of gastrotomy* for the relief of œsophageal obstruction from any cause is wise and usually effective. (See Instruments Employed, page 889.) The parachute snare is useful in these cases.

The Operation.—An incision is made in the median line between the umbilicus and ensiform cartilage two or three inches in length, the anterior surface of the stomach is drawn forward and opened, the left index finger or the hand is introduced, and the cardiac orifice sought for, by directing the index finger upward, backward, and to the left opposite to a point just outside of the articulation of the costal cartilage of the seventh rib with the sternum. From this time forward either one of two plans of removal can be practiced: 1. The drawing upward into the mouth of the foreign body by means of a sponge (Bull) or other suitable entangling agent connected to a string introduced at the cardiac orifice through the opened stomach, and carried upward beside the obstacle and out of the mouth by means of a small bougie. 2. By dilatation of the cardiac orifice and the lower part of the œsophagus with the index finger (Richardson) or a suitable instrumental dilator, and the removal of the foreign body downward by forceps, or by the employment of the sponge and string introduced in the reverse manner to that already described. Richardson advises that foreign bodies located thirteen inches or more from the incisor teeth be removed by the latter plan.

The Precautions.—The removal of foreign bodies from the œsophagus through the stomach should be conducted with great care and infinite patience by means of forceps, supplemented with dilatation of the opening, and downward pressure by way of the mouth, combined with dextrous handling of the obstructing body. Rapid, forcible, and illogical attempts at withdrawal cause lacerations and perforations of the œsophagus, followed by the unfortunate sequelæ which such procedures invite.

The Comments.—The size of the abdominal and of the gastric incision is regulated by the necessity of the case, which necessity should be promptly recognized in order to facilitate the operation and lessen the danger. Before the incision is made into the stomach careful packing around the organ at the borders of the abdominal wound should be practiced to obviate peritoneal infection. Forceful manipulations in the extraction of foreign bodies, or in extended digital exploration of the stomach or the œsophagus carried on through inadequate incisions, are often needlessly prolonged and are harmful. When the size and mobility of the stomach will permit it should be extensively drawn through the abdominal opening before being incised or explored (Fig. 851). Transverse openings into the stomach cause less hæmorrhage than longitudinal ones; but extensive longitudinal incisions made midway between the greater and lesser curvatures do not, for anatomical

reasons, cause dangerous hemorrhage. In digital and instrumental explorations the gastric incisions are made comparatively small and located so as to shorten the route to the objective point. In digital exploration of the stomach it is difficult indeed sometimes to locate with the fingers the site of

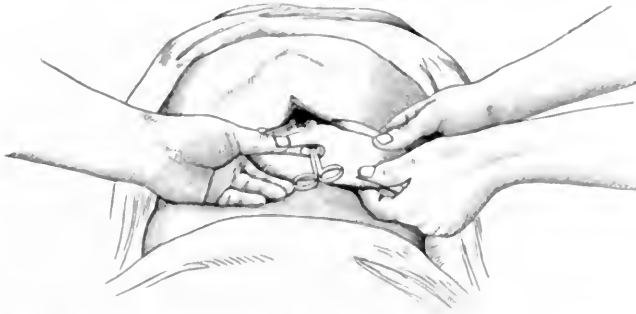


FIG. 851.—Delivery of stomach and introduction of forceps.

the œsophageal opening, because of its obliteration due to contraction of the walls of the stomach, provoked no doubt by the presence of the finger. However, if the finger be pressed cautiously for a time at the site of the opening relaxation will take place and the end of the finger will readily enter the tube. Downward traction on the stomach attended with flexion of the cervical and dorsal portions of the spine render the cardiac opening more accessible to manipulation. The putting of the lesser curvature on the stretch by downward traction on the stomach enables one to readily pass a bougie along the curvature into the cardiac opening, especially if the gastric incision be located well to the right.

Stricture of the Œsophagus.—For the purpose of consideration, stricture of the œsophagus will be classified as malignant and non-malignant, and although either may be treated by *dilatation*, *divulsion*, *external* or *internal division*, or *tubage*, it will appear that a diversity of modes of treatment is better. In the œsophagus as in the urethra, the first indication consists in locating the seat of the stricture, after which the treatment suited best for the case is carried into effect. Sometimes supplemental steps, such as opening the stomach or œsophagus, are needed to bring the stricture within the proper reach of the curative manipulations. Bulbous bougies (Fig. 852) are the common diagnostic agents employed. The fluoroscope, when used in connection with a metallic bougie or with any shadow-casting substance introduced into the œsophagus, affords an excellent means of locating a stricture and of computing its relations to contiguous bone structures. The œsophagoscope is useful, but should be carefully employed.

Dilatation is the simplest and safest method of practice in non-malignant stricture. Direct and retrograde dilatation are the methods employed. The variously formed and sized bougies are utilized for the purpose, and the finest filiform variety may fail to pass. The size should be increased from time to time, and when directly used, the instrument should be introduced in the manner already described (page 665).

The introduction is practiced once in two or three days, according to the characteristics of the constriction. The possibility of the presence of aneurismal constriction of the tube should be eliminated before an attempt is made to overcome the obstruction.

Retrograde Dilatation.—Retrograde dilatation is directed to the treatment of stricture of the lower portion of the œsophagus by way of an opening through the stomach (gastrostomy), made as for the removal of foreign

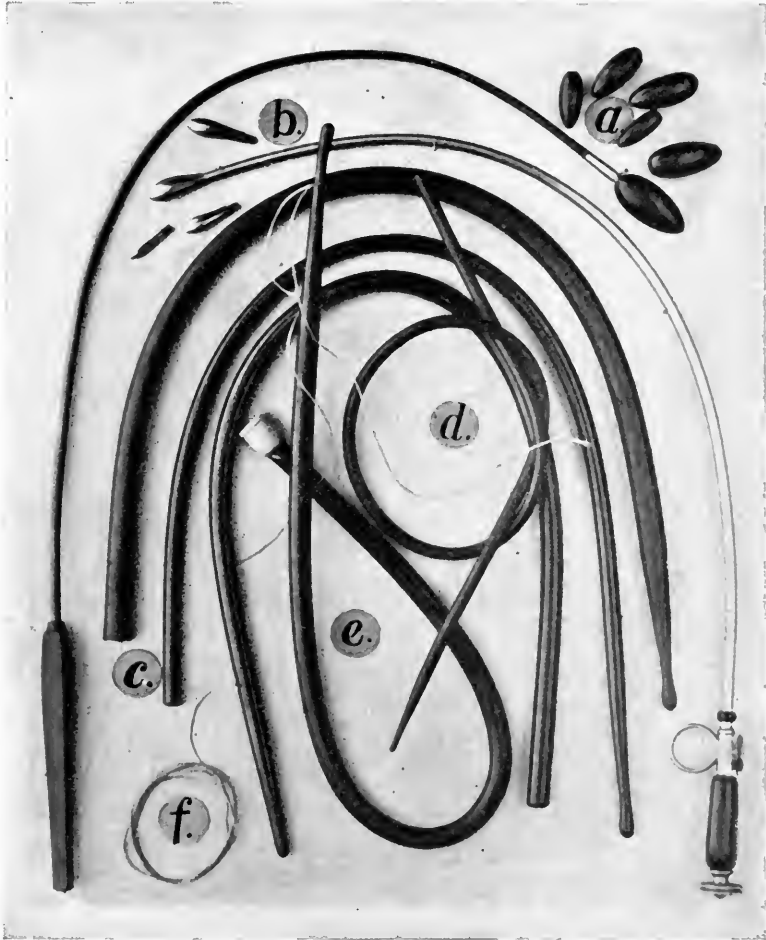


FIG. 852.—Instruments employed in treatment of stricture of the œsophagus.

- a.* Whalebone bougie, bulbs of assorted sizes. *b.* Sands's œsophagotome, bulbs of assorted sizes. *c, d.* Bulbous and pointed bougies. *e.* Bougie with string attachment. *f.* String for friction purposes. Bougies of various materials and of assorted sizes are for sale.

bodies, or through the fistula of gastrostomy, as the nature of the case shall determine. And in neither instance should the opening into the stomach be so small or so placed as to interfere with ready approach to the cardiac

orifice. Dilatation may be produced by the finger or by any of the stereotyped urethral or uterine dilators of suitable size and shape; also sponge tents, laminaria, and conical metal-capped bougies with string attachment are utilized for the purpose. Various devices for the primary introduction of a dilating agent are employed. The swallowing of a shot attached to a string (Socin) in advance of opening the stomach, and the pulling of the shotted end through the gastric opening to secure the return of a bougie or friction string or rubber tube (Ochsner) is an effective measure.

Thus Knott's conical bougies, or laminaria or rubber tubes of increasing sizes, may each be drawn upward, dilating the stricture. It is sometimes difficult to locate the cardiac aperture after opening the stomach, because of the obliteration of the orifice. The localization of it with the finger or with a bougie, as already described (page 672), may be practiced. The introduction of an endoscope along a string passed down from above (Silver), or of a tunneled catheter, may suffice. Direct observation through the endoscope at the seat of the opening may detect the entrance to the stomach from above of fluid swallowed for the purpose (Lange) (see page 663). Other ingenious devices can be named, but sufficient is noted already to invite the exercise of discreet and fertile judgment in this regard.

Divulsion.—Divulsion of an obstruction is not as safe a procedure as dilatation. However, in the case of failure of the latter, divulsion can be carefully practiced when necessary, in the absence of other means of treatment. *Direct* and *retrograde divulsion* are employed. The former consists in the introduction through the stricture in prompt succession of two or more œsophageal bougies of graded size, with sufficient vigor to rupture in a minor degree the contracted tissues of the obstruction. The latter is practiced in a rapid and forcible manner through an opening into the stomach by the agents employed in dilatation.

The immediate results are quite satisfactory, and the patency of the tube may be maintained thereafter by the continued introduction of bougies by the direct method. *External division* or external œsophagotomy has been considered already (page 668). Strictures of the cervical portion of the œsophagus may be divided from without. The stricture is first located by a bougie introduced into the tube, and is then cut down upon through an external incision as in œsophagotomy.

Internal Œsophagotomy (Internal division).—Internal œsophagotomy consists in the division of the constricting tissue after the manner of urethral practice, with enlarged patterns of the instruments employed in internal urethrotomy (Fig. 852, *b*). An instrument arranged so as to be passed upon a guide, as in internal urethrotomy, has been successfully employed on several occasions in internal œsophagotomy. However, the contiguity of important anatomical structures, and the inability to comprehend the exact relations of the stricture to the outer wall of the tube, make the operation an exceedingly hazardous one. If it be attempted, the constriction should be incised only sufficiently to admit a bougie, by means of which dilatation should be subsequently practiced.

The Results.—In nineteen cases of internal œsophagotomy treated by incision, one third died in sixteen days from results associated with the

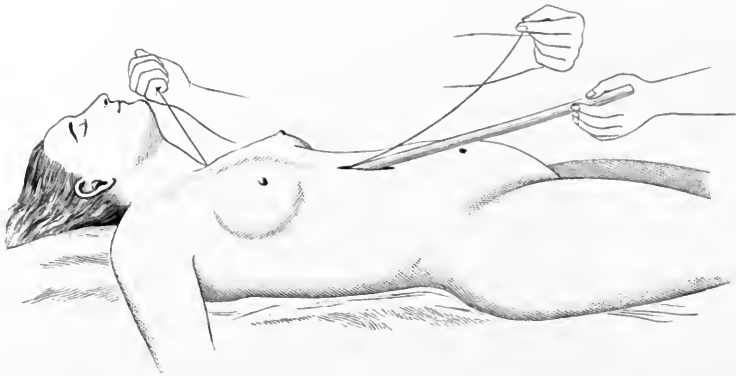


FIG. 853.—Abbe's string friction method; string escaping through a low cervical œsophagotomy instead of through the mouth.

operation. Of the remainder, three are said to have recovered, while the others survived for a period from one month to several years. About one third of the cases required one or more repetitions of the operation.

The division of the stricture by means of string friction, as devised by Abbe and practiced by himself and others, is a decided advance along the line of safety in the treatment of stricture of the œsophagus. The stomach is opened sufficiently to admit two fingers, along which as a guide, a bougie carrying a long silk thread is passed up the œsophagus and out of the mouth (Fig. 853). The lower end of the string is seized and the stricture made tense by the introduction of a conical bougie (Fig. 854); after which the upper end of the string is grasped and carried well back into the pharynx, while the lower end is carried into the stomach; then the string is drawn tight and moved rapidly upward and downward several times until the constricting bougie is released. This bougie is removed and the tension at the site of constriction renewed by the introduction of a larger one, and so on until the œsophageal tube is permeable or firm resistance is encountered by the string. As soon as a suitable sized bougie can be passed by the mouth, the operation is discontinued, the string is removed, the abdominal openings are closed, and thereafter bougies are introduced at regular intervals until all fear of closure ceases. It is not frequent that the conditions require the œsophageal incision, only, in fact, when the manipulations through other channels are futile, insufficient,

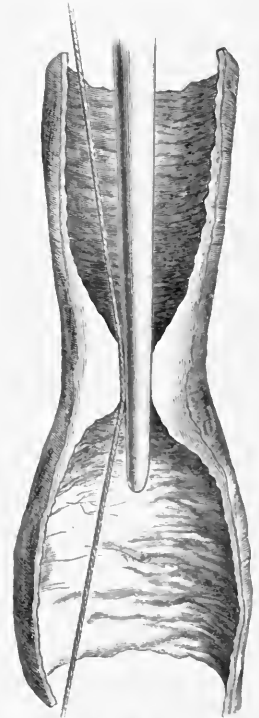


FIG. 854.—Making tense the stricture.

or needlessly dangerous to the patient. The author suggested not long since the employment of string friction through the mouth alone in the following manner: Introduce a long, firm, silken thread through an opening made transversely at the advancing end of a bougie (Fig. 852, *c*). In-

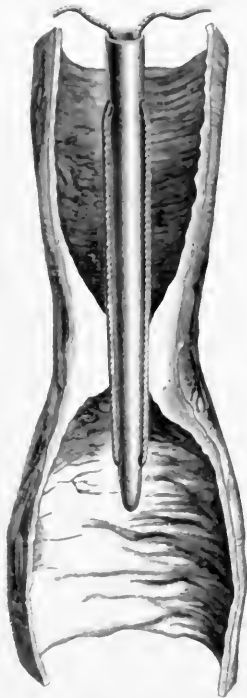

FIG. 855.
String friction employed
through mouth only.

troduce the bougie through the mouth into the grasp of the stricture (Fig. 855), then seizing the ends of the thread make the rapid sawing motion while pressing downward upon the bougie, the thread being thus made to move to and fro through the hole in the end of the bougie as over a pulley. The connection to the advancing end of the bougie of a small adjustable wheel (Fig. 856, *a*), around which the thread will move, and the passing of the ends of the string through projecting arms provided with wheels (Fig. 856, *b*), facilitate the movements of the string. If a hollow bougie be employed, the apparatus can be simplified by carrying the ends of the string into the bougie through openings at the lower part, and thence upward and out of the upper extremity sufficiently far to permit of proper handling. In every instance the bougie should be a stiff one, and the end should not be carried far into the stricture before the string is brought into play. By this method of employment of the string the time of use is much lessened and the therapeutic effect greatly increased.

It is not impossible, therefore, to reduce the stomach feature of the operation if desired from two steps to one, and perhaps in some cases to avoid it altogether, by this method of employment at either aspect of the obstruction, of string friction.

The Comments.—In the event of failure to dilate the stricture by way of the mouth the surgeon must supplement the effort by the advantages arising from the performance of gastrostomy or gastrotomy. The enfeebled condition of many of the patients with œsophageal stricture from lack of nourishment, and the tendency of obstinate strictures to relax after a longer or shorter quiescence of the tube, have led to increased frequency of employment of the latter plan, in order to permit of ample and immediate nutrition and to afford the rest to the œsophagus essential to stricture relaxation. *Silver* regards those cases characterized by impassable stricture and pronounced regurgitation—the latter indicating decided pouching of the œsophagus—as suitable for prompt gastrostomy. Cancer of the œsopha-



FIG. 856.
String friction
appliance.

gus, especially, calls for early relief by this method. The opening into the stomach should be made of sufficient size to admit one or two fingers along with the necessary instrument for dilatation, and be placed well up on the anterior surface to permit of as easy access to the cardiac orifice as possible, and also to limit the danger of leakage during the manipulation. The borders of the gastric opening can be drawn apart by traction loops, to afford better observation, or they may be drawn by the loops closely against the exploring agent, thus lessening the danger of escape of the contents of the stomach. This opening may be closed independently of the abdominal one, provided dilatation sufficient to allow the ready passage of fluid food and the employment of bougies from above have taken place. The dilatation should be completed at a single sitting, if possible. If preliminary gastrostomy be performed, it is safer, other things being equal, that two sittings be given to the operation than that it be completed at one.

The After-treatment.—The passage of the largest bougies practicable once a week or once a month, according to the demands of the case, supplemented with the free use of solid food and the giving of exacting admonitions regarding the need of surgical surveillance for an indefinite time to come, are essential to final success.

The Results.—The results of retrograde dilatation are very satisfactory indeed. Woolsey reports twenty-eight cases "with no death due to the operation." To this number Silver has added ten with no change in the immediate results of the operation. The final outcome is much enhanced indeed by prompt resort to opening of the stomach. A steady and persistent loss of weight, due to obstruction in swallowing, forbids temporizing, and demands prompt and radical operative practice.

Tubage with String Attachment.—This plan is adapted to the treatment of malignant strictures, and is practiced on those patients in whom for any reason early gastrostomy is not practicable. While it is true that through the agency of tubage ample food may be taken for a time, also the saliva swallowed, and the objections to early operation condoned, still, the progressive nature of the disease causing the obstruction, the effect on the disease of pressure, and the dangers and annoyances of the introduction and retention of the tubes, especially in the advanced stages, together with the opportunity afforded for procrastination of operative practice until much too late for fitting success, suggest the fact that tubage, although an ingenious and sometimes temporarily useful means is, on the whole, a measure of questionable utility. However, the tube finds its most rational use in cases unsuited for operation. The method is practiced by introducing into the stricture by means of a whalebone conductor a funnel-shaped flexible gum-elastic tube with a string attached (Fig. 857, *b*) four to six inches in length, until the funnel rests above on the stricture. The lower end of the tube resembles that of the ordinary catheter, except the eye is made larger to permit the free passage of fluid food. The tube can remain in place often from one to two months without causing apparent trouble. The string escapes through the mouth and is carried over the ear for both security and convenience. It should be carefully guarded to prevent premature withdrawal of the tube

because of careless traction, and difficult removal on account of the breaking of the string. Sometimes coughing attends deglutition, and then the short tube should be replaced by a long one, which can be easily extemporized by cutting obliquely and closing the end of a suitable piece of red-rubber tubing, making the eye about an inch above the end, and introducing it through the stricture with a suitable conductor.

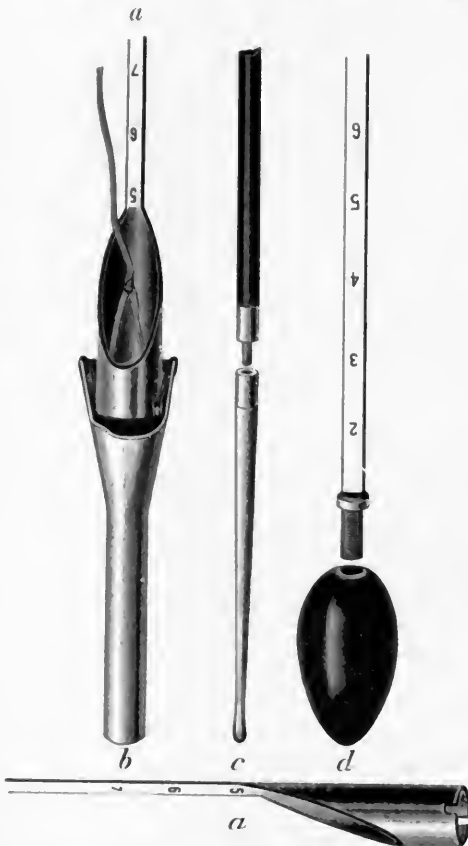

FIG. 857.—*a.* Tube conductor. *b.* Gum-elastic tube. *c.* Small flexible bougie. *d.* Bulbous bougie.

The Results.—Of seventeen cases treated by this method, nine died from the effects of the disease, without obstructed deglutition.

The Results.—Of seventeen cases treated by this method, nine died from the effects of the disease, without obstructed deglutition.

Œsophagectomy.—Œsophagectomy consists in excising a portion of the œsophagus through an incision made in the same manner as for cervical œsophagotomy (page 668) or for thoracotomy, for the removal of a cancerous growth. In the former the upper end of the lower portion of the tube is raised forward and united to the wound, thereby forming an opening through which food may be introduced by means of a tube. The latter method is noted under the proper heading (page 1288 *et seq.*).

The Results.—Butlin reports 14 cases, 5 dying of operation, 1 from a false passage, a short time after; 6 dead or alive with return, and 2 unreported. There

is reason to believe that life can be extended for a longer time by gastrostomy or by feeding through a tube than by this procedure.

Œsophagostomy.—Œsophagostomy is employed to establish a fistulous opening with the œsophagus, below the point of an incurable, impassable constriction. It provides for the introduction of food into the stomach, and serves as a temporary palliative measure. While its adoption obviates for a time at least the performance of gastrostomy, still there is no good reason to believe that it can be regarded in any instance as the wiser procedure.

Diverticula of the Œsophagus.—These pouches may be either congenital, or arise from stricture, from external pressure or from internal contraction. When occurring in the neck they can be quite readily removed.

The Operation.—Anæsthetize the patient, pass a curved bougie into the pouch, noting its presence by external pressure; pass another, if possible, into the stomach, thus determining the exact location of the œsophagus and the absence of stricture; make an incision at the anterior border of the left sterno-mastoid muscle from the hyoid bone to just above the sternum; divide the omo-hyoid and the superior thyroid vessels; draw outward the carotid sheath and rotate the larynx outward with blunt hooks, thus exposing the pouch; isolate carefully the pouch by dissection, aided by movement of the included bougie; grasp the pouch with forceps and draw it carefully from the wound (Fig. 858); cut away the diverticulum

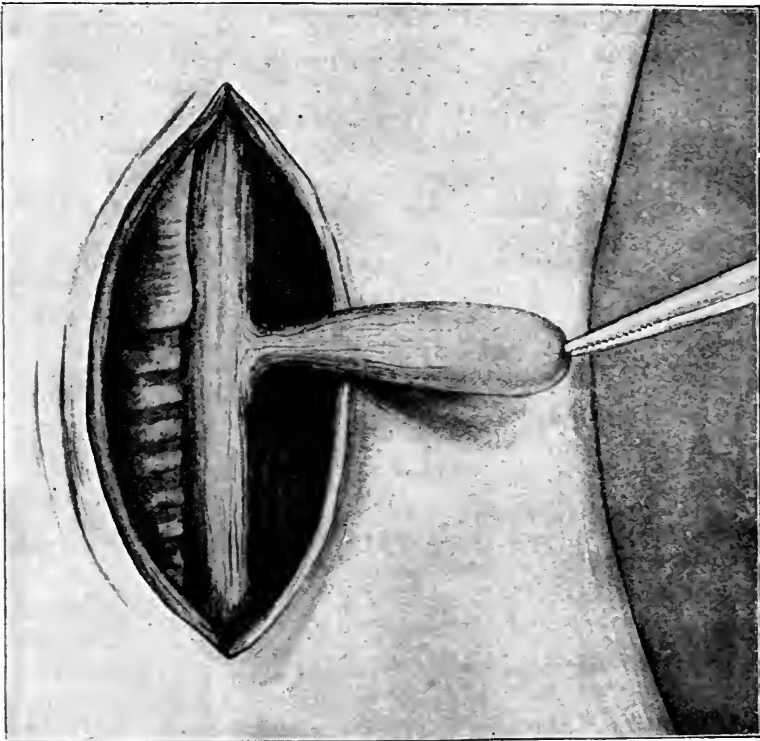


FIG. 858.—(Esophageal diverticulum dissected out ready for removal.

from above downward, closing the wound with fine silk or chromicized catgut sutures; close the ends of the wound, introducing gauze wicks or gauze packing lightly into the central part, and apply the usual external dressings.

The Remarks.—Richardson, in one case, cut away the pouch (Fig. 858), inverted the mucous membrane, united its borders with catgut (Fig. 859) and those of the outer layer of the œsophagus with silk sutures, followed by good results (Fig. 860). In another case, while passing the finger through the opening to estimate a stricture below, a longitudinal rupture

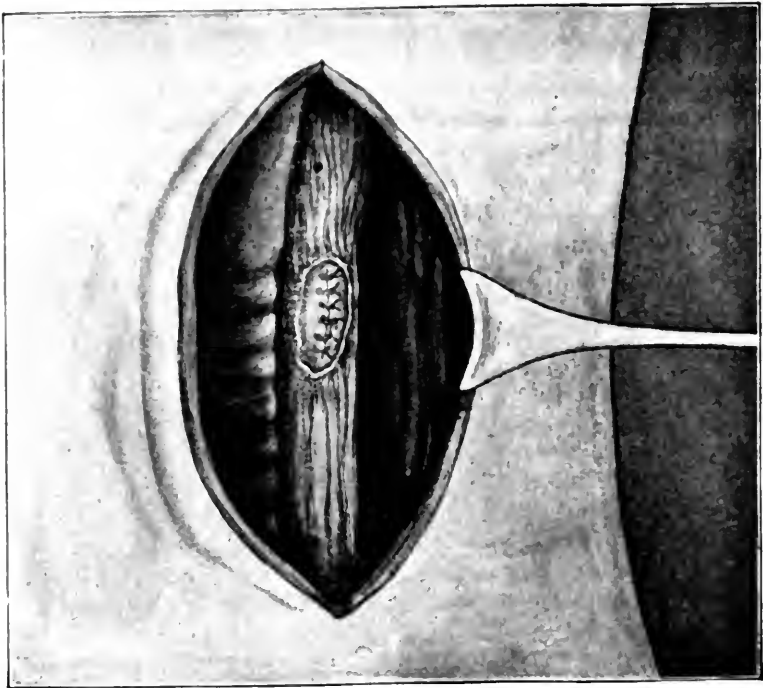


FIG. 859.—Diverticulum removed and borders of mucous membrane united.

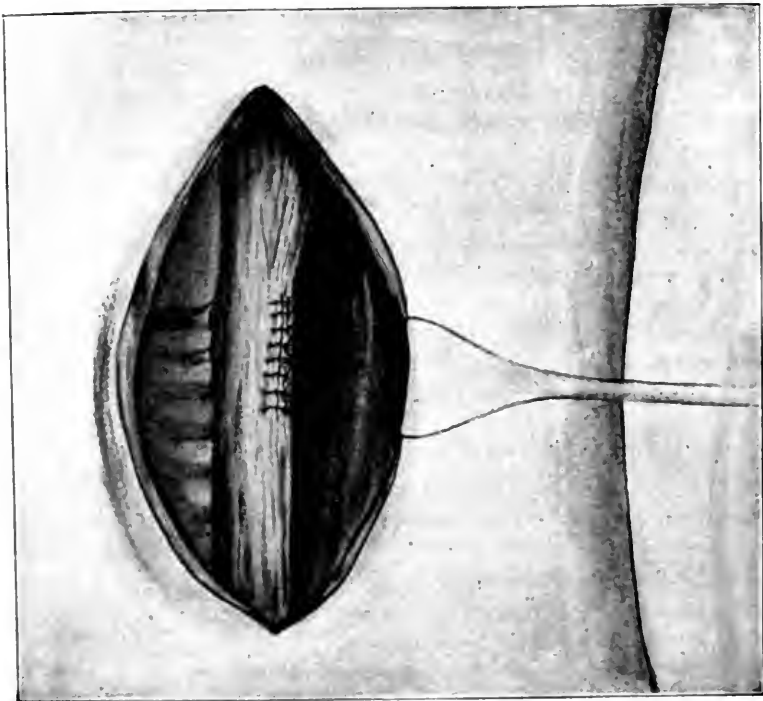


FIG. 860.—Line of union of mucous membrane covered by union of outer coats.

happened below the stricture. The border of the opening and the stricture were then divided down into the rupture. A portion of the pouch left above was turned down and attached to the incised posterior surface of the longitudinal division of the œsophagus, the gap united transversely, as in pyloroplasty, and the original opening of the pouch closed in a vertical line.

Girard invaginated the pouch and closed the opening externally by three layers of sutures, thus avoiding opening into the œsophagus. The invaginated pouch atrophied, causing no obstruction. The great danger of leakage forbids complete closure at once of the wound.

The after-treatment differs in no essential regard from that of œsophagotomy. Solid food ought not to be taken for five or six days.

The Results.—Of 22 cases operated on, 5 resulted fatally (Veiel*).

OPERATIONS ON THE NECK.

Bronchotomy.—The expression bronchotomy includes four distinct operations: *laryngotomy*, *tracheotomy*, *laryngo-tracheotomy*, and *thyrotomy*, the first two of which are still further classified. These operations are comparatively easy in the adult, especially if the neck be long and thin, and the landmarks well developed. In the infant and the child, and before puberty—the periods of life when they are most demanded—their performance is difficult and perplexing, owing to the shortness of the neck, obesity of the patient, the rudimentary condition of the landmarks, and the exigencies of the occasion.

The Anatomical Points.—The trachea in the adult is about four inches and a half in length and three quarters of an inch from side to side. The distance between the sternum and the cricoid cartilage is about two and three quarters inches in the adult, and two and a quarter, two, and one and a half at ten, seven, and five years respectively. The following illustrative scheme (Trevé) shows the relation between the respective ages and sizes of the corresponding tubes (Fig. 861). Deviations from the normal size of the trachea from congenital and acquired influences are so infrequent as not to figure significantly, except perhaps in adults, and then from pressure effects already well understood.

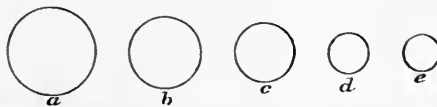


FIG. 861.—Comparative diameters of tracheotomy tubes based on age of patients. *a.* .47 + inch (12 mm.), twelve to fifteen years. *b.* .40 — inch (10 mm.), eight to ten years. *c.* .31 + inch (8 mm.), four to eight years. *d.* .24 — inch (6 mm.), two to four years. *e.* .20 — inch (5 mm.), one and a half to two years. Adults, $\frac{1}{2}$ to $\frac{3}{4}$ inch; under one year and a half, .15 + inch.

The thyroid cartilage (Fig. 862, *c*), which is well marked in the adult, constituting a prominent point of reckoning, is scarcely discernible in the child.

and in the infant it is quite impracticable to determine its location by physical examination. The cricoid cartilage (*e*) is a far better guide by which to determine the comparative relations of the parts. It is the distinctive cartilage of the laryngeal group, and, irrespective of age, it can be felt as a firm, round ring, much more prominent than the cartilaginous rings of the trachea, which lie immediately below it. The crico-thyroid space (*d*), through which in laryngotomy the deep incision is made, is located immediately above the cricoid cartilage (Fig. 862). This space is situated at the bottom of the first groove-like depression above the cricoid cartilage. The crico-thyroid membrane (*d*) is composed of yellow elastic tissue, is therefore of a yellowish appearance, and is often dotted by openings for small vessels. When incised it will retract, owing to its resilient nature; hence all hæmorrhage should be

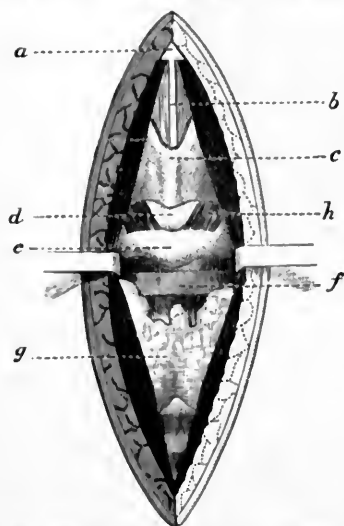


FIG. 862.—The topography of the larynx, etc. *a*. Body of hyoid bone. *b*. Thyro-hyoid membrane. *c*. Thyroid cartilage. *d*. Cricothyroid membrane. *e*. Cricoid cartilage. *f*. First tracheal ring. *g*. Isthmus of thyroid body, with tracheal rings below. *h*. Cricothyroid muscle.

stopped before it is opened if the urgency of the case will permit. It is not difficult to locate the guides in the dead subject under ordinary circumstances; but in the living when they are being jerked upward and downward by the efforts of impeded respiration, it is a matter of great difficulty, and may be impossible. The only artery normally in the line of the operation of laryngotomy that need be respected is the crico-thyroid (Fig. 863, *d*); it runs along the upper border of the space, resting on the membrane of the same name. This artery is troublesome, not from the amount of blood it contains, but from its relation to the opening in the membrane through which a small amount of blood may pass into the tube. The vessels causing the greatest annoyance—especially if the patient be much cyanosed—are the small venous trunks which run across the tracheal and laryngeal region, without any definitely established relationship, and which return their blood chiefly into the superior thyroid veins (Fig. 863). The anterior jugular veins will be trouble-

some unless the median line be adhered to closely. It is unnecessary, I trust, to allude to the well-known relation between the larynx and the large vessels of the neck. The thymus gland in the very young deserves respectful manipulative consideration. The innominate and common carotid arteries, especially in the right, may encroach on the operation in low tracheotomy.

The *anæsthetic* to be given in operations where the respiratory function of the larynx is involved is a matter entitled to careful consideration. For instance, if ether be given to one who has no laryngeal irritation or obstruction, the frequent spasm of those parts is familiar to all. If to this be added the deficient aëration of the blood, due to a laryngeal obstruction, together

with the increased tendency to spasm, dependent on laryngeal disease and to fright, then is the danger of asphyxia greatly augmented. Chloroform may be given with but little danger of causing spasm; if ether be administered, it must be commenced very gradually, to avoid as much as possible the occurrence of laryngeal spasms. In many instances the pressing nature of the case will not permit the expenditure of the time necessary to produce general anæsthesia. Local anæsthesia may be employed. In those cases presenting marked cyanosis the sense of pain is much blunted and the operation should be done without anæsthesia. *The instruments* suitable for these operations (Fig. 864) are quite numerous, yet the absence of any one or more of them is not to be considered a reason for non-performance of bronchotomy when demanded. When necessary, a pocketknife, and a hairpin, a toothpick, or a catheter (Fig. 864) can be extemporized to advantage, thus preventing the death of the patient unaided because a tracheotomy tube is not obtainable.

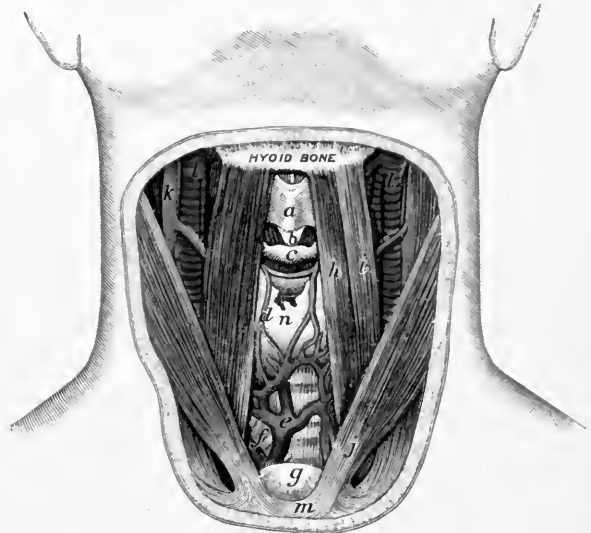


Fig. 863.—The surgical anatomy of larynx and trachea. *a.* Thyroid cartilage. *b.* Crico-thyroid membrane and artery, crico-thyroid muscle at either side. *c.* Cricoid cartilage. *d.* Superior thyroid vein. *e.* Inferior thyroid vein. *f.* Innominate artery. *g.* Thymus gland. *h.* Sterno-hyoid muscle. *i.* Omo-hyoid muscle. *j.* Sternal attachment of sterno-mastoid. *k.* Jugular vein and branches. *l, l'* Carotid arteries and branches. *m.* Sternum. *n.* Thyroid body.

When necessary, a pocketknife, and a hairpin, a toothpick, or a catheter (Fig. 864) can be extemporized to advantage, thus preventing the death of the patient unaided because a tracheotomy tube is not obtainable.

Langenbeck's hook (Fig. 865) is the best in use, because the line of the cut can be made between its blades, and the middle line of the trachea is therefore the better assured. There are various forms of tracheotomes, which should not, in our opinion, be substituted for the sharp-pointed bistoury, because they are much less surgical in their inception and far more dangerous in their use. Trachea dilators, too, are quite numerous and varied in pattern (Fig. 864, *p, q, r*). The borders of the tracheal opening can always be easily drawn apart by common tenacula or by two of the ordinary grooved directors with aneurism-needle attachments (Fig. 864, *e*). The bivalve trachea tube is an admirable instrument, since it can be introduced through the opening in the trachea much more readily than the ordinary blunt-ended pattern, and can be quickly opened afterward by the introduction into it of the companion tube (Fig. 864, *u*). A long feather, with the end of the brush remaining (Fig. 864, *u*), should be at hand to insert




FIG. 864.—Instruments employed in operations on the trachea.

- a.* Scalpels, sharp and probe-pointed. *b.* Scissors, curved and straight, blunt-pointed. *c.* Forcepressure. *d.* Mouse-tooth forceps. *e.* Directors with hooked extremities. *f.* Blunt hook. *g.* Strong tenaculum. *h.* Two-tined retractor. *i.* Small blunt retractor. *k.* Rubber tracheotomy tube with tapes attached. *l.* Hard-rubber tube. *m.* Gussenbauer's tube. *n.* Bivalve tube. *o.* König's tube. *p.* Trousseau's trachea dilator. *q.* Tiemann's dilator. *r.* Chassaignac's dilator. *s.* Hairpin, pocketknife, and female catheter. *t.* Trachea forceps. *u.* Feather for introduction to trachea. *v.* Trachea forceps. *w.* Trachea aspirator. *x.* Ligatures, traction loops, and sutures. Spatula, mouth gag, tongue forceps, wipers, and shield, for mouth and eyes of operator in diphtheria, ought to be at hand. Genzmer's modification of König's tube (*o*) is valuable.

through the tube into the trachea, to create the irritation sometimes necessary to cause the expulsion of the tracheal mucus. A so-called trachea aspirator has been devised to remove mucus and blood from the trachea (Fig. 864, *w*). It is used as follows: After the insertion of the trachea tube, place the thumb on the air-hole of the barrel; apply the soft-rubber cup over the tube, and withdraw the piston, when the mucus and blood will enter the barrel. It has not infrequently happened that a patient is unable to expel the blood and mucus on account of stupor or weakness, and the lips of the operator were used to clear the trachea. This is obviously a hazardous procedure if the patient have syphilis or diphtheria. The possession of the tracheal aspirator will be welcomed as preferable under all circumstances. A serviceable instrument for the purpose of removing blood, etc., from the trachea tube, and even from the trachea itself, can be quickly extemporized by attaching to the nozzle of an ordinary two-ounce rubber syringe a soft piece of rubber tubing five or six inches in length. The unattached end of the rubber tubing is inserted into the trachea tube or into the trachea itself; the piston of the syringe is withdrawn somewhat quickly, and the fluid sucked up. If the suction be made too quickly the tube will be collapsed and inoperative. Large portions of membrane have been drawn by the writer from the bronchial tubes in this manner.

The After-treatment.—The soft parts above and below the tubes are closed by sutures and the patient is then placed in bed and caused to breathe air saturated with warm vapor from which all floating particles of dirt should be excluded. The tube is carefully watched to prevent it from becoming closed, and occasionally removed and cleansed to prevent wound and pulmonary infection. Too great emphasis can not be laid upon the necessity of instantly relieving the sudden occlusion of the tube due to false membrane. For this reason a momentary inattention, as leaving the room, etc., may prove fatal to the patient. After three or four days the tube may be removed and the patient allowed to breathe through the opening for a few hours, after which the tube should be again inserted; later in the case it may be inserted only during the night. As soon as the patient can breathe well, the tube should be removed entirely, the opening cleansed, and the borders closed, joined by sutures. If antiseptic gauze (not bichloride) be placed between the surface of the neck (Fig. 869) and the flanges of the tube, the danger of irritation of the soft parts at that situation by the discharges will be obviated.

Laryngotomy.—Although all operations in which the larynx is opened are included under the name laryngotomy, for convenience of expression limited divisions of the organ are named for the part divided—i. e., thyrotomy, cricotomy (Figs. 866, 867), etc.

The Operation.—Place the patient on the table with the shoulders elevated, head thrown back, and neck exposed to a strong light. If hurried, a



FIG. 865.
Langenbeck's
double hook.

round bottle or loaf of bread or block of wood may be placed under the neck, or if the head hang supported over the edge of the bed or table, the object will be gained. At least three assistants are required, especially if an anæsthetic be given. Locate the cricoid cartilage; support the larynx firmly between the thumb and finger of the left hand; make an incision through the integument one inch and a half in length in the adult, terminating at the lower border of the cricoid cartilage; divide the fascia on a director; divide the connections between, and separate the borders of the sterno-hyoid (Fig. 863) muscles with retractors; push aside the veins and connective tissue and the crico-thyroid membrane will be seen (*b*).

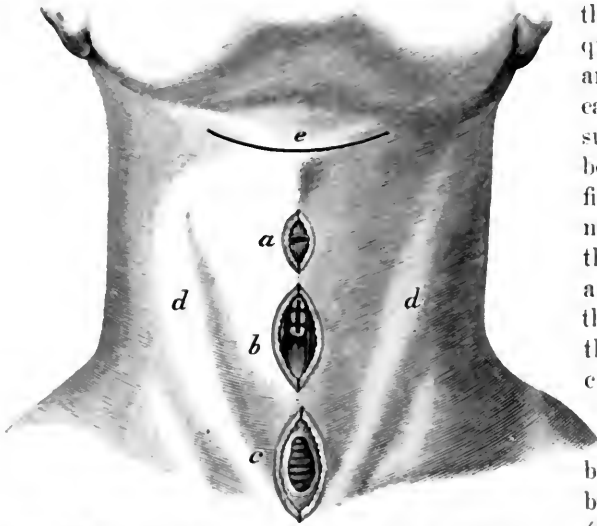


FIG. 866.—*a*. Incision in laryngotomy. *b*. Incision in tracheotomy above the isthmus of the thyroid body. *c*. Incision in tracheotomy below the isthmus of thyroid body. *d, d*. Sterno-cleido-mastoid muscles. *e*. Incision in subhyoid pharyngotomy.

If the case be not urgent, check all hæmorrhage before opening the larynx. If otherwise, open it at once, when the entrance of air and the resumption of the respiratory functions will dispel the cyanosis and check the bleeding. The larynx is seized and held firmly upward and forward by the tenaculum, while the opening is made through the crico-thyroid membrane, transversely near the upper border of the cricoid cartilage, both to avoid the crico-thyroid artery, which runs along the upper border of the membrane near the thyroid cartilage, and also to remove the tube as far as possible from the vocal cords. The whistling of the ingoing air, succeeded by an expulsive cough—which ejects the mucus, blood, and other matters—follow quickly after the incision. If the operation be performed for the removal of a foreign body it may at this time be expelled, or become lodged near the opening, when it can be removed by forceps. If the operation be performed for laryngeal diphtheria, the tube should not be inserted until all loose membrane has been expelled, and such as may be within reach of the forceps has been pulled away. If blood escape into the opening from the oozing vessels, the pressure of the tube upon the lips of the wounds will serve to check it, and for this reason it may be introduced promptly. The tube is carried carefully in while the borders of the opening are held apart with the orthodox retractors, or by means of two blunt artery needles or tenacula, after which it is fastened in position by means of tapes carried around the neck and tied behind (Fig. 869). If the opening be too

small, it may be increased by division of the cricoid cartilage (*crico-laryngotomy*).

Tracheotomy.—The operation of tracheotomy consists in opening the trachea, and is usually performed upon children, owing to the small size of their crico-thyroid spaces. It is the preferable operation in all instances when the incision is to be made as far as possible from a contagious local disease. *Tracheotomy may be done at three situations:* below (Fig. 866, *c*), above (*b*), and behind the isthmus of the thyroid gland; the operation below the isthmus is to be preferred.

The Anatomical Points.—The upper portion of the trachea is quite superficial, while the lower is from half an inch to one inch below the surface, depending upon the shortness of the neck and the obesity of the patient. The lower portion recedes, following the curve of the spinal column. The vascular structures associated with this portion are far more important and numerous than in other parts of its course; the inferior thyroid veins (Fig. 863), and their communications, pass in the course of the incision; the arteria thyroidea ima when present runs along the center of the trachea; the arteria innominata, especially in the child, runs obliquely across it, at the root of the neck from left to right. The isthmus of the thyroid covers the second, third, and often the fourth rings of the trachea; above it is seen the communicating branch between the superior thyroid veins (Fig. 863); the thymus gland, which attains its full size at two years, encroaches upon the space from below upward with each labored respiratory act, and may be incised. *It is sometimes difficult* for the beginner, when surrounded by the turmoil incident to the operation, to be certain of the location of the trachea. If the index finger be inserted into the wound the trachea will roll under it, and be felt ascending and descending beneath its extremity, and, when sufficiently isolated, the rings can be seen and felt. Also, the inexperienced operator is likely to open the trachea at one side of the median cut, making it difficult to introduce the tube, causing it to bind after introduction, and not infrequently, if the tissues overlap the cut before its introduction, causing air to be forced between their planes, creating local emphysema. If the knife be inserted too far, the posterior wall of the trachea will be divided.

If the knife be inserted too far, the posterior wall of the trachea will be divided.

The Operation below the Isthmus (Low Tracheotomy, Figs. 866 and 867).—Place the patient as for laryngotomy, and, if practicable, employ an anæsthetic. Support the trachea in the median line, and make an incision extending from the cricoid cartilage to within half an inch of the top of the

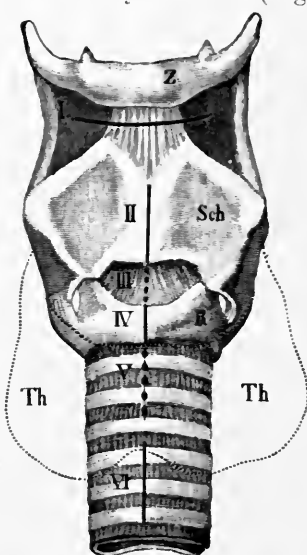


FIG. 867.—Operations on the larynx. Z. Hyoid bone. Sch. Thyroid cartilage. R. Cricoid cartilage. Th. Outline of the thyroid gland. I. Subhyoid pharyngotomy. II. Thyrotomy. III. Infrathyroid laryngotomy. IV. Cricotomy. V. High tracheotomy. VI. Low tracheotomy.

sternum; divide the fascia on a director; cautiously separate and pull aside the sterno-thyroid and sterno-hyoid muscles, thus exposing the deeper cervical fascia, beneath which are located the inferior thyroid veins (Fig. 863), supported by connective tissue. This fascia should be torn asunder by a blunt instrument, and pushed aside along with the veins and connective tissue beneath, which will expose the

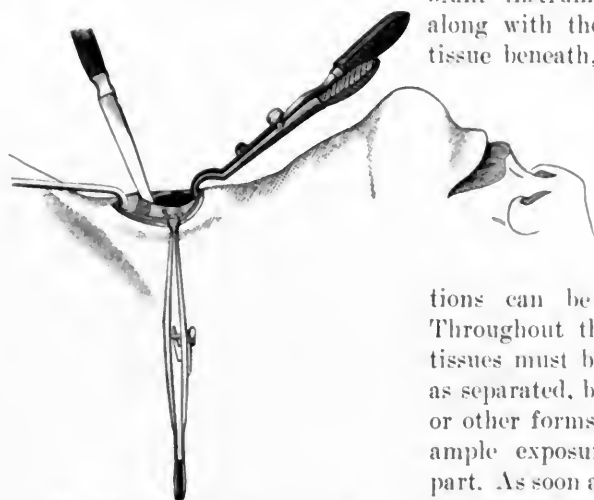


FIG. 868.—Opening the trachea.

trachea. The blunt ends of two ordinary directors can be utilized for separating the fascia, or instruments especially devised for dry dissections can be employed (Fig. 49). Throughout the entire operation the tissues must be drawn asunder as fast as separated, by means of blunt hooks or other forms of retractors, to afford ample exposure of each succeeding part. As soon as the trachea is reached, and all hemorrhage checked, it is seized by one or two hooks—the double hook of Langenbeck (Fig. 865) being the best—drawn forward to near the surface of the wound, firmly held, and three or four rings of the trachea divided exactly in the median line from above downward, or better from below upward, by a sharp-pointed knife (Fig. 868). Then the dilator (Fig. 864) is introduced, and the tube inserted and confined in position after the tracheal mucus and blood have been expelled (Fig. 869). All incisions, except the primary one, should be directed upward to avoid the great vessels at the root of the neck. The opening in the trachea should be long enough to admit the easy expulsion of all false membranes and foreign bodies (an inch in length is not too much for this purpose), and must likewise readily admit the trachea tube.

The Operation above the Isthmus (High Tracheotomy, Figs. 866 and 867).—Make an incision of the usual length, its center corresponding to the lower border of the cricoid cartilage (Fig. 866, *b*); divide and carefully separate the tissues as before; the loop of communication between the superior thyroid veins (Fig. 863) must be carefully drawn upward, the fascial attachment between the isthmus and

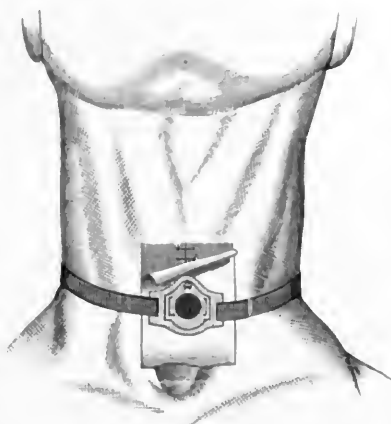


FIG. 869.—Tube in position.

carefully drawn upward, the fascial attachment between the isthmus and

the cricoid cartilage divided, the isthmus pulled downward and drawn forward by a blunt hook, when the trachea can be opened beneath it from below upward, and the tube inserted with the same precautions as before.

The Operation through the Isthmus.—This method is hardly of enough practical importance to be entitled to a detailed consideration, since the opportunities afforded above and below it will be sufficient. If, however, this position be selected for operation, the isthmus should be divided between two ligatures to avoid the probability of troublesome hæmorrhage. It sometimes happens that the isthmus is small or too illy developed to be troublesome after its division without ligature.

Laryngo-tracheotomy.—In laryngo-tracheotomy the larynx and trachea are both opened by a continuous incision, which is usually made to increase the space, that foreign bodies and false membrane may be removed. The incision through the cricoid cartilage and upper rings of the trachea is then secondary to the opening of the larynx. Before the primary incision is extended, the communicating branches of the superior thyroid veins should be pulled downward, the lower border of the cricoid exposed, the fascial connections of the isthmus to it severed, and the isthmus drawn downward and forward as before, to prevent it from being injured.

Rapid Laryngo-tracheotomy (*Saint-Germain*).—It is sometimes necessary to open the larynx very quickly; therefore, it is quite proper to mention some of the points connected with this operation that the surgeon may be prepared to act with dispatch combined with caution.

The Operation.—With the patient placed in the usual position for tracheal operations, the surgeon locates the thyroid and cricoid cartilages and the space between them. Then, standing on the right side of the patient, he seizes and pushes forward the larynx by pressing the thumb on one side and index finger on the other, between it and the vertebral column, thereby making the integument tense. At the same time the index finger locates the lower border of the thyroid cartilage. A straight, sharp-pointed bistoury is then seized between the thumb and index and middle fingers, its back upward, with the middle finger so placed on the blade that the knife can not penetrate to exceed half an inch in depth. While thus held, its point is quickly thrust into the larynx in the median line at the lower border of the thyroid cartilage and the blade is carried downward with a sawing motion, dividing the crico-thyroid membrane, cricoid cartilage, and one or two rings of the trachea. The opening through the integument should equal in length the one made in the larynx and trachea. The dilator is introduced, all bleeding checked, and the tracheal tube placed in position. *Saint-Germain* up to 1877 had operated by this method 97 times, with but three instances of important hæmorrhage, in one of which the posterior wall of the trachea was cut.

Thyrotomy.—Thyrotomy consists in dividing the thyroid cartilage partially or completely in the median line (Fig. 867, *II*), together with division of the thyro-hyoid and crico-thyroid membranes when additional room is desired. Thyrotomy is performed for the relief of laryngeal obstruction dependent upon various causes, when not amenable to proper aid by simpler means.

The Operation.—Place the patient as for laryngotomy, and after proper anæsthesia make in *complete thyrotomy* an incision through the skin *exactly* in the median line from the lower border of the hyoid bone to the upper border of the cricoid cartilage, extending it later as circumstances require; divide in the median line the fascia and contiguous soft tissues down to the cartilage, carefully avoiding the crico-thyroid vessels; draw to either side the borders of the divided soft parts, exposing the thyroid cartilage and the upper portion of the crico-thyroid membrane; incise the crico-thyroid membrane transversely at the lower border of the thyroid cartilage for a short distance, avoiding the crico-thyroid artery below and the cricoid muscles at either side; insert the point of a sharp knife beneath the lower border of the thyroid cartilage exactly in the median line and cut upward sufficiently for the purpose of the operation, leaving, if possible, the upper border of the cartilage unsevered; divide the upper border, if need be, from within outward on a director with a blunt-pointed knife; draw apart the respective borders of the cartilage, detaching sufficiently the crico-thyroid and thyro-hyoid membranes from the cartilage on either side of the larynx to permit of a full view of the laryngeal cavity, after which the special features of the operation are carried into effect.

The Precautions.—Divide to no greater extent than necessary the cartilage, for, if complete division be practiced, it is difficult to so adjust the parts as to prevent thereafter functional disturbances of the voice. It is advised that the cartilages be notched in front, also that the sutures be passed through the borders of the cartilages before complete division so that a more accurate union of them may be afterward secured. Since closure of the rima glottidis may result from the swelling following thyrotomy and other operative manipulations, a tracheotomy tube should be passed into the trachea through the lower limit of the wound and retained as long as required, unless a tube is already present below.

The Remarks.—A low tracheotomy should be performed before the larynx is opened, when the nature of the trouble bespeaks free hæmorrhage, in which case tamponing may be practiced. Some operators place the patient in Trendelenburg's position, thus obviating the need of the tampon. If the cartilage is calcified, bone-cutting forceps or strong scissors may be required to make the separation.

The General Comments.—If the tube be too large, too loose, or too angular, it is liable to cause erosions and ulcerations of the trachea, which may extend through it and implicate the vessels at the root of the neck, causing fatal hæmorrhage. The method of opening into the trachea by a single incision is fraught with danger, and should not be attempted except the neck of the patient be long and thin, and not even then unless the exigencies of the case call for it. The division of the tissues down to the trachea by means of thermo-cautery or galvano-cautery has many advocates; it is not, however, a commendable practice, except, perhaps, in local infections. The searing of the tissues may prevent or lessen hæmorrhage, and likewise obviate the occurrence of infection. This is not altogether true, since the large veins which might be otherwise avoided are burned asunder and too

often cause severe hæmorrhage, which is not easily controlled because of the difficulty of properly securing the charred extremities of the vessels. The resulting cicatrix is more disfiguring than that following other methods. It is advised in bronchotomy for diphtheria and acute affections of the air passages that the tube be dispensed with, since it can only prove a source of local irritation, and obstructs the exit of false membranes and the secretions. As a substitute, the borders of the tracheal opening can be kept drawn asunder by passing looped ligatures through them (Martin), which are united to each other behind the neck with this appliance. The patient must be carefully watched, since if the head be turned the opening may become closed. If this arrangement prove troublesome, an elliptical piece can be removed from the anterior surface of the trachea. If the piece to be removed exceed a third of the diameter of the tube, the high operation, above the isthmus, would be the one more easily and quickly performed, and would as well be less dangerous, as the vessels in that situation are more superficial, smaller, and of less significance. Cutaneous emphysema, bronchopneumonia, and pus infiltration of the thorax are more liable to happen in the low than in the high operation. It is wise to confine the hands and arms of the patient with a body bandage before operation. The median line of the neck should always point toward the center of the episternal notch during operation. The trachea should be seized with a hook and held as steady as possible during its incision and the introduction of the tube. The hissing entrance of air, coughing, etc., indicate that the lumen of the trachea is entered. The use of a probe-pointed bistoury in the enlargement of the tracheal wound affords better protection than the sharp-pointed to the posterior wall of the trachea. Low tracheotomy is indicated when it is desirable to remove the opening as far as possible from the seat of local infection above, also from the seat of hæmorrhage in order that the entrance to the trachea of blood may be more surely prevented. Large growths above call for low tracheotomy. In fact, the site of the opening is controlled by the demands of the case. Careful scrutiny during the operation of low tracheotomy should be exercised to observe and avoid the innominate, carotid, and median arteries, also the active thymus gland in children. As silver tubes sometimes cause the characteristic poisoning of that metal, it is better to use those made of other substances. The introduction of tubes wrapped in tightly fitting iodoform gauze, and their retention for two days, is sometimes practiced for antiseptic purposes. If the tube fits too tightly erosion of the cartilage follows. This sequel is oftener seen in children because of the too limited space in laryngotomy without division of the cricoid cartilage. A tube can be introduced more readily and safely if the head be raised up during the act. The employment of traction loops carried behind the neck and tied together, or connected with a small rubber band for securer action, should be discreetly practiced to avoid the constriction incident to swollen tissues and the tension arising from injudicious tying and persistent rubber traction. Severe and fatal hæmorrhage is sometimes a part of the history of the long-continued use of a badly fitting tube, especially in cases of low tracheotomy. The presence of granulations at the anterior and posterior

parts of the tracheal wound often render the incautious removal of the instrument painful and dangerous because of their obstruction to the entrance of air.

The After-treatment.—The tube should be kept in place until the cause for the operation is removed, after which the sooner it is dispensed with the better. However, the final removal should be approached in easy stages so regulated as not to expose the patient to the dangers and discomforts of obstructive symptoms that are so often a part of the history of a case, especially one of a prolonged or paralytic nature, in withdrawal of the tube. Cleanliness of the wound, absence of dust, and the utilization of moistened and medicated air, etc., are the essential features of treatment. The assurance that the tube is open and securely fixed in the trachea during the danger period requires constant attention, especially in children, who by restlessness or non-restraint may displace or remove it.

The Results.—But few perish from the direct results of the preceding operations. Bronchitis, infection pneumonia, hæmorrhage from ulceration through the trachea caused by the tube, and primary hæmorrhage from wounds of the vessels at the root of the neck, or from an abnormally large crico-thyroid artery, constitute the leading causes of death directly due to the operation. A deeply cyanosed patient, in the tonic stage of anaesthesia, may die, especially if blood be allowed to enter the tracheal opening. In this contingency the blood must be removed at once, and artificial respiration be resorted to. Tracheotomy in diphtheria is undoubtedly a most feasible operation, and should be performed early, before cyanosis is well established. *Monti*, of Vienna, in his recent work on Croup and Diphtheria, records 12,736 tracheotomies for diphtheria alone, with 3,409 recoveries, or nearly 28 per cent. It is estimated that 25 per cent of these cases have been saved which otherwise would have died. About 27.5 per cent perish from bronchotomy for the removal of foreign bodies. The use of antitoxine and the employment of intubation have rendered in this country the operation of tracheotomy comparatively infrequent. The beneficence of this change in both sentimental and medical aspects is of pronounced importance. The employment of antitoxine at the proper period, while not always preventing the need of tracheotomy, lessens the fatality when required.

Subhyoid Pharyngotomy.—This operation is practiced for the removal of foreign bodies and morbid growths situated high up in the air passage, and for the relief of abscesses at the base of the epiglottis.

The Operation.—Place the patient as for laryngotomy; administer an anaesthetic, and make an incision an inch and a half or two inches in length transversely along the lower border of the hyoid bone, with its center in the median line (Fig. 866, e). The integument, fascia, platysma, and the inner portions of the sterno-hyoid muscles, and finally of the thyro-hyoid muscles, are divided on a director. The only vessel contiguous to the incision is the superior thyroid artery, which runs along the upper border of the thyroid cartilage parallel with the incision. The thyro-hyoid membrane is now exposed and opened by a sharp-pointed knife carried obliquely upward. The mucous membrane is divided through the glosso-epiglottic fossa aided

by the fingers introduced into the mouth. If the greater cornua of the hyoid bone be severed about three fourths of an inch from the extremities, access to the pharynx will be facilitated. Divided vessels should be promptly tied to prevent entrance of blood to the trachea. As soon as the thyro-hyoid membrane is cut, the epiglottis will project through the opening, and must be drawn aside, when the tumor will be exposed to view (Fig. 870). After the removal of the growth, the wound is closed and dressed antiseptically. The majority of the conditions calling for this operation can be satisfactorily treated through the mouth.

The Prognosis.—The operation itself implies no unusual danger to the patient.

A preliminary tracheotomy should be performed if undue hæmorrhage is anticipated, as in the extirpation of a vascular growth, supplemented, perhaps, by plugging the trachea in urgent instances. The Trendelenburg posture will afford great advantage.

Intubation of the Larynx.—*Bouchut*, of Paris, conceived the idea, and *O'Dwyer*, of New York, by indefatigable and patient labor achieved the imperishable distinction of establishing its utility upon an enduring basis. Foreign bodies in the larynx and diseased processes contiguous to it, causing obstructive dyspnœa, are, as a rule, better treated by tracheotomy than by intubation. Chronic stenosis of the larynx from tubercle, syphilis, and other chronic states of an inflammatory nature can be promptly and often effectually treated by intubation. However, the chief importance of the measure rests in affording prompt relief in impending suffocation from membranous obstruction (Fig. 871). The following is a description of the apparatus:

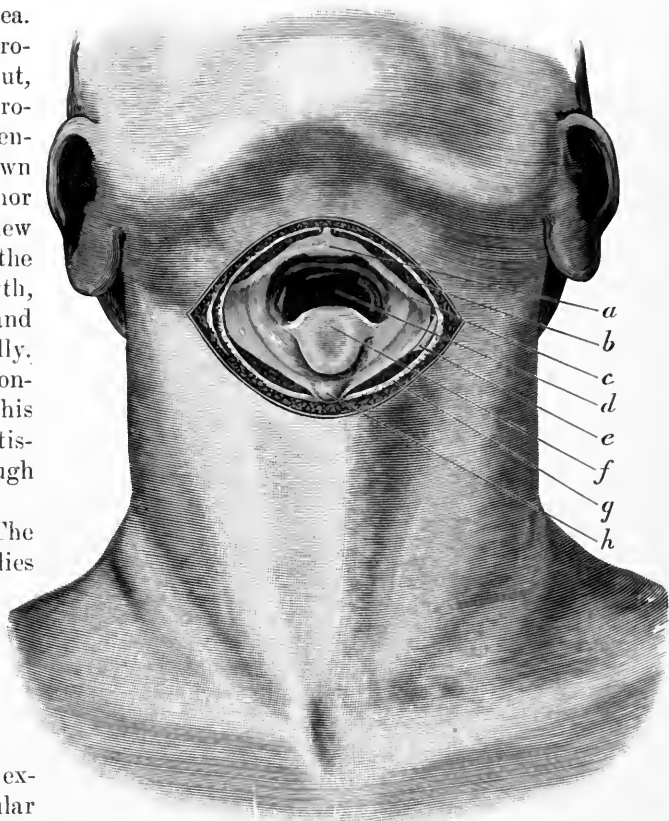


FIG. 870.—The operation of subhyoid pharyngotomy. *a.* Hyoid bone with thyro-hyoid membrane attached. *b.* Sterno-hyoid and omo-hyoid muscles. *c.* Extremity of greater cornu. *d.* Entrance to larynx. *e.* Superior laryngeal nerve. *f.* Epiglottis. *g.* Platysma. *h.* Thyroïd notch.

"The numbers on the scale (Fig. 871, *e*) indicate the years for which the corresponding tubes are suitable. For instance, the smallest tube when applied to the scale will reach the first line, marked 1, and is intended to

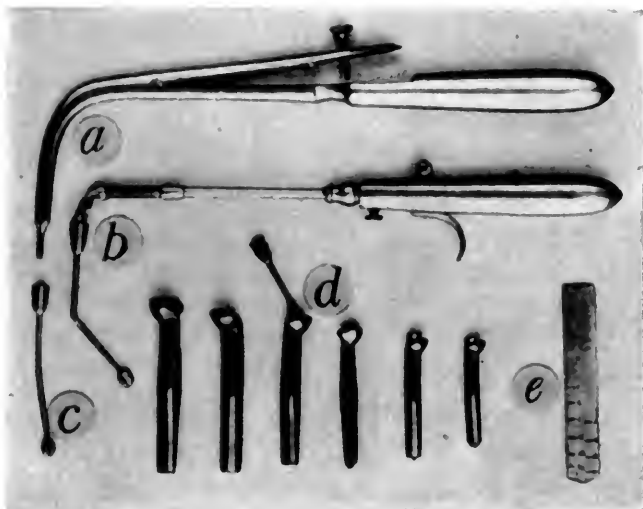


FIG. 871.—The O'Dwyer apparatus for intubation.

a. Extractor. *b.* Introducer with obturator attached. *c.* Obturator detached. *d.* Tubes, assorted sizes, one with obturator in place. *e.* Scale indicating size of tube mouth gag (Figs. 4 and 872), also the O'Dwyer gag. Tongue depressor may be required.

be used up to the age of twelve or fifteen months; the size marked 2 is suitable for the next year, 3 and 4 for these years, and so on. When the proper tube is selected for the case to be operated on, a loop of fine thread about fourteen inches in length is fixed through the small hole near its anterior angle, and left long enough to hang out of the mouth after the introduction of the tube, its object being to withdraw the tube should it be found to have passed into the cesophagus instead of the larynx.

"The obturator (Fig. 871, *c*) is then fastened tightly to the introducer (Fig. 871, *b*), to prevent the possibility of its rotating while being inserted, and passed into the tube.

"The following is the *method of introducing the tube*, which is done without the use of an anæsthetic: The child, with the arms confined, is held upright in the arms of a nurse, and the gag is (Fig. 872) inserted in the left angle of the mouth, well back between the teeth, and widely opened; an assistant holds the head, thrown somewhat backward, while the operator, standing in front, inserts the index finger of the left hand backward and downward into the throat, elevates the epiglottis, draws the base of the tongue forward, and at the same time directs the tube into the larynx (Fig. 873).

"The handle of the introducer (Fig. 871, *b*) is held close to the patient's chest in the beginning of the operation, and rapidly elevated so that the tube approaches the glottis at an acute angle, and passing under the end of the

finger (Fig. 874) is then pushed downward in the median line, without using force, and pressed into place by the finger and the tube detached (Fig. 875). The joint in the shank of the obturator is for the purpose of facilitating this part of the operation. As soon as the obturator is removed, and it is ascertained that the tube is in the larynx, the thread is withdrawn, but at the same time the finger is kept in contact with the tube to prevent its being also withdrawn (Fig. 876).

“It is important that the attempt at introduction be made quickly, as respiration is practically suspended from the time that the finger enters the larynx until the obturator is removed. It is therefore, under the circumstances, much safer to make several abortive attempts than one prolonged effort, even if successful.

“For the purpose of removal, the patient is held in a similar position, except that the head is not inclined backward, or very slight-

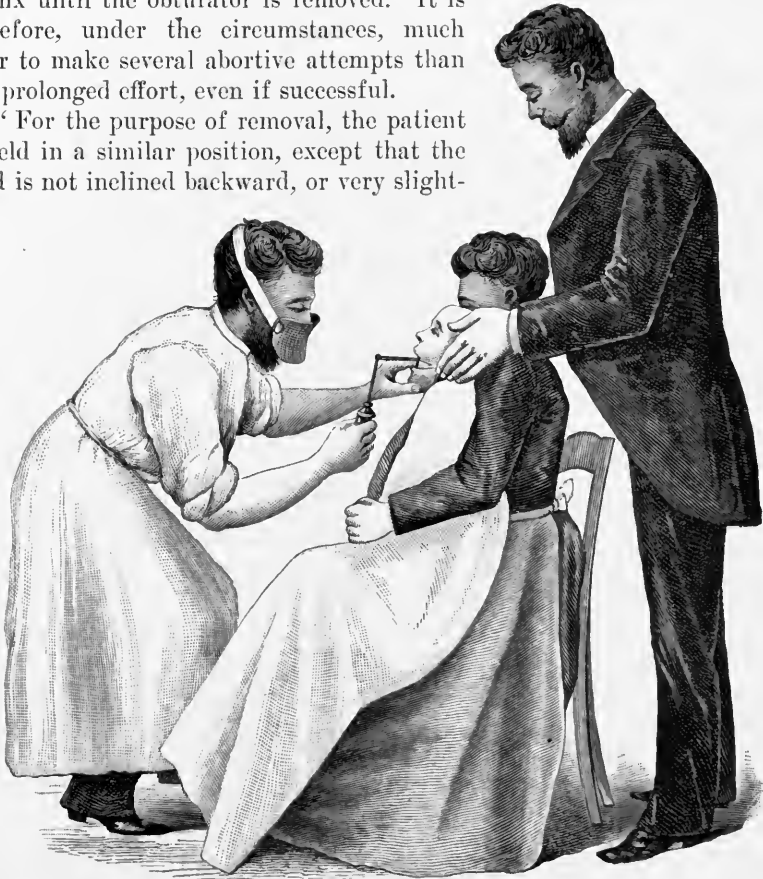


FIG. 872.—The operation of intubation. Method of introducing the tube. The respiratory tract of operator protected from infection by mouth shield, and clothing by a gown.

ly so, and the extractor (Fig. 871, *a*) is passed cautiously and lightly into the tube guided by the index finger of the left hand, which also fixes the epiglottis, and is brought in contact with the head of the tube. Firm pressure with the thumb is then made on the lever, above the handle, while the tube is being withdrawn. If secondary dyspnoea supervenes at any time, the tube should be removed and a larger one substituted.”

The late Dr. O'Dwyer recommended that preliminary practice in the introduction and removal of the tube, and touching of the parts, be had upon the cadaver when possible. The removal of the tube is more difficult than

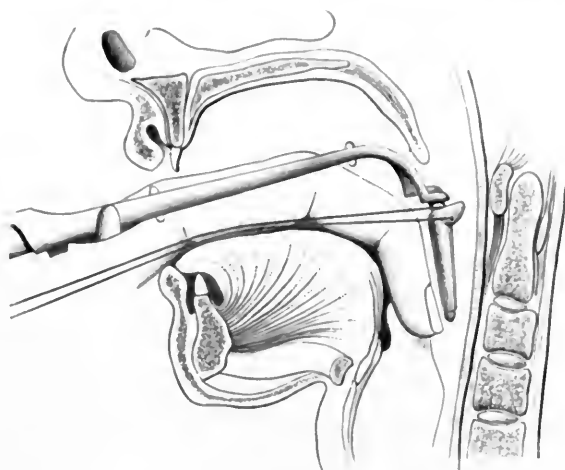


FIG. 873.—The operation of intubation. Elevating epiglottis and drawing tongue forward with finger, directing tube into larynx. String in tube.

the introduction, on account of the trouble of inserting the blades of the extractor into the open upper end of the tube while more or less completely hidden from view by the natural position of the surrounding soft parts. This part of the operation becomes especially troublesome when the patient offers any opposition to the attempt, and it may become necessary under these circumstances to administer an anæsthetic before the tube can be safely removed. The

occurrence of spasm during this time may be met by holding the finger in place until the irritation subsides.

The Precautions.—It is often wise in intubation to prepare for tracheotomy (Fig. 864), as efforts at intubation may not succeed.

Do not remove the loop until quiet breathing has continued for half an hour or so, and do not permit the patient to grasp it. The introduction of the tube is rarely attended with asphyxia due to detachment downward of the membrane, and then, if the patient be caused to cough as the tube is quickly withdrawn, the membrane is usually expelled. Failing in this, tracheotomy forceps may be tried for removal of the membrane, which, if ineffective, is followed at once by tracheotomy. Three or four

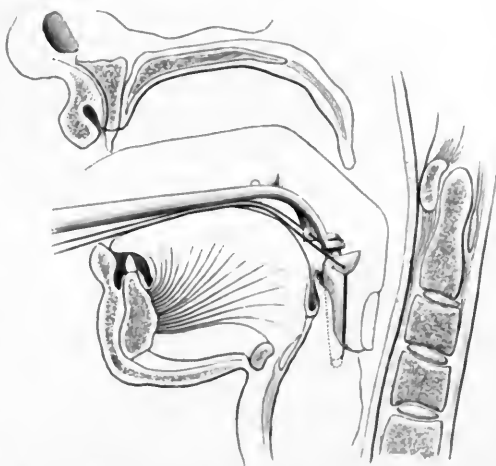


FIG. 874.—The operation of intubation. Tube passing under end of finger.

per cent only require the latter measure of relief. The tube may be passed into the œsophagus and possibly enter the trachea. The evidences of par-

tially detached membrane in the trachea call for prompt removal of the tube. Inversion of the patient and striking of the body by the attendants

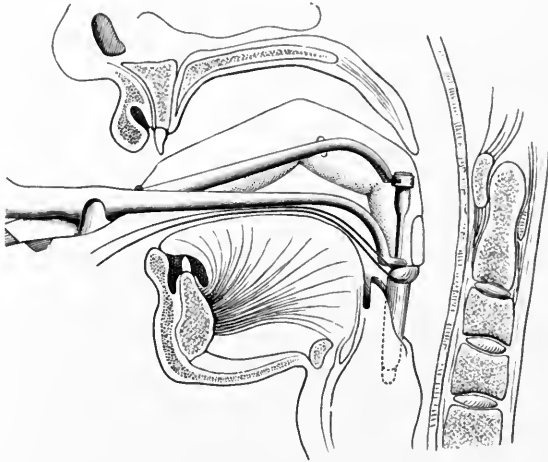


FIG. 875.—The operation of intubation. The tube pressed into place with the finger and detached from obturator.

may cause the tube to be expelled along with the obstructing membrane and rescue the patient without the dangers of delay. The not infrequent occurrence of severe and perhaps fatal dyspnoea, following removal of the tube, enjoins close attention to the patient for an hour or so thereafter.

The Remarks.—In the adult the tube can be introduced by aid of a mirror, especially when the throat is accustomed to the use. It is wise for the operator to give some little amount of time to practicing in introducing the tube. The extracting of the tube from the clinched hand will offer in a degree the needed opportunity for this kind of practice. Should the tube happen to slip below the vocal cords it will no doubt be arrested by the cricoid cartilage, and only by division of the latter can the tube be withdrawn from below.

The After-treatment.—Quiet, support, and cleanliness are indicated. *Carey* and *Casselberry* have recorded the important fact that with the head lower than the shoulders food can be swallowed quite readily with the tube in place without much trouble. Highly nutritious fluid foods are commonly employed in these cases.

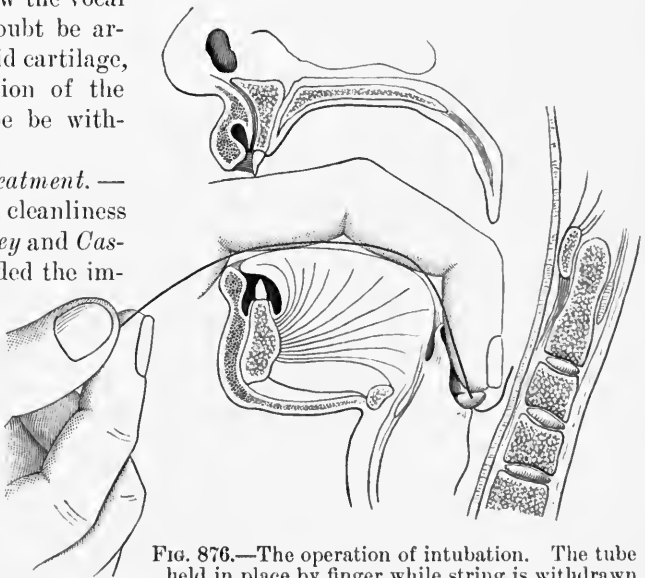


FIG. 876.—The operation of intubation. The tube held in place by finger while string is withdrawn.

Usually the tube is removed in four or five days and not reintroduced thereafter without special indications.

The Results.—*McNaughton* and *Maddern* reported 5,546 cases of intubation with 69.5 per cent mortality without the use of antitoxine. Five hundred and thirty-three cases with the use of antitoxine gave 25.9 per cent mortality. With the use of antitoxine—

	Cases.	Recoveries.
Brown reports	2,368	647
Ranke reports	1,445	553
McNaughton reports	72	28
O'Dwyer reports	30	10

Waxham reports 543 cases of intubation in private practice with 39.29 per cent recoveries.

It is quite apparent that intubation is followed by a higher rate of recovery than is tracheotomy, and that the administration of antitoxine increases the efficiency of intubation in an astonishing degree.

Foreign Bodies in the Air Passages.—Foreign bodies invade the air passages, and in many instances cause alarming symptoms followed by a rapid and fatal outcome. The larynx, trachea, and bronchi are the common sites of invasion, and demand the exercise of discreet though prompt and efficient action for relief. A knowledge of the nature of the foreign body is of great importance, as bearing on the ease of removal and the kind of tissue changes induced by its presence. The surroundings of the patient have much to do with determining the nature of these bodies. However, corn, beans, various seeds, and small toys make up a large proportion of these offending agents. Seeds increase in size naturally from the absorption of moisture, and become therefore more difficult of removal as time advances. Organic agents of infective character are especially dangerous because of the tissue changes which they incite. Inorganic substances are the least objectionable unless endowed with some special destructive nature. The employment of the X rays are especially serviceable in determining the location and nature of the object.

The invasion of the larynx by a foreign body, attended with symptoms of pronounced character, calls for a prompt examination of the throat and larynx with the finger, and unless relief be thus promptly afforded, laryngotomy in the adult and tracheotomy in the child should be performed at once. When the symptoms are not urgent, a more deliberate course can be followed, fortified by the knowledge gained by the use of the laryngoscope, fluoroscope, and other methods of inquiry. And, too, the removal may be deliberately conducted with approved instruments, and operative procedures directed to opening the larynx above, through, or below the thyroid cartilage, according to the situation of the foreign body, utilizing by this route the best channel for removal.

The invasion of the trachea by a foreign body calls for a prompt low tracheotomy, which should be done, if possible, before the fixation of the foreign body in a bronchus takes place. The opening should be free to admit of prompt escape of the offending agent with the act of coughing. If the foreign body have become fixed already, dislodgment should be at-

tempted with a probe or feather, while the tracheal opening is held widely apart to facilitate the escape. Inversion of the patient, thumping on the back, etc., are practiced *after tracheotomy* is performed. In the interval of the attempts at removal the borders of the tracheal wound should be held widely apart with traction sutures carried through each border around the neck and tied behind.

The invasion of a bronchus by, and final fixation there, of a foreign body, while not immediately dangerous, exposes the patient to many problematical contingencies of a fatal nature. The foreign body may block the entire right or left bronchus, or one or more subdivisions of the same, singly or simultaneously, according to its size. The right bronchus is involved more frequently than the left, the proportion being three of the former to two of the latter.

The Treatment.—In the instance of seed impaction, a policy of conservatism is usually the wiser one.

Inversion and thumping on the back can be practiced without tracheotomy when the object is known to be of so small a size as to readily escape through the rima glottidis. However, if the object be a large one or of uncertain size, or the case one which has been attended already by violent efforts at expulsion, then tracheotomy and wide separation of the tracheal opening should always precede any effort at dislodgment.

Direct dislodgment is practiced with forceps, probes, bent wire, blunt hooks, suction by a rubber tube attached to Bigelow's litholopaxy pump, corkscrew apparatus, etc. The stereotyped and extemporized implements and means for extraction are numerous, but favorable outcome does not keep pace with ingenuous though often unwise instrumentation. In general terms the following plan of interference is commended: Locate the site of the impacted obstruction by auscultation, etc.; perform a free, low tracheotomy, and hold the borders of the tracheal wound widely asunder with traction sutures; introduce a flexible probe, and locate the obstruction and dislodge it if possible; failing in this, try forceps of proper size and shape, or a wire with a hooked extremity, or fine silver wire looped and passed beyond the obstructing agent and withdrawn. The patient should be under an anæsthetic during the attempts, otherwise the spasmodic cough, due to the irritation of the manipulation, will defeat careful effort and perhaps cause avoidable disaster. It may be advisable to open the thorax posteriorly to effect relief (page 1288).

The Comments.—When tracheotomy is followed by entire relief from dyspnœa, the foreign body is either in the larynx or occupies a small tube. The presence of a foreign body in the bronchus is not an absolute indication for operation, as circumstances may contraindicate it. When the obstruction can be located, a low tracheotomy is justifiable with brief, cautious attempts at extraction.

The question of tracheotomy will depend largely upon the form, size, and character of the foreign body. Not more than three attempts of a minute each should be employed with forceps to remove a foreign body (Gross).

“Low tracheotomy is advisable when the presence of a foreign body is certain; it adds but little to the risk and affords easier escape for the object, even when extraction is not feasible.

“Subsequent dangers arise from severe and prolonged instrumentation, not from tracheotomy. Voluntary expulsion is more probable after than before tracheotomy.

“The risks of thoracotomy and bronchotomy, following unsuccessful tracheotomy, are greater than the dangers incurred by permitting the foreign body to remain” (Willard).

The Results.—*Voluntary expulsion* is not an uncommon occurrence, happening within a few hours, or after weeks' and even years' delay. Nearly 90 per cent will recover without operative interference (Weist).

“When a foreign body becomes impacted in the bronchus, extraction is an impossibility in 78 per cent of the cases even after tracheotomy” (Willard).

The employment of instruments increases the death rate from pneumonia 12 per cent. *Smith* reports in 1,600 cases a 70-per-cent rate of recovery in the non-operative and 76 per cent in operative cases. *Dunham* reports 50 per cent recoveries in non-operative and 77 per cent in operative cases.

Guyon and *Dunham* in 1,674 cases report 70 per cent recoveries in non-operative and 75 per cent in operative cases. About 10 per cent die from the operation only.

Laryngectomy.—Laryngectomy is a serious operation and is not practiced except for the cure of malignant disease. It consists in the removal of a part or the whole of the larynx, and is classified, therefore, as the complete and incomplete varieties.

Complete Laryngectomy.—If the neck be not too short for the purpose, as may be the case in emphysematous patients, a preliminary tracheotomy should be performed several days in advance of the major operation, to accustom the pulmonary tissues of the patient the sooner to the influences of the abnormal respiratory channel. If the neck be too short for the utilization of this preparatory step, the cannula may be introduced during the course of the operation (Kocher). After the patient is anesthetized, the trachea should be plugged by the use of the Trendelenburg or the Hahn sponge tampon cannula (Figs. 878 and 879), being certain that the rubber tampon is new and that it be slowly distended into the proper position. The ordinary cannula, supplemented by sponge packing, is employed with entire satisfaction by many surgeons.

The Operation (Kocher).—Place the patient on the back with the shoulders raised and the head extended over a padded bottle or sandbag; make an incision in the median line from the hyoid bone downward to a point an inch and a quarter below the cricoid cartilage, exposing the thyroid and cricoid cartilages and the upper border of the isthmus of the thyroid body; divide the suspensory ligament of the isthmus at the lower border of the cricoid; separate the isthmus and its associated transverse veins from the trachea and push them downward with a blunt dissector; divide the cricoid

and upper rings of the trachea in the median line, forcing the isthmus downward and even dividing it between two ligatures in the median line if sufficient room can not be otherwise gained; introduce the tampon cannula; make a transverse incision through the skin and fascia along the hyoid bone, ligaturing the anterior jugular veins; divide the sterno-hyoid, the omo-hyoid, and thyro-hyoid muscles close to the hyoid bone, at their insertions; draw the hyoid bone up with a strong, sharp hook; divide transversely the portion of the thyro-hyoid membrane attached to the middle part of the hyoid bone; divide also the subjacent mucous membrane and seize the epiglottis at its upper part with a sharp hook and draw it forward; slit the epiglottis medianly if healthy, if unhealthy cut round it beyond the diseased tissue; split the thyroid cartilage at the middle downward to the tracheal wound; arrest hæmorrhage at the wound edges and paint them with a ten-per-cent solution of cocain to obviate the coughing and swallowing reflexes; define the limits of the new growth and divide the tissues beyond them; divide the mucous membrane with the thermo-cautery. If the whole larynx be diseased, divide the mucous membrane along the epiglottis, arytenoid cartilages, the larynx or trachea, to below the tumor; expose the outer surface of the larynx, preserving the muscles in so far as is consistent with the removal of diseased tissue; expose the cartilages and remove them partially or entirely, according to the extent of the disease; retain the healthy and movable mucous membranes at the posterior surface of the cricoid cartilage; continue downward the dissection to the lower limit of the disease, dividing the healthy cricoid or trachea transversely; sew upward as far as possible the anterior wall of the œsophagus and pharynx to re-establish the septum between the respiratory and alimentary passages (page 709).

The After-treatment.—Substitute a simple cannula for the tampon cannula. Introduce no sutures, but stuff the cavity with carbolic gauze which is changed every two hours. Feed the patient through an œsophageal tube and get him out of bed as soon as possible.

The Results.—But 1 case in 12 died from this plan of operation.

Treves's Method.—The following succinct plan of procedure is introduced from Treves's Operative Surgery:

The Operation.—The patient lies upon the back, close to the right border of the table. The shoulders are raised, and the head is well extended over a hard cushion or sandbag. The surgeon stands on the patient's right. The chief assistant takes his place at the head of the couch, and close to the surgeon's left. An incision is made in the median line from the center of the thyro-hyoid membrane to the second or third ring of the trachea. At the upper end of this incision a transverse cut is made which is carried outward on either side sufficiently far to reach the sterno-mastoid muscles.

"The flaps thus marked out are turned back. Some division of the fibers of the sterno-mastoid muscles may be necessary. The vertical incision should go down to the thyroid and cricoid cartilages and the trachea.

"The superior thyroid arteries may, if thought fit, be dealt with at this stage. They should be secured by two ligatures, and then divided between

them. The vessels would be sought for at the posterior margin of the thyro-hyoid muscle, close to the upper border of the thyroid cartilage.

“The inferior thyroid arteries may be exposed and dealt with in the same manner as they turn forward at the lower margin of the larynx. They should be sought for beneath the posterior edge of the sterno-thyroid muscle.

“The fascia having been well divided in the middle line, a broad periosteal elevator or a rugine is introduced, and by means of it the soft parts can be separated from the laryngeal cartilages without employing the knife.

“The crico-thyroid, sterno-thyroid, and thyro-hyoid muscles are detached on one side, and are, together with the other soft parts, held with a retractor while the larynx is drawn over to the other side by means of a sharp double hook. The attachment of the inferior constrictor muscle to the thyroid cartilage can now be severed, partly by detachment with the elevator or rugine, and partly by cutting it with curved, blunt-pointed scissors, which are kept very close to the cartilage. The larynx is now pulled forward as well as to the opposite side, and the tissues are divided about the gap which intervenes between the cut and now separated ends of the superior thyroid artery. The superior laryngeal nerve is also now divided. The thyroid gland is pushed aside with the soft parts.

“If the larynx be now well drawn over to the other side, the other half of the organ can be stripped of its coverings in precisely the same manner.

“The next step is to divide the thyro-hyoid ligaments and membrane, and to cut the extralaryngeal connections of the epiglottis. This structure may be conveniently drawn forward while its attachments are being freed.

“The entire larynx is now pulled forward by means of sharp hooks introduced into its upper part, and the organ is separated from its remaining connections with the pharynx and œsophagus—at first laterally, and then from above downward.

“If proper care be taken, the œsophagus should be nowhere ‘button-holed.’ Special care is required to separate the cricoid cartilage from the commencement of the gullet.

“The trachea is now secured (unless already adherent) by means of two ligatures, which are held by an assistant, and the excision is completed by dividing the membrane between the cricoid cartilage and the trachea from behind forward.

“One or more rings of the trachea may be removed at the same time if it be considered necessary.

“The upper end of the divided trachea, which has been prevented from slipping down by the two ligatures, is now secured to the integument by several points of interrupted suture.

“Three or four deep sutures of silver wire are passed beneath the uppermost ring, and are made to attach the windpipe securely to the skin; a further series of fine superficial sutures unite the mucous membrane of the trachea to the cut margin of the skin.

“The bleeding throughout the operation will be free, and each small vessel should be ligatured as soon as it is divided. The limited space does not favor the use of many pressure forceps.”

It often happens that in addition to the larynx the hyoid bone, base of the tongue, pharynx, and œsophagus are involved in a malignant growth. If operation be attempted, under these circumstances, the first step is to introduce the tampon cannula of Trendelenburg, or a substitute, through which the anæsthetic is administered. Then make a transverse incision through the skin from the inner edge of one sterno-mastoid muscle to the other, passing half an inch above the hyoid bone; from this carry a second one vertically downward along the median line of the trachea to the incision made to open the trachea; turn the flaps outward; remove all large glands in the vicinity; divide the muscular attachments to the hyoid bone; tie the lingual and superior thyroid arteries; excise the tongue below the disease, along with the palato-pharyngeal arches, if necessary, carefully avoiding the external carotid arteries when it is possible; if not possible, draw them forward along with the pharynx and divide them between two ligatures; cut the lingual and hypoglossal nerves. The larynx is now separated from the trachea by cutting the latter just below the cricoid cartilage; a cannula is introduced into it, the parts are thoroughly washed with a carbolized solution, the flaps placed in contact with the raw surfaces without sutures, and the wound sprinkled with iodoform. If the œsophagus be divided, its lower extremity must be kept open and so placed that it can be protected from the entrance of discharges, and become an available channel through which to nourish the patient.

Partial Laryngectomy.—Partial laryngectomy is practiced when the limited extent of the disease does not require the removal of the entire organ. Half of the larynx, or half of the thyroid cartilage, with or without the cricoid, may be removed. Inasmuch as the same dangers are incurred as in the complete operation, although in a lesser degree in some respects, similar means of prevention are necessarily employed. The incisions relate only to the affected side. The organ is split in the median line and the cavity examined. The thyroid cartilage is carefully removed (page 700), cautiously avoiding injury of the pharynx. The associated membranes are divided as closely as practicable to the cartilage. The superior cornu of the cartilage is removed with strong scissors or pliers. The epiglottis is usually left entire, and the aryteno-epiglottidean fold of the diseased side is divided close to the cuneiform cartilage.

The Precautions.—Prompt arrest of hæmorrhage, close hugging of the cartilage during removal, careful avoidance of injury to the œsophagus, complete asepsis, and the prevention of pulmonary infection are the important features of the operation.

The Remarks.—The tampon cannula and the tracheotomy tube are used the same (if at all) as in the complete operation, except that they are employed for a briefer period. The cricoid cartilage may be removed entire, or half only may be taken away along with the thyroid. The fact that cancer slowly involves the cartilage, causing localized death, unattended by much infiltration, suggests the practice of removal of circumscribed disease by cutting and scraping, even when the cartilage is superficially involved. We are not disposed to regard with favor treatments of this kind, unless for some

special reason, and then only when a strict monthly surveillance can be exercised to note any evidences of return. The after-treatment is not unlike that of the complete operation, but is less extended because of the less profound nature of the wound.

The Results.—The death rate of partial removal is lower than is that of complete removal. The rate of final cure is somewhat less in the former than in the latter method of practice.

The General Remarks.—An ordinary tracheotomy tube can be fortified with a sponge confined in place around the tube with thread, so that when wet it will occlude the trachea. *Gussenbauer* regards high tracheotomy as a legitimate part of the procedure and performs it as an initial step. Splitting of the larynx enables one to determine the extent of the disease, and perhaps save a part of the organ. There appears to be no good reason why the epiglottis and cricoid cartilage should be saved even though not diseased and their presence is sometimes objectionable. Enlarged cervical glands should be sought for and removed. Malignant involvement of the soft parts outside the larynx contraindicates operation. Only the transverse skin incisions are sewed. The wound is stuffed with gauze, which is changed every eight hours or so. The tampon cannula is usually removed and the tracheotomy tube substituted after two or three days. However, some surgeons employ the former much longer—ten or twelve days. *Treves* advises that a rubber tube be introduced into the stomach through the œsophagus, and fastened there for four or five days, and even longer, for alimentary purposes. In 171 cases preliminary tracheotomy was omitted in but 8. The tissues should not be bruised or torn during their separation from the larynx, but instead should be clean cut. Therefore, suitable room for observation and treatment should be secured by judicious division of restraining tissues. Complete arrest of bleeding is necessary before opening the air passages, especially if preliminary tracheotomy has not been done. Additional caution is requisite to prevent wound infection when the larynx has been split before removal.

Keen's Plan of Operation.—*Keen*, in a recent address* on the technique of total laryngectomy, in reporting a strikingly successful case of his own, dwelt especially on the preparatory and technical steps of the operation. He advises that thorough preliminary disinfection of the mouth, nasopharynx, and larynx with suitable antiseptic solutions be frequently made for two or three days before the operation. Thorough and frequent use of the toothbrush and the removal of offending carious stumps are also advised. The performance of tracheotomy ten days or two weeks before operation is counseled in cases suffering from dyspnoea, and then only for improving the patient's condition and not to prevent the entrance of blood to the trachea. Tracheotomy immediately preceding or attending the operation, *Keen* does not regard as essential in all cases, and when thus practiced the opening should be closed, if practicable, as soon as the operation is completed. He substitutes when advisable the Trendelenburg position for the

* Transactions of the American Surgical Association, vol. xvii, 1899.

use of the various tampon cannulæ, thus removing from the list an agent of hindrance and of special danger. Anæsthetics are administered through the mouth until the air passage is opened, when a large tracheotomy tube is introduced, through which anæsthesia is continued. The patient's head is kept low for a day following the operation by raising the foot of the bed. On the second day the horizontal, on the third day the sitting posture, and on the fourth out-of-bed, respectively, is advised. Nutritive enemata are given for two days, followed by a teaspoonful of liquid food every half hour by the mouth, washed down by a tablespoonful of sterile water. At the end of a week the amount is much increased, solid food being taken after the tenth day. In the reported case the patient could swallow from the first without instrumental aid. Also in this case the gauze drain was removed on the following day, half of the stitches on the fourth, and the remainder on the sixth day after the operation. In the case in question the total extirpation followed about four and a half months after a thyrotomy performed for cure of an intralaryngeal malignant growth. The patient was placed in the Trendelenburg position and a median incision was made along the scar of the previous operation. The thyroid cartilage was split in halves, the borders were drawn apart to determine the extent of the disease, and thereby also that of the proposed operation. The soft parts were dissected away from the sides of the larynx, the median incision was carried down nearly to the sternum, the trachea exposed, a low tracheotomy done, an ordinary large tracheotomy tube introduced, the inner tube then removed, and the chloroform apparatus connected with the central tube by means of the metal tube of Hahn's cannula. The trachea was then divided across below the thyroid cartilage, the lower end of the larynx drawn forward and upward by means of a hook and the finger, and the posterior surface of the organ was separated from the œsophagus by means of the finger and Allis's blunt dissector as far as the upper border, when the attachments to this portion were divided with scissors and the larynx was removed. The epiglottis was also removed. "The upper edge of the anterior wall of the pharynx was then carefully attached to the tissues just below the hyoid bone by interrupted silk sutures placed very close together," thus shutting off the secretions of the pharynx and mouth from the wound. The upper end of the trachea was united to the skin by silk sutures, the tube removed, and the tracheotomy wound closed by suturing the rings with catgut, and the remaining tissues of the wound by silkworm-gut sutures. The wound above the exposed end of the trachea was closed by silkworm-gut sutures and a small gauze drain inserted at its lower portion. Narrow strips of folded gauze were laid above and below the exposed end of the trachea, which was then protected by placing over it a sterilized wooden pill box without bottom or top, covered with two or three layers of gauze properly fastened to the contiguous dressing. The pill box and gauze were removed from time to time for the purposes of cleanliness. The wound healed at once throughout and the patient made a prompt, complete, and uneventful recovery.

The Remarks.—After four days the occasional introduction of the tube was advisable to counteract the tendency to closure of the open end, because

of contraction, and to the inturning of the integumentary borders. As already indicated at the beginning, the stitches should be removed as promptly as possible. In indicating briefly the future technique in a similar case, Keen says: "In my next case, after dissecting the soft parts from the larynx and upper trachea back to the œsophagus on both sides, I shall place the patient in the Trendelenburg position and deepen the narcosis to a slight extent. I shall then divide the trachea transversely, and by three sutures, one in the middle line and one on each side, shall quickly attach the tracheal stump to the skin. Then I shall introduce the ordinary tracheotomy tube into the open end of the trachea instead of through a tracheotomy wound, and continue the anæsthetic through the tube. The later steps of the operation will be the same as above described. In order not to embarrass the operator the flange of the tracheotomy tube should only project at the sides, as the usual wide upper border of the flange would interfere with access to the parts at the beginning of the removal of the larynx."

The plan of action expressed and practiced by Keen reduces the danger from infection to a minimum and shortens the time of operation. In suitable cases, and in the hands of experienced operators, the arrangement of the details will without doubt greatly improve the outcome in many respects. The amount of hæmorrhage is comparatively small in any event if care be exercised in the selection of cases and in their treatment. The utilization of the artificial larynx is prevented in this method unless a secondary operation be done.

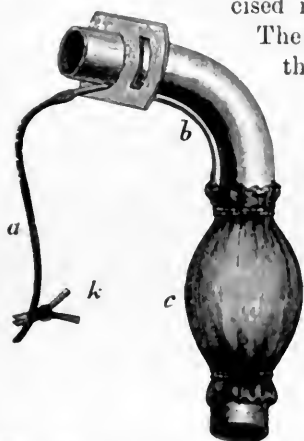


FIG. 877.—Trendelenburg's tampon. *a*, *b*. Tube for inflating rubber bag (*c*). *k*. Clamp.

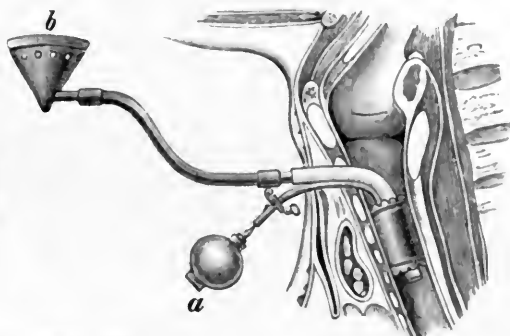


FIG. 878.—Trendelenburg's tampon in position. *a*, Bag for inflation of the tampon. *b*. Metallic funnel covered with flannel for anæsthesia.

Perier recommends the performance of laryngectomy without preliminary tracheotomy through an I-shaped incision made from the hyoid bone to below the cricoid cartilage. The larynx is exposed laterally, two stout threads are passed through the trachea at the site of proposed division, the trachea is severed, and a special tube is inserted into the open end through which anæsthesia is continued while the operation is being completed.

Tamponing of the Trachea.—Tamponing the trachea calls for more than passing notice because of the acknowledged, direct, and consequent dangers

which the act incurs, and also of the growing tendency to ignore tampon cannulae altogether when it is possible to supplement their utility by postural methods. Tamponing the trachea is done to prevent the entrance of blood to the trachea in unusual operations on the larynx, and the oral and pharyngeal cavities. The methods most often employed are those of Trendelenburg (Figs. 877 and 878), Hahn (Fig. 879), and Gerster (Fig. 880). *The first* is provided with a thin rubber bag so adjusted to the tube that after introduction into the trachea it can be inflated with air by a rubber bulb. If it is to remain some time after the operation, water or glycerin are regarded as more serviceable than air. *In the second*, medicated sponge is substituted for the rubber bag. The sponge is fashioned of a proper shape and thickness, fastened around the tube with thread, and permitted to dry. The thread is then removed, leaving the sponge firmly fixed in place, which is then covered with rubber tissue tied in position. The extremity of the tampon is introduced and the sponge moistened with a solution of boric acid injected into it through an opening in the tube by a hypodermic syringe. The sponge swells and closes the trachea, and may be permitted to remain in place for some time provided that the discharges of the wound do not come in contact with it. *The third form* is caused to fit the trachea by inflation. The mechanism of its adjustment for use is commendable. However, the objections to the use of these forms of apparatus is fast leading to their abandonment when possible. The rings of the trachea have sustained severe injury from their introduction and from pressure necrosis. The failure to properly close the trachea and the liability of the rubber to rupture have been followed by



FIG. 879.—Tampon after Hahn and Michael.

annoying complications from hæmorrhage. A too great distention may cause the rubber tissue to balloon and obstruct the end of the tube. Gerster's apparatus seems to afford the most satisfaction of any. Each of these cannula is provided for the adjustment of a stereotyped (Fig. 878) or extemporized (Fig.

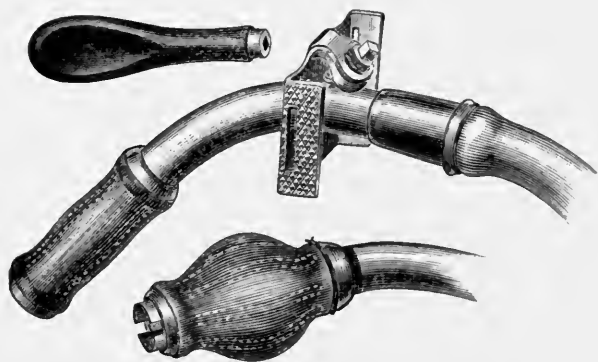


FIG. 880.—Gerster's trachea tampon cannula.

831) appliance for the administration of the anæsthetic. The introduction into the open end of a tracheal stump of a large ordinary tracheotomy tube supplemented by gauze packing around it is a prompt and serviceable

method of practice. The introduction above the tube, in low tracheotomy, of pieces of iodoform gauze to arrest discharges coming from above are regarded as beneficial in diphtheria and infectious discharges from other causes.

The Artificial Larynx (Fig. 881).—Within four or five weeks after operation, or when the parts are well healed, the artificial larynx may be

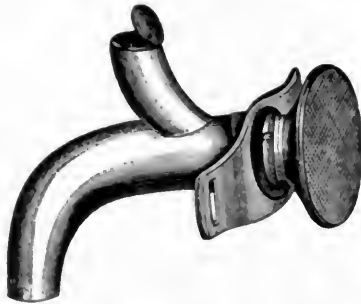


FIG. 881.—Gussenbauer's artificial larynx.

inserted. At that time competent authority should be consulted in order to secure the most serviceable apparatus in all respects. In some instances the artificial larynx gives but little trouble and adds much comfort to the patient; in others its use is but little cultivated and often quickly discarded. Gussenbauer's artificial larynx consists of a long tracheal tube and an upper short speaking tube. Wolff's apparatus is by some regarded more efficient than the former. A T-shaped tube is preferred by some patients, although it affords

only the lisping voice. Methodical exercise will often enable a patient to speak aloud without the use of an artificial appliance.

The Precautions.—Exercise forethought and care to save the mucous membrane of the anterior aspect of the upper end of the pharynx, the posterior aspect of the larynx, and the epiglottis itself (Bardenhauer), with the idea of so uniting together these various structures as to eliminate from the wound, the mouth, the pharynx, and the œsophagus, along with their malign infective influences. If now the divided muscles (Rotter) (depressors of the os hyoid) be united over the mucous flaps the latter will be correspondingly strengthened in all respects. The utilization of skin flaps over the muscular tissue (Rotter) adds greatly to the strength of repair and lessens the size of the external wound. *Hartley* emphasizes the need of determining the presence of infected lymph nodes before operation, and the hopelessness of operation unless all disease can be removed. The lymph nodes can be practically divided into those of the upper and the lower districts of the larynx. Those of the *upper* are located upon the thyro-hyoid membrane, near the lesser cornu of the hyoid bone, beneath the posterior belly of the digastric, upon the posterior border of the thyro-hyoid muscle and at the bifurcation of the carotid artery. Those of the *lower* are found over the crico-thyroid membrane and the isthmus of the thyroid gland, over the crico-thyroid muscles and the posterior surface of the lateral lobes of the thyroid gland and behind the lateral lobes and in the interval between the trachea and œsophagus. These various locations should be thoroughly examined for diseased nodes during operation.

The Comments.—Infective processes of the lungs and of the cervical tissues are not infrequent causes of death in this operation. With the view of obviating the former, local instead of general anæsthesia (ether) is now employed when practicable. Cocain for local effect on the mucous

membrane and perhaps by infiltration (page 40) during operation, either alone or supplemented with chloroform or morphine, is commendable practice. The positions of Trendelenburg and of Rose by gravitation prevent insufflation infection and render unimportant provisional tracheotomy and the use of the various forms of tampon cannulæ. Glück apparently secured his gratifying results by eliminating the possibility of pulmonary infection by dividing the trachea above and then raising forward and fixing the upper end in the cervical wound before removing the larynx. The shutting of the wound from the mouth and pharynx is another advance of decided benefit (see Precautions). Glück as well shut off the mouth and pharynx from the wound, chiefly by means of superimposed skin flaps taken from the neck and arranged after the manner practiced by Szymanowsky for cure of urethral fistula (Fig. 1684). Free loosening of the trachea from its immediate connections permitted Foederle to unite the end to hyoid bone with sutures. To this may be added the union of the mucous membrane of the trachea to the borders of the mucous membrane of the posterior aspect of the larynx. In this connection it should be said that gangrene of the trachea from a too free separation of its connecting tissue, along with undue traction and infection, and the giving way of the union between it and the hyoid bone from too great traction, are complications not unknown and always to be apprehended in this plan of treatment. It is apparent at once that the extent of the closure, as well as the primary location, will exercise great influence in the selection of the source of the tissue for purposes of repair. The cricoid cartilage should be saved if possible.

The After-treatment.—The unclosed part of the wound is packed with gauze and the patient is kept in bed without a pillow with the foot of the bed raised, thus favoring dependant drainage. Rectal nourishment is administered every sixth and saline solution every third hour. On the third day the patient is encouraged to try swallowing small amounts of water, which a little later he will do successfully provided the wound be properly shut off from the oro-pharynx. A closure of the wound by gentle external digital pressure during the effort of swallowing (the same as in œsophagotomy) (page 670) may effect the purpose. In case of failure the use of a catheter passed through the nostril or the mouth may be required. It will not come amiss if the patient be taught to swallow in the Trendelenburg posture before operation, for apparent reasons.

The Results.—The mortality of 60 per cent of 1881 was reduced to 33 per cent in 1895, as based on 309 cases, of which 10 per cent had remained cured for over three years (Powers and White). In 1900, Glück reported 34 total operations for malignant diseases with a mortality of only 8.5 per cent. Hartley reports that the death rate for laryngectomies from 1886 to 1900 diminished from 44 per cent to 8.5 per cent, and that the remaining cured for over three years increased from 13 per cent to 33 per cent during that time. Regarding excision of the soft parts of the larynx combined with thyrectomy, Hartley reports that the permanent cures are 44 per cent, with a death rate of about 11 per cent. This steady increase

is due to the improvement in the technique especially relating to measures directed to the prevention of infective pneumonia and cellulitis of the contiguous cervical tissue. It can be safely said, we think, that earlier recognition of the disease and prompter diagnosis attended with urgent demand on the part of the medical attendant that the aid of the surgeon be invoked, will add much indeed to the present outcome.

Estimates show a positive cure (three years or more) of 10 per cent, a relative cure (less than three years) of 48 per cent, and a recurrence of 20 per cent (Schmiegelow).

Operation on the Thyroid Body.—An enlarged thyroid body is removed partially or completely, not infrequently, and otherwise surgically treated to afford relief from physical suffering and the mental disquietude which the deformity due to its presence causes. Complete removal is not practiced now except for malignant disease, on account of the unfortunate sequels due to its removal from the human economy. At the present time the following operative procedures are employed in the surgical treatment of goitre: 1, Partial excision; 2, enucleation—resection; 3, enucleation; 4, ligation of the arteries and exothyropexy. Complete excision is practiced in malignant cases only, and with great conservatism.

The Anatomical Points.—The relations of the normal thyroid body to the trachea, œsophagus, recurrent laryngeal nerves, and to the carotid sheath and its contents, should be given careful consideration before beginning the operation. The shape, size, nature, and extent of the growth will modify in a marked degree its normal relations to important structures, and have much to do to establish or disprove the idea of operative action. The inferior thyroid arteries are larger than the superior, but the anastomosis between them all is of the freest kind. The right superior thyroid artery was absent in a case of removal by the author. The *arteria thyroidea ima* supplements often the deficiency due to anomalies of the regular arterial supply of the body. The superior and inferior thyroid veins are of large size, are intimately associated with the arteries of the same name, and empty their blood into the internal jugular and innominate veins respectively. The superior thyroid arteries approach the anterior and upper parts of the organ which they mainly supply. The inferior lie below and posteriorly to the organ, and supply chiefly the corresponding portion of this body. The recurrent laryngeal nerves are closely and indefinitely associated with the inferior arteries, and for this reason extra care is needed to prevent injury of them during ligation of these vessels. The sympathetic nerves and the middle cervical ganglion are in quite intimate relations with the inferior thyroid arteries, and great care should be exercised to avoid injury of them. Portions of glandular tissue of small size and separated from the main structure are found from the arch of the aorta to the hyoid bone. These accessory bodies are of much importance, as they may become the seat of carcinomatous growths. The location of the third lobe and its relation to the isthmus and to contiguous structures should be noted. It is sometimes the seat of disease, and it is important to know that when healthy it often remains behind in complete extirpation of the major lobes. The thyroid body is

covered in front by the sterno-hyoid, the sterno-thyroid, the omo-hyoid, and the anterior border of the sterno-mastoid muscles. It lies between two layers of fascia which unite above and are attached to the cricoid cartilage. A distinction should be made between the fascial covering and the proper capsule of the thyroid body, otherwise great confusion will attend the isolation of the gland from its contiguous tissues. The atrophy of the tissues overlying the enlargement may be mistaken for the capsule of the thyroid body itself.

The Preparation of the Patient.—The strict local aseptic measures are practiced. The bowels should be unloaded freely the day before the operation to obviate the need of defecation for the first few days afterward. *Kocher* usually employs only cocain infiltration anæsthesia in this operation. Chloroform anæsthesia (if general anæsthesia be employed) is preferable in this as in most other operations at this situation. The patient is placed on the back, with the shoulders raised, and the neck extended and well exposed.

The Operation of Partial Excision (Kocher).—Either a transverse or angular incision may be employed. If the tumor be small, movable, limited,

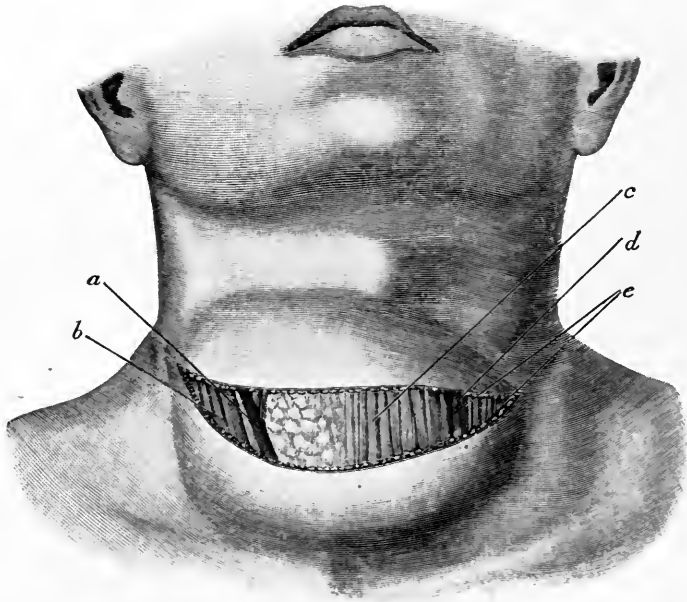


FIG. 882.—The operation of excision of goitre of the right side. Kocher's method. *a.* Branch of communication between anterior and external jugular veins. *b.* Sternocleido-mastoid muscle. *c.* Sterno-thyroid muscle. *d.* Anterior jugular vein. *e.* Sterno-hyoid muscle.

and of simple structure, and cosmetic gain be important, make a liberal transverse incision with a slightly upward convexity along the line of cleavage of the skin, across the most prominent part of the tumor, through the integument and platysma, between the outer borders of the sterno-mastoid muscles (Fig. 882), catching the superficial vessels and dividing them between two ligatures; divide the fascia and expose the spread-out fibers of

the sterno-laryngeal and sterno-mastoid muscles; separate the former muscles in the median line and divide the subjacent fascia upward and downward upon the finger; push the muscles toward the larynx the requisite distance, incising the needed extent when required; divide at this time the external capsule of the tumor so as to permit ready separation of the goitre with a blunt instrument.

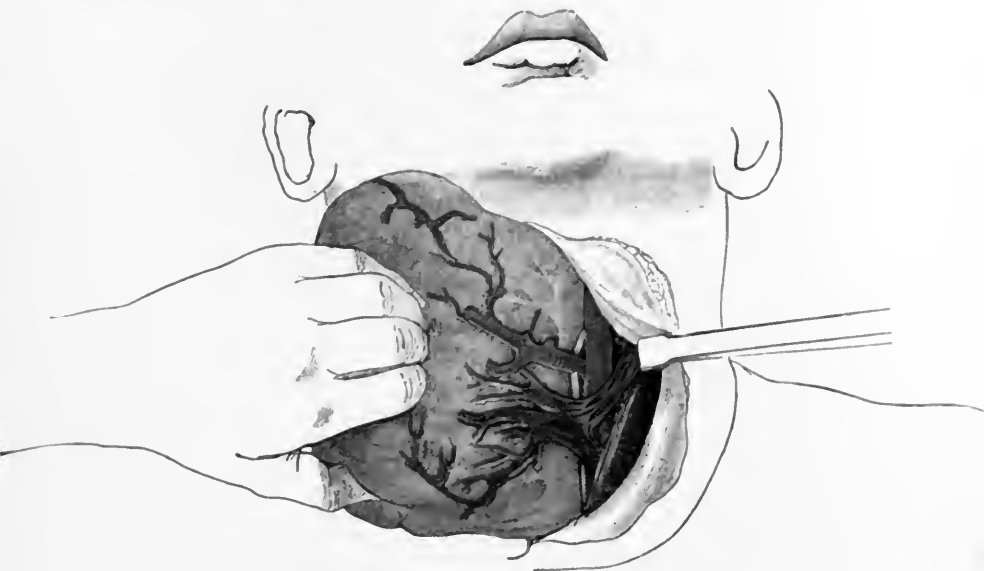

FIG. 883.—The dislocation of the goitre.

The Dislocation of the Goitre.—Draw aside the muscles with retractors; introduce the finger underneath the incised capsule and the muscles and carry it around the tumor, hooking forward the bands stretching between the adjacent tissues and the tumor; ligature and divide the veins associated with the bands, which

former are often quite large, also divide the bands at the same time; drag forward the goitre with the fingers (Fig. 883), thus affording relief from any dyspnœa; ligature the main vessels in regular order, beginning with the *superior thyroid*. Separate with a blunt director the capsule internally and externally from the upper cornu, forming a pedicle of the superior thyroid artery and vein (Fig. 884), which carefully divide between two ligatures.

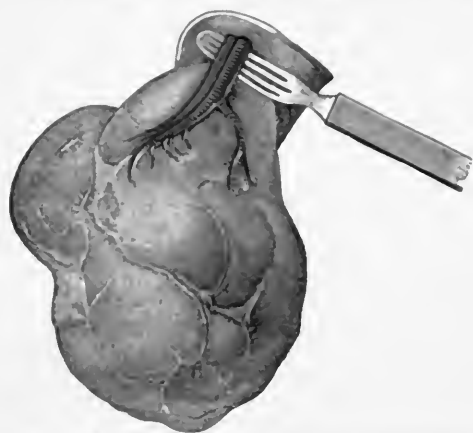


FIG. 884.—The ligaturing of superior thyroid vessels.

The Inferior Thyroid.—Pull forcibly the tumor to the opposite side, retracting the muscles away from the growth at the same time, thereby exposing the artery to touch as it emerges obliquely (Fig. 885) or transversely from behind the carotid, passing inward and entering the thyroid at the point of its attachment to the trachea; ligature the vessels with care, avoiding the recurrent laryngeal nerve ascending behind it; divide the vessels between the two ligatures and examine the lower pole of the tumor at its median surface for the *arteria thyroidea ima* and the attending veins. Push back the outer capsule of the goitre (Fig. 886); locate and isolate with the fingers at the anterior and inner aspects of the lobe the vessels just named and divide them between two ligatures. *Locate, isolate, and divide the isthmus, and the processus pyramidalis* when present. Free the latter, ligature and divide its vessels as in the preceding

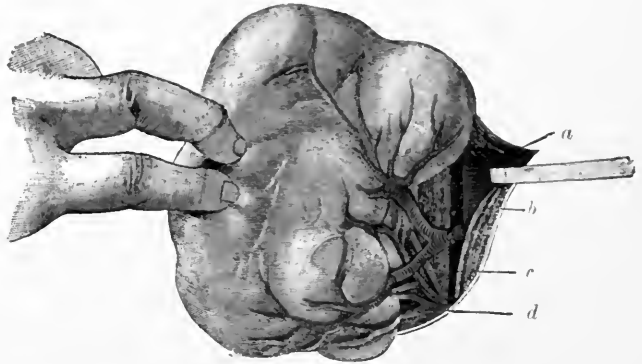


FIG. 885.—The ligaturing of the inferior thyroid vessels. *a.* The common carotid artery. *b.* The sterno-mastoid muscle. *c.* The recurrent laryngeal veins. *d.* The inferior thyroid vein.

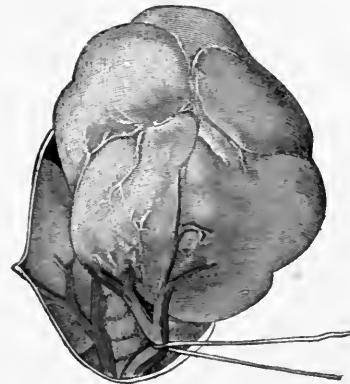


FIG. 886.—The ligaturing of the *arteria thyroidea ima* vessels.

technic; isolate the former by first separating and dividing the communicating veins at the upper and lower borders of the isthmus (in front when present) between two ligatures; separate the isthmus from the trachea, apply special forceps to it firmly, leaving uncrushed only the included vessels and the connective tissue, which are then firmly and securely ligatured. Raise upward the goitre, exposing its attachment to the trachea and cricoid cartilage; catch and tie all bleeding points and those that attend the severing, and leaving behind (if healthy) of the portion of gland (attached, as above stated) for the protection of the recurrent laryngeal nerve.

The wound is then washed out with a warm sterilized salt solution, surrounding parts and the hands purified, ligature sutures tied *after* putting on clean sterilized cotton gloves. Divided muscles are properly sutured, wound closed with continuous section, and a small drainage tube inserted and usually permitted to remain for twenty-four hours (Koehler).

The Remarks.—The divided veins should be retracted with the superficial tissues to avoid dividing them a second time.

The Angular Incision.—Kocher uses much less than formerly the angular incision, reserving it for goitres that extend far upward and are immov-

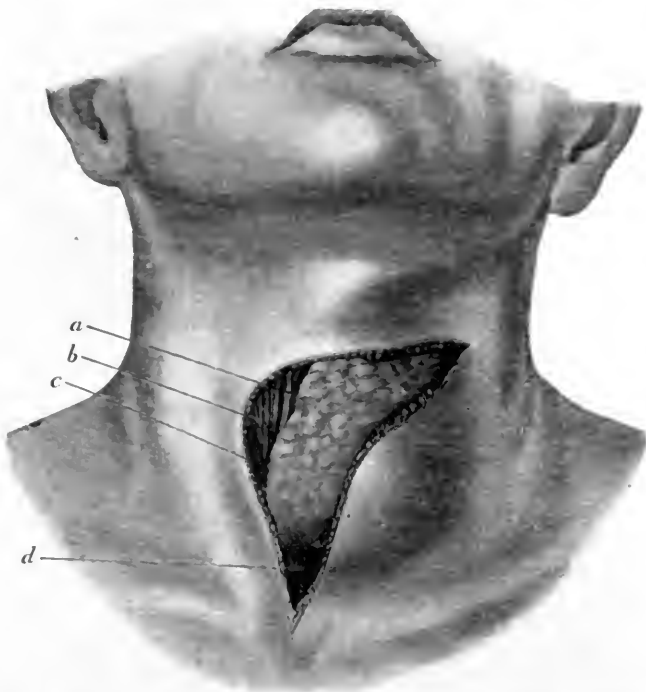


FIG. 887.—The operation of excision of goitre of left side by angular incision, Kocher's method. *a.* Anterior jugular vein. *b.* Sterno-hyoid muscle. *c.* Communicating branch between anterior and external jugular veins. *d.* Inferior thyroid veins.

able, as is frequently the case "in very large diffused colloid tumors and in inflamed and malignant goitres." *Commence the angular incision* at the level of the thyroid cartilage over the prominence of the sterno-mastoid muscle, and extend it transversely in the direction of the skin crease to the median line of the neck, thence vertically downward even to the suprasternal notch, if the size of the tumor demands (Fig. 887), cutting through the skin, fascia, and platysma, dividing the vessels between two ligatures as they appear, expose the fibers of the sterno-mastoid at the outer part of the incision; free the border of the muscle and draw it aside with hooks; incise and draw upward the fascia that covers the sterno-hyoid and sterno-thyroid muscles at the middle portion of the horizontal incision; divide in the median line the fascia that connects the sterno-laryngeal muscles of the respective sides, ligaturing the vein that lies transversely above the suprasternal notch; free the inner edges of these muscles, introduce the finger under and partially divide them at the upper ends; ligature divided vessels and draw aside with hooks the borders of these muscles, thus

exposing the outer capsule of the goitre. The remaining steps of the operation are the same as those of the transverse incision, to which the reader is referred.

The Precautions.—The patient's neck should be flexed from time to time, in order that small veins emptied by extension may fill again and escape untimely division. If the proper capsule of the growth be not entered at first, the aimless efforts to isolate it will cause great embarrassment and lead to harmful delay. The application of the ligature to the thyroid vessels at a distance from the growth, or the use of temporary ligatures, should be practiced when proper isolation of the recurrent laryngeal nerve is not assured. During the separation of the goitre from the trachea the recurrent laryngeal nerve may be injured "in spite of every care," especially where it passes beneath the lower border of the larynx. To prevent this accident Kocher advises that a posterior portion of the capsule of the growth be cut away and left behind at that situation. In instances of encap-

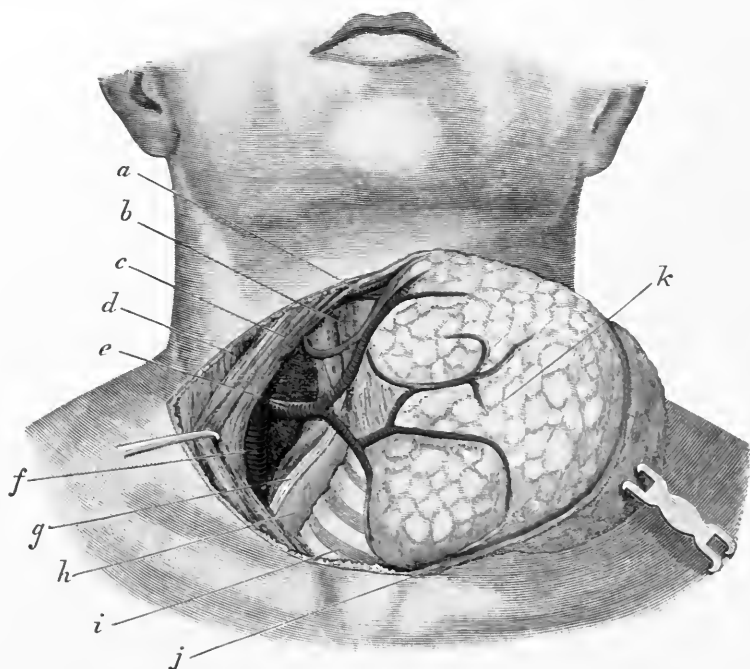


FIG. 888.—The operation of excision of goitre of right side through transverse incision (Fig. 886), Kocher's method. *a.* Superior thyroid artery and vein. *b.* Posterior border of thyroid cartilage. *c.* Sterno-hyoid and sterno-thyroid muscles. *d.* Sternocleidomastoid muscle. *e.* Inferior thyroid artery. *f.* Right common carotid artery. *g.* Right recurrent laryngeal nerve. *h.* Oesophagus. *i.* Trachea. *j.* Inferior thyroid vein. *k.* Right half of goitre turned out toward the left side.

sulated thyroid nodules, not separable posteriorly from the internal thyroid capsule, the capsule must be cut through, but not sufficiently near to the trachea to beget a dangerous removal. The possible adhesion of large growths to the jugular vein should not be overlooked. Undue compression

upon or a kinking of the pressure-softened trachea by rough handling may cause alarming and perhaps fatal dyspnoea. Since the hæmorrhage and the peculiar fever that often follow operation are increased in direct proportion to the amount of laceration of the thyroid body attending the removal,

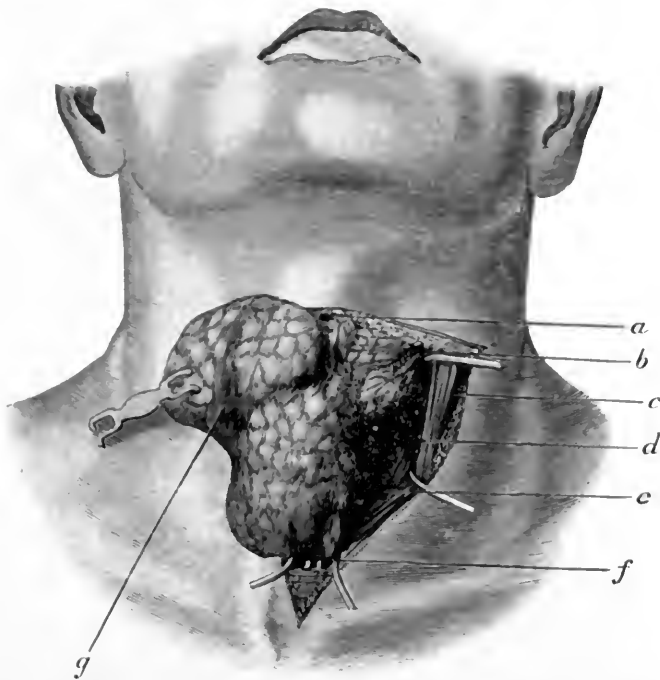


FIG. 889.—The operation of excision of left-sided goitre, angular incision, Kocher's method. *a*, Superior thyroid vein. *b*, Superior thyroid vessels. *c*, Sterno-mastoid muscle. *d*, Sterno-hyoid muscle. *e*, Inferior thyroid artery. *f*, Inferior thyroid vessels. *g*, Goitre dislocated to the right over trachea. The inferior and superior thyroid arteries and veins are ligatured.

needless injury of the structure should be carefully avoided. Alarming symptoms or sudden death may attend rough handling or squeezing of a goitre. Vertical incision for removal of goitre should rarely be made.

The Comments.—A pair of blunt-pointed scissors curved on the flat are efficient instruments for enucleation purposes. A bronchocele may not only surround the trachea, but so insinuate itself with other important structures as to make the removal impossible, or the attempt unjustifiable. Kocher advises the employment of local anæsthesia in all cases attended with marked dyspnoea. General anæsthesia causes engorgement of the vessels, increases the hæmorrhage, and incites secondary bleeding by consequent vomiting. Kocher advises the use of a one-per-cent solution of cocain in all suitable cases, and regards the dangers as being greatly lessened by local anæsthesia. But little pain is caused, and the consciousness of the patient will permit of his co-operation, and of the recognition of involvement of the recurrent laryngeal nerve by noting the character of the voice.

Blind and hurried clamping of bleeding points should not be practiced in this operation.

The Removal of Intra-Thoracic Goitre.—This form of goitre may be entirely overlooked. For apparent reasons a goitre at this situation is replete with disastrous probabilities. Therefore they should receive early operative attention. Their removal is especially difficult, and established plans of procedure can hardly be formulated. *The incision* should be made low down, the angular being usually the better one.

The upper pole of the growth should be thoroughly freed, the vessels being secured by two ligatures each and divided, and the isthmus severed if practicable. The vessels related to the surface of the growth should be ligatured and divided, and the sternal head of the sterno-mastoid, and the sterno-laryngeal muscles of the affected side should be cut across. When the tumor is raised upward all vessels as they appear that are connected with it should be at once tied and cut to prevent dangerous hæmorrhage. In the instances of enormous goitre that cannot be delivered through the sterno-cervical aperture without incision or tapping—as in the cystic form, and opening and breaking up as in the colloid variety—additional dangers are encountered, principally at first from severe hæmorrhage. It is apparent in such cases that delivery must be rapid and the bleeding promptly arrested to avoid the loss of a patient. The inferior thyroid vessels should be controlled as soon as exposed by advancing delivery. If rupture happen, prompt control by digital pressure is the best, until the vessel can be clamped. Careful after-thought to obviate sepsis should be given. Strong-pronged forceps and suitably shaped spoons for the purposes of blunt dissection and lifting are requisite.

Enucleation—Resection (Kocher). — Enucleation-resection is advised by Kocher as being superior to enucleation, because of the severe hæmorrhage that often attends enucleation, and the resulting need of packing the wound; also the consequent danger of sepsis, the delay in healing that follows packing, and the less certainty of permanent cure in cases of multiple growth and those of questionable nature, than when excision is practiced. *Wölfler* concurs in these reasons.

Expose the goitre through the transverse or angular incision, as seems best; dislodge the growth as before described (page 712), omitting ligature of the vessels; ligature and divide the isthmus as in the preceding instance (page 713); expose the inner border of the nodule to be enucleated through the cut following division of the isthmus; separate the nodule from the surrounding gland tissue with a blunt dissector, so as to allow the introduction of the pressure forceps, and their use in an upward and downward direction, followed by the application of a ligature to the compressed tissue by means of an aneurism needle; divide the overlying gland tissue along



FIG. 890. — Kocher's grooved director for operations on goitre.

the line indicated by the needles (Fig. 891) between two ligatures; separate the nodule at the upper and lower parts from the inner capsule with the finger; free a fair extent of the posterior surface in the same manner; divide the posterior part of the inner capsule vertically at the posterior surface with scissors, so that the cut opens into the line of section made just before at the anterior surface (Fig. 891, *k*); remove the nodule and the part of the gland lying in front of it, and close the wound.

The Comments.—Less bleeding follows this plan than in enucleation and resection, and the piece of gland tissue remaining posteriorly maintains the needed function. The recurrent nerve is not exposed to injury.

The Precautions.—In cutting away the thyroid structure, do not approach sufficiently near to the trachea to invite danger to it or to the laryngeal nerve.

Enucleation (Socin).—Expose the surface of the goitre through a median incision, or one made over the anterior border of the sterno-mastoid, according to the prominence of the growth (Socin). Separate the sterno-laryngeal muscles and draw their borders apart; draw aside the omo-hyoid if practicable, if not, divide it; expose the surface of the tumor by division of the overlying tissue at the situation of the nodule. It is recognized by its bluish white covering, and enucleated through the incision made down upon it, deeply or superficially, as the case may be, arresting hæmorrhage as it occurs.

Kocher's Incision.—Expose the capsule as noted on page 711 *et seq.*; incise the gland tissue at prominent points until the nodules appear, arresting bleeding with forcipressure; shell out the nodule with a suitable instrument by blunt dissection, reducing the size by incision if advisable; arrest bleeding with forceps, the need being greater the deeper the blunt dissection. If enucleation be not feasible, supplement by excision or enucleation-resection.

The Comments.—Enucleation is suited to instances of crippling of the gland by previous operations on the opposite side, when a limited number (two or three) of isolated nodules are present in otherwise healthy gland structure, when a single nodule causing extensive pressure-atrophy of the gland substance is present, and the latter is noted only at the posterior aspect of the tumor, and when as the result of inflammation or hæmorrhage the goitre is adherent to the external capsule (Kocher).

The Comments.—The recurrent laryngeal nerve is not exposed to danger in this operation; the healthy structure of the organ is preserved, and deformity is prevented. Attempted cure by injection complicates enucleation. In some instances hæmorrhage is quite profuse. Temporary or permanent ligature of the arteries may be practiced. However, the indication is commonly well met by elastic constriction around the neck of the affected part of the gland (Bose). This operation is adapted to the cure of cysts and solid tumors of established size, but not to advancing goitre, as then recurrence is quite certain. A free incision may not be required for the removal of each independent cyst, as a contiguous cyst may be removed through the thin-walled compartment of another.

Enucleation is regarded by many operators with great favor. Nearly 2,700 cases are reported in which neither hæmorrhage, sepsis, nor cachexia caused death. Operative involvement of the recurrent laryngeal nerves and of other important contiguous structures are less frequent than in the more extended operations. *Shepard* strongly favors the method in both solid and cystic tumors. In their removal he adheres closely to the outer limits of each; in the latter he taps the sac, grasps it with forceps, and carefully removes it. In each instance hæmorrhage is arrested by ligatures and gauze packing, the wound sutured above and left open below for removal of the gauze.

Resection of Goitre (*Thyroidectomy*) (Kocher).—Cases in which the nodules are small and prominent and apparently isolated and bleeding surfaces can be controlled after division are suitable for this measure. Diffuse colloid changes difficult to raise may be treated by this method. However, it

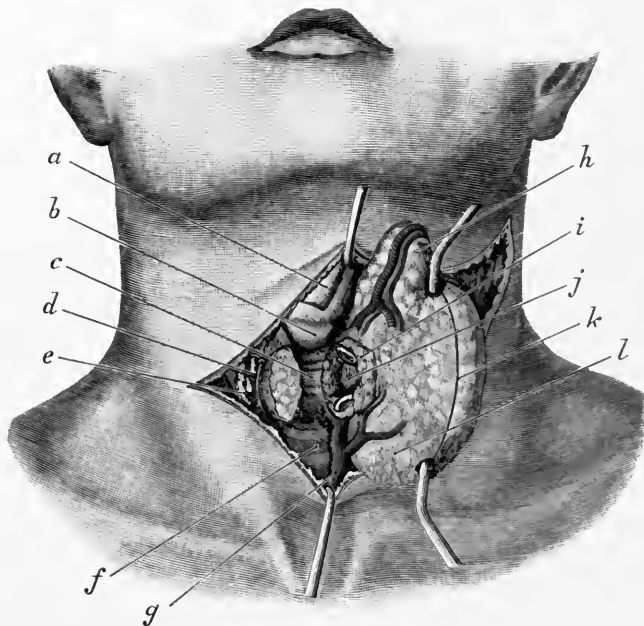


FIG. 891.—The operation of enucleation-resection of a hypertrophied nodule from the left lobe, Kocher's method. *a.* Angle of thyroid cartilage. *b.* Cricoid cartilage. *c.* Piece of posterior portion of capsule of goitre. *d.* Ligatured isthmus. *e.* Healthy portion of thyroid. *f.* Trachea. *g.* Inferior thyroid vein. *h.* Upper horn of thyroid and superior thyroid vessels. *i.* Cut surface of isthmus. *j.* Surface of nodule. *k.* Line of division of capsule of goitre at posterior surface. (This line is located too far forward.) *l.* Lower horn of thyroid. The left lobe is dislocated through the incision, isthmus ligatured, cut across, and the cut surfaces drawn apart so as to expose nodule.

may be better to practice unilateral excision, and should difficulty of healing be apprehended from persistence of the morbid growth primary ligation of the vessels should be practiced. Resection of the growth is sometimes done for relief from the severe pressure symptoms incident to colloid degeneration.

tion of both lobes, or of the malignant complications, as well as for their cure. A *long transverse incision* is made with an upward extension at both ends, followed by a free transverse division of the muscles, when necessary, with ligature of the main vessels of one side and a vessel above or below on the other side. When practicable forward, successive luxation of the respective halves of the growth is done, and resection practiced under elastic tension, supplemented with numerous artery forceps. Angiotribes and other forms of tissue crushers can be well employed in these cases. In this way only can partial removal of both lobes be practiced without extensive hæmorrhage when cutting through the thyroid tissue. The overlying structures involved in malignant growths should also be dissected away.

The Remarks.—At the best, resection of a goitre is a difficult and often a dangerous measure. In this class of cases difficulty of breathing is frequently present. And in these, as in others similarly afflicted, ether is contraindicated. Slight morphin narcosis and cocain anæsthesia should be employed instead. In so-called complete extirpation a small portion of gland is left, and often a pyramidal process (third lobe) remains. Ligature and division of the isthmus has been advised for the relief of pressure dyspnœa in inoperable cases. *Wölfler* practiced “operative dislocation” for the same purpose, the goitre being raised from its bed without cutting the arteries, and transplanted to a more favorable situation. In malignant disease the fatal outcome is so pronounced as to almost forbid the practice. Thirty-three per cent die from the operation, and 60 per cent die within six and 84 per cent within eight months after operation.

Recurrent Goitre.—Recurrent goitre happens in about 18 per cent of the cases, the majority of which follow enucleation. *Kocher* advises the following general plan of operative treatment: Expose, free, and isolate the tumor in the usual manner. If the upper pole is healthy, crush the gland the width of the forceps so as to leave the healthy part still supplied with its vessels; ligature, divide, and remove through the part crushed the diseased portion; repeat the act with the remainder of the gland. *If the upper pole be entirely diseased* and dislocation cannot be done without ligature, then first tie the superior thyroid vessels, dislocate the tumors, ligature the vessels at the lower pole, raise the tumor with the trachea, leaving gland tissues attached if practicable. Control deep vessels near the trachea, incise goitre tissue vertically near the isthmus, thus forming a posterior capsule from which the diseased material is scraped. By continued dissection a flat mass of goitre tissue is separated posteriorly sufficient to maintain the thyroid functions.

The scars of previous operations complicate the removal, which is patiently conducted with the idea of removing the diseased and leaving behind enough well-nourished normal tissue to meet the functions of the gland.

The Treatment by Ligature of the Thyroid Arteries.—The ligature of the superior thyroid is not difficult or especially dangerous (page 197). Ligature of the inferior thyroid is more difficult, and incurs special dangers from the involvement of important structures (page 177). *Kocher* reaches the vessel through an incision made along the inner border of the sterno-mastoid,

and ties the artery in front of the scalenus anticus. *Rydygier* made a transverse incision three inches in length, one inch above the clavicle, so that more than half the length lies behind the sterno-mastoid muscle, through which he exposes the thyroid axis, and secures and ligatures the artery.

The Comments.—The rapidly developing parenchymatous, vascular goitres, especially in the young and those unfitted for enucleation, are proper cases for treatment by ligature. The gradual atrophy following simultaneous ligature of both of the arteries does not appear to expose the patient to the common sequels of complete removal of the thyroid body. The vascular goitre of Graves's disease is suited to this procedure. *Trendelenburg* ties the arteries of one side, a month later those of the other. *Wölfler* and *Porta* have practiced the same with favorable results. *Kocher* advises that the artery supplying the portion of the thyroid involved should be tied first, and be followed by ligature in order of the vessels supplying succeeding enlargements, provided that a beneficial effect be noted. The different plans of action advised, and the uncertainty of the outcome from the ligature, together with the difficulty attending it in many instances when compared with the established technique and success of the radical methods, leave but a limited field of utility in this disease for ligature.

Exothyropexy (*Jaboulay*).—Exothyropexy consists in freeing the gland from its capsular environment, raising and fixing it superficially in the wound, and leaving it to granulate and adhere under antiseptic dressing. The influence of exposure to air, and of resulting venous sinus thrombosis, contribute to the shrinkage. *Poncet*, *Wölfler*, and others have secured in this manner a limited shrinkage of the gland. The presence of thrombosis and the laceration attendant on the displacement are elements of danger from systemic infection. In cases of threatened suffocation high or low tracheotomy, according to the size and situation of the goitre, with the introduction of a tube suited to the peculiar requirements of the case (Fig. 867. *o* and *m*), is a wise preliminary step and often a proper final measure. It seems especially fitted for the relief of dyspnoea of parenchymatous and other inoperable goitres. Larger experience is required to establish the practicability of the measure in all respects.

Excision of the Sympathetic.—*Jaboulay* and *Jonnesco* have advised and practiced this measure for the relief of patients with exophthalmic goitre (see Vol. II, page 1518).

The injection of goitre for cure is now practiced much less than formerly. Injection should not be employed at all in cases for which operation is contemplated, on account of the periglandular adhesions that it causes, which beget special difficulties in the event of subsequent operation. The cystic and recent follicular varieties are those to which the treatment is best suited. The excellent results now obtained by operation limit the use of injections to the narrow and illogical field of unsurgical expediency. The tincture of iodine (five to ten drops) and a like amount of carbolic-acid solution (five per cent) are regarded as the best medicinal agents for the purpose. Strict aseptic precautions throughout should be taken.

The needle should be thrust slowly into the gland, carefully avoiding the superficial veins; the syringe is then removed to see if blood will escape through the needle, thus avoiding the introduction of the fluid into a vein. Eight or ten drops of the fluid are then slowly injected, watching carefully the effects of the introduction. But one injection is made at a sitting, and an interval of three or four days should have elapsed before it is repeated. Different aspects of the tumor are subjected to treatment. *Senn* speaks in high terms of the carbolic-acid treatment established by *Gunn*. *Schwartz* regards iodine as the most efficacious and least dangerous for ordinary cystic goitre. *Heymann* reports 16 deaths from injection, one of which happened suddenly after the use of iodine, which had been injected twice per week for four months.

The Dangers of the Operations.—Hæmorrhage is a constant danger during, and it may happen after, the operation. If care be exercised to divide nothing incautiously and to divide the vessels between two ligatures, but little annoyance is likely to happen from this cause during operation, unless the growth be a soft and highly vascular one, when a startling and profuse bleeding will be provoked by opening the capsule. The difficulty of finding and securing the bleeding points in such cases is often trying, and may seriously test the composure of the surgeon. If careful scrutiny be exercised to detect bleeding points before the wound is closed, and the ligatures have been securely placed during operation, no rational fear need be felt regarding hæmorrhage thereafter. The danger of the entrance of air into the veins is especially prominent here because of their great number, large size, and intimate relation with the influence of respiratory aspiration. These peculiarities contribute to danger from the use of injections, and to the presence of thrombi. Gentle manipulations of the tumor are essential to security of the patient.

The Recurrent Laryngeal Nerve.—If this nerve be cut, bruised, or included in a ligature during operation, serious laryngeal manifestations may occur at the time or may happen afterward. Undue dragging on the nerve, its involvement in cicatricial formation, or the presence of neuritis may cause aphonia after operation. Fortunately, however, these manifestations are not always permanent. Large, adherent, illy-defined tumors are dangerous for this reason, as are those surrounding closely the trachea and œsophagus. A subsequent operation may be necessary to relieve these symptoms. The lymphatic duct, especially the right, may be bruised or torn during the removal of large or low goitres. The distinctive appearance of the lymph will suggest the nature of the structure involved.

Cellulitis.—Cellulitis of a septic nature may follow operation even for small growths, and lead to the formation of pus in the mediastinum. A scrupulous aseptic technique will obviate this danger.

Cachexia Thyreopriva.—Cachexia thyreopriva manifests its presence by a species of tetany and myxœdema. The continued and frequent occurrence of these sequels in complete extirpation led to its abandonment except in malignant disease. The removal of a greater or lesser fractional part of the gland may be followed by these manifestations in a minor degree.

However, the best evidence of their infrequency is witnessed by the fact that in 1,600 cases of operation by Kocher's method but 4 suffered from this sequel.

The dressing of the wound requires no especial technique. The cavity of the wound is mopped with an aseptic solution or wiped dry; loose clots are removed, and all bleeding points are arrested. The margins of the wound are carefully united with silkworm-gut sutures, and drainage is employed at the dependent parts. The walls of the wound are pressed together and dead spaces eliminated by catgut sutures, and sponge pressure carefully adjusted and equalized by a thick covering of absorbent cotton held in place with bandages. If the bandages are applied too tightly much discomfort will follow. A mild pharyngitis, attended with profuse expectoration of mucus, often occurs, as in other operations on the neck, at the sides, and at the median line.

The after-treatment is of a routine character. The head is kept flexed as much as comfort will permit, and the dressings are changed to conform with needed cleanliness. The drainage is removed after a day or two. The food should be bland and nutrient, and fresh air freely provided.

The Results.—The 40-per-cent death rate of forty-five years ago was reduced to 21 before 1871, and to 11 per cent before 1877. In 1895 Kocher reported 1,000 cases of benign goitre operated on by himself, with an operation death rate of 1 per cent. To this list can now be added 700 others, of which Kocher performed 550 and his assistants the remainder. The last 600 of this series includes 18 malignant and 15 exophthalmic cases, and still the average death rate is but 1 per cent. Kocher still later reports 1,100 operations with three deaths. *Krönlein* and *Sulzer* report 200 and 144 cases respectively without a death. A 2-per-cent rate of mortality is now a fair estimate of the results of experienced hands in benign cases. The outlook in malignant cases is gloomy. Kocher's operative death rate is 33.33 per cent. The average duration of life is about six months (Orcel); 84 per cent die in six and 60 per cent in eight weeks (Rotter). In exophthalmic goitre the rate of mortality from operation is well shown by the cases collected by Starr. In 190 cases 74 were cured, 45 improved, 3 unimproved, and 23 died from the operation. The remaining 45 not stated. The mortality rate varies from 7 (Kinnicut) to 12 or 15 per cent, depending on the judgment and operative skill of the surgeon.

Wounds of the Neck.—Incised, stab, and gunshot wounds of the neck are of not infrequent occurrence. Incised wounds happen oftenest because of suicidal attempts. The location and extent of the incision modify its severity. If at the front and above the hyoid bone, the base of the tongue may be involved, if through the thyro-hyoid space, the epiglottis and pharynx (Fig. 870), if lower, the larynx and trachea respectively may be involved. In attempted suicide the wounds at the median line are often shallow, the force of the attempt being outwardly expended on the lower jaw. Incision through the thyro-hyoid space occurs most frequently. If the wound be superficial, but little harm may arise; if deep, free division of the air passage and per-

haps of important vessels on either side is followed more or less promptly by death from hæmorrhage or asphyxia, unless relieved. Deep wounds, involving the spaces immediately above and below the hyoid bone, incite suffocation from the closure of the larynx by the down-falling of the base of the divided tongue and of the divided epiglottis respectively. Inflowing blood is an important element of immediate and remote danger in all instances of air-passage involvement, causing infection in the first and septic inflammation of the lungs and bronchi in the latter instance. Œdema of the glottis and emphysema of the connective tissue are common and important complications of these wounds, the former happening most frequently with upper and the latter with lower involvements of the air passages. The importance of gunshot and stab wounds relates to the direction and extent of injury. The important vessels and nerves, the œsophagus, the trachea, and even the pleural cavity and lung itself, may be involved in these injuries.

Fracture of the larynx and hyoid bone may result from direct blows and from manual choking. These injuries may so deform and cripple the parts as to threaten suffocation in the former, and cause much pain and annoyance in the latter instance.

The Treatment.—The treatment is regulated by the urgency of the symptoms. Severe hæmorrhage and asphyxia demand instant arrest of bleeding, the removal of obstruction, and the performance of tracheotomy, if then required. When time will permit, thorough asepsis should be practiced. In wounds involving the air passages the arrest of bleeding is of double significance, preventing the entrance of blood into the respiratory passages as well as the loss to the patient. Temporary tracheotomy is usually required in wounds of the trachea, the larynx, and the pharynx, especially the latter two, in order that the danger incurred by the sudden advent of œdema of the glottis may be forestalled. Wounds of the trachea may be closed with catgut at once and tracheotomy omitted. In wounds of other kinds the tube may be inserted at the seat of injury or through a high tracheotomy, if the location of the wound permits. In wounds involving the pharynx, tracheotomy is often advisable as the best means of avoiding the septic exposures arising from discharges provoked by food contact, as well as the dangers of œdema of the glottis. Tracheotomy permits of careful cleansing and closure of the original wound in many instances. In wounds of the œsophagus, infiltration of the deep tissues of the neck from swallowing food and fluid may happen before the existence of an injury is suspected. In stab and gunshot wounds of the trachea extensive and dangerous emphysema may arise, requiring tracheotomy and free incision for relief. A gunshot wound of the neck, passing contiguous to but not involving the trachea, and entering the lung, may cause extensive emphysema and otherwise simulate in all important respects a wound of the trachea. Œsophageal wounds should be exposed at once, cleansed, and, if clean cut, sutured. Ragged wounds, howsoever inflicted, should be treated by drainage and packing. In no instance is it wise to completely close a wound in case of œsophageal involvement (page 596), because the uncertainty of union of the tube renders primary closure unsafe. Wounds of the tongue and epiglottis are sewed care-

fully at once, the divided borders of the being closely apposed by sewing before the more superficial structures are united. In all suitable instances wounds of the neck should be carefully closed.

The divided borders of the muscles and gaping structures should be united with sutures to secure prompt and effective union, thus eliminating dead spaces. After suture of the soft parts the neck is flexed, and sufficient pressure is applied to cause still further the approximation and retention essential to the prevention of dead spaces and to good union. Drainage should be employed only in the instance of suspected infection. Fixed position of the neck, cleanliness, alimentation by the bowel for a day or so in case of pharyngeal wound, followed by feeding by the stomach tube, are important measures of treatment. If the head be lowered for the first two or three days, an increase of blood in the brain and the flow of the discharges away from the wound will be favored. The tracheal, the œsophageal, and laryngeal sequels should be treated as necessity demands.

Abscess and Phlegmon of the Neck.—Abscess and phlegmon of the neck located in the sublingual (Ludwig's angina), submaxillary, and parotid regions, also at the anterior and lateral cervical regions from glandular involvement, not infrequently occur. In each instance early relief should be sought by free incision.

The awaiting the presence of fluctuation while encouraging its appearance by poultices, etc., is often fraught with grave dangers

from purulent and serous infection, infiltration of the deep tissues of the neck, and œdema glottidis, especially in those cases located below the inferior maxilla. Extensive sloughing of the connective tissue of the neck,

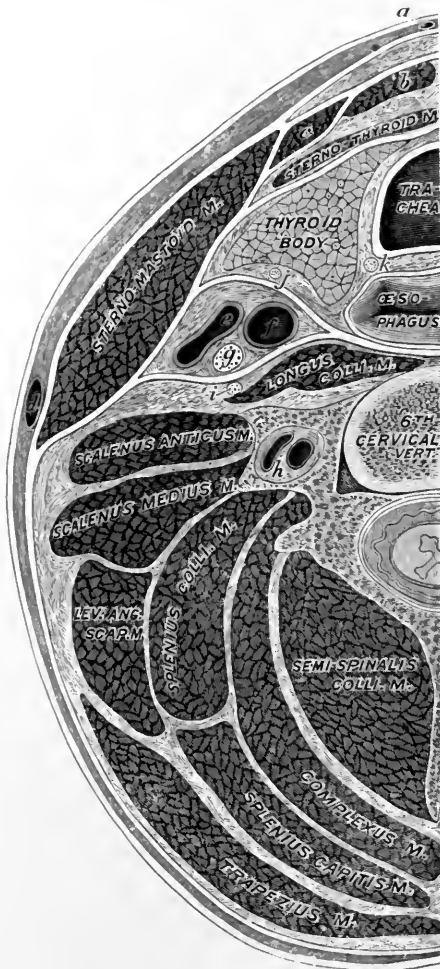


FIG. 892. — Arrangement of the deep cervical fascia, muscles, vessels, nerves, etc., as shown by transverse section on level with sixth cervical vertebra. *a*. Anterior jugular vein. *b*. Sternohyoid muscle. *c*. Omo-hyoid muscle. *d*. External jugular vein. *e*. Internal jugular vein. *f*. Common carotid artery. *g*. Pneumogastric nerve. *h*. Vertebral vessels. *i*. Sympathetic nerve. *j*. Descendens hypoglossi nerve. *k*. Recurrent laryngeal nerve.

attended with foetid gas, have been seen by the writer. The relief of the tension, prevention of sloughing, and extensive infiltration of morbid products, even into the thorax, requires early and decided action. Also the liability to sudden and fatal œdema of the glottis demands the exercise of the forethought necessary to meet and relieve the complication at once by bronchotomy (page 681).

Retropharyngeal Abscess.—Retropharyngeal abscess is not an infrequent affection, especially in children. Phlegmonous inflammation of the pharyngeal tissues, the softening of diseased lymphatic glands, and caries of the bodies of cervical vertebræ, are frequent causes of this variety of abscess.

The Anatomical Points.—The relations of the various extensions of the deep cervical fascia to the œsophagus, pharynx, and the other deep structures of the neck (Fig. 892), together with the fact that the lower limit of the pharynx corresponds to the intervertebral disk of the fifth and sixth cervical vertebræ, and the liability of the extension by burrowing of post-pharyngeal suppuration into the thorax, are individually and collectively important items (Gerster). Retropharyngeal abscess may be opened internally through the pharynx and externally through the neck at two situations.

The evacuation through the mouth is not advisable, except in the instance of small collections of pus dependent upon transient causes. The chronic discharge of pus into the pharynx is objectionable from nearly every standpoint, and especially when the disease is thus protracted by inefficient drainage and inadequate cleanliness. If it be determined to evacuate the abscess through the pharynx, cleanse the part thoroughly, place the patient on the back in a good light, cocainize the mucous membrane, fasten the jaws apart, seize the tongue and draw it forward. The end of the left index finger is placed against the prominent fluctuating point, and the patient is caused to inspire deeply. A sharp-pointed bistoury, its blade protected, except at the point, with adhesive plaster, is then (Fig. 893) carried along the finger into the abscess, and an opening is made downward or upward, according to the location of the point of greatest prominence, half an inch or so in length (Fig. 893). As the fluid escapes, the finger is withdrawn, and the patient turned over and caused to expire forcibly, so as to clear the throat of the discharge. Sponging with sterilized water, to remove the pus and promote cleanliness, is practiced from time to time until healing takes place. In every instance when extended suppuration is anticipated, the evacuating incision should be made from without, behind, or in front of the sterno-mastoid muscle.

Chiene's Method.—*Chiene* made an incision from the mastoid process downward along the posterior border of the sterno-mastoid muscle the proper distance through the integument and fascia, drew the posterior border of the muscle forward and passed in front of the scalenus anticus,

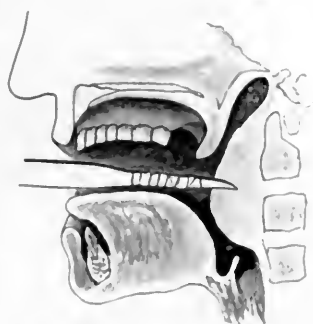

FIG. 893.—Opening a retropharyngeal abscess.

(Fig. 892) behind the deep vessels and the longus colli to the retropharyngeal space, by means of blunt dissection.

This plan of evacuation is a comparatively simple one, as no important structures intervene. The course is direct, the drainage quite dependent, and any resulting disfigurement is at the side rather than in the front of the neck. This plan is to be commended.

Buckhardt's Method.—*Buckhardt* made an incision at the anterior border of the sterno-mastoid muscle, at the level of the larynx, through the skin and platysma, and reached the vessels of the thyroid body, which he pushed aside. The carotid sheath was quickly exposed and drawn outward along with its contents by means of a hook. The prevertebral fascia covering the longus colli (Fig. 892) was quickly opened, and the prevertebral space promptly gained by blunt dissection directed transversely inward across the muscle. The only vessels directly in the course of this dissection were a small subcutaneous vein, which was tied between two ligatures, and the thyroid vessels, which were pushed aside. The route by the latter method is somewhat shorter, and the field of disease is more easily exposed. However, the drainage is less free and the disfigurement more prominent than in the former.

The Remarks.—Tuberculous products, foreign bodies, and diseased bone should be removed carefully, suitable drainage introduced, cleanliness secured, and repair encouraged by the recognized antiseptic means.

The Results.—Little or no danger arises from the operation if conducted antiseptically and with care. The final outcome is dependent on the nature of the disease causing the abscess.

The Removal of Diseased Cervical Lymphatic Glands.—The devious and unforeseen relations that exist between diseased cervical glands and the important superficial and deep structures of the neck, invest their removal with a sense of responsibility that often begets a strong feeling of uncertainty as to the wisdom of the attempt in many instances. Apparently simple cases often become, as the operation progresses, difficult and complex, and sometimes even dangerous of execution. It is wise, therefore, that the patient or the friends be given at the outset a quite definite idea of the uncertainties that too often are a serious part of the procedure. At all events, they ought not to be permitted to regard the operation as trivial. The glands may be more or less firm and independently encapsulated or broken down and adherent to each other. Caseous and inflammatory products may take the place of or mingle with definite gland structure. The superficial and deep series of glands may be affected independently of each other, but usually they are diseased conjointly, although in an irregular and often unexpected manner. An easily removable diseased superficial series may communicate freely with a deep one that is intricately associated with important structures.

The Anatomical Points.—Before attempting the removal in pronounced cases, the course and relation of the superficial and deep nerves and vessels should be reviewed. The superficial branches of the cervical plexus are especially exposed to division. The cervico-facial branch of the facial nerve

and its terminal branches may be injured, causing objectionable paralysis of the lower lip. The relation of the spinal accessory to the upper end of the sterno-mastoid is of great importance. The relation of the superficial and deep glands with the sterno-mastoid muscle, and the latter with the deep glands of the neck, are matters of great significance. Any good text-book on anatomy will illustrate forcibly these important features. The presence and location of the lymphatic ducts should not escape attention.

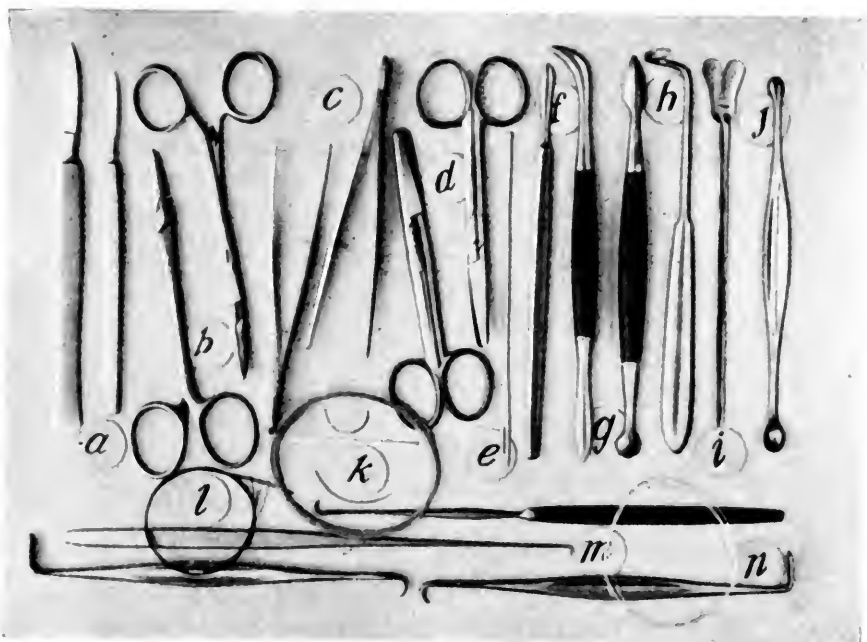


FIG. 894.—The instruments employed in removal of diseased cervical lymphatic glands. *a*, Scalpels, large and small. *b*, Forcepressure, curved and straight. *c*, Forceps, dissecting and mouse-tooth. *d*, Scissors, short blunt-pointed straight, and curved on the flat. *e*, Probe. *f*, Blunt dissectors. *g*, Sharper blunt dissector. *h*, Aneurism needle. *i*, Grooved director. *j*, Small scoop. *k*, Needles and catgut. *l*, Horsehair. *m*, Single- and two-tined tenacula. *n*, Small hooked and blunt-pointed retractors. Wipers, ligatures, drainage agents, large retractors, and ample gauze and plaster-of-Paris bandages are needed.

The incisions for the removal vary in accordance with the situation and extent of the glandular involvement, the importance of the contiguous anatomy, and the liability to operative disfigurement. The transversely directed skin fold at the upper part of the neck suggests the site of an incision to obviate deformity in the removal of glands located opposite to the hyoid bone and anterior to the sterno-mastoid muscle. The glands in the lower part of the posterior triangle can be well approached through a similar incision at that situation. At other situations oblique incisions arranged to conform to the anterior or posterior border of the sterno-mastoid are advisable. The S-shaped incision of Hartley (Fig. 895), employed as a whole or in part, as circumstances require, is a commendable one. In all

instances the incision should be made sufficiently free to afford ample room. Safety of execution should not be exchanged for cosmetic result. The patient should be placed upon the back, with the shoulders raised and the head turned to the opposite side. A good light, plenty of time and assistance, and aseptic detail should be at the command of the operator. Chloroform or A. C. E. mixture should be given to avoid congestion of the vessels, unless contraindicated.

The Operation (Treves).—Make a free incision along the selected line through the skin, platysma, and fascia, avoiding the division of the superficial nerves, if possible; expose and free the sterno-mastoid muscle and hold it aside with retractors when in the field of operation; divide the muscular fibers to a limited extent, and then only when necessary; divide the deep fascia and expose the capsules of the enlarged glands; turn out the glands with the handle of the scalpel or a similarly shaped implement, if they be non-adherent; if adherent, attack the aggregation at the point least firmly fixed, keeping close to the capsules throughout the dissection, and removing adherent portions of the same; dissect out, rather than tear out a mass of tissue, as the latter procedure ruptures the connective vessels, the nerves, and also the capsules, smearing the tissues with the disorganized gland structure; relax and examine constricting bands of tissue before division, as they may contain vessels, nerves, etc., and when in doubt regarding the presence of the former divide the tissue between constricting agents; isolate torn vessels, and tie above and below the rent with catgut; search carefully for isolated and deep-seated glands, leaving none behind, unless their removal as a whole begets unwarranted danger, and in such as these divide the capsule and dig away the contents, removing the capsule afterward, if practicable; flush out the wound with an antiseptic solution, removing blood clots and arresting all bleeding points; close the wound with deep and superficial sutures, eradicating all dead spaces; introduce drainage in deep wounds, those with lacerated borders, and in any in which diseased tissue remains behind; apply antiseptic dressings with overlying sponges for compression, bandaging them as firmly in place as the respiratory and circulatory functions of the neck of the patient will permit.

The Precautions.—Avoid rupturing the diseased glands, as consequent infection of contiguous freshened surfaces may follow. In such instances careful cleansing should be practiced at once. Incautious attention and indifference to anatomical details during removal of these glands leads to unnecessary division of the superficial nerves, especially the superficial cervical. This nerve passes across the neck on either side, nearly opposite the thyroid cartilage. The spinal accessory is exposed in operations at the upper part of the posterior triangle, but can be readily recognized, when irritated, by the causing of contractions of the muscles it supplies. The phrenic, pneumogastric, recurrent laryngeal, descendens hypoglossi, the primary cords of the brachial plexus, and the cervical sympathetic nerves are in but little danger except in extensive involvement of the deep series of glands, or during removal of deep-seated growths of a different nature. Under similar circumstances, the apices of the pleural cavities—which

extend above the first rib at either side of the body of the seventh cervical vertebra, and higher in the female than in the male—may be invaded. The right and left lymphatic ducts are also endangered by dissection at these situations. The entrance of air into the veins is a danger to be apprehended here. The prevention and treatment is considered already on page 122. "Keep close to the capsule; make no cut in the dark; be chary of cutting tissues which are only seen when put fully upon the stretch," are wise admonitions of Treves.

The effects of *division of the recurrent laryngeal*, sympathetic, and common motor nerves of the neck are well understood, and need no special mention. The effect of division of one or both phrenic nerves is comparatively so well illustrated by the outcome in cases of crushing attendant on fracture of the cervical vertebræ as to need only the admonition which the latter teach to impress the importance of the maintenance of their structural integrity. Regarding the pneumogastric in this connection one can do no better than to quote the conclusion of *Park*, uttered in 1895, after an able consideration of recorded cases: "Nevertheless, the preponderance of testimony is in favor of the comparative safety of attacking this nerve when involved in disease, and when too much other disturbance is not necessitated by the condition which has caused the operation." *

If *injury of the thoracic duct* be detected in time, and the seat of the wound can be found, repair may be made by means of interrupted sutures, implantation (page 1043), or size and ligature, as required. Usually a knowledge of the injury occurs too late for the purpose, and even when favorably recognized, detection of the breach in the duct may not be possible. Under the circumstances direct pressure with gauze compresses is the suitable and usually successful treatment in both instances. Avoid fatty food.

The Remarks.—The natural intimate association of the lymphatic structures with the veins bespeaks the difficulty of the removal of the former when diseased. The compressed veins become changed in their normal aspects, and therefore are often divided in spite of the greatest caution. When a vein can not be separated from a lymphatic enlargement, it should be sacrificed, except, perhaps, in the instance of the internal jugular, when the gland should be removed piecemeal if need be. Excision (page 215) of a portion of this vein between two ligatures is justifiable when it is torn or traverses a malignant growth. Normal veins of a minor size often resemble the largest ones when compressed by glandular enlargements and malignant growths. The sterno-mastoid muscle should not be divided, if possible to avoid it, as marked deformity may follow imperfect union of the divided ends.

Hartley's Method.—Hartley devised, some time since, the following ingenious plan of approach to diseased glands of the neck. The operative convenience and the curative and cosmetic outcome of the plan are such as to commend its employment. The following description is quoted from *Stimson's* valuable work on operative surgery, and has the additional worth due to Hartley's personal revision.

* Transactions of the American Surgical Association, vol. xiii.

The Operation.—The incision is S-shaped (Fig. 895), and involves only the skin, subcutaneous tissue, and fascia; starting below the chin it passes in a curve downward and backward to the hyoid bone, then up behind the angle of the jaw to near the lobule of the ear, whence it sweeps down along the anterior border of the trapezius, forward over the sterno-mastoid, and downward and backward again to terminate above the middle of the clavicle (*b, c, d*). The flaps thus formed are dissected up, exposing nearly the whole length of the sterno-mastoid, and the latter is cut transversely near its center and the ends reflected, care being taken not to injure the spinal accessory nerve above. The point where the muscle is divided must not be in the line of the cutaneous incision, but under the middle of one of the flaps, preferably the upper (*a*). The great vessels are thus exposed from the mastoid process to the clavicle, and the operator can excise the adherent and diseased glands, and avoid injury to the adjacent important structures.

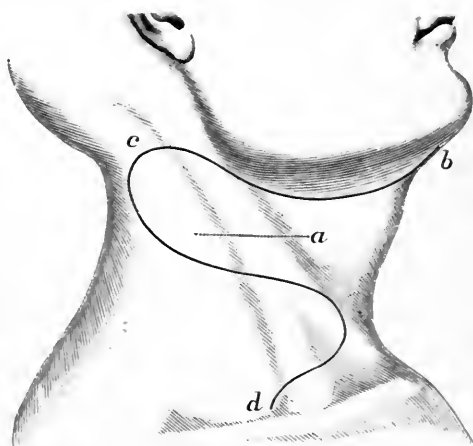


FIG. 895.—The removal of diseased cervical lymphatic glands, Hartley's method. *a*. Point of division of the sterno-mastoid muscle. *b, c, d*. Line of incision.

At the close of the operation the divided ends of the sterno-mastoid are united with catgut, the flaps replaced and loosely sutured in position, and drainage provided for in the most dependent angles.

This large incision is only used when the glands in the superior and inferior carotid and submaxillary triangles are involved simultaneously. For less extensive disease the upper or lower flap may be employed alone; or one may be fashioned with a pedicle in a position the reverse of that shown in the figure. The incision for a single flap should approximately correspond to the circumference of the tumor, which is then exposed in its entirety by division of the sterno-mastoid below the point where it is entered by the spinal accessory nerve. The flap consists of skin, subcutaneous tissue, platysma, and fascia.

*The Johns Hopkins Hospital (Mitchell)** plan of practice may be briefly expressed as follows:

The Operation.—Make a curved incision (Fig. 896) from over the mastoid process, forward along the anterior border of the sterno-mastoid muscle, thence slightly backward to the middle of the clavicle; make a transverse incision along the upper border of the clavicle, forming with the preceding, a T-shaped outline; dissect back the skin, uncovering a quad-

ilateral area, through which all parts of the neck can be easily reached; divide the subcutaneous fascia and the platysma of the angle between the posterior border of the sterno-mastoid muscle and the clavicle, along with a few of the posterior fibres of this muscle, and turn the tissues back, exposing the external jugular vein; ligature, divide, and turn aside this vein, thus exposing the "key to the operation"—the omo-hyoid muscle; seize

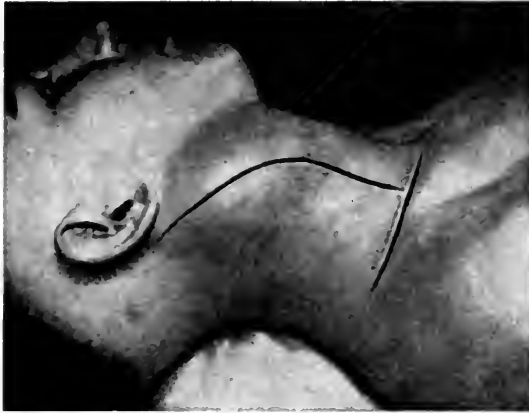

FIG. 896.—Skin incision for complete removal of glands of neck.

and divide the omo-hyoid and (using the upper part as a retractor) pull aside the posterior border of the sterno-mastoid, thus permitting the dissection to be carried up along the internal jugular and posterior border of the sterno-mastoid to the posterior branch of the spinal accessory; remove the diseased glands from the nerve, leaving them connected with those above, and continue the whole dissection from the medi-

an line and below, upward and outward. *In some instances* the degree of involvement of the spinal accessory and the sterno-mastoid and trapezius muscles is such that their rescue by continued dissection in this manner is practically impossible. In such cases the following plan is practiced: use as before the omo-hyoid for a guide and divide the sterno-mastoid low down on a line with it; reflect the ends of the sterno-mastoid upward and downward, thereby exposing a large area and the anterior and posterior chain of glands embracing the muscle and nerve above; rescue now both branches of the nerve, ligaturing and removing the internal jugular if required. In some instances the disease may be so extensive as to require removal of some portions of the sterno-mastoid and trapezius muscles. The ends of the divided muscles should be sutured and their functions favored until repair is completed; when removed, deeper muscles assume the functions. The wounds are closed with subcuticular silver sutures, temporary drainage provided, abundance of gauze applied, and strict immobility enforced by plaster-of-paris bandages supplemented with three box-wood splints embracing the head and shoulders.

The Remarks.—The disease is usually descending, because of the oral sources of the infliction. *Mitchell* recalls the facts that, practically speaking, the lymph glands of the neck may be divided into four groups: "Those in the anterior triangle and those in the posterior, with two connecting chains, one passing in front and the other behind the sterno-mastoid muscle." The chain behind the muscle appears to be the most commonly involved, hence arises much of the difficulty of the operation for removal.

The superior triangle is involved in 70 per cent of the cases, and the disease is more extensive here than elsewhere in the neck when its other regions are implicated. By the preceding method the internal jugular is exposed at its lowest portion at the beginning of the operation, and can be provisionally tied to prevent entrance of air if injured later. The most difficult part of the operation is with the chain of glands connecting those of the anterior and posterior triangles behind the sterno-mastoid muscle at the seat of the spinal accessory nerve, with which the nerve is sometimes perplexingly involved, and great care and patience is often needed to safely rescue it from the diseased investment. Some of the branches of the cervical plexus are necessarily divided, but the descendens noni and the phrenic should always escape, especially the latter. Carefully avoid the thoracic ducts: if cream be given before the operation the injury is more easily detected (Allen and Biggs). Perpendicular scars spread and become more conspicuous. Transverse ones diminish in conspicuousness, therefore the vertical should be short and be placed on living surfaces when possible, and the transverse should follow the folds of the neck. However, cosmetic considerations ought not to supersede curative means.

The After-treatment.—The after-treatment in these operations consists in securing the complete local rest consistent with the proper cleanliness of the wound. Fluids should be given, and movements of the lower jaw interdicted. The drainage should be removed in a day or two, except when diseased products are present. The sutures are taken out in seven or eight days; the buried ones, of course, remain.

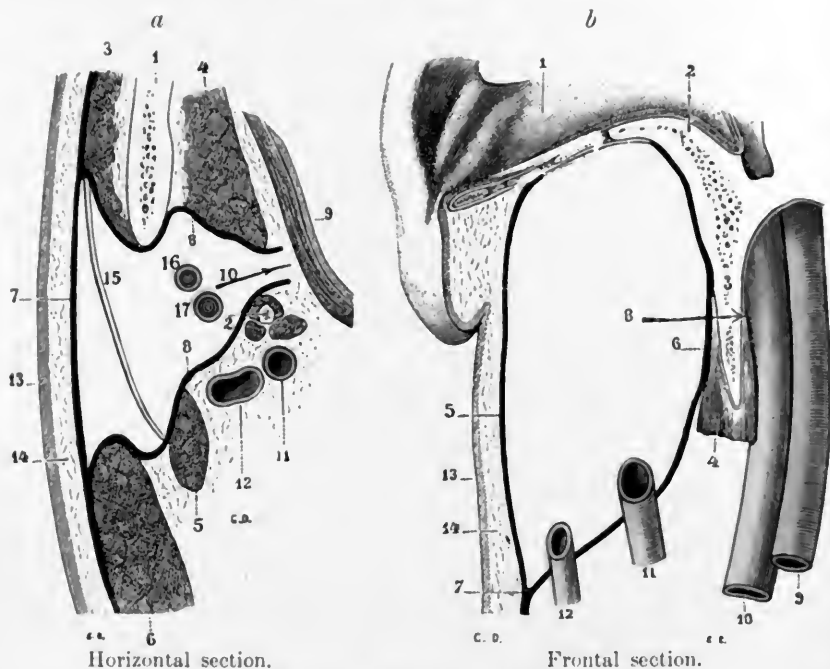
The Results.—In 128 cases operated on by Billroth, 91 healed by primary union, 25 suppurated, and erysipelas developed in 5. In 49 the final result could not be obtained. In 24 per cent no recurrence appeared in three and a half years. Local relapse happened in 14 per cent, and in 4 per cent at points distant from the seat of operation. In 16 cases the internal jugular was tied.

The Results.—The dangers of operation are slight; shock does not characterize it. *Jordan* and *Blos* report 328 cases without a death. Transient tachycardia and occasional hæmorrhage follow; local recurrence happened in from 7 (*Mitchell*) to 30 (*Blos*) per cent.

Branchial Cysts.—Branchial cysts are of congenital origin and should be removed as early in their history as practicable. Their frequent intimate association with the important deep structures of the neck invest their treatment with especial concern. Not infrequently a somewhat superficial cyst of this nature is connected deeply by means of a long, narrow, devious tract, the discovery and eradication of which is necessary to a final cure. The steps of the operative removal of these morbid developments differ in no essential respect from those directed to the treatment of diseased glands. The frequent greater profundity of the former is offset by the extensive morbid changes of the latter, so far as operative technique is concerned. The introduction of a probe along the channel to the seat of origin is often advantageous in the treatment of this variety of cases. In the instance of removal from the neck of other tumors than the special ones already con-

sidered, the rules of technique applicable to the latter can be satisfactorily applied to the removal of the former class. Briefly stated, free exposure of the growth through an incision best suited to the purpose; the removal by cautious blunt dissection, attended with prompt control of bleeding points; the prevention of air thrombosis; and the preservation of important structures.

The Extirpation of the Parotid Gland.—The complete removal of this gland is a most difficult operation, especially when its relations are changed by a malignant growth implicating its structure.



Horizontal section.

Frontal section.

FIG. 897.—The parotid compartment.

1. The ramus of the lower jaw. 2. The styloid process and its muscles. 3. The masseter muscle. 4. The internal pterygoid muscle. 5. The digastric muscle. 6. The sterno-mastoid muscle. 7. The superficial parotid aponeurosis. 8. The deep parotid aponeurosis. 9. The wall of the pharynx. 10. The pharyngeal orifice of the parotid sheath. 11. The internal carotid artery. 12. The internal jugular vein. 13. The integument. 14. The subcutaneous tissue. 15. The facial nerve. 16. The temporo-maxillary vein. 17. The external carotid artery.
1. The external auditory meatus. 2. The skull. 3 and 4. The styloid process and its muscles. 5. The superficial parotid aponeurosis. 6. The deep parotid aponeurosis. 7. The junction of inferior parts of compartment. 8. The situation of the pharyngeal orifice. 9. The internal carotid artery. 10. The internal jugular vein. 11. The external carotid artery. 12. The external jugular vein. 13. The integument. 14. The subcutaneous tissue

The Anatomical Points.—The parotid gland is located in the *parotid compartment*, which is formed by the deep cervical fascia; it is trabeculated, and is bounded *in front* by the posterior border of the ramus of the

lower jaw and its associated masseter and internal pterygoid muscles (Fig. 897, Horizontal section); *behind* by the sterno-mastoid, the posterior belly of the digastric muscles, and the mastoid process; *above* by the external auditory meatus and the posterior part of the glenoid fossa; *below* by the stylo-maxillary ligament separating the parotid from the posterior extremity of the submaxillary gland; *internally* by the styloid process and its attached muscles separating the gland behind from the internal carotid, the internal jugulars, and their accompanying nerves; in front from the loose sub-pharyngeal tissue. The external layer and the internal layer of the sheath of the sterno-mastoid correspondingly surround the parotid, meeting at its anterior border, thus forming chiefly the sheath or compartment of the gland. This sheath is incomplete (Fig. 897, 10, Horizontal section) at the inner aspect in front of the styloid process, corresponding to the pharyngeal wall, therefore, the pharynx and the gland are not infrequently reciprocally involved in disease of either of these regions. Also this sheath is not complete above corresponding to the external ear (Fig. 897, Frontal section), accounting for the readiness with which inflammations of the gland invade the auricular region at this situation. Extension of the head and protrusion of the jaw increase somewhat the access to the compartment in old age. In infancy the jaw encroaches the least upon the superficial area of the parotid compartment. *A careful study of the anatomy of this gland and its environments* should precede all efforts directed to its removal. Elongations of the gland of considerable size extend from its deep surface inward, one in front of and the other behind the styloid process, the former passing behind the mastoid process and sterno-mastoid muscle, the latter to the back part of the glenoid fossa. The external carotid artery passes through the gland from below upward, dividing into its terminal branches before its escape. Superficial to this artery there is a venous trunk formed by the union of the temporal and internal maxillary veins (Fig. 897, 16 and 17, Horizontal section); to this trunk the internal jugular is connected by a small branch that passes through the gland structure. The facial nerve (15) and its branches traverse the gland from behind forward, and receive a communicating branch from the great auricular in its substance. Immediately beneath the floor of the space lie the internal carotid artery and internal jugular vein, along with the spinal accessory, glossopharyngeal, and pneumogastric nerves. Lymphatic glands lie over the parotid and are present within it, and their enlargement may be mistaken for that of the gland itself.

The Contraindications to Extirpation.—Immobility of the tumor and a malignant growth implicating the structure of the gland may be regarded as strong contraindications to operation.

The Operation.—Place the patient upon a suitable table in a good light, with the shoulders elevated and the head turned to the opposite side. Make an incision from the zygoma downward along the central line of the tumor to its lower border. If necessary, this one can be supplemented by one or more extending from it at right angles. The integumentary flaps are freely reflected to expose the growth. The tumor should be raised from below

upward, and held by a volsella. This will raise the external carotid from its bed, when it should be isolated, tied between two ligatures, and divided. The vessels that enter or escape from the tumor at this point should be treated in the same manner (Fig. 898). The tumor can now be raised upward, and its separation from the deeper tissues continued by means of

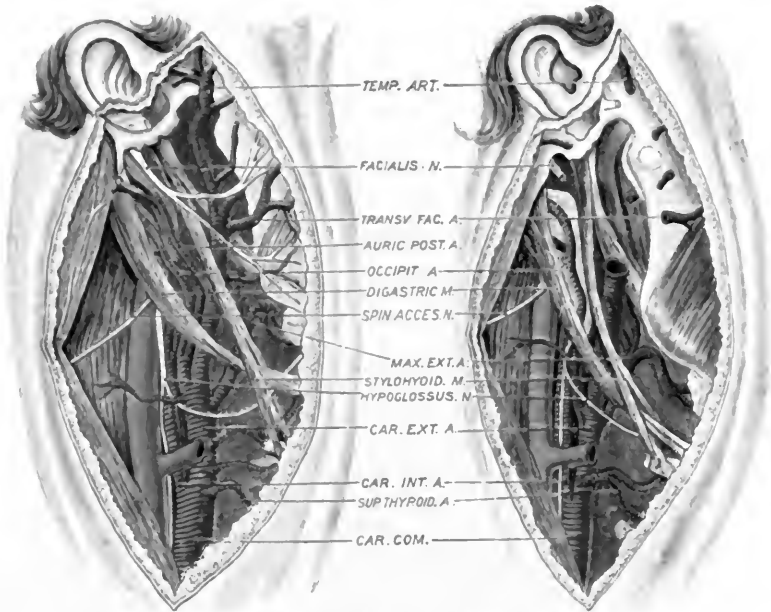


FIG. 898.—The surgical anatomy of the parotid gland.

the fingers or handle of the scalpel; the former are the better. The vessels, as they appear in the course of the dissection, are isolated and cut between two ligatures.

The separation of the growth from the floor of the space must be done gently and with great caution on account of the contiguity of the internal jugular vein and the other important vessels, and the nerves located there, which, if the growth be a large one, will be pressed upon by it, and may have become adherent to it. It is scarcely possible to avoid division of the facial nerves if the growth be compact. If it be soft and spongy, the integrity of the nerve may be preserved by a careful use of the fingers or director. The upper extremity of the gland is last removed. This step of the operation is necessarily attended with considerable hæmorrhage, which is, however, easily controlled. After the removal, unite the flaps, establish drainage, and dress antiseptically. During the dissection, room can be gained by causing the patient to open the mouth. Some tumors of large size, without adhesions, are more easily removed than small adherent tumors. When, as one approaches the large vessels, the adhesions become more resistant, great caution should be exercised, as the important structures may be closely adherent to the tumor. If, then, further efforts to

separate the tumor be unwise, the separated portion should be cut away and the remainder left in space. Often under these circumstances the remaining portion becomes with increasing growth more superficial, when it can be removed. The division and turning aside the ramus of the jaw has been done in some instances to gain more room. The limited space in which the gland is located leads to early adhesions at its important aspects. Preliminary ligature of the external carotid lessens the amount of the bleeding from the arteries directly concerned in the operation. Respiratory aspiration exercises its influence on the veins involved in the operation.

The Results.—This operation has been done upward of 200 times. When performed for malignant growths, the disease has almost invariably returned within six months. The dangers to life from the operation itself are about 12 per cent; only a few cases of cure of malignant disease are reported.



INDEX.

- Abbe's method of controlling hæmorrhage in operation on superior maxillary nerve, 283; method of intracranial neurectomy of trifacial nerve, 306; method of intracranial neurectomy of trifacial nerve, remarks on, 306; operation for stricture of œsophagus, 675.
- Abdominal aorta, contiguous anatomy of, 130; compression of, 540; ligature of, 130.
- Abdominal injury, shock due to, 120.
- Abdominal wall, weak point in, 141.
- Abscess, cerebellar, 260; cerebral, 258; of neck, 725; of tonsil, 634; retropharyngeal, 726; retropharyngeal, Buckhardt's method of opening, 727; retropharyngeal, Chiene's method of opening, 726.
- A. C. E. mixture, 10-31; indications for, 32.
- Acid, boric, saturated solution, 61; carbolic, 60; carbolic, for instruments, 52; carbolic, injection of, in goitre, Senn, 722; carbolic, with oleaginous substances, 60; oxalic, in cleansing hands, 114; salicylic, 61; sulphurous, 61.
- Acquired deformities, 558.
- Acromion process of scapula, excision of, 382.
- Actual cantery, 79.
- Acupressure, 75; applied to varicose veins, 216; Simpson's method, 75.
- Acute hydrocephalus, 229; lumbar puncture in, 229; results of operation on, 229.
- Adams's operation for Dupuytren's contraction, 351; results, 351; saw, 433; subcutaneous division of the neck of the femur, 436.
- Adductor longus, tenotomy of, 337.
- Adhesive strips in treatment of operation wound, 97.
- Adrenalin, 241; during shock, 122.
- Adrenalin chloride, 66; Crile on action of, 67; methods of administration of, 67.
- Agents for control of hæmorrhage, 65.
- Agnew's method of flap formation in amputations of thigh, 535; operation for salivary fistula, 632; operation for webbed fingers, 566.
- Air in veins, 122; Kemp's treatment of, 124; preventive treatment of, 124; symptoms of, 122; treatment of, 122.
- Air passages, foreign bodies in, 698; comments on, 699; results of, 700; treatment of, 699.
- Alcohol, 62; hypodermics of, 14; in preparation of field of operation, 95; in sterilizing and preserving sutures, 91.
- Alcoholic patients, operations on, 6.
- Alexander's method of ligaturing vertebral artery, 176.
- Allis's inhaler, 25.
- Alum as a styptic, 68.
- Alveolar process of lower jaw, excision of, 376.
- Ammonia, 119; for cleansing the hands, 114.
- Amputating knife, manner of grasping the, 462; knives, 461; knives, the Catlin, 462.
- Amputating saws, 464; proper method of using, 464.
- Amputation, agents required for, 461; aims sought in, 451; circular method, 453; circular method modified, 456; double-flap method, 457; equilateral flaps, 458; flaps, 451, 452; hood flap, 458; Langenbeck's method, 458; mixed double flap, Scdillot's method, 457; oval or racket method, 456; periosteal flap, 459; rectangular flap, Teale's method, 458; retractors used in, 466; semilunar flaps, Liston's, 456; selection of method of, 460; single flap method of, 456; stump, 451.
- Amputation above shoulder joint, 492; Berger's, 492; comments on, 494; precautions for, 494; results of, 495.
- Amputation at ankle joint, fallacies of, 511; modification of Syme's, 510; Roux's method, 512; Roux's method, remarks on, 512; Syme's method, 509; Syme's method, results, 512; Wyeth's, 511.
- Amputation at astragalus, Hancock's, 508.
- Amputation at carpo-metacarpal articulation of thumb, little, and index finger, 473; oval method, 473; lateral-flap method, 475.

- Amputation at elbow joint, 481; anatomical points for, 481; anterior single-flap method, 482; comments on, 483; circular method, 482; elliptical-flap methods, 481; results of, 483.
- Amputation at finger, 469.
- Amputation at hip joint, 540; anterior racket method, 550; antero-posterior-flap method, Guthrie's, 555; bloodless, Senn's, 546; circular-flap method, Diefenbach's, 552; control of hæmorrhage in, 73, 540; external racket method, 549; external racket method, Lister's modification, 550; Furneaux-Jordan method, 554; Lloyd's method of controlling hæmorrhage in, 545; long anterior and short posterior-flap method, Manec's, 551; McBurney's method of controlling hæmorrhage in, 545; methods of, 549; results, 546, 557; shock after, 546; single flap, Malgaigne's, 555; Tilden Brown's clamp for controlling hæmorrhage in, 546; tourniquet for control of hæmorrhage in, 540; treatment after, 557; Trendelenburg's rod in, 542; Wyeth's method of controlling hæmorrhage in, 542.
- Amputation at knee joint, 523; anatomical points for, 524; bilateral-flap method, Stephen Smith's, 524; fallacies of bilateral-flap method, Stephen Smith's, 525; precautions in bilateral-flap method, Stephen Smith's, 525; circular-flap method, 526; elliptical incision method, Baudens's, 526; long anterior and short posterior-flap method, Pollock's, 527; methods of, 524; results of, 527; Stephen Smith's method for gangrenous condition of toes and foot, 525.
- Amputation at the medio-tarsal joint, Chopart's, 504; remarks on, 505; results of, 505; Forbes's modification of Chopart's, 505.
- Amputation at metacarpo-phalangeal articulation, 471; by lateral-flap method, 472; by oval-flap method, 471; of second and third fingers, 471.
- Amputation at metatarso-phalangeal articulation of all toes, 499; comments on, 500; results of, 500.
- Amputation at phalangeal articulation, hand, 469; anatomical points for, 469.
- Amputation at phalangeal articulation, second row, finger, 470.
- Amputation at phalanx, terminal, finger, 469.
- Amputation at shoulder joint, 486; circular incision method, 489; circular incision method, remarks on, 489; external and internal-flap method, Dupuytren's, 488; oval-flap method, Larrey's, 491; prevention of hæmorrhage in, 487; racket-flap method, Spence's, 491; remarks on, 492; results of, 492; special considerations for, 487; Wyeth's needles in, 487.
- Amputation at tarso-metatarsal joints, Baudens's modification of Lisfranc's, 504; Hey's modification of Lisfranc's, 504; Lisfranc's, 502; Lisfranc's, remarks on, 504; Skey's modification of Lisfranc's, 504; Smith's modification of Lisfranc's, 504.
- Amputation at wrist, 477; anatomical points for, 477; circular-flap method, 477; double-flap method, Ruysch's, 478; radial flap, Dubrueil's, 479; remarks, 479; results, 479; single palmar flap, 478.
- Amputation of arm, 483; antero-posterior-flap method, 484; circular-flap method, 483; irregular double-flap method, 484; irregular double-flap method, remarks on, 484; large anterior and small posterior skin-flap method, 485; musculo-cutaneous flaps in, Langenbeck's, 484; Teale's method, 485.
- Amputation of arm at surgical neck of humerus, 485; anatomical points for, 485; oval method, Guthrie's, 486; single external-flap method, Farabeuf's, 486; remarks on, 486; results of, 486.
- Amputation of foot, Bruns's, 515; Es-march's modification of Le Fort's, 515; Fergusson's modification of Pirogoff's, 513; Le Fort's modification of, Pirogoff's, 514; Pirogoff's, 512; Pirogoff's, remarks on, 513; Pirogoff's, results of, 513; results of, 515.
- Amputation of forearm, 479; anatomical points for, 479; circular skin-flap method, 479; comments on, 481; equilateral skin-flap method, 480; Jacobson's posterior flap in, 480; musculo-cutaneous-flap method, 480; results of, 481.
- Amputation of great toe, 498; by square-flap method, 498; first phalanx, 496-497; or little toe, 498; or little toe, internal plantar flap-method of Farabeuf, 499; or little toe, oval-flap method, 499; through last phalanx, 497.
- Amputation of great toe with metatarsal bone, 501.
- Amputation of leg, lower third, author's circular, with periosteal flap, 516; author's circular, with periosteal flap, remarks on, 517; author's circular, with periosteal flap, results of, 518; Duval's supramalleolar, 516; Guyon's supramalleolar, 516; methods of, 516; results of, 520; Teale's method, 518; with bilateral flaps, 519; with hood flap, 520; with large posterior flap, 518.
- Amputation of leg at middle third, 520; large posterior-flap method, Hey's, 520; Lee's modification of Teale's, 521; long external-flap method, 521; results of, 521.
- Amputation of leg at upper third, 521;

- bilateral-flap or hood method, 523; circular-flap method, 522; large external-flap method, Farabeuf's, 521; results, 523.
- Amputation of leg, osteoplastic, Bier's, 530; Eiselberg's, 530.
- Amputation of leg, treatment after, 523.
- Amputation of metacarpal bones, four, with fingers, 476; inner three, 476; last four, 475; last two, 476.
- Amputation of metatarsal bone of second, third, or fourth toe, 502; comments on, 502.
- Amputation of phalanges, fingers, remarks on, 470.
- Amputation of thigh, 532; Agnew's method of flap formation in, 535; antero-posterior musculo-integumentary flap method, 534; bilateral-flap method, 533; circular integumentary flap method, 535; circular integumentary flap method, Syme's modification of, 535; equilateral-flap method, Vermale's, 533; general remarks on, 537; long anterior and short posterior-flap method, Farabeuf's, 537; long anterior-flap method, Sédillot's, 537; methods of, 533; results of, 540; single circular incision method, Celsus's, 536; single circular incision method, Celsus's, remarks on, 537; special considerations for, 532; suturing over the ends of bone after, 537; treatment after, 539.
- Amputation of thigh through condyles, 528; Carden's method, 528; Carden's method, results, 528; Farabeuf's method, 529; Gritti's osteoplastic method, 529; Gritti's osteoplastic method, fallacies of, 529; Lister's modification of Carden's method, 528; Sabanejeff's osteoplastic method, 532; Stokes's modification of Gritti's method, 529; results of Stokes's and Gritti's method, 530.
- Amputation of thigh through trochanters, 540.
- Amputation of toes, little, 498; little, with metatarsal bone, 501; phalanges of, 499; second, third, and fourth, 497; single, 497; two adjoining, 499.
- Amputation, subtragaloid, 506; Lignerolles's, 507; Lignerolles's, results of, 508; heel-flap method, 508; Verneuil's, 508.
- Amputation, tarsal, irregular, Mollière's, 506.
- Amputation through metacarpal bones, 475; remarks on, 475.
- Amputation through metatarsal bones, 500.
- Amputation through os calcis, Tripier's, 508.
- Amputations at leg, 515.
- Amputations at lower extremity, duty of surgeon, 496.
- Amputations at upper extremity, general remarks on, 468.
- Amputations, comments on, 467; general consideration of, 451.
- Amputations of thumb and fingers, remarks on, 477; results of, 477.
- Amputations, tarsal, results of, 509; treatment after, 509.
- Amyl nitrite, 119; during shock, 122.
- Anæsthesia, administration of oxygen during, 35; coughing and swallowing under, 12; dangers of, 16; during operations on tongue, 635; fancies during, 14, 15; for excision of upper jaw, 365; for operation on cervical lymphatic glands, 729; for operation on thyroid body, 711, 716; for removal of nasal growths, 660; for removal of nasal polyp, 651; for removal of tonsil, 633; hypodermic injections during, 14; in gunshot wounds of the cranium, 266; in staphyloorrhaphy, 620; in tuberculosis, 5; incomplete, dangers of, 16; infiltration, with cocain (Schleich), 38; instruments for, 13; intraneural, 38; laryngeal obstruction during, 16; muscles during, 15; preparation of patient for, 10; pulse during, 14; pupils during, 15; pushing jaw forward during, 15; reflexes as guides during, 15; regional paraneural infiltration, 38; respiration during, 14, 15; spinal, 41; stimulants during, 14; struggling of patients under, 11; suffocation from vomited matter during, 120; through tracheotomy tube, 660.
- Anæsthetic for bronchotomy, 682; for laryngotomy, 628; for tracheotomy, 682; in craniotomy, 250; in intubation of larynx, 696; rapid respiration as an, 36.
- Anæsthetics, A. C. E. mixture, 31; chloroform, 28; chloroform before ether, 34; chloroform mixtures before ether, 34; choice of, 4, 10, 23, 34; dangers, of, 15; deaths from, 22; ether, 23; ethyl bromide, 34; ethyl chloride, 34; gas before ether, 34; inebriation before, 35; morphine with, 35; nitrous oxide, 32; nitrous oxide with oxygen, 33; Schleich's mixture, 38; local, 36.
- Anæsthetist, duties of, 14, 93; equipment of, 13; one assistant necessary as an, 93; preparation of, 12.
- Anatomical guide, contiguous, to an artery, 125.
- Anatomical points of lingual or gustatory nerve, 288.
- Anchlyosis, bony, of knee joint, 441; general remarks on osteotomy for, 441; osteotomy for, 441.
- Anderson's method of lengthening tendo-Achillis, 341.
- Aneurismal needle in amputating, 467.
- Aneurism, extirpation of, 202; fusiform, radical cure of, 207; needle, 129; needle in ligature of arteries, 127; of the extremities, 206; of the extremities, ex-

- tirpation of, 206; of the extremities, ligature of collateral branches of, 206; of the extremities, remarks on extirpation of, 207; radical cure of, Matas's method, 207; remarks on Matas's method of radical cure of, 209; saciform, radical cure of, 208; spontaneous subclavian, 203; traumatic, 202.
- Anger's operation for ingrown toe-nail, 567.
- Angina, Ludwig's, 725.
- Angular incision for goitre, 714.
- Angular gyrus, 250.
- Angular nose, 595.
- Ankle-joint amputation, 509; modifications of Syme's method, 510; Roux's method, 512; Roux's method, remarks on, 512; Syme's method, 509; Syme's method, fallacies of, 511; Syme's method, results of, 512; Wyeth's method, 511.
- Ankle joint, arthrectomy of, Brun-425; Busch's non-subperiosteal excision of, 413; excision of, 411; landmarks for excision of, 412; Langenbeck's subperiosteal excision of, 412; results of excision of, 414; treatment after excision of, 414; Vogt's excision of, 413.
- Annandale's operation for removal of nasal growths, 657.
- Anterior dental nerve, division of, 278.
- Anterior tibial artery, anatomical points of, 150; ligature of, 150; linear guide to, 151; muscular guide to, 151.
- Antipyrine solution for control of hæmorrhage, 241.
- Antiseptic, dressings, 107; and aseptic methods, 50; gauze, improvised, 112; method, 94; technique in gunshot wounds of the cranium, 266; varnish, Whitehead's, 639.
- Antrum, mastoid, opening of, 262.
- Aorta, abdominal, compression of, 540; digital, 540; with Davy's lever, 541; with Esmarch's tourniquet, 541; with Lister's tourniquet, 541; with Pancoast's tourniquet, 541.
- Aorta, abdominal, contiguous anatomy of, 130; ligature of, 130; ligature of, Cooper's method, 130.
- Aortic tissue ligatures, 93.
- Apparel of surgeon and assistants, 115.
- Aqua ammonia for cleansing hands, 114.
- Arches, palmar, ligature of, 190; guide to linear, 190; precautions in ligature of, 190; relations of, 190.
- Aristol, 110.
- Arm, amputation, 483; antero-posterior-flap method, 484; circular-flap method, 483; irregular double-flap method, 484; irregular double-flap method, remarks on, 484; large anterior and small posterior skin-flap method, 485; musculocutaneous flaps in Langenbeck's, 484; Teale's method, 485.
- Arm, amputation at surgical neck of humerus, 485; anatomical points for, 485; oval method, Guthrie's, 486; remarks on, 486; results of, 486; single external-flap method, Farabeuf's, 486.
- Armamentarium, variety and extent of, 45.
- Arterial infusion, 223; selection of vessel for, 223.
- Arterial pressure in shock, 122; tension in shock, 122.
- Arteries, accompanied by a single vein, 125; accompanied by venae comites, 125; color of, 126; common iliacs, relations of, 132; guides to, 125; instruments required to ligature, in continuity, 129; ligature of, general considerations of, 125; ligature of, in continuity, 125; pulsation of, 126; relation of, to veins, 126; special operations on, 202.
- Arteriorrhaphy, 211; Bangle's method, 214; Murphy's method, 213; Salomon's method, 214; suture material for, 213; when the wound exceeds one-half the circumference of the vessel, 213; remarks on, 214.
- Arterio-venous aneurism, extirpation of, 202.
- Artery, digital compression of femoral, 540; iliac, internal, relations of, 135; middle meningeal, 237; scapular, possible origin of, 173.
- Artery, ligature of, anterior tibial, 150; axillary, 178; brachial, 180; common carotid, 191; common carotid, both, 193; common carotid, temporary, 194; common iliac, 131; deep epigastric, 141; deep circumflex iliac, 142; dorsalis pedis, 153; dorsalis penis, 138; external carotid, 194; external circumflex, 148; external iliac, 138; facial, 200; femoral, 142; femoral, common, 143; femoral, deep (profunda), 148; femoral, superficial, 145; gluteal, 136; inferior thyroid, 177; innominate, 158; internal carotid, 195; internal iliac, 135; internal mammary, 177; internal pudic, 137; lingual, 197; middle meningeal, 214; occipital, 201; peroneal, 155; popliteal, 149; posterior tibial, 153; procedure for, 126; radial, 185; sciatic, 136; subclavian, 168; superior thyroid, 197; temporal, 201; ulna, 188; vertebral, 174.
- Artery compressor, Gross's, 78.
- Arthrectomy, 424; of ankle joint, Brun-425; results of, 424.
- Arthrotomy at hip, for dislocation, 431; incisions for, 431; instruments for, 431; results of, 431.
- Arthrotomy for irreducible dislocation of humerus, 391; with fracture, 392; without fracture, 392; remarks on, 393; results of, 393; treatment after, 393.
- Artificial hæmostatics, 65; heat after anaesthesia, 21; larynx, 708; respiration, 119.

- Aseptic and antiseptic solutions, 59.
- Aseptic dressing, 107; method, 50, 94; gauze, improvised, 112; gauze pads, 63; towels and sheets, 57.
- Asphyxia, after-effects of, 20; care of patients after, 21; circulatory depression during, 17; stertor during, 17.
- Aspiration of heart, 123.
- Aspirator, trachea, 684.
- Assistants, disposition of, at operation, 93; number of, necessary for an operation, 93; one necessary as an anæsthetist, 93; preparation of, for an operation, 113.
- Astragalo-seaphoid joint, excision of, for relief of talipes, Ogston's, 449.
- Astragalus, amputation through, Hancock's, 508; enucleation for clubfoot, Lund's, 449; enucleation for clubfoot, results, 449; excision of, 410; excision of, by oval incision, 410; excision of, by double incision, 411; linear osteotomy of neck of, for talipes equinus-varus, 448; removal of, for relief of talipes, Vogt's, 449.
- Auricularis magnus nerve, operation on, 320.
- Auriculo-temporal nerve, exposure of, 289; guide to, 289.
- Axillary artery, anatomical points of first portion, 178; guides to, first portion, 178; guides to third portion, 179; ligature of, 178; relations of first portion, 178; relations of third portion, 180; three points for ligature, 178.
- Axillary vein, results of ligature of, 215.
- Baker's operation for removal of tongue with éraseur, 641.
- Ballance and Edmunds stay knot, 84; in ligature of the innominate, 162.
- Balsam of Peru after operation, 118.
- Bandage, Esmarch's elastic, 69; Martin's, 70.
- Bandages, 108; elastic in shock, 119; inelastic, as hæmostats, 68.
- Bandaging to control bleeding, 96.
- Bardenheuer's method of ligature of the innominate, 161.
- Barker's excision of hip joint, 428; pegs in excision of knee joint, 422.
- Barton's cuneiform osteotomy for ankylosis of knee joint, 441; operation for bony ankylosis of knee joint, 538.
- Batteries, storage, for galvano-cautery, 81.
- Battery, electric, during operation, 119.
- Bauden's amputation at knee joint, 526; modification of Lisfranc's tarso-metatarsal amputation, 504; oblique incision for excision of upper end of humerus, 385.
- Baum's operation for exposing facial nerve, 307; comments on, 309; results of, 310.
- Bellocoq's cannula for plugging posterior nares, 650.
- Bennett's inhaler, 28, 33.
- Berger's amputation above the shoulder joint, 492.
- Beta eucain, 43.
- Beta-naphthol, 61; for instruments, 52.
- Biceps flexor cubiti, tenotomy of, 332.
- Biceps flexor cruris, tenotomy of, 336.
- Bichloride gauze, 111; objections to, 113.
- Bichloride of mercury, instability of, 113; tablets of, 113.
- Bier's osteoplastic amputation of leg, 530.
- Billroth's method of removal of tongue, 642; method of tendon suturing, 340.
- Binders, 108.
- Binioidide of mercury, solutions of, 60.
- Bird's cuneiform osteotomy for relief of talipes, 449; excision of knee joint through transverse incision, 419.
- Birthmark, 223.
- Birthmark, treatment of, by electrolysis, 224; by freezing and incisions, Squire's, 223; by heated needles, 224; by injection, 224; by Paquelin's cautery, 224.
- Blasius's method of cheiloplasty of lower lip, 606.
- Bleaching powder for cleansing the hands, 114.
- Bleeding from operation wounds, 96.
- Blood, during shock, 120; examination after operation, 118; in operation wound, 97; shock due to loss of, 121.
- Blood-clot, organization of, in osteoplasty, 450.
- Bloodless stretching of great sciatic nerve, 326.
- Blunt dissection, 49.
- Boeckel's operation for removal of nasal growths, 657.
- Boiled water, 62.
- Bone, caries of, 356; chips in osteoplasty, 450; chips, preparation of, 450; excision of, 361; flap in craniotomy, 251; fracture of hyoid, 724; functions of, 356; necrosis of, 356; subperiosteal removal of, 361; transplantation of, 450; transplantation of, *en masse*, 450; treatment of, in amputations, 452.
- Bone-cutting forceps, Liston's, 465.
- Bone-forceps, in dislocation and fracture of the humerus, 392.
- Bone-holding forceps for excision of bone, 364.
- Bones, fixation of, after excision of knee joint, 422; long, distortion of, 559.
- Bones, metacarpal, amputation of four, with fingers, 476; of inner three, 476; of last four, 475; of last two, 476; through, 475.
- Bones, metatarsal, amputation through, 500.
- Bones, of the face, excision of, 365; of the leg, excision of, 416; operations on, 356.

- Bony defects**, Neuber's method of healing by canalization, 358; Schede's method of healing, 358.
- Bony guide to artery**, 125; to external carotid artery, 195; to inferior thyroid artery, 178; to internal carotid artery, 196; to temporal artery, 201; to lingual artery, 198; to subclavian artery, second and third portions, 172; to vertebral artery, 175.
- Bony guides**, to facial nerve, 307; to subclavian artery, 168.
- Bony landmarks of the skull**, 245.
- Boric acid**, saturated solution of, 61.
- Bougie**, œsophageal, 664; conical, Knott's, 674.
- Bow legs**, osteotomy for, 445.
- Brain**, abscess, results after operation on, 260; exploration of, for pus, 258; exploration of, for tumor, 253; foreign bodies found within, after gunshot wounds, 266; injury, shock due to, 120; penetration of, with probe, 267; tumor, craniotomy for, 245; tumor, results of operation for, 255; tumor, treatment of, 253.
- Brachial artery**, anatomical points of, 180; guides to, 180; high bifurcation of, 183; ligature of, 180, 182; points for ligature of, 181; relations of, 180.
- Brachial plexus**, operation on branches of, 321.
- Bradford's linear osteotomy of neck of astragalus for talipes equino varus**, 448.
- Branchial cysts**, 733.
- Brandy**, 119; with anæsthetics, 35.
- Brisment forcée for anchylosed joints**, 558; for anchylosed knee joint, 558; for anchylosed knee joint, results of, 559; for anchylosed knee joint, treatment after, 559.
- Broca's convolution**, 250.
- Bronchitis after anæsthesia**, 21.
- Bronchotomy**, 681; anatomical points for, 681; anæsthetic for, 682; general comments on, 690; instruments for, 683; results of, 692; treatment after, 685, 692; use of thermo-cautery in, 690.
- Bronchus**, foreign body in, 699.
- Brown's (Tilden) clamp for controlling hæmorrhage in amputation at hip joint**, 546.
- Bruised tissue**, drainage of, 105.
- Brun's amputation of foot**, 515; arthroctomy of ankle joint, 425; method of cheiloplasty of lower lip, 608; method of cheiloplasty of upper lip, 612; method of flap transfer in plastic surgery, 573.
- Bryant's, J. D.**, amputation of leg with periosteal flap, 516.
- Buccal nerve**, exposure of, 290; operations on, 290; results of operations on, 290.
- Buccal route to inferior dental nerve**, 285.
- Buchanan's method of cheiloplasty of lower lip**, 609.
- Buckhardt's method of opening retro-phalangeal abscess**, 727.
- Buck's intero-lateral-flap method of cheiloplasty of upper lip**, 612; method of cheiloplasty of lower lip, 609; method of stomatoplasty, 615; pin, 76; pin carrier, 103; semicircular vertical-flap method of cheiloplasty for entire loss of upper lip, 613.
- Bullet**, approach of, through counter opening in cranium, author's method, 269; location of, after gunshot wounds of cranium, 267; removal of, after gunshot wounds of cranium, 268.
- Bunion**, operations for, 447; treatment of, and remarks on, 568.
- Buried suture**, 103.
- Burow's method of flap transfer in plastic surgery**, 573.
- Burrell's method of ligature of the innominate**, with resection of the sternoclavicular articulation and upper end of sternum, 160; operation for habitual dislocation of humerus, 393.
- Bursæ**, 352; mucous, 353.
- Bursitis**, postolecranon, treatment of, 354; prepatellar, treatment of, 353.
- Busch's non-subperiosteal excision of ankle joint**, 413.
- Button suture**, 103.
- Cachexia thyreopriva**, 722.
- Caffein citrate**, 119.
- Calcaneum**, attachment of tendo-Achillis, 409; excision of, 409; gouging of, 409.
- Calcium chlorid in cholemia**, 67; in hæmophilia, 67.
- Canalization**, drainage by, 107.
- Capillaries**, operations on, 215-223.
- Cannula**, Bellocq's, 650.
- Carbolic acid**, 60; injection of, in goitre, Senn, 722; in preparation of field of operation, 95; solutions, 59; solutions for instruments, 52; with oleaginous substances, 60.
- Carbonate of soda**, for cleansing the hands, 114; solutions of, for instruments, 62.
- Carden's amputation of thigh through condyles**, 528; results of, 528.
- Cardiac action during shock**, 120.
- Caries of bones**, 356.
- Carious bone**, gouging of, 356; comments on gouging of, 356.
- Carnochan-Chavasse operation on second division of trifacial nerve**, 283; precautions in, 283.
- Carnot's solution**, 66.
- Carotid artery**, common, anatomical points of, 191; common, ligature of, 190; external, anatomical points of, 194; external, excision of, Dawbarn, 209; external, guides to, 195; external, ligature of, 194; external, relations of, 194; internal, anatomical points of,

- 196; internal, guides to, 196: internal, injury of, in excision of the tonsil, 634; internal, ligature of, 196; internal, relations of, 196.
- Campo-metacarpal articulation, amputation of, of thumb, little, and index fingers, 473.
- Carrier, pin, Buck's, 103; Post's, 103.
- Cartilage, thyroid, 681.
- Catgut, chromacized, 93; chromacized, in radical cure of aneurism, 207; drainage, 106.
- Catgut ligatures, 81, 86; characteristics of, 87; chromacized, 90; cumolized, 91; length of, 87; preparation of, 87; sterilization of, 87; tensile strength of, 87; varieties of, 87.
- Catgut, preparation of, at Bellevue Hospital, 87; at Jefferson Hospital, 92; at Johns Hopkins Hospital, 92; at New York Hospital, 92; at Saint Luke's Hospital, 92.
- Catgut sutures, 97.
- Catlin in amputating, 463.
- Caustic soda in preparation of dressings, 113.
- Cautery as an hæmostatic, 79; for control of hæmorrhage, 79, 241; Paquelin, in treatment of birthmark, 224.
- Cavity, filling of, with bone chips in osteoplasty, 450; preparation of, in osteoplasty, 450.
- Cellulitis, danger of, in operations on thyroid, 722.
- Celluloid plate, use of, after craniotomy for epilepsy, 256.
- Celluloid thread suture, 98.
- Celsus's method of cheiloplasty of lower lip, 607; single circular incision method of amputation of thigh, 536.
- Cerebellar abscess, 260.
- Cerebellar tumor, craniotomy for, 255.
- Cerebral abscess, 258; operation for, 259; operation for, precautions in, 260.
- Cerebral tumor, craniotomy for, 251.
- Cervical nerves, operations on branches of, 320; excision of posterior branches of first three, 320; resection of posterior divisions of, for spasmodic wry-neck, 562.
- Cervical œsophagotomy, 668; fallacies of, 668; remarks on, 669; results of, 670; treatment after, 670.
- Chain saw, for excision of bone, 364.
- Chalot's operation for nasal growths, 656.
- Champagne, 119.
- Chassaignac's operation for nasal and naso-pharyngeal polypi, 654.
- Chavasse's operation on the second portion of trifacial nerve, 283.
- Cheek, deformities of, 616.
- Cheever's method of pharyngotomy, 645; remarks on, 645; operation for nasal growths, 659.
- Cheiloplasty, 605.
- Cheiloplasty of lower lip, 605; Blasius's method, 606; Bruns's method, 608; Buck's method, 609; Celsus's method, 607; Dowd's method, 611; Estlander's method, 607; Grant's method, 606; horizontal incision method, 606; Langenbeck's circular method, 608; Langenbeck's chin-flap method, 609; Maligne's method, 610; Sédillot's method, 611; Syme-Buchanan method, 609; Syme's method, 609; "V"-incision method, 605.
- Cheiloplasty of upper lip, 612; Bruns's method, 612; Buck's method, 612; Buck's semicircular vertical-flap method, 613; Dieffenbach's curved flap method, 614; Dieffenbach's "S"-shaped flap method, 614; for entire loss, 612; Ledran-Mackenzie method, 615; Sédillot's vertical-flap method, 613; Szymanowski's method, 614.
- Cheyne's method of drainage of the lateral ventricles, 229.
- Chiene's method of locating the Fissure of Rolando, 247; method of opening retropharyngeal abscess, 726; operation of osteo-arthrotomy for genu valgum, 444.
- Chicken bones, drainage with, 106.
- Chisel, for osteotomy, 435; Hartley's, 298; Pyle's, 298.
- Chloride of lime for cleansing the hands, 114.
- Chloride of zinc, solutions of, 60.
- Chloroform, 28; administration of, 29; before ether, 34; dangers of, 17; inhalers, 30; mixtures of, before ether, 34.
- Chloroform anaesthesia, 28; cases suited for, 29; cause of death during, 28, 29; death rate of, 22; in craniotomy, 238.
- Cholæmia, action of calcium chlorid in, 67.
- Chopart's amputation at mediotalar joint, 504.
- Chromacized catgut, 90; sutures, 97.
- Chronic hydrocephalus, 227; drainage agents in, 228.
- Chronic thecitis, 352.
- Cicatricial contraction, Croft's operation for, 578.
- Cicatrix, position of, after amputation, 451.
- Cricoid growth, treatment of, by division and ligature, 226.
- Circular craniotomy for fracture of skull, important considerations of, 236; for fracture of skull, repair of cranial opening after, 235; for fracture of skull, results of, 238; removal of button in, 234; utilization of rongeur and gouge in, 235.
- Circumclusion, for arrest of hæmorrhage, 76.
- Circumflex artery, external, ligature of, 148.

- Circumflex iliac artery, deep ligature of, 142.
- Circumflex nerve, arm, operation on, 323.
- Clamp, for correction of deviation of septum nasi, 661; Langenbeck's, 69; Tilden Brown's, for control of hæmorrhage in amputation at the hip joint, 546.
- Clark's method of preparing catgut, 91.
- Clavicle, anatomical relations of, 379; excision of, 379; morbid processes of, 379; operation for malignant growth of, 380.
- Cleanliness of a wound, drainage as a factor in, 104.
- Cleveland's operating table, 54.
- Clover's inhaler, 26.
- Coaptation and relaxation suture, 104.
- Coaptation, retentive, of wound surfaces, 96.
- Cocain as a local anæsthetic, 37; for arrest of hæmorrhage from brain, 241; in tenotomy, 331; in the prevention of shock, 121; sterilization of, 41.
- Coccyx, excision of, 432.
- Coffee, 119; in shock, 121.
- Coleman's method of controlling hæmorrhage in typhoid fever, 66.
- Collapse, 120, 122.
- Colley's method of uranoplasty, 626.
- Collodion, 101; styptic, 68.
- Colly's cuneiform osteotomy of tarsus for talipes equino-varus, 447.
- Combined dressing, 108.
- Common carotid arteries, ligature of both, 193.
- Common carotid artery, anatomical points of, 191; guides to, 191; ligature of, 190; points for ligature of, 192; relations of, 191; temporary ligature of, 194.
- Common iliac arteries, relations of, 132.
- Compensative appliances after amputation, 451.
- Composition of iodoform gauze, 111.
- Compresses as hæmostatics, 70.
- Considerations, important, in treatment of operation wound, 96.
- Condyles, amputation of thigh through, 528; Carden's method, 528; Carden's method, results, 528; Farabeuf's modification of Carden's method, 529; Gritti's method, 529; Lister's modification of Carden's method, 528; results of Stokes's and Gritti's method, 530; Sabancjeff's osteoplastic method, 532; Stokes's modification of Gritti's method, 529.
- Cone, cloth and paper, 24.
- Congenital deformities, 558.
- Congenital displacement of hip, Hoffa's operation, 439; Lorenz's operation, 440; results of Hoffa's operation, 440; results of Lorenz's operation, 440; treatment after Hoffa's operation, 439.
- Contiguous anatomical guide to an artery, 125.
- Contiguous anatomy of abdominal aorta, 130, 131; of axillary artery, first portion, 178; of axillary artery, third portion, 180; of brachial artery, 180; of common carotid artery, 191; common iliac artery, 132; of external carotid artery, 194; external iliac artery, 139; of femoral artery, 142; of inferior thyroid artery, 177; innominate artery, 158; of internal carotid artery, 196; of internal iliac artery, 135; of internal pudic artery, 138; of palmar arches, 190; of popliteal artery, 149; of radial artery, 185; of sciatic artery, 137; of subclavian artery, first portion, left side, 169; subclavian artery, first portion, right side, 170; subclavian artery, second portion, 174; subclavian artery, third portion, 171; of ulna artery, 188; of vertebral artery, 174.
- Continuity, ligature of arteries in, 125.
- Continuous suture, 102.
- Cooper's method of ligaturing abdominal aorta, 130; of ligaturing the innominate, 162.
- Cornu, posterior (brain), 249.
- Corrosive sublimate solutions, 59.
- Cotting's operation for ingrown toe-nail, 568.
- Cotton batting dressing, 108.
- Cotton gloves, 115.
- Cotton, medicated, 108.
- Cranio-cerebral topography, 245.
- Craniotomy, circular, 231.
- Craniotomy, for fracture of the skull, 231; for brain tumor, 245; for brain tumor, precautions, 254; for brain tumor, results, 255; for cerebral tumor, 251; for cerebellar tumor, 255; for cerebellar tumor, precautions, 256; for cerebellar tumor, results, 256; for epilepsy, 256; for epilepsy, introduction of foreign substances after, 256; for epilepsy, remarks on, 257; for epilepsy, results, 257; for evacuation of pus, 257; for general paralysis of the insane, 261; for gunshot wounds, 266; for gunshot wounds, after treatment, 270; for gunshot wounds, precautions in, 270; for gunshot wounds, results, 270; for meningeal hæmorrhage, 238; for meningeal hæmorrhage, precautions, 239; for meningeal hæmorrhage, results, 239; for microcephalus, linear, 241; for thrombosis of lateral sinus and jugular vein, 260; for thrombosis of lateral sinus and jugular vein, precautions, 261; for thrombosis of lateral sinus and jugular vein, results, 261; varieties of, 231.
- Cranium, gunshot wounds of, 266; trephining of, 231.

- Crede's operation on trifacial nerve at foramen ovale, 293.
 Cricoid cartilage, 682.
 Crico-laryngotomy, 687.
 Crico-thyroid space, 682.
 Cricotomy, 685.
 Crile on action of adrenalin, 67.
 Crile's hot-water mattress, 55; rubber suit for shock, 122; treatment of shock, 121; views on shock, 120.
 Croft's operation for cicatricial contraction, 578; remarks on, 580.
 Crural nerve, anterior, operation on, 327.
 Cumolized catgut, 91.
 Cuneiform osteotomy, 433.
 Curvature of spine, 560; plaster-of-Paris jacket for, Sayre, 560.
 Curtis's method of ligaturing the innominate, 164; placing of ligature in, 166; remarks on, 167.
 Cushing's method of intracranial neurectomy of trifacial nerve, 303; remarks on, 305; results of, 306.
 Cushing's operation for facial paralysis of extra cerebral origin, 310; remarks on, 310.
 Cushion of oakum after operation, 118.
 Cushion, rubber, surgical, 54.
 Cutaneous amputation flaps, 452.
 Cutting tendency of silkworm gut, 98.
 Cyanosis during shock, 122.
 Cystic tumor of brain, treatment of, 254.
 Cysts, branchial, 733.
 Czerny's method of pharyngotomy, 646.
- Davidson's syringe, 119.
 Davies-Colly, cuneiform osteotomy of tarsus for talipes equino-varus, 447.
 Davies-Colly method of uranoplasty, 626; remarks on, 626.
 Davy's lever, 73; for compressing abdominal aorta, 541.
 Dawbarn's excision of externus carotid, 209; method of saline transfusion, 221; removal of external carotid arteries, 194.
 Dead spaces, in operation wound, 97; management of, 101, 104.
 Death, cause of, after excision of lower jaw, 377; after intracranial neurectomy of trifacial nerve, 301; in amputation at hip joint, 540.
 Death, due to air in veins, 122; following rupture of third perforating branch of the profunda artery, 148; from lateral ligature of the internal jugular vein (Braun), 215.
 Death-rate after linear craniotomy, 245; for removal of brain tumor, 255.
 Deaths from anæsthetics, 22, 43.
 Dec's operation for webbed fingers, 564.
 Decalcified tubes, Neuber's, for drainage, 106.
 Deep palmar arch, incision for, 191.
 Deep sutures, 98.
 Deformities, 558; dependent upon per-
- verse muscular action, 561; due to fusion, 563; of cheek, 616; of mouth, 615; of nose, 592; of nose, operations for, 593; of nose, comments on, 593; of nose, injection of paraffin for, 593; upper lip, 612.
 Deformity of nasal septum, 661.
 Deguise's operation for salivary fistula, 633.
 Deltoid, myotomy of, 348.
 Denhard's mouth gag, 285.
 Dental nerve, anterior, division of, 278.
 Dental nerve, inferior, 284; comments on operation on, 286; exposure of, in dental canal, 288; external or facial route to, 286; Horsley's incision for, 287; internal or buccal route to, 285; Keen's incision for, 287; Linhart's incision for, 287; Lücke's incision for, 287; operation on, 285; precautions for operation on, 286, 288; situations for exposure of, 285.
 Desault's operation for salivary fistula, 632.
 Desprez's operation for removal of nasal and naso-pharyngeal polypi, 653.
 Diagram of arrangements for operation, 115.
 Diday's operation for webbed fingers, 564; objections to, 565.
 Dieffenbach-Fergusson method of uranoplasty, 625; remarks on, 625.
 Dieffenbach's circular-flap method of amputation at hip, 552; method of flap transfer in plastic surgery, 572; operation for single harelip, 602; operation of rhinoplasty, 584; pyriform flap in rhinoplasty, 589; "S"-shaped flap method of cheiloplasty, 614; curved-flap method of cheiloplasty, 614.
- Diet, 9.
 Digital pressure as an hæmostatic, 71.
 Digitalis, 119; during shock, 122.
 Director, grooved, 47, 129.
 Disarticulation at ankle joint, 509; at carpo-metacarpal joint of three inner metacarpal bones, 473; at elbow joint, 481; at hip joint, 540; at knee joint, 523; at knee joint, results, 527; at mediotarsal joint, 504; at metacarpophalangeal articulations, 471; at metatarsophalangeal joint, 499; at phalangeal articulations of hand, 469; at shoulder joint, 486; at tarso-metatarsal joints, 502; at wrist joint, 477.
 Disarticulation of great toe, 498; of last four metacarpal bones, 475; of little toe, 498; of phalanges of toes, 496; of toes, 497; subastragaloid, of foot, 506.
 Dislocation at hip, arthrotomy for, 431.
 Dislocation of humerus, habitual, operation for, 393; habitual, results of operation for, 393; irreducible, arthrotomy for, 391.
 Displacement of ulnar nerve, 324; McCormac's method of treatment of, 324.

- Dissection, blunt, 49.
 Divided tissues, uniting of, 98.
 Dorsalis pedis artery, ligature of, 153;
 linear guide to, 153; muscular guide
 to, 153.
 Dorsalis penis artery, ligature of, 138.
 Douche, temperature of, 117.
 Douching cut surfaces, 116.
 Douching apparatus, 108; improvised,
 108.
 Dowd's method of cheiloplasty of lower
 lip, 611; remarks on, 612.
 Downes's thermic angiotube, 79.
 Doyen's method of intracranial neurec-
 tomy of trifacial nerve, 302.
 Drainage, 104; after gunshot wounds of
 the cranium, 268, 270; after removal
 of brain tumor, 254; agents in chronic
 hydrocephalus, 228; anterior, of lateral
 ventricles (Cheyne, Southerland), 229;
 by canalization, 107; in septic cases,
 95; means of securing, 105; spinal men-
 ingeal, 316; with catgut, 106; with
 chicken bones, 106; with horsehair,
 106; with silkworm gut, 106.
 Drainage tubes, 105; removal of, 106.
 Dressing, combined, 108; cotton batting,
 108; gauze, 110, 111, 112; jute, 112;
 moss, 112; muslin, 112; open, after op-
 eration, 118; peat, 112; rubber dam,
 108; sawdust, 112; wood pulp, 112;
 wood wool, 112.
 Dressings, antiseptic, 107; aseptic, 107;
 change of, after operation, 118; pro-
 tective, 107.
 Dry stretching of nerves, 272.
 Dubrueil's radial-flap method of ampu-
 tation at the wrist joint, 479.
 Duncan's method of neuroplasty, 275.
 Dupuytren's external and internal flap,
 amputation at shoulder joint, 488.
 Dupuytren's contraction, 351; Adams's
 operation for, 351; Goyraud's opera-
 tion for, 351; Hardie's modification of
 Goyraud's operation for, 351; remarks
 on operations for, 352.
 Dura, closure of, after craniotomy, 314;
 exposure of, in Hartley-Kranse opera-
 tion, 299; opening of, in laminectomy,
 313.
 Dural flap in craniotomy for brain tu-
 mor, 253.
 Duration of drainage, 105.
 Duval's supramalleolar amputation of
 leg, 516.
 Érasme, removal of tongue with, Ba-
 ker, 641.
 Edebolis's method of preparing chroma-
 tized catgut, 90; operating table,
 56.
 Edmunds's stay knot, 84; in ligature of
 the innominate, 162.
 Eiselsberg's osteoplastic amputation of
 leg, 530.
 Elastic bandage, Esmarch's, 69.
 Elastic bandages in shock, 119.
 Elbow joint amputation, 481; anatomical
 points for, 481; anterior single-flap
 method, 482; circular method, 482;
 comments on, 483; results of, 483; ellip-
 tical-flap methods, 481.
 Elbow joint, excision of, 395; Hüter's,
 395; Langenbeck's, 396; Liston's, 397;
 Ollier's, 397; Ollier's, subperiosteal,
 396.
 Electric battery, during operation, 119.
 Electro-cautery, 79.
 Electrolysis in treatment of birthmark,
 224.
 Emergencies, special, during an opera-
 tion, 120.
 Emphysema after wounds of neck, 724.
 Encapsulate brain tumor, treatment of,
 253.
 Encephalocle, 231.
 Endoscope in œsophageal stricture, 674.
 Enemata, high, during shock, 121; of
 saline fluid, 222.
 Engine, surgical, 364.
 Enucleation of astragalus for clubfoot,
 Lund, 449; results, 449.
 Enucleation of goitre, Socin's, 718; com-
 ments on, 718.
 Enucleation resection of goitre, Kocher's,
 717.
 Enteroclysis, 222; during shock, 121.
 Epidural hæmorrhage, 238.
 Epigastric artery, deep, ligature of, 141;
 linear guide to, 141.
 Epilepsy, craniotomy for, 256; operations
 for, 257.
 Epileptics, operations on, 6.
 Erosion of joint, 424.
 Erector spinae, myotomy of, 338.
 Erysipelas, 6.
 Esmarch's amputation of foot, 515; band-
 age in aneurism of the extremities, 206,
 207; elastic bandage, 69; inhaler, 30;
 operation for immobility of inferior
 maxilla, 377; tourniquet for compres-
 sion of abdominal aorta, 541.
 Essential oils, 62.
 Essential requirements relating to opera-
 tions, 9.
 Estlander's method of cheiloplasty of
 lower lip, 607.
 Ether, 23; amount required to produce
 insensibility, 27; as a local anæsthetic,
 36; contra-indications to use of, 24;
 dangers of, 17; during shock, 122; hy-
 podermics of, 14; inflammability of,
 24; in preparation of field of operation,
 95; manner of administering, 27; with
 chloroform, 31.
 Ether anæsthesia, cerebral excitement in,
 24; death-rate in, 22; stages of, 28.
 Ether inhalers, 24.
 Ethereal solution in preparation of field
 of operation, 95.
 Ethyl chloride as a general anæsthetic,
 34; as a local anæsthetic, 36.

- Ethyl bromide as a general anæsthetic, 34.
- Eucain hydrochlorate, 43.
- Eucalyptol, 62.
- Excision of ankle joint, 411; landmarks for, 412; non-subperiosteal, Busch, 413; non-subperiosteal, comments on, 414; results of, 414; subperiosteal, Langenbeck, 412; Vogt's, 413; treatment after, 414.
- Excision of astragalo-scaphoid joint for relief of talipes, Ogston, 449.
- Excision of astragalus, 410; anatomical points for, 410; by double incision, 411; by oval incision, 410; results of, 411.
- Excision of bone, 361; general remarks on, 361; incisions for, 361; instruments employed, 363; in young persons, 362; time for operation of, 362; treatment of wounds after, 365; usefulness of member after, 362.
- Excision of bones of face, 365.
- Excision of bones of forearm, lower extremities of, Bourgary, 400.
- Excision of bones of leg, 416; precautions for, 416.
- Excision of calcaneum, 409; Farabeuf's incision for, 410; remarks on, 410; results of, 410.
- Excision of cervical nerves, posterior divisions of first three, 320; results of, 320.
- Excision of clavicle, 379; entire, 380; in part, 381; precautions for, 381; results of, 381.
- Excision of coccyx, 432.
- Excision of elbow joint, 395; anatomical points for, 395; Hüinter's, 395; Langenbeck's, 396; Liston's, 397; Ollier's, 397; subperiosteal, 396; remarks on, 397; results, 399; treatment after, 398.
- Excision of external carotid artery, Dabarn's, 209; comments on, 210; results, 211.
- Excision of great trochanter, 425.
- Excision of hip joint, 425; anatomical points for, 425; Barker's, 428; conservative subperiosteal operation of, Langenbeck's, 427; Farabeuf's, 428; general remarks on, 429; methods of, 426; radical operation, White's, 426; results of, 430; Sayre's, 429; treatment after, 430.
- Excision of humerus, 384; anatomical points for, 384; complete, 395; head of, 388; lower extremity of, 394; partial, 387; results of, 395; shaft of, 394; subperiosteal, of head, 387; treatment after, 395; upper end, 385; upper end, MacCormac's posterior incision for, 386; upper end, oblique incision for, 385; upper end, through Langenbeck's vertical incision, 385; upper end, through posterior incision, 387.
- Excision of knee joint, 416; anatomical points for, 417; by transverse incision, Bird's, 419; fixation of bones after, 422; König's method of fixing bones after, 423; non-subperiosteal, Mackenzie, 418; subperiosteal, Langenbeck's, 420; subperiosteal, Ollier's, 421; remarks on, 421; results of, 423; treatment after, 423.
- Excision of lower jaw, 373; alveolar process of, 376; anatomical considerations for, 373; central portion of, 374; complete, 376; condyle of, 378; incisions for, 374; lateral portion of, 375; remarks on, 374; results of, 377; treatment after, 377.
- Excision of metacarpo-phalangeal joints, 407.
- Excision of metatarso-phalangeal joint of great toe, 408.
- Excision of metatarso-phalangeal joints, 408.
- Excision of meningocele, 230, 318; precautions for, 230; results of, 231, 318.
- Excision of patella, 425; precautions in, 425; results of, 425.
- Excision of phalangeal joints of, 407.
- Excision of radius, 399; results of, 400.
- Excision of scapula, 381; acromion process of, 382; angles of, 383; body of, 382; complete, 381; complete, Ferguson's method of, 382; glenoid angle of, 383; glenoid angle of, MacCormac's, 382; glenoid angle of, Pollock's, 382; remarks on, 384; results of, 384; Spence's, 382; subperiosteal, 383; treatment after, 384.
- Excision of shoulder joint from behind, Kocher's, 390; comments on, 391.
- Excision of the sternum, 379; results of, 379.
- Excision of superior maxillæ, simultaneous, 372; results, 373.
- Excision of the sympathetic for exophthalmic goitre, Jaboulay and Jonnesco's, 721.
- Excision of tarso-metatarsal joints, 408; remarks on, 408.
- Excision of tongue, methods of, 635; "V"-shaped incision for, 635.
- Excision of tonsil, 633.
- Excision of ulna, 399; results of, 400.
- Excision of upper jaw, 365; below floor of orbit with median incision, 369; below infraorbital foramen, extra buccal method, 371; below infraorbital foramen, intrabuccal method, 371; complete, 367; complete, anatomical considerations for, 367; complete with median incision, 368; Ferguson's incision for, 368; Gensoul's incision for, 368; Langenbeck's incision for, 368; lines of incision for, 367; Liston's incision for, 368; Lizar's incision for, 367; partial, 371; remarks on, 365; results of, 373; subperiosteal, 370; through intra-

- buccal incisions, 370; treatment after, 372; Velpeau's incision for, 368.
- Excision of varicose veins, 217.
- Excision of wrist joint, 400; comments on, 404; complete subperiosteal, Langenbeck's, 402; complete subperiosteal, Lister's, 404; complete subperiosteal, Ollier's, 403; important considerations for, 400; precautions for, 405; results of, 406; treatment after, 405.
- Excision, treatment of spina bifida by, 318.
- Excisions of lower extremities, 407.
- Excisions of phalangeal joints of tarsus, 407.
- Excisions of upper extremity, 384.
- Exophthalmic goitre, excision of sympathetic for, Jaboulay and Jonnesco's, 721.
- Exothyropexy, Jaboulay's, 721.
- Exploration of brain for pus, 258; for tumor, 253.
- Extemporized retractors, 129.
- Extensor, brevis pollicis, tenotomy of, 331; communis digitorum, tenotomy of, 331; longus digitorum, tenotomy of, 335; longus pollicis, tenotomy of, 331; ossis metacarpo pollicis, tenotomy of, 331; proprius hallucis, tenotomy of, 335.
- External carotid artery, ligature of, 194.
- External or facial route to inferior dental nerve, 286.
- Extirpation of aneurism, 202; of the extremities, 206.
- Extrabuccal, operation on buccal nerve, Zuckerkandl's, 290; route to lingual nerve, 289.
- Extract, suprarenal, as an hæmostatic, 66.
- Extraperitoneal ligature of the common iliac artery, 133; of internal iliac artery, 136.
- Fabrics, textile, sterilization of, 112.
- Face, excision of bones of, 365.
- Facial artery, anatomical points of, 200; guides to, 200; ligature of, 200.
- Facial nerve, 307; bony guides to, 307; exposure of, behind pina, Baum's, 307; stretching, 307; stretching, results of, 310.
- Facial nerves in opening the mastoid antrum, 264.
- Facial paralysis, extracerebral origin, operation for, Cushing's, 310; remarks on operation for, 311.
- Facial route to inferior dental nerve, 286.
- False joint, formation of, at hip, 437.
- False teeth, removal of, before anæsthesia, 11.
- Farabeuf's amputation of leg at upper third, 521; amputation of thigh, long anterior and short posterior flap method, 537; excision of hip joint, 428; forceps, 465; incision for excision of os calcis, 410; internal plantar-flap method of amputation for great or little toes, 409; modification of Carden's amputation of thigh through condyles, 529.
- Fascia, division of, 127; division of contracted, 352; palmar, 350; plantar, 349.
- Fasciæ, important, 349.
- Fasciatome, 349.
- Fauces and tonsil, anatomical points of, 644.
- Fauces, pillar, tumor of, and of tonsil, removal of, 644.
- Feeding after intubation of larynx, 697.
- Femoral artery, anatomical points of, 142; digital compression of, 540; ligature of, 142; points for ligature of, 143; common, ligature of, 143; common, relations of, 142; deep, ligature of, 148; deep, relation to femur, 148; superficial, anatomical points of, 145; superficial, ligature of, 145; superficial, relations of, 142.
- Femoral vein, results of ligature of, 215.
- Femur, division of neck of, Volkmann's, 437; division of neck of, with osteotome, 437; intertrochanteric osteotomy of, Sayre's modification of Barton's, 438; intertrochanteric osteotomy of, Volkmann's, 438; neck of, subcutaneous division of, Adams's, 436; osteotomy of shaft of, Gant's, 438; treatment of, after osteotomy, 439.
- Fergusson's incision for complete excision of upper jaw, 368; lion-jawed forceps, 465; method of excision of scapula, 382; method of uranoplasty, 625, 626; method of uranoplasty, cases suitable for, 628; method of uranoplasty, remarks on, 628; method of uranoplasty, treatment after, 628; modification of Pirogoff's amputation of foot, 513; operation for varicose veins, 218.
- Fergusson-Webber's incision for raising the superior maxilla, 660.
- Field of operation, preparation of, 94.
- Finger, amputation at first phalanx, 469; amputation at second phalanx, 470; index, amputation of, at carpo-metacarpal articulation, 473; little, amputation of, at carpo-metacarpal articulation, 473; stalls, rubber, 115; supernumerary, 563.
- Fingers, amputations of, 469; webbed, 563.
- Fissure, intra-parietal, 249; longitudinal, 248; parieto-occipital, 248; precentral or vertical temporal, 249; of Rolando, 246; of Rolando, location of, by Chiene's method, 247; of Sylvius, 247; subfrontal, 249; superfrontal, 249; transverse, 248.
- Fistula, salivary, 632; Agnew's operation for, 632; Deguise's operation for, 633; Desault's operation for, 632; Richelot's operation for, 633; Van Buren's operation for, 632.

- Flap, amputation, elliptical, 481; dural, in craniotomy for brain tumor, 253; for rhinoplasty, 588; for rhinoplasty, Keegan's, 589; for rhinoplasty, Langenbeck's, 589; for rhinoplasty, pyriform, of Dieffenbach, 589; for rhinoplasty, triangular, 588; osteoplastic, in laminectomy, 315; of soft parts, in craniotomy for cerebellar tumor, 256; size of, in plastic surgery, 569.
- Flaps, Agnew's method of forming, in thigh amputations, 535.
- Flaps, amputation, circular, 453; comparative merits of different forms of, 453, 459; cutaneous, 452; double, 472; equilateral, 458; hood, 458; lateral, 472; Lister's rule for length of, 458; methods of making, 453; mixed double, Sédillot, 457; modified circular, 456; musculo-cutaneous, 452; oval or racket, 456; periosteal, 452, 459; rectangular, Teale's, 458; semilunar, Liston's, 456; single, 456.
- Flaps, bone, in craniotomy, 251; classification of, in amputations, 452; dependent as a means of drainage, 105; length of, in amputation, 451; methods of transfer of, in plastic surgery, 571; migratory, in plastic surgery, 571; nutritive integrity of, after amputation, 452; osteoplastic, 530; osteoplastic, in uranoplasty, 625.
- Flaps, transfer of, in plastic surgery, 571; by grafting, 575; by inversion and eversion, 574; by jumping, 574; by sliding in a curved line, 572; by sliding in a direct line, 571; by Tagliacotian method, 574.
- Fletcher's aneurism needle, 130.
- Flexor carpi, radialis, tenotomy of, 331; ulnaris, tenotomy of, 331.
- Flexor longus digitorum, tenotomy of, 332; precautions in tenotomy of, 333.
- Flexor longus pollicis, tenotomy of, 333.
- Flexor profundus digitorum, tenotomy of, 331.
- Flexor sublimis digitorum, tenotomy of, 331.
- Floss silk stay knot, 84.
- Fluhrer's probe, 267.
- Focal epilepsy, results of operations for, 257.
- Food, after anæsthesia, 21.
- Foot, amputation of, Bruns's, 515; Es-march's modification of Le Fort's, 515; Ferguson's modification of Pirogoff's, 513; Le Fort's modification of Pirogoff's, 514; Pirogoff's, 512; Pirogoff's, remarks on and results of, 513; results of, 515.
- Forbes's modification of Chopart's amputation at mediotarsal joint, 505.
- Forceps, 77; bone-cutting, Liston's, 465; bone-holding, 364; bone, in dislocation and fracture of humerus, 392; Ferguson's lion-jawed, 465; Farabeuf's, 465; for correction of deviation of septum nasi, 661; Hofmann's bone-cutting, 242; needle, 99; throat, 664; thumb, 46, 129; thumb, with claw bite, 47; thumb, mouse tooth, 129; tongue, 13, 119; torsion, 77.
- Forepressure, 78-129.
- Forearm amputation, 479; anatomical points for, 479; circular skin-flap method, 479; comments on, 481; equilateral skin-flap method, 480; Jacobson's posterior flap in, 480; musculo-cutaneous method of, 480; results of, 481.
- Foreign bodies, found within the brain after gunshot wound, 266; in air passages, 698; in air passages, comments on, 699; in air passages, results, 700; in air passages, treatment of, 699; in œsophagus, 664; in œsophagus, intrathoracic portion, 670; in œsophagus, remarks on, 665.
- Foreign body in bronchus, 699; in larynx, 698; in trachea, 698.
- Fork as a retractor, 129.
- Fountain syringe as an irrigator, 108.
- Fowler's inhaler, 26; method of sterilizing catgut, 87; operating table, 55; operation for webbed fingers, 566.
- Fracture of larynx or hyoid bone, 724; of skull, craniotomy for, 231.
- Frazier's method of intracranial division of trifacial nerve, 306.
- French method of rhinoplasty, 580.
- Fresh air during shock, 121.
- Friction knot, 82.
- Frontal sinus, trephining, 265.
- Functions of bones, 356.
- Furueux-Jordan amputation at hip joint, 554.
- Fusiform aneurism, radical cure of, 207.
- Gag, mouth, 119; Denhard's, 285; Good-willie's, 285.
- Galt's trephine, 231.
- Galvano-cautery, 80; in bronchotomy, 690.
- Ganglion, 352; Meckel's, 278; operative methods for cure of, 352.
- Gangrene following ligature of the femoral vein, 215; use of the elastic bandage in, 70.
- Gant's method of osteotomy of shaft of femur, 438.
- "Gas and ether" anæsthesia, death-rate in, 22.
- Gas and ether before chloroform, 34.
- Gas and oxygen anæsthesia, 33.
- Gas before ether, 34.
- Gastrostomy, 671, 673; comments on, 671; instruments for, 671; precautions in, 671.
- Gauze, bichloride, 111; dressing for operation wound, 107; improvised aseptic and antiseptic, 112; iodoform, 110; iodoform, in septic cases, 95; packing, to arrest bleeding, 96; pads, aseptic, 63;

- quality used at Bellevue Hospital, 112; strips for drainage, 106; Thiersch's, 111.
- Gelatin as an hæmostatic, 66.
- General considerations in ligature of arteries, 125; distinction between arteries and veins, 126; guides to arteries, 125; kind of instruments required, 129; modes of ligaturing, 125; opening of sheath of vessels, 127; passage of ligature, 127, 128; position of part, 126; primary incision, 126; selection of site for, 126; tying of ligature, 129.
- General considerations of amputations, 451.
- General considerations of operative surgery, 1; age, 2; diet, 9; nursing, 9; occupation, 3; physical condition, 3; place for operation, 7; relation of surgeon to patient, 1; requirements for operation, 9; sex, 3; sick-room, 8; time for operation, 7.
- General remarks on preparation for operation, 95.
- Gensoul's incision for complete excision of upper jaw, 368.
- Genu valgum, anatomical points for operations for, 442; operations for, 442; osteoarthrotomy for, Chiene's, 444; osteoarthrotomy for, Ogston's, 443; osteoarthrotomy for, Reeves's, 443; osteoarthrotomy for, results of, 444; supracondyloid osteotomy for, Macewen's, 443; supracondyloid osteotomy for, results, 443.
- Genu varum, osteotomy for, 444; osteotomy for, results, 445.
- Gerster's method of tamponing the trachea, 707.
- Gersuny's method of meloplasty, 618.
- Gibney's method of shortening tendo Achillis, 342.
- Gigli-Haertel saw, 243; saw for excision of bone, 364.
- Giraldès's operation for single harelip, 602.
- Girard's operation for diverticula of the œsophagus, 681.
- Girdner's telephone probe, 267.
- Gland, parotid, anatomical points of, 734; contra-indications to extirpation of, 735; extirpation of, 734; results of extirpation of, 737.
- Glands, lymphatic, cervical, incisions for removal of, 728; Hartley's operation on, 730; Johns Hopkins Hospital operation on, Mitchell's, 731; removal of, 727; results of removal of, 733; treatment after removal of, 733; Treves's operation on, 729.
- Gleiss's method of nerve suture, 274.
- Glover's, the, suture, 102.
- Gloves, antiseptic, 114; cotton, 115.
- Gluteal artery, anatomical points of, 136; artery, ligature of, 136; nerve, exposure of, 324.
- Glycosuria after anæsthesia, 21.
- Goitre, anæsthesia for, 716; angular incision for, 714; dangers of operations on, 722; dislocation of the, 712; enucleation of, 717, 718; enucleation-resection of, Kocher's, 717; enucleation-resection of, comments on, 718; enucleation-resection of, precautions in, 718; exophthalmic, excision of sympathetic for, Jaboulay and Jonnesco's, 721; injection of, 721; intrathoracic, removal of, 717; precautions for excision of, 715; recurrent, 720; resection of, Kocher's, 719; treatment of, by ligature of thyroid arteries, 720; Trendelenburg's operation for, 721.
- Goodwillie's mouth gag, 285.
- Gouging of calcaneum, 409; of carious bone, 356; of carious bone, comments on, 356.
- Goyraud's operation for Dupuytren's contraction, 351.
- Gracilis, tenotomy of, 336.
- Grad's method of loosening ligatures, 85.
- Grafting, skin, 575.
- Grant's method of cheiloplasty for lower lip, 606.
- Graves's disease, 721.
- Great toe, amputation of, 498; by internal plantar-flap method, Farabeuf's, 499; by oval-flap method, 499; by square-flap method, 498; first phalanx of, 496, 497; with metatarsal bone, 501; through last phalanx, 497.
- Great toe, excision of metatarso-phalangeal joint of, 408.
- Green soap, confined, in preparation of area for operation, 95; for cleansing the hands, 114.
- Gridiron incision for ligature of external iliac artery, 140.
- Gritti's osteoplastic amputation of thigh, 529.
- Grooved director, 47, 129.
- Gross's artery compressor, 78.
- Guérin's operation for nasal growths, 659.
- Guide, bony, to carotid artery, external, 195; to carotid artery, internal, 196; to lingual artery, 198; to subclavian artery, second and third portions, 172; to temporal artery, 201; to thyroid artery, inferior, 178; to vertebral artery, 175.
- Guide, linear, to abdominal aorta, 130, 131; to axillary artery, first portion, 178; to axillary artery, third portion, 179; to brachial artery, 181; to carotid artery, common, 191; to carotid artery, external, 194; to carotid artery, internal, 196; to dorsalis pedis artery, 153; to epigastric artery, deep, 141; to femoral artery, 143; to gluteal artery, 136; to iliac artery, common, 132, 133; to iliac artery, external, 138; to iliac artery, internal, 135; to mammary artery, internal, 177; to lingual artery, 198; to palmar arches, 190; to peroneal ar-

- tery, 155; to popliteal artery, 149; to pudic artery, internal, 138; to radial artery, 186; to sciatic artery, 137; to subclavian artery, second portion, 174; to subclavian artery, third portion, 171; to tibial artery, posterior, 154; to tibial artery, anterior, 151; to thyroid artery, inferior, 177; to ulnar artery, 188; to vertebral artery, 175.
- Guide, muscular, to axillary artery, first portion, 178; to axillary artery, third portion, 180; to brachial artery, 181; to carotid artery, common, 191; to carotid artery, external, 194; to carotid artery, internal, 196; to dorsalis pedis artery, 153; to facial artery, 200; to femoral artery, 143; to iliac artery, common, 133; to iliac artery, external, 139; to iliac artery, internal, 135; to popliteal artery, 149; to radial artery, 186; to sciatic artery, 137; to subclavian artery, second portion, 174; to subclavian artery, second and third portions, 171; to tibial artery, anterior, 151; to tibial artery, posterior, 154; to ulnar artery, 188; to vertebral artery, 175.
- Guide, to inferior dental nerve, deep, 285; to inferior dental nerve, superficial, 285; to subclavian artery, first portion, left side, 168; to subclavian artery, first portion, right side, 170; to subclavian artery, third portion, jugular vein as a, 172.
- Guides, bony, to facial nerve, 307.
- Guides, to arteries, 125; to innominate artery, 158; to lingual or gustatory nerve, 289; to subclavian artery, 168; to trifacial nerve in intracranial neurotomy, 300.
- Gunshot wounds of the cranium, 266; after-treatment of, 270; foreign bodies found within the brain in, 266; location of bullet in, 267; operation for, 266; removal of bullet after, 268; steps in treatment of, 266.
- Gussenbauer's artificial larynx, 708; method of meloplasty, 617.
- Gustatory nerve, 288; anatomical points of, 288; guides to, 289.
- Guthrie's antero-posterior-flap method of amputation at the hip, 555.
- Guyon's supramalleolar amputation of leg, 516.
- Gyrus, angular (brain), 250.
- Hæmophilia, 6; action of calcium chlorid in, 67.
- Hæmorrhage, after bronchotomy, 691; after complete removal of tongue through mouth, 639; after enucleation of thyroid body, 717; after laminectomy, 311; after removal of tonsil, 633; agents for the control of, 65; arrest of middle meningeal, 239; control of, in excision of upper jaw, 369; during operations on harelip, 598; during operations on tongue, 634; during operations on tongue, Langenbeck's method of controlling, 634; elastic bandage after, 70; epidural, 238; from gunshot wounds of cranium, 266; from pia, arrest of, 241; from pia in craniotomy, 253; from sinuses, 238; in circular craniotomy, 236; in craniotomy for lateral sinus thrombosis, 261; in craniotomy for tumor, 251; indications of progressive, 238; in laryngotomy, 690; in linear craniotomy, 244; in operations on second portion of trifacial nerve, 283; in typhoid fever, Coleman's method of controlling, 66; Keen's method of arresting, in intracranial neurotomy, 299; ligature of third portion of subclavian for, 174; methods for control of, in amputation at hip joint, 540; middle meningeal, 238; secondary, 72, 77; subdural, 238, 240.
- Hæmostatic, artificial, 65; natural, 65; position as an, 68.
- Hæmostatics, artificial, adrenalin chlorid, 66; acupressure, 75; bandages, 68; Buck's pin and carrier, 76; calcium chlorid, 67; cautery, 79; circumclusion, 76; circumferential elastic pressure as an, 242; compresses, graduated, 71; compresses, simple, 71; Davy's lever, 73; digital pressure, 71; Esmarch's elastic bandage, 69; extemporized tourniquet, 72; forceps, 77; forceipressure, 78; gelatin, 66; Gross's compressor, 78; instrumental pressure, 72; ligature, 81; Petit's tourniquet, 72; pins, 76; retroclusion, 76; rubber rings, 70; serre-lines, 77; Simpson's method of acupressure, 75; styptics, 68; suprarenal extract, 66; tenacula, 77, 78; thermic angiotribe, 79; torsion, 76; torsoclusion, 76; Trendelenburg's rod, 74; Wyeth's pins, 75.
- Haertel saw, 243, 364.
- Hagedorn's operation for double complicated harelip, 604; for single harelip, 601.
- Hahn's method of tamponing the trachea, 707.
- Halsted's ligature of subclavian artery, left side, first portion, 170; method of sterilizing and preserving ligatures and sutures, 91; subcuticular suture, 104.
- Halux valgus, 446; cuneiform osteotomy for, 447; linear osteotomy for, 447; removal of head of metatarsal bone for, 447.
- Hamilton's forceps, 77.
- Hammer toe, treatment of, 562.
- Hamstring muscles, tenotomy of, 336.
- Hancock's amputation at the astragalus, 508.
- Hands, method of cleansing, at Johns Hopkins Hospital, 114; method of cleansing for an operation, 114; nascent

- chlorine method of cleansing, 114; preparation of, for an operation, 113.
- Hardie's modification of Goyraud's operation for Dupuytren's contraction, 351.
- Harelip, 596; control of patient during operation for, 596; instruments employed in operation on, 598; operation for, 599; suture, 102; time for operation on, 596.
- Harelip, complicated, 603; management of projecting intermaxillary bone in, 603.
- Harelip, double, 603.
- Harelip, double, complicated, Hagedorn's operation for, 604; operation for, 604; Owen's operation for, 605; results of operations for, 605; treatment after operations for, 605.
- Harelip, single, 600; Dieffenbach's operation, 602; double-flap operation, Malgaigne, 600; Giraldès's operation, 602; Hagedorn's operation, 601; König's operation, 602; Simon's operation, 601; single-flap operation, Mirault's, 600.
- Hartley-Krause method of intracranial neurotomy of the trifacial, 296.
- Hartley's chisel, 298; incision for removal of cervical lymphatic glands, 728; operation upon cervical lymphatic glands.
- Hartmann's rule in opening the mastoid antrum, 264.
- Head, lowering of, in shock, 121; position of, in intracranial neurotomy of the trifacial, Keen's, 299.
- Headache after anæsthesia, 20.
- Heart, aspiration of, 123.
- Heart failure, use of adrenalin in, 67.
- Heat as an antiseptic, 62.
- Heath's method of tying the reef knot, 83.
- Hemp ligatures, 81.
- Hey's amputation of leg, middle third, 520; modification of Lisfranc's tarsometatarsal amputation, 504.
- Hill's method of treating syncope during anæsthesia, 19.
- Hip, arthrotoomy for dislocations at, 431.
- Hip, congenital displacement of, Lorenz's operation for, 440; Lorenz's operation for, remarks on, 440; Lorenz's operation for, results of, 440; Hoffa's operation for, 439; Hoffa's operation for, remarks on, 439; Hoffa's operation for, results of, 440; Hoffa's operation for, treatment after, 439.
- Hip-joint amputation, 540; anterior-racket method, 550; antero-posterior-flap method, Guthrie, 555; bloodless, Senn, 546; circular-flap method, Dieffenbach, 552; control of hæmorrhage in, 73, 540; Furneaux-Jordan method, 554; external-racket method, 549; Lister's modification of external-racket method, 550; Lloyd's method of controlling hæmorrhage in, 545; long anterior and short posterior flap method, Manec, 551; McBurney's method of controlling hæmorrhage in, 545; methods of, 549; results of, 546, 557; shock after, 546; single-flap method, Malgaigne's, 555; Tilden Brown's clamp for controlling hæmorrhage in, 546; tourniquet for control of hæmorrhage in, 540; treatment after, 557; Trendelenburg's rod for controlling hæmorrhage in, 542; Wyeth's method for controlling hæmorrhage in, 542.
- Hip joint, disarticulation at, 540.
- Hip joint, excision of, 425; Barker's, 428; conservative subperiosteal operation, Langenbeck's, 427; Farabeuf's, 428; general remarks on, 429; radical operation, White's, 426; results, 430; Sayre's, 429; treatment after, 430.
- Hoffa's operation for congenital displacement of hip, 439; remarks on, 439; results of, 440; treatment after, 439.
- Hofmann's bone-cutting forceps, 242.
- Holden's maxim, 236.
- HOLDERS, needle, 99.
- Hooks, tension with, before sewing, 99.
- Horsehair, sutures, 98; drainage, 106.
- Horsley's, fissure meter, 246; incision for inferior dental nerve, 287; intradural division of the trifacial nerve, 307; operation for brain tumor, 254; wax, 236.
- Hot water bags during shock, 121.
- Hot water in the arrest of hæmorrhage, 68.
- Hot water mattress, Crile's, 55.
- Housemaid's knee, treatment of, 353.
- Hueter's, method of tendon suturing, 340; oblique incision for excision of upper end of humerus, 385; operation for excision of elbow joint, 395; operation on the tongue, 638.
- Humerus, amputation at surgical neck of, 485; anatomical points for, 485; oval method, Guthrie's, 486; single external-flap method, Farabeuf's, 486.
- Humerus, arthrotoomy for irreducible dislocation of, 391.
- Humerus, excision of, 384; complete, 395; lower extremity of, 394; shaft of, 394; through Langenbeck's vertical incision, 385; upper extremity, 385.
- Humerus, habitual dislocation of, operation for, 393.
- Hunter's canal, femoral artery in, 143.
- Hydrocephalus, acute, 229; results of operation in, 229; chronic, 227; chronic, drainage agents in, 228.
- Hydrogen peroxide, 61; in septic cases, 95.
- Hyoid bone, fracture of, 724.
- Hypertrophy of tongue, 637.
- Hypodermic injections during anæsthesia, 14.
- Hypodermic syringe, 119.
- Hypodermoclysis, 222; in shock, 121.
- Hysterical patients, operations on, 6.
- Ice as an anæsthetic, 36.
- Iliac arteries, common, ligature of, 131; common, relations of, 132; common, linear guide to, 132; deep circumflex,

- ligature of, 142; external, anatomical points of, 138; eternal. gridiron incision in ligature of, 140; external. ligature of, 138: external, linear guide to, 138; external, relations of, 139; internal, ligature of, 135; internal, relations of, 135.
- Immobility of inferior maxilla, 377; division of the neck of the bone for, 378; Esmarch's operation for, 377; excision of condyle for, 378; remarks on excision of condyle for, 379; Rizzoli's operation for, 378.
- Important considerations in treatment of an operation wound, 96.
- Improvised aseptic and antiseptic gauze, 112.
- Incision and ligaturing of varicose veins, 217.
- Incision, forms of, in linear craniotomy, 242; Phelps's open, for talipes equino tarus, 448; Phelps's open, for talipes equino-varus, results, 449; primary, in ligature of arteries, 126; primary, in ligature of internal iliac, 135.
- Incisions, for buccal nerve, 290; varieties of, 49.
- Inclined plane, portable, 56; improvised, 56.
- Indian operation of rhinoplasty, 586.
- Infected tissue, drainage of, 105.
- Infection from sponges, 62.
- Inferior dental nerve, 284; exposure of, 285; exposure of, in dental canal, 288; external or facial route to, 286; comments on operation on, 286; guides to, 285, 286; Horsley's incision for, 287; internal or buccal route to, 285; Keen's incision for, 287; Kühn's incision for, 287; Lühart's incision for, 287; Lücke's incision for, 287; operation on, 285; precautions in operation on, 286.
- Inferior maxilla, immobility of, 377.
- Infiltration, anæsthesia, Schleich's method, 38; intraneural, 38; method of introducing fluid, 39; regional paraneural, 38.
- Infraorbital nerve, operations on, 277.
- Infusion, arterial, 223; venous, 220; venous, amount of solution introduced in, 221.
- Ingrown toe-nail, 567; Anger's operation for, 567; Cotting's operation for, 568; results of operation for, 568.
- Inhaler, Allis's, 25; Bennett's, 28-33; Clover's, 26; Esmarch's, 30; Fowler's, 26; Junker's, 30; Ormsby's, 27; Skinner's, 30.
- Inhalers, chloroform, 30; ether, 24.
- Injection, of a meningocele, 230; of birth-marks with ergot, 224; of hot water into vascular growths (Wyeth), 226; of hot water into vascular growths, remarks on, 226; of hot water into vascular growths, results of, 226; of iodine solution into the ventricles, 228; of saline solution into the ventricles, 228; of saline solutions, 221; of varicose veins, 216; of varicose veins, results, 216.
- Innominate artery, anatomical points of, 158; guides to, 158; ligature of, 158; relations of, 158.
- Inorganic ligatures, 81; sutures, 97.
- Iusanc, craniotomy for general paralysis of, 261; operations on, 6; tapping ventricles for general paralysis of, 261.
- Insanity after anæsthesia, 21.
- Instrumental pressure as an hæmostatic, 72.
- Instruments, 44; action of sodium carbonate on, 62; construction and finish of, 44; cutting, estimation of quality of, 44; in general use, 44, 45; for special purposes, 44; necessary for operations, 44; sterilization of, 112, 152; preparation of, for an operation, 113; receptacles for, 51; selection of, 44; solutions suitable for, 52; required to ligature arteries in continuity, 129.
- Integumentary flaps, amputation, 452.
- Internal carotid artery, 196; iliac artery, ligature of, 135; mammary artery, anatomical points of, 177; mammary artery, ligature of, 177; mammary artery, linear guide to, 177; or buccal route to inferior dental nerve, 285; pudic artery, anatomical points of, 138; pudic artery, ligature of, 137.
- Interrupted suture, 101; removal of, 102.
- Intrabuccal operation on buccal nerve, 290; route to lingual nerve, 289.
- Intracranial neurectomy of trifacial nerve, 295; Abbe's method, 306; complications in, 300; Cushing's method, 303; Doyen's method, 302; Hartley-Krause method, 296; methods of, 295; precautions in, 300; remarks on, 301; results of, 301; Rose's method, 295; sequels of, 301.
- Intraneural infiltration anæsthesia, 38.
- Intraparietal fissure, localizing of, 249.
- Intraspinal division of the roots of spinal nerves, 321; remarks on, 321; results of, 321.
- Intrathoracic goitre, removal of, 717.
- Intravenous injection during shock, 121; use of adrenalin, 67.
- Intubation of larynx, 693; apparatus for, O'Dwyer's, 694; method of, 694; precautions in, 696; results of, 698; treatment after, 697.
- Iodine, injection of, in goitre, Schwartz's, 722; solution, injection of, into ventricles, 228; solutions of, 60.
- Iodoform, 109; objections to use of, 112; pulverized, 109.
- Iodoform and ether, saturated solution of, 61.
- Iodoform gauze, 110; composition of, 111; in septic cases, 95; percentage of iodoform in, 110; preparation of, at Bellevue Hospital, 110; strips for drainage, 106.

- Iodoglycerine solution, injection of, in spina bifida, 317.
- Iodol, 110.
- Iron subsulphate as a styptic, 68.
- Irrigator, fountain syringe as an, 108.
- Isolation ring in cocaine anæsthesia, 38.
- Israel's method of meloplasty, 617; modification of König's operation of osteoplastic rhinoplasty, 591.
- Italian operation of rhinoplasty, 590.
- Jaboulay's excision of the sympathetic for exophthalmic goitre, 721; exothyropexy, 721.
- Jacket of plaster of Paris for curvature of spine, 560.
- Jacksonian epilepsy, results of operations for, 257.
- Jacobson's posterior flap in amputation of forearm, 480.
- Jaeger's method of removal of tongue, 641.
- Jaesche-Dieffenbach method of flap transfer in plastic surgery, 573.
- Jaundice, after anæsthesia, 21.
- Jaw, division of, in removal of tongue, 640; excision of upper, 365.
- Jaw-pry, author's wooden, 14.
- Johns Hopkins Hospital operation on cervical lymphatic glands, Mitchell, 731.
- Joint, ankylosed, Briseinent forcé in, 558.
- Joint, ankle, amputation at, 509; arthrectomy of, Bruns's, 425; excision of, 411; landmarks of, 412.
- Joint, elbow, amputation at, 481; excision of, 395.
- Joint, erosion of, 424.
- Joint, false, formation of, at hip, 437.
- Joint, hip, amputation, 540; anterior racket method, 550; antero-posterior-flap method, Guthrie's, 555; bloodless, Senn's, 546; circular-flap method, Dieffenbach's, 552; control of hæmorrhage in, 540; external-racket method, 549; Furneaux-Jordan method, 554; Lister's modification of external-racket method, 550; Lloyd's method of controlling hæmorrhage in, 545; long anterior and short posterior-flap method, Manec's, 551; McBurney's method of controlling hæmorrhage in, 545; methods of, 549; results, 546, 557; shock after, 546; single-flap method, Malgaigne's, 555; Tilden Brown's clamp for controlling hæmorrhage in, 546; tourniquets for control of hæmorrhage in, 540; treatment after, 557; Wyeth's method of controlling hæmorrhage in, 542.
- Joint, hip, disarticulation at, 540; excision of, 425.
- Joint, knee, amputation, 523; bilateral-flap method of Stephen Smith, 523; circular-flap method, 526; elliptical-incision method, Baudens's, 526; long ante-
- rior- and short posterior-flap method, Pollock's, 527; Stephen Smith's method for gangrenous condition of toes and foot, 525; results, 527.
- Joint, knee, bony ankylosis of, 441; Briseinent forcé for, 558.
- Joint, knee, excision of, 416.
- Joint, knee, osteotomy of, 441-558.
- Joint, medio-tarsal, amputation at, Cho-part's, 504.
- Joint, metatarso-phalangeal, amputations at, 499; excision of, 408; of great toe, excision of, 408.
- Joint, shoulder, amputation at, 486; excision of, 390.
- Joint, wrist, amputation at, 477; excision of, 400.
- Joints, metacarpo-phalangeal, excision of, 407; phalangeal, excision of, 407; phalangeal, of foot, excision of, 407; tarsal, operations on, 408.
- Joints, tarso-metatarsal, amputation at, 502; excision of, 408.
- Jonnesco's excision of the sympathetic for exophthalmic goitre, 721.
- Jordan's amputation at the hip, 554.
- Jugular vein, craniotomy for thrombosis of, 260; external, as a guide to the third portion of the subclavian artery, 172; in ligature of the common carotid artery, 193; results of ligature of, 215.
- Junker's chloroform apparatus, 30.
- Jury mast, Sayre's, 561.
- Jute dressing, 112.
- Kangaroo tendon sutures, 97.
- Keegan's flap for rhinoplasty, 589; operation of rhinoplasty, 589.
- Keen's incision for inferior dental nerve, 287; method of controlling hæmorrhage in intracranial neurectomy, 299; operation of laryngectomy, 704.
- Kemp's treatment of air in veins, 124.
- Knee joint, amputation at, 523; anatomical points for, 524; bilateral-flap method of Stephen Smith, 524; circular-flap method, 526; elliptical-incision method, Baudens's, 526; fallacies of bilateral-flap method, 525; long anterior- and short posterior-flap method, Pollock's, 527; methods of, 524; results of, 527; Stephen Smith's method for gangrene of toes and foot, 525.
- Knee joint, arthrectomy of, 424; briseinent forcé for ankylosis of, 558; bony ankylosis of, 441; bony ankylosis, treatment of, Barton's, 558; cuneiform osteotomy for ankylosis of, 441; disarticulation at, 523; excision of, 416; excision of, by transverse incision, Bird's, 419; linear osteotomy for bony ankylosis of, 441; non-subperiosteal excision of, Mackenzie's, 418; osteotomy for bony ankylosis of, 558; results after excision of, 423; subperiosteal excision of, Langenbeck's, 420; subperi-

- osteal excision of, Ollier's, 421; treatment of, after excision, 423.
- Knife, amputating, the Catlin, 462.
- Knives, amputating, 461; manner of grasping, 462.
- Knots, 82; friction, 82; "granny," 83; reef, 83; square, 83; Staffordshire, 84; stay, of Ballance and Edmunds, 84; surgeon's, 82.
- Knott's conical œsophageal bougies, 674.
- Kocher's complete laryngectomy, 700; excision of shoulder joint, 390; method of removal of tongue, 639; operation for removal of nasal growths, 659; operation of enucleation resection of goitre, 717; operation of partial excision of thyroid body, 711; operation of resection of goitre, 719; operation on second division of trifacial nerve, 281; operation on trifacial nerve at foramen ovale, 292.
- König's method of fixing bones after excision of knee joint, 423; method of preparing catgut, 91; operation of osteoplastic rhinoplasty, 591; operation for single harelip, 602.
- Kraske's method of meloplasty, 618.
- Krause's method of intracranial neurectomy of trifacial nerve, 296; method of skin grafting, 577.
- Kreolin, 61.
- Krönlein's method of locating the middle meningeal artery, 239; operation on trifacial nerve at foramen ovale, 293.
- Kühn's incision for inferior dental nerve, 287.
- Lallemând's method of meloplasty, 618.
- Laminectomy, dangers of, 311; operation of, 312; results of, 316.
- Landmarks, bony, of the skull, 245.
- Lane's method of staphyloplasty, 631.
- Langenbeck's chin-flap method of cheiloplasty of lower lip, 609; circular method of cheiloplasty of lower lip, 608; clamp, 69; excision of head of humerus, 387; excision of hip joint, subperiosteal, 427; excision of elbow joint, subperiosteal, 396; excision of knee joint, subperiosteal, 420; excision of upper end of humerus, vertical incision for, 385; excision of wrist joint, complete subperiosteal, 402; flap for rhinoplasty, 589; hook for tracheotomy, 683; method of amputating, 458; method of controlling hæmorrhage during operations on the tongue, 634; method of uranoplasty, 623; musculo-cutaneous flaps in amputation of arm, 484; operation for removal of nasal growths, maxillary route, 657; operation for removal of nasal growths, nasal route, 655; operation for removal of tongue, 642; operation of rhinoplasty, 582; saw, 433; serre-fine forceps, 78; subperiosteal excision of ankle joint, 412.
- Lannelongue's method of uranoplasty, 625.
- Larrey's oval-flap amputation at the shoulder joint, 491.
- Laryngectomy, 700; general remarks on, 704; Keen's method, 704; complete, Kocher's, 700; complete, Treves's, 701; partial, 703; Perier's method, 706; precautions for and comments on, 708; precautions for partial, 703; remarks on partial, 703; results of, 709; results of complete, 701; results of partial, 704; treatment after, 709; treatment after complete, 701.
- Laryngo-tracheotomy, 689; instruments for, 683; rapid, Saint-Germain's, 689.
- Laryngotomy, 685; during operation, 119; instruments for, 683; preliminary to operations on the tongue, 635.
- Larynx, artificial, 708; fracture of, 724; foreign body in, 698.
- Larynx, intubation of, 693; apparatus for, O'Dwyer's, 694; method of, 694; precautions in, 696; results of, 697; treatment after, 697.
- Lateral sinus, relation of, to mastoid antrum, 262; thrombosis, craniotomy for, 260.
- Latissimus dorsi, tenotomy of, 337; myotomy of, 338.
- Lawrence's method of removal of nasal growths, 655.
- Ledran-Maekenzie method of cheiloplasty of upper lip, 615.
- Lee's amputation of leg at middle third, 521.
- LeFort's modification of Pirogoff's amputation of foot, 514.
- Leg, amputation, at lower third, 516; author's circular, with periosteal flap, 516; Duval's supramalleolar method, 516; Guyon's supramalleolar method, 516; methods of, 516; remarks on author's circular, 517; results, 518, 520; Teale's method, 518; with bilateral flaps, 519; with hood flap, 520; with large posterior flap, 518.
- Leg, amputation, at middle third, 520; large posterior-flap method, Hey's, 520; Lee's modification of Teale's, 521; long external-flap method, 521; results, 521.
- Leg, amputation, at upper third, 521; bilateral-flap or hood-flap method, 523; circular-flap method, 522; large external-flap method, Farabeuf's, 521; results, 523.
- Leg amputation, osteoplastic, Bier and Eiselsberg, 530; treatment after, 523.
- Leg, amputations, 515.
- Leg, excision of bones of, 416.
- Leucocythæmia, 6.
- Lever, Davy's, 73.
- Ligaments, result of traumatism and disease on, 348.
- Ligamentum patellæ, elongation or rupture of, 348.

- Ligature, *en masse*, 96.
- Ligature of abdominal aorta, 130; Cooper's method, 130; Murray's method, 131; results of, 131.
- Ligature of an artery, primary incision for, 126.
- Ligature of arteries, general considerations of, 125; in continuity, 125.
- Ligature of axillary artery, 178; first portion, 178, 179; first portion, fallacies and results of, 179; second portion, 179; third portion, 179; third portion, fallacies and results of, 180; three points for, 178.
- Ligature of brachial artery, 180; fallacies of, 183; results of, 185.
- Ligature of carotid arteries, common, both, 193; results, 193.
- Ligature of carotid artery, common, 191; above omohyoid bone, 192; below omohyoid bone, 192; fallacies of, 193; for hemorrhage of its divisions, 193; temporary, 194; three points for, 192; results, 193.
- Ligature of carotid artery, external, 194; above digastric muscle, 196; below digastric muscle, 195; precautions and fallacies of, below digastric muscle, 195; results, 196; situations for, 195.
- Ligature of carotid artery, internal, 196; fallacies of, 197; point of election for, 196; results, 196.
- Ligature of the external circumflex artery, 148.
- Ligature of dorsalis pedis artery, 153; of dorsalis pedis, fallacy of, 153.
- Ligature of dorsalis penis artery, 138.
- Ligature of deep epigastric artery, 141.
- Ligature of facial artery, 200; at angle of mouth, 201; at ramus of jaw, 200; fallacies in, 201; in neck, 200; three situations for, 200.
- Ligature of femoral artery, 142; at apex of Scarpa's triangle, 143; below Poupert's ligament, 143; common, 143; common, danger of, 143; deep (*profunda*), 148; deep, fallacies in, 148; fallacies in, 146; in Hunter's canal, 143; superficial, 145; results, 148.
- Ligature of femoral vein, 215; gangrene following, 215; lateral, 215.
- Ligature of gluteal artery, 136; fallacies of, 136; results of, 136.
- Ligature of iliac artery, common, 131; extraperitoneal, 133; extraperitoneal, dangers and fallacies of, 134; results, 133, 135; transperitoneal, 12.
- Ligature of iliac artery, deep circumflex, 142; at internal abdominal ring, 142; at superior spinous process of ilium, 142.
- Ligature of iliac artery, external, 138; extraperitoneal, 139; fallacies in, 140; gridiron incision for, 140; results, 140; transperitoneal, 140.
- Ligature of iliac artery, internal, 135; extraperitoneal, 136; transperitoneal, 135.
- Ligature of the innominate artery, 158, 161; Ballance and Edmunds stay knot in, 162; Bardenheuer's method, 161; Cooper's method of, 162; Curtis's method of, 164; drainage in, 168; fallacies in, 167; general remarks on, 167; Kocher's incision for, 159; material used for ligature in, 167; Milton's method, 164; Mott's incision for, 158; number of ligatures in, 167; results, 168; splitting the manubrium in, 163; with resection of sterno-clavicular articulation and upper end of sternum, Burrell's, 160; with stay knot, 84.
- Ligature of internal mammary artery, 177.
- Ligature of jugular vein, external, 215; internal, lateral, 215; internal, results, 215.
- Ligature of lingual artery, 197; at apex of greater cornu, 198; at point of election, 199; between greater cornu and posterior belly of digastric, 198; in triangle made by the digastric and mylohyoid muscles and hypoglossal nerves, 199; results, 200; three situations for, 198.
- Ligature of meningocele, 230.
- Ligature of middle meningeal artery, 214.
- Ligature of occipital artery, 201; at origin, 202; behind mastoid process, 202.
- Ligature of palmar arches, 190.
- Ligature of peroneal artery, 155; fallacies of, 158.
- Ligature of popliteal artery, 149; lower third, 150; middle third, 149; upper third, 150; results, 150.
- Ligature of pudic, internal, artery, 137.
- Ligature of radial artery, 185; at apex of styloid process, 187; fallacies in, 188; lower third, 187; results, 188; upper third, 186.
- Ligature of saphenous vein, internal, for varicose veins, Trendelenburg, 217.
- Ligature of sciatic artery, 136; fallacies of, 137; results of, 137.
- Ligature of subclavian artery, 168; first portion, left side, 168, 169; first portion, left side, results, 170; first portion, right side, 170; first portion, right side, results, 171; second portion, 174; second portion, results, 174; third portion, 171, 172; third portion, results, 174.
- Ligature of subclavian vein, lateral, 215.
- Ligature of temporal artery, 201.
- Ligature of thyroid artery, inferior, 177, 178; inferior, fallacies and results of, 178; superior, 197.
- Ligature of tibial artery, anterior, 150; fallacies of, 152; lower third, 152; middle third, 151; upper third, 151.
- Ligature of tibial artery, posterior, 153; between os calcis and internal malleo-

- lus, 155; fallacies, 155; lower third, 154; middle third, 154.
- Ligature of ulnar artery, 188; at junction of upper and middle thirds, 189; at wrist, 189; fallacies, 189; lower third, 189; results, 190.
- Ligature of varicose veins, subcutaneous, 216; needle for, 217; precautions in, 217; results of, 217.
- Ligature of veins, 215; at extremities, 215; in continuity, 215; materials for, 215.
- Ligature of vertebral artery, 174; before entering vertebral canal, 175; between atlas and axis, 176; between atlas and occipital bone, 177; fallacy, 177; results, 177.
- Ligature, selection of vessel for, 126.
- Ligatures, 129; as hæmostatics, 81; catgut, 86; force necessary to tie, 81; Grad's method of loosening, 85; materials for, 85; method of application of, 82; of aortic tissue, 93; of whalebone tissue, 93; silk, 85; size of, 81.
- Ligaturing, subcutaneous, of a nævus, 224.
- Lignerolles's subastragaloid amputation, 507.
- Linear craniotomy for microcephalus, 241; dangers of, 244; forms of bone incision in, 242; removal of areas of bone in, 243; results of, 244; the operation of, 242.
- Linear guide to abdominal aorta, 130, 131; to an artery, 125; to axillary artery, first portion, 178; to axillary artery, third portion, 179; to brachial artery, 181; to carotid artery, common, 191; to carotid artery, external, 195; to carotid artery, internal, 196, 197; to dorsalis pedis artery, 153; to epigastric artery, deep, 141; to femoral artery, 143; to gluteal artery, 136; to iliac artery, 132; to iliac artery, common, 133; to iliac artery, external, 138; to iliac artery, internal, 135; to innominate artery, 158; to internal mammary artery, 177; to lingual artery, 198; to palmar arches, 190; to peroneal artery, 155; to popliteal artery, 149; to pudic artery, internal, 138; to radial artery, 186; to sciatic artery, 137; to subclavian artery, second portion, 174; to subclavian artery, third portion, 171; to thyroid artery, inferior, 177; to tibial artery, anterior, 151; to tibial artery, posterior, 154; to ulnar artery, 188; to vertebral artery, 175.
- Linear osteotomy, 433.
- Linear semilunaris as a guide to the iliac artery, 132.
- Lingual artery, anatomical points of, 197, 199; guides to, 198; ligature of, 197.
- Lingual nerve (gustatory), 288; anatomical points of, 288; extrabuccal operation on, 289; guides to, 289; intrabuccal operation on, 289; routes to, 289.
- Lion-jawed forceps, Fergusson's, 465.
- Lip, lower, cheiloplasty of, 605; Blasius's method, 606; Bruns's method, 608; Buck's method, 609; Celsus's method, 607; Dowd's method, 611; Estlander's method, 607; Grant's method, 606; horizontal incision method, 606; Langenbeck's chin-flap method, 609; Langenbeck's circular-method, 608; Sédillot's method, 611; Syme-Buchanan method, 609; Syme's method, 609; "V"-incision method, 605; Malgaigne's method, 610.
- Lip, upper, deformities of, 612.
- Lip, upper, cheiloplasty of, 612; Bruns's method of, 612; Buck's intero-lateral-flap method, 612; Buck's semicircular vertical-flap method, 613; Dieffenback's curved-flap method, 614; Dieffenbach's "S"-shaped-flap method, 614; for entire loss of upper lip, 613; Ledran-Mackenzie method, 615; Sédillot's vertical-flap method, 613; Szymanowski's method, 614.
- Lisfranc's amputation at the tarso-metatarsal joints, 502.
- Lister's complete subperiosteal excision of wrist joint, 404; modification of Carden's amputation of thigh through condyles, 528; rule for length of amputation flaps, 458; tourniquet for compressing abdominal aorta, 541.
- Liston's bone-cutting forceps, 465; forceps, 77; semilunar flap, method of amputation, 456; incision for complete excision of upper jaw, 368.
- Littenneur's method of flap transfer in plastic surgery, 573.
- Lizar's outer incision for complete excision of the upper jaw, 367.
- Lloyd's method of controlling hæmorrhage in amputation at the hip joint, 545.
- Local anaesthesia, 36; Gonka's method of, 40; indications for, 40.
- Local anaesthetics, 36; Beta eucain, 43; chloride of ethyl, 36; cocain, 37; ether, 36; eucain, 43; ice, 36; introduction into skin of sterilized fluids, 36; tropococain, 40.
- Longitudinal fissure (brain), 248.
- Loops, traction, 129, 130.
- Lorenz's operation for congenital displacement of hip, 440; remarks on, 440; results of, 440.
- Lösse's operation on second portion of trifacial nerve, 284.
- Lower extremities, excisions of, 407.
- Lower extremity, duty of surgeon in amputations at, 496.
- Lower jaw, excision of, 373; excision of condyle of, 378; phosphoric necrosis of, 374.
- Lücke's incision for inferior dental nerve, 287; operation on second division of trifacial nerve, 284.

- Ludwig's angina, 725.
 Lumbar plexus, operations on, 327.
 Lumbar puncture for acute hydrocephalus, 229.
 Lund's enucleation of astragalus for club-foot, 449.
 Lungs, examination after operation, 118.
 Lusk's (Z. J.) method of skin-grafting, 577.
 Lymphatic glands, cervical, Hartley's operation on, 730; incisions for removal of, 728; Johns Hopkins Hospital operation on, Mitchell, 731; results of removal of, 733; removal of, 727; treatment after removal of, 733; Treves's operation on, 729.
- MacCormac's method of excision of scapula, 382; method of treating displacement of the ulnar nerve, 324; posterior incision for excision of upper end of humerus, 386.
 Macewen's operation for brain tumor, 254; supracondyloid osteotomy for genu valgum, 443.
 Mackenzie's method of cheiloplasty of upper lip, 615; non-subperiosteal excision of knee joint, 418; tonsillotome, 633.
 Malaria, 6.
 Malgaigne's double-flap operation for single harelip, 600; method of cheiloplasty for lower lip, 610; single-flap method of amputation at the hip, 555.
 Malignant disease, removal of associated structures in, 377.
 Malignant growth of clavicle, operation for, 380.
 Mallet finger, 562.
 Mallet for osteotomy, 435.
 Manec's long anterior- and short posterior-flap method of hip amputation, 551.
 Martin's bandage, 70; operation for deformity of nose, 593; platinum support for deformities of nose, 592.
 Mastoid antrum, opening of, 262; operation of opening, 264; precautions for operation of opening, 265; results of operation for opening, 265.
 Mastoid cells, 264.
 Mastoid process, in the adult, 262; in the infant, 262.
 Matas's infiltration anæsthesia apparatus, 39; method of radical cure of aneurism, 207; operation on aneurism, stages of, 202.
 Materials necessary for treatment of operation wounds, 96.
 Mathieu's tonsillotome, 633.
 Mattress, Crile's hot water, 55.
 Maxilla inferior, immobility of, 377.
 Maxille, superior, simultaneous removal of, 372.
 McBurney's hook in dislocation and fracture of humerus, 392; method of controlling hæmorrhage in amputation at hip joint, 545; tension hooks, 576.
- Meckel's ganglion, 278.
 Median nerve, relation of, to brachial artery, 183; situations for exposure of, 324.
 Medicated cotton, 108.
 Medio-tarsal joint, amputation, Chopart's, 504; Forbes's modification of Chopart's, 505; remarks on and results of Chopart's, 505.
 Melon-seed concretions of thecitis, 354.
 Meloplasty, 616; Gersuny's method, 618; Gussenbauer's method, 617; Israel's method, 617; Kraske's method, 618; Lallemand's method, 618; remarks on, 618; Trendelenburg's method, 617.
 Meningeal artery, middle, 237; ligature of, 214.
 Meningeal drainage, spinal, 316.
 Meningeal hæmorrhage, craniotomy for, 238.
 Meningitis after craniotomy, 244.
 Meningocele, 229; excision of, 230, 318; injection of, 230; ligature of, 230; operative measures for, 229; puncture and tapping of, 230.
 Meningo-myelocele, result of operation on, 319; treatment of, 318.
 Mercury biniodide, solutions of, 60.
 Metacarpal bones, amputation of four, with fingers, 476; of inner three, 476; of last four, 475; of last two, 476; through, 475.
 Metacarpophalangeal articulation, amputation at, 471; by lateral-flap method, 472; by oval-flap method, 471; of second and third fingers, 471.
 Metacarpophalangeal joints, excision of, 407.
 Metallic sutures, 98.
 Metatarsal bone of second, third or fourth toe, amputation of, 502.
 Metatarsal bones, amputation through, 500.
 Metatarso-phalangeal articulation, amputation of all toes at, 499; comments on and results of, 500.
 Metatarso-phalangeal joint, excision of, 408; of great toe, excision of, 408.
 Microcephalus, linear craniotomy for, 241.
 Middle meningeal artery, 237; arrest of hæmorrhage from, 237; Krönlein's method of locating, 29; ligature of, 214.
 Migratory flaps in plastic surgery, 571.
 Mikulicz's method of pharyngotomy, 646; osteoplastic resection of tarsus, 415.
 Miller's method of preparing catgut, 91.
 Milne's serre-fine forceps, 78.
 Milton's method of ligature of the innominate, 164.
 Miner's elbow, 353.
 Mirault's single-flap operation for single harelip, 600.
 Mitchell's operation on cervical lymphatic glands, 731; remarks on, 732.

- Mittens, antiseptic, 114.
 Mixer's operation on trifacial nerve at base of skull, 293.
 Mollière's tarsal amputation, 506.
 Morbid processes of clavicle, 379.
 Morphiu-cocain-chloroform anæsthesia, 40.
 Morphine with anæsthetics, 35.
 Mortality in gunshot wounds of the cranium, 270.
 Morton's method of inducing spinal anæsthesia, 43.
 Moss dressing, 112.
 "Mother's mark," 223; treatment of, 223; by electrolysis, 224; by freezing and incisions, 223; by heated needles, 224; by injection, 224; by Paquelin cautery, 224.
 Motor center, removal of, for cure of epilepsy, 257.
 Mott's incision for ligation of the innominate artery, 158; retractors, 129.
 Mouse-tooth forceps, 129.
 Mouth, deformities of, 615; operations on, 632.
 Mouth gag, 13, 119; Denhard's, 285; Goodwillie's, 285.
 Movable immovable aneurism needle, 130.
 Moynihan's operation on spontaneous subclavian aneurism, 203.
 Mucous bursæ, 353.
 Mucous surfaces, preparation of, for operation, 95.
 Multifidus spinæ, myotomy of, 337.
 Murray's method of ligaturing abdominal aorta, 131; of preparing catgut, 92.
 Muscle, division of, 347; rupture of, 348.
 Muscles, concerned with staphylorrhaphy, 621; manner of dividing, in amputation, 534; retraction of divided, 455; retraction of, in amputations after removal of Esmarch's bandage, 533; rupture of, 347.
 Muscular action, perverse, as a cause of deformities, 561.
 Muscular guide to an artery, 125; to axillary artery, first portion, 178; to axillary artery, third portion, 180; to brachial artery, 181; to carotid artery, common, 191; to carotid artery, external, 195; to carotid artery, internal, 196; to dorsalis pedis artery, 153; to iliac artery, internal, 135; to facial artery, 200; to femoral artery, 143; to popliteal artery, 149; to radial artery, 186; to sciatic artery, 137; to subclavian artery, first portion, 168, 170; to subclavian artery, second portion, 171, 174; to subclavian artery, third portion, 171; to tibial artery, anterior, 151; to tibial artery, posterior, 154; to ulnar artery, 188; to vertebral artery, 175.
 Muscular guides to subclavian artery, 168.
 Muscular influence in staphylorrhaphy, 621.
 Musculo-cutaneous amputation flaps, 452.
 Musculo-cutaneous nerve, situations for exposure of, 322; operations on, 322.
 Musculo-spinal nerve, operations on, 322.
 Muslin as a dressing, 112.
 Mustard sinapisms during shock, 121.
 Myotome, 337, 347.
 Myotomy, 337, 347; oblique, 347; of deltoid, 348; of erector spinæ, 338; of latissimus dorsi, 338; of multifidus spinæ, 337; of pectineus, 337; of pectoralis major, 348; of sterno-cleido mastoid, 338; of tensor vaginæ femoris, 337; of trapezius, 338; "V"-shaped, 347.
 Nævus, treatment of, by ligature, double, 224, 225; by ligature, single, 224; by ligature, subcutaneous, 224; with setons in, 225.
 Nail, toe, ingrown, operations for, 567; Anger's, 567; Cotting's, 568; results of, 568.
 Nails, preparation of the, for an operation, 113.
 Naphthalin, 110.
 Nares, plugging of posterior, 650.
 Nasal and naso-pharyngeal polypi, operation for, Annandale's, 657; Boeckel's, 657; Chalot's, 656; Chassaignac's, 654; Cheever's, 659; choice of, for removal of, 661; Desprez's, 653; general comments on, 659; Guérin's, 659; instruments for, 653; Kocher's, 659; Langenbeck's, maxillary route, 657; Langenbeck's, maxillary route, comments on, 658; Langenbeck's, nasal route, 655; Lawrence's, 655; nasal route, 653; nasal route, comments on, 655; Nélaton's, 656; Ollier's, 654; palatine route, 656; Rouge's, 654, 655; results, 661; treatment after, 661.
 Nasal growths, operations for, *vide* Nasal and Naso-pharyngeal Polypi, operations for.
 Nasal polypi, removal of, with forceps or snare, 651.
 Nasal septum, deviation of, 661; deviation of, Post's operation for, 662; deviation of, Wagner's operation for, 662.
 Nasal splints, 662.
 Naso-lambdoidal line, Poirier's, 250.
 Naso-pharyngeal polypi, removal of, 653.
 Natural hæmostatics, 65.
 Neck, abscess and phlegmon of, 725; excision of diseased lymphatic glands of, 727; operations on, 681; treatment of wounds of, 724; wounds of, 723.
 Necrosis, of bone, 356; phosphoric, of lower jaw, 374.
 Needle, aneurism, 129; Fletcher's, 130; in ligation of arteries, 127; movable immovable, 130; student's, 130.

- Needle, aneurismal, in amputating, 467.
- Needle, forceps or holders, 99.
- Needle, for subcutaneous ligaturing of varicose veins, 217.
- Needle, heated, for treatment of birth-mark, 224.
- Needle, surgical, 76.
- Needle, Wyeth's, in shoulder-joint amputation, 487.
- Needles, 98.
- Nélaton's operation for removal of nasal growths, 656.
- Neoplasms of the nose, operations for, *vide* Nasal and Naso-pharyngeal Polypi.
- Nephritis after anæsthesia, 21.
- Nerve, auriculo-temporal, 289: auricularis magnus, operation on, 320; avulsion, 272; buccal, exposure of, 290; circumflex, operations on, 323; crural, anterior, operation on, 327; dental, anterior division of, 278; dental inferior, 284; facial exposure of, 307; fifth, supramaxillary division of, 277; gluteal, exposure of, 324; inclusion of, in ligature, 82; infraorbital, operations on, 277; laryngeal, recurrent, dangers to, in operations on thyroid, 722; lingual or gustatory, 288; median exposure of, 324; musculo-cutaneous, situations for exposure of, 322; musculo-spiral, operations on, 322; obturator, exposure of, 327; occipitalis major, 320; perineal, exposure of, 327; popliteal, external, method of reaching, 326; popliteal, internal, method of reaching, 326; pudic, exposure of, 324; radial exposure of, 324; resection, 271; saphenous, external or short, exposure of, 328; saphenous, internal or long, exposure of, 328; section, 271; sciatic, great exposure of, 324; sciatic, small, exposure of, 324; spinal accessory, operation on, 319; stretching, dry, 272; submaxillary, 279; suboccipital, 320; superior maxillary, 278; supraorbital, operations on, 276; supratrochlear, operations on, 277; suture, 272; suture, Gleiss's method, 274; suture, primary, 273; suture, results, 274; suture, secondary, 273; tibial, anterior, exposure of, 327; tibial, posterior, exposure of, 327; trifacial, first division of, operations on, 276; trifacial, second division of, operations on, 277; trifacial, third division of, operations on, 284; ulnar, exposure of, 324; ulnar, displacement of, 324.
- Nerves, cervical, operations on branches of, 320; facial, in opening the mastoid antrum, 264; operations on special, 276; plantar, exposure of, 327; recurrent laryngeal, effect of division of, 730; resection of spinal accessory and posterior divisions of cervical, for wry-neck, 562; severing of, in amputations, 452; spinal, intraspinal division of, 321; spinal, operations on, 311; special operations on, 271; tibial, anterior and posterior, exposure of, 327.
- Nervous guides to an artery, 125.
- Nervous system, operations on, 227.
- Neuber's decalcified tubes for drainage, 106; method of drainage by canalization, 107; method of healing bony defects by canalization, 358.
- Neurectomy, intracranial of trifacial, 295.
- Neuroplasty, 274; Duncan's method, 275.
- Nicoladoni's method of tendon suturing, 340.
- Nitrite of amyl, 119.
- Nitrous oxide, 32; danger of, 17; with oxygen, 33.
- Noma, 616.
- Non-encapsulated brain tumor, treatment of, 254.
- Norton's operation for webbed fingers, 564.
- Nose, angular, 595; deformities of, angular, 592; deformities of, comments on, 593; deformities of, injection of paraffin for, 593; deformities of, Martin's operation for, 593; deformities of, platinum support for, 592; deformities of, saddle-back, 592; deformities of, supports for, 593; disfigurement of, dependent on morbid growths, 596; operations on, 650.
- Nursing, 9.
- Oakum cushion after operation, 118.
- Obturator nerve, exposure of, 327.
- Occipital artery, anatomical points of, 201; ligature of, 201.
- Occipitalis major nerve, operation on, 320.
- Ochsner's method of treating stricture of the œsophagus, 674.
- O'Dwyer's apparatus for intubation of larynx, 694.
- œsophageal bougie, 664; bougie, conical, Knott's, 674; probang, 664.
- œsophagotomy, 678; results of, 678.
- œsophagostomy, 678.
- œsophagotomy, 668; cervical, 668; cervical, falciæ of, 669; cervical, remarks on, 669; cervical, results of, 670; external, 674; internal, 674; instruments for internal, 674; results of internal, 675.
- œsophagus, diverticula of, 678; Girard's operation for, 681; operation for, 679; results of operation on, 681; treatment after operation on, 681.
- œsophagus, foreign bodies in, 663, 667; intrathoracic portion of, 670.
- œsophagus, introduction of instruments into, 665; precautions in and remarks on, 666.
- œsophagus, methods of entering, 668.

- Œsophagus**, operations on, 663; anatomical points for, 663.
- Œsophagus**, stricture of, 672; Abbe's operation for, 675; author's operation for, 676; comments on operations for, 676; dilatation of, 672; division of, 674; division of, by string fiction, 675; external œsophagotomy for, 674; internal œsophagotomy for, 674; malignant, 677; results after operations for, 677; results of tubage in, 678; treatment after operations for, 677; tubage in, 677.
- Œsophagus**, surgical relations of, 668.
- Ogston's excision of astragalo-scapoid joint for relief of talipes**, 449; osteoarthrotomy for genu valgum, 443.
- Oil of camphor during shock**, 121.
- Oiled silk as a dressing**, 107.
- Oils**, essential, 62.
- Ollier's excision of knee joint, subperiosteal**, 421; excision of humerus, upper end, oblique incision, 385; excision of scapula, subperiosteal, 383; excision of wrist joint, complete, subperiosteal, 403; operation for removal of nasal and naso-pharyngeal polypi, 654; operation of osteoplastic rhinoplasty, 590.
- Oozing**, from operation-wounds, 96.
- Open dressing**, after operation, 118.
- Operating cases and bags**, 45.
- Operating-room**, temperature of, 130.
- Operating table**, 53, 113; characteristics of a good, 54; Cleveland's, 54; Edebohl's, 56; extemporized, 53; Fowler's, 55; inclined plane for use in conjunction with, 56; portable, 56; Pryor's, 56; preparation of, 53.
- Operation**, disposition of assistants at, 93; care of patient after, 118; change of dressings after, 118; consent of patient to, 6; emergencies during, special, 120; number of assistants necessary for, 93; nurse at, 94; place for, 7; preparation for, general remarks on, 95; preparation for, of septic parts, 95; preparation for, summary, 113; preparation of field of, 94; preparation of mucous surfaces for, 95; preparation of patient for, 94; preparatory treatment for, 7; relation of, shock to, 120; rehearsal of steps of, by surgeon, 119; relation of things necessary to, 93; requirements for, essential, 9; requirements for, precautionary, 119; time for, 7.
- Operations**, after reaction from shock, 4; complications of, 5; cosmetic effects of, 2; diet after, 9; during shock, 4; facts to be considered prior to, 2, 6; in old age, 2; in youth, 2; instruments necessary for, 44; nursing after, 9; on alcoholics, 6; on arteries, special, 202; on athletics, 3; on bones, 356; on diabetics, 5; on genito-urinary organs, anæsthesia in, 16; on hæmophiliacs, 6; on mouth, anæsthesia in, 16; on nervous system, 227; on obese, 3; on plethoric, 3; on rectum, anæsthesia in, 16; on semi-invalids, 3; on tendons, ligaments, fascias, muscles and bursæ, 329; on veins and capillaries, 215; on women, 3; preparation of room for, 8; requirements, relating to, essential, 9; requirements, relating to, precautionary, 9; risks of, 2; supervision of shock during, 4.
- Operation-wound**, drainage of, 104; dressing of, 107; treatment of, 96.
- Operative propriety**, 10.
- Operative surgery**, general considerations of, 1.
- Operator**, preparation of, 113.
- Oral screw**, 14.
- Organic ligatures**, 81; sutures, 97.
- Ormsby's inhaler**, 27.
- Os calcis**, amputation through, Tripiet's, 508.
- Ossification**, periods of, in calcaneum, importance of a knowledge of, 408.
- Osteoarthrotomy for genu valgum**, Chiene's, 444; Ogston's, 443; Reeves's, 443; results, 444.
- Osteoplastic amputation of leg**, Bier's and Eiselsberg's, 530.
- Osteoplastic amputation of thigh**, Gritti's method, 529; results, 530; Sabanejeff's method, 532; Stokes's modification of Gritti's method, 529.
- Osteoplastic flaps**, 530; in laminectomy, 315; in uranoplasty, 625.
- Osteoplastic rhinoplasty**, 590; Israel's modification of König's operation, 591; König's operation, 591; Ollier's operation, 590; Pancoast's subcutaneous, 592.
- Osteoplastic resection of tarsus**, Wladimirov-Mikulicz method, 415; results, 416.
- Osteoplasty**, 450.
- Osteotome**, 435.
- Osteotomy**, 432; comments on operation of, 435; methods of, 433; instruments for, 433.
- Osteotomy at neck of femur**, Volkman's, 437; Volkman's, results, 438; with osteotome, 437; with osteotome, remarks on, 437.
- Osteotomy, cuneiform**, for bony ankylosis of knee, 441; for bony ankylosis of knee, Barton's, 441; for genu varum, 446; for relief of talipes, Bird's, 449; for relief of talipes, Stokes's, 449; intertrochanteric, of femur, Volkman's, 438; intertrochanteric of femur, results, 438; of tarsus for talipes equinovarus, Davies-Colly, 447; of tarsus for talipes equinovarus, results, 448.
- Osteotomy for ankylosis of knee**, general remarks on, 442.
- Osteotomy for genu varum**, 444; of tibia, 445; results, 445, 446; treatment after, 446.
- Osteotomy for talipes**, 447.

- Osteotomy, intertrochanteric, of femur. Sayre's modification of Barton's, 438; results, 438.
- Osteotomy, linear, for bony ankylosis at knee, 441; for genu varum, 445; of neck of astragalus for talipes equinovarus, Bradford's, 448; of neck of astragalus for talipes equinovarus, results, 448.
- Osteotomy of femur, intertrochanteric, 438; shaft of, Gaut's, 438; shaft of, remarks on, 439; neck of, subcutaneous, Adams's, 436; neck of, subcutaneous, remarks and results, 437; supracondyloid, for genu valgum, Macewen's, 443; supracondyloid for genu valgum, results, 443; treatment after, 439.
- Otitis media, as a cause of cerebral abscess, 258.
- Owen's operation for complicated double harelip, 605.
- Oxalic acid in cleansing the hands, 114.
- Oxygen, administration of, during anæsthesia, 35; during shock, 121.
- Packing after removal of brain tumor, 254.
- Pads, of aseptic gauze, 63; use of, in serous cavities, 64.
- Pain, due to inclusion of nerve in ligature, 82.
- Palate, closure of opening in, by mechanical means, 630; hard, fissure in, 623; soft, abnormal opening in, 620; operations on, 618; operations on, instruments for, 620.
- Pallor during shock, 121.
- Palmar arches, ligature of, 190; linear guide, 190; precautions in ligature of, 191; relations of, 190.
- Palmar fascia, 350.
- Pancoast's operation on the trifacial nerve at foramen ovale, 293; subcutaneous operation of osteoplastic rhinoplasty, 592; tourniquet for compressing abdominal aorta, 541.
- Paquelin cautery, 79; in treatment of birthmark, 224.
- Paraffin, injection of, for nasal deformities, 593; dangers of, 595; remarks on, and results of, 595.
- Paralysis, facial, extra cerebral origin, operation for, 310; general, of the insane, craniotomy for, 261.
- Paraneural infiltration anæsthesia, regional, 38.
- Paravincini's operation on inferior dental nerve, 285.
- Parieto-occipital fissure, 248.
- Parker's retractors, 129.
- Parkin's operation of tapping subarachnoid space, 316; results of, 316.
- Parotid gland, anatomical points of, 734; extirpation of, 734; contraindications to extirpation of, 735; results of extirpation of, 737.
- Patella, excision of, 425; precautions in excision of, 425; removal of, in excision of knee joint, 424; results of excision of, 425.
- Patient, care of, after anæsthesia, 21; care of, after operation, 118; considerations relating to, prior to operation, 2, 6; control of, during operation for harelip, 596; coughing and swallowing of, under anæsthesia, 12; effects of iodiform upon, 112; giving fluids to an unconscious, 119; method of restraint of, under anæsthetic, 11; position of, for staphylorrhaphy, 620; preparation of, for craniotomy, 250; preparation of, for plastic surgery, 569; preparation of, for operation, 94, 113; preparation of, for operations on tongue, 635; relation of, to anæsthetist, 15; struggling of, under anæsthetic, 11.
- Peat dressing, 112.
- Pectineus, myotomy of, 337.
- Pectoralis major, myotomy of, 348.
- Pedicles, removal of ligatures from, Grad, 85.
- Perier's method of laryngectomy, 706.
- Perineal nerve, exposure of, 327.
- Periosteal elevator, 465.
- Periosteal flap, amputation, 452.
- Periosteum in young subjects, 377; preservation of, 522; treatment of, in amputations, 452.
- Permanganate of potash in cleansing the hands, 114.
- Peroneal artery, anatomical points of, 155; ligature of, 155; linear guide to, 155.
- Peroneus brevis, tenotomy of, 334; longus, tenotomy of, 334; tertius, tenotomy of, 335.
- Peroxide of hydrogen, 61; in septic cases, 95.
- Petit's tourniquet, 72.
- Petrous portion of temporal bone in cerebral abscess, 260.
- Phalangeal articulations, hand, amputations at, 469; anatomical points for amputation at, 469; remarks on amputations at, 470.
- Phalangeal joints, excision of, 407; of tarsus, excision of, 407.
- Phalanges of toes, amputation of, 496.
- Phalanx, finger, terminal, amputation of, 469.
- Pharyngotomy, Cheever's method, 645; Czerny's method, 646; general remarks on, 646; low lateral, 647; low lateral, remarks on, 649; low lateral results of, 650; Mikulicz's method, 646; results of, 647; subhyoid, 692; subhyoid, prognosis in, 693; treatment after, 647.
- Phelps's open incision for talipes equinovarus, 448; results of, 449.
- Phlebectomy, 215.
- Phleborrhaphy, 214.
- Phlegmon of neck, 725.

- Phosphoric necrosis of lower jaw, 374.
 Pia mater, division of, in craniotomy for tumor, 253; hæmorrhage from, 241.
 Pin, Buck's, 76; use of, in securing drainage tube, 106; Wyeth's, 75.
 Pin carrier, Post's or Buck's, 103.
 Pin suture, 102.
 Pirogoff's amputation of foot, 512.
 Plantar fasciotomy, 349.
 Plantar nerves, exposure of, 327.
 Plaster-of-Paris bandage, after excision of head of humerus, 389; jacket for curvature of spine, Sayre's, 560.
 Plastic surgery, 569; preparation of patient for, 569; size of flaps in, 569.
 Plastic surgery, transfer of flaps in, methods of, 571; grafting, 575; inversion and eversion, 574; jumping, 574; sliding in a curved line, 572; sliding in a direct line, 571; tagliacotian method, 574.
 Plethora, operations on the, 3.
 Plexus, brachial, operations on branches of, 321; lumbar, operations on, 327; sacral, exposure of branches of, 324.
 Plugging of posterior nares, 650; remarks on, 651.
 Pneumogastric nerve during shock, 120.
 Pneumonia after anæsthesia, 21.
 Pocket cases, 45.
 Poirier's naso-lambdoidal line, 250.
 Poisoning, iodoform, symptoms of, 112.
 Pollock's amputation at knee joint, long anterior- and short posterior-flap method, 527; method of excision of scapula, 382.
 Polydaetylim, 563.
 Polypi, nasal, removal of, with forceps or snare, 651; nasopharyngeal, removal of, 653.
 Polypi, nasal and nasopharyngeal, Anandale's operation for, 657; Boeckel's operation for, 657; Chalot's operation for, 656; Chassaignac's operation for, 654; Cheever's operation for, 559; choice of operation for removal of, 661; Desprez's operation for, 653; general comments on removal of, 659; Guérin's operation for, 659; instruments for removal of, 653; Kocher's operation for, 659; Langenbeck's operation for, maxillary route, 657; Langenbeck's operation for, maxillary route, results of, 659; Langenbeck's operation for, nasal route, 655; Lawrence's operation for, 655; maxillary route for removal of, 657; nasal route for removal of, 655; Nélaton's operation for, 556; Ollier's operation for, 654; palatine route for removal of, 656; results of operation for, 661; Rouge's operation for, 654, 655; treatment after removal of, 661.
 Popliteal artery, anatomical points of, 149; ligature of, 149; ligature at middle third, dangers of, 149; linear guide to, 149; muscular guides to, 149.
 Popliteal nerve, external, method of reaching, 326; internal, method of reaching, 326.
 Position as an hæmostatic, 68.
 Posterior nares, plugging of, 650.
 Posterior tibial artery, anatomical points of, 153; ligature of, 153; linear guide to, 154; muscular guide to, 154.
 Post-olecranon bursitis, treatment of, 354.
 Post's operation for deviation of septum nasi, 662; pin carrier, 103.
 Potassium permanganate in cleansing the hands, 114.
 Powell's electric saw, 243.
 Pravaz syringe, 41.
 Precautionary requirements relating to operation, 9, 119.
 Precentral fissure (brain), 249.
 Preparation, for operation, general remarks on, 95; for operation, summary of, 113; of cavity in osteoplasty, 450; of catgut, 87; of field of operation, 94, 113; of gauze, bichloride, 111; of gauze, iodoform, 110; of gauze, Thiersch's, 111; of hands for operation, 114; of mucous surfaces for operation, 95; of muslin dressing, 112; of operator and assistants at operation, 113; of patient for craniotomy, 250; of patient for operation, 94, 113; of a septic part for operation, 95; of sponges, 63.
 Prepatellar bursitis, treatment of, 353.
 Pressure, digital, as an hæmostatic, 71; instrumental, as an hæmostatic, 72.
 Primary incision in ligature of arteries, 126.
 Primary suturing of nerves, 273.
 Probang, œsophageal, 664.
 Probe, 129; Fluhrer's, 267; Girdner's telephone, 267; in ligature of arteries, 127; locating bullet with, after gunshot wounds of cranium, 267.
 Professional reputation, 120.
 Profunda artery, ligature of, 148.
 Protective dressing, 107.
 Pryor's operating table, 56.
 Pudic artery, internal, anatomical points of, 138; ligature of, 137.
 Pudic nerve, exposure of, 324.
 Pulsation as a guide to an artery, 125, 126.
 Pulse during anæsthesia, 14, 15; during shock, 121.
 Puncture and tapping of a meningocele, 230.
 Pupils, during anæsthesia, 15; during chloroform anæsthesia, 29.
 Pus, between the dura and cranium, 257; craniotomy for the evacuation of, 257; exploration of brain for, 258.
 Pyæmia after craniotomy, 244.
 Pyle's chisel, 298.
 Quadriceps extensor, tenotomy of, 337.
 Quilled suture, 102.

- Quilt suture, Wölfler's, in tendon suturing, 340.
- Radial artery, anatomical points of, 185; guides to, 186; ligature of, 185; points for ligature of, 186; pulsation of, at wrist, 186; relations of, 185.
- Radial nerve, exposure of, 324.
- Radius, excision of, 399.
- Ranula, 644.
- Receptacles, for antiseptic fluids, 57; for instruments, 51.
- Recurrent goitre, 720.
- Recurrent laryngeal nerve, effect of division of, 730.
- Reef knot, 83.
- Reeves's osteo-arthroto-my for genu valgum, 443.
- Reflex stimulation during shock, 120.
- Regnoli's method of removal of tongue, 642.
- Relation of arteries and veins, 126.
- Relations of subclavian artery, left side, first portion, 169.
- Relaxation and coaptation suture, 104.
- Repair of cranial opening after circular craniotomy, 235.
- Reputation, professional, 120.
- Requirements for operation, essential, 9; precautionary, 9, 119.
- Resection of goitre, Koehler's, 719; of goitre, remarks on, 720; of nerve, 271; of tarsus, osteoplastic, results, 416; of tarsus, osteoplastic, Wladimirov-Mikulicz, 415.
- Resin as a styptic, 68.
- Respiration, artificial, 18, 19, 119; artificial, Laborde's method, 22; during anaesthesia, 14, 15; rapid, as an anaesthetic, 36.
- Respirations during shock, 121.
- Respiratory force, impairment of, after laminectomy, 312.
- Restlessness during shock, 221.
- Restraint of patients under anaesthesia, method of, 11.
- Retentive coaptation of wound surfaces, 96.
- Retractor, 50, 129; cloth in amputating, 466; special metal, for amputations at thigh and arm, 466.
- Retroclusion, 76.
- Retropharyngeal abscess, 726; Buckhardt's method of opening, 727; Chiene's method of opening, 726.
- Reverdin's method of skin-grafting, 575.
- Rhinoplasty, 580; Dieffenbach's operation, 584; for loss of bony or cartilaginous septum, with or without loss of nasal bones, 584; for loss of column, 583; for loss of septum and nasal bones, outline of flap in, 588; for loss of septum and nasal bones, treatment after, 588; French method, 580; Indian operation, 586; Italian operation, 590; Keegan's operation, 589; Langenbeck's operation, 582; Syme's operation, 581; Weber's operation, 583; Verneuil's operation, 585.
- Rhinoplasty, osteoplastic, 590; Israel's modification of König's, 591; König's operation, 591; Ollier's operation, 590; Pancoast's subcutaneous, 592.
- Rice concretions of thecitis, 354.
- Rice's method of preparing catgut, 87; method of preparing iodoform gauze at Bellevue Hospital, 110.
- Richardson's operation for diverticulum of oesophagus, 679.
- Richelot's operation for salivary fistula, 633.
- Rivington's method of ligaturing the common carotid artery, 194.
- Rizzoli's operation for immobility of inferior maxilla, 378.
- Rod, Trendelenburg's, 74.
- Roger's ligature or subclavian artery, left side, first portion, 170.
- Rolando, location of fissure of, 246; location of fissure of, by Chiene's method, 247.
- Rose's method of intracranial neurectomy of trifacial nerve, 295; position for staphylorrhaphy, 620.
- Rouge's operation for diseased bone and naso-pharyngeal growths, 654, 655.
- Routes to lingual nerve, 289.
- Roux's amputation at ankle joint, 512.
- Rubber, dam as a dressing, 107; finger stalls, 115; rings, to control hemorrhage, 70; suit, for shock (Crile), 122; surgical cushion, 54; tissue as a dressing, 107; tubing, for drainage, 105.
- Rudtorffer's operation for webbed fingers, 564.
- Rugine, 465.
- Ruyseh's method of wrist-joint amputation, 478.
- Sabanejeff's osteoplastic amputation of thigh, 532.
- Sacciform aneurism, radical cure of, 208.
- Sacral plexus, exposure of branches of, 324.
- Sailer's method of gelatin injection, 66.
- Saint Germain's operation of rapid laryngo-tracheotomy, 689.
- Salicylic acid, 61.
- Saline solution, 62; enemata of, 222; ingredients of (Szumann), 221; in shock, 121; injection of, 221; injection of, into ventricles, 228; subcutaneous injection of, 222; temperature of, for transfusion, 221.
- Saline transfusion, 220; Dawbarn's method, 221; fallacies of, 222; during operation, 119.
- Salivary fistula, 632; Agnew's operation for, 632; Desault's operation for, 632; Deguise's operation for, 633; Richelot's operation for, 633; Van Buren's operation for, 632.

- Salzer's operation on trifacial nerve at foramen ovale, 293.
- Sand pillow for osteotomy, 435.
- Saphenous nerve, internal situations for exposure of, 328; external exposure of, 328.
- Sartorius, tenotomy of, 336.
- Saw, amputating, 464; amputating, method of using, 464; chain, 364, 464; for correction of deviation of nasal septum, 662; Gigli-Haertel wire, 243, 364, 464; Powell's electric, 243; Shradys, 434; Szymanowski's, 419.
- Sawdust dressing, 112.
- Sayre's excision of hip joint, 429; jury-mast, 561; modification of Barton's intertrochanteric osteotomy, 438; plaster-of-Paris dressing for curvature of spine, 560.
- Scalpels, 129; for osteotomy, 435; in amputating, 463; methods of holding, 45.
- Scapula, contiguous anatomy of, 381; excision of, 381; excision of acromion process of, 382; excision of angles of, 383; excision of body of, 382; excision of, complete, 381; excision of glenoid angle of, 383; excision of, subperiosteal, 383.
- Scarpa's space, femoral artery in, 145.
- Schede's method of healing bony defects, 358; incision around leg for varicose veins, 218.
- Schleich's mixtures for general anaesthesia, 32; solutions for local anaesthesia, 38.
- Schönborn's operation of staphyloplasty, 630; results of, 631.
- Schumpert's ligature of the subclavian artery, left side, first portion, 170.
- Schwartz's method of resection of goitre, 722.
- Sciatic artery, anatomical points of, 137; ligature of, 136.
- Sciatic nerve, great, bloodless stretching of, 326; great, exposure of, 324, 326; great, fallacy of operation on, 326; great, operations on, 324; great, results of operations on, 326; small, exposure of, 324.
- Scissors, 48.
- Scurvy, 6.
- Secondary hæmorrhage, 72, 77.
- Secondary suturing, 101; of nerves, 273.
- Section of nerve, 271.
- Sédillot's amputation of thigh, long anterior-flap method, 537; method of cheiloplasty of lower lip, 611; method of removal of tongue with division of jaw, 640; mixed double-flap method of amputation, 457; vertical-flap method of cheiloplasty of upper lip, 613.
- Selection of vessel for arterial infusion, 223.
- Semimembranosus, tenotomy of, 336.
- Semitendinosus, tenotomy of, 336.
- Senn's bloodless amputation at hip joint, 546; method of injection of goitre, 722; operation for excision of head of humerus, 388.
- Sepsis, after enucleation of thyroid body, 717; after laminectomy, 311.
- Septic part, preparation for operation of, 95.
- Septum nasi, deviation of, 661; Post's operation for, 662; Wagner's operation for, 662.
- Sequestromy, 358; direct method, 358; indirect method, 361; instruments for, 358; on clavicle, 880; precautions in direct method of, 358.
- Serous surfaces, needles for, 99.
- Serre-fines, 77, 78.
- Serre's method of stomatoplasty, 616.
- Sheath of a vessel as a guide to an artery, 125.
- Sheaths, of flexor tendons of hand, communicability of, 354; tendon, treatment of, at amputations, 468.
- Sheets, clean aseptic, 57.
- Shock, 120; after laminectomy, 311; Crile's rubber suit for shock, 122; due to loss of blood, symptoms of, 121; in linear craniotomy, 244; operations during, 4; sinapisms of mustard for, 121; prevention of, 120; treatment of, 121; use of adrenalin in, 67.
- Shoulder joint, amputation above, 492; Berger's, 493; comments on, 494, precautions, 494; results of, 495.
- Shoulder joint, amputation at, 486; circular-incision method, 489; circular-incision method, remarks on, 489; external- and internal-flap method, Dupuytren's 488; oval-flap method, Larrey's, 491; prevention of hæmorrhage in, 487; racket-flap method, Spence's, 491; remarks on, 492; results of, 492; special considerations for, 487; Wyeth's needles in, 487.
- Shoulder joint, Kocher's excision of, from behind, 390.
- Shradys saw, 434.
- Sick-room, 8.
- Silk ligatures, 81, 85.
- Silk, oiled, as a dressing, 107.
- Silk sutures, 97.
- Silkworm-gut, 85, 106.
- Silver wire sutures, 98, 102.
- Silvester's method, artificial respiration, 18.
- Simon's operation for single harelip, 601.
- Simpson's method of acupressure, 75.
- Sinapisms, mustard, during shock, 121.
- Single harelip, 600.
- Sinus, frontal, trephining of, 265; formation in operative wound, 97; lateral, craniotomy for thrombosis of, 260.
- Sinuses, the location of, 237.
- Situation usually chosen for tapping the ventricles, 227.

- Key's modification of Lisfranc's tarso-metatarsal amputation, 504.
- Skin, during shock, 121; flaps in amputating, 452.
- Skin-grafting, 575; Krause's method, 577; Lusk's (Z. J.) method, 577; remarks on, 577, 578; Reverdin's method, 575; Thiersch's method, 576.
- Skinner's inhaler, 30.
- Skull, bony landmarks of, 245; craniotomy for fracture of, 231; opening through, for cerebellar tumor, 256.
- Smith's (Stephen) amputation at knee joint for gangrenous condition of toes and foot, 525.
- Smith's modification of Lisfranc's tarso-metatarsal amputation, 504.
- Soap-finger, 563.
- Soap for cleansing the hands, 114.
- Socin's method of enucleation of goitre, 718; method of treating œsophageal stricture, 674.
- Soda, caustic, in preparation of dressings, 113; washing, in preparation of dressings, 112.
- Sodium carbonate, for cleansing the hands, 114; solutions of, 62.
- Solutions, aseptic and antiseptic, 59; biniodide of mercury, 60; boric acid, 61; carbolic acid, 59, 60; corrosive sublimate, 59, 60, 61; for spinal anæsthesia, 41, 43; iodine, 60; saline, 62; saline, injection of, 221; saturated, of iodoform and ether, 61; sodium carbonate, 62; sulpho-carbolate of zinc, 60; sulphurous acid, 61; Thiersch's, 61; zinc chloride, 60.
- Southerland's method of drainage of lateral ventricles, 229.
- Spaces, dead, management of, 101.
- Spasmodic wryneck, resection of spinal accessory and posterior divisions of cervical nerves for, 562.
- Special emergencies during an operation, 120.
- Special nerves, operations on, 276.
- Special operations on nerves, 271.
- Spence's method of excision of scapula, 382; racket-flap method of amputation at the shoulder joint, 491.
- Spiller and Frazer method of intracranial division of trifacial nerve, 306.
- Spina bifida, 317; injections of iodoglycerin solution in, 317; palliative treatment of, 317; radical cure of, 317; results of injection of iodoglycerin solution in, 318; treatment of, by excision, 318; varieties of, 317.
- Spinal accessory nerve, 319; anatomical points of, 319; operations on, 319; points for exposure, 319; remarks on operation on, 320; resection of, for spasmodic wryneck, 562; results of operations on, 320.
- Spinal anæsthesia, 41; Morton's method, 43; precautions in, 42; Tuffier's method, 42.
- Spinal canal, examination of, in laminectomy, 312.
- Spinal cord and spinal nerves, operations on, 311.
- Spinal cord, tumors of, 319; result of operations on, 319.
- Spinal meningeal drainage, 316; anatomical points for, 316.
- Spinal nerves, intraspinal division of roots of, 321; operations on, 311.
- Spine, curvature of, 560; curvature of, treatment with plaster-of-Paris jacket, Sayre's, 560; of Spix, 285; supra-meat, as a guide to bony meatus, 263.
- Splints, nasal, 662.
- Sponge on holder in anæsthesia, 14.
- Sponges, 9, 57, 62; assistant to count, 94; preparation of, 63.
- Spontaneous subclavian aneurism, Moynihan's operation on, 203; remarks on, and results of, 206.
- Square knot, 83.
- Squire's method of treating "birthmark," 223.
- Staffordshire knot, 84.
- Stalls, rubber finger, 115.
- Staphyloplasty, 630; Lane's method, 631; Schönborn's operation of, 630.
- Staphyloorrhaphy, 620; anæsthesia in, 620; comments on, 620; muscular influence in, 621; muscles concerned with, 621; position of patient during, 620; remarks on, 621; results of, 623; Rose's position for, 620; steps in operation of, 622; time for, 620.
- Starr's statistics for removal of brain tumors, 255.
- Stay knot, Ballance and Edmunds's, 84.
- Sterilization of catgut, Fowler's method, 87; of catgut, Rice's method, 87; of gelatin, Sailer's method, 66; of instruments, 52, 112; of fabrics, 112; of silk ligatures, 85.
- Sterilizers, portable and fixed, 52.
- Sterno-cleido mastoid, myotomy of, 338; remarks on myotomy of, 338.
- Sternum, excision of, 379; results of excision of, 379.
- Stimulants, 119; in anæsthesia, 14.
- Stokes's cuneiform osteotomy for relief of talipes, 449; modification of Gritti's amputation of thigh through condyles, 529.
- Stomach, examination of, during gastrotomy, 671.
- Stomatoplasty, 615; Buck's method, 615; Serre's method, 616.
- Storage batteries for galvano-cautery, 81.
- Stretching of the great sciatic nerve, bloodless, 326.
- Stricture of œsophagus, 672; comments on operations for, 676; dilatation of, 672; division of, with string friction, Abbe's method, 675; division of, with

- string friction, author's method, 675; division of, 674; external œsophagotomy for, 674; internal œsophagotomy for, 674; malignant, 677; results of operations for, 677; results of tubage in, 678; retrograde dilatation of, 673; treatment after operations for, 677; tubage in, 677.
- Strips, gauze, for drainage, 106.
- strychnine, 119, 122.
- Studdiford's method of sterilizing catgut, 89.
- "Student's" needle, 130.
- Stump, qualities of a good, 451.
- Styptic collodion, 68.
- Styptics, 68; alum, 68; hot and cold water as, 68; resin, 68; subsulphate of iron as, 68; tannin, 68.
- Susastragaloid amputation, heel-flap method, 508; Lingnerolles's method, 507; Verneuil's method, 508.
- Subastragaloid dislocation, 506.
- Subclavian artery, anatomical points of, 168; guides to, 168; ligature of, 168.
- Subclavian artery, first portion, left side, guide to, 168; left side, ligature of, 168; left side, relations of, 169; right side, guide to, 170; right side, ligature of, 170; right side, relations of, 170.
- Subclavian artery, second portion, ligature of, 174; relations of, 174.
- Subclavian artery, third portion, external jugular vein as a guide to, 172; ligature of, 171, 172; linear guide to, 171; relations of, 171.
- Subclavian vein, results of ligature of, 215.
- Subcutaneous injection of saline fluid, 222; ligaturing of nævus, 224; nerve section, 272.
- Subcutaneous ligaturing of varicose veins, 216; needle for, 216; precautions in, 216; results in, 217.
- Subcuticular suture, 104.
- Subdural hæmorrhage, 238, 240; operation for, 241; results of, 241.
- Subfrontal fissure, 249.
- Subhyoid pharyngotomy, 692; prognosis in, 693.
- Sublimate solution in cleansing the hands, 113.
- Submammary infusion, 223.
- Submaxillary nerve, division of, 279.
- Suboccipital nerve, 320.
- Subperiosteal removal of bone, 361.
- Subsulphate of iron, as a styptic, 68; injection of varicose veins with, 216.
- Suffocation from contents of stomach during anæsthesia, 120.
- Sulpho-carbolate of zinc, solutions of, 60.
- Sulphurous acid, 61.
- Summary of preparations for operation, 113.
- Superfrontal fissure, 249.
- Superficial palmar arch, incision for, 191.
- Superior maxillæ, simultaneous removal of, 372.
- Superior maxillary ærve, 278; Carnochan-Chavasse operation on, 283; dental branches of, 279; division and removal of, 279; infra-orbital portion, 279; intra-cranial portion, 279; Kocher's operation on, 281; Lössen's operation on, 284; Lücke's operation on, 284; operation for division and removal of, 280; point for division of, 279; precautions for operation on, 280; precautions in Carnochan-Chavasse operation, 283; remarks on Kocher's operation on, 281; remarks on operation on, 280; removal of, 279; results of operation on, 284; sphenomaxillary portion of, 279; stretching of, 279.
- Superior thyroid artery, ligature of, 197.
- Supernumerary finger, 563.
- Suppuration, relation of, to scurvy, 6; to glycosuria, 5; to malaria, 6.
- Supramalleolar amputation of leg, 516.
- Supra-maxillary division of fifth nerve, 277.
- Supra-meatal spine as a guide to bony meatus, 264.
- Supra-orbital nerve, operations on, 276.
- Supra-renal extract as an hæmostatic, 66; during anæsthesia, 20.
- Supratrochlear nerve, operations on, 277.
- Surgeon, apparel of, 115; duty of, in amputations at lower extremity, 496; rehearsal of steps of operation by, 119; relation of, to patient, 1.
- Surgeon's knot, 82.
- Surgery, plastic, 569.
- Surgical cushion, rubber, 54.
- Surgical engine, 364.
- Surgical needle, 76.
- Suture, of nerves, 272; of tendons, 338.
- Sutures, buried, 103; button, 103; catgut, 97; celluloid thread, 98; chromicized catgut, 97; classification of, 97; continuous or glover's, 102; deep, 98; deep, to control bleeding, 96; depth of and distance between, 99; different forms of, 101; for three-cornered wounds, 104; Halsted's method of sterilizing and preserving, 90; harelip, 102; horsehair, 98; inorganic, 97, 98; interrupted, 101; kangaroo tendon, 97; organic, 97; pin, 102; quilled, 102; relaxation and coaptation, 104; silk, 97; silkworm-gut, 97; silver wire, 98, 102; subcuticular, 104; tension of, 100; time for, to remain *in situ*, 100; twisted, 102, 103.
- Suturing, secondary, 101.
- Sylvius, fissure of, location of (Reid), 247; posterior limb of, 250.
- Syme-Buchanan method of cheiloplasty of lower lip, 609.
- Syme's amputation at ankle joint, 509; method of cheiloplasty of lower lip, 609; modification of circular integumentary-flap method of amputation of

- thigh, 535; operation of rhinoplasty, 581; operation of rhinoplasty, remarks on, 582.
- Sympathetic, excision of the, for exophthalmic goitre, Jaboulay and Jonnesco's, 721.
- Syncope, 120; during anaesthesia, 18; treatment of, 18.
- Syndactylism, 563; Agnew's operation for, 566; Dee's operation for, 564; Diday's operation for, 564; Fowler's operation for, 566; Norton's operation for, 564; remarks on, 567; Rudtlorffer's operation for, 564; Zeller's operation for, 566.
- Syndesmotomy, 348.
- Syringe, fountain, as an irrigator, 108; Davidson's, 119; hypodermic, 119; Matas's, for infiltration anaesthesia, 39; Pravaz's, 41.
- Szymanowski's method of cheiloplasty of upper lip, 614; saw, 419.
- Table, operating, 9, 53, 113; characteristics of a good, 54; Cleveland's, 54; Edebohls's, 56; extemporized, 53; Fowler's, 55; inclined plane for use in conjunction with, 56; portable, 56; preparation of an, 53; Pryor's, 56.
- Tablescoop as a retractor, 129.
- Tablets of bichloride of mercury, 113.
- Taglioctian operation, 574.
- Talipes, cuneiform osteotomy for relief of, Bird's, 449; cuneiform osteotomy for relief of, Stokes's, 449; osteotomy for, 447; removal of astragalus for relief of, Vogt's, 449; excision of astragaloscaphoid joint for relief of, Ogston's, 449.
- Talipes equino-varus, cuneiform osteotomy of tarsus for, Davies-Colly, 447; linear osteotomy of neck of astragalus for, Bradford's, 448; linear osteotomy of neck of astragalus for, results of, 448; open incision for, Phelps's, 448; open incision for, results, 449.
- Talipes varus, tibialis anticus in, 335; tibialis posticus in, 332.
- Tamponing of trachea, 706; Gerster's method, 707; Hahn's method, 707; Trendelenburg's method, 707.
- Tannin as a styptic, 68.
- Tapping subarachnoid space, Parkin's operation for, 316.
- Tapping the ventricles for acute hydrocephalus, 229; for chronic hydrocephalus, 227; for paralysis of insane, 261.
- Tarsal amputations, irregular, Molliere's, 506; treatment after, 509; results of, 509.
- Tarsal joints, operations on, 408.
- Tarsectomy for talipes equino-varus, Davies-Colly, 447; results, 448.
- Tarso-metatarsal joint, amputation at, Baudens's, 504; Hey's, 504; Lisfranc's, 502; Skey's, 504; Smith's, 504.
- Tarso-metatarsal joint, excision of, 408.
- Tarsus, cuneiform osteotomy of, for talipes equino-varus, Davies-Colly, 447; excision of phalangeal joints of, 407; osteoplastic resection of Wladimirov-Mikulicz, 415.
- Teale's method of amputation of arm, 485; method of amputation of leg, 518; rectangular-flap amputation, 458.
- Technique, antiseptic, in gunshot wounds of the cranium, 266; aseptic and antiseptic, 94.
- Telephone probe, Girdner's, 267.
- Temporal artery, anatomical points of, 201; bony guide to, 201; ligature of, 201.
- Temporal bone in cerebral abscess, 260.
- Tenaculum, 77, 78, 129; in amputating, 467.
- Tendo Achillis, attachment of, 409; care after tenotomy of, 334; lengthening of, 341; lengthening of, by Anderson's method, 341; lengthening of, by transplantation of tubercle of os calcis, 341; shortening of, 342; shortening of, Gibney's method, 342; shortening of, Willett's method, 343; shortening of, Z method, 343; tenotomy of, 333.
- Tendon anastomosis, remarks on, 345; anastomosis, Vulpius's operation, 345.
- Tendon graft, 340.
- Tendon lengthening, 340; lengthening, by accordeon plan, 341; lengthening, by incision method, 341; lengthening, by single flap, 341.
- Tendon sheaths, treatment of, at amputations, 468.
- Tendon shortening, 342; remarks on, 343.
- Tendon sutures, kangaroo, 97.
- Tendon suturing, 338; after oblique division, 340; Billroth's method, 340; Hueber's method, 340; materials for, 339, 340; methods of, 340; Nicoladoni's method, 340; Witzel's method of, 340; Wüller's quilt suture in, 340.
- Tendon transplantation, 343; after treatment of, 346; choice of methods in, 346; results of, 346.
- Tendons, retraction of, 339; severed ends of, in amputations, 452.
- Tenorrhaphy, 338; special considerations of, 339.
- Tenosynovitis, 355.
- Tenotomes, 329.
- Tenotomy, 329; instruments employed in, 329; of lower extremities, 332; of adductor longus, 337; of biceps flexor cruris, 336; of biceps flexor cubite, 332; of extensor brevis pollicis, 331; of extensor communis digitorum, 331; of extensor longus digitorum, 335; of extensor longus pollicis, 331; of extensor ossis metacarpi pollicis, 331; of extensor proprius hallucis, 335; of flexor carpi radialis, 331; of flexor carpi ulnaris, 331; of flexor longus digitorum, 332; of flexor longus digitorum, precautions in, 333;

- of flexor longus pollicis, 333; of flexor profundus digitorum, 331; of flexor sublimis digitorum, 331; of flexor sublimis digitorum, precautions in, 331; of gracilis, 336; of hamstrings, 336; of latissimus dorsi, 337; of peroneus brevis, 334; of peroneus longus, 334; of peroneus tertius, 335; of quadriceps extensor, 337; of sartorius, 336; of semimembranosus, 336; of semitendinosus, 336; of tendo Achillis, 333; of tibialis anticus, 335; of tibialis posticus, 332; order of procedure in, 330; to relieve flexed leg, remarks on, 336; upper extremities, 331.
- Tensile strength of catgut, 87.
- Tension, of sutures, 100; of wound when sewing, 99.
- Tensor vaginae femoris, myotomy of, 337.
- Testicle, shock due to injury of, 120.
- Textile fabrics, sterilization of, 112.
- Thecitis, 354; acute, 355; chronic, 352; operative treatment of, 354.
- Thermic angiotripsy, 79.
- Thermo-cautery, 79; in bronchotomy, 690.
- Thiersch's fluid, 61; fluid for instruments, 52; gauze, preparation of, 111; method of skin-grafting, 576.
- Thigh, amputation of, 532; Agnew's method of forming flaps in, 535; antero-posterior musculo-integumentary-flap method, 534; bilateral flap method, 533; circular integumentary-flap method, 535; equilateral-flap method, Vermale's, 533; general remarks on, 537; long anterior- and short posterior-flap method, Farabœuf's, 537; long anterior-flap method, Sédillot's, 537; methods of, 533; single circular-incision method, Celsus's, 536; results of, 540; special considerations for, 532; suturing over the end of bone after, 537; Syme's modification of circular integumentary-flap method, 535; through trochanters, 540; treatment after, 539.
- Thigh, amputation of, through condyles, 528; Carden's method, 528; Carden's method, results of, 528; fallacies of Gritti's method, 529; Farabœuf's modification of Carden's method, 529; Gritti's method, 529; Lister's modification of Carden's method, 528; results of Stokes's and Gritti's methods, 530; Sabancjef's osteoplastic method, 532; Stokes's modification of Gritti's method, 529.
- Thoracic duct, injury of, 730; in ligature of the subclavian, left side, first portion, 170.
- Thoracic injury, shock due to, 120.
- Thread suture, celluloid, 98.
- Three-cornered wound suture, 104.
- Throat forceps, 664.
- Thrombosis after craniotomy, 244; of lateral sinus and jugular vein, craniotomy for, 260.
- Thumb, amputation of, at carpo-metacarpal articulation, 473.
- Thumb forceps, 46, 129.
- Thymol, 62.
- Thyroid artery, inferior, anatomical points of, 177; inferior, guide to, linear, 177; inferior, ligature of, 177; superior, anatomical points of, 197; superior, ligature of, 197.
- Thyroid body, comments on partial enucleation of, 716; dangers of operations on, 722; dressing of wound after operations on, 723; enucleation of, 717, 718; enucleation resection of, Kocher's, 717; in ligature of common carotid, 193; operations on, 710; operations on, anatomical points for, 710; partial excision of, Kocher's, 711; partial excision of, Kocher's, remarks on, 714; partial excision of, precautions in, 715; partial excision of, through angular incision, 714; preparation of patient for operations on, 711; results of operation on, 722; treatment after operation on, 722.
- Thyroid cartilage, 681.
- Thyroidectomy, Kocher's, 719; remarks on, 720.
- Thyrotomy, 685, 689; instruments for, 683; precautions in, 690; remarks on, 690.
- Tibial artery, anterior, anatomical points of, 150; anterior, ligature of, 150; anterior, linear guide to, 151; anterior, muscular guide to, 151; posterior, anatomical points of, 153; posterior, ligature of, 153; posterior, linear guide to, 154; posterior, muscular guide to, 154.
- Tibial nerves, anterior and posterior, exposure of, 327.
- Tibialis anticus in talipes varus, 335; tenotomy of, 335.
- Tibialis posticus in talipes varus, 332; tenotomy of, 332.
- Tissue, rubber, as a dressing, 107.
- Tissues, separation of, in ligature of arteries, 127; uniting of divided, 98.
- Time in the prevention of shock, 121.
- Toe, great, amputation of, 498; by internal plantar-flap method, Farabœuf's, 499; by oval-flap method, 499; by square-flap method, 498; first phalanx of, 496, 497; with metatarsal bone, 501; through last phalanx of, 497.
- Toe, great, excision of metatarso-phalangeal joint of, 408.
- Toe, little, amputation of, 498; by internal plantar-flap method, Farabœuf's, 499; by oval flap method, 499; with metatarsal bone, 501.
- Toe-nail, ingrown, 567; Anger's operation for, 567; Cotting's operation for, 568; results of operation for, 568.
- Toes, amputation of, 497; amputation of two adjoining, 499; removal of second, third, or fourth, 497.

- Tongue, choice of method in removal of, 643; control of hemorrhage during operation on, Langenbeck's method, 634.
- Tongue, excision of, methods of, 635; "V"-shaped incision for, 635.
- Tongue forceps, 13, 119.
- Tongue, Hueter's operation on, 638.
- Tongue, hypertrophy of, 637.
- Tongue, operations on, 634; laryngotomy preliminary to, 635.
- Tongue, removal of, Billroth's method, 642; entire, methods of, 638; entire, through mouth, 638; entire, through mouth, treatment after, 639; general remarks on, 643; Jaeger's method, 641; Kocher's method, 639; Langenbeck's method, 642; one-half of, 637; one-half of, comments on, 638; Regnoli's method, 642; results of, 643; treatment after, 643; when floor of mouth is involved, 642; with division of jaw, Sédillot's method, 640; with *écraseur*, 641.
- Tongue-tie, 644.
- Tonsil, abscess of, 634; excision of, 633; excision of, results of, 634; removal of, with knife and scissors, 633.
- Tonsil and pillar of fauces, tumor of, removal of, 644; anatomical points of, 644.
- Tonsillotomes, 633.
- Tonsils, relations of, to internal carotid artery, 196.
- Torsion as an hæmostatic, 76.
- Torsion forceps, 76.
- Torsoclusion, 76.
- Torticollis, 561; spasmodic, resection of spinal accessory and cervical nerves for, 562; treatment of, by open method, 561; treatment of, by open method, results of, 562.
- Tourniquet for compressing abdominal aorta, 540; Esmarch's, 541; Lister's, 541; Pancoast's, 541.
- Tourniquet, extemporized, 72; Petit's, 72.
- Towels, clean aseptic, 57.
- Toxic dose of adrenalin, 67.
- Trachea aspirator, 684; dilators, 683; foreign body in, 698; general comments on operations on, 690; operations on, treatment after, 692; operations on, results of, 692; size of, in adult, 681; tamponing, 706; tube, bivalve, 683.
- Tracheotomy, above the isthmus, 688; anatomical points for, 687; below isthmus, 687; high, 687; instruments for, 683; low, 687; preliminary to excision of, upper jaw, 365; preliminary to removal of entire tongue, 639; preliminary to removal of nasal growth, 657, 660; situations for, 687; through isthmus, 689; tube, 119.
- Traction loops, 50, 129, 130.
- Transfixion flaps, 453.
- Transfusion, apparatus for, 220; during operation, 119; point for introduction of, 220; saline, Dawbarn's method, 221; solutions used for, 220.
- Transperitoneal ligature of the common iliac artery, 132; of internal iliac artery, 135.
- Transplantation, of bone, 450; of tubercle of os calcis in lengthening tendo Achillis, 341; of tubercle of os calcis in shortening tendo Achillis, 343.
- Transverse fissure (brain), 248.
- Trapezius, myotomy of, 338.
- Traumatic aneurism, extirpation of, 202; aneurism, results of, 203.
- Traumatic epilepsy, results of operations for, 257.
- Treatment of brain tumor, 253; of operation wounds, 96.
- Trendelenburg's apparatus for administration of anæsthetic through tracheotomy tube, 660; apparatus for anæsthesia, extemporized substitutes for, 660; method of meloplasty, 617; method of tamponing the trachea, 707; operation for goitre, 721; operation for varicose veins, 217; posture in laryngotomy, 690; posture in ligation of common iliac artery, 133; posture in ligation of external iliac artery, 139; posture in ligation of internal iliac artery, 135; rod, 74; rod, use of, in amputations at hip joint, 542.
- Trepine, passage of, through *diplœ*, 234.
- Trepines, circular or crown, 231; conical or Galt, 231.
- Trephining, cranium, 231; frontal sinus, 265; frontal sinus, precautions for, 266; over important vessels, 237.
- Treves's method of complete laryngectomy, 701; operation on cervical lymphatic glands, 729; operation on cervical lymphatic glands, precautions in, 729; operation on cervical lymphatic glands, remarks on, 730.
- Trifacial nerve, anatomical points of trunk of, at foramen ovale, 290; guide to, in intracranial neurectomy, 300; Horsley's intradural division of, 307; Mixer's operation on, at base of skull, 293; Mixer's operation, comments on, 294; operations applicable to first and second portions and to Meckel's ganglion, 281; operations on first division of, 276; operations on second division of, 277; precautions in operations on, at base of skull, 294; results of operations on, at base of skull, 294; Spiller and Frazer method of intracranial division of, 306; third division of, 284; treatment after operations on, at base of skull, 294; trunk of, at foramen ovale, 290.
- Trifacial nerve, intracranial neurectomy of, 295; Abbe's method, 306; Cushing's method, 303; Doyen's method, 302; Hartley-Krause method, 296; Rose's method, 295.

- Trifacial nerve, operation on, at foramen ovale, Credé's, 293; Kocher's, 292; Krönlein's, 293; Pancoast's, 293; Salzer's, 293.
- Tripier's amputation through the os calis, 508.
- Trochanter, great, excision of, 425.
- Trochanters, amputation of thigh through, 540.
- Tube, trachea, bivalve, 683; tracheotomy, 119.
- Tubercle bacilli in thecitis, 354.
- Tubes, drainage, removal of, 106; Neuber's decalcified, for drainage, 106.
- Tubing, rubber, for drainage, 105.
- Tuffier's method for inducing spinal anæsthesia, 42.
- Tumor, brain, craniotomy for, 245; brain, treatment of, 253; cerebellar, craniotomy for, 255; due to dilatation of capillaries, 223; of spinal cord, 319; of spinal cord, result of operations on, 319; of tonsil and pillar of fauces, removal of, 644.
- "Tupfers," 63, 64.
- Turnipseed's amputation of foot, 514.
- Twisted suture, 102, 103.
- Ulna, excision of, 399.
- Ulnar artery, anatomical points of, 188; guides to, 188; ligature of, 188; points for ligature of, 189; relations of, 188.
- Ulnar nerve, displacement of, 324; situations for exposure of, 324.
- Union by first intention, 97.
- Upper extremity, amputation at, 468; in female subject, 185.
- Uranoplasty, 623; comments on, 629; Davies-Colly method, 626; Dieffenbach-Fergusson method, 625; Fergusson's method, 626; Langenbeck's method, 623; Lannelongue's method, 625; results of, 630; treatment after, 629.
- Urine, examination of, after operation, 118; suppression of, after anæsthesia, 21.
- Uvula, elongated, 631.
- Van Bergmann's method of preparing catgut, 91.
- Van Buren's operation for salivary fistula, 632.
- Varicose veins, operative interference by acupressure, 216; operative interference by injection for, 216; excision of a portion of the saphenous vein for (Fergusson), 218; incision around leg for (Schede), 218; ligature of the internal saphenous vein for (Trendelenburg), 217; operations on, 215; subcutaneous ligaturing of, 216; treatment of, by incision and ligaturing, 217; treatment of, by excision, 217.
- Varnish, antiseptic, Whitehead's, 639.
- Vascular growth, introduction of setons into, 225.
- Vascular guides to an artery, 125.
- Vaso-motor center in collapse, 120; in shock, 120.
- Vein, companion to large arteries, 125; external jugular, as a guide to the third portion of the subclavian, 172; jugular, craniotomy for thrombosis of, 260.
- Veins, air in, 122; and capillaries, operations on, 215; color of, 126; ligature of, 215; relation of, to arteries, 126; varicose, operations on, 215.
- Velpeau's incision for complete excision of upper jaw, 368.
- Venæ comites, 125; ligature of, with artery, 153.
- Venesection, 218; amount of blood taken in, 219; arrest of blood flow after, 219; at external jugular, 219; at median cephalic, 218; instruments for, 218; selection of veins for, 218.
- Venous infusion, precautions for, 221; the operation of, 220.
- Ventricles, injection of saline solution into, 228; tapping of the, for chronic hydrocephalus, 227.
- Vernale's amputation of thigh, equilateral-flap method, 533.
- Vernuil's operation of rhinoplasty, 585; operation of rhinoplasty, remarks on, 586; subastragaloid amputation, 508.
- Vertebral artery, anatomical points of, 174; linear guide to, 175; muscular guide to, 175; points for ligature of, 175; relations of, 174.
- Vertebral artery, ligature of, 174; Alexander's method, 176; before entering vertebral canal, 175; between atlas and axis, 176; between atlas and occipital bone, 177; precaution in, 176.
- Vertical frontal fissure, 249.
- Vessel, closure of, *en masse*, 96; opening sheath of, 127; selection of, for ligature, 126.
- Vessels, color of, as a guide to an artery, 125; empty, 9, 57; healthy condition of, as hæmostatic, 65.
- Vogt's excision of ankle joint, 413.
- Volkman's division of neck of femur, 437; division of neck of femur, results of, 437; inter-trochanteric osteotomy of femur, 438.
- Vomiting after anæsthesia, 20.
- Washing soda in preparation of dressings, 112.
- Water, as a local anæsthetic, 36; boiled, as a menstruum, 62; hot and cold, as styptics, 68.
- Wax, Horsley's, 236.
- Webbed fingers, 563; remarks on, 567.
- Webbed fingers, operation for, Agnew's, 566; Dec's, 564; Diday's, 564; Fowler's, 566; Norton's, 564; Rudtlofffer's, 564; Zeller's, 566.
- Webber's incision for raising superior maxilla, 660.

- Weber's method of flap transfer in plastic surgery, 574; operation of rhinoplasty, 583.
- Weeping sinew, 352.
- Weir's method of cleansing the hands, 114.
- Whalebone tissue ligatures, 93.
- Whiskey, 119; in shock, 121; with anæsthetics, 35.
- White's radical excision of hip joint, 426.
- Whitehead's antiseptic varnish, 639.
- Willett's method of shortening the tendo Achillis, 343.
- "Wipers," 63; relation of, to surgeon, 64.
- Wire saw, Gigli-Haertel, 243.
- Wire *serre-fines*, 78.
- Wire sutures, silver, 98, 102.
- Witzel's method of tendon suturing, 340.
- Wladimirow-Mikulicz, osteoplastic resection of tarsus, 415.
- Wolff's artificial larynx, 708.
- Wöllner's quilt suture in tendon suturing, 340.
- Wood-pulp dressing, 112.
- Wood-wool dressing, 112.
- Wound, closure of a, 99; drainage of, 104; dressing of, after operation on thyroid, 723; douching of, 108; treatment of, after operation, 118.
- Wounds, gunshot, of the cranium, 266; of neck, 723; of neck, treatment of, 724; treatment of operation, 96.
- Wright on use of calcium chlorid in hæmophilia, 67.
- Wrist oint, amputation at, 477; circular-flap method, 477; double-flap method, Ruysch's, 478; radial flap, Dubrucil's, 479; remarks on, 479; results of, 479; single palmar flap, 478.
- Wrist joint, excision of, 400; excision of, complete subperiosteal, Langenbeck's, 402; complete subperiosteal, Lister's, 404; complete subperiosteal, Ollier's, 403.
- Wryneck, 561; spasmodic, resection of spinal accessory and cervical nerves for, 562; treatment by open method, 561; treatment by open method, remarks on, 562.
- Wyeth's amputation at ankle joint, 511; method of controlling hæmorrhage in amputations at the hip, 542; method of treating vascular growths, 226; needles in amputation at shoulder joint, 487; pegs after excision of knee joint, 422; pin, 75.
- "X" rays, location of bullet by, 267.
- "Z" method of shortening tendo Achillis, 343.
- Zeller's operation for webbed fingers, 566.
- Zinc chloride, solutions of, 60.
- Zinc, sulphocarbolate, solutions of, 60.
- Zuckerkandl's extrabuccal operation on buccal nerve, 290.

THE SURGICAL DISEASES OF THE GENITO-URINARY ORGANS.

NEW SECOND EDITION, REVISED AND ENLARGED

By E. L. KEYES, A.M., M.D., LL.D.

Consulting Surgeon to the Bellevue and the Skin and Cancer Hospitals; formerly Professor of Genito-Urinary Surgery, Syphilology, and Dermatology at the Bellevue Hospital Medical College, etc.; and

E. L. KEYES, JR., A.B., M.D., PH.D.,

Adjunct Professor of Genito-Urinary Surgery, New York Polyclinic Medical School and Hospital; Assistant Visiting Surgeon to St. Vincent's Hospital; Special Lecturer on Genito-Urinary Diseases, Georgetown University Medical School, etc.

Cloth, \$5.00; half leather, \$5.50.

Sold only by Subscription.

WITH ONE HUNDRED AND SEVENTY-FOUR ILLUSTRATIONS IN THE TEXT AND ELEVEN PLATES, EIGHT OF WHICH ARE IN COLORS.

"It is certainly refreshing that a man of the experience and ability of the author of this volume has culled from this mass of literature the essentials, and given us in a well-planned volume the gist of the entire subject.

"The book is systematically arranged, and each subject is taken up and dealt with in a way that makes it easily accessible to the busy practitioner. The style is explicit and never verbose, which, with the fine vein of humor running through it, makes it very enjoyable reading."—*Northwestern Lancet*.

"Gonorrhea is gone into more extensively than in any other work."—*Denver Medical Times*.

"As a text-book on Genito-Urinary Surgery it stands at the head of the publications on the subject in the English language. Our readers wishing an up-to-date work on the subject can not do better than to buy this latest and newest work."—*Medical Century*.

"The book is well illustrated, well printed, well arranged, and will be more popular than its predecessors."—*Chicago Medical Recorder*.

"The chapters on the affections of the posterior urethra, prostate and seminal vesicles are especially good, and many 'pointers' are found in the chapter on the 'Treatment of Urethral Inflammation and their Immediate Complications.'"—*Canada Medical Record*.

"This is a good book on an important subject. Within the compass of 800 pages it gives a comprehensive treatment of the various diseases of this special branch of surgery, and, while not discarding the good of the older work, it embraces all that is new in this field."—*Journal of Medicine and Science*.

"This is so well written as to be exhaustive in character, and needs little or no comment from the reviewer further than to mention its completeness in every particular."—*Cincinnati Lancet-Clinic*.

D. APPLETON AND COMPANY, NEW YORK.

DISEASES OF THE HEART AND ARTERIAL SYSTEM

By ROBERT H. BABCOCK, A.M., M.D.

Professor of Clinical Medicine and Diseases of the Chest, College of Physicians
and Surgeons (Medical Department of the Illinois State University),
Chicago; Attending Physician to Cook County Hospital for
Consumptives; Fellow and former President of the
American Climatological Association, etc.

Three Colored Plates and One Hundred and Thirty-nine
Illustrations in the Text. 8vo. Cloth, \$6.00

SECOND EDITION

SOLD ONLY BY SUBSCRIPTION

"This treatise is evidently the result, not only of large clinical experience, but of wide reading and careful reflection. The author disclaims any pretense of originality, but it is open to question whether the conclusions and results of a ripe judgment, such as are presented in this volume, are not worth quite as much as some academic so-called original work. Certainly a large amount of material, both clinical and literary, has been worked out and presented in a most clear, succinct, and practical manner. The author's style is pleasing and without ambiguity, nor is the text over-loaded with unnecessary technical terms. After a careful perusal of Dr. Babcock's book there are two features which strike the reader as characteristic and valuable. These are, on the one hand, the case histories, and, on the other, the unusual number and value of the pages devoted to the therapeutics of the subject. The narration of cases, although at times in much detail, does not cause the usual weariness of flesh in the reading, mainly because of the interesting manner in which they are written. They are particularly well chosen to illustrate the manifold varieties of disease and the practical wisdom required in the management of actual cases. Regarding the therapeutic side of the work none but words of praise are required. So far as the reviewer's reading goes there is no more complete and reliable exposition of the treatment of circulatory disease than that found in this volume. That this high commendation is deserved will readily be admitted after reading chapters 16, 17, and 18 upon the treatment of valvular heart disease. These chapters are distinguished by a fulness of detail and a variety of therapeutic resource which cannot but prove of great value, not only to the young practitioner, but, as well, to the clinician of years.

"The book can be unhesitatingly recommended as a distinct acquisition to one's working library."—*Brooklyn Medical Journal*.

"We commend to our readers this work of Babcock's as a very desirable work for both the specialist and the practitioner, and wish the author a most hearty welcome for his admirable literary endeavor."—*Medical News*.

D. APPLETON AND COMPANY, NEW YORK.

CANCER OF THE UTERUS:

Its Pathology, Symptomatology, Diagnosis, and Treatment; also
the Pathology of the Diseases of the Endometrium.

By THOMAS STEPHEN CULLEN, M. B.
(Toronto), Associate Professor of Gynecology in the Johns Hopkins University.

ILLUSTRATED BY MAX BRÖDEL AND HERMAN BECKER.

Complete in One Royal Octavo Volume of about 700 pages,
Twelve Colored Plates, and Three Hundred Illustrations in the Text.

Cloth, \$7.50; half morocco, \$8.50.

Sold only by subscription.

“He presents in the book before us all of value that is known upon the subject. The book is of great value to the pathologist, to the family physician, and to the surgeon. The chapters on the early recognition of cancer are so distinct and clear that a wayfaring man, though a general practitioner, should not err in giving or directing prompt and efficient relief.”—*Medical News, New York.*

“A work of this class is an addition of real value to medical literature.”—*Boston Medical and Surgical Journal.*

“We know that the Baltimore school of medicine has carried the utilization of clinical and scientific material almost to perfection, and this volume is a fresh witness to this truth. Lastly, the clinical features of the different varieties of uterine cancer and of innocent disease which simulate it are described very clearly so that Dr. Cullen's volume will be as useful to the practitioner as to the specialist and the teacher of pathology.”—*British Medical Journal.*

“It represents the latest exposition of all that is known about cancer of the uterus, and we may say at once that as a monograph on this subject it absolutely eclipses any previous work. No one who wishes to be well informed on the subject of cancer of the uterus can afford to be without it.”—*Medical Press and Circular, London.*

D. APPLETON AND COMPANY, NEW YORK.

DISEASES OF THE ANUS, RECTUM, AND PELVIC COLON.

SECOND REVISED AND ENLARGED EDITION.

By JAMES P. TUTTLE, A.M., M.D.

Professor of Rectal Surgery, New York Polyclinic Medical School and Hospital; Visiting Surgeon to the Almshouse and Workhouse Hospital; Fellow of New York Academy of Medicine; Fellow of Chicago Academy of Medicine, etc.

EIGHT COLORED PLATES, THREE HUNDRED AND THIRTY-EIGHT
ILLUSTRATIONS IN THE TEXT.

Cloth, \$6.00; Half Leather, \$6.50.

SOLD ONLY BY SUBSCRIPTION

"Probably no book that has appeared this year has been looked forward to with so much anticipation as this work of Dr. Tuttle. Not only has the author gained an enviable national reputation as a specialist in his chosen field, but he is widely known also as a successful teacher in this comparatively new specialty. Great expectations are apt to meet with disappointment, but in this instance there is a marked exception. The book is almost encyclopedic in the amount of information it contains, and yet the information is presented in a concise and attractive style. The illustrations in the book are on a high plane of artistic merit; they are readily understood, and are also instructive. The work is destined to become the authority on this subject for both the specialist and the general practitioner."—*The New York State Journal of Medicine.*

"This volume deals with one of the most important departments of medicine and surgery, and one which is progressively attracting more and more attention. A long experience in one of the largest rectal clinics in the world has peculiarly fitted the author to discuss the subject in an exhaustive manner. While in great measure the volume reflects the personal experience of the author, much attention is nevertheless given to the ideas and results of other operators, and in every instance the reader is afforded an opportunity to choose between the different methods of management or treatment proposed. It is by no means exclusively a surgical work, for much attention is devoted to the medical management of the diseases of the anus, rectum, and pelvic colon. A great deal of attention has been devoted to the examination, diagnosis, and local treatment of rectal diseases, and the chapters devoted to these subjects are nowhere excelled in the English language; chapters which every practising physician and surgeon could and should read with much profit, for in no department of medical science is the general practitioner more lamentably weak than in the examination, diagnosis, and management of rectal disorders."—*Medical News.*

"We are pleased to observe that medical as well as surgical treatment has received the most painstaking consideration, and the treatise is a remarkably well-balanced one. The embryology, anatomy, and physiology of the parts concerned are discussed with thoroughness and clearness, and the text is further enlightened by the beautifully executed drawings to which we have referred. The subject of rectal feeding is discussed with full regard for the practical side. The author has included a large number of carefully selected formulæ for rectal feeding. In our opinion the chapters devoted to the consideration of malignant neoplasms, containing as they do the most accurate and clear description of operative procedures, are worthy of the highest praise. No less admirable is the somewhat brief but well-presented discussion of constipation, obstipation, and fecal impaction."—*The Philadelphia Medical Journal.*

D. APPLETON AND COMPANY, NEW YORK.

257-52
37

161



COLLEGE OF OSTEO

Bryant, Joseph
Operative surgery

WO 500
B915 o
1905
v.1

**MEDICAL SCIENCES LIBRARY
UNIVERSITY OF CALIFORNIA, IRVINE
IRVINE, CALIFORNIA 92664**

